

# SMILE DESIGN: FROM DIGITAL TREATMENT PLANNING TO CLINICAL REALITY

*Christian Coachman, DDS, CDT*

*Eric Van Dooren, DDS*

*Galip Gürel, MSc*

*Cobi J. Landsberg, DMD*

*Marcelo A. Calamita, DDS, MSD, PhD*

*Nitzan Bichacho, DMD*



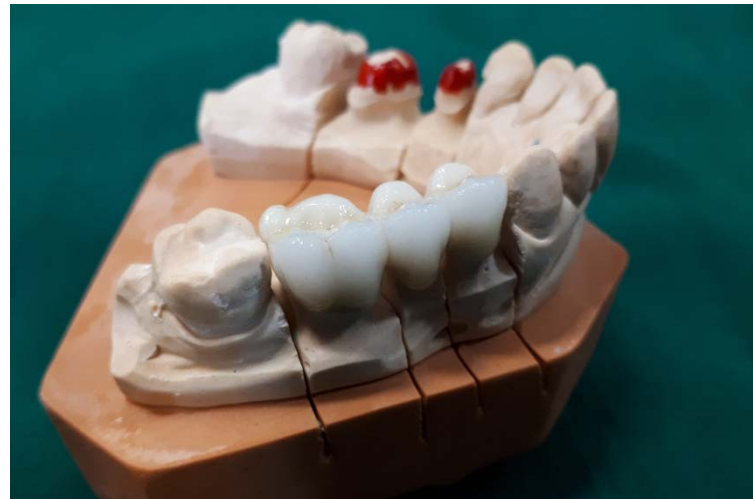
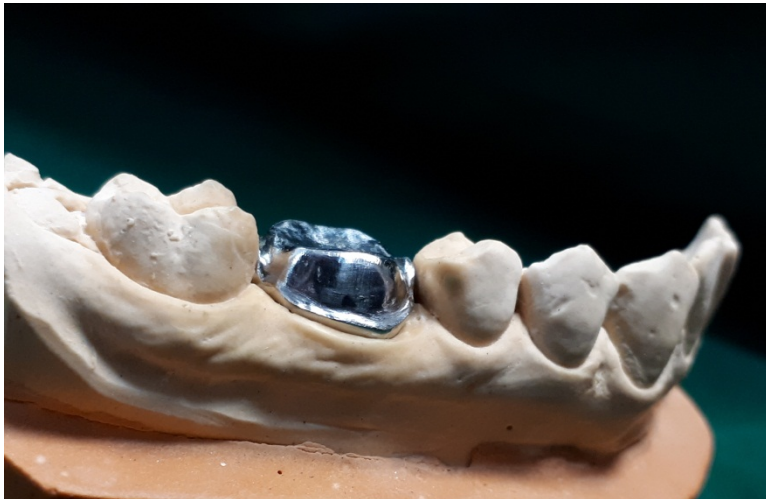
# مرکز تخصصی پروتزهای دندانی هایک دنت

طراحی و ساخت انواع پروتزهای دندانی بویژه ایمپلنت  
برگزار کننده دوره های آموزشی تخصصی و جامع دندانسازی و...

**با ما همراه باشید...**

**[WWW.HIGHDENTlab.com](http://WWW.HIGHDENTlab.com)**



## EDITOR'S INTRODUCTION

One of dentistry's most challenging dilemmas relates to whether or not we can actually meet or exceed patients' expectations for treatment in the esthetic zone. The world's most prominent clinician-lecturers would have you believe so. Dental publications, advertisements, and media saturation also dramatically increase patient expectations. The reality is that this may not be the case.

Professional audiences are dazzled by bone and soft tissue augmentation procedures that result in exquisite dental outcomes and engaging smiles. But are these results reproducible chairside each and every day? Are there limits to what is actually achievable? What can we promise our patients, if anything?

This chapter addresses severe deformities and failure in the esthetic zone. There are no "magic bullets" here. Compromise is an integral part of the treatment landscape, and part of this process is setting realistic expectations with the patient before any treatment is instituted. And yet, with new diagnostic methodologies, the introduction of digital treatment planning, and masterful laboratory procedures, even compromise can result in stunning results and delighted patients.

The suite of cases presented in this chapter by three master clinicians and a dedicated team of master laboratory technicians all have been designed with compromise in mind, readily accepting that the "ideal" is not readily achievable or even possible. Practicality prevails, and with some ingenuity (use of the concept of "smile design"), effective communication in a collaborative team setting, and an understanding patient, treatment results can be quite gratifying.

Drs Christian Coachman and Marcelo Calamita first introduce the reader to the concept of smile design. Drs Bichacho, Landsberg, Gürel, and Van Dooren then offer cases for the reader to treatment plan, incorporating the concept of smile design into their presentations. Finally, Drs Coachman and Calamita describe in the Commentary section the practical aspects and workflow of digital smile design (DSD). Dr Coachman provided the laboratory support for all of the treatment-planning cases. He has been the conceiver and link to the treatment modality employed by each clinician in achieving these remarkable outcomes.

## AUTHORS' INTRODUCTION

With the increasing demand for highly customized treatment in contemporary esthetic dentistry, it is paramount to incorporate tools that can strengthen our diagnostic vision, improve the communication between the team members, and create predictable systems throughout the smile design process and treatment.

In order to obtain consistent outcomes, the design of the restorations should be defined as soon as all diagnostic data is gathered, guiding the subsequent phases of the rehabilitation.<sup>1</sup> Every work of art requires an initial visualization: In architecture, painting, or sculpture, it is necessary to make use of plans, drafts, or prototypes. They are two-dimensional (2D) or three-dimensional (3D) representations of the final outcome, and once developed, they will guide the processes of drawing, modeling, and building. Similarly, in dentistry, all of the patient's needs and desires and functional and biologic issues must be scientifically incorporated into the esthetic treatment design and serve as a frame of reference for all of the treatment that will be performed.<sup>2,3</sup>

The aim of this chapter is to present a unique concept of 2D DSD, which will provide important parameters to guide an effective 3D diagnostic wax-up. The DSD is based on the use of high-quality digital images—static and dynamic—that are essential for analysis, documentation, and communication in contemporary esthetic dentistry<sup>4</sup> and can also be used as a basis to perform a series of diagnostic procedures, adding critical data to the process of treatment planning.

Prior to treatment planning the cases in this chapter, the reader should understand the concept and diagnostic rationale of DSD. DSD allows a gradual discovery of many critical factors involved in simple or complex restorative cases that might have been overlooked during the clinical, photographic, or study cast evaluation. The drawing of reference lines and shapes over high-quality images on a computer screen following a predetermined sequence widens the diagnostic vision and helps the team measure limitations and risk factors such as asymmetries, disharmonies, and violations of esthetic principles. Choosing the appropriate technique is easier once the problem has been identified and the solution clearly visualized.

The DSD protocol is characterized by effective communication between the interdisciplinary team members, including the dental technician. It is also an amazing tool for communication with patients, enabling them to better visualize the issues and possible solution, balancing their expectations, and increasing their commitment to and trust in the team. By increasing understanding of the issues involved, the clinician can better explain the treatment plan, transforming future retrospective excuses into prospective explanations. Team members can identify and highlight discrepancies in soft or hard tissue morphology, discussing—with the aid of digitally magnified and measured images on the monitor—the best possible solutions for the case. Every team member can add information directly on the slides, in writing or using voiceover, simplifying the process even more. All team members can access this information whenever necessary, changing or adding new elements during the diagnostic and treatment phases. The use of the DSD can make the diagnosis more effective and the treatment planning more complete, and the effort required to implement it is rewarded as the treatment sequence becomes more logical and straightforward, time and materials are saved, and the costs of treatment are reduced.

The following cases have been chosen for treatment planning in this chapter because they present significant challenges in achieving optimal esthetic outcomes. Compromise was accepted in all of these cases, and yet with meticulous and careful analysis of the diagnostic information and some extremely well-organized and creative planning, exceptional outcomes were achieved. Compromise is not necessarily akin to defeat. It should be considered an opportunity to achieve gratifying treatment results using alternative methods. Each case has its own unique lessons to be shared with the reader.

The first case presentation focuses on the advantages of performing a precise esthetic analysis through digital photography and digital design. The lines and drawings clearly illustrate the challenges and provide very important insights into potential solutions. The patient's focus was short treatment duration because her wedding was scheduled in 3 months.

The second case presentation shows the advantages of performing a white and pink mock-up to communicate to the patient the esthetic issues to be faced in treatment. This case also addresses the importance of understanding both tooth morphology for proper shaping of the teeth as well as gingival design. The patient's main objective was to achieve the best possible esthetic outcome despite past negative dental experiences.

The third and final case presentation shows the importance of the diagnostic wax-up in guiding treatment planning and in visualizing the defect and the challenges that the clinician is going to face. The wax-up also guides the fabrication of acceptable provisional restorations and surgical stents. The patient's focus was minimally invasive treatment because of previous traumatic dental experiences.



# PROSTHETIC CHALLENGES ASSOCIATED WITH THE IMPLANT- SUPPORTED RESTORATION IN A DEFICIENT RIDGE

*Nitzan Bichacho, DMD*

*Cobi J. Landsberg, DMD*



Treating missing teeth in the esthetic zone is always a challenge when improved function and a natural appearance are the primary goals. When the supporting tissue foundation is impaired, the risks associated with the treatment become much higher and the outcomes considerably more speculative.

We chose this case because it exemplifies realistic clinical quandaries that we confront in practice every day. It also represents what is possible when obstacles are formidable and options few.

This case presentation combines some initial treatment that was performed in the late 1990s with more recent dental implant therapy and underscores the attendant challenges with ridge deficiencies in the esthetic zone. The treatment of three missing maxillary incisors with implant-supported restorations is described and analyzed. The surgical and prosthetic phases of the treatment resulted in a compromised outcome, and 10 years later the treatment site was prosthetically re-treated.

# CASE PRESENTATION

*Treating clinicians*

*Prosthodontist:* Nitzan Bichacho, DMD

*Periodontist and implant surgeon:* Cobi J. Landsberg, DMD

*Dental laboratory and smile designer:* Christian Coachman, DDS, CDT

## CLINICAL TREATMENT PLANNING

Age at initial presentation: 17 years

Initial presentation: November 1998

Active treatment completed: August 2010

## Introduction and background

A 17-year-old girl presented to the clinic unhappy with her appearance after prolonged orthodontic treatment. She was in a car accident a year earlier that resulted in a fracture of the right condyle, loss of tooth no. 8, and intrusive luxation and mesial displacement of tooth no. 9. This tooth had not lost its vitality. After a year of intensive dental care she was quite discouraged by the orthodontic result, making her reluctant to smile.

## Medical history

- Noncontributory

## Diagnostic findings

### *Extraoral and facial findings*

- High lip line
- Maxillary midline shifted to the right
- Noticeable anterior ridge deficiency where tooth no. 8 had been lost

### *Intraoral findings*

#### Dental

- Tooth no. 9 apically displaced
- Open occlusal relationship in the central incisor area
- Disproportionate sizes of the one remaining maxillary central incisor and the pontic that had replaced missing tooth no. 8 and was attached to the archwire
- Missing tooth no. 8 and significantly reduced tissue volume
- Apically displaced tooth no. 9 shifted and tilted to the right, with a disproportionately large tooth crown compared with the other natural teeth

#### Periodontal

- Generally healthy periodontium
- Significant ridge resorption in tooth no. 9 area

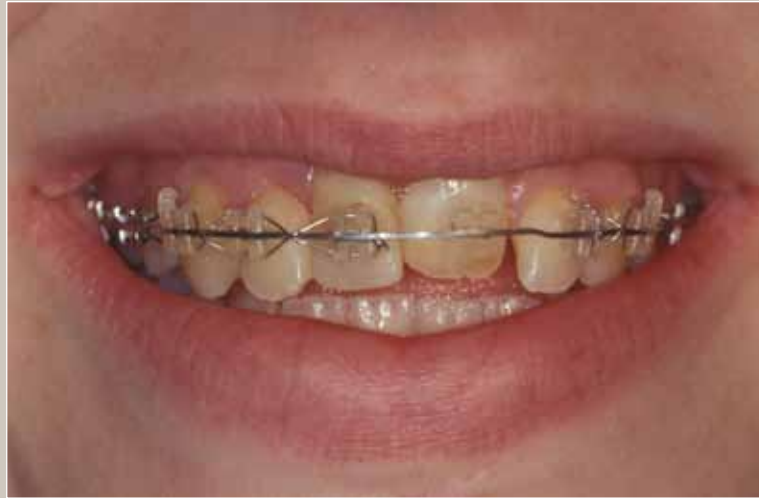### *Occlusal notes*

- Not able to accurately assess centric relation (CR) and centric occlusion (CO) due to previous orthodontic therapy
- Tongue thrust evident upon swallowing
- Moderate vertical and horizontal overlap evident with exception of apically displaced tooth no. 9

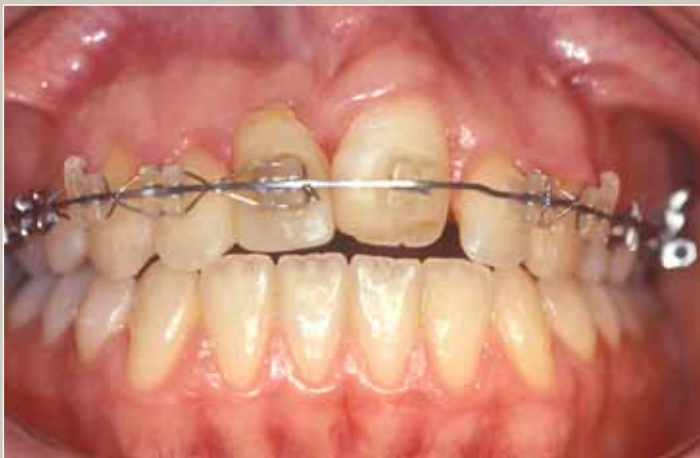### *Radiographic findings*

- Apically positioned tooth no. 9 exhibited a short root with presentation of a minimal periodontal ligament space and appeared ankylosed
- Tooth no. 7 showed a short root with internal and external cervical resorption
- Tooth no. 8 missing

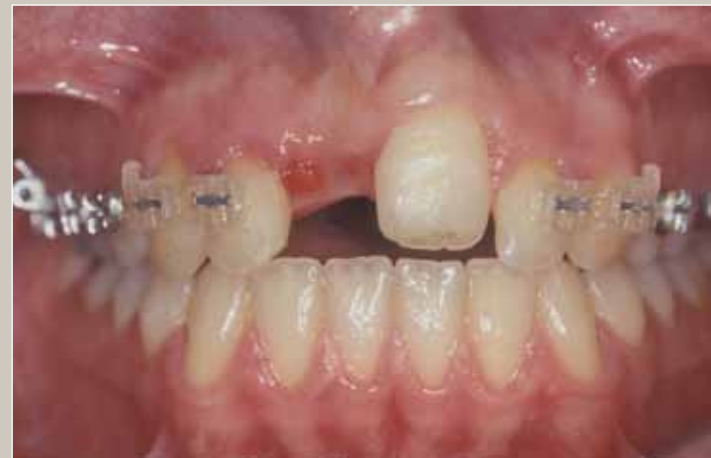## PRETREATMENT



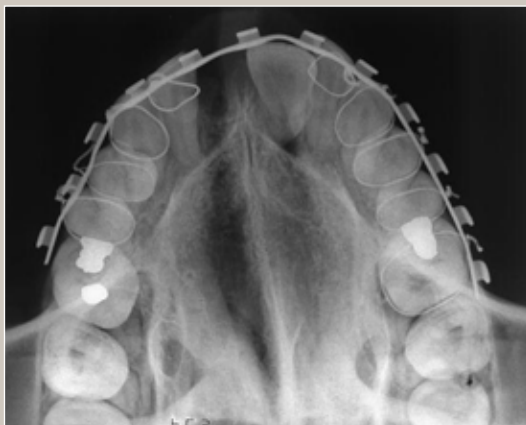Smile view.



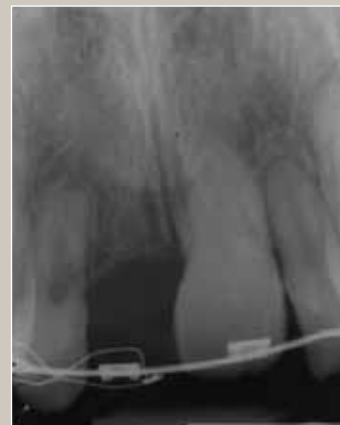Intraoral frontal view.



Removal of the archwire and pontic.



Occlusal radiograph of the maxilla.



Periapical radiograph of maxillary anterior teeth.

### *Diagnosis and prognosis*

- AAP Type II
- Tooth no. 7: hopeless because of a short root and cervical root resorption
- Tooth no. 8: missing with residual ridge defect
- Tooth no. 9: hopeless from a restorative perspective because it is ankylosed and malpositioned
- Tongue thrust

### *Summary of concerns*

1. With the anterior ridge deficiency in the area of tooth no. 9 and the prospect of possible esthetic compromise, would the treating clinicians be able to meet or exceed the patient's treatment expectations?
2. How much could realistically be gained from vertical ridge augmentation and would it be possible to reconstruct the edentulous ridge to reestablish all that had been lost from the traumatic injury?





## PROPOSED TREATMENT PLAN

### *Goals/objectives of treatment*

The clinicians opted to treat the affected site without involving the adjacent teeth. The patient declined any plan that would include a removable appliance. This applied to any provisional restorations as well. An implant-supported restoration would be designed; however, a number of treatment choices could still be considered:

1. Three implants to replace missing tooth no. 8 and the two adjacent teeth, which would be extracted
2. An anterior implant-supported fixed partial denture on teeth nos. 7 to 9 with a pontic in the no. 8 site
3. Two implants to replace missing tooth no. 8 and soon-to-be-extracted tooth no. 9, with the no. 7 position treated as a cantilevered pontic extending from the implant in site no. 8

Before establishing which treatment option to use, it was important to lay out the esthetic goals and objectives because this could help to determine which choice would most likely meet everyone's expectations. The three esthetic goals were to:

1. Rebuild the deficient horizontal volume
2. Create a harmonious gingival line with the adjacent natural dentition
3. Create scalloping of the gingival line confluent with the interproximal papillae

The treatment team evaluated the three options in terms of achieving the above goals and did not find any of the choices to be significantly superior to any of the others. Ultimately, it was decided that three implant placements would result in blunted or shortened papillae and probably the most compromised esthetic outcome. With two implant placements, the best choice seemed to be using sites nos. 8 and 9. The pontic area of site no. 7 would be the smallest and most likely subject to the least amount of vascular compromise following soft tissue augmentation. There would also be a positive influence on tissue height from the mesial of natural tooth no. 6. Therefore, the plan was to place implants in the nos. 8 and 9 areas and fabricate a cantilevered pontic in the no. 7 location.

### *Phase I: Provisional endodontic treatment of tooth no. 7*

This would involve pulp extirpation and filling with calcium hydroxide. Although it is somewhat unusual to perform root canal therapy on a tooth planned for extraction, this was considered necessary because of the length of time required for this tooth to act as an abutment in a provisional adhesive fixed partial denture while the central incisor sites were being developed and osseointegration was taking place.

### *Phase II: Extraction of tooth no. 9 with socket preservation*

### *Phase III: Implant placement with guided bone regeneration*

After waiting 6 months, two implants would be placed in the nos. 8 and 9 locations.

### *Phase IV: Implant exposure following osseointegration*

After waiting 6 months for osseointegration, the implants would be exposed.

### *Phase V: Extraction of tooth no. 7 with socket preservation and ridge augmentation*

After waiting approximately 8 weeks, tooth no. 7 would be extracted with simultaneous socket preservation and ridge augmentation.

### *Phase VI: Fabrication and seating of a provisional screw-retained acrylic fixed partial denture*

### *Phase VII: Definitive restoration*

Prosthetic rehabilitation with a screw-retained, implant-supported cantilevered fixed partial denture.

## ACTIVE CLINICAL TREATMENT

### *Review of the goals/objectives of treatment*

This patient was discouraged by the proposed solutions and treatment immediately following her traumatic injury. She was emphatic about not wanting a removable appliance but was open to any treatment plan that would restore her smile and self-esteem.

Due to the unsightly anterior ridge defect that was caused by the traumatic injury, there were some very specific goals and objectives set in addition to restoring the patient's overall morale. They included:

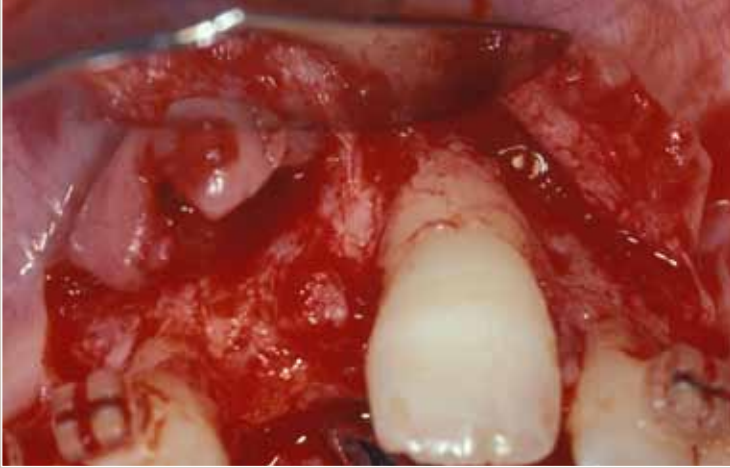- Rebuilding the maxillary ridge to restore 3D hard and soft tissue volume
- Re-creating a normal scalloped gingival appearance in harmony with the adjacent natural teeth
- Achieving overall esthetic enhancement

### *Phase I: Provisional endodontic treatment of tooth no. 7*

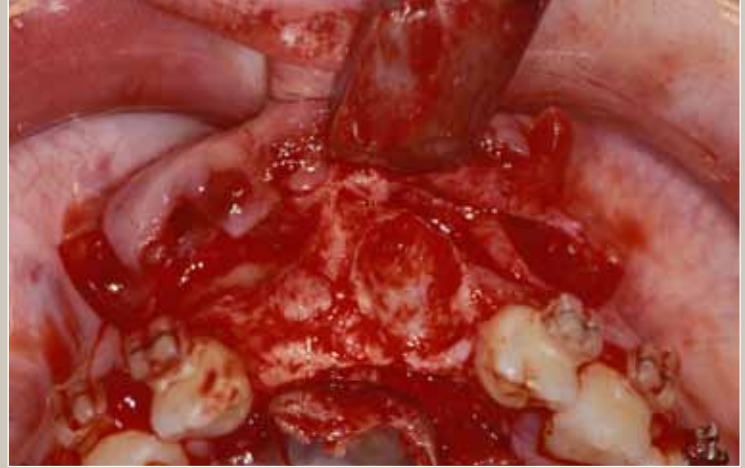Because this tooth was to be removed at a later stage in treatment, the pulp was extirpated and calcium hydroxide placed. Glass ionomer was introduced and forced through the canal in an attempt to block the resorption defect.

### *Phase II: Extraction of tooth no. 9 with socket preservation*

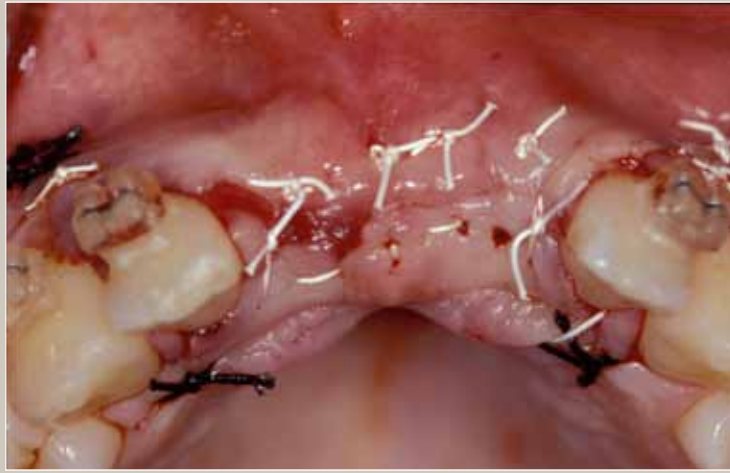Tooth no. 9, which was partially ankylosed, was carefully removed by hollowing out the internal aspect of the tooth until a thin shell remained. This shell was then infractured and remaining pieces of the tooth removed. A thin plate of buccal bone remained. After an analysis of the anatomy of the area, a decision was made to augment the ridge in two steps. Initially an attempt to preserve the socket dimensions was made using an expanded polytetrafluoroethylene (e-PTFE) membrane only. During a 4-month healing period, a six-unit adhesive partial denture was fabricated for the patient. At this time, the edentulous ridge, as anticipated, had not gained the adequate buccolingual dimensions for implant placement; however, the soft tissue covering the ridge was more than adequate to set the stage for a guided bone regeneration (GBR) procedure with simultaneous implant placement.



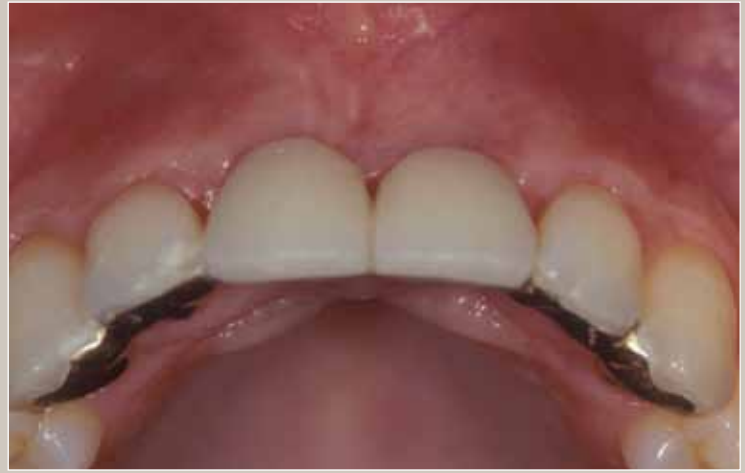Tooth no. 9 just prior to extraction.



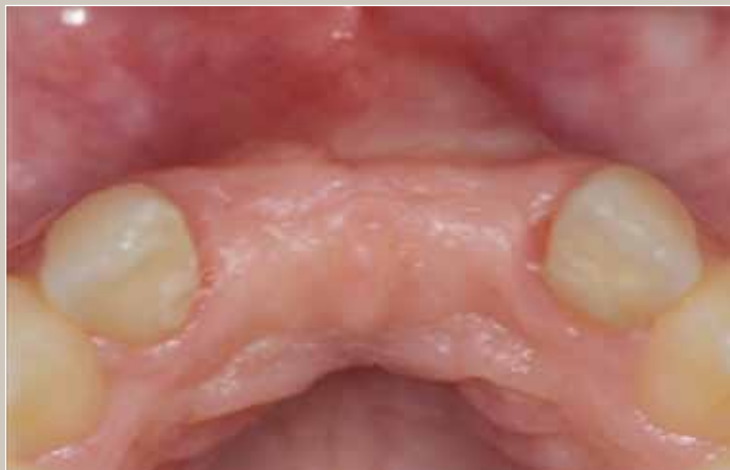Immediately following extraction of tooth no. 9.



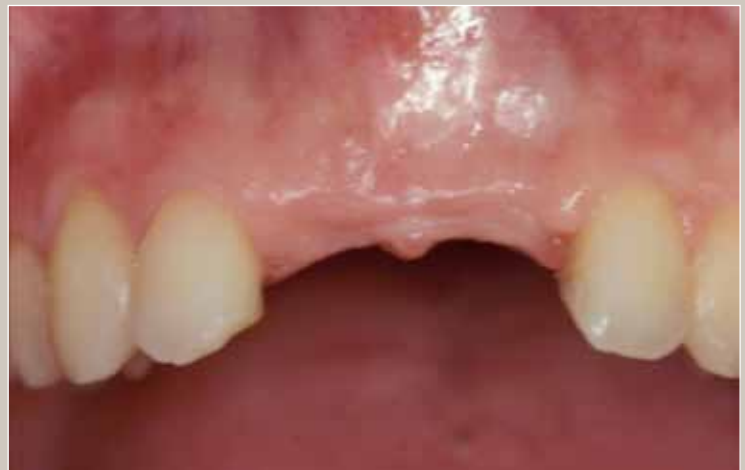Suturing following placement of e-PTFE membrane for socket preservation.



Occlusal view of six-unit adhesive provisional partial denture.



Occlusal view of sites nos. 8 and 9 after 4 months of healing.



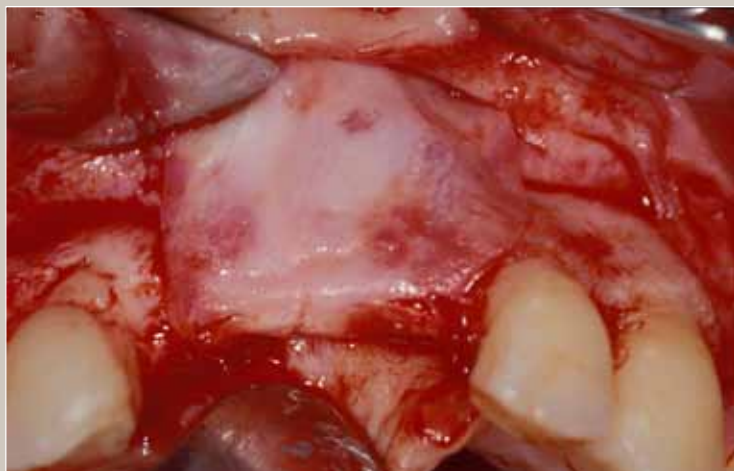
Frontal view of sites nos. 8 and 9 after 4 months of healing.

### *Phase III: Implant placement with guided bone regeneration*

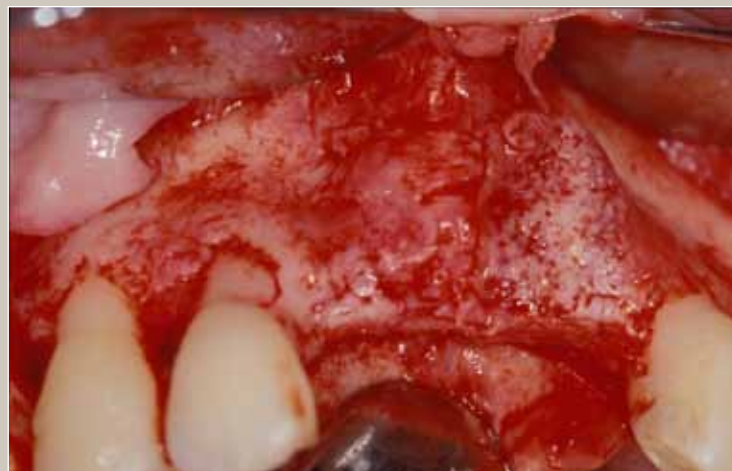Four months following socket preservation, the e-PTFE membrane (W. L. Gore) was uncovered and found intact with a typical sheath of connective tissue underneath. The ridge was fully exposed, and two implants (Steri-Oss external hex, 3.4-mm diameter; Nobel Biocare) were placed in sites nos. 8 and 9.

The ridge was simultaneously augmented with autogenous bone chips harvested from the chin as a first graft layer and deproteinized bovine (Bio-Oss, Geistlich) as a second layer. An e-PTFE membrane was fixed and adapted to cover the augmented ridge. The membrane was fully concealed by primary closure of the flaps with a combination of simple and mattress sutures.

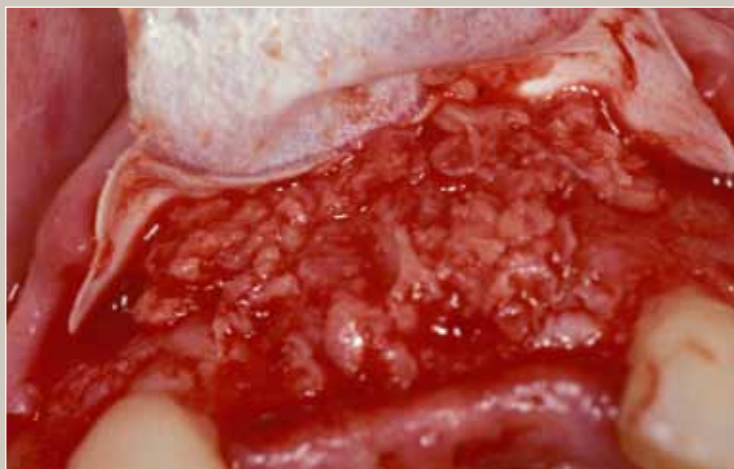



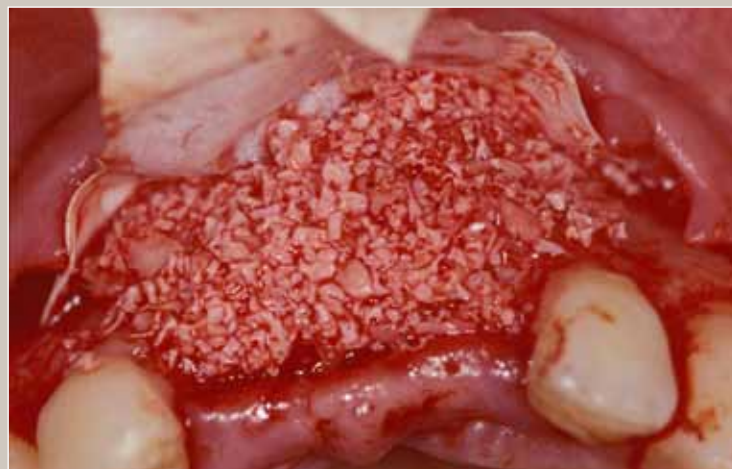
Uncovering of e-PTFE membrane.



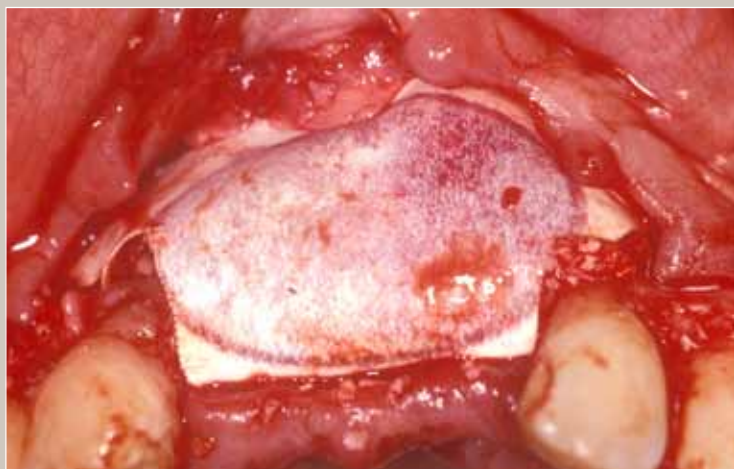Full exposure of ridge immediately prior to implant placement.



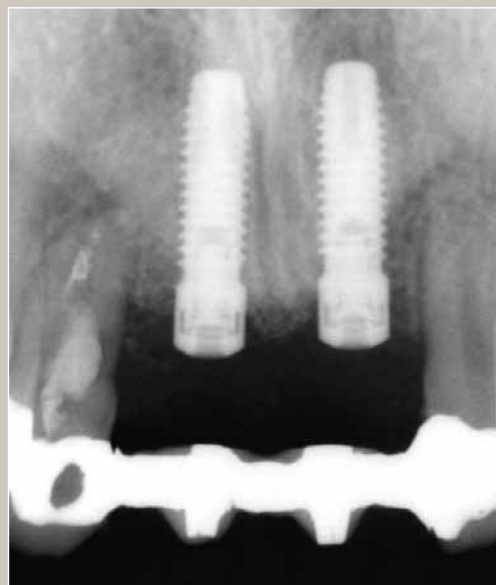
Placement of autogenous bone chips after implant placement.



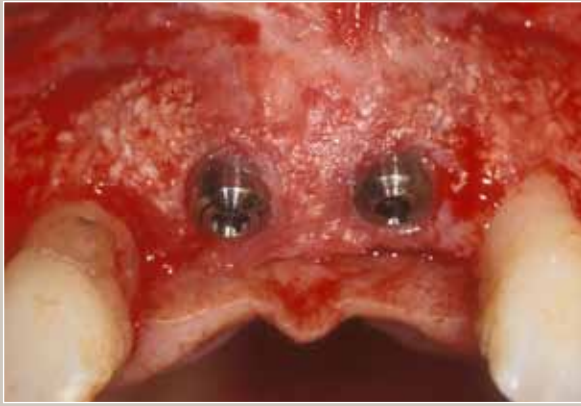
Placement of Bio-Oss as second graft layer.



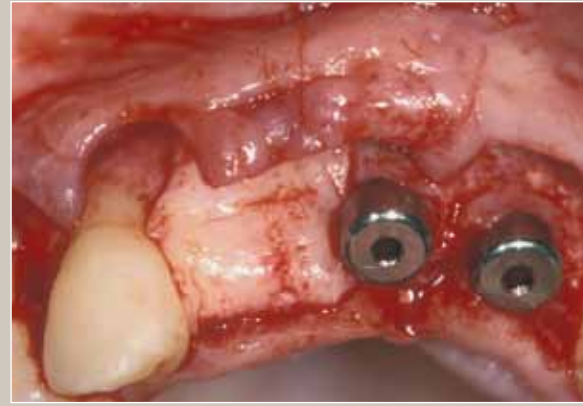
Adaptation of e-PTFE membrane.



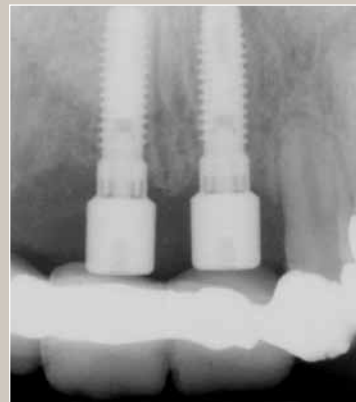
Radiograph following implant placement.



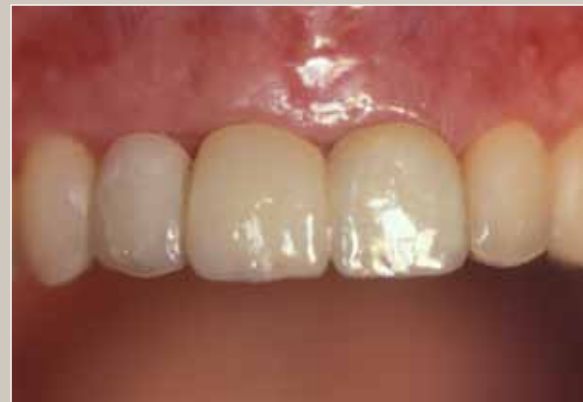Exposure of implants 6 months after placement.



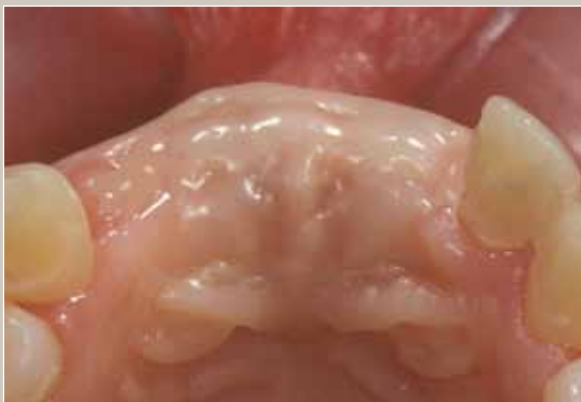Placement of connective tissue graft following extraction of tooth no. 7.



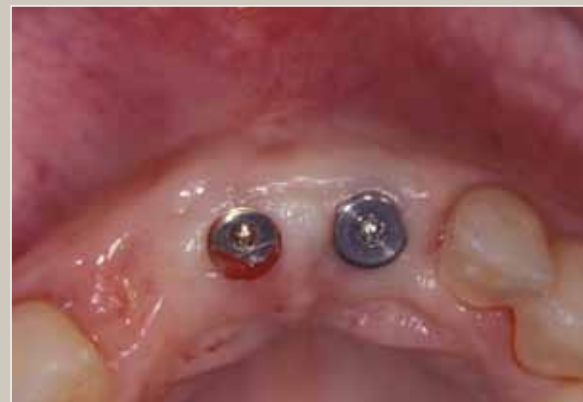Radiograph of healing abutments and new adhesive fixed partial denture.



Intraoral frontal view of adhesive provisional partial denture with three pontics.



Occlusal view of edentulous ridge after 3 months of healing.



Following tissue punch exposure of implants.

#### *Phase IV: Extraction of tooth no. 7 and socket preservation and ridge augmentation*

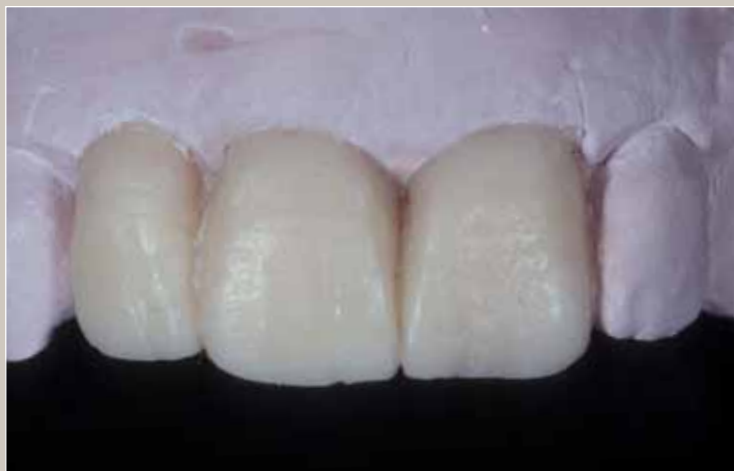Six months later, the membrane was removed, and the implants in sites nos. 8 and 9 were exposed. Two healing abutments (4 mm in height) were connected, and the buccal flap was advanced to fully cover them. Tooth no. 7 was extracted at the same time, and the extraction site was filled with bovine bone to help preserve as much of the ridge as possible. A connective tissue graft was placed as an onlay over the grafted bone. The buccal flap, which covered the abutments, was also

advanced to cover the extraction site. During a healing period of 3 months, a new adhesive partial denture with three pontics was bonded to the adjacent teeth.

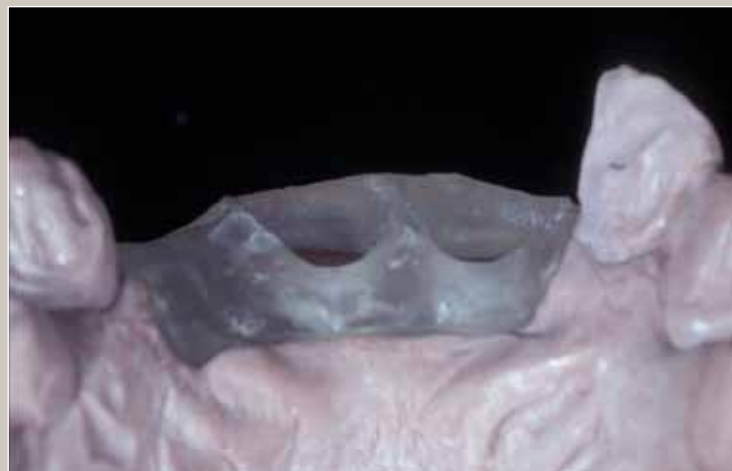#### *Phase V: Implant exposure at site no. 7*

At 3 months, because the edentulous ridge (no. 7 site) had gained sufficient volume, it was found suitable to expose the implants using a biopsy punch without the need for flap elevation.

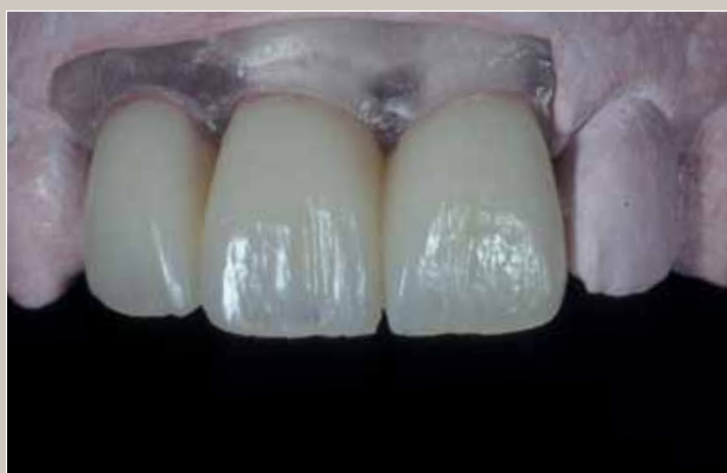



Diagnostic wax-up.



Redesign of the peri-implant mucosa on the working cast.



Provisional acrylic restoration connected to implant replicas.

### *Phase VI: Fabrication and seating of a provisional screw-retained acrylic fixed partial denture*

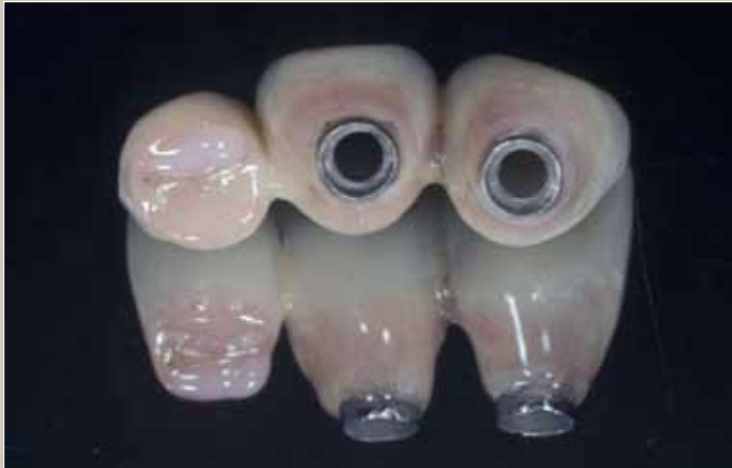It was decided to restore the missing teeth with a three-unit, screw-retained (UCLA-type) fixed partial denture to avoid the negative consequences of excess cement entrapment apical to the crown-abutment margins that might occur with a cement-retained fixed partial denture over screw-retained abutments.

A conventional method for taking impressions was used for the implants and adjacent tissues. Narrow impression transfers were used with an open-tray method, and a stone master cast was poured. A diagnostic wax-up was used to assess the optimal tooth dimensions and the curvature of the gingival line of the teeth to be restored.

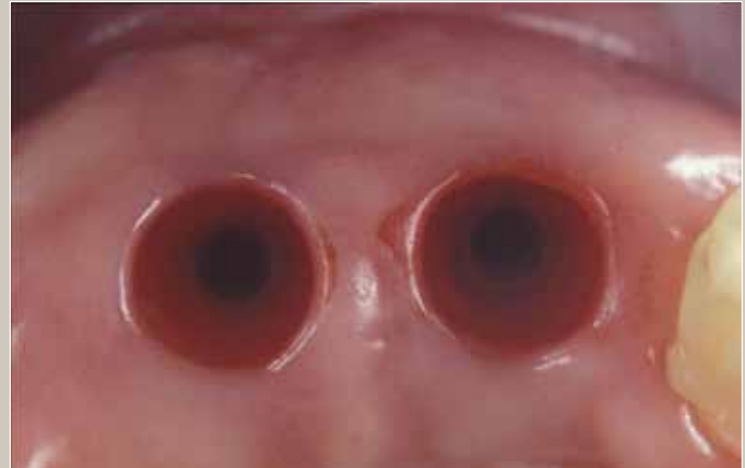
The authors' experience has shown that the most predictable and efficient way to achieve optimal esthetic integration of the implants with the soft tissues (in cases of delayed placement and restoration) is by implementing a cervical contouring concept. A prerequisite for this technique is having excess

soft tissue that can be prosthetically manipulated surrounding the head of the implant. The replica of the peri-implant mucosal envelope is redesigned to its desired 3D configuration on the laboratory master cast. Then the transmucosal prosthetic component is designed to match and support the desired new "mucosal" configuration. Subsequent intraoral connection of the prosthetic component will force the surrounding mucosa into its predesigned optimal configuration.

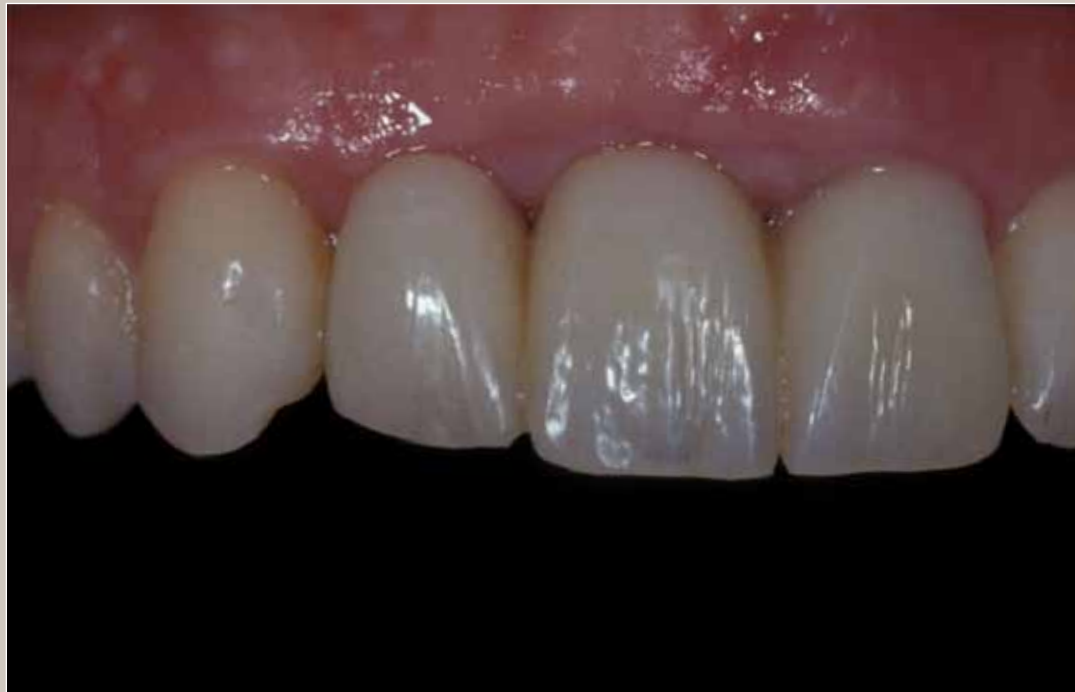Redesign of the peri-implant mucosa was created on the working cast in a removable clear acrylic resin in the desired shape to match the diagnostic wax-up. A three-unit provisional fixed partial denture (metal-reinforced acrylic resin) was created to match the tooth form of the diagnostic wax-up and the newly scalloped mucosa replica. The submergence profiles of the implant provisional crowns were designed with convex proximal contours to support the papillae, whereas the buccal submucosal aspect was made relatively flat in order to avoid excessive pressure on the labial mucosa. The provisional fixed partial denture blended naturally with the adjacent teeth and the surrounding mucosa.



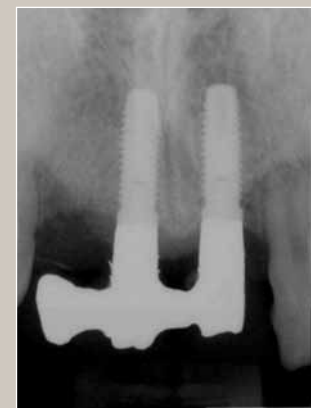
Implant provisional crowns with convex proximal contours and flat buccal submucosal aspects.



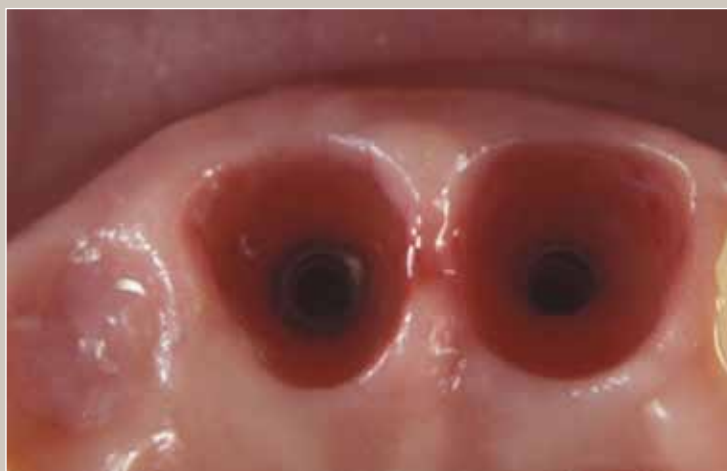Occlusal view of implant heads and peri-implant mucosa following removal of healing abutments.



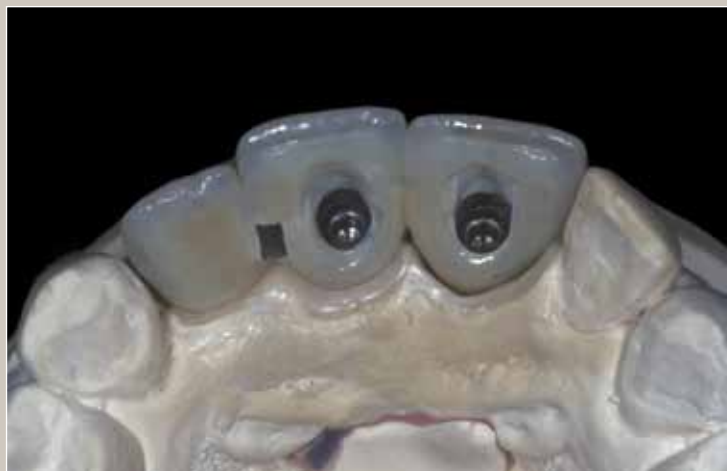Provisional fixed partial denture in place.



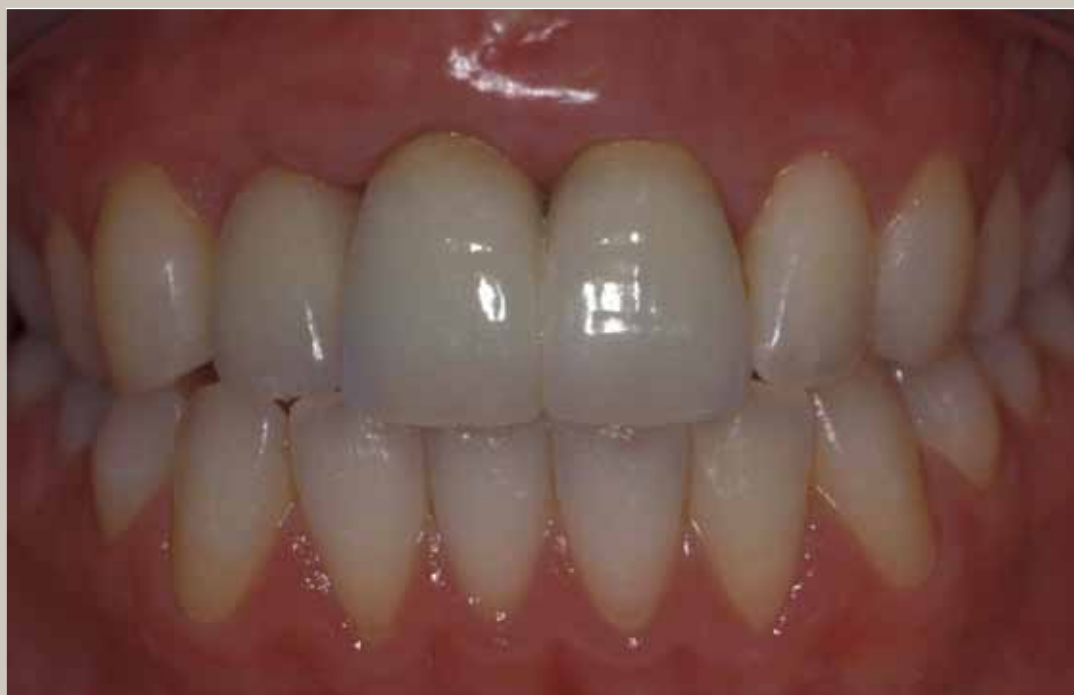Radiograph with provisional fixed partial denture in place.



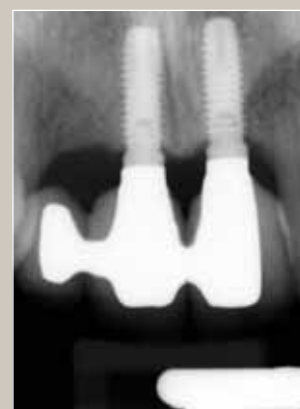Occlusal view of peri-implant mucosa and pontic sites following removal of provisional restoration.



Occlusal view of definitive restoration on the cast.



Intraoral frontal view of the definitive restoration.



Radiograph with the definitive restoration in place.

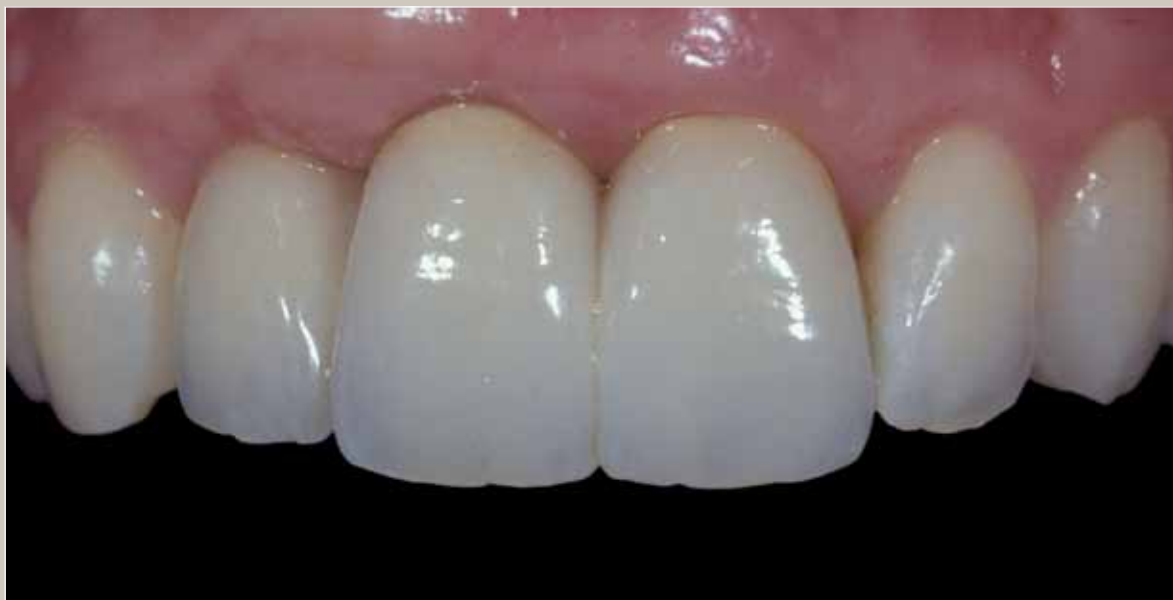### *Phase VII: Definitive restoration*

Three months after the provisional restoration was fabricated, the treating clinicians verified that both esthetics and function were acceptable and initiated the steps toward definitive restoration. Following removal of the provisional restoration, it was determined that the peri-implant mucosa and the pontic site configuration matched the design that had been made on the master cast. Therefore, the same design was used for fabrication of the definitive restoration. For porcelain buildup, a plaster cast was used.

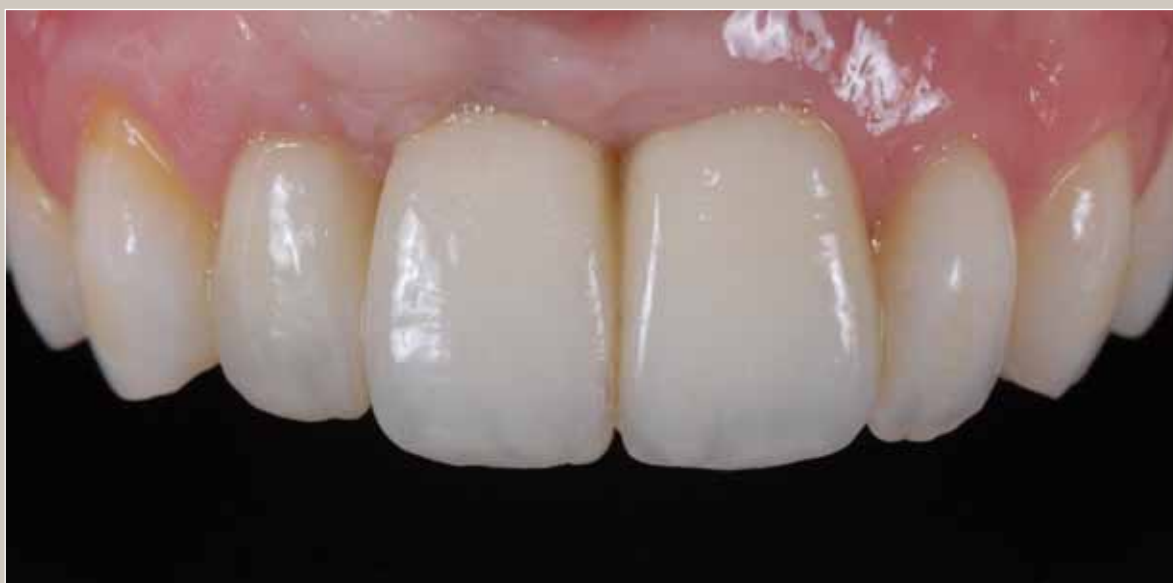Because the soft tissue adaptation to the submucosal prosthetic configuration of the provisional restoration was

acceptable, even though it did not duplicate the master cast design exactly, the same design could be used for fabrication of the definitive restoration. This would ensure identical shape, contour, and appearance of the provisional and definitive restorations. In cases where the provisional restoration has been modified intraorally and is no longer a blueprint of the mucosal design of the cast, an additional impression of the modified intraoral mucosa must be taken to serve as the template for the definitive restoration design.

A three-unit, screw-retained porcelain-fused-to-gold restoration was fabricated. The patient was 19 years old at the time treatment was completed.



Intraoral frontal view of maxilla at 2-year posttreatment re-evaluation.



One year after modification of crowns to close gaps.

### *Phase VIII: Two-year posttreatment re-evaluation*

The patient returned for examination and complained of saliva and air bubbles readily passing through the gingival embrasures between her crowns. She requested that the gaps be closed because this had become quite bothersome. Changing the crown contours to close the spaces might make the patient more comfortable but also would result in the oval shape of her crowns becoming more square in form and the scalloping of the gingival line becoming flatter, altering her appearance. However, the patient insisted on making these alterations.

One-year follow-up of the modified crowns revealed a flat and more apical gingival line, and the patient was still complaining of bubbles in the gaps between the crowns. At this stage, the patient relocated without additional treatment.

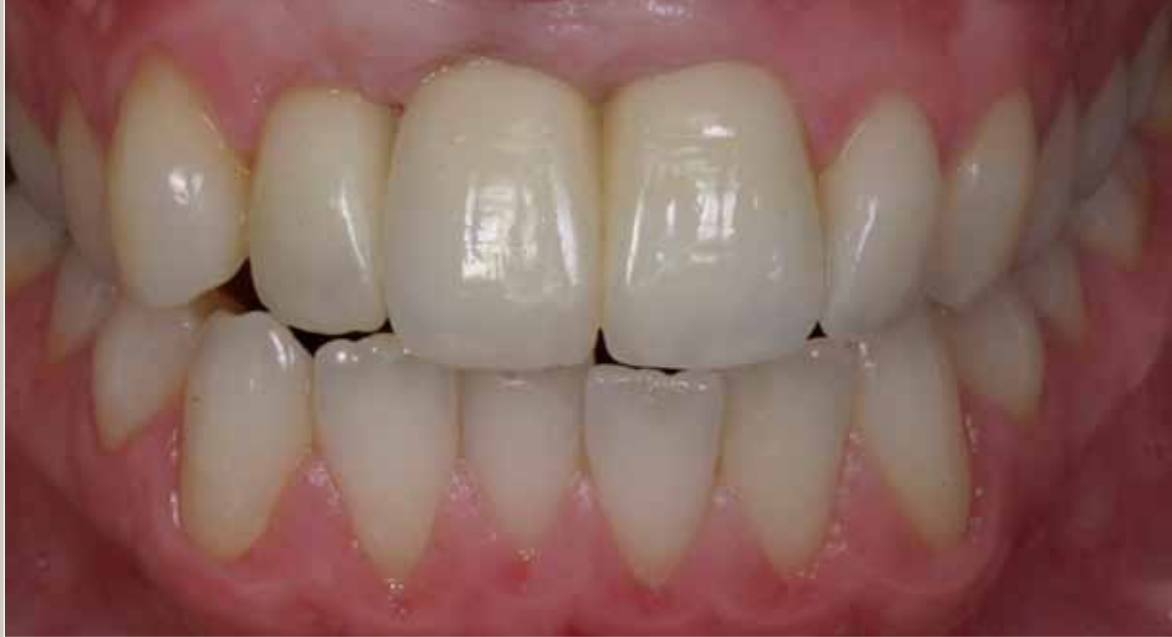### *Phase IX: Seven-year posttreatment re-evaluation*

The patient returned for examination and consultation 4 years later at the age of 26. During this time, some changes had occurred:

- Tooth no. 6 had moved buccally.
- The mandibular anterior teeth had also moved buccally and had become crowded.
- Gingival recession was noted on the facial aspects of some anterior teeth.

The patient accepted a recommendation for orthodontic treatment to reposition and realign the mandibular anterior teeth and tooth no. 6. The Invisalign system (Align Technology) was used.





Intraoral frontal view at 7-year posttreatment re-evaluation.

After orthodontic treatment, the patient returned with some esthetic concerns. She was unhappy with the tooth form and her appearance when smiling. She wanted to know if there was anything else we could do to improve her smile.

The key objective at this point was to determine the exact cause of her unattractive appearance. Envisioning the ideal form and three-dimensional position of the teeth aided in distinguishing between this and any other deviation such as soft tissue discrepancies.

Ridge augmentation procedures are designed to re-establish lost hard and soft tissue volume. Unfortunately, many of these procedures fall short of the restorative dentist's clinical expectations. Lack of papilla volume is a common postoperative deficiency. Even when ridge grafting fills most of the defect (eg, 90%), the problem is that usually the most critical portion of the void still remains. The final missing 10% is exactly what would be required to allow for fabrication of natural-looking crowns. This 10% usually includes the papillae and gingival margins—the framework for the future restoration.

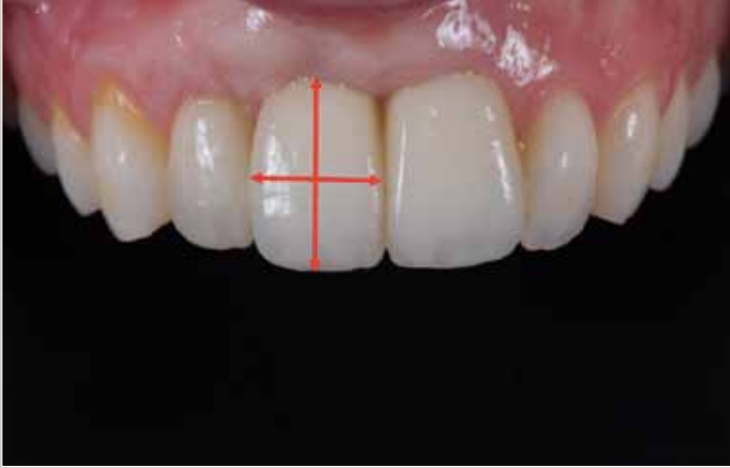This is exactly what had happened with our patient. There was a soft tissue discrepancy that was affecting the shape and position of the crowns, and this was responsible for the unattractive appearance of her smile.

### **Morphologic and esthetic problems when restoring a deficient ridge**

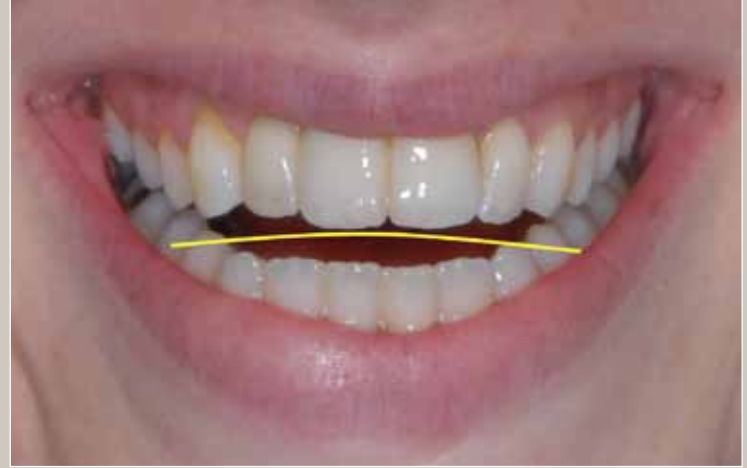Maxillary anterior tooth loss generates a bone resorption process in the direction and inclination of the roots, shortening the height of the ridge and the perimeter of the arch form. In order to reconstruct this vertical loss of the ridge and gingiva, the surgeon will typically first execute grafts to gain the essential height, hopeful that this will re-create satisfactory papilla form for the restorative phase. What we have seen most often is a horizontally shortened arch with vertically re-established height but with unsatisfactory papilla and gingival esthetics. This is the worst-case scenario for the ceramist. Usually in these situations, if the restorative dentist and ceramist opt for a conventional partial denture, ie, without prosthetic gingiva, we can expect the problems below:

- Narrower teeth due to less mesiodistal circumference and arch space.
- Longer teeth toward the apical aspect due to the ridge height that remains inadequate, even following surgical augmentation.
- Inverted smile line: Because the crown is longer apically, the technician typically must compensate by shortening the incisal edges of the anterior teeth, trying to keep reasonable

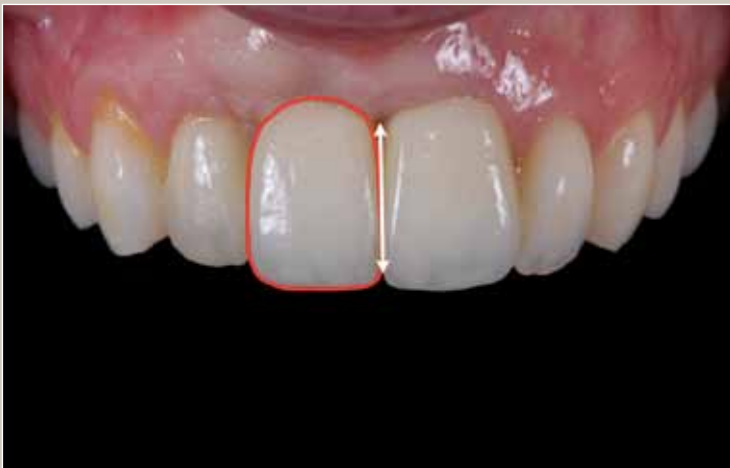



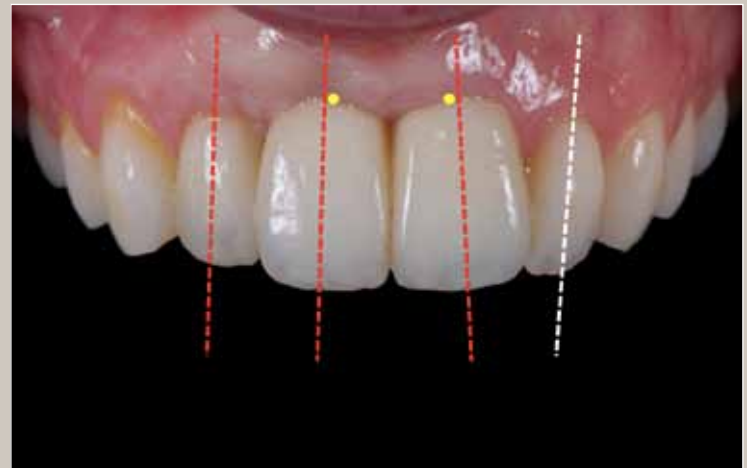
Incorrect dental proportion (long and narrow teeth).



Short incisal edge of the crowns and inverted smile line.



Rectangular teeth and long contacts.



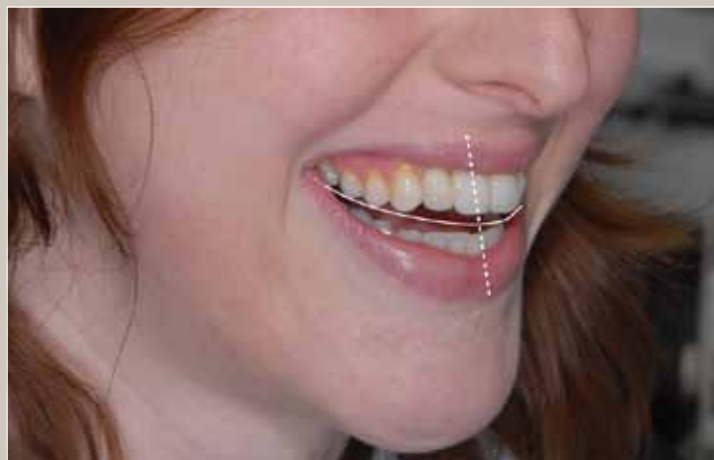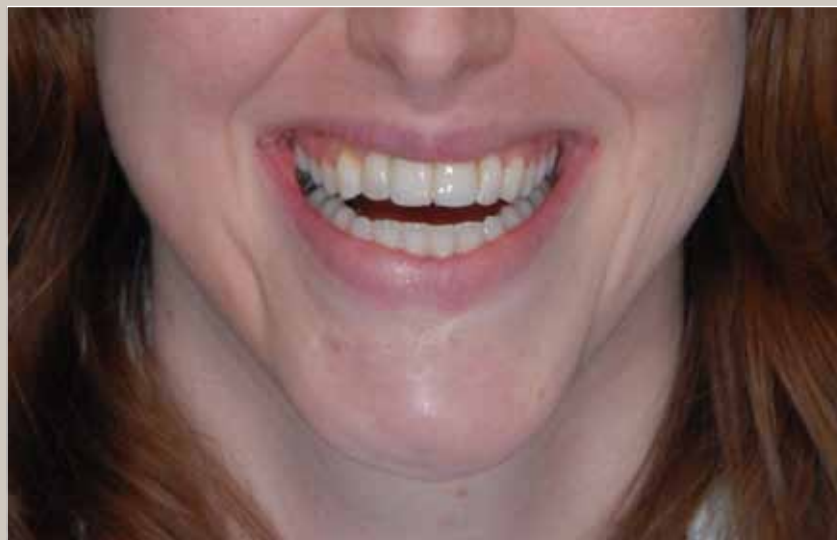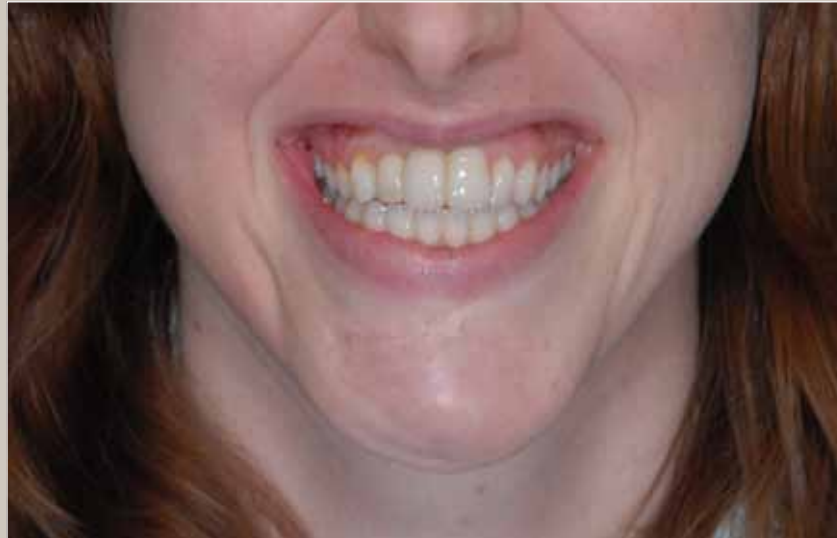Incorrect tooth axis and zenith position.

tooth proportions. That will make the anterior teeth shorter than ideal and lead to poor lip-tooth esthetic form.

- Rectangular teeth without natural tooth anatomy due to extended contact points in the interproximal area: Lack of papilla volume often requires the ceramist to create these longer contact areas in an effort to avoid the black holes interproximally.
- Inversion of the tooth axes: Instead of converging toward the incisal half of the tooth, the tooth axes will diverge. This is typically observed when conventional partial dentures are fabricated over resorbed ridges. This occurs when the ceramist tries to keep the incisal third on the occlusal plane, guided by the mandibular teeth, and at

the same time tries to take the cervical third of the tooth form toward the reduced ridge, modifying the natural tooth axis. It is interesting to note that when the correct modifications are made on the crowns to give them the proper axis, spaces for the artificial papillae are naturally opened. The correct positioning of the crowns in the arch will therefore lead to the need for prosthetic gingiva.

- Unsupported upper lip: When fabricating a partial denture with lack of adequate arch perimeter, we lose appropriate support, and the upper lip will tend to move down and backwards. Consequently, the patient shows less of the maxillary teeth, which creates an aged appearance.

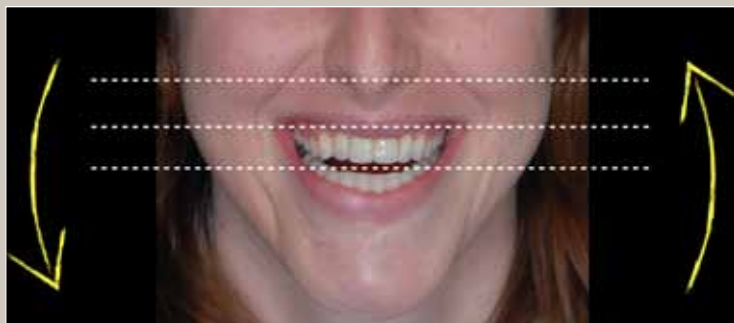

Facial views of the patient's smile for the DSD.

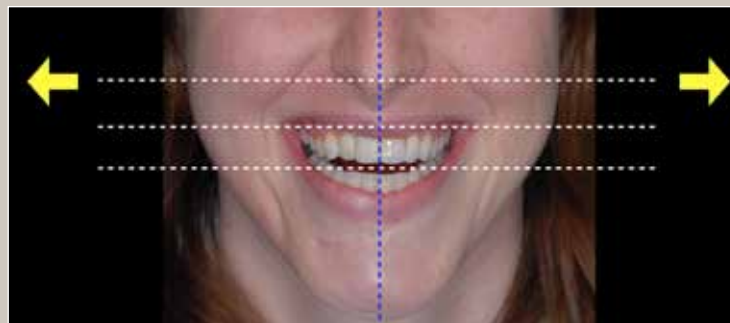
### *Phase X: Digital smile design*

Initially, a full digital photographic series was taken. A Key-note presentation (Apple) was created with the photos, and the facial analyses were completed. The facial midline and horizontal plane were determined. The two main guidelines (vertical midline and horizontal line) were transferred to the

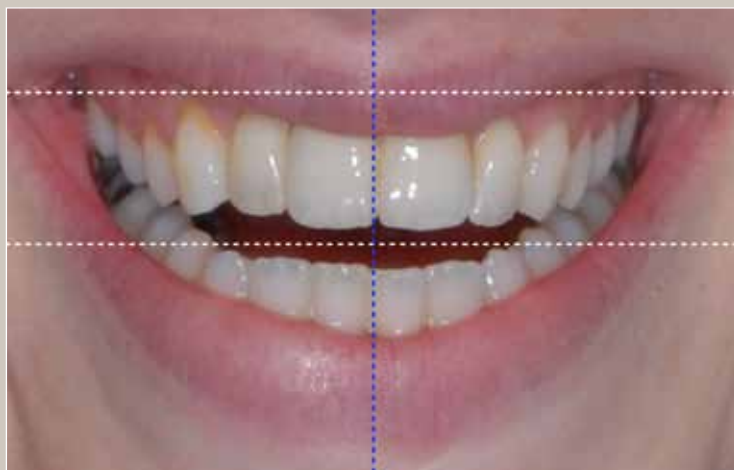
smile photo, and the ideal incisal edge position was designed. The lines then were transferred to the intraoral photo, allowing us to better visualize the proposed treatment outcome in relation to the face. After creating the intraoral photo with the two main guidelines and incisal edge position, we could then develop the dentogingival design.



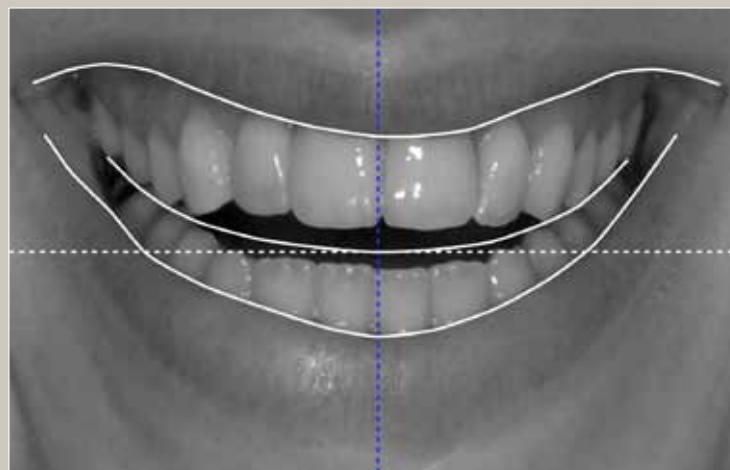
Determining the ideal facial position according to the horizontal plane of reference.



Determining a harmonious midline position.



Close-up of the smile with midline and horizontal lines marked.



Black and white version of photograph with lip lines for determination of ideal incisal edge position.

### *Phase XI: White and pink mock-up*

The decision was made to prepare a white and pink mock-up to evaluate the problem. The mock-up design was guided by the DSD. The mock-up was fabricated with the white and pink composite directly added to the existing implant partial denture. The white composite was added first to alter the position of the teeth, and then the pink was added, filling in the interproximal spaces to re-create the ideal gingival esthetics.

The following steps were taken to complete the mock-up:

1. Lengthening incisally to fix the inverted smile line
2. Adding cervical volume to both central incisors to position the teeth perpendicular to the occlusal plane and eliminate the flared out appearance
3. Adding distobuccal volume on the lateral incisor to correct the tooth axis, mimicking the contralateral tooth that converges (instead of diverging) towards the incisal
4. Reshaping the interproximal spaces to create good tooth form and appropriate interproximal contact appearance and opening ideal space for natural-looking papillae

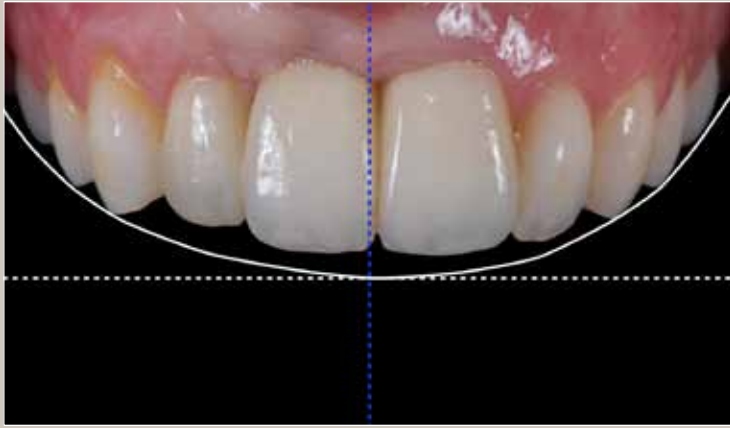
5. Adding pink composite and repositioning the papillae ideally to match the remaining natural papillae
6. Recreating ideal zenith position and gingival margin design

After the mock-up was finished, photos were taken (face, smile, and intraoral) to best communicate the new design to the patient. The patient approved the design and had great confidence that this approach would solve her problem.

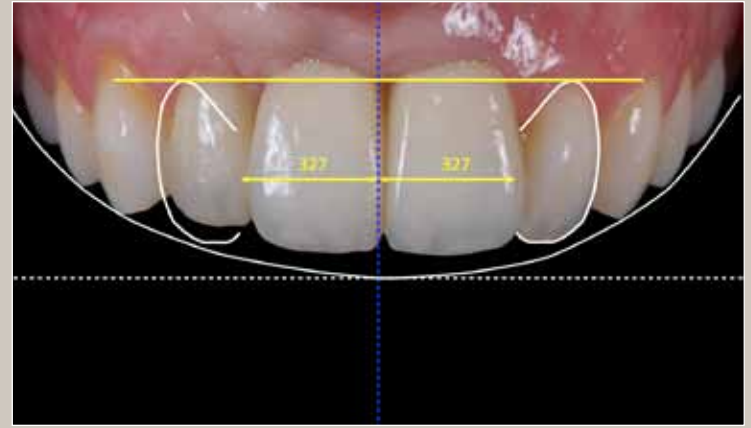
Prior to initiating treatment, the team had to answer some very important questions:

- Many treatment paths existed. Which would provide the most predictable, esthetically pleasing outcome?
- Would additional surgery to augment the ridge enhance the final esthetic outcome or would this add an additional element of risk? For instance, was there a risk of additional recession?
- In lieu of a surgical reconstruction, would it be more prudent to consider reconstructing the defect prosthetically?
- What would be the drawbacks of a nonsurgical prosthetic reconstruction?

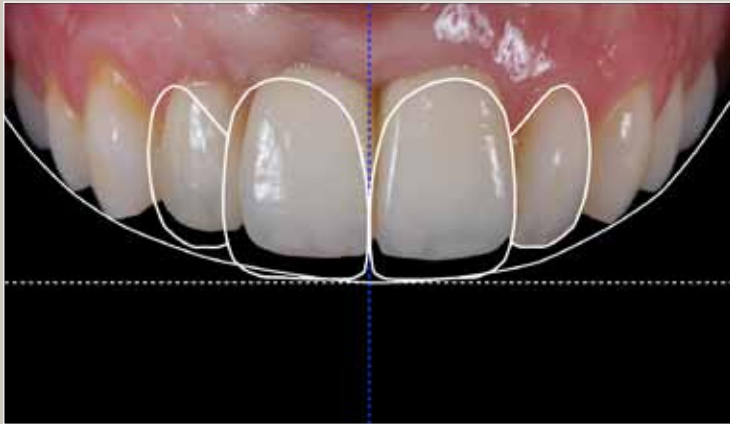




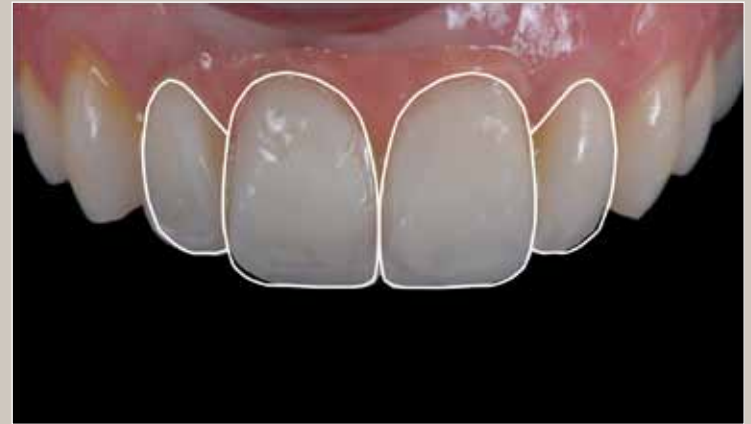Intraoral photo with facial lines transferred.



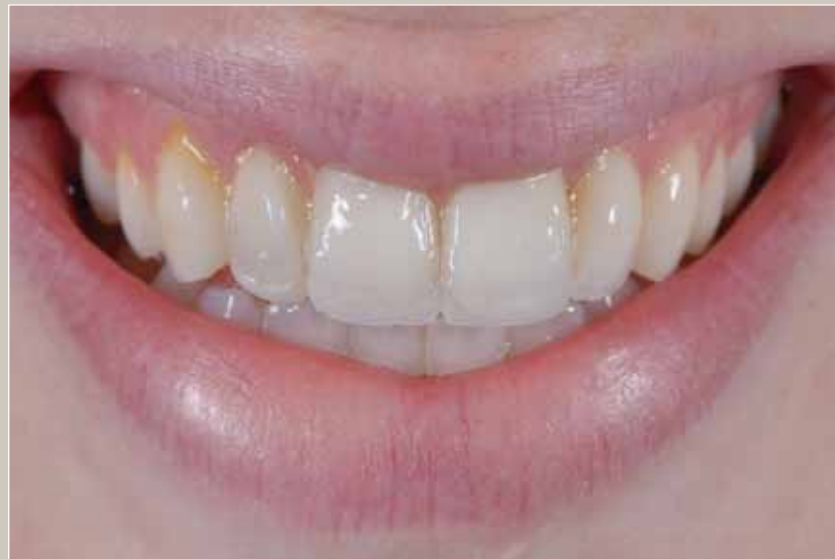Outline of tooth no. 10 duplicated, flipped, and repositioned equidistant to the midline during the dentogingival design process.



Design and position of the central incisors according to the reference lines.



Photograph of mock-up overlapping the intraoral DSD photograph.



Photograph of smile with mock-up in place.

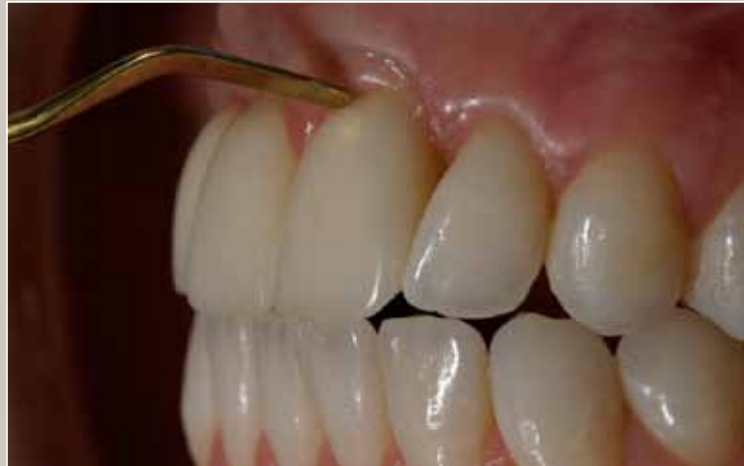The treatment team, in accordance with the patient's wishes, decided to institute a nonsurgical, prosthetically driven treatment plan.

The rationale for this decision was as follows:

- Additional surgery to reconstruct the ridge area could still fall short of what would be necessary to ensure an esthetically pleasing result. Although a purely prosthetic approach might also fall short of patient expectations, it

would be far less invasive, thus giving the patient one less reason to be unhappy.

- This patient had a very negative and stressful dental history and we wanted to minimize the risk of this continuing.
- This patient was very difficult and demanding, and we wanted to minimize the number of visits necessary to complete treatment.
- The patient was getting married in a few months, which presented time constraints.



Direct addition of pink composite resin over the pink ceramics of the definitive three-unit implant partial denture.

The decision was made to create a new implant fixed partial denture with artificial gingiva. The technique of choice was the so-called pink hybrid restoration. The main advantage of this approach is that we could re-create pink and white esthetics predictably without extra surgery. The main disadvantage would be the need for constant care and maintenance.

### *Phase XII: Fabrication and placement of the pink hybrid restoration*

Using the mock-up as a guide, a zirconium frame was fabricated, and a ceramic buildup was performed. The crowns were ideally located to receive the artificial gingiva.

The pink hybrid restoration consists of an implant partial denture with ceramics providing the white esthetics (teeth) and the pink esthetics (the base). After the ceramic part of the restoration was completed, the pink base was treated so that pink composite material could be bonded intraorally.

The seating process was achieved in two different appointments. The first appointment focused on the white esthetics and soft tissue conditioning. The partial denture was tried in prior to application of the pink composite. After all of the esthetic parameters involved were checked and all of the necessary adjustments were made, the partial denture was glazed and screwed back in. The condition of the soft tissues was not ideal at this time because of compression, bleeding, and blanching. This necessitated application of the pink composite at a separate appointment.

A few days later, after adequate healing of the soft tissue, the shape and color of the soft tissues was again stable, and we were able to add the pink composite material to the pink base. The implant partial denture was removed from the

mouth. The gingival area was treated for bonding in the following sequence:

1. Creation of mechanical retention with a small, round diamond bur in multiple locations
2. Hydrofluoric acid etching
3. Application of a silane coupling agent
4. Application of a bonding agent
5. Application of the first layer of pink composite extraorally to guarantee good bonding (without the interference of saliva)
6. Reattachment of the implant partial denture and addition of the remainder of the pink composite, matching shape, color, and texture to the natural soft tissue of the patient

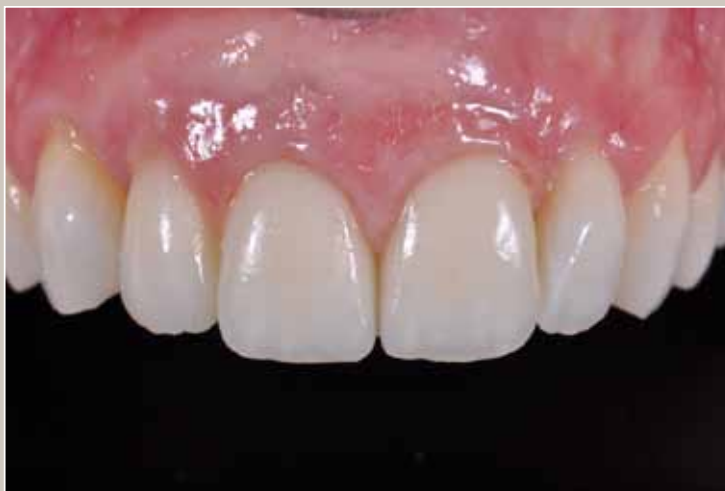The key was to blend in the interface between the artificial and natural soft tissue, which is facilitated by the pink composite.

After the restoration was completed, the focus switched to oral hygiene maintenance. Very specific hygiene instruction was given in order to adequately maintain this unique type of restoration. This is essential for long-term success.

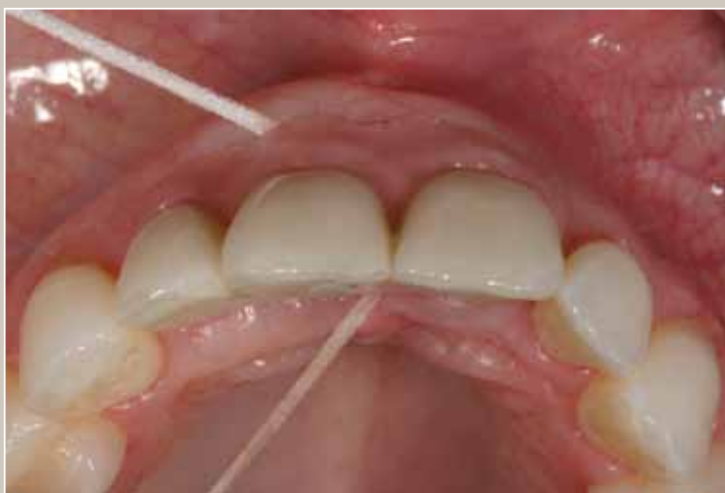The most important aspect of this restoration is that it has to be retrievable. The pink hybrid restoration is designed to be screw retained for maintenance purposes. The patient was scheduled for a checkup 3 months after seating to confirm that hygiene was being performed correctly. After this, at every 6-month hygiene appointment, the partial denture will be removed to check the peri-implant and periodontal status and to examine the adjacent teeth to confirm that the artificial pink extensions are not causing any harm to the soft tissues. The screws will require replacement every year (after two rounds of insertion and removal).



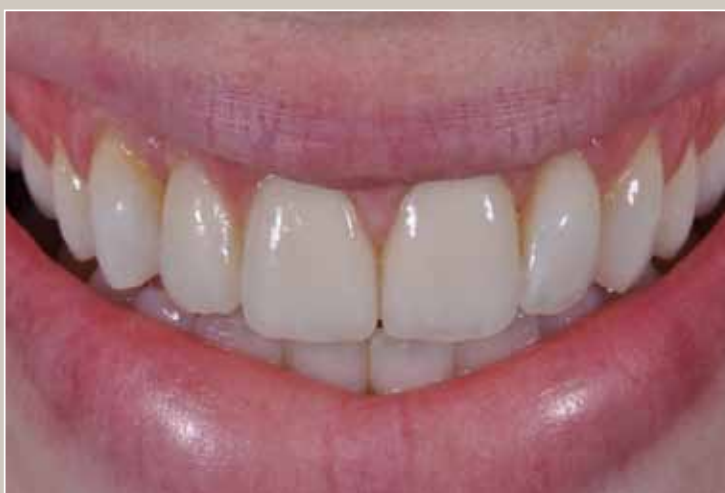## POSTTREATMENT



Intraoral frontal view of the anterior maxilla.



Occlusal view of essential hygiene procedures.



Smile view.

*You may now place the corresponding posttreatment overlay found in the separate folder over the pretreatment periodontal chart on page XX.*

[Au: Page number to be determined once paginated.]

# OVERCOMING INCORRECT IMPLANT INCLINATIONS

*Galip Gürel, MSc*



Despite recent advances in periodontal and peri-implant surgical regenerative procedures, predictably re-establishing hard and soft tissue contours remains a formidable challenge in cases with 3D ridge deficiencies.

This case was chosen because it presents a reliable and consistently predictable alternative in prosthetically compromised cases in which patients are unwilling to undergo regenerative surgical procedures. As already shown, the pink hybrid restoration<sup>5-8</sup> represents a remarkable

innovation because it ensures an extremely close match between the prosthetic and natural gingiva with simplicity and dependability while still providing easy maintenance.

The main issue in this case was to overcome the implant angulations, which were inappropriate for a pink restoration. The implants, already placed, had a buccal inclination not allowing for a one-piece, screw-retained framework, which is ideal for the pink hybrid restoration.

# Case Presentation

*Treating clinicians*

*Prosthodontist: Galip Gürel, MSc*

*Dental laboratory and smile designer: Christian Coachman, DDS, CDT*

## CLINICAL TREATMENT PLANNING

Age at initial presentation: 30 years

Initial presentation: December 2007

Active treatment completed: June 2008

## Medical history

- Noncontributory

## Introduction and background

This patient had been in an automobile accident approximately 3 years before her presentation for examination in our office. She had lost five anterior teeth (nos. 7 to 11) and had undergone numerous surgical procedures to correct the facial and intraoral defects that resulted from the traumatic injury. She presented with facial asymmetry and a large depression on the left side of her upper lip. Previous treatment was directed toward correcting these deficiencies by augmenting the intraoral defect with hard and soft tissue grafts and placing three implants. The augmentation procedures did not provide enough new bone volume to fill the defect completely and compromised the definitive restorative outcome. Although there was some esthetic improvement extraorally, the patient was very disappointed with the shape and proportions of her new teeth as well as their relation to her gingival tissues. The traumatic injury, multiple surgeries, hundreds of hours in the dental chair with lost work time, and an enormous financial investment had resulted in depression and complete loss of self-esteem. She had given up hope and had severed her relationship with the previous dental surgeon.

At initial presentation, the patient complained about the appearance of her teeth and the minor facial asymmetry that still existed due to the lack of bone support for her upper lip. She was tired of treatment and was adamant about not proceeding with any additional surgical procedures. The only option remaining to improve esthetics and to help this patient feel better about herself was to use a minimally invasive prosthetic approach.

## Diagnostic findings

### *Extraoral and facial findings*

- Normal profile with visible depression on the upper lip
- Asymmetric facial appearance due to the loss of lip support, mainly on the left side
- Flared incisal edges of the anterior teeth
- Lack of papillary display when smiling, resulting in longer-looking teeth

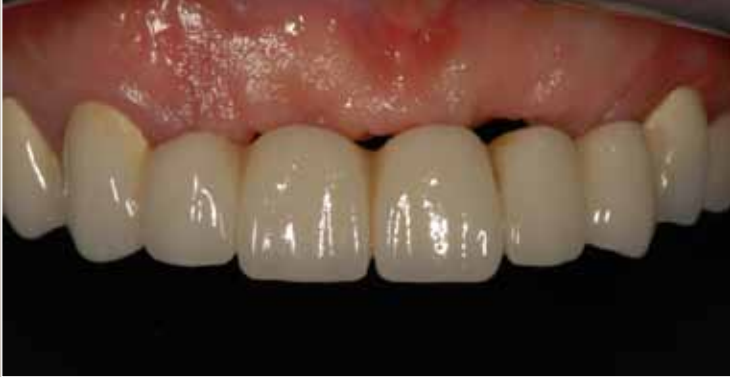### *TMJ and mandibular range of motion*

- Normal range of motion
- No joint sounds with external palpation
- No muscle tenderness
- No pain on opening or with lateral movement
- Very easy manipulation
- No signs or symptoms of temporomandibular disorders

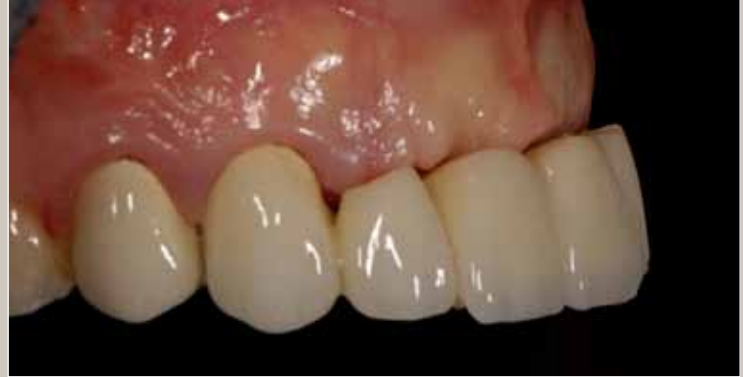### *Intraoral findings*

- Porcelain-fused-to-metal (PFM) partial denture extending from teeth nos. 5 to 13
- Long proximal contact areas on the anterior teeth
- Incisal edges flared out
- Asymmetric gingival levels
- Lack of interproximal papillae in the maxillary left anterior segment

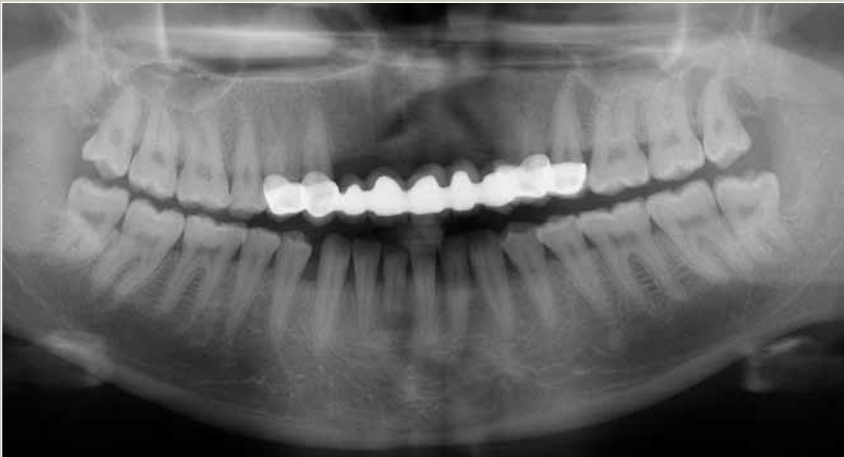## PRETREATMENT



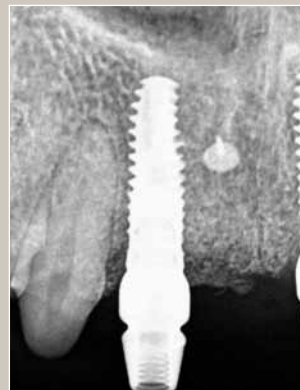Intraoral frontal view of maxilla with existing fixed partial denture, which was trimmed at the cervical aspect and used as a provisional.



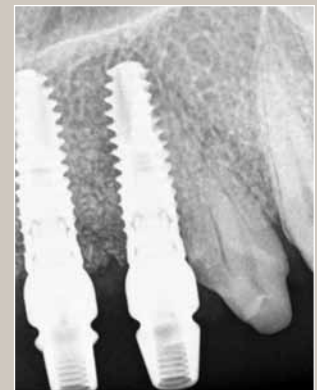Intraoral lateral view of maxilla with existing fixed partial denture.



Panoramic radiograph taken before implant placement.



Radiograph of implant at site no. 7.



Radiograph of implants at sites nos. 9 and 11.

### Dental

- Missing teeth nos. 7 to 11
- No active caries on the remaining teeth
- Diastema between teeth nos. 27 and 28
- No significant wear or attrition

### Periodontal

- Acceptable plaque control and oral hygiene
- Isolated areas with slight gingival inflammation
- Healthy and stable periodontium with minimal periodontal pocketing
- Little or no tooth mobility
- Furcation areas intact

### Occlusal notes

- Class I canine and molar relationships
- Slight CR-CO shift on closing
- 1-mm horizontal and 1-mm vertical overlap

### Radiographic findings

- Good bone levels with exception of anterior bony defect
- Implants replacing missing teeth nos. 7, 9, and 11
- No sign of caries

### Diagnosis and prognosis

- AAP Type I
- Healthy periodontium
- Excellent prognosis for all teeth





## PROPOSED TREATMENT PLAN

### *Goals/objectives of treatment*

Our plan was to accomplish the following:

- Gain white and pink esthetic harmony with a smile design that complements the patient's facial features
- Restore the teeth and implants that had already been placed
- Restore the lost horizontal volume
- Gain lip support and correct the facial asymmetry
- Correct the papillary and gingival levels
- Correct the buccolingual axis of the anterior teeth
- Correct the inverted smile line

### *Phase I: Initial therapy*

1. Comprehensive examination and consultation
2. Pretreatment photographic series
3. Prophylaxis, root planing and scaling, oral hygiene instruction

### *Phase II: Smile design test drive*

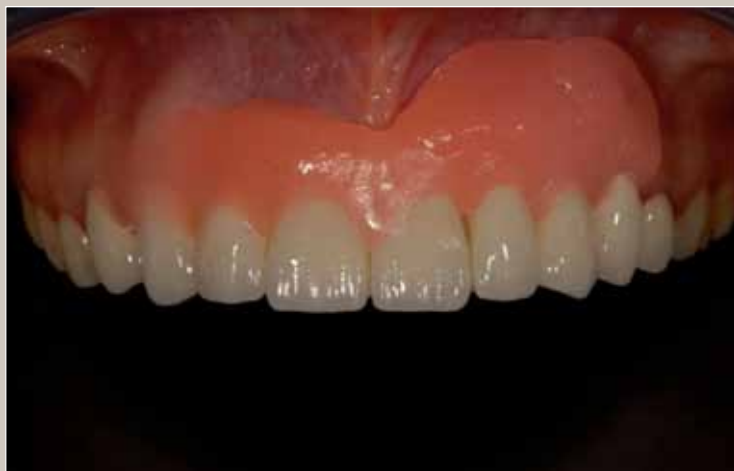4. Clinical and photographic analysis
5. White and pink mock-up to re-create an attractive smile design, support the upper lip, and level the papillae
6. Records taken
7. Finalization of treatment plan and presentation to the patient

### *Phase III: Definitive restoration*

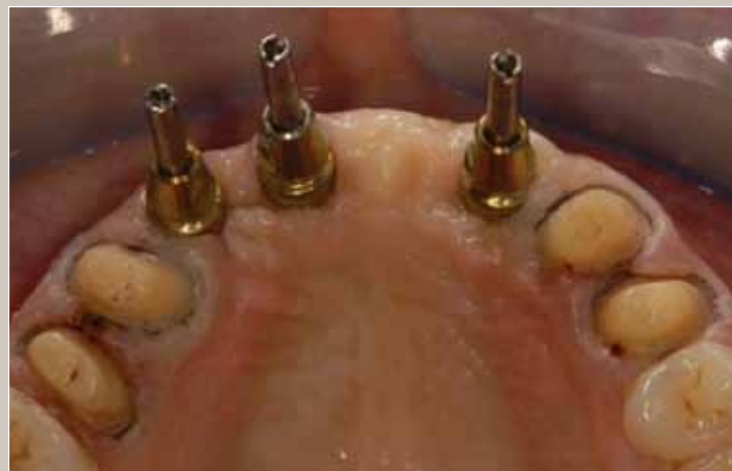8. Final precision implant impression
9. Fabrication of master casts
10. Maxillomandibular relationship record
11. Framework design
12. Definitive design and implementation of white esthetics
13. Try-in
14. Definitive design and implementation of pink esthetics
15. Finishing
16. Hygiene test
17. Seating of definitive restoration

### *Phase IV: Follow-up/recall*

## ACTIVE CLINICAL TREATMENT



Pink wax placed over the ridge defect to check for interference with upper lip support.



Occlusal view of the maxilla prior to taking open-tray impressions of the teeth and implants.

### *Review of the goals/objectives of treatment*

- Gain white and pink esthetic harmony with a smile design that complements the patient's facial features
- Restore the teeth and implants that had already been placed
- Restore the lost horizontal volume
- Gain lip support and correct the facial asymmetry
- Correct the papillary and gingival levels
- Correct the buccolingual axis of the anterior teeth
- Correct the inverted smile line

### *Phase I: Initial therapy*

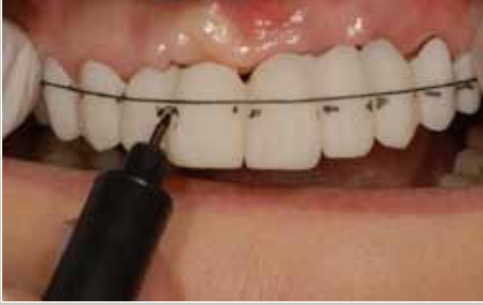At the initial examination, it became quite clear that we would have to address this patient's discontent with her past dental experiences and her appearance before we could consider moving forward with any treatment. Although an examination was scheduled for the first appointment, this was not initi-

ated. Instead, a great deal of time was spent simply listening, acknowledging that her concerns were valid, and expressing a commitment to helping this patient improve her appearance and ultimately her self-esteem. No promises were made other than to explore all treatment possibilities and to decide together what would be the most reasonable approach.

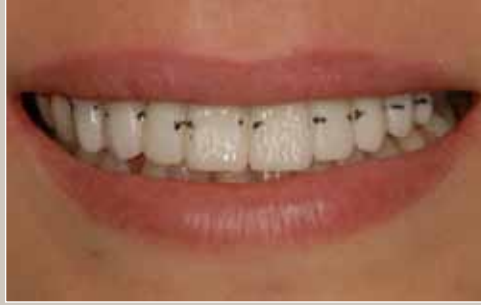The patient was willing to go through more surgeries if that was the only way to improve her appearance, even though she was very traumatized by previous treatment. Her only hesitation was related to the uncertainty of the treatment outcome even with surgical intervention.

Possible limitations were discussed and realistic expectations set. This appointment cleared the way for developing a good relationship with this patient and gaining an ally in moving forward with treatment.

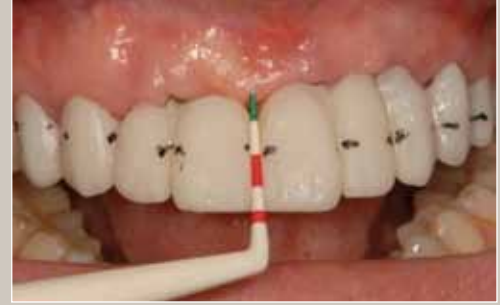At the following appointment, a comprehensive examination was performed and a photographic series taken. The patient was then appointed for initial root planing and scaling procedures and oral hygiene instruction.



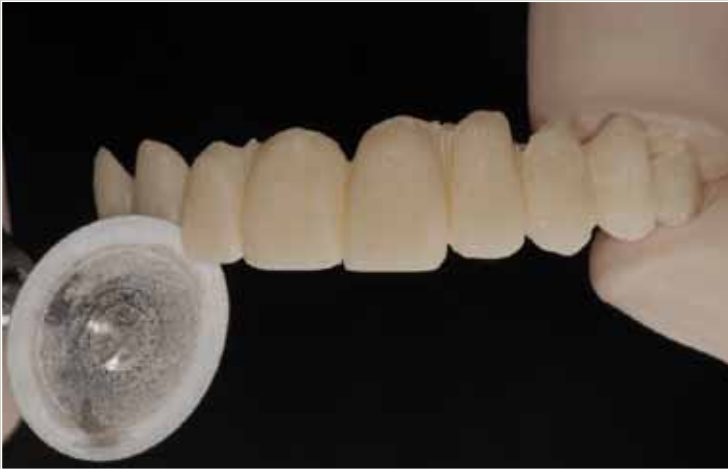Marking the ideal position of the papillae on a new acrylic provisional restoration.



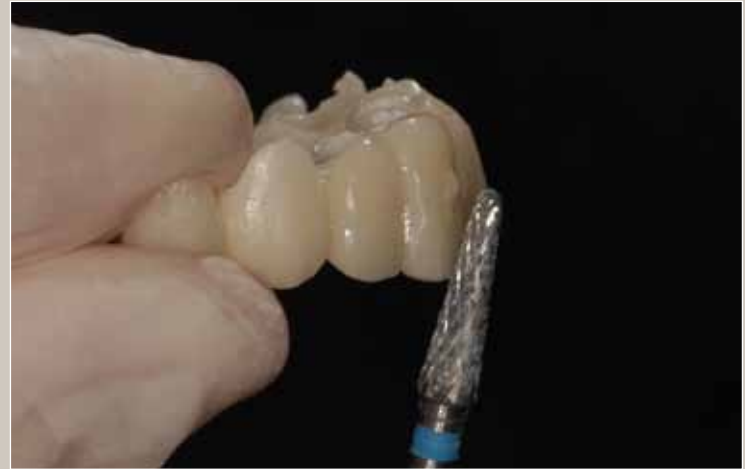Analyzing and comparing the position of the papillae with the lips.



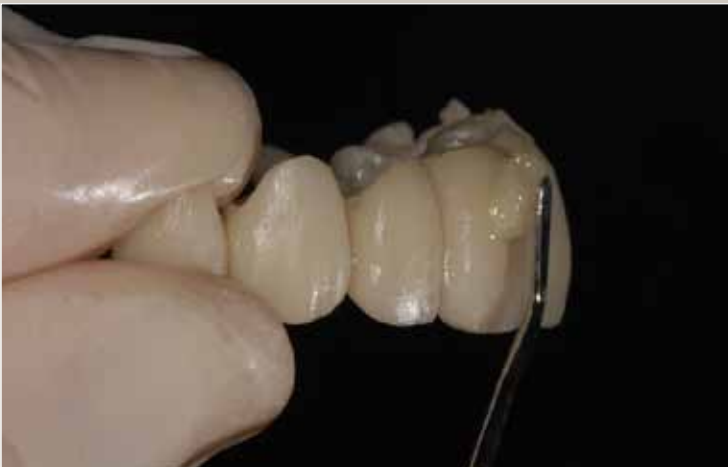Checking the size of the vertical component of the defect with a probe. Note 5-mm vertical soft tissue deficiency.



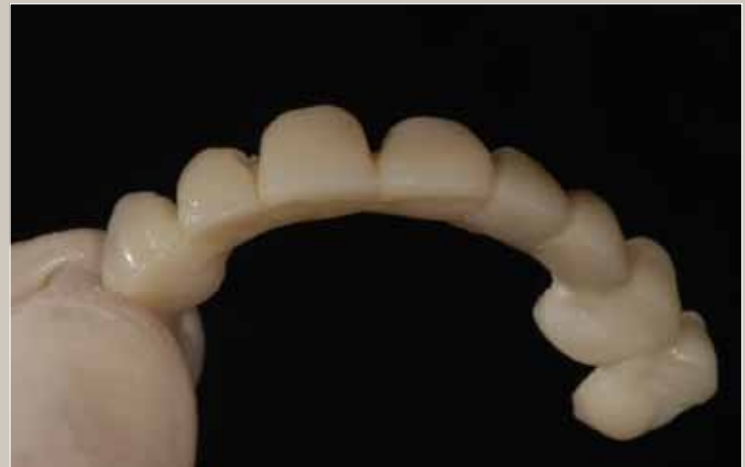Shaping the partial denture.



Reducing the incisal third to decrease flaring.



Increasing the cervical volume.

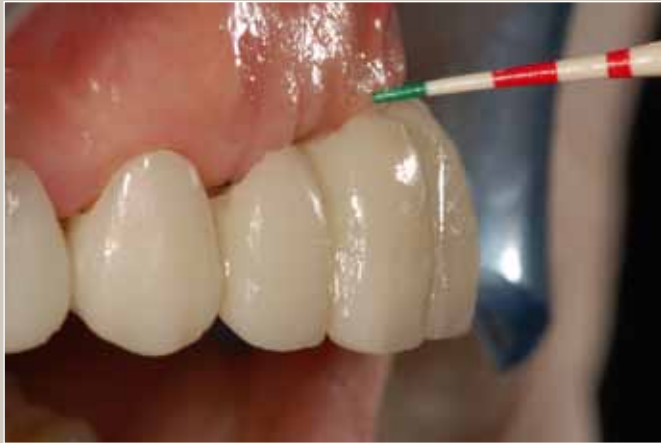

Occlusal view of restoration showing the difference between the side with increased cervical volume and the side that was not modified.

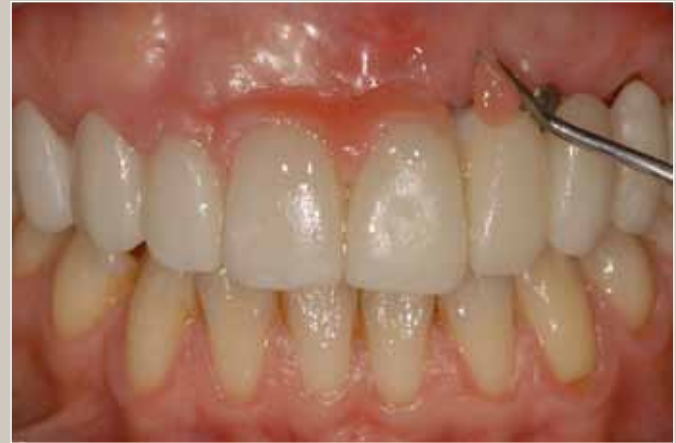## Phase II: Smile design test drive

The main goal of the test drive phase was to more clearly assess the actual dimension of the defect and then be able to determine the most optimal solution, whether it be surgically or prosthetically driven. During this phase of treatment,

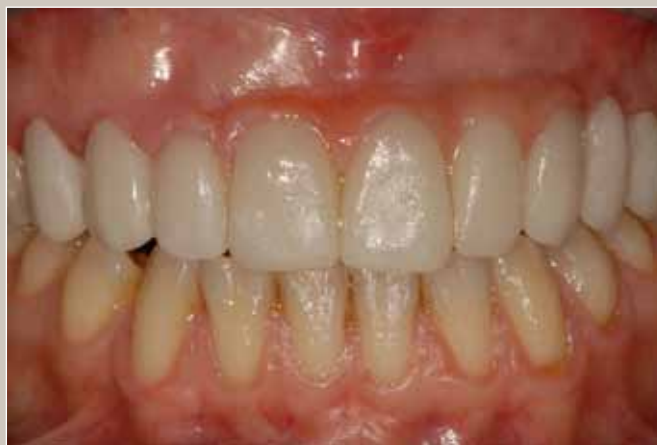the first step was to remove the old fixed partial denture and replace it with a new acrylic provisional restoration. This partial denture was seated, and an initial esthetic evaluation was made. The objective was to reposition the anterior teeth into an ideal 3D position, which would complement the face and lips, ignoring the existing ridge defect and its distance from the



Intraoral lateral view of acrylic provisional restoration showing the horizontal component of the ridge defect (minimum 3 mm).



Intraoral addition of pink composite to replace the missing soft tissues.



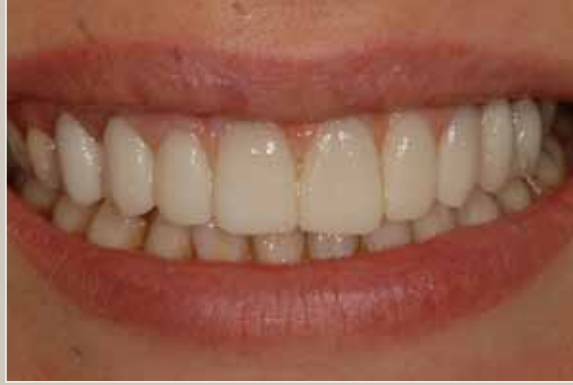Intraoral frontal view of provisional restoration after placement of the pink composite. Note the correct proportions of the teeth as defined by the new papillae shapes and horizontal pink composite addition.

new location of the teeth. To create the most ideal position, composite material was added on the buccal of the acrylic partial denture to position the teeth anteriorly and incisally, improving the overall esthetic display, reversing the inverted smile line, and correcting the flaring of the anterior teeth. An emphasis was also placed on properly shaping the interproximal areas to create natural tooth morphology and opening space for the future addition of artificial pink material. The shape of the interproximal area is the most critical and challenging part of designing an anterior partial denture. Ideal management of this area allows for the individualization of each crown, creating the illusion of separation among splinted crowns. The interproximal area will also determine the tooth

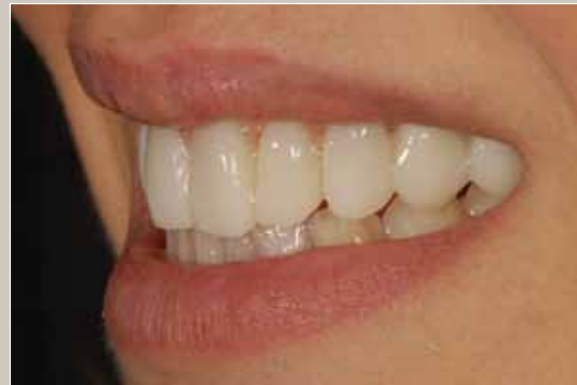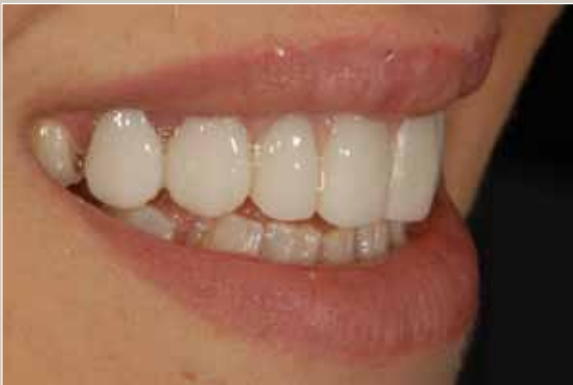silhouette, which is so important in creating the illusion of tooth shape and proportion. Understanding how to shape this area is a key factor in being able to create natural-looking artificial papillae.

After this first step was completed, the partial denture was seated in the mouth, and the deficient soft tissue space was filled in with pink composite material, re-creating ideal gingival design. The objective was to use the unaffected adjacent gingiva as a guide in shaping the pink composite so that it would blend well with the existing soft tissues. This was most important in the area of the distal papilla of the maxillary right canine and in harmonizing the artificial gingiva with the upper lip.





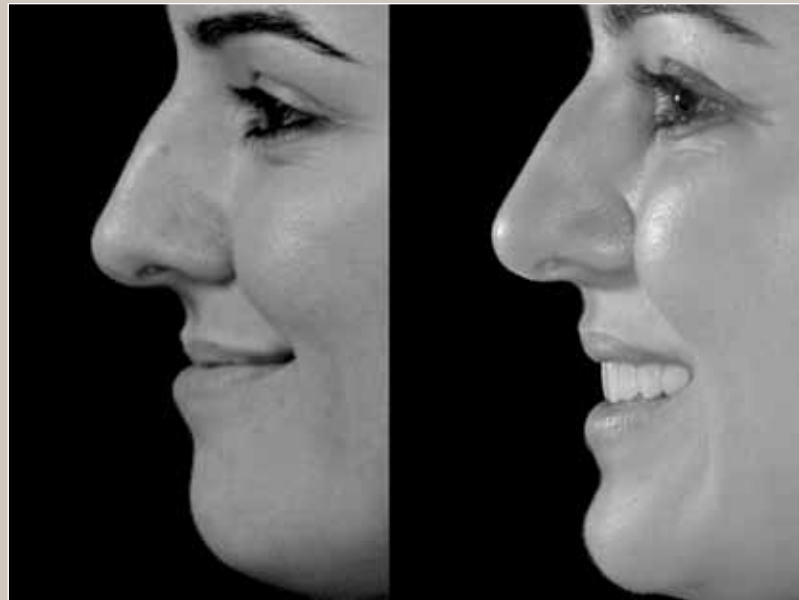Frontal view of smile with the provisional restoration.



Lateral views of the smile with the provisional restoration.



Facial view of smile with the provisional restoration.

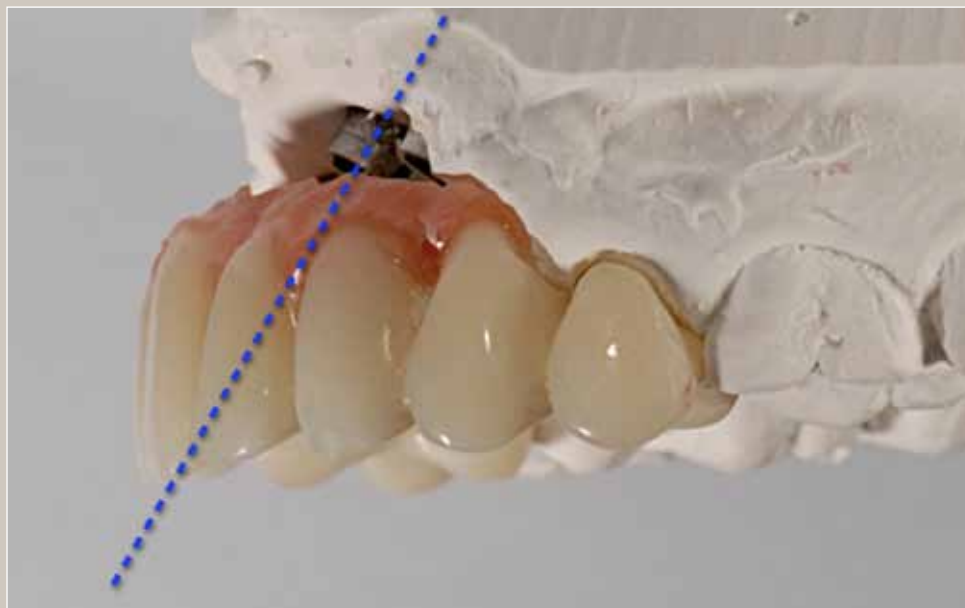
Comparison of facial profiles with the old fixed partial denture (*left*) and the new provisional partial denture (*right*).

Communicating the proposed definitive esthetic outcome of the smile design test drive with the patient was essential. Photos were taken with the mock-up in the mouth, and final adjustments were made to achieve the best esthetic design for the patient. After this was achieved, an alginate impression was made, and photos were taken to serve as a guide for the definitive restoration.

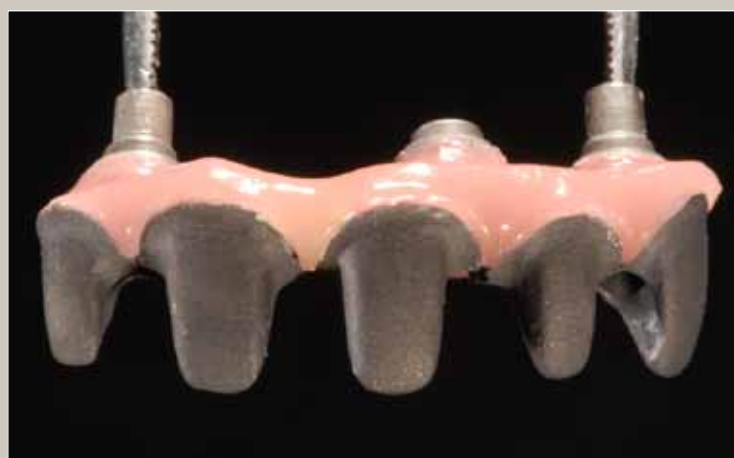When comparing the photos of the face with the old fixed partial denture to the new mock-up, the patient was very

excited about gaining additional lip support and, most importantly, improving her entire dental and facial appearance.

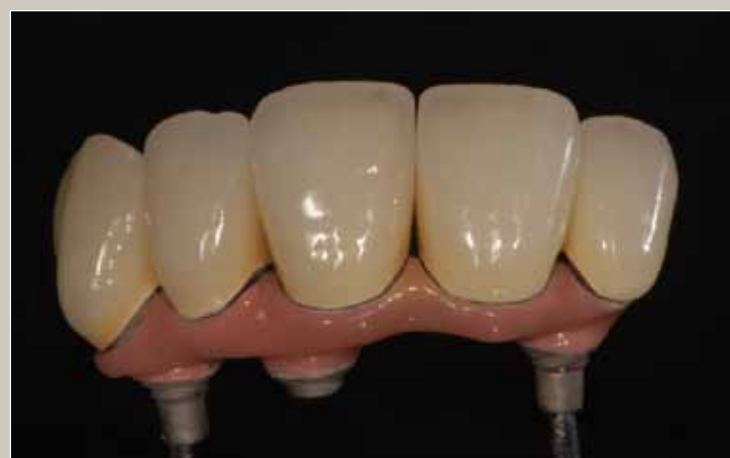After analyzing the mock-up clinically and reviewing the photos, it was apparent that a surgical approach would not result in achieving our goals. The patient was informed of this, and an alternative plan was considered. We decided to use the implants placed and fabricate a pink hybrid partial denture. The plan was to design a framework that would allow a retrievable restoration.



Provisional restoration placed on the cast, showing the implant axis (*dashed line*), which does not allow lingual screw access.



Infrastructure with pink ceramics.



Single crowns on the infrastructure.

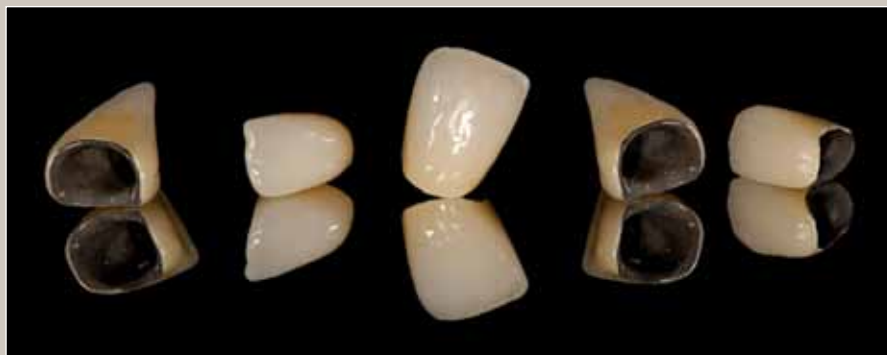### *Phase III: Definitive restoration*

#### **Framework design**

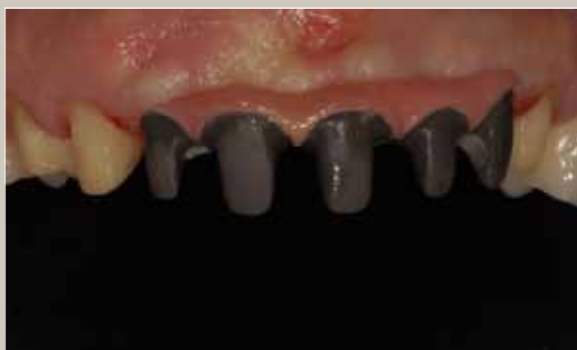There are many advantages to a pink hybrid restoration. These include remarkable esthetic outcomes considering the extent of the hard and soft tissue defects present and retrievability should anything fail in the future. However, there are drawbacks as well. These are related to the design of the restoration, which makes it difficult to perform adequate home care and provide adequate soft tissue conditioning. The solution, interestingly enough, is also found in the design of the restoration, in that it is removable by the dentist to allow for any necessary adjustments, hygiene maintenance, and the addition of restorative material in the future to maintain intimate contact with the soft tissues as recession occurs.

When implant placements are anticipated, we always plan for lingual screw access so that a one-piece, implant-level partial denture can be fabricated. If implants already exist, their locations and/or angulations may not allow for this, and we may have to create alternative solutions, with retrievability still in mind.

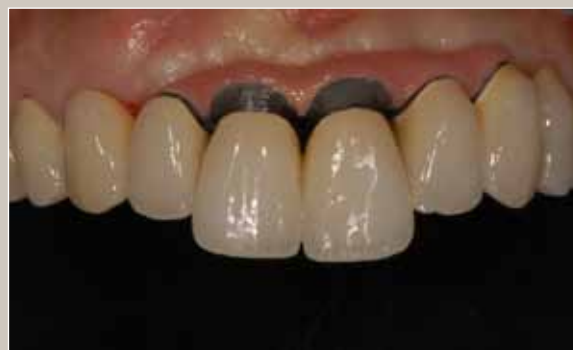In this case, the three implants were emerging from the facial aspect of the future restorations. This would not allow for lingual screw access and presented a formidable challenge. Ultimately, a solution was found. The plan was to develop an infrastructure that would receive the pink material and be screwed over the implants. This infrastructure was made out of dental alloy. The framework would also have the shape of preparations toward the level of the crowns. Then single crowns could be cemented on top of this with provisional cement, allowing us to access the screws when necessary.



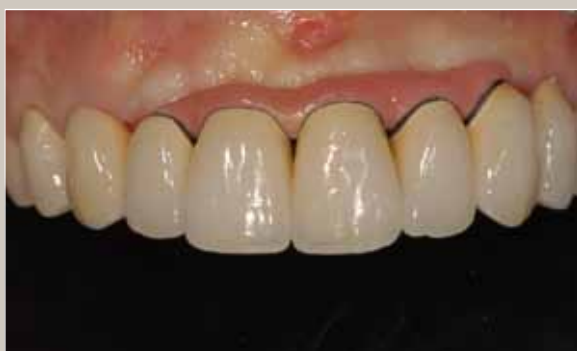Single PFM restorations.



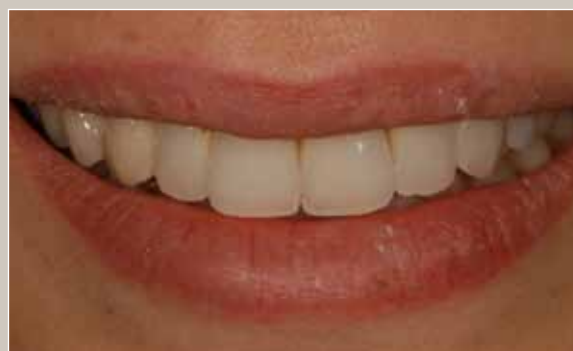Infrastructure screwed in intraorally.



Try-in of the crowns.



Intraoral frontal view of the crowns in position.



Smile view of the crowns.

### White esthetics

Single dental alloy-ceramic restorations were fabricated on top of the infrastructure, following the white esthetic principles developed on the mock-up.

### Try-in

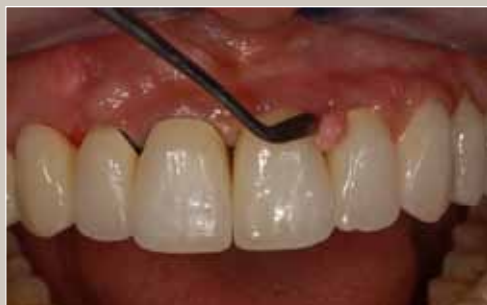The infrastructure was screwed in the mouth. The crowns were seated in position, and the white esthetic evaluation was made. After the necessary final adjustments, the crowns were glazed.

### Pink esthetics

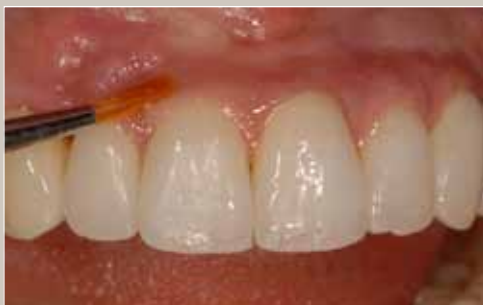The infrastructure was then removed and the pink ceramics treated to be able to receive the pink composite when resealed intraorally. The frame was then resealed, crowns were cemented provisionally on top of it, and the pink composite was added, following the pink esthetic principles developed on the mock-up.

### Finishing

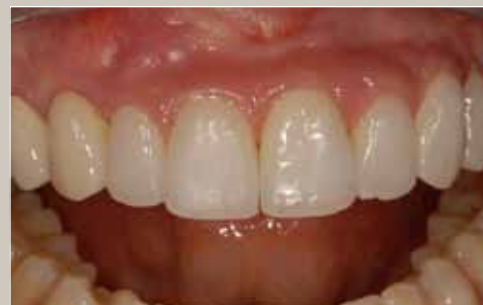The partial denture was unscrewed following removal of the crowns. The pink composite was refined at the laboratory bench, with the undercuts and thin edges removed, followed by a final light curing cycle and polishing of the restoration.



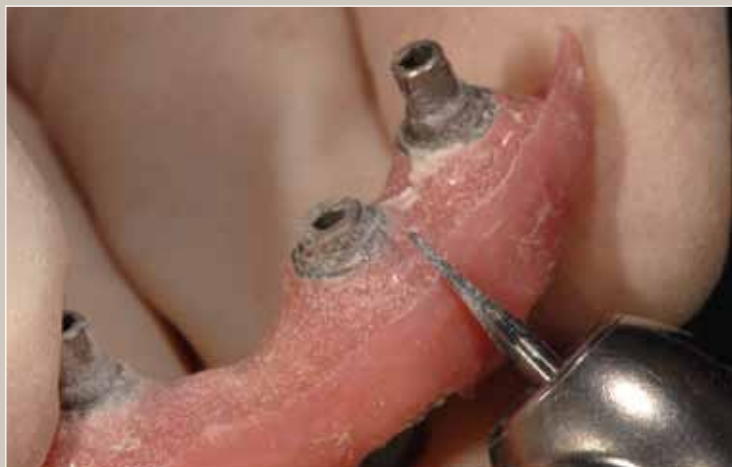Incremental addition and light curing of the pink composite intraorally.



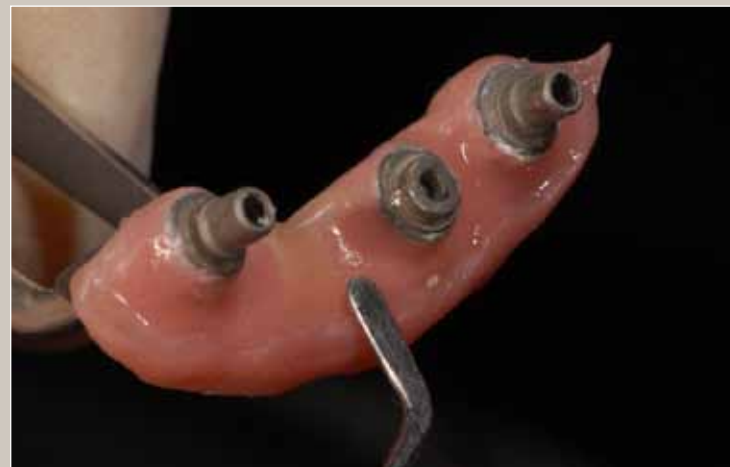A brush is used to apply stains, the edges are blended, and texture is created.



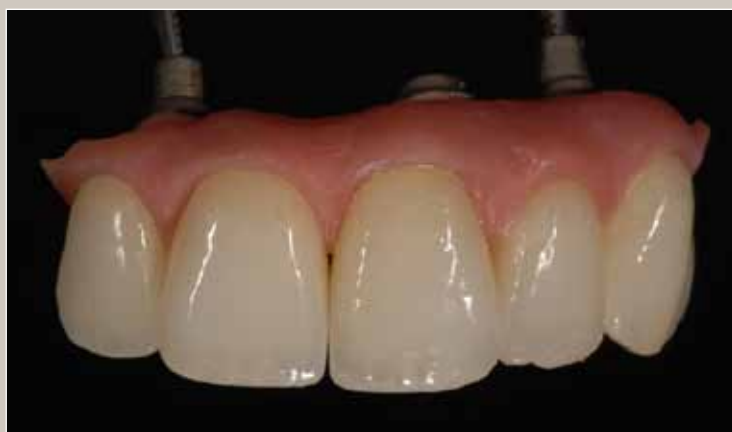Intraoral frontal view after completion of direct pink composite.



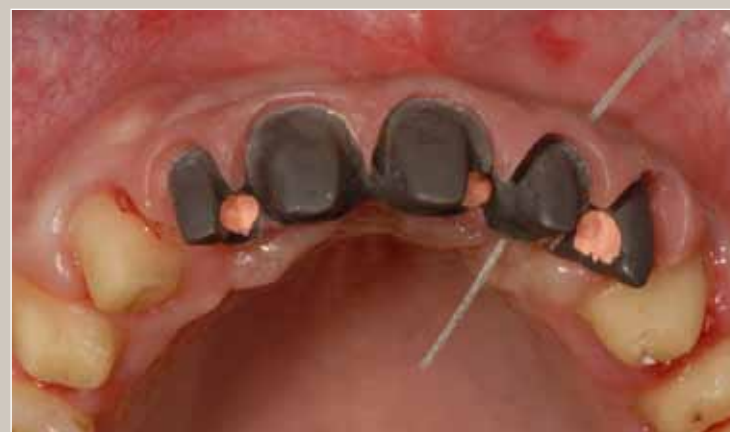After removal of the crowns and infrastructure from the mouth, the edges of the pink composite are smoothed with a carbide bur.



Addition of pink composite to improve the emergence profile and fill in undercuts.



Definitive partial denture ready for the last try-in.



Occlusal view of flossing procedures around the infrastructure.

### Hygiene test

The infrastructure was placed back in the mouth, and the flossing procedure was tested. The entire interface between artificial and natural gingiva should be cleansable. If some spots are difficult to reach, adjustments can be made on the restoration to improve access for ideal home care. The process should be tested by the clinician and then explained and demonstrated very carefully to the patient.

### Final seating

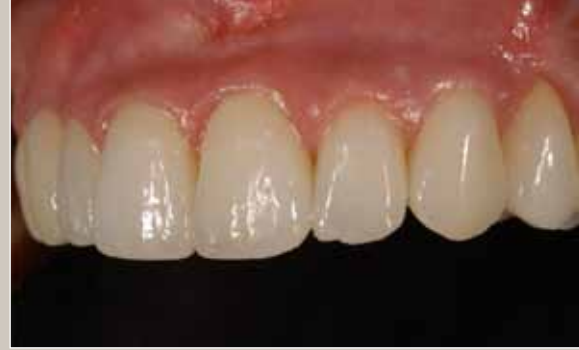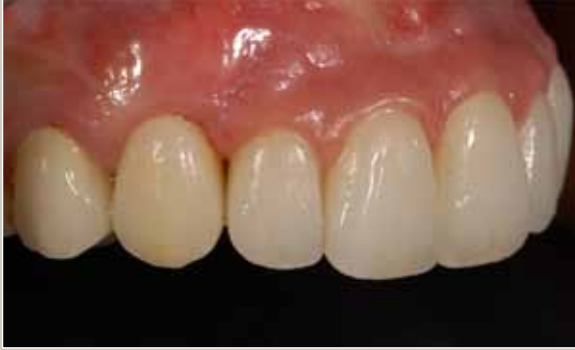After final evaluation of access for adequate oral hygiene and the condition of the soft tissue, the infrastructure was screwed down definitively, and the single crowns were seated with cement.

### Follow-up

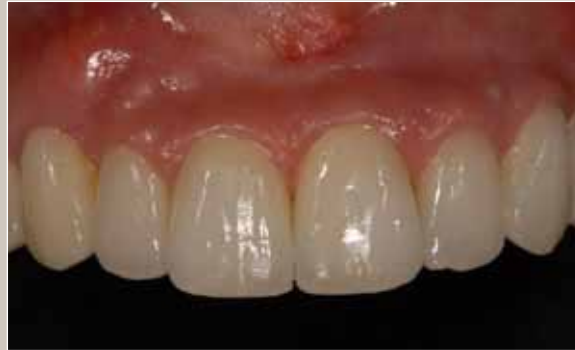The patient was scheduled for a 3-month postoperative re-evaluation, at which we planned to evaluate the soft tissue condition and the patient's level of oral hygiene. Oral hygiene reinforcement and instruction would be implemented if necessary.



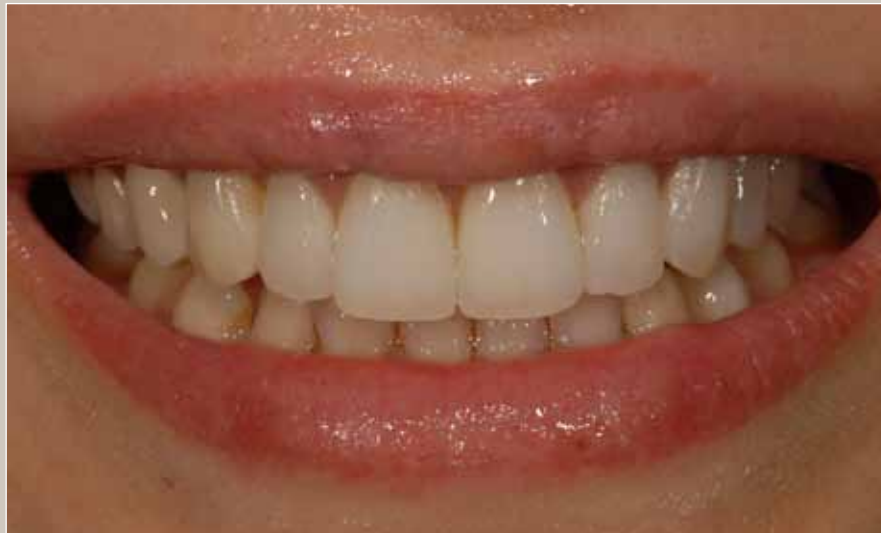## POSTTREATMENT



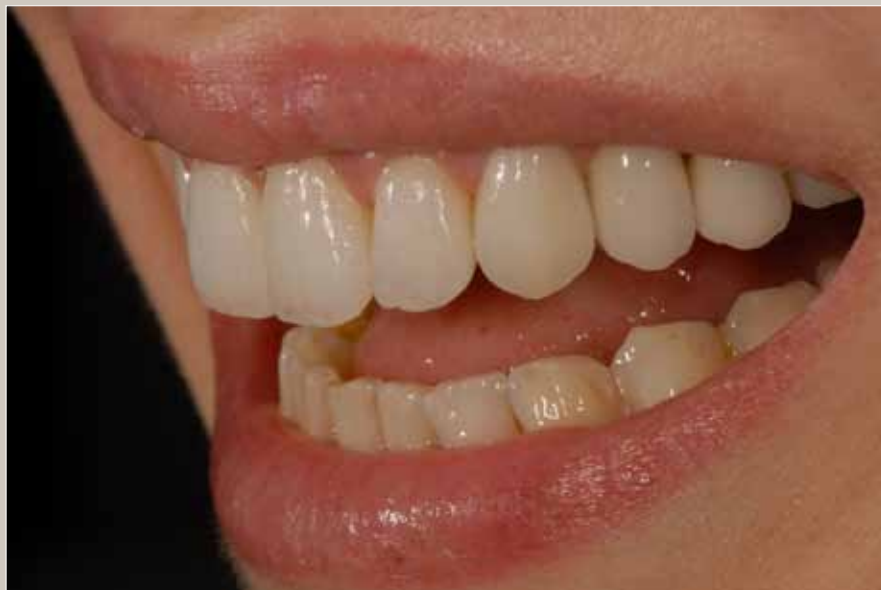Intraoral lateral views of definitive restoration.




Intraoral frontal view.



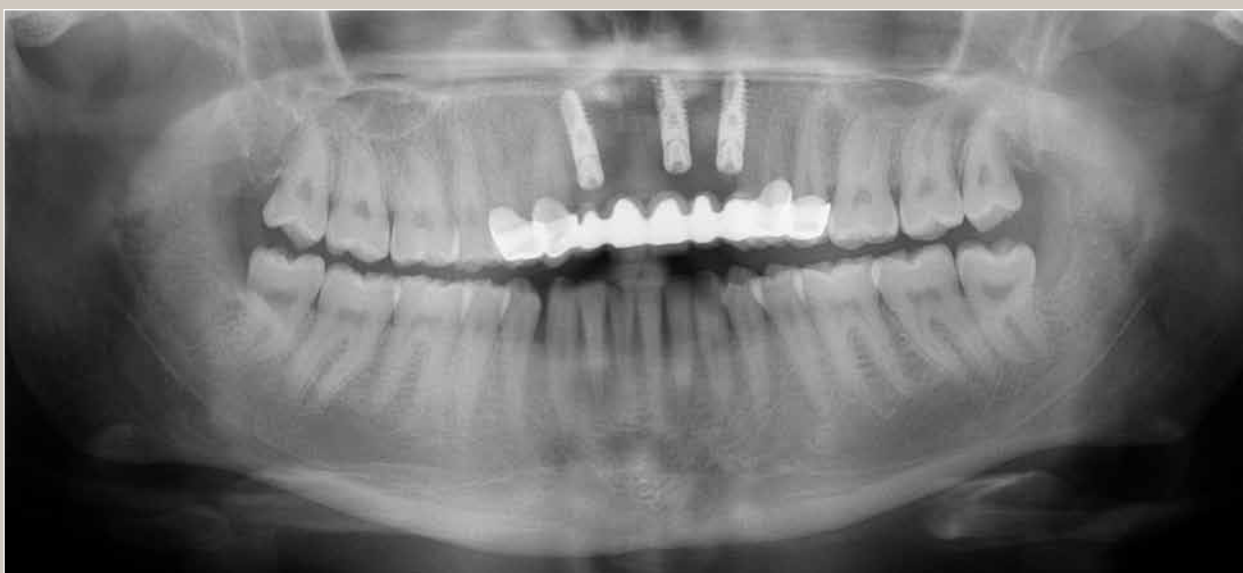Frontal smile view.



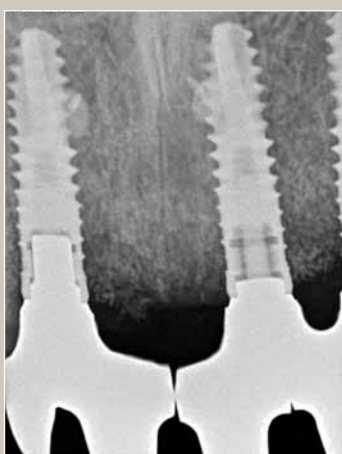
Oblique left lateral smile view.



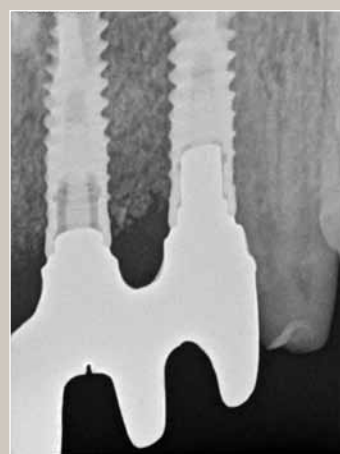Facial view of smile.



Panoramic radiograph.



Radiograph of implants at sites nos. 7 and 9.



Radiograph of implants at sites nos. 9 and 11.

*You may now place the corresponding posttreatment overlay found in the separate folder over the pretreatment periodontal chart on page XX.*

[Au: Page number to be determined once paginated.]

# A NOVEL DESIGN FOR OVERCOMING BONE LOSS

*Eric Van Dooren, DDS*



The “new world” of esthetic dentistry has created a great burden for the practicing clinician. Media-centered advertising would have one believe that anyone and everyone can buy the “perfect” smile. Although most of us recognize that this is not the case, this global hype has created a number of negative consequences:

- Patients present for treatment with unrealistic expectations.
- Many dentists are misguided into thinking that they should be able to meet or exceed patient esthetic expectations in all cases. Many of these clinicians feel inadequate if they cannot achieve the results that they see in monthly dental journals and magazines and online resources.
- Some cosmetic dentists are focusing more on patient “wants” than on patient “needs” and are not availing themselves of a comprehensive approach to treatment.

This case was chosen because it does not exemplify ideal treatment. It is not a treatment plan that the present-day cosmetic dentist would necessarily want to implement. And it is not a plan that the treating clinicians would consider as a first or even second choice of therapy. However, it is a very realistic and practical plan, considering the amount of bone loss present in the esthetic zone. It is novel in its design and relatively straightforward in implementation. This plan was minimally invasive and simple in concept, and the treatment outcome was esthetically pleasing.

# Case PRESENTATION 3

## *Treating clinicians*

*Prosthodontist, periodontist, and implant surgeon:* Eric Van Dooren, DDS

*Orthodontist:* Ralph Lemmens, DDS

*Dental laboratory and smile designer:* Christian Coachman, DDS, CDT

## CLINICAL TREATMENT PLANNING

Age at initial presentation: 42 years

Initial presentation: August 2007

Active treatment completed: February 2009

## Introduction and background

A 42-year-old woman presented with an esthetic problem associated with a failing implant restoration. The previous treatment, which was necessitated by trauma resulting from a car accident, was performed 7 years prior to the initial examination. Extensive bone grafting was performed at that time in order to restore the anterior ridge defect. Two implants had been placed in the areas of the missing teeth nos. 9 and 10. This patient's main complaint was an unpleasing smile. She was not in favor of re-treating the area surgically but stated that she might consider this option if it was minimally invasive. She also insisted that any solution be relatively simple and limited to as few procedures as possible.

## Medical history

- No notable findings
- Smokes 10 cigarettes/day

## Diagnostic findings

### *Extraoral and facial findings*

- Patient attempts to conceal teeth when smiling but displays teeth with full smile.

### *Intraoral findings*

#### Dental

- Crowding of the mandibular anterior teeth
- Supraeruption of teeth nos. 23 to 26
- Porcelain cracked and failing on teeth nos. 6 and 11
- Caries on tooth no. 8

#### Periodontal

- Thin gingival phenotype
- Generalized slight gingival inflammation
- Generalized periodontal probing depths of 2 to 3 mm
- Generalized moderate scalloping of gingival margins
- Generalized slight gingival recession
- Slight localized gingival recession on facial of previously restored teeth, especially tooth no. 6
- Extensive ridge deficiency in the area of teeth nos. 9 and 10
- Slight facial gingival excess on teeth nos. 2, 3, 7, 12, and 13
- Fair to good home care with minimal to moderate amounts of plaque present

### *Occlusal notes*

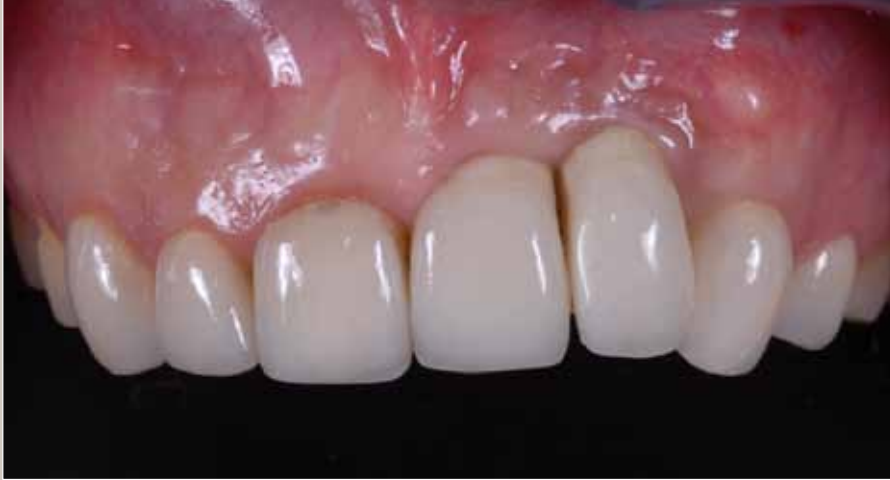- Angle Class II occlusion
- Horizontal overlap: 2.0 mm
- Vertical overlap: 2.5 mm
- Mandibular range of motion within normal limits

### *Radiographic findings*

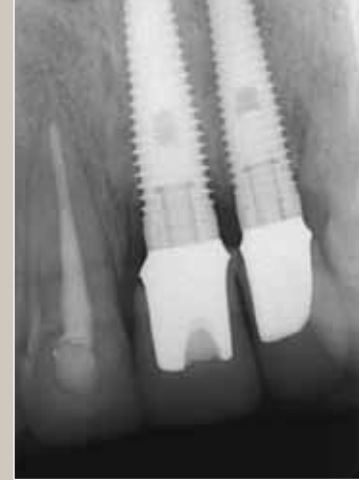- Advanced bone loss between implants at sites nos. 9 and 10
- Subgingival cement trapped between implants at sites nos. 9 and 10
- Open margins and imprecise fit of full crown on implant at site no. 9



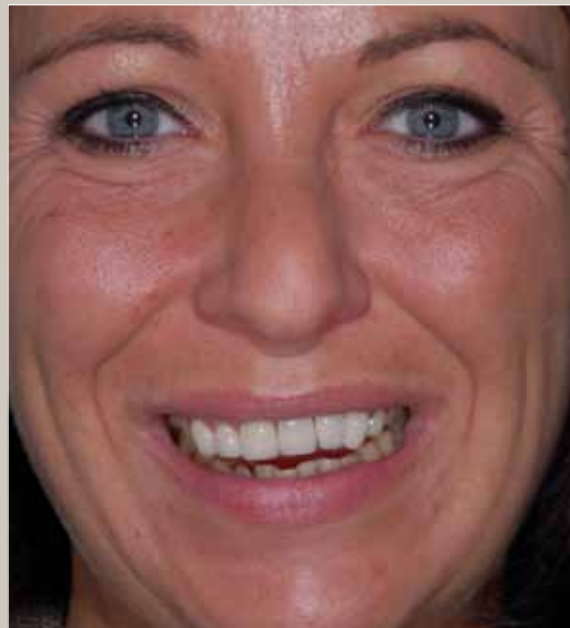## PRETREATMENT



Intraoral frontal view of maxilla.



Radiograph of implants.



Facial view of smile.

### Diagnosis

- Generalized slight marginal gingivitis
- Advanced bone loss around implants at sites nos. 9 and 10
- Severe soft tissue deformity in area of implants at sites nos. 9 and 10

### Prognosis

- General: excellent
- Implants at sites nos. 9 and 10: poor

### Treatment-planning considerations

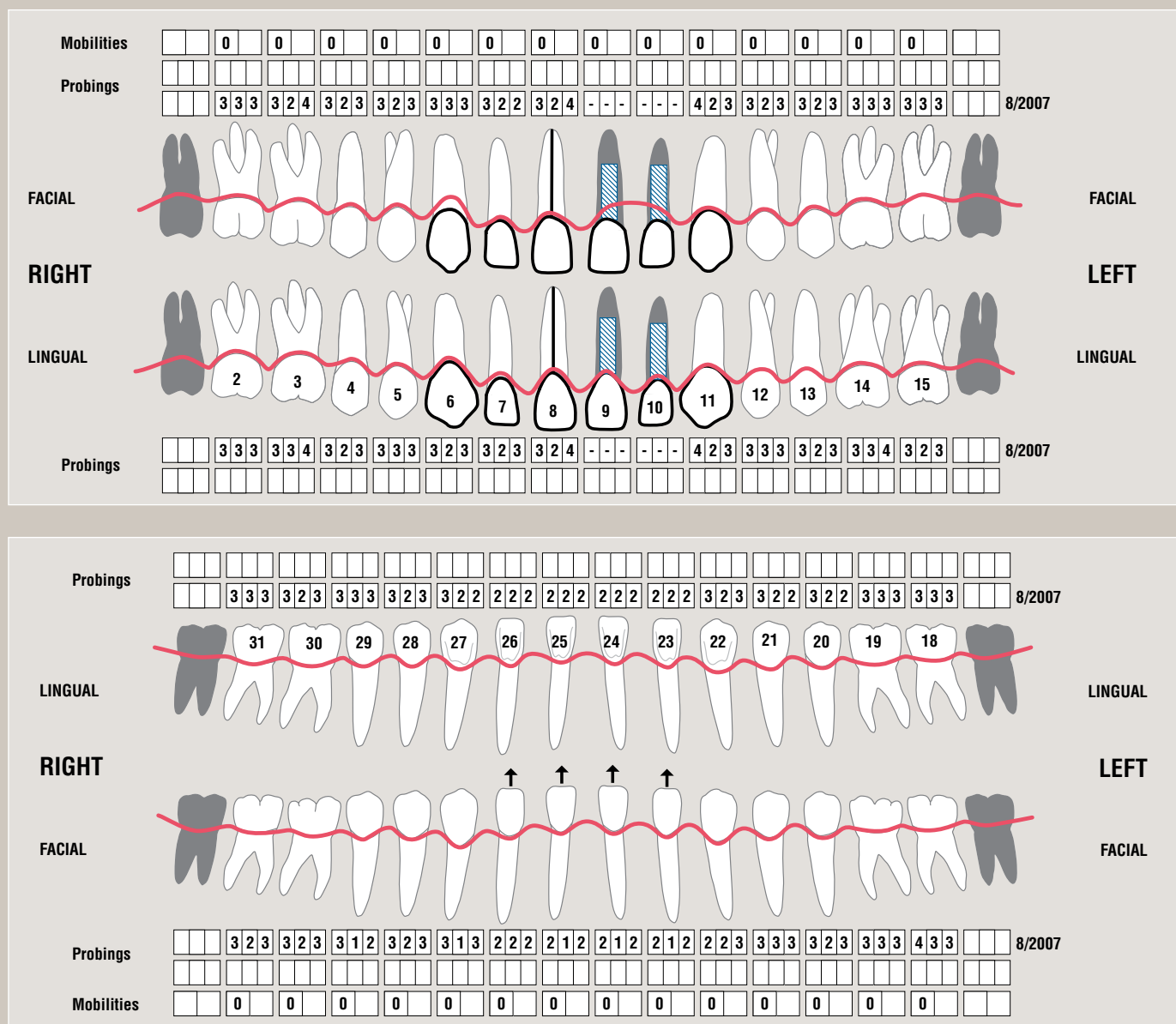
- This patient was very apprehensive about treatment because of negative past dental experiences and expressed interest in a noninvasive, nonsurgical approach to treatment. She qualified her wishes by stating that if surgery was absolutely unavoidable to achieve a successful esthetic result, it should be minimal and limited to a single surgical procedure.
- The patient expressed some concerns about her smile, especially regarding the midline, inclination of the incisal plane, and lack of symmetry in the length and form of her anterior teeth.
- This patient wanted to focus on the failing implants and did not want any of her other teeth to be treated. On the other hand, she understood that in order to improve tooth proportions and to create more esthetic harmony and balance, additional teeth may require treatment.

## Summary of concerns

1. Even if the patient consents to surgical soft and hard tissue augmentation, are there any surgical techniques that would predictably and fully restore the anterior ridge to its original state? Is it advisable to propose surgery, even with qualifications, and possibly create unrealistic expectations?
2. Considering that this patient is hesitant to proceed with any surgical treatment, if a decision is made to replace the

existing crowns and to try to restore harmony and balance to the face and smile, how can this be accomplished with minimally invasive procedures?

3. Recognizing that we may be limited in the amount of vertical ridge augmentation that can be achieved, how will we be able to compensate for this restoratively to meet or exceed the patient's treatment expectations?



*As a learning exercise, you may now outline goals/objectives of treatment and a treatment plan.*

## PROPOSED TREATMENT PLAN

### *Goals/objectives of treatment*

- Accomplish a fixed method of rehabilitation without involving nonrestored teeth
- Achieve optimal esthetics

### *Phase I: Data gathering and digital planning*

1. Intraoral and full-face digital photos are captured in order to establish:

- Proper incisal edge position
- Appropriate midline position and angulation
- Ideal tooth proportions and gingival contours

Photographic documentation is transferred to the computer for digital planning. The first step would be to relate the full-face smile photo to the horizontal reference line. The most common reference line used is the interpupillary line; however, the nasal or commissural lines can also be used. The midline is then projected onto the horizontal line, and digital planning is initiated. The treatment plan is evaluated, modified, and related to the DSD.

### *Phase II: Transfer of digital wax-up to the master cast*

2. The digital plan is transferred to the master cast.
3. Tooth form is copied from the digital forms.
4. White esthetics are optimized.
5. Pink esthetics are optimized.
6. The 3D defect around the implants is filled with pink wax, which allows us to evaluate the vertical and horizontal components of the ridge deficiency.

### *Phase III: Fabrication of intraoral mock-up and provisional partial denture*

7. The digital project or intraoral smile design is evaluated.
8. Old restorations are removed, and tooth locations and form are evaluated. Anterior provisional partial denture is fabricated.
9. DSD is evaluated and minor changes in form are made, if necessary, by applying flowable composite. The size of the anterior ridge defect is visualized by both the patient and the dentist.
10. Decisions are made as to whether and to what extent the anterior defect can be managed and how this will affect the

definitive restoration. Much of the decision making occurs based on careful 3D evaluation of the soft tissue contours, with special focus on the papilla heights and volume.

11. Esthetic and functional evaluation is performed to establish incisal edge position, soft tissue contours, altered midline inclination, lip support, and tooth form, which should provide overall facial balance and harmony.
12. Patient approval is obtained.
13. The treatment plan is finalized.

### *Phase IV: Establishing the definitive treatment plan*

14. Any final changes to the treatment plan are made, taking into consideration patient preferences. Final adjustments are also made to maximize soft tissue harmony, gain optimal soft tissue contours (compensating for the ridge deficiency), and optimize selection of prosthetic materials.
15. The definitive digital and intraoral concept is translated into the definitive treatment plan.

### *Phase V: Orthodontic therapy*

16. Orthodontic treatment is initiated in the mandibular arch to realign the mandibular anterior teeth and to intrude the incisors to aid in reducing the existing vertical overlap.

### *Phase VI: Surgical treatment*

17. Surgical therapy is performed, including possible clinical crown lengthening to attain adequate biologic width in the maxillary anterior segment.
18. Connective tissue grafting is performed where indicated to augment the anterior ridge.
19. Postoperative care is provided, and healing is allowed to occur.

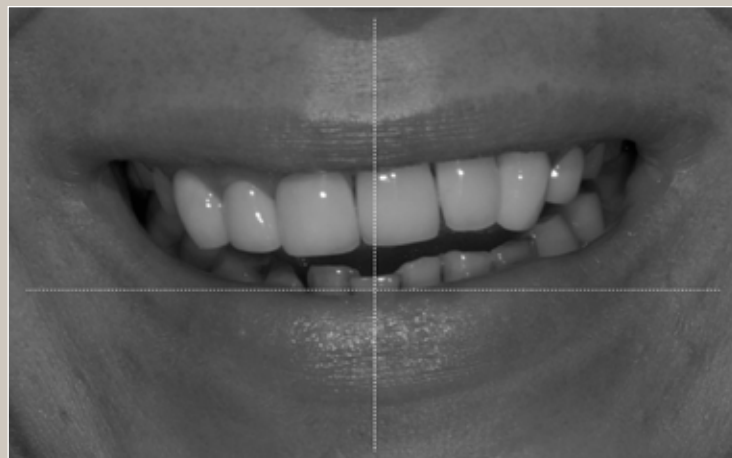### *Phase VII: Definitive restorations*

20. Minimally invasive definitive tooth preparation is performed.
21. Final impressions are taken, and the master cast is fabricated.
22. Definitive restorations are fabricated.
23. All restorations are tried in.
24. The definitive restoration is cemented.

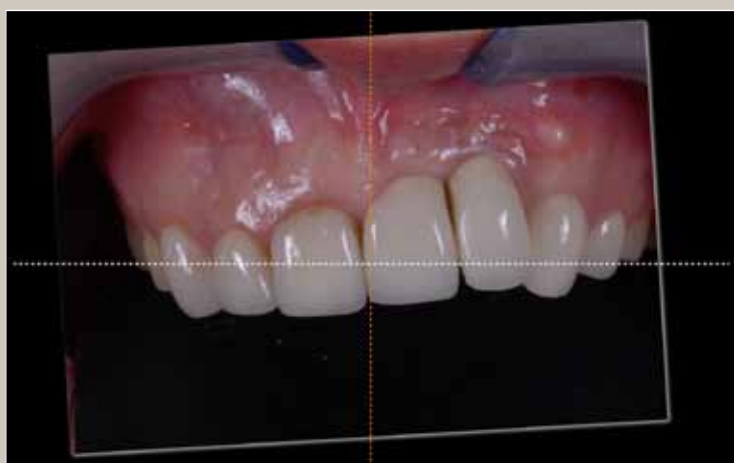## ACTIVE CLINICAL TREATMENT



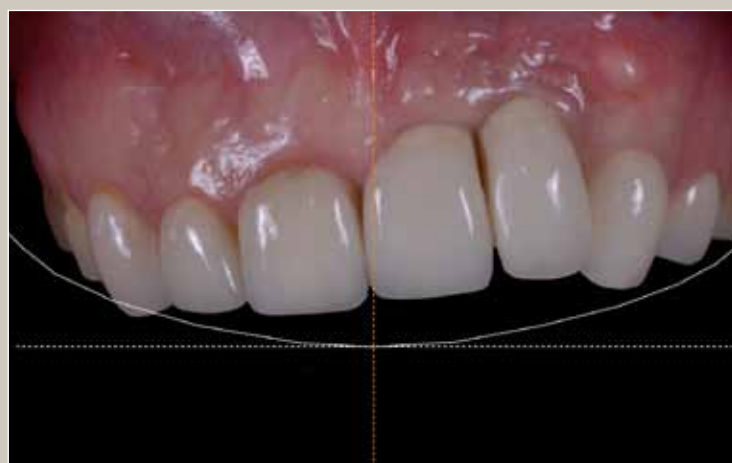Digital determination of the facial midline and horizontal reference plane on the facial photograph.



Close-up of smile from facial photograph with facial reference lines.



Transfer of the reference lines to the intraoral situation.



Incisal edge guideline.

### *Review of the goals/objectives of treatment*

- The goals and objectives of treatment for this patient were to accomplish a fixed method of rehabilitation without involving nonrestored teeth and to achieve optimal esthetics. The patient limited possible therapeutic options by insisting that treatment be performed with the fewest number of minimally invasive procedures.
- Digital treatment planning would be used in designing the most practical approach to achieving esthetic success considering the extent of the anterior alveolar ridge deficiency present.

### *Phase I: Data gathering and digital planning*

A protocol was established to be able to transfer the clinical and digital findings into a digital treatment plan. Photographic and dynamic video data were gathered on the patient. Intraoral and full-face smile images were taken. This data would be important for establishing proper incisal edge posi-

tion, midline position and angulation, tooth preparation, and gingival contours.

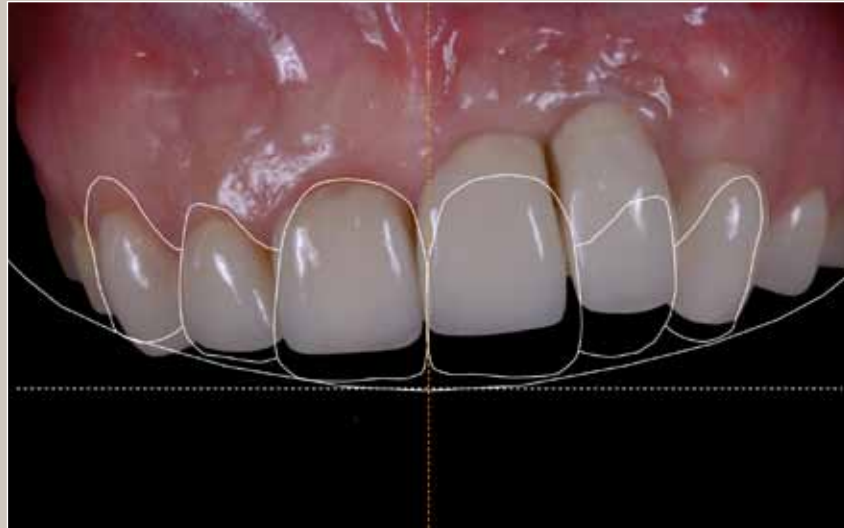
The photographic information was transferred to a computer so that digital planning could be initiated by relating the full-face smile image to the horizontal reference line. It was evident that digital planning with only an intraoral photo would make it extremely difficult to correctly analyze these parameters because of the lack of any facial horizontal reference.

The interpupillary line should be the first reference used to establish the horizontal plane, but it should not be the only one. We have to analyze the face as a whole and then determine the best horizontal reference that will result in the most harmonious facial outcome. Other facial lines, such as the nasal line, commissure line, and mandibular angle, should be analyzed. Determining the horizontal plane of reference is a much more subjective and artistic decision than an objective exercise. We have found that it is easier to determine this esthetic reference digitally rather than relying on a facebow or any other device. The static image of the patient on the computer screen and the addition of the lines is the most

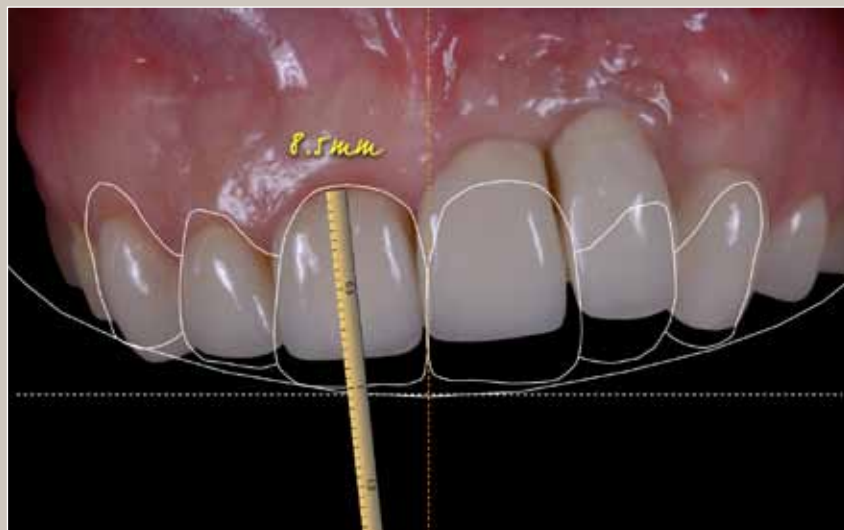




Photograph of the patient taken before the accident with the natural dentition intact.



Outlines of the teeth accomplished using Keynote software.



Digital ruler used to make initial measurements.

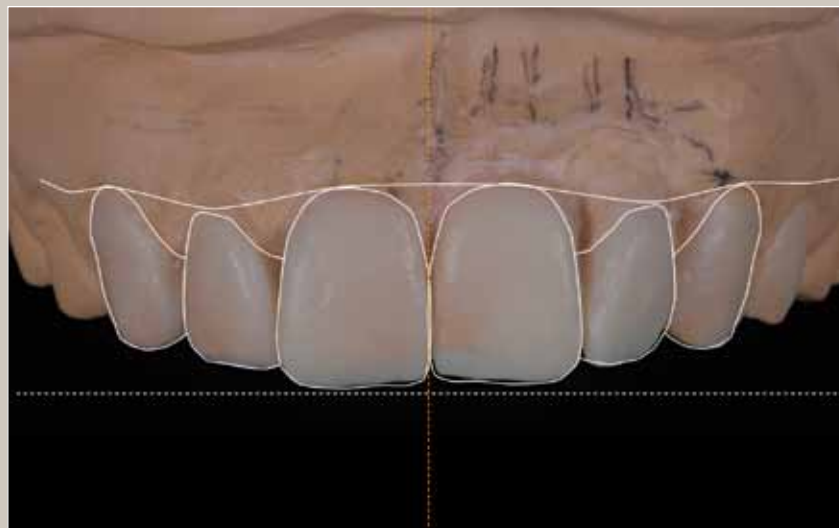
precise way to determine this horizontal plane. Then this digital information must be transferred to the master cast, which is accomplished using the digital ruler and a real caliper. Once the horizontal reference has been established, the midline can then be projected onto the horizontal line.

It became quite evident that in this particular case the midline was significantly canted and the incisal edge position and length were incorrect. Tooth no. 6 appeared disproportionately long, and excessive gingival display was present around teeth nos. 4 to 7, 12, and 13.

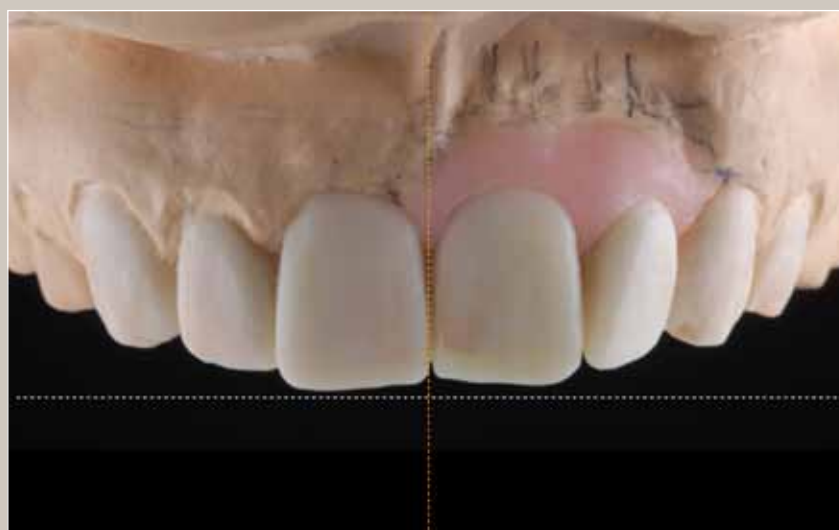
After relating the intraoral to the full-face photograph, keeping the same angulation, we initiated digital planning. First the incisal length of one of the central incisors was determined digitally by outlining the correct tooth proportions and ideal form. This image was then mirrored, and from this point a digital setup could be completed. A facial photo that was taken before the accident was very helpful at this stage. We

considered this a virtual mock-up, allowing us to relate the digitally created forms to the existing clinical situation and the face. At this point, the clinical treatment plan for the patient needed to be adjusted and related to the DSD.

By evaluating the distance from the digitally determined ideal incisal edge position of tooth nos. 9 and 10 to the existing marginal soft tissue level, it was apparent that surgical ridge augmentation would not accomplish what was necessary to significantly improve the esthetic outcome. After evaluating the buccal soft tissue level of tooth no. 10 as it related to the buccal placement of the implant (followed by apical soft tissue shifting) and the papilla height defect between teeth nos. 9 and 10, it became clear that this area was not surgically restorable. Limitations of vertical augmentation procedures, especially for papilla augmentation, should be recognized early and then assessed to determine the most prudent treatment approach if compromise is going to be accepted.



Information and measurements transferred to the study cast.



Addition of pink wax to create the ideal gingival outline.

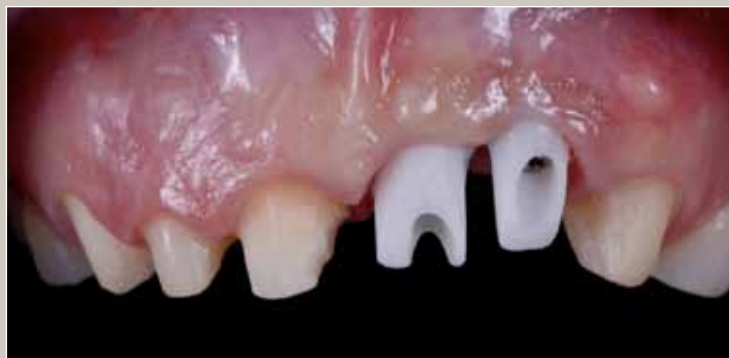By designing the incisal contours, relating them to the horizontal line, and correcting the interincisal line, it became evident that the patient would benefit from plastic periodontal surgery and surgical crown lengthening.

### *Phase II: Transfer of digital wax-up to the master cast*

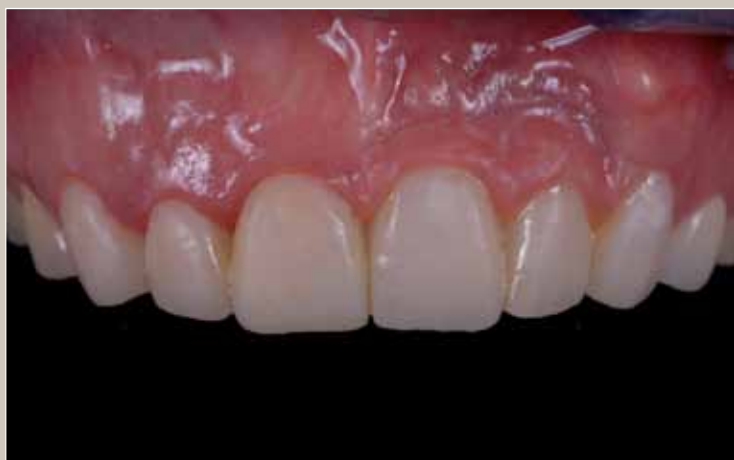At this point, we needed to transfer the digital plan to the master cast. It was important to position the cast in the articulator with the same inclination as was established in the digital planning. Digital measurements are made on the computer and then transferred to the cast with a caliper. First the horizontal plane and then all other measurable information are transferred from digital form to the cast with a pencil. The

information transferred to the cast will act as a guide in the wax-up procedure. Drawing a horizontal line, keeping the cast in hand, and comparing it visually with the digital inclination aided in accomplishing this. Tooth form was copied from the digital forms. At this point, the dental technician focused on ideal tooth form.

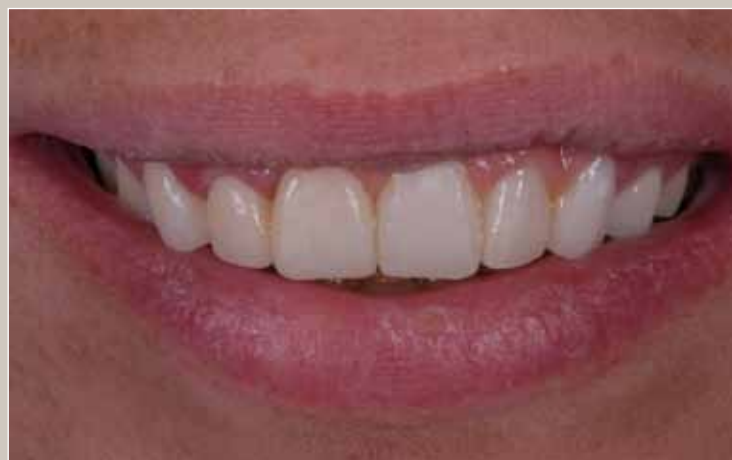After white esthetics were optimized, ideal pink esthetics were established by filling the 3D defect around the implants with pink wax. This would again allow us to evaluate the vertical and horizontal component of the ridge deficiency. With careful pre-evaluation of an ideal white and pink wax-up by the surgical team, there would be a better understanding of the 3D topography of the ridge defect and its effect on smile design. From this wax-up, we could produce a silicone index that would enable us to intraorally fabricate an exact copy of the wax-up.



Intraoral view after removal of the old crowns.



Intraoral view of provisional partial denture with pink composite.



Smile view of provisional partial denture.

### *Phase III: Fabrication of intraoral mock-up and provisional partial denture*

In the next phase, we evaluated the DSD intraorally. The old restorations were removed. It became evident that the implant in tooth position no. 10 was in significant labioversion. A silicone index (related to the final tooth forms on the wax-up) guided the preparation of the provisional restorations. At this point, an acrylic material (Outline, Anaxdent) was injected in the silicone index and applied intraorally. The provisional partial denture was seated and adjusted.

At this stage, the digital plan was evaluated, and a flowable composite was used to visualize the size and extent of the soft tissue and bony defects. As previously anticipated, the defect

was going to be unmanageable surgically, and we would not be able to restore the ridge to its original dimensions.

To better conceptualize the size of the defect, a pink composite provisional material was applied to the provisional partial denture. While the optimal tooth form was the guide for this provisional pink application, care was taken to establish the ideal 3D soft tissue contours, focusing on the papilla heights and volume. This step led to the conclusion that the defect was affecting not only the vertical and horizontal components of the ridge but also the papilla height and volume on the mesial aspect of tooth no. 8 and distal aspect of tooth no. 11. At this time, it was apparent that the most optimal esthetic and functional restoration would be an artificial prosthetic gingival restoration.

The papilla height of the natural teeth on the contralateral side was used as a reference in order to establish proper gingival contours in the area of the defect. Many times it is easier to establish the papilla design digitally first by taking a photograph of the provisional partial denture and designing the soft tissue contours on the computer screen in an Apple Keynote presentation. This makes it easier to transfer the DSD concept to the oral environment.

At this time, we performed an esthetic and functional evaluation. The objective was for the incisal edge position, soft tissue contours, altered midline inclination, lip support, and tooth form to create an overall balance and facial harmony. Once the projected esthetic outcome was approved by the patient, the final treatment plan was established.

Hygiene instruction was provided because it is crucial for all artificial prosthetic gingival restorations, including the provisional restorations.

### *Phase IV: Establishing the definitive treatment plan*

When it was time to translate the digital intraoral concept into a final treatment plan, we contemplated what we could do to maximally enhance the definitive esthetic and functional outcomes, considering that the patient wanted little or no surgery and that the existing ridge deficiency could not be restored surgically if we wanted any symmetry in soft tissue levels and papilla heights.

The following ideas were considered:

- We would improve soft tissue harmony and achieve a better balance in soft tissue levels by performing surgical clinical crown lengthening on teeth nos. 4 to 8, 12, and 13. The patient was reluctant but willing to undergo this procedure.
- We would fabricate a pink hybrid restoration to compensate for the extremely compromised ridge. There were two options considered to achieve this:
  1. Use the two natural teeth (nos. 8 and 11) as abutments for a four-unit fixed partial denture. With this approach, the implants would be submerged or eventually removed.
  2. One or both implants would be incorporated into the hybrid restoration.

Using the natural teeth as abutments for a fixed partial denture would not be ideal because the pink interface between natural and artificial gingiva would not be esthetically pleasing. Moreover, there would be limited retrievability should the restorative material need to be replaced in the future. Therefore, the hybrid concept was chosen.

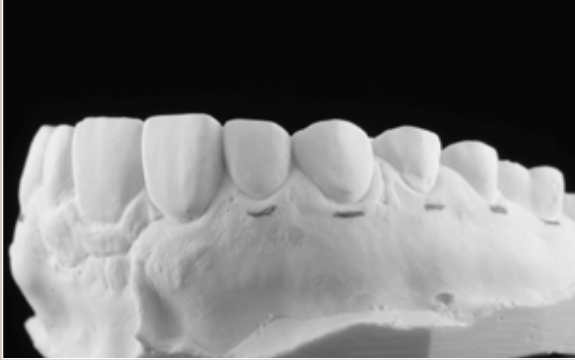
The decision was also made to incorporate only one implant as an abutment in supporting the hybrid restoration because it would provide easier access for hygiene maintenance. Also, with a cantilever it would be easier to achieve optimal esthetics with the artificial gingiva. We decided to use the implant in the no. 9 position and to submerge the implant in the location of tooth no. 10. A connective tissue graft procedure was performed to augment the buccal aspect of the ridge defect at the time that the implant was submerged. This resulted in easier and better adaptation of the artificial gingiva material.

- We would endeavor to optimize the prosthetic materials. All-ceramic single crowns (e.max Press, Ivoclar Vivadent) were to be fabricated on teeth nos. 6 to 8, 11, and 12. A PFM, two-unit, palatally screw-retained, cantilevered partial denture would be fabricated on the implant at site no. 9. The challenge for the technician would be to match the two-unit, PFM partial denture to the all-ceramic, single-tooth restorations.

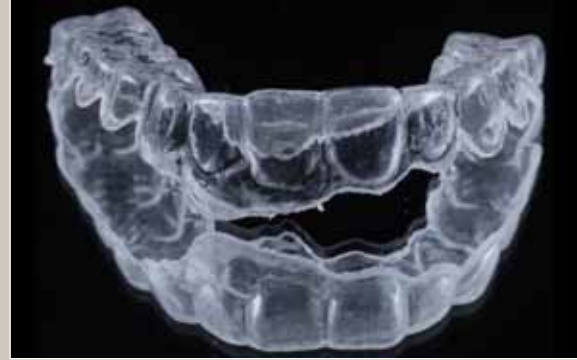### *Phase V: Orthodontic therapy*

Once the treatment plan had been finalized, orthodontic therapy was initiated to intrude and align the mandibular anterior teeth. This took approximately 6 months to complete, was uneventful, and did not interfere with any treatment being performed simultaneously in the maxillary arch.

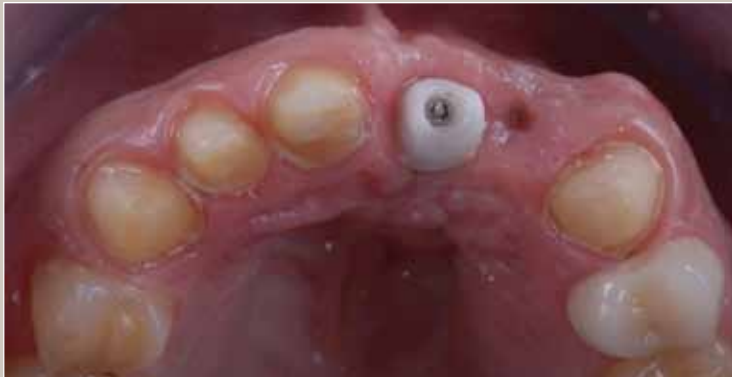



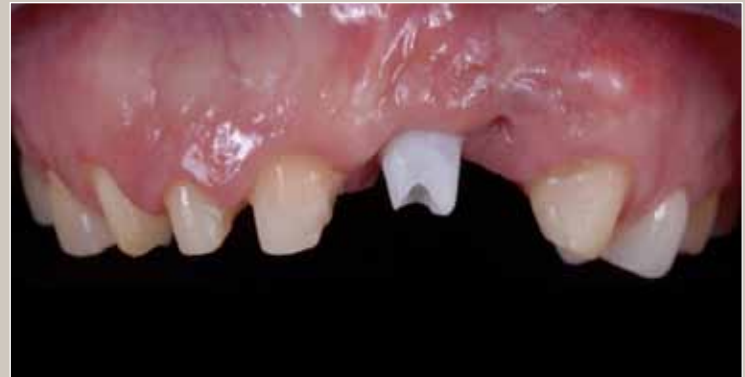Crown lengthening suggested on the digital design transferred to the cast for fabrication of surgical stent.



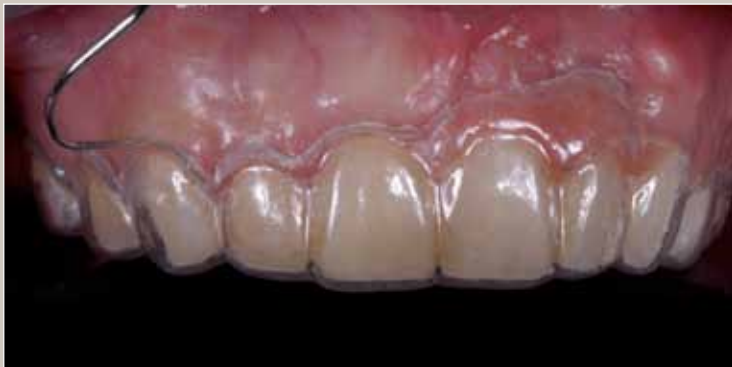Crown lengthening surgical stent.



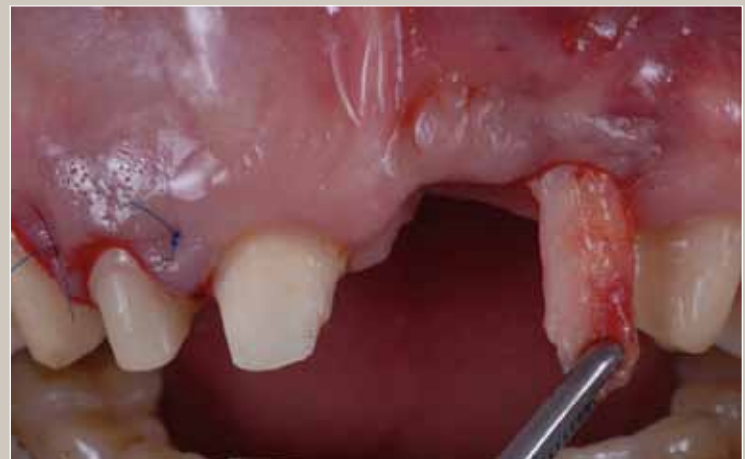Occlusal view of anterior maxilla before surgery.



Intraoral frontal view of maxilla before surgery and after removal of the zirconia abutment of tooth no. 10.



Marking the soft tissue with the explorer with the crown lengthening surgical stent in place.



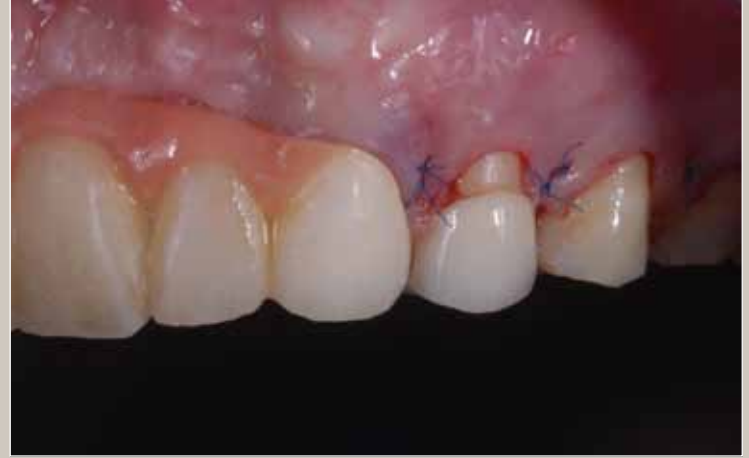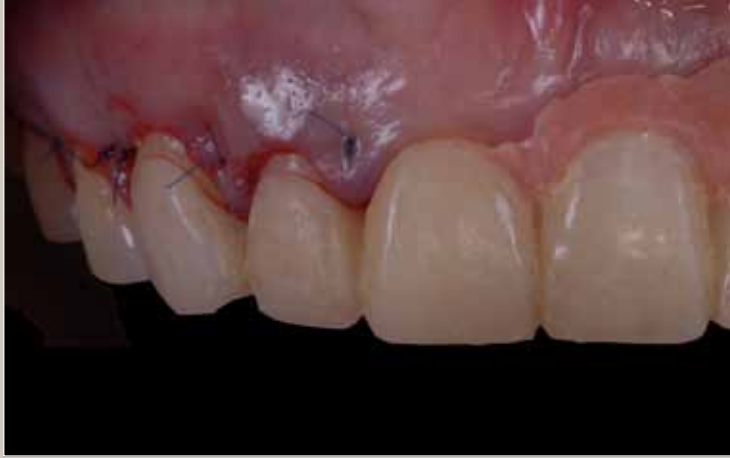Connective tissue graft for submergence of the implant at site no. 10 and to improve the horizontal aspect of the defect.

### *Phase VI: Surgical treatment*

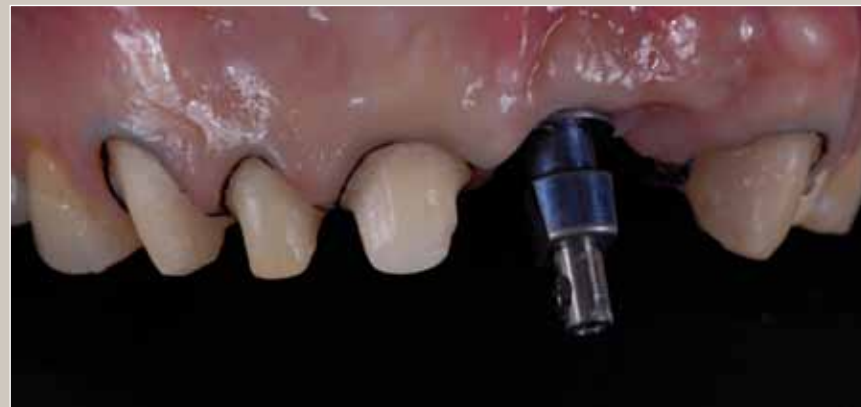Surgical treatment was guided by a surgical stent designed and fabricated from the cast made with the approved provisional fixed partial denture.

Clinical crown lengthening via osseous resection was performed on teeth nos. 4 to 7 and 11 to 13, making sure

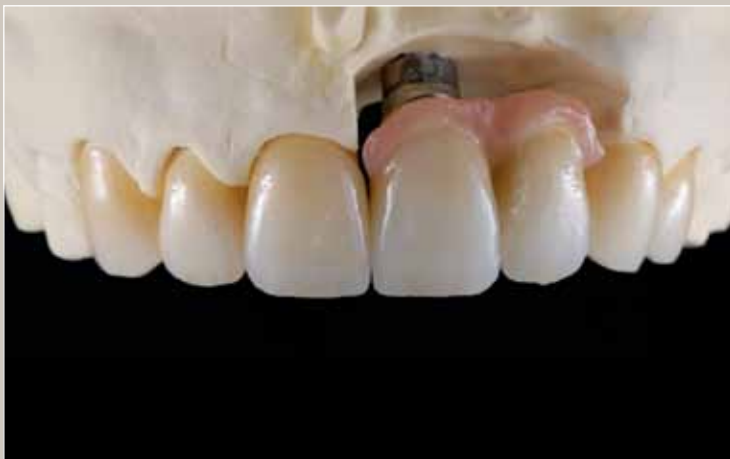that at least 3 mm of functional, attached gingiva was maintained. Adequate biologic width was also created. A connective tissue graft was placed as an onlay to the ridge (covering the implant) and in a buccal pouch at site no. 10. Healing was uneventful, and sutures were removed after 1 week.



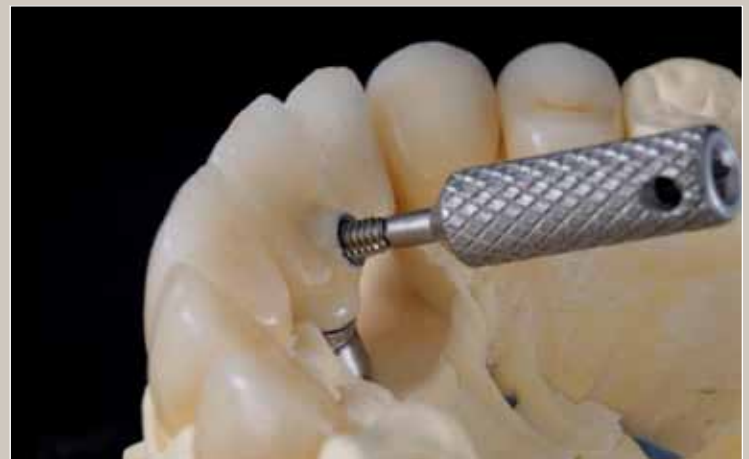Intraoral lateral views of the maxilla after crown lengthening.



Intraoral frontal view of maxilla prior to final impression taking.



Definitive restorations on the cast.

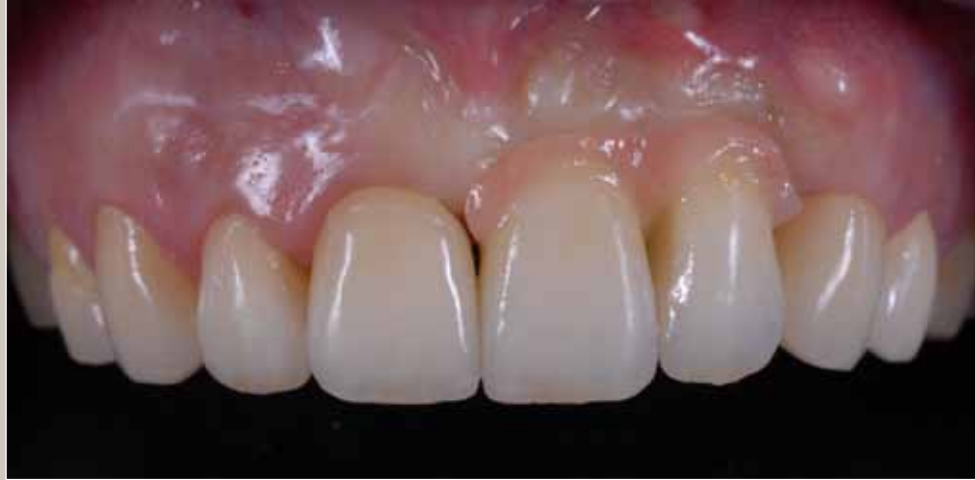

Placement of palatal screw.

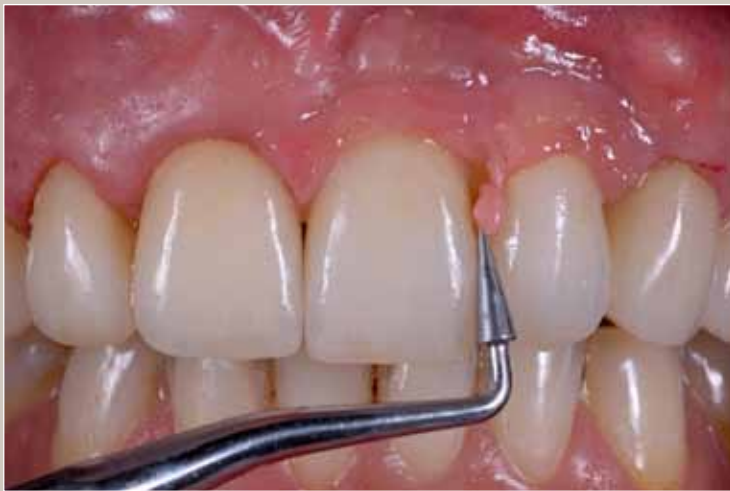### *Phase VII: Definitive restorations*

At 4 months postoperative, final tooth preparation was initiated. Care was taken to maintain a minimally invasive approach and to achieve biologically compatible preparations and impressions. A silicone index (related to the tooth forms of the provisional design) was used to guide our final preparations. Impressions were taken, and the master cast was fabricated.

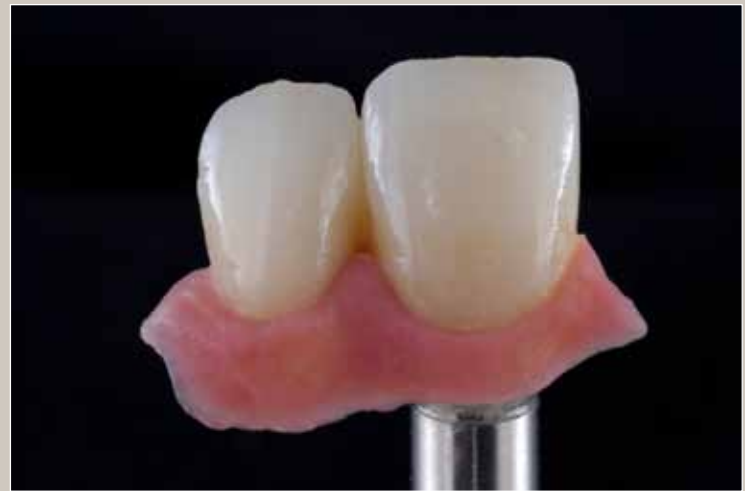Ideally, for the pink hybrid restoration,<sup>5-8</sup> an implant-supported restoration should be retrievable. Because the implant in site no. 9 was placed buccally, a custom abutment was required to allow for adequate retention of the palatal screw. All-ceramic single crowns and a two-unit PFM partial denture (IPS d.Sign, Ivoclar Vivadent) were fabricated. The two-unit partial denture was already provided with a palatal layer of pink porcelain, which allowed for intraoral application and finishing with pink composite material (Anaxgum, Anaxdent).



Intraoral frontal view of maxilla at try-in.



Intraoral application of the pink composite layer.



Partial denture with finished pink composite removed for final shaping, polishing, and glazing.

At this stage, all prosthetic components and crowns were tried in, and minor modifications were made. Tight adaptation with some light ischemia was visible around the pink porcelain at the try-in.

All single e.max crowns were adhesively cemented, which was followed by intraoral application of the pink composite layer. Prior to this, in the lab, the usual protocol of steaming, sandblasting, etching, silanization, bonding, and application of the first layer of flowable pink composite was used to ensure effective and strong bonding between the pink porcelain and the first layer of pink composite.

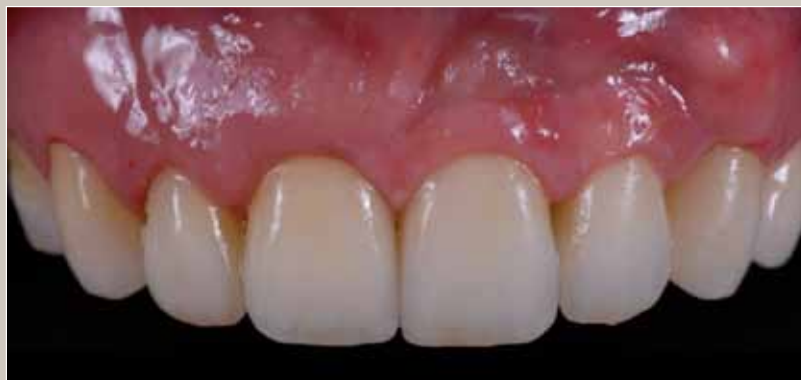The color of the gingiva on the right side was used to select the most ideal color of pink composite. Different shades and

tints were used to enhance the esthetic outcome. Surface texture and polish of the pink composite were optimized, and after final polymerization and polishing in the lab, the two-unit partial denture was cemented. Occlusion and hygiene were checked. The patient was seen on a 6-month maintenance program.

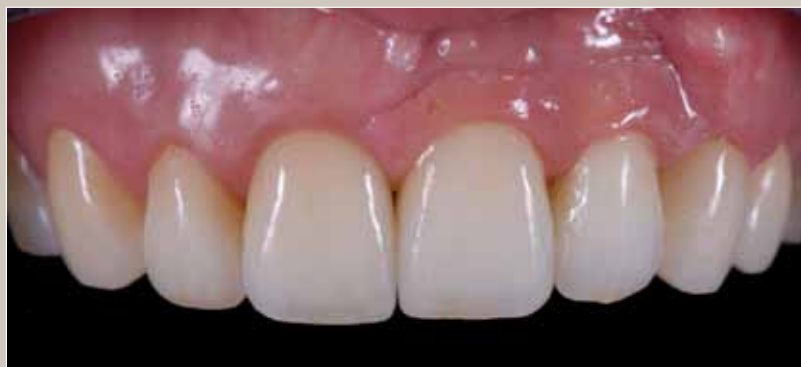The 18-month postoperative pictures demonstrate a very acceptable and pleasing esthetic and functional result. When comparing the before and after pictures, a dramatic change could be observed. It is clear that diagnosis and treatment planning, using digital technology, can assist in evaluating ridge deficiencies, visualizing potential treatment solutions, and achieving predictable esthetic and functional outcomes.



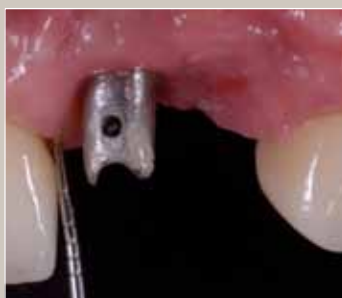## POSTTREATMENT



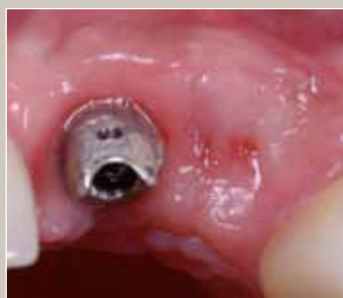Intraoral frontal view of maxilla at the end of treatment.



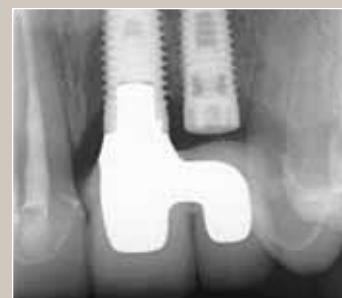Intraoral frontal view of maxilla 18 months after treatment.



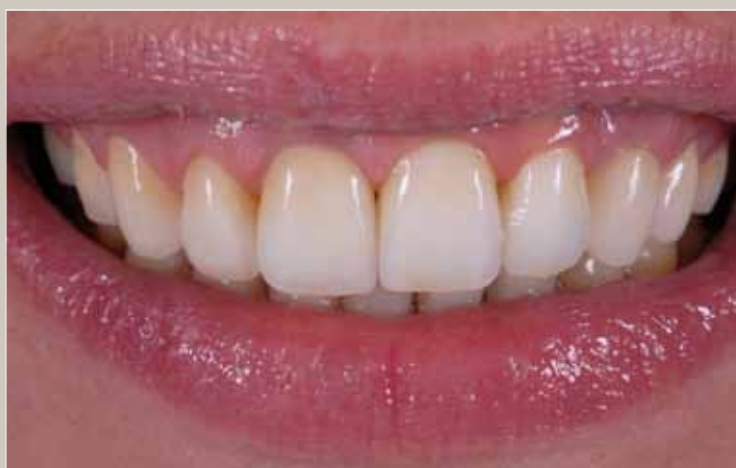Removal of partial denture to check the soft tissue condition at 18-month checkup.



Occlusal view of healthy soft tissues at 18-month recall.



Radiograph at 18-month recall.



Smile view at 18 months posttreatment.

*You may now place the corresponding posttreatment overlay found in the separate folder over the pretreatment periodontal chart on page XX.*

[Au: Page number to be determined once paginated.]



## COMMENTARY

### *Communication*

The dental literature has highlighted the importance of the smile design, although it has been vague regarding how the information ideally should be gathered and implemented. The importance of gathering the diagnostic data through forms and checklists<sup>9-14</sup> is emphasized. However, many of these pieces of information may be lost if their real meaning is not transferred in an adequate way to the design of the rehabilitation.

Traditionally, the smile design has been instituted by the dental technician, who performs the restorative wax-up, creates shapes and arrangements in accordance with limited information, and follows instructions and guidelines provided by the clinician in writing or by phone. In many cases, the technician is not given enough information to use his or her skills to their maximum potential, and the opportunity to produce a restoration that will truly satisfy the patient is missed.

When the treatment coordinator or another member of the restorative team who has developed a strong personal relationship with the patient takes the responsibility for the smile design, the results are likely to be far superior. This individual has the ability to communicate the patient's personal preferences and/or morphopsychologic features to the laboratory technician, providing information that can elevate the quality of the restoration from one that is adequate to one that is viewed by the patient as exceptional.<sup>14,15</sup>

With this valuable information and that from the 2D DSD in hand, the dental technician will be able to develop a 3D wax-up more efficiently, focusing on developing anatomical features within the parameters provided, such as planes of reference, facial and dental midlines, recommended incisal edge position, lip dynamics, basic tooth arrangement, and the incisal plane.

Transferring this information from the wax-up to the test-drive phase is achieved through a mock-up or a provisional

restoration.<sup>11,13,16</sup> The design of the definitive esthetic restorations should be developed and tested as soon as possible, guiding the treatment sequence to a predetermined esthetic result. Efficient treatment planning results in the entire treatment team being able to better identify the challenges they will face and helps expedite the initiation and completion of treatment.<sup>1</sup>

### *Assessment, feedback, and learning*

The DSD allows a precise re-evaluation of the results obtained in every phase of treatment. With the drawings and reference lines created, it is possible to perform simple comparisons between the before and after pictures, determining if they are in accordance with the original planning or if any other adjunctive procedures are necessary to improve the outcome. The dental technician also gains feedback related to tooth shape, arrangement, and color so that definitive refinements can be made. This constant double-checking of information ensures that a higher-quality product will be delivered from the laboratory and also provides a great learning tool for the entire interdisciplinary team.

### *Education*

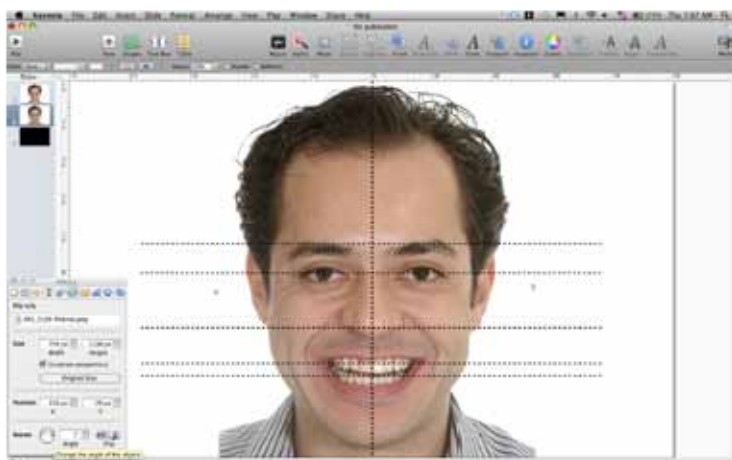
In many cases, patients are not satisfied with their appearance but really do not understand which contributing factors are responsible. When the clinician is able to clearly illustrate the elements present that deviate from ideal esthetic principles, the patient is more likely to appreciate the treatment challenges ahead and the potential compromises that may ensue. In an educational presentation, the clinician can explain the severity of the case, introduce strategies for treatment, discuss the prognosis, and make case management recommendations.

## CASE PRESENTATION

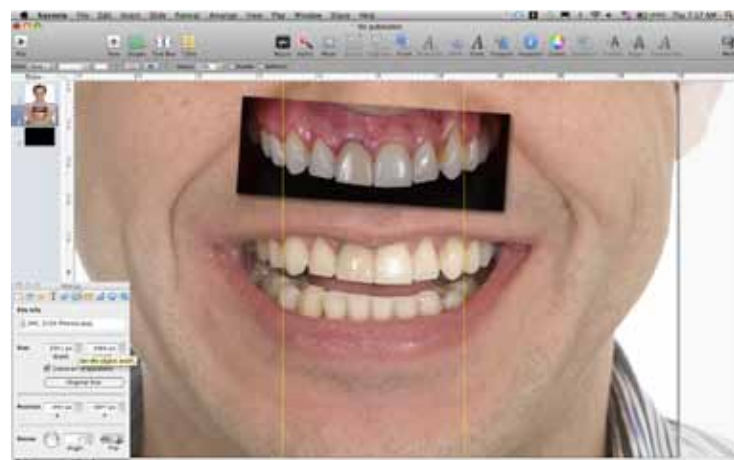The DSD makes the treatment-planning presentation much more effective and clear because it allows patients to see and better understand the combined multiple factors that are responsible for their orofacial issues. The case presentation is effective and dynamic because the problem list is superimposed over the patient's own photographs, increasing the credibility, trust, and acceptance of the proposed plan.

### *Digital smile design workflow*

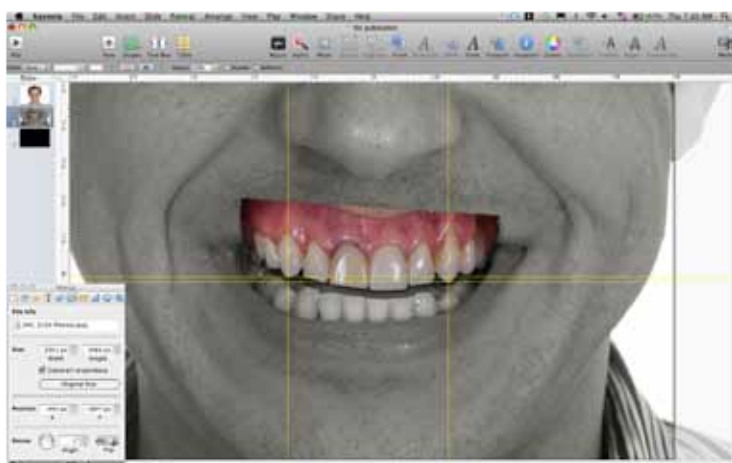
The proposed DSD technique is performed by the authors using Apple Keynote; however, other similar software, such as Microsoft PowerPoint, can also be used with minor adjustments in the technique. Keynote allows simple manipulation of the digital images and the addition of drawings, lines, shapes, and measurements over the clinical and laboratory images. The main steps of the DSD are described and illustrated below.



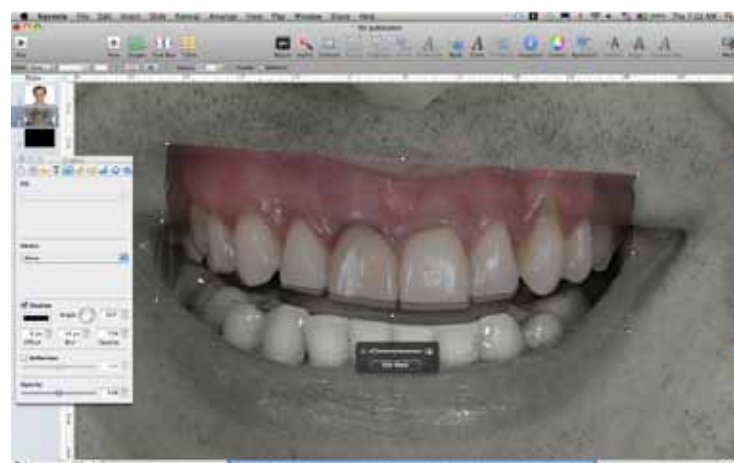1. Digital facebow: Determining adequate horizontal plane of reference and facial midline by moving and turning the photo behind the lines.



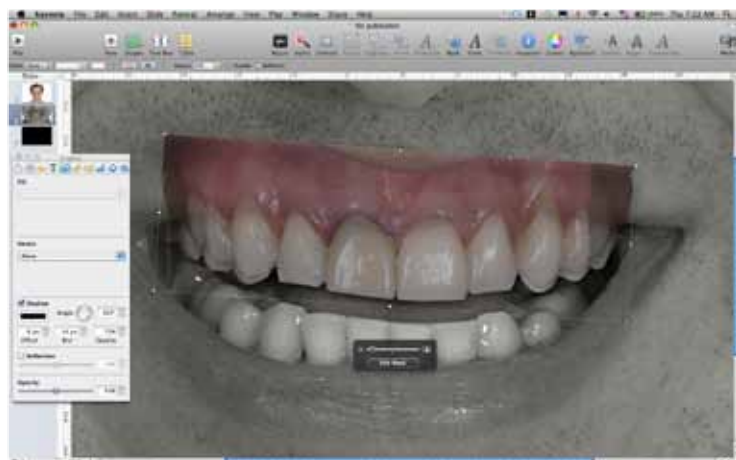2. Transferring the facial lines to the intraoral situation by grouping the lines and overlapping the photos. Matching the dimensions of the photos by using the two vertical lines on the distal of the canines as a reference.



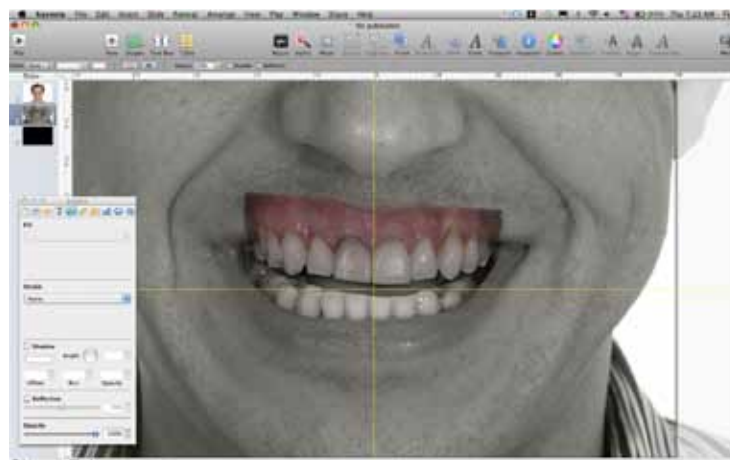3. Leveling the canting of the incisal edges by taking as a reference the tips of the canines. The black background of the intraoral photo is removed to facilitate the process.



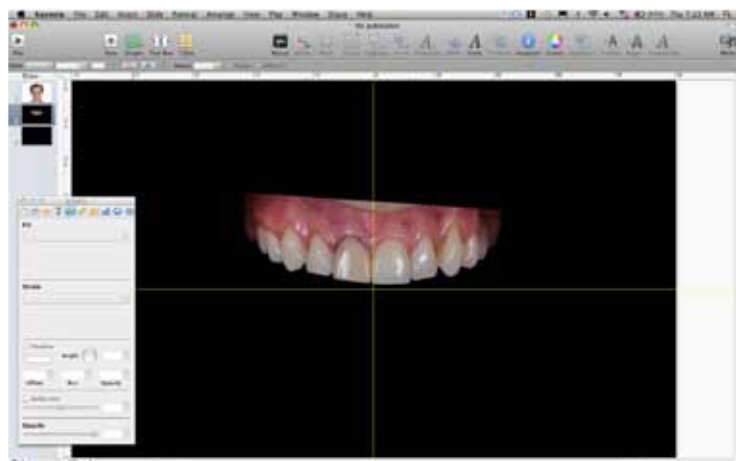
4. Matching the dental midlines by moving the photo left and/or right. The opacity of the intraoral photo is decreased (50%) to facilitate the process.



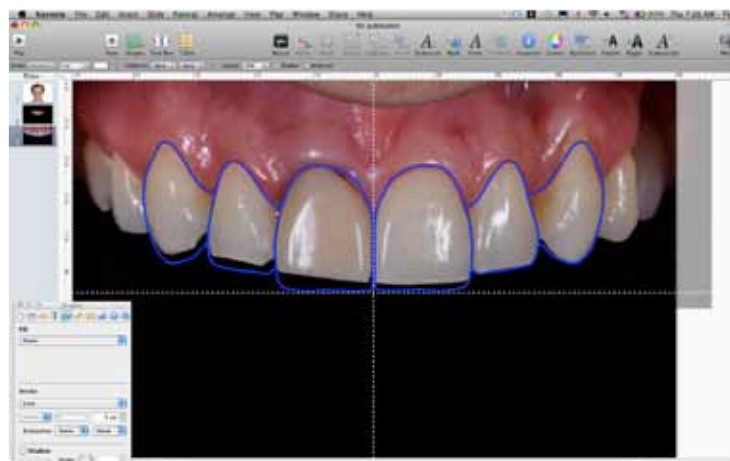
5. Matching the incisal edge of the central incisors by moving the intraoral photo up and/or down.



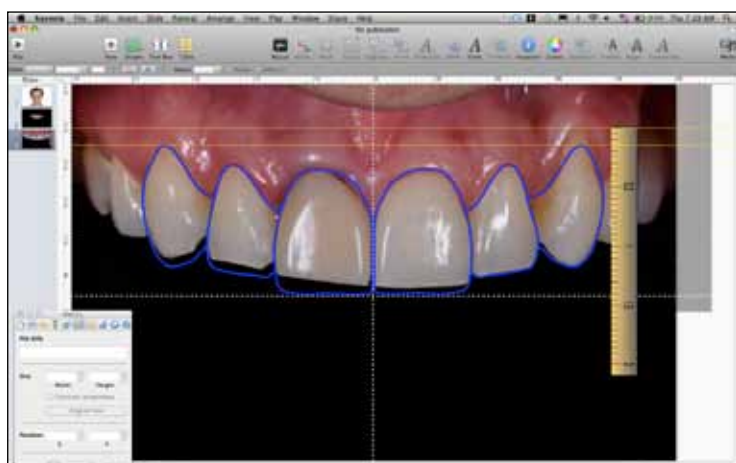
6. The intraoral photo is then completely adjusted to the facial reality.



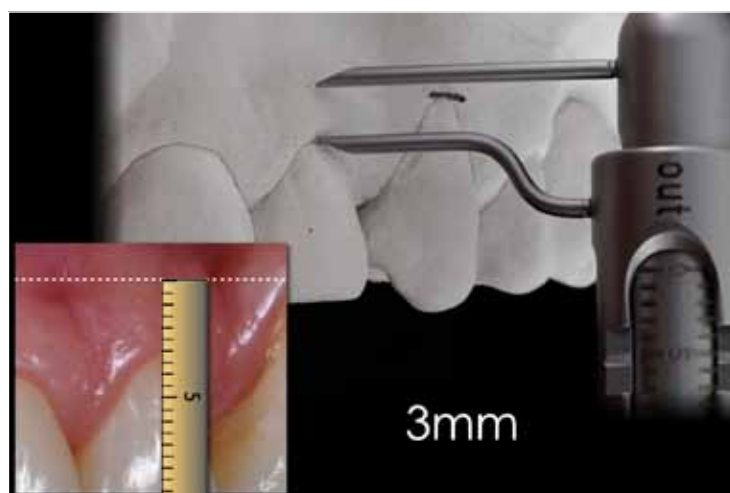
7. Deleting the facial photo and analyzing the intraoral photo according to the two main facial guidelines.



8. Digital mock-up: Designing the teeth on the screen following the guidelines. Analyzing the discrepancies and possible solutions.

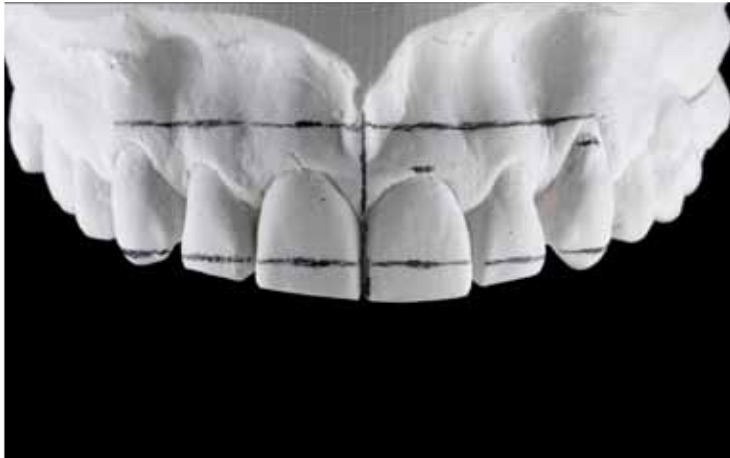


9. Digital ruler: Making all the digital measurements necessary to transfer the guidelines to the working cast. Before measurement, the ruler needs to be calibrated by measuring the real size of the central incisor on the stone cast.

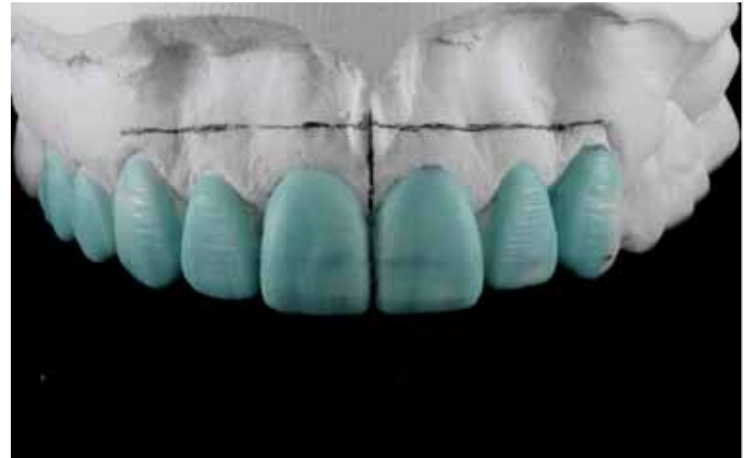


10. Transferring the measurements to the working cast using a caliper.

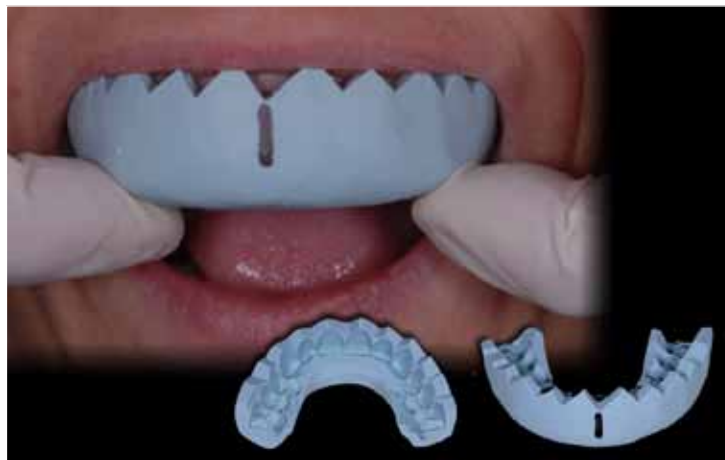



The cast is ready for a guided, precise, and predictable wax-up that will be in harmony with the patient's face and smile.



11. Performing a guided wax-up.



12. Testing the whole project by transforming the wax-up into a mock-up using silicone indices and resin.



13. Using photographs and videos to analyze the mock-up and communicate with the patient to determine the final project for the new smile design.



## LIVING WITH COMPROMISE

The cases presented for treatment planning in this chapter all challenge our willingness to accept compromise. The concept of compromise sometimes can be hard to swallow, and yet the treatment outcomes in all three cases suggest that falling short of the ideal should not necessarily be taken as defeat. Treatment success is most important and is subject to the interpretation of the patient. Patient satisfaction trumps the clinician's view of the ideal outcome every time that the two are not the same. As previously proposed in the Editor's Introduction to this suite of cases, compromise

should be considered an opportunity to achieve exceptional treatment results using alternative treatment modalities. The treating clinicians and laboratory technicians in all three cases are well versed in ideal dentistry and yet feel that the outcomes in situations like these are the most fulfilling and rewarding. All three patients expressed their gratitude and appreciation for treatment that far exceeded their expectations. They were thrilled with the results, and is this not the reason that we engage in our profession each day?

## REFERENCES

1. Dawson PE. Functional Occlusion: From TMJ to Smile Design. St Louis: Mosby, 2007.
2. Spear FM. The maxillary central incisor edge: A key to esthetic and functional treatment planning. *Compend Contin Educ Dent* 1999;20:512-516.
3. Kois JC. Diagnostically driven interdisciplinary treatment planning. *Seattle Study Club J* 2002;6(4):28-34.
4. Terry DA, Snow SR, McLaren EA. Contemporary dental photography: Selection and application. *Compend Contin Educ Dent* 2008;29:432-440.
5. Coachman C, Van Dooren E, Gürel G, Calamita MA, Calgaro M, Souza Neto J. Minimally invasive reconstruction in implant therapy: The prosthetic restoration. *Quintessence Dent Technol* 2010;33:61-75.
6. Coachman C, Salama M, Garber D, Calamita M, Salama H, Cabral G. Prosthetic gingival reconstruction in a fixed partial restoration. Part 1: Introduction to artificial gingiva as an alternative therapy. *Int J Periodontics Restorative Dent* 2009;29:471-477.
7. Coachman C, Salama M, Garber D, Calamita M, Salama H, Cabral G. Prosthetic gingival reconstruction in the fixed partial restoration. Part 2: Diagnosis and treatment planning. *Int J Periodontics Restorative Dent* 2009;29:573-581.
8. Coachman C, Salama M, Garber D, Calamita M, Salama H, Cabral G. Prosthetic gingival reconstruction in the fixed partial restoration. Part 3. *Int J Periodontics Restorative Dent* 2010;30:18-29.
9. Goldstein RE. *Esthetics in Dentistry: Principles, Communication, Treatment Methods*. Ontario: Decker, 1998.
10. Chiche GJ, Pinault A. *Esthetics of Anterior Fixed Prosthodontics*. Chicago: Quintessence, 1996.
11. Magne P, Belser U. *Bonded Porcelain Restorations in the Anterior Dentition: A Biomimetic Approach*. Chicago: Quintessence, 2002.
12. Fradeani M. *Esthetic Rehabilitation in Fixed Prosthodontics, Vol 1. Esthetic Analysis: A Systematic Approach to Prosthetic Treatment*. Chicago: Quintessence, 2004.
13. Gürel G. *The Science and Art of Porcelain Laminate Veneers*. Berlin: Quintessence, 2003.
14. Rufenacht CR. *Fundamentals of Esthetics*. Chicago: Quintessence, 1990.
15. Paolucci B. Visagismo e odontologia. In: Hallawell P. *Visagismo integrado: Identidade, estilo e beleza*. São Paulo: Senac, 2009:243-250.
16. Gürel G, Bichacho N. Permanent diagnostic provisional restorations for predictable results when redesigning smiles. *Pract Proced Aesthet Dent* 2006;18:281-286.