



Clinical Cases in Prosthodontics

Leila Jahangiri, B.D.S., D.M.D., M.M.Sc.

Clinical Associate Professor and Chair
Department of Prosthodontics
New York University College of Dentistry

Marjan Moghadam, D.D.S., M.A.

Clinical Assistant Professor and Director of Pre-doctoral Fixed Prosthodontic Clinics
Department of Prosthodontics
New York University College of Dentistry

Mijin Choi, D.D.S., M.S., F.A.C.P.

Clinical Associate Professor and Course Director of Advanced Prosthodontics
Department of Prosthodontics
New York University College of Dentistry

Michael Ferguson, D.M.D., C.A.G.S.

Clinical Associate Professor and Director of Pre-doctoral Fixed Prosthodontic Clinics
Department of Prosthodontics
New York University College of Dentistry

 **WILEY-BLACKWELL**

A John Wiley & Sons, Inc., Publication

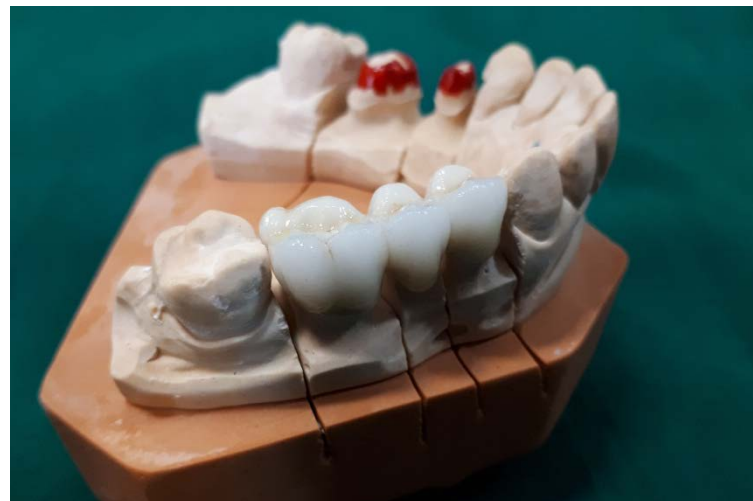
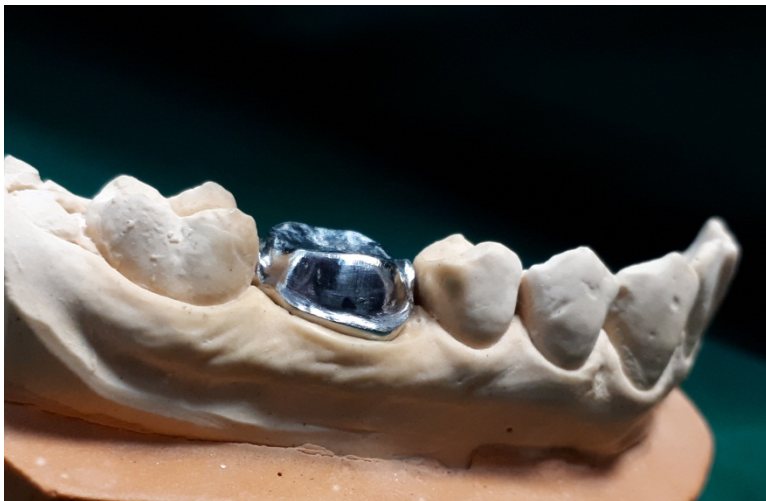
مرکز تخصصی پروتزهای دندانی هایک دنت

طراحی و ساخت انواع پروتزهای دندانی بویژه ایمپلنت
برگزار کننده دوره های آموزشی تخصصی و جامع دندانسازی و...

با ما همراه باشید...

WWW.HIGHDENTLAB.COM



Edition first published 2011
© 2011 Blackwell Publishing Ltd.

Blackwell Publishing was acquired by John Wiley & Sons in February 2007. Blackwell's publishing program has been merged with Wiley's global Scientific, Technical, and Medical business to form Wiley-Blackwell.

Editorial Office
2121 State Avenue, Ames, Iowa 50014-8300, USA

For details of our global editorial offices, for customer services, and for information about how to apply for permission to reuse the copyright material in this book, please see our Website at www.wiley.com/wiley-blackwell.

Authorization to photocopy items for internal or personal use, or the internal or personal use of specific clients, is granted by Blackwell Publishing, provided that the base fee is paid directly to the Copyright Clearance Center, 222 Rosewood Drive, Danvers, MA 01923. For those organizations that have been granted a photocopy license by CCC, a separate system of payments has been arranged. The fee code for users of the Transactional Reporting Service is ISBN-13: 978-0-8138-1664-7/2011.

Designations used by companies to distinguish their products are often claimed as trademarks. All brand names and product names used in this book are trade names, service marks, trademarks or registered trademarks of their respective owners. The publisher is not associated with any product or vendor mentioned in this book. This publication is designed to provide accurate and authoritative information in regard to the subject matter covered. It is sold on the understanding that the publisher is not engaged in rendering professional services. If professional advice or other expert assistance is required, the services of a competent professional should be sought.

DISCLAIMER

The treatments proposed or rendered in the following cases suggest a consensus among the authors and do not necessarily reflect the opinions of the New York University College of Dentistry faculty at large.

Library of Congress Cataloging-in-Publication Data

Clinical cases in prosthodontics / Leila Jahangiri . . . [et al.].

p. ; cm. — (Clinical cases)

Includes bibliographical references and index.

ISBN 978-0-8138-1664-7 (pbk. : alk. paper)

1. Prosthodontics—Case studies. I. Jahangiri, Leila. II. Series: Clinical cases (Ames, Iowa)

[DNLM: 1. Prosthodontics—methods—Case Reports. 2. Prosthodontics—methods—Problems and Exercises. 3. Oral Surgical Procedures, Preprosthetic—methods—Case Reports. 4. Oral Surgical Procedures, Preprosthetic—methods—Problems and Exercises. WU 18.2 C641 2011]

RK651.C58 2011

617.6'9—dc22

2010020440

A catalog record for this book is available from the U.S. Library of Congress.

Set in 10 on 13 pt Univers Light by Toppan Best-set Premedia Limited
Printed in Singapore

1 2011

Dedication

To all of our students who challenge us daily and enrich our lives

CONTENTS

Authors	xi
Preface.	xii
Acknowledgments	xiv
Introduction to Evidence-Based Practice (EBP)	3
Case 1	9
Treatment of an edentulous patient with conventional complete denture prostheses	
Case 2	15
Treatment of an edentulous patient with two-implant-retained mandibular overdenture	
Case 3	21
Treatment of a patient with combination syndrome	
Case 4	27
Treatment of an edentulous patient with a severely atrophic mandible	
Case 5	33
Management of florid cemento-osseous dysplasia (FCOD)	
Case 6	39
Treatment of a partially edentulous patient with implant-retained removable partial denture prosthesis	
Case 7	45
Treatment of a partially edentulous patient with fixed and removable prostheses	
Case 8	53
Management of ectodermal dysplasia I—overdenture prostheses	

Case 9	59
Management of ectodermal dysplasia II—implant-retained removable prostheses	
Case 10	65
Management of ectodermal dysplasia III—a multidisciplinary approach	
Case 11	73
Management of a fractured central incisor I—mild	
Case 12	79
Management of a fractured central incisor II—moderate	
Case 13	85
Management of a fractured central incisor III—severe	
Case 14	91
Rehabilitation of anterior teeth I—combination of complete and partial coverage restorations	
Case 15	97
Rehabilitation of anterior teeth II—partial coverage restorations	
Case 16	103
Rehabilitation of anterior teeth requiring orthodontic extrusion	
Case 17	109
Management of severe crowding—a multidisciplinary approach	
Case 18	117
Management of a patient with maxillary canine transposition	
Case 19	123
Management of a patient with loss of posterior support	
Case 20	129
Management of the consequences of partial edentulism	
Case 21	137
Management of worn dentition I—resulting from dental malocclusion	
Case 22	145
Management of worn dentition II—localized severe wear	

Case 23	153
Management of worn dentition III—generalized severe wear	
Case 24	159
Implant therapy versus endodontic therapy	
Case 25	165
Management of endodontically treated teeth	
Case 26	173
Prognostic indicators for strategic extractions in a full mouth rehabilitation	
Case 27	179
Treatment of a patient with implant-supported fixed complete denture prostheses	
Case 28	185
Full mouth rehabilitation—implant-supported prostheses I	
Case 29	191
Full mouth rehabilitation—implant-supported prostheses II	
Case 30	199
Full mouth rehabilitation—implant-supported, screw-retained prostheses	
Case 31	205
Full mouth rehabilitation—implant-supported, cementable fixed prostheses	
Case 32	211
Full mouth rehabilitation—combination of implant and tooth-supported fixed prostheses	
Case 33	217
Full mouth rehabilitation—combination of implant and tooth-supported fixed and removable prostheses	
Case 34	223
Management of a patient with bulimia	
Case 35	229
Management of oral manifestations of methamphetamine abuse	

Case 36	235
Management of cleidocranial dysplasia I—treatment of an adolescent patient	
Case 37	241
Management of cleidocranial dysplasia II—treatment of an adult patient	
Index	247

Authors

Leila Jahangiri, B.D.S., D.M.D., M.M.Sc.

Clinical Associate Professor and Chair, Department of Prosthodontics
New York University College of Dentistry

Marjan Moghadam, D.D.S., M.A.

Clinical Assistant Professor and Director of Pre-doctoral Fixed Prosthodontic Clinics
Department of Prosthodontics
New York University College of Dentistry

Mijin Choi, D.D.S., M.S., F.A.C.P.

Clinical Associate Professor and Course Director of Advanced Prosthodontics
Department of Prosthodontics
New York University College of Dentistry

Michael Ferguson, D.M.D., C.A.G.S.

Clinical Associate Professor and Director of Pre-doctoral Fixed Prosthodontic Clinics
Department of Prosthodontics
New York University College of Dentistry

Preface

Leila Jahangiri

Two seasoned clinicians are discussing a case. Upon hearing the treatment plan, one clinician says, "I would not have done it that way." The other clinician responds by explaining the path of treatment based on critical decision-making factors and justifying it with judgment and experience. The argument will get progressively stronger if it is substantiated with the best available evidence at every step in the decision-making process. Many clinicians rely on their observed evidence from years of practice. Although decisions made this way can be valid, the clinicians can augment and enhance their knowledge if they also investigate the literature to see what others have reported in similar cases. This will invariably confirm or, at times, alter what they do. For a practicing clinician, this process is described as *lifelong learning*. The combination of experience with a strong justification based on the best available evidence in the literature shifts the treatment planning process from a purely personal choice (*subjective*) to a collective profession's choice (*objective*).

The number of case-based books with an emphasis on the discipline of prosthodontics and treatment planning is in short supply. *Clinical Cases in Prosthodontics* uses cases to help students and practitioners focus on a few key elements that become the basis of the decision-making criteria. This book is a unique compilation of scenarios concentrating specifically on *objective* treatment planning. Over the past 15 years that I've been teaching prosthodontics, this has been the students' greatest challenge, one that eventually is met through extensive clinical experience but can be learned from case studies. The purpose of this book is to provide you with greater exposure to clinical cases and illustrate a pathway to decision-making for effective treatments. We define

the treatment plan as a road map, which provides a rational and justified method for determining the patient's needs and building a pathway to reestablish form, function, and aesthetics. More importantly, effective treatment planning goes beyond the immediate dental needs and addresses the patient as a whole. A complete plan must consider a patient's medical conditions, risk factors, etiology of any disease, emotions, psychological state, and motivation, as well as any financial constraints. This book is designed with a greater emphasis on the treatment planning *process* rather than on the treatment *rendered*. Ideally, at the time of treatment planning, the clinician should be able to envision the outcome and prognosis.

When the opportunity to write this book arose, our team was determined to focus solely on treatment planning with the critical decision-making process in mind. Our collective experience and our responsibilities as full-time faculty at New York University College of Dentistry have given us access to a vast number of patients presenting with a diversity of needs, leading us to incorporate case-based teaching in our core curriculum. I discussed the style of our case teaching approach with colleagues from other institutions, and they overwhelmingly encouraged me to develop these cases in the format in which they appear today. This book is not intended to be an in-depth explanation of techniques, materials, or procedural steps. You will find that the prosthodontics literature is rich with textbooks on core principles and fundamentals that are successfully being utilized in dental education. Our intention is to provide you with the *application* of such fundamental principles. *Clinical Cases in Prosthodontics* can be used by students, graduate residents, faculty, and clinicians who wish to expand their knowledge of prosthodontics

and forever strive to maintain their practices using evidence-based dentistry.

The cases presented throughout the book vary from simple to complex. There are occasions where we challenge certain traditional concepts in our decision-making criteria, strengthening our approach with new evidence or facts and substantiating our choices with appropriate literature. We encourage you to view treatment planning in a similar manner, as a dynamic, lifelong learning process that is bound to change as the scientific evidence evolves and progresses. The first chapter, "Introduction to Evidence-Based Practice (EBP)," is specifically written to help you in the inquisitive process. This is an effort to stimulate you to question and seek answers for the rest of your practicing life. Although it is expected that, over time, treatment and practice might change, it is hoped that the process of sieving through literature for guidance will remain as a core concept behind sound decision making.

A wide variety of cases are presented, which can be reviewed sequentially or randomly. Each case follows a similar pattern, beginning with a brief "story" of how the patient presents, while identifying the patient's chief complaint or issue. A selection of supporting figures and relevant charts are included to help you in the decision-making process. Carefully selected learning goals and objectives are clearly outlined, and these will assist you in examining the

specific details of the case. Pertinent data is listed, including medical/dental/social history, medications, vital signs, and other significant clinical findings that justify the diagnosis. This information is followed by critical *Clinical Decision-Making Determining Factors* used to support the recommended treatment plan. At the end of the analysis, a series of multiple-choice questions are offered to further your understanding of the goals and objectives. The questions can also be used to test your knowledge and help you develop your decision-making skills. A list of references is given to identify the supporting literature for the concepts discussed. We are not advocating that the treatments presented here are the only ways to address the issues. However, we are justifying the selected paths toward the final decisions based on the currently available scientific data.

An added benefit in reading *Clinical Cases in Prosthodontics* is that national and regional examinations in dentistry and prosthodontics, as well as board certification in prosthodontics, are, in part, based on discussions of cases similar to the ones presented in this book. Your attention to the detailed analysis and treatment planning decisions may help you prepare for these exams.

We hope that this book can set you on a path to discovery and a questioning process that expands your existing knowledge and enhances your patient care capabilities.

Acknowledgments

We wish to thank our institution, New York University College of Dentistry, for creating an enriching, patient-centered environment from which these cases have been selected. We also express our deepest gratitude to Dr. Farhad Vahidi, Associate Professor and Director of the Jonathan and Maxine Ferencz Advanced Education Program in Prosthodontics. His meticulous efforts in cataloging numerous cases have been instrumental in the development of this book. Sincere thanks go to our faculty, dental students, and residents, past and present, who have allowed us to collectively learn and further our knowledge. A special thank you goes to our colleague Silvia E. Spivakovsky, D.D.S. for her invaluable contribution to the chapter on

evidence-based practice. Most importantly, we truly appreciate the willing cooperation of our patients, who made *Clinical Cases in Prosthodontics* possible. We would like to give additional thanks to all who selflessly contributed their case photographs to the production of this book. A specific acknowledgment is given to the treating clinician at the end of each case.

On a personal note (L.J.), my sincerest appreciation goes to my team of coauthors who brought a great sense of enthusiasm and untiring energy into this project. They offered their time and expertise, and they researched, organized, and edited, making the writing process most enjoyable.

Clinical Cases in Prosthodontics

Introduction to Evidence-Based Practice (EBP)

Silvia E. Spivakovsky* and Leila Jahangiri

Practicing dentistry is about making *informed* clinical decisions in order to deliver the best possible care to patients. In practice, the choice of adopting certain treatment modalities is based on a variety of factors, including education, clinical experience, colleague recommendations, research findings, and patient suggestions.

While there are many sources of available evidence, the process of Evidence-Based Practice (EBP) is fast becoming the standard for practitioners to make informed clinical decisions. EBP is a *scientific method* of gathering systematic research findings as the evidence necessary to select the best course of treatment. The American Dental Association defines EBP as "An approach to oral health care that requires the judicious integration of systematic assessments of clinically relevant scientific evidence, relating to the patient's oral and medical condition and history, with the dentist's clinical expertise and the patient's treatment needs and preferences."¹

EBP promotes the collection and interpretation of research-derived evidence to determine or reject a treatment option. The *query and search* process uncovers relevant findings that justify a particular clinical decision and the subsequent delivery of appropriate care. In addition, the EBP process embraces and promotes lifelong learning.

It may be impractical for the busy practitioner to utilize EBP for every clinical decision; however, EBP is the most valid method for answering clinical questions, updating knowledge, and understanding the validity of new procedures.

The PROCESS of Evidence-Based Practice

Scientific evidence is continually evolving and information is readily accessible. The problem with having immediate access to an abundance of data is in managing the volume of that data. In fact, as new information augments or supplants existing data, some traditional sources can become obsolete, leaving the practitioner with the challenge of keeping up with the latest evidence, the application of which allows for the delivery of better care.

Since properly *applied knowledge* directly affects the quality of patient care, EBP is developed to help clinicians evaluate, qualify, and recognize the most *useful* evidence to apply to a given situation.

EBP is a 5-step process, commonly referred to as the FIVE A's:²

1. **ASK** an answerable clinical question
2. **ACQUIRE** the best evidence
3. **APPRAISE** the strength and relevancy of the information
4. **APPLY** the appropriate action
5. **ASSESS** the outcome

This structured approach allows the practitioner to become an effective consumer of *high-quality, relevant, and reliable* information with the purpose of improving the quality of care.

1. Ask

To find the best possible answer requires the most suitable question. A good clinical inquiry uses the most

*Silvia E. Spivakovsky, D.D.S. is a Clinical Associate Professor in the Department of Oral & Maxillofacial Pathology, Radiology & Medicine, at the New York University College of Dentistry. She is a Course Director of *Oral Medicine and Diagnosis* and *Senior Comprehensive Care*.

Clinical Cases in Prosthodontics, Leila Jahangiri, Marjan Moghadam, Mijin Choi, and Michael Ferguson, © 2011 Blackwell Publishing Ltd.

appropriate words to formulate an *answerable* question related to care. There are methods available to help a practitioner ask the “right” question. One such format used to generate a searchable question is called PICO,³ and the components of the acronym are

- P: Population, Patient, or Problem (basically the disease or affliction)
- I: Intervention (such as a drug, a test, or other procedure)
- C: Comparison (to another drug, placebo, test, procedure, etc.)
- O: Outcome (the desired effect)

The PICO format helps identify search terms. Start by combining the most significant patient issue (P in PICO) with the intervention therapy (I in PICO). If there are too many results from that search or there appears to be no answer, then add the comparison intervention (C in PICO) to the search. It is understood that some questions may not have a comparison.

The use of the PICO format forces the inquiring clinician to clarify the components of a question in order to create a path to discovering a meaningful answer and determine the desired outcome (O in PICO). To illustrate this process using EBP, the following PICO is developed for a clinical query.

THE DOWEL DILEMMA

A practitioner seeks to determine the best type of dowel and core needed to restore a tooth after endodontic therapy, with a minimal coronal tooth structure remaining. The PICO components are as follows:

- P:** Endodontically treated teeth with minimal coronal tooth structure remaining
- I:** Prefabricated dowels
- C:** Cast dowels
- O:** Longevity of the final restoration

From the PICO the searchable question is formed: “What is the best type of dowel and core needed to restore a tooth after endodontic therapy, with a minimal coronal tooth structure remaining?”

2. Acquire

To answer the dowel question, the next step is to ACQUIRE information. Potential sources of information include original research studies, systematic reviews, evidence-based journal articles, and other educational literature. The availability and ease of access to information can potentially lead to an overwhelming amount of data that will be difficult to sort.

Table 1

Clinical Question	Best Research Design in Order of Significance
Therapy	Randomized control trial (RCT) > cohort study > case-control study > case series
Diagnosis	Prospective, blind comparison to a reference standard
Etiology or Harm	Cohort study > case-control study > case series
Prognosis	Cohort study > case-control study > case series

Adapted from *Evidence-based Dentistry: Managing Information for Better Practice*.²

For example, using the popular search engine Google, the search for the phrase “best post and core in dentistry,” yields over 47,000 results. Although the entries are sequenced in some search-engine hierarchy, arranged by the number of times the phrase is found or repeated, there is no sure way of knowing which search results will lead to the discovery of useful information. Very often, the search process can be “hit and miss,” especially when the search is more general than specific.

Successful use of EBP tools and resources can make the search more effective and less time consuming. One approach is to narrow down the scope of a given question by categorizing it as a *therapy*, *diagnosis*, *etiology*, *harm*, or *prognosis*. Depending on the assigned category, the following research design options can help in the process of EBP (Table 1).

“Research design” refers to Randomized Control Trials, Cohort Studies, Case-Control Studies, Case Series, and Expert Opinions. Each study design has strengths and limitations due to biases. A *hierarchy* of available information can be developed from a search within a *specific* category (therapy, diagnosis, etiology, harm, or prognosis) to aid in prioritizing the evidence. Many efforts are in place to try to consolidate relevant information into an easy-to-use format. Examples include guidelines, recommendations, and systematic reviews. For a *therapy* question, the hierarchy may look like a pyramid (Fig. 1). The pyramid shape illustrates the magnitude of information available in each tier. The larger the tier, the more information to examine; the smaller the tier, the more relevant the data. Thus, information found in higher tiers may increase the certainty of answering the clinical question.

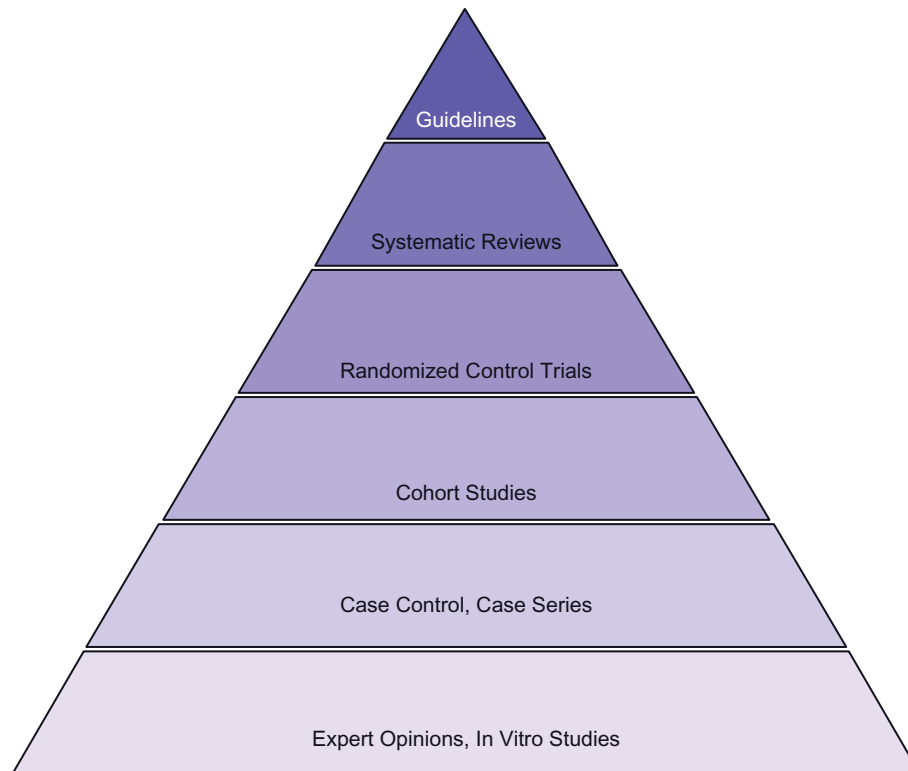


Figure 1: Evidence structure for a clinical question related to therapy.

Evidence-based clinical *guidelines* and *recommendations* appear at the apex. According to the ADA “clinical recommendations are useful tools that can be used by practitioners in conjunction with their clinical judgment and their patients’ needs and preferences to make evidence-based treatment decisions.”⁴

As of the writing of this book, there are few clinical guidelines and recommendations in dentistry and none in prosthodontics. The depicted pyramid is with the hope that clinicians, researchers, and reputable organizations contribute to the creation of systematic reviews and the development of guidelines.

In continuing with the Dowel Dilemma, a PICO was developed for the following clinical question: “What is the best type of dowel and core needed to restore a tooth after endodontic therapy, with a minimal coronal tooth structure remaining?”

Given the lack of clinical *guidelines*, a search for *systematic reviews* is the next best step because it becomes the highest available tier on the pyramid.

According to the ADA “a systematic review is a comprehensive and unbiased review process that locates, appraises, and synthesizes evidence from the scientific studies to obtain a reliable overview.”⁵

Systematic reviews are different from narrative reviews because the latter is more subjective in the appraisal and in the synthesis. A good systematic review is considered a reliable source of high-quality information. Some databases for dental systematic reviews are The Cochrane Library, the Center for Evidence-Based Dentistry in the ADA, and PubMed’s clinical queries filter. Special attention should be given to the systematic reviews from the Cochrane Collaboration since these reviews follow a very comprehensive methodology set to the highest standards. In light of this, the Cochrane Library is considered the gold standard and the recommended starting point to find the answer to a clinical question, such as the *dowel*. Keep in mind that repeated searches, beyond Cochrane, may still yield no systematic reviews. Results might be inconclusive for several reasons, the most common stemming from the lack of quality studies.

The process of finding evidence for the dowel should continue by searching for *randomized control trials* followed by *cohort studies*. If there is still a lack of evidence, the dowel search moves to a lower level in the pyramid, individual clinical studies, which may

be *case-control studies* or *case series*. As the pyramid shape illustrates, lower tiers are likely to contain more information but at a lower level of evidence.

There are many search engines available for these individual clinical studies; one of the most popular is PubMed. Searching for individual articles using basic search terms can yield thousands of results, many of which may be unrelated. To avoid this uncontrolled collection of content, it is recommended to first browse the Medical Subject Heading (MeSH) database, "the U.S. National Library of Medicine's controlled vocabulary used for indexing articles for MEDLINE/PubMed. MeSH terminology provides a consistent way to retrieve information that may use different terminology for the same concepts."⁶

Because the lower tiers on the pyramid may contain a large body of literature, the search can be narrowed and made more efficient by adding filters such as research design, date of publication, and language of publication.

To continue with the dowel question, filtered results may lead to case series and reports on various prefabricated dowels (the I in PICO), and some studies may reveal comparisons (the C) to cast dowels. These results can collectively aid in *clinical decision making*.

3. Appraise

Finding relevant information is not the end of the process; it is merely a step toward using the information to address the clinical concern. Gathered information must be appraised to impartially determine the validity and reliability of the data. Such determinations cannot be made by just reading the abstract of a journal article. Critical appraisal is the process of objectively evaluating three major aspects of a study:

1. Is the trial valid?
2. What are the results?
3. Are the results relevant to the problem?

Because of the complexity and the time needed to complete the appraisal process, several sources of preappraised literature, also known as secondary or filtered literature, are created for the practitioner. These sources include individual articles or systematic reviews that have been objectively appraised and the findings are reported in a user-friendly format, covering several pages. The evidence is also graded based on quality, quantity, consistency, and relevance.

Secondary literature can be found in the *Journal of Evidence-Based Dental Practice*, *Evidence-Based*

Dentistry journal, the critical summaries at the ADA Center for Evidence-Based Dentistry and the Centre for Evidence-Based Dentistry. For the busy practitioner these are excellent sources to consider when looking for answers.

Prior to the creation of secondary literature, the process of effective critical appraisal is done by using one of the freely available standardized tools offered in the Critical Appraisal Skills Programme (CASP), developed in the U.K. in 1993.⁷ For systematic reviews, other tools (besides CASP) include AMSTAR and the PRISMA Statement. The AMSTAR tool assesses the methodological quality of systematic reviews. The PRISMA Statement (Preferred Reporting Items for Systematic Reviews and Meta-Analyses) provides an evidence-based minimum set of items for reporting systematic reviews and meta-analyses.

Within the appraisal, a focus is placed on the validity of the evidence. Validity is the degree to which the results of the study are likely to be true, believable, and free from bias. Bias is any factor (other than the experimental factor) that could change the study results in a nonrandom way.⁸ To determine validity it is recommended to use the appropriate appraisal tool that is specific to the research design being appraised. The overall balance between strengths and weaknesses will determine the quality. Once validity is established the magnitude or significance of the results can be confirmed. It is important to point out that statistically significant results do not always mean clinically significant ones.

4. Apply

After gathering the best available evidence, the practitioner must decide whether or not to APPLY the evidence to the particular patient, based on existing circumstances. The process of collecting and refining relevant, reliable evidence allows for a strong decision in support of the treatment. Since the most up-to-date dental knowledge has a shelf life of only 10–15 years,⁹ applied knowledge in this manner leads to best practices.

5. Assess

Understanding the impact of applied evidence is critical in the assessment process. The clinician must compare changes based on originally predicted outcomes to measure the effect of suggested treatment.

For the dowel question, the outcome (the O in PICO) concerns the longevity of final restoration.

Ultimately, if the practitioner follows the patient treatment and determines through follow-up examinations whether the dowel choice was effective, a reporting of this assessment can add to the body of literature and thereby increase lifelong learning.

References

1. <http://ebd.ada.org/about.aspx>
2. Richards, D. and J. Clarkson. (2008). *Evidence-based dentistry: Managing information for better practice*.

London, Quintessence Publishing Co. Ltd.

3. Richardson, W., M. Wilson et al. (1995). The well-built clinical question: A key to evidence-based decisions. *ACP Journal Club* 123: A12–13.
4. <http://ebd.ada.org/ClinicalRecommendations.aspx>
5. <http://ebd.ada.org/SystematicReviews.aspx>
6. <http://www.ncbi.nlm.nih.gov/mesh>
7. <http://www.phru.nhs.uk/Pages/PHD/resources.htm>
8. <http://www.cebd.org/practising-ebd/appraise/>
9. Glick, M. (2006). Dental-lore-based dentistry, or where is the evidence? *J Am Dent Assoc* 137(5): 576, 578.

Case 1

Case 1

Treatment of an edentulous patient with conventional complete denture prostheses

CASE STORY

A 62-year-old completely edentulous Caucasian male presents requiring maxillary and mandibular complete dentures to restore form, function, and aesthetics. He has been edentulous in the maxilla for the past 15 years and had his mandibular anterior incisors extracted about 8 months ago. He presents with a chief complaint of: "I need new teeth (dentures)." The patient states that his present dentures are ill-fitting and they move when he eats and speaks. Intraoral examination reveals moderately inflamed oral tissues, consistent with an ill-fitting denture; however, the amount of alveolar bone present is adequate for denture support.

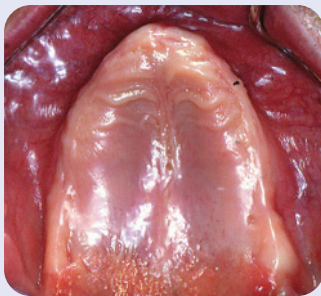


Figure 1: Preoperative maxilla.

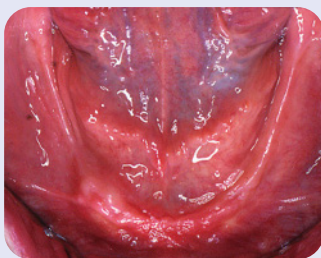

Figure 2: Preoperative mandible.

LEARNING GOALS AND OBJECTIVES

- Manage soft tissues prior to prostheses fabrication.
- Determine and reestablish proper vertical dimension of occlusion (VDO).
- Assess anterior artificial tooth arrangement.
- Recognize and treat common postinsertion sequelae.

Medical History

- Diabetes: diagnosed at the age of 17, well controlled with medication

Dental History

- Extraction of maxillary teeth 15 years ago and the remaining mandibular anterior teeth 8 months ago; patient states that all extractions were due to "gum disease."
- The patient soaks his dentures at night in water but does not brush them; however, he does rinse his mouth with mouthwash daily before reinserting the dentures.
- His diet is described as normal, but lately consisting of softer food.

Medications and Allergies

- Metformin (Glucophage) 500mg twice daily
- Multivitamin daily

Review of Systems

- Diabetes mellitus type II
- Vital signs:
 - Blood pressure: 129/78
 - Heart rate: 72 beats/minute
 - Respiratory rate: 16 breaths/minute

Social History

- Smoking: cigarettes, one pack per day since the age of 15

- Alcohol: 2–3 pints of beer daily
- Recreational drugs: denies having ever used them

Extraoral Examination

- Head: normocephalic, symmetrical, no masses or scars
- Neck: within normal limits
- Muscles: within normal limits
- Lymph nodes: within normal limits
- TMJ: no clicks, pops, or tenderness; normal range of motion; no deviation on opening or closing

Soft Tissue Examination

- Lips: moist; symmetrical; normal shape, size, and color, with mild angular cheilitis present
- Mucosa: mildly inflamed; patent Stenson's duct; no masses, scars, or lesions
- Hard palate: normal size and shape with nicotinic stomatitis present
- Soft palate: slightly erythematous, normal size and shape
- Tongue: normal size and shape; no masses, scars, or lesions; candida overgrowth present leaving erythematous palatal mucosa when rubbed off
- Saliva: appears to be of normal flow and consistency (Examination of soft tissues and salivary flow rate are important considerations when planning for and constructing a new complete denture.)
- Floor of mouth: Patent Wharton's duct; no masses, scars, or lesions. (Examination of soft tissues and salivary flow rate are important considerations when planning for and constructing a new complete denture.)
- Oral cancer screen: negative for clinical signs of oral cancer. (Examination important because of history of smoking and alcohol consumption.)

Clinical Findings/Problem List

- Complete edentulism
- Inadequate oral hygiene
- Inadequate existing complete dentures
- Poor masticatory function

Diagnosis

- Complete edentulism
- Angular cheilitis
- Candidiasis
- Nicotinic stomatitis
- Insufficient vertical dimension of occlusion (VDO)

Clinical Decision-Making Determining Factors

- Edentulism is defined as having no teeth and is usually the result of dental caries and/or periodontal disease. The remaining residual ridge can undergo remodeling and resorption often with an unpredictable pattern. This can result in the instability of the complete dentures. Adequate ridge height and width must be carefully evaluated in the fabrication of complete dentures (Slagter, Olthoff et al. 1992; Eklund and Burt 1994; Carlsson 2004).
- Denture retention and comfort are directly related to the supporting tissues of the residual ridge. Sufficient vestibular depth is crucial for a good basal seat of the denture base. An ill-fitting denture can irritate the mucosa and produce redundant soft tissue known as epulis fissuratum or ulcerations. These tissue inflammations should be resolved prior to new denture fabrication and certainly prior to the making of the final impression. This can be achieved by using tissue conditioners and corrective adjustments to the present dentures. In cases where corrective adjustments are not possible, discontinued use of dentures for 48–72 hours prior to final impressions is recommended (Lytle 1957; Klein and Lennon 1984; MacEntee 1985).
- The proper vertical dimension of occlusion should be verified both in the wax rim and artificial tooth arrangement try-in stages when fabricating complete dentures. Denture base pressure, especially if the occlusal forces are unevenly distributed or if there is excess vertical dimension of occlusion, can cause low-grade inflammation of the supporting mucosa and the underlying alveolar bone. In most cases this inflammation is reversible (Davies, Gray et al. 2001).
- Insufficient vertical dimension of occlusion can result from improper establishment of vertical dimension of occlusion during the initial denture fabrication, or as a result of teeth wear or physiological changes of alveolar bone over time. Insufficient vertical dimension can present as angular cheilitis, difficulty in mastication, drooling, and pseudo-class III occlusion (Turrell 1972).
- The position of the maxillary anterior artificial teeth is based on aesthetics and phonetics. These aesthetic parameters include lip support, amount of incisal display, axial inclination, anterior plane of occlusion, and symmetry. The phonetic parameters include but are not limited to pronunciation of fricative ("f" and "v") sounds and sibilant ("s") sounds (Pound 1977).

- At the time of initial insertion of new dentures, the dentist should focus on adequacy of basal seat adaptation, elimination of overextended denture borders, and presence and adequacy of maxillary posterior palatal seal. Once these are established, the occlusion is best checked with remount procedures (Landa 1977; Ettinger and Scandrett 1980; Shigli, Angadi et al. 2008).
- Proper daily denture hygiene, in addition to maintenance and follow-up appointments, are critical for long-term health of oral tissues. This helps to ensure quality of life for the edentulous individual. Annual follow-up should be stressed to the edentulous patient, because oral changes are an ongoing biologic process (Chamberlain, Bernier et al. 1985).

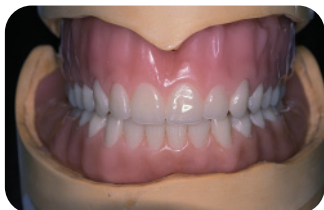

Figure 3: Completed denture tooth arrangement.

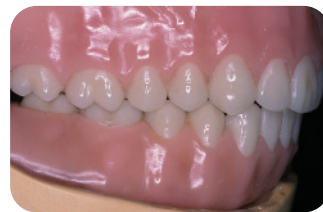

Figure 4: Completed denture tooth arrangement, right side.

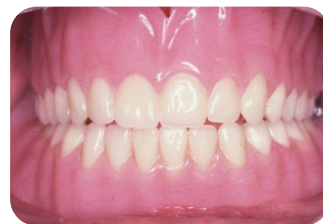

Figure 5: Complete dentures at delivery.

Questions

1. Before making the preliminary impression for complete maxillary and mandibular dentures one should

- A. Perform a thorough intraoral exam to evaluate the oral cavity and the health of the soft and hard tissues that will support the dentures
- B. Resolve any inflammation or infection present
- C. Examine the existing prostheses where applicable
- D. All are important.

2. What etiologic factors could be contributing to Mr. Smith's angular cheilitis?

- A. The presence of candida and an ill-fitting denture with loss of vertical dimension of occlusion
- B. A dry mouth
- C. Adequate oral hygiene practices
- D. An ill-fitting denture with excessive vertical dimension of occlusion

3. The major objective of complete denture impressions is to

- A. Eliminate epulis fissuratum
- B. Achieve retention, stability, and support for the denture and the soft tissues
- C. Aid in relining an existing denture
- D. Assist in tooth selection for the denture

4. Custom trays made from an adequate diagnostic cast should be

- A. Made of a rigid and dimensionally stable tray material and be border molded
- B. Cut short 8mm from the depth of vestibule captured in the diagnostic cast
- C. Constructed without a handle
- D. Made to create an overextended final cast

5. When considering the reestablishment of the proper vertical dimension of occlusion (VDO), which statement is true?

- A. VDO is the vertical length of the face as measured between 2 arbitrary points selected above and below the mouth when natural teeth or wax rims are in contact in centric.
- B. The VDO is always greater than vertical dimension of rest VDR.
- C. The VDO and the interocclusal distance are not equal to VDR.
- D. VDO is also known as freeway space.

6. When establishing occlusion in dentures,

- A. Occlusal plane can be established without the patient.
- B. Record bases and occlusal rims should be used to determine and establish the vertical dimension of occlusion.
- C. Vertical dimension of occlusion equals vertical dimension at rest.
- D. In older patients, the vertical dimension of occlusion is greater than the vertical dimension at rest.

7. The purpose of the anterior teeth try-in step during the fabrication of complete dentures includes the following assessment(s):

- A. Aesthetics, phonetics, soft tissue support
- B. Condylar inclination, vertical dimension of occlusion
- C. Centric relation
- D. Verification of vertical dimension at rest

8. When creating a bilateral balanced occlusal scheme, the following characteristics should be considered:

- A. Compensating curve
- B. Excursive jaw movements
- C. Mediotrusive and laterotrusive contacts
- D. All of the above

9. At the delivery appointment, the patient complains that the "bite doesn't feel right." You should

- A. Remove the denture and apply topical anesthetic.
- B. Use an articulating paper and adjust intraorally.
- C. Perform a lab or a clinical remount for further occlusal equilibration.
- D. None of the above

10. The patient returns after 3 weeks complaining of speech problems especially with the "s" sounds, which sound like "th." What could cause this?

- A. This is part of the normal adaptation process.
- B. Incisor teeth are set too far palatally.
- C. The teeth are too buccally placed.
- D. Insufficient vertical dimension of occlusion

ANSWERS

1. D (Devan 1952)
2. A (Young 1949)
3. B (Friedman 1957)
4. A (Collett 1965)
5. A (Moyers 1956)

6. B (Turrell 1972)
7. A (Zarb, Bolender et al. 2004)
8. D (Feldmann 1971)
9. C (Lutes, Henderson et al. 1972; Shigli, Angadi et al. 2008)
10. B (Woods 1964)

The authors would like to acknowledge and thank Dr. Mijin Choi for the clinical case photographs and treatment performed.

References

- Carlsson, G. E. (2004). "Responses of jawbone to pressure." *Gerodontology* 21(2): 65–70.
- Chamberlain, B. B., S. H. Bernier et al. (1985). "Denture plaque control and inflammation in the edentulous patient." *J Prosthet Dent* 54(1): 78–81.
- Collett, H. A. (1965). "Complete Denture Impressions." *J Prosthet Dent* 15: 603–14.
- Davies, S. J., R. M. Gray et al. (2001). "Good occlusal practice in removable prosthodontics." *Br Dent J* 191(9): 491–4, 497–502.
- Devan, M. M. (1952). "Basic principles of impression making." *J Prosthet Dent* 2: 26–35.
- Eklund, S. A. and B. A. Burt (1994). "Risk factors for total tooth loss in the United States; longitudinal analysis of national data." *J Public Health Dent* 54(1): 5–14.
- Ettinger, R. L. and F. R. Scandrett (1980). "The posterior palatal seal. A review." *Aust Dent J* 25(4): 197–200.
- Feldmann, E. E. (1971). "Tooth contacts in denture occlusion—centric occlusion only." *Dent Clin North Am* 15(4): 875–87.
- Friedman, S. (1957). "Edentulous impression procedures for maximum retention and stability." *J Prosthet Dent* 7: 14–26.
- Klein, I. E. and C. A. Lennon (1984). "A comprehensive approach to tissue conditioning for complete dentures." *J Prosthet Dent* 51(2): 147–51.
- Landa, L. S. (1977). "Practical guidelines for complete denture esthetics." *Dent Clin North Am* 21(2): 285–98.
- Lutes, M. R., D. Henderson et al. (1972). "Denture modification during adjustment phase of complete denture service." *J Prosthet Dent* 28(6): 572–9.
- Lytle, R. B. (1957). "The management of abused oral tissues in complete denture construction." *J Prosthet Dent* 7: 27–42.
- MacEntee, M. I. (1985). "The prevalence of edentulism and diseases related to dentures—a literature review." *J Oral Rehabil* 12(3): 195–207.
- Moyers, R. E. (1956). "Some physiologic considerations of centric and other jaw relations." *J Prosthet Dent* 6: 183–94.
- Pound, E. (1977). "Let /S/ be your guide." *J Prosthet Dent* 38(5): 482–9.
- Shigli, K., G. S. Angadi et al. (2008). "The effect of remount procedures on patient comfort for complete denture treatment." *J Prosthet Dent* 99(1): 66–72.
- Slagter, A. P., L. W. Olthoff et al. (1992). "Masticatory ability, denture quality, and oral conditions in edentulous subjects." *J Prosthet Dent* 68(2): 299–307.
- Turrell, A. J. (1972). "Clinical assessment of vertical dimension." *J Prosthet Dent* 28(3): 238–46.
- Woods, V. (1964). "Management of post-insertion problems." *Dent Clin North Am* 8: 735–748.
- Young, H. A. (1949). "Diagnosis of problems in complete denture prosthesis." *J Am Dent Assoc* 39(2): 185–200.
- Zarb, G. A., C. L. Bolender et al. (2004). *Prosthodontic treatment for edentulous patients: complete dentures and implant-supported prostheses*. St. Louis, Mosby.

Case 2

Case 2

Treatment of an edentulous patient with two-implant-retained mandibular overdenture

CASE STORY

A 65-year-old male patient presents to the dental office with a chief complaint of: "My lower denture is loose and I can't eat with them." He has been edentulous for over 25 years and has been wearing his current dentures for 8 years. The patient claims that he was never very comfortable with his ability to function with the dentures. He has limited himself to a soft diet and primarily relies on supplemental drinks for nutrition. His mandibular edentulous ridge exhibits severe ridge resorption and he presents with angular cheilitis bilaterally.

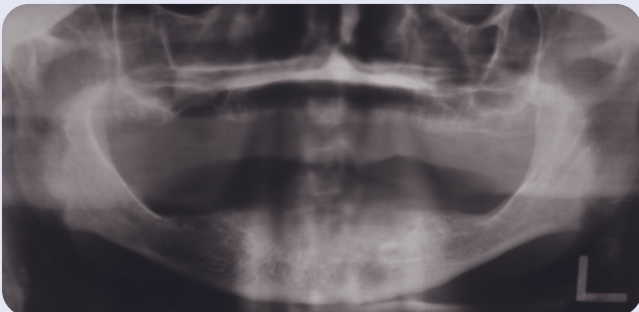


Figure 1: Preoperative panoramic radiograph.

LEARNING GOALS AND OBJECTIVES

- Understand advantages of a mandibular implant-retained complete overdenture.
- Sequence treatment.
- Understand treatment limitations related to the number of implants.
- Manage and maintain patients with implant-retained overdentures (short- and long-term).

Medical History

- Hypertension
- Hypertriglyceridemia

Dental History

- Patient's teeth have been extracted over a period of 40 years due to decay and periodontal disease.
- Patient has been completely edentulous for 25 years.
- Patient relies on denture adhesives to retain his mandibular denture.
- His current dentures are 8 years old, and he cleans the dentures every night and soaks them in water overnight.
- Patient cleans his mouth with a rinse in the evening and the morning before using his dentures.

Medications and Allergies

- Atenolol—50 mg per day
- Lipitor—20 mg per day
- No known drug allergies

Clinical Cases in Prosthodontics, Leila Jahangiri, Marjan Moghadam, Mijin Choi, and Michael Ferguson, © 2011 Blackwell Publishing Ltd.

Review of Systems

- Vital signs:
 - Blood pressure: 120/82
 - Heart rate: 70 beats/minute
 - Respiratory rate: 17 breaths/minute

Social History

- No history of smoking or drug abuse

Significant Soft Tissue Examination Findings

- Lips: appear moist, symmetrical, and normal shape, size, and color
- Angular cheilitis noted bilaterally, more pronounced on the patient's left side

Clinical Findings/Problem List

- Complete edentulism
- Inadequate existing complete dentures
- Compromised chewing function

Diagnosis

- Complete edentulism
- Residual ridge resorption that is pronounced in the mandible
- Angular cheilitis

Clinical Decision-Making Determining Factors

- Residual ridge remodeling is a chronic condition that affects different people at different rates. The amount of remaining residual ridge as well as the ridge morphology and height should be taken into consideration when planning the surgical and restorative treatment with overdentures (Jahangiri, Devlin et al. 1998).
- Adequate amount of bone for implant placement should be available. The bone height should be a minimum of 10–12 mm, and the bone width at the crest of the ridge should be at least 5–6 mm. Success of osseointegration is highly dependent on bone type. Bone type is classified as type I–IV based on the amount of cortical layer and the density of trabecular bone. The success rate of osseointegration in the anterior mandible is the highest of all sites due to the favorable type II bone. Proper diagnostic imaging should be obtained to ensure adequate bone volume as an aid in treatment planning. Adequate imaging often can be achieved with a panoramic radiograph, or it may be necessary to use computerized tomography (CT) (Misch 1999).
- Determination of appropriate vertical dimension of occlusion is critical in fabricating complete dentures.

Several methods can be used to determine the proper vertical dimension of rest and occlusion.

A prosthesis at a reduced vertical dimension may sometimes lead to the development of angular cheilitis, which is a local infection at the corners of the mouth presumably due to the pooling of saliva that occurs as a result of a loss of vertical dimension of occlusion. Restoring the vertical dimension should help alleviate this situation (Turrell 1972; Davies, Gray et al. 2001; Zarb, Bolender et al. 2004).

- Studies have shown that a patient's nutritional intake diminishes as his/her number of teeth decreases. The impact of this on the general health of the elderly patient can be devastating. Implant-retained overdenture therapy may increase comfort and compliance of use in the elderly population who are more susceptible to malnutrition (Feine and Carlsson 2003; Sheiham, Steele et al. 2001).
- Multiple studies have demonstrated that patient satisfaction is significantly higher in patients with mandibular overdentures versus conventional dentures. Given the improved quality of life and overall health that can be achieved with this treatment option, patients who are educated to the advantages would more readily accept treatment (Grogono, Lancaster et al. 1989; Boerrigter, Geertman et al. 1995; Kiyak, Beach et al. 1990).
- In consideration of the patient's chief complaint, a mandibular overdenture retained by two implants was constructed as well as a new maxillary complete denture.
- Considering the patient's chief complaint of a loose mandibular denture, the treatment option of a two-implant-retained overdenture was presented. Since the patient's existing dentures were inadequate, new dentures were fabricated. Manual examination of the mandibular residual ridges indicated an adequate width. A routine panoramic radiograph demonstrated adequate bone height for implant placement. Because the patient's medical history presented no contraindications to surgical treatment, the patient received two implants in the anterior mandible. The position of these implants was determined using the newly constructed denture to assure that the placement of the implants was within acceptable anatomical borders of the prosthesis. The implants demonstrated initial stability at the time of placement, and overdenture was activated 3 months after the initial surgical date.

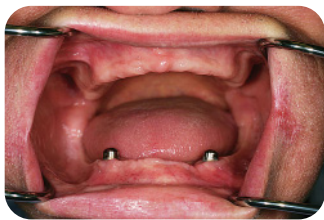


Figure 2: Postoperative presentation.

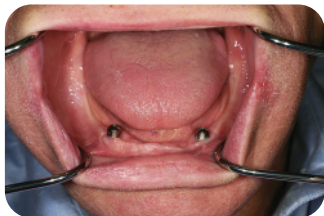

Figure 3: Postoperative presentation.

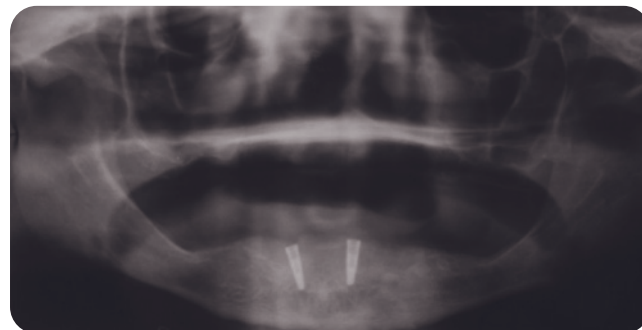


Figure 4: Postoperative panoramic radiograph.

Questions

1. It has been shown that the rate of residual ridge resorption in the mandible is ____ as compared to the maxilla.

- A. 2 times greater
- B. 4 times greater
- C. 8 times greater
- D. 1/2 as much
- E. 1/4 as much

2. Which of the following are advantages of a mandibular implant overdenture as compared to a mandibular conventional denture?

- A. Improved retention
- B. Improved masticatory function
- C. Improved quality of life
- D. Improved chewing efficiency
- E. All of the above

3. You will be constructing a new maxillary complete denture and a new mandibular overdenture for an edentulous patient. Why is the denture construction recommended prior to surgical implant placement?

- A. The denture can be used as a guide for location of the implants.
- B. Improved fit
- C. Improved occlusion
- D. Establishment of vertical dimension of occlusion
- E. All of the above

4. When comparing edentulous patients who have received an implant-supported prosthesis versus conventional dentures, the following finding(s) were reported in the implant groups:

- A. Improved ability to chew soft foods
- B. Improved ability to chew hard and soft foods
- C. Improved habit in eating foods such as carrots and apples
- D. All of the above

5. Patient attitudes toward implant treatment are often vague due to lack of knowledge about the advantages of overdentures. Studies have shown that patient satisfaction after therapy is significantly higher in patients who receive mandibular overdentures versus conventional dentures. The main reason for the increased satisfaction is improved

- A. Oral function
- B. Aesthetics
- C. Adaptation of the denture to the edentulous ridge
- D. Proprioception

6. Several attachment systems exist for mandibular overdentures. Typically, two implants are placed in the mandibular anterior region, and either a bar is used to connect the two implants or the implants remain separate. What is the difference in patient satisfaction of the overdenture between the different attachment types?

- A. There is no significant difference between the two retention mechanisms.
- B. The bar-supported overdenture is more stable.
- C. The individual implant-supported overdenture is more stable.
- D. The bar-supported overdenture requires more maintenance in the long term.

7. Implant placement in the anterior mandible has been shown to have the highest rate of success as compared to other areas in the mouth. There is concern however, that the rate of success may be different in the elderly population. Studies with regard to this issue have shown

- A. Implants placed for the elderly population have similar rates of success as compared to implants placed in younger patients.
- B. The rate of success is significantly higher in the younger population.
- C. The rate of success is significantly lower in the younger population.
- D. The studies have been inconclusive.

8. Which of the following will result in improved overall mandibular overdenture stability?

- A. The placement of two implants in the canine area
- B. Use of a surgical template
- C. No recall appointments are needed because no ridge resorption should result after implant placement.
- D. Immediate loading of the implants should be done to ensure proper adaptation of the denture to the ridge.

9. Angular cheilitis is often associated with candida albicans. The appearance of angular cheilitis most often results from

- A. Poor oral hygiene
- B. Ill-fitting dentures
- C. Decreased vertical dimension of occlusion
- D. Compromised medical condition

10. Maintaining good oral hygiene is imperative for the long-term success of implant therapy. Older patients typically have a more difficult time with maintenance of proper oral hygiene. It is recommended to check oral hygiene, plaque accumulation, and radiographic bone levels at each recall visit. Which of the following can result from the lack of proper plaque elimination from the implant-abutment surface?

- A. Periimplantitis
- B. Periodontitis
- C. Pericoronitis
- D. Gingivitis

ANSWERS

1. B (Tallgren 1972)
2. E (Feine and Carlsson 2003)
3. A (Feine and Carlsson 2003)
4. B (Allen and McMillan 2002)
5. A (Awad, Lund et al. 2003)

6. A (Naert, Gizani et al. 1999; Oetterli, Kiener et al. 2001)
7. A (Jemt 1993)
8. A (Feine and Carlsson 2003)
9. C (Turrell 1972; Zarb, Bolender et al. 2004)
10. A (Misch 1999)

The authors would like to acknowledge and thank Group Practices at New York University College of Dentistry for clinical case photographs and treatment performed.

References

- Allen, F. and A. McMillan (2002). "Food selection and perceptions of chewing ability following provision of implant and conventional prostheses in complete denture wearers." *Clin Oral Implants Res* 13(3): 320–6.
- Awad, M. A., J. P. Lund et al. (2003). "Oral health status and treatment satisfaction with mandibular implant overdentures and conventional dentures: a randomized clinical trial in a senior population." *Int J Prosthodont* 16(4): 390–6.
- Boerrigter, E. M., M. E. Geertman et al. (1995). "Patient satisfaction with implant-retained mandibular overdentures. A comparison with new complete dentures not retained by implants—a multicentre randomized clinical trial." *Br J Oral Maxillofac Surg* 33(5): 282–8.
- Davies, S. J., R. M. Gray et al. (2001). "Good occlusal practice in removable prosthodontics." *Br Dent J* 191(9): 491–4, 497–502.
- Feine, J. S. and G. E. Carlsson (2003). *Implant overdentures : the standard of care for edentulous patients*. Chicago, Quintessence Pub. Co.
- Grogono, A. L., D. M. Lancaster et al. (1989). "Dental implants: a survey of patients' attitudes." *J Prosthet Dent* 62(5): 573–6.
- Jahangiri, L., H. Devlin et al. (1998). "Current perspectives in residual ridge remodeling and its clinical implications: a review." *J Prosthet Dent* 80(2): 224–37.
- Jemt, T. (1993). "Implant treatment in elderly patients." *Int J Prosthodont* 6(5): 456–61.
- Kiyak, H. A., B. H. Beach et al. (1990). "Psychological impact of osseointegrated dental implants." *Int J Oral Maxillofac Implants* 5(1): 61–9.
- Misch, C. E. (1999). *Contemporary implant dentistry*. St. Louis, Mosby.
- Naert, I., S. Gizani et al. (1999). "A 5-year prospective randomized clinical trial on the influence of splinted and unsplinted oral implants retaining a mandibular overdenture: prosthetic aspects and patient satisfaction." *J Oral Rehabil* 26(3): 195–202.
- Oetterli, M., P. Kiener et al. (2001). "A longitudinal study on mandibular implants supporting an overdenture: the influence of retention mechanism and anatomic-prosthetic variables on periimplant parameters." *Int J Prosthodont* 14(6): 536–42.
- Sheiham, A., J. G. Steele et al. (2001). "The relationship among dental status, nutrient intake, and nutritional status in older people." *J Dent Res* 80(2): 408–13.
- Tallgren, A. (1972). "The continuing reduction of the residual alveolar ridges in complete denture wearers: a mixed-longitudinal study covering 25 years." *J Prosthet Dent* 27(2): 120–32.
- Turrell, A. J. (1972). "Clinical assessment of vertical dimension." *J Prosthet Dent* 28(3): 238–46.
- Zarb, G. A., C. L. Bolender et al. (2004). *Prosthodontic treatment for edentulous patients: complete dentures and implant-supported prostheses*. St. Louis, Mosby.

Case 3

Case 3

Treatment of a patient with combination syndrome

CASE STORY

A 58-year-old African American male presents with maxillary complete edentulism and mandibular partial edentulism, with remaining mandibular anterior teeth. His chief complaint is: "I need teeth to look better and to be able to chew my food." The patient had an ill-fitting denture that is now lost. The patient has existing crowns on mandibular right and left canines and right first premolar (22, 27, 28), which were placed simultaneously with the removable partial denture approximately 6 years ago. The abutment teeth are now failing due to recurrent decay. He now presents with bone loss accompanied with excessive and hyperplastic (flabby) tissues in the maxillary anterior region. These tissues are especially sore as his mandibular teeth occlude and traumatize the area.

The patient requires soft tissue treatment in the maxilla as well as a new complete denture. He also requires new prosthetic reconstruction in the mandible, which includes survey crowns and a new removable partial denture, to restore form, function, and aesthetics.

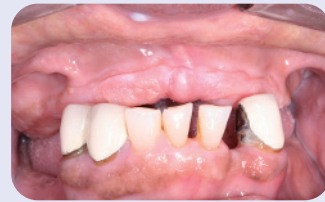

Figure 1: Preoperative presentation.

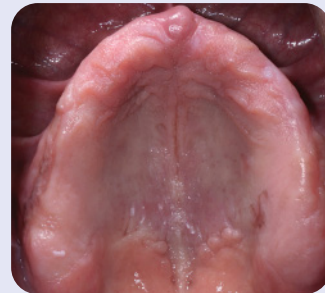

Figure 2: Preoperative maxilla.

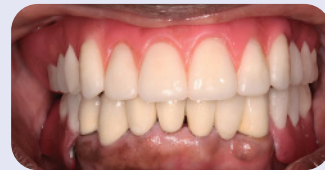

Figure 3: Final artificial tooth arrangement and try-in.

LEARNING GOALS AND OBJECTIVES

- Diagnose and manage combination syndrome.
- Select proper impression techniques.
- Establish an appropriate occlusal scheme.
- Manage and maintain patients with partial edentulism.

Medical History

- Physical exam 3 years ago: diagnosed with elevated blood pressure
- Patient reports he has not taken his blood pressure medication for about 1 year.

Dental History

- Multiple extractions due to caries, periodontal disease, and failed endodontic treatment
- Loss of maxillary complete denture 4 months ago; patient reports that he wore the denture only a few hours per day because it was loose and uncomfortable.
- Patient received regular dental care prior to retirement about 20 years ago; since then, patient has received only sporadic care with inadequate maintenance/follow-up visits.
- Last dental visit approximately 6 years ago when crowns in the mandible were delivered, but due to financial constraints, patient was unable to finish the planned dental work

Medications and Allergies

- Norvasc 10mg/daily—patient has not taken this medication in over a year
- No known drug allergies

Review of Systems

- History of elevated blood pressure, which is controlled by diet and exercise only, since the patient has discontinued his medication
- Vital signs:
 - Blood pressure: 140/90
 - Heart rate: 68 beats/minute
 - Respiratory rate: 18 breaths/minute

Social History

- Presently receives a modest retirement check from the U.S. Army and has basic medical and dental benefits

- Divorced and lives with a friend
- Smoking: 1 pack per day for the last 44 years
- Alcohol: 1 case of beer per week
- Recreational drugs: denies ever using

Significant Soft Tissue Examination Findings

- Lips: appear dry
- Mucosa: epulis fissuratum present in anterior maxilla
- Hard palate: Nicotinic stomatitis

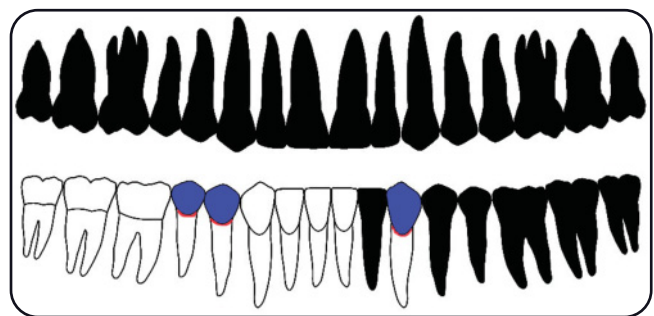
Charting

Figure 4: Dental charting.

Clinical Findings/Problem List

- Edentulous maxillary arch with no prosthesis
- Partially edentulous mandibular arch
- Recurrent decay on teeth with existing crowns
- Inadequate oral hygiene
- Poor masticatory function
- Poorly controlled high blood pressure
- Heavy smoker
- Moderate alcohol consumption

Diagnosis

- Combination Syndrome
- Epulis fissuratum
- Nicotinic stomatitis
- Improper vertical dimension of occlusion
- Generalized moderate chronic periodontitis
- Caries

Clinical Decision-Making Determining Factors

- Combination Syndrome is a series of five findings described by Kelly in 1972 in patients wearing a complete maxillary denture opposing a mandibular distal extension prosthesis. Typically, the patient

presents with mandibular anterior teeth. The syndrome typically presents with the following characteristics:

1. Advanced bone loss in the pre-maxilla with hyperplastic tissues
 2. Supraeruption of mandibular anterior teeth
 3. Bone loss in the posterior mandible
 4. Presence of papillary hyperplasia and candida infection in the maxilla
 5. Downgrowth of the maxillary tuberosities
- There is little evidence for the cause of the overgrowth of the tuberosities (Kelly 1972; Saunders, Gillis et al. 1979; Schmitt 1985).
 - The residual ridge is subjected to unpredictable resorption patterns and remodeling of the alveolar bone when teeth are lost. Ridge height and width must be carefully evaluated to establish adequate stability, retention, and occlusal plane when fabricating complete and partial dentures (Carlsson 2004).
 - Classic findings in patients with Combination Syndrome can include: hyperplastic (flabby) tissues in the pre-maxilla, fibrous overgrowth of tissues, and enlargement of the maxillary tuberosities as well as increased resorption in the mandibular distal extension area. Complete and partial denture retention and comfort are directly related to the supporting tissues of the residual ridges. Sufficient vestibular depth is crucial for a good basal seat of the denture. An ill-fitting denture can irritate the mucosa, cause ulcerations, and—long-term—produce hyperplastic tissues resulting in epulis

fissuratum (Lytle 1957; Klein and Lennon 1984; MacEntee 1985).

- Decreased vertical dimension of occlusion is often observed in patients who have Combination Syndrome.
- Successful treatment is determined by the patient's ability to wear and adapt to the prostheses. Predictable prognosis is offered by construction of new, properly fitting prostheses after tissues have been treated for inflammation, and the occlusion is corrected by eliminating anterior contacts. Elimination of inflammation can be achieved by correction of the plane of occlusion, cleaning of existing prostheses, and use of tissue conditioners (Davies, Gray et al. 2001).
- Elimination of candidiasis and papillary hyperplasia may require removal of the existing prostheses for 2–3 days with simultaneous or subsequent use of antifungal lozenges intraorally and methods to treat the existing prostheses. The prostheses can be treated with Nystatin cream or bleach or can be immersed in water and microwaved. This phase of treatment may require several visits, and fabrication of the definitive restorations should be postponed until resolution of the inflammation is achieved (Ettinger 1975).
- Consideration of the patient's overall health as well as oral health should be part of the ongoing recall/reevaluation process. Regular oral cancer screening, examination of soft tissues, and salivary flow rate are especially important in patients with a history of tobacco and alcohol use (Chamberlain, Bernier et al. 1985; Slagter, Olthoff et al. 1992).

Questions

1. Which statement describes a typical occurrence in Combination Syndrome?

- A. Two completely edentulous opposing ridges
- B. Loss of anterior teeth
- C. Progressive anterior maxillary bone loss can be seen in cases of complete maxillary denture opposed by the distal extension RPD.
- D. Edentulous mandible opposing a partially edentulous maxilla with retained maxillary anterior teeth

2. A hyperplastic ridge in the maxillary anterior region can be a result of

- A. Excessive loading of the posterior edentulous ridge
- B. Rapid alveolar bone loss in the mandible
- C. An edentulous ridge that is opposed by natural teeth
- D. Aging in patients over the age of 40

3. When trying to establish a proper plane of occlusion, which should be sequenced first?

- A. Relating the maxillary occlusal plane to the condylar axis (facebow transfer)
- B. Selection of artificial teeth
- C. Recording of maxillomandibular relationship
- D. Establishment of a centric record

4. Which of the following statements regarding intracoronal attachments is *false*?

- A. Provide greater aesthetics
- B. Direct forces along the long axis of the abutment teeth
- C. Require greater tooth preparation
- D. Are ideal in distal extension cases

5. Currently, the best method for treatment of hyperplastic tissues in the maxillary anterior region is

- A. Tissue conditioning to eliminate inflammation
- B. Tissue massage
- C. Surgical removal
- D. All of the above
- E. A and B only

6. Which technique can be used for impressions of hyperplastic tissues?

- A. Altered cast
- B. Open tray
- C. Closed mouth
- D. Functional impression

7. Maxillary anterior teeth in a complete denture are usually arranged based on aesthetics and phonetics. Their position is typically

- A. Exactly over the ridge
- B. Lingual to the ridge
- C. 3mm above the ridge
- D. Facial to the ridge

8. When fabricating a maxillary complete denture against a mandibular removable partial denture with bilateral distal extension, the selected type of occlusal scheme should be

- A. Canine-guided
- B. Bilateral balanced
- C. Unilateral balanced
- D. Cross articulation

9. When the mandible is in its physiologic rest or postural position, the contact of teeth should be

- A. Slight
- B. Maximum
- C. Not present
- D. Premature

10. All statements regarding oral hygiene are true *except*

- A. When removed from the oral cavity, prostheses should be kept submerged in water to avoid distortion of the acrylic.
- B. Removable prostheses should be removed while sleeping.
- C. One should use a toothbrush to remove plaque from prostheses.
- D. Prostheses should be worn 24 hours a day.

ANSWERS

1. C (Kelly 1972; Palmqvist, Carlsson et al. 2003)
2. C (Saunders, Gillis et al. 1979; Schmitt 1985; Barber, Scott et al. 1990)
3. A (Langer, Laufer et al. 1995)
4. D (Owall and Jonsson 1998)
5. A (Klein and Lennon 1984)

6. B (Khan, Jagers et al. 1981)
7. D (Budtz-Jorgensen, Bochet et al. 2000)
8. B (Jameson 2003)
9. C (Davies, Gray et al. 2001)
10. D (Chamberlain, Bernier et al. 1985)

The authors would like to acknowledge and thank Dr. Bhavani Venkatachalam for the clinical case photographs and treatment performed at New York University, College of Dentistry.

References

- Barber, H. D., R. F. Scott et al. (1990). "Evaluation of anterior maxillary alveolar ridge resorption when opposed by the transmandibular implant." *J Oral Maxillofac Surg* 48(12): 1283–7.
- Budtz-Jorgensen, E., G. Bochet et al. (2000). "Aesthetic considerations for the treatment of partially edentulous patients with removable dentures." *Pract Periodontics Aesthet Dent* 12(8): 765–72; quiz 774.
- Carlsson, G. E. (2004). "Responses of jawbone to pressure." *Gerodontology* 21(2): 65–70.
- Chamberlain, B. B., S. H. Bernier et al. (1985). "Denture plaque control and inflammation in the edentulous patient." *J Prosthet Dent* 54(1): 78–81.
- Davies, S. J., R. M. Gray et al. (2001). "Good occlusal practice in removable prosthodontics." *Br Dent J* 191(9): 491–4, 497–502.
- Ettinger, R. L. (1975). "The etiology of inflammatory papillary hyperplasia." *J Prosthet Dent* 34: 254.
- Jameson, W. S. (2003). "Various clinical situations and their influence on linear occlusion in treating combination syndrome: a discussion of treatment options." *Gen Dent* 51(5): 443–7.
- Kelly, E. (1972). "Changes caused by a mandibular removable partial denture opposing a maxillary complete denture." *J Prosthet Dent* 27(2): 140–50.
- Khan, Z., J. H. Jagers et al. (1981). "Impressions of unsupported movable tissues." *J Am Dent Assoc* 103(4): 590–2.
- Klein, I. E. and C. A. Lennon (1984). "A comprehensive approach to tissue conditioning for complete dentures." *J Prosthet Dent* 51(2): 147–51.
- Langer, Y., B. Z. Laufer et al. (1995). "Modalities of treatment for the combination syndrome." *J Prosthodont* 4(2): 76–81.
- Lytle, R. B. (1957). "The management of abused oral tissues in complete denture construction." *J Prosthet Dent* 7: 27–42.
- MacEntee, M. I. (1985). "The prevalence of edentulism and diseases related to dentures—a literature review." *J Oral Rehabil* 12(3): 195–207.
- Owall, B. and L. Jonsson (1998). "Precision attachment-retained removable partial dentures. Part 3. General practitioner results up to 2 years." *Int J Prosthodont* 11(6): 574–9.
- Palmqvist, S., G. E. Carlsson et al. (2003). "The combination syndrome: a literature review." *J Prosthet Dent* 90(3): 270–5.
- Saunders, T. R., R. E. Gillis, Jr. et al. (1979). "The maxillary complete denture opposing the mandibular bilateral distal-extension partial denture: treatment considerations." *J Prosthet Dent* 41(2): 124–8.
- Schmitt, S. M. (1985). "Combination syndrome: a treatment approach." *J Prosthet Dent* 54(5): 664–71.
- Slagter, A. P., L. W. Olthoff et al. (1992). "Masticatory ability, denture quality, and oral conditions in edentulous subjects." *J Prosthet Dent* 68(2): 299–307.

Case 4

Case 4

Treatment of an edentulous patient with a severely atrophic mandible

CASE STORY

A 79-year-old male patient presents with the chief complaint of: "I want new dentures. My lower denture is very loose and I can't eat properly." The patient's maxillary and mandibular teeth were extracted when the patient was in his 20's and 30's because he was unable to afford replacement restorations. He became completely edentulous by the age of 36.

He presents with a severely resorbed mandible requesting a more stable mandibular denture. The patient inquired about the possibility of implant placement and fabrication of a mandibular overdenture because several of his friends had been satisfied with this treatment option for themselves.

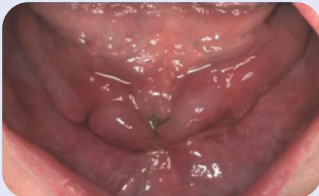

Figure 1: Pretreatment mandible, occlusal view.

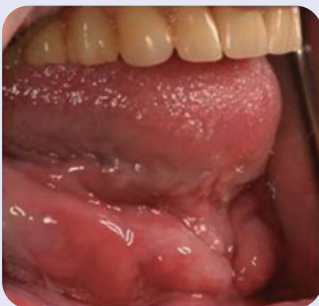

Figure 2: Pretreatment mandible, lateral view.

LEARNING GOALS AND OBJECTIVES

- Classification of complete edentulism
- Management of the severely resorbed mandible
- Management of the retracted tongue position

Medical History

- Hypertension—controlled with medication

Dental History

- Multiple extractions of carious teeth

Medications and Allergies

- Atenolol for control of hypertension
- Allergic to penicillin

Review of Systems

- Vital signs:
 - Blood pressure: 126/82
 - Heart rate: 76 beats/minute
 - Respiration rate: 17 breaths/minute

Social History

- No significant social findings

Significant Soft Tissue Examination Findings

- Soft tissues appear within normal limits with the exception of the mandible where there is a presence of redundant tissue and epulis fissuratum/inflammatory fibrous hyperplasia (overgrowth of fibrous connective tissue).

Significant Clinical Findings/Problem List

- Overgrowth of fibrous connective tissue in the mandible
- Severely resorbed mandibular residual ridge

Radiographs

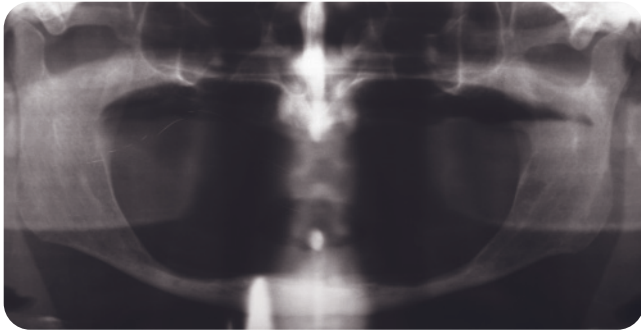


Figure 3: Panoramic radiograph.

Diagnosis

- Complete edentulism
- Severely resorbed mandibular residual ridge

Clinical Decision-Making Determining Factors

- The American College of Prosthodontists (ACP) classification system for the completely edentulous patient has been developed in order to help with diagnosis and proper treatment planning for the edentulous patient. The classification criteria include (but are not limited to) the following: anatomy, interarch space, and oral manifestation of system disease. The current patient is considered an ACP classification IV patient due to the following findings in the mandibular arch:
 - Less than 10mm of mandibular bone height
 - Attached mucosa only in the posterior mandible
 - Hyperactive tongue anatomy, with retracted position
- Given the severity of this patient's condition, careful consideration should be given to treatment planning. The patient's current amount of bone height will not allow for safe and predictable placement of the traditional (endosseous) two implants for support of a new complete denture because there is a great risk for mandibular fracture. In certain clinical situations, such as the one presented here where the patient is severely lacking in bone for placement of two implants, a single implant can be used instead. This single implant may be placed in the midline where there may be sufficient bone. Although at this time, we do not have extensive evidence evaluating the outcome of this approach, in cases where there are no alternative treatment plans available, a single implant-retained overdenture may

help to improve function and quality of life for the patient. A recent study by Walton and Glick demonstrated that with regard to patient satisfaction of treatment with one versus two implant overdentures, there was no difference between the two groups (McGarry, Nimmo et al. 1999; Wolfart, Braasch et al. 2008; Alsabeeha, Payne et al. 2009; Walton, Glick et al. 2009).

- The position and activity of the tongue can have a great effect on the stability and retention of a mandibular complete denture. Some have described the ideal position of the tongue as one in which the tip of the tongue just touches the lingual surfaces of the anterior teeth and that the lateral borders touch the posterior teeth (Wright 1966). However, if the patient exhibits a retracted tongue position, the stability provided by the ideal tongue position is lost. Obtaining the proper border seal on the mandibular denture is not truly possible when the patient has a retracted tongue position (Shanahan 1962). With training and proper patient education, even the use of phonetics can help the patient find the correct tongue position and reestablish a more stable denture position (Bohnenkamp and Garcia 2007).
- According to Wright, the retracted tongue position (also known as the retruded tongue position or the awkward tongue position) is characterized by the following:
 - The tongue appears to be pulled to the back of the mouth.
 - The floor of the mouth is easily visible.
 - The lateral borders of the tongue are located inside or posterior to the residual alveolar ridge.
 - The tip of the tongue may be pulled to the back of the mouth or withdrawn into the body of the tongue.
- Typically the retracted tongue position does not pose a problem to the patient or the dentist unless the patient becomes edentulous and requires a mandibular complete denture. Exercises and repositioning guides have been developed to help aid the patient with a retracted tongue to place his/her tongue in the proper position (Shanahan 1962; Wright 1966; Herring and Akerly 1981).
- A retracted tongue can compromise the stability of a mandibular complete denture by disrupting the peripheral seal needed for retention and stability in a conventional denture. When the tongue is retracted into the posterior portion of the mouth, the anterior floor of the mouth is exposed. It also causes an alteration to the shape of the lingual sulcus, which in

turn disrupts the peripheral seal of the denture. The retracted tongue position may not be as significant an issue for patients with implant-retained overdentures. For the patient presented here, the retracted tongue position poses a great deal of frustration for the patient and the dentist. This patient presents with severely atrophic mandibular ridge in conjunction with the retracted tongue position making his treatment even more challenging (Jacobson and Krol 1983; Lang 1994; Lee, Chen et al. 2009).

- In a recent study, Lee et al. trained patients with a retracted tongue position to hold their tongue in the ideal position. This test was done for patients with normal and with severely resorbed ridges. The finding was that there was a clinically significant improvement in denture stability after the patients were trained to hold their tongues in the more ideal position. Patient education in nonideal treatment situations can be a great aid to success of treatment outcomes (Lee, Chen et al. 2009).
- Residual ridge resorption is a chronic and irreversible process that occurs after loss of teeth. It has been described as a "continuous size reduction of the residual ridge, largely due to bone loss after tooth

extraction." The rate of resorption is generally unpredictable. The pattern of resorption in the maxilla is different from that of the mandible (see question 9 below) (Atwood 1962; Tallgren 1972; Jahangiri, Devlin et al. 1998).

- Typically, a severely resorbed residual ridge can be managed with extension of the flanges of the denture for more stability and retention. If the ridge is extremely resorbed, surgical procedures may be considered to gain better stability and retention. Vestibuloplasty may create more ideal vestibules for denture extension. Bone grafts may be considered for enhancement of the residual ridge. Implants may also be used as aids in increasing retention. Options for patients with severely resorbed ridges requiring implants include short endosseous implants or transosseous/transmandibular implants. In cases where the resorption process has resulted in no remaining residual ridge, even these procedures may not help. The patient should be educated about the limitations of these procedures and a decision should be made together with the treating dentist as to what the best course of action may be (Curtis and Ware 1977; Jennings 1989; Stellingsma, Vissink et al. 2004; Stellingsma, Raghoobar et al. 2004).

Questions

1. The ACP classification of the edentulous patient is based on only one diagnostic criterion. The anatomy of the tongue is not considered in the classification system.

- The first statement is true and the second statement is false.
- The first statement is false and the second statement is true.
- Both statements are true.
- Both statements are false.

2. When considering the muscle attachments in the mandibular arch for classification purposes, which of the following clinical situations would result in a class III edentulous patient?

- Adequate attached mucosa
- No attached mucosa on buccal of anterior segment
- No anterior buccal and lingual vestibule (canine-to-canine area)
- No attached mucosa in anterior or posterior areas

3. Which of the following muscles *does not* form the floor of the mouth?

- A. Mylohyoid
- B. Genioglossus
- C. Geniohyoid
- D. Digastric
- E. Platysma

4. What is considered to be a major factor in residual ridge resorption?

- A. Occlusal forces
- B. Bone density
- C. Medical history positive for osteoporosis
- D. Ill-fitting prosthesis

5. How can residual ridge resorption be minimized when fabricating complete dentures?

- A. Use of denture adhesive to ensure proper retention of denture
- B. Soaking dentures in hot water prior to use
- C. Appropriate adjustment of denture occlusion postinsertion
- D. Always using bilateral balanced occlusal scheme

6. Residual ridge resorption in a completely edentulous patient can be described as a process that is

- A. Inflammatory in nature
- B. Chronic
- C. Short-term
- D. Painful

7. Transosseous/transmandibular implants are placed

- A. Intraorally under local anesthesia
- B. Extraorally under local anesthesia
- C. Intraorally under general anesthesia
- D. Extraorally under general anesthesia

8. What other advantage is there in utilizing a single implant rather than two implants to retain a complete overdenture?

- A. Less time in treatment
- B. Less cost of treatment
- C. Easier postsurgical recovery for the patient
- D. Fewer prosthetic complications

9. How does the resorption pattern differ in the maxilla versus the mandible?

- A. The bone in the mandible resorbs four times more than the maxilla.
- B. The bone in the mandible resorbs eight times more than the maxilla.
- C. The mandible resorbs from the buccal to the lingual, and the maxilla resorbs from the palatal to the buccal.
- D. There is no difference in the resorption pattern of the maxilla and the mandible.

10. Phonetics can be used to help patients learn how their conscious behavior can help with the stability and retention of a complete denture. What sound should the patient make to help coordinate the position of the tongue and buccinators?

- A. The "f" sound
- B. The "ah" sound
- C. The "e" sound
- D. The "v" sound

ANSWERS

1. D (McGarry, Nimmo et al. 1999)
2. C (McGarry, Nimmo et al. 1999)
3. E (Clemente 2007)
4. A (Klemetti 1996)
5. C (Kelsey 1971)
6. B (Jahangiri, Devlin et al. 1998)

7. D (Stellingsma, Vissink et al. 2004)
8. B (Wolfart, Braasch et al. 2008; Alsabeeha, Payne et al. 2009; Walton, Glick et al. 2009)
9. A (Tallgren 1972)
10. C (Bohnenkamp and Garcia 2007)

The authors would like to acknowledge and thank Dr. Robert Berg for clinical case photographs and treatment performed.

References

- Alsabeeha, N., A. G. Payne et al. (2009). "Mandibular single-implant overdentures: a review with surgical and prosthodontic perspectives of a novel approach." *Clin Oral Implants Res* 20(4): 356–365.
- Atwood, D. A. (1962). "Some clinical factors related to rate of resorption of residual ridges." *Journal of Prosthetic Dentistry* 12(12): 441–451.
- Bohnenkamp, D. M. and L. T. Garcia (2007). "Phonetics and tongue position to improve mandibular denture retention: a clinical report." *J Prosthet Dent* 98(5): 344–347.
- Clemente, C. D. (2007). *Anatomy : a regional atlas of the human body*. Philadelphia, Lippincott Williams & Wilkins.
- Curtis, T. A. and W. H. Ware (1977). "Autogenous bone graft procedures for atrophic edentulous mandibles." *J Prosthet Dent* 38(4): 366–379.
- Herring, H. W., Jr. and W. B. Akerly (1981). "Aid to correct tongue position in the mandibular complete denture." *J Prosthet Dent* 46(6): 676–677.
- Jacobson, T. E. and A. J. Krol (1983). "A contemporary review of the factors involved in complete denture retention, stability, and support. Part I: retention." *J Prosthet Dent* 49(1): 5–15.
- Jahangiri, L., H. Devlin et al. (1998). "Current perspectives in residual ridge remodeling and its clinical implications: a review." *J Prosthet Dent* 80(2): 224–237.
- Jennings, D. E. (1989). "Treatment of the mandibular compromised ridge: a literature review." *J Prosthet Dent* 61(5): 575–579.
- Kelsey, C. C. (1971). "Alveolar bone resorption under complete dentures." *J Prosthet Dent* 25(3): 152–161.
- Klemetti, E. (1996). "A review of residual ridge resorption and bone density." *J Prosthet Dent* 75(5): 512–514.
- Lang, B. R. (1994). "A review of traditional therapies in complete dentures." *J Prosthet Dent* 72(5): 538–542.
- Lee, J. H., J. H. Chen et al. (2009). "Improved denture retention in patients with retracted tongues." *Journal of the American Dental Association* 140(8): 987–991.
- McGarry, T. J., A. Nimmo et al. (1999). "Classification system for complete edentulism. The American College of Prosthodontics." *J Prosthodont* 8(1): 27–39.
- Shanahan, J. R. (1962). "Stabilizing lower dentures on unfavorable ridges." *Journal of Prosthetic Dentistry* 12(3): 420–424.
- Stellingsma, C., A. Vissink et al. (2004). "Implantology and the severely resorbed edentulous mandible." *Crit Rev Oral Biol Med* 15(4): 240–248.
- Stellingsma, K., G. M. Raghoobar et al. (2004). "The extremely resorbed mandible: a comparative prospective study of 2-year results with 3 treatment strategies." *Int J Oral Maxillofac Implants* 19(4): 563–577.
- Tallgren, A. (1972). "The continuing reduction of the residual alveolar ridges in complete denture wearers: a mixed-longitudinal study covering 25 years." *J Prosthet Dent* 27(2): 120–132.
- Walton, J. N., N. Glick et al. (2009). "A randomized clinical trial comparing patient satisfaction and prosthetic outcomes with mandibular overdentures retained by one or two implants." *Int J Prosthodont* 22(4): 331–339.
- Wolfart, S., K. Braasch et al. (2008). "The central single implant in the edentulous mandible: improvement of function and quality of life. A report of 2 cases." *Quintessence Int* 39(7): 541–548.
- Wright, C. R. (1966). "Evaluation of the factors necessary to develop stability in mandibular dentures." *J Prosthet Dent* 16(3): 414–430.

Case 5

Case 5

Management of florid cemento-osseous dysplasia (FCOD)

Florid cemento-osseous dysplasia (FCOD) is defined as a benign fibro-osseous lesion. FCOD is predominant in the mandible, but it may affect all four quadrants with prevalence in middle-aged African American and Asian females. A review of the current literature shows

limited prosthetic treatments for patients affected with FCOD. In this chapter, a removable prosthodontic treatment approach for a patient with severely expanded buccal and lingual cortical plates is described.

CASE STORY

A 48-year-old African-American female presents with pain in the mandibular anterior region. After careful assessments of radiographs, intraoral exam, consultation with an oral pathologist, and an oral surgeon, the patient was diagnosed with florid cemento-osseous dysplasia (FCOD).

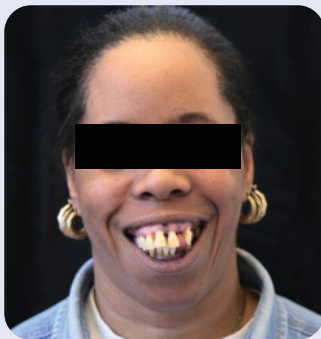

Figure 1: Pretreatment front view.

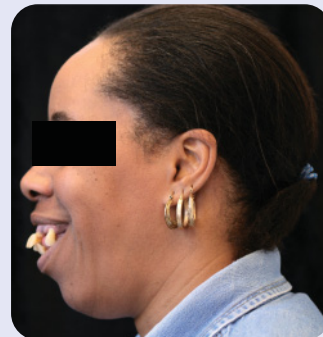

Figure 2: Pretreatment side view.

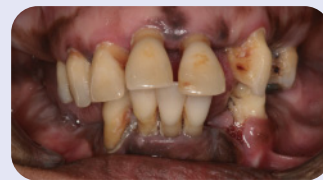
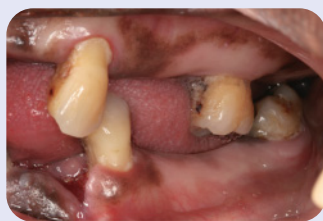
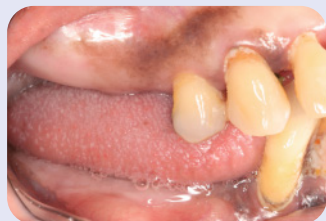Figure 3: Pretreatment maximum intercuspal position.



Figures 4 and 5: Pretreatment side views.

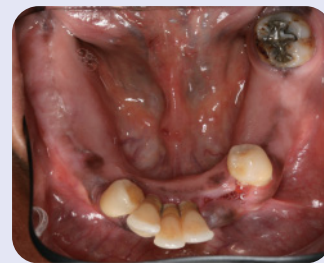
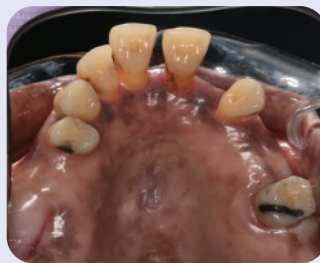
Figure 6: Maxillary and mandibular occlusal views.

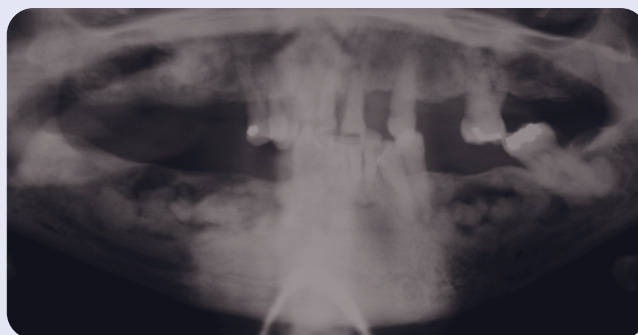

Figure 7: Panoramic radiograph.

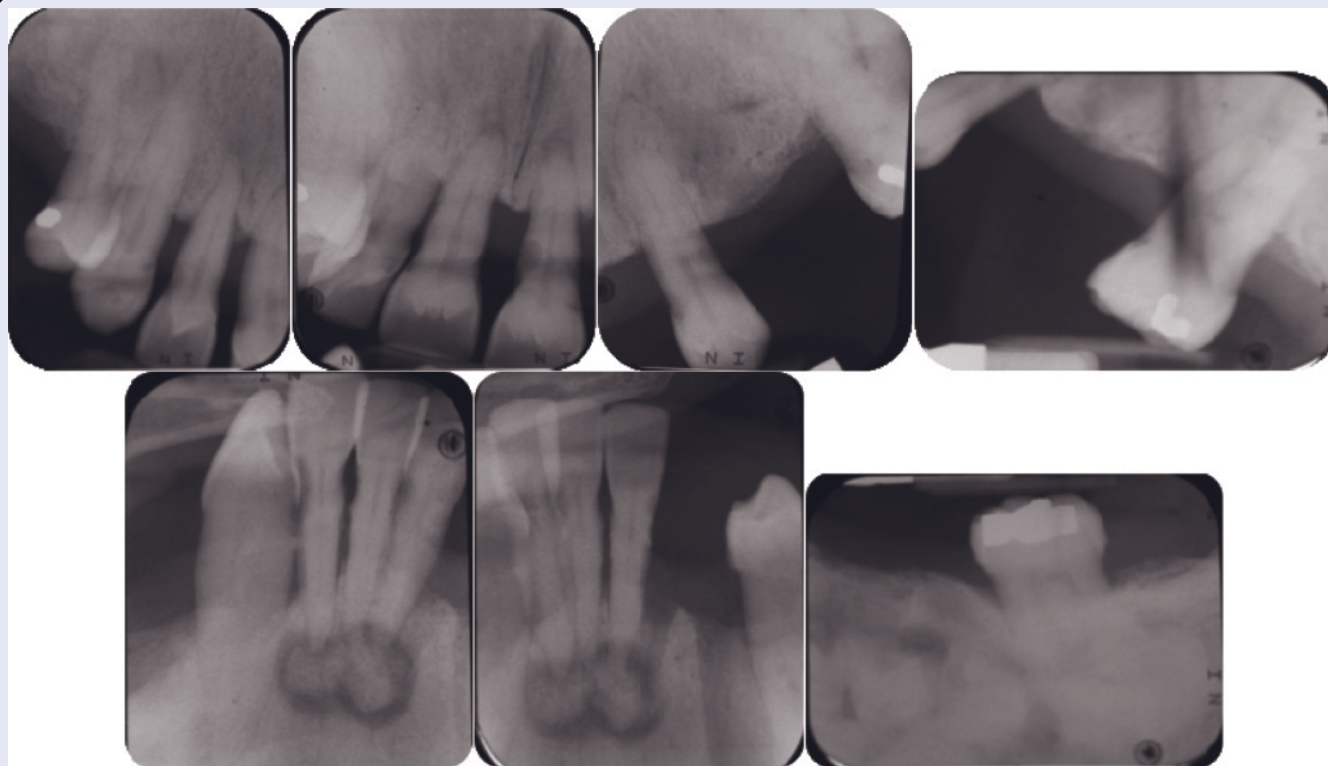


Figure 8: Periapical radiographs.

LEARNING GOALS AND OBJECTIVES

- Identify clinical features and symptoms of florid cemento-osseous dysplasia.
- Identify treatment options for patients with FCOD.

Medical History

- No significant contributory systemic findings

Dental History

- Multiple extractions in the past 5 years
- Patient has not worn any prostheses in the past

Clinical Findings/Problem List

- Missing teeth
- Supraerupted remaining dentition
- Grade II–III mobility
- Occlusal plane discrepancy
- Limited interarch space

Radiographic Findings

- Diffuse sclerotic lobulated masses with radiolucent borders in maxilla and mandible in irregular pattern
- Generalized 60–90% bone loss
- Periapical radiolucency on the remaining mandibular dentition

Diagnosis

- Severe adult chronic periodontitis
- Chronic periradicular periodontitis
- Partial edentulism
- Limited interarch space
- Florid cemento-osseous dysplasia

Clinical Decision-Making Determining Factors

- Florid cement-osseous dysplasia is a benign fibro-osseous lesion, which may affect all four quadrants of the mouth. These lesions contain fibrous connective tissue with abnormal bone or cementum (Singer, Mupparapu et al. 2005).
- The potential treatment complications result from the poor vascular nature of the involved bone. Therefore, the healing ability of the affected site can be compromised (Bencharit, Schardt-Sacco et al. 2003).
- Currently, there is no established data on the healing rate following the surgical procedure on these patients. However, a case report by Bencharit et al.

describes successful healing after mandibular resection and implant surgery. Bencharit et al. further demonstrated successful osseointegration of implants with a functioning fixed detachable mandibular prosthesis in a patient with FCOD (Bencharit, Schardt-Sacco et al. 2003).

- Limited interarch space due to overgrowth of alveolar bone can be a complicating factor in rehabilitation of these patients.

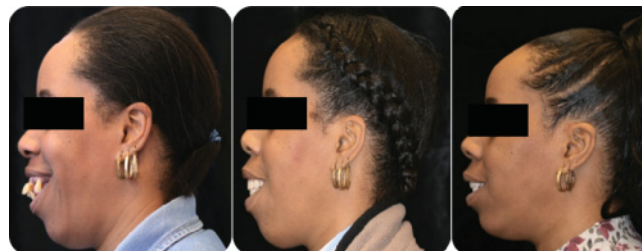

Figure 9: Patient profile throughout treatment.

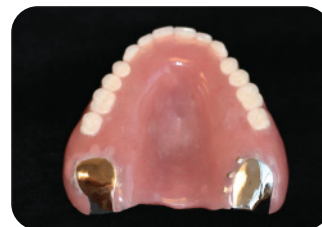

Figure 10: Maxillary prosthesis.

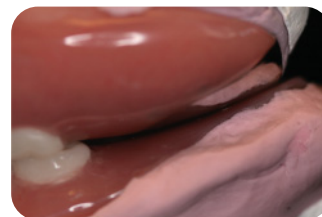

Figure 11: Prostheses remounted.

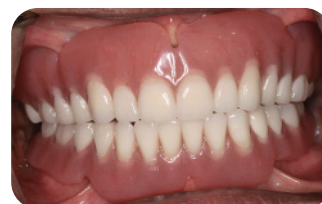

Figure 12: Posttreatment front view.

Questions

1. The cause of florid cemento-osseous dysplasia (FCOD) is

- A. Unknown
- B. Chronic periapical infection
- C. Chronic periodontitis
- D. Chronic gingivitis

2. FCOD is mostly seen in which population?

- A. Asian
- B. Caucasian
- C. African American
- D. Pacific islander

3. Which arch is more likely to be involved in florid cemento-osseous dysplasia?

- A. Maxilla
- B. Mandible
- C. No predilection between the arches

4. Which of the following symptoms and clinical features is *not* associated with FCOD?

- A. Jaw expansion
- B. Spontaneous pain
- C. Size of lesion can be 1 to–10 cm
- D. Poorly circumscribed and initially radiolucent

5. Which of the following statements regarding the treatment approach for management of FCOD is *true*?

- A. There is no specific recommended treatment for patients with FCOD.
- B. Initially, conservative treatment is indicated.
- C. Avascular nature of the lesion can lead to bone necrosis, requiring surgical and prosthodontic treatment.
- D. All of the above

6. The clinical and radiographic features of florid cemento-osseous dysplasia are also seen in

- A. Chronic diffuse osteomyelitis
- B. Condensing osteitis
- C. Cemento-osseous dysplasia
- D. Chronic periradicular periodontitis

7. Which of the following statements regarding the management of aggressive forms of florid cemento-osseous dysplasia is *incorrect*?

- A. Aggressive surgical treatment is indicated in the presence of persistent infection.
- B. Surgical treatment approaches for an aggressive benign tumor or a carcinoma in situ lesion have been suggested.
- C. Trauma from denture prostheses can lead to unresolved secondary infections.
- D. Dental implant therapy is shown to be successful in prosthetic rehabilitation of patients with aggressive florid cemento-osseous dysplasia.

8. Secondary infection in patients with FCOD usually occurs with

- A. Trauma from an ill-fitting prosthesis
- B. Recurrent periapical infection
- C. Persistent periodontitis
- D. Persistent gingivitis

9. Surgical intervention for management of FCOD should be carefully considered due to

- A. The lack of vascularity of lesions
- B. Poor response to antibiotic therapy
- C. High risk of osteomyelitis
- D. All of the above

ANSWERS

1. A (Tonioi and Schindler 2004)
2. C (Tonioi and Schindler 2004)
3. B (MacDonald-Jankowski 2003)
4. B (Bencharit, Schardt-Sacco et al. 2003; Melrose, Abrams et al. 1976; Coleman, Altini et al. 1996; Thakkar, Horner et al. 1993; Ackermann and Altini 1992; Arij, Arij et al. 1994)

5. D (Bencharit, Schardt-Sacco et al. 2003)
6. A (Singer, Mupparapu et al. 2005)
7. D (Bencharit, Schardt-Sacco et al. 2003)
8. A (Bencharit, Schardt-Sacco et al. 2003)
9. D (Bencharit, Schardt-Sacco et al. 2003; MacDonald-Jankowski 2003)

The authors would like to acknowledge and thank Dr. Mary Kang and Dr. Mijin Choi for clinical case photographs and treatment performed at New York University College of Dentistry.

References

- Ackermann, G. L. and M. Altini (1992). "The cementomas—a clinicopathological re-appraisal." *J Dent Assoc S Afr* 47(5): 187–194.
- Arij, Y., E. Arij et al. (1994). "Florid cemento-osseous dysplasia. Radiographic study with special emphasis on computed tomography." *Oral Surg Oral Med Oral Pathol* 78(3): 391–396.
- Bencharit, S., D. Schardt-Sacco et al. (2003). "Surgical and prosthodontic rehabilitation for a patient with aggressive florid cemento-osseous dysplasia: a clinical report." *J Prosthet Dent* 90(3): 220–224.
- Coleman, H., M. Altini et al. (1996). "Familial florid cemento-osseous dysplasia—a case report and review of the literature." *J Dent Assoc S Afr* 51(12): 766–770.
- MacDonald-Jankowski, D. S. (2003). "Florid cemento-osseous dysplasia: a systematic review." *Dentomaxillofac Radiol* 32(3): 141–149.
- Melrose, R. J., A. M. Abrams et al. (1976). "Florid osseous dysplasia. A clinical-pathologic study of thirty-four cases." *Oral Surg Oral Med Oral Pathol* 41(1): 62–82.
- Singer, S. R., M. Mupparapu et al. (2005). "Florid cemento-osseous dysplasia and chronic diffuse osteomyelitis: Report of a simultaneous presentation and review of the literature." *J Am Dent Assoc* 136(7): 927–931.
- Thakkar, N. S., K. Horner et al. (1993). "Familial occurrence of periapical cemental dysplasia." *Virchows Arch A Pathol Anat Histopathol* 423(3): 233–236.
- Tonioi, M. B. and W. G. Schindler (2004). "Treatment of a maxillary molar in a patient presenting with florid cemento-osseous dysplasia: a case report." *J Endod* 30(9): 665–667.

Case 6

Case 6

Treatment of a partially edentulous patient with implant-retained removable partial denture prosthesis

CASE STORY

A 55-year-old male patient presents with a chief complaint of "I am not happy with the way my partial denture fits." The patient has been wearing a removable partial denture in the maxilla for over 10 years. Given the design of the RPD, there was little retention on the patient's left side. The patient wished to keep as many of his remaining natural teeth as possible.

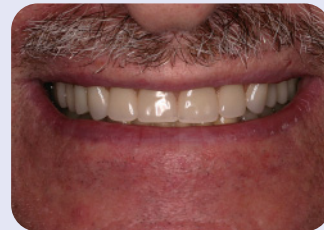
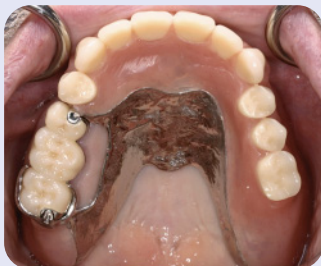
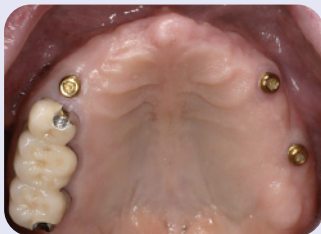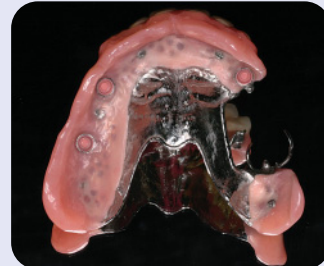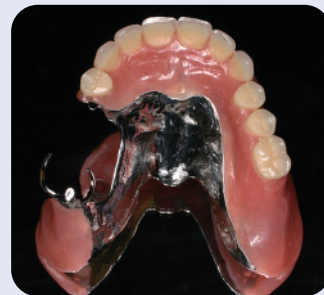Figure 3: Posttreatment smile.



Figures 1 and 2: Posttreatment maxilla with implant-retained removable partial denture.



Figures 4 and 5: Implant-retained removable partial denture.

LEARNING GOALS AND OBJECTIVES

- Indications for implant-retained removable partial dentures (IRRPD)
- Design of IRRPD frameworks
- Supplemental RPD framework design elements in anticipation of future tooth loss

Medical History

- No significant findings

Dental History

- Multiple extractions due to caries and periodontal disease
- Fixed partial dentures and single-unit full coverage restorations
- Removable partial dentures in the maxilla and mandible
- Endodontic therapy of multiple teeth including maxillary right second premolar (4)

Medications and Allergies

- No medications
- No known drug allergies

Review of Systems

- Vital signs:
 - Blood pressure: 120/80
 - Heart rate: 74 beats/minute
 - Respiration: 16 breaths/minute

Social History

- History of smoking one pack cigarettes per day for 10 years
- Discontinued smoking 25 years ago

Significant Soft Tissue Examination Findings

- No significant findings

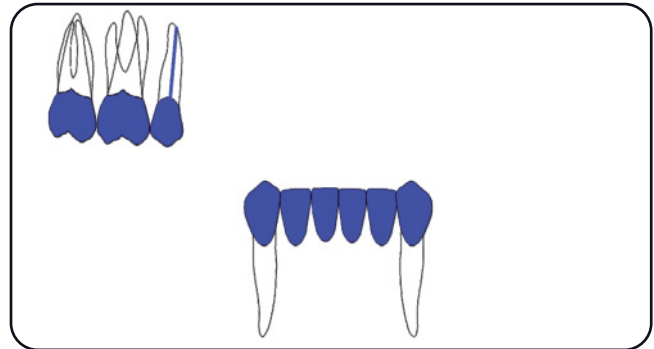
Charting

Figure 6: Dental charting.

Significant Clinical Findings/ Problem List

- Caries: Maxillary right 1st and 2nd molars and 2nd premolar (2, 3, 4)
- Ill-fitting maxillary removable partial denture

Diagnosis

- Caries
- Maxillary and mandibular partial edentulism

Clinical Decision-Making Determining Factors

- Removable partial dentures provide a sound and desirable treatment option for many prosthodontic patients. This can be for several reasons:
 - Lack of suitable abutments for conventional fixed partial dentures
 - Lack of suitable bone for implant therapy with fixed prostheses
 - Financial constraints
- For these patients, a conventional removable partial denture (RPD) may be a comfortable, affordable, and desirable treatment option. In some clinical situations, however, the retention and function of a conventional RPD may be compromised due to lack

of an adequate number of abutment teeth. This is the case for the patient being discussed here. Treatment alternatives for this patient include the following:

- Removal of the three remaining maxillary teeth and fabrication of a maxillary complete denture
- Fabrication of a conventional removable partial denture
- Fabrication of an implant-retained removable partial denture
- Because the patient has expressed the desire to maintain his remaining teeth yet have more retention with his RPD, option 3 was selected for his treatment.
- Implant-retained removable partial dentures (IRRPDs) have recently become the focus of dental treatment planning for patients who require affordable treatment and better retention for their removable prostheses. They can be designed either as having only support elements, typically with a healing abutment on which distal extension(s) of the RPD rest, or they can include retentive elements in the form of resilient attachments such as Locator attachments, as we utilized for the patient presented here (Mijiritsky 2007).
- Laboratory and long-term clinical studies are needed for an evidence-based approach to the design of the IRRPD framework. However, even without such studies, conventional design practices as well as sound clinical judgment should be used. The following are some of the proposed design guidelines (Grossmann, Nissan et al. 2009):
 - Rest seats and guiding planes should be used.
 - The major connector should be rigid.
 - Resilient attachments should be used for retention.
 - Whenever possible, implants should be placed in areas conducive to future fixed restoration, should that become a possible option for the patient.
 - For support in a mandibular distal extension IRRPD, the implants should be placed in the second molar area.

- Increased patient satisfaction with a removable prosthesis is another advantage of using IRRPDs. Increased retention leads to better function and improved mastication. Furthermore, a clasplless design improves aesthetics. This advantage is clearly important for patients because their previous, conventional RPDs required buccal clasp arms (Mitrani, Brudvik et al. 2003; Grossmann, Levin et al. 2008).
- In anticipation of possible loss of the remaining abutment teeth, the IRRPD framework was designed with elements that would allow conversion of the prostheses to an implant-retained complete denture.

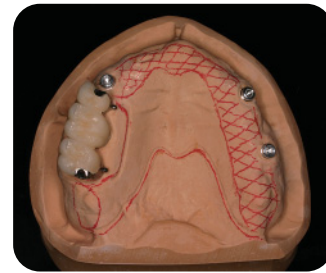


Figure 7: Design of removable partial denture.

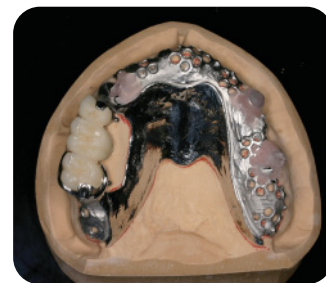

Figure 8: Removable partial denture framework.

Questions

1. What is the patient-perceived advantage of IRRPDs versus complete denture therapy?

- A. Decreased expense
- B. Decreased amount of surgery
- C. Maintained proprioception by keeping natural teeth
- D. Maintained vertical dimension

2. What are some of the patient-perceived advantages of IRRPDs versus conventional RPDs?

- A. Increased retention
- B. Increased support
- C. Increased chewing efficiency
- D. Increased aesthetics
- E. All of the above

3. It is theoretically possible to convert partially edentulous arches from one Kennedy classification to another by the introduction of implants in the edentulous areas. Conversion of a Kennedy class I edentulous arch to which of the following would be most beneficial in terms of providing a more stable and functional arch?

- A. Class II
- B. Class III
- C. Class IV
- D. Class I modification I
- E. Class II modification I

4. Several studies have demonstrated patients reporting that their chewing efficiency has improved after treatment with implant-retained removable partial dentures. These are patients with Kennedy class I design IRRPDs. What could be the main contributing factor for this finding?

- A. The vertical stop from the implants providing more stability for mastication
- B. Increased retention of the RPD
- C. Conversion of the RPD design from Kennedy class I to Kennedy class II
- D. Increased proprioception with implants

5. Attachment systems such as the Locator attachment allow for a resilient attachment of the prosthesis to the implant. In the case of the Locator attachment, how is vertical resilience achieved?

- A. There is a 0.2 mm space in the nylon patrix of the attachment.
- B. By removing a portion of the denture base acrylic
- C. By not including rest seats in the IRRPD framework design
- D. No vertical resilience should be allowed.

6. Residual ridge resorption is an unfortunate sequela with use of a distal extension removable partial denture. Studies have compared residual ridge resorption in patients wearing conventional removable prostheses versus patients wearing implant-retained removable prostheses. The difference in residual ridge resorption was shown to be almost 1 mm in 5 years between the two groups in favor of the implant-retained prostheses. What could be contributing to the reduction in residual ridge resorption?

- A. Increased distribution of load around the dental arch
- B. Decrease of cantilever effect on abutment teeth
- C. Stimulation of remodeling around implants in function
- D. Improved masticatory efficiency resulting in decreased pressure on the edentulous areas of the arch

Continued on page 44.

7. Patient satisfaction surveys have shown that patients are more satisfied with IRRPDs as compared to conventional RPDs. One of the greatest advantages to the use of IRRPDs is the increase in compliance of the denture patient. Because the patients are more likely to wear their prostheses, which of the following other concern(s) of the restorative dentist will be addressed?

- A. Posterior support will be consistently provided for the patient.
- B. Bone loss will be reduced in the edentulous areas.
- C. Periodontal health of remaining abutment teeth will improve.
- D. Caries risk of remaining teeth will decrease.
- E. All of the above

8. A common complication with IRRPDs is

- A. Abutment tooth fracture
- B. Implant abutment loosening
- C. Framework warping
- D. Inflammation of the periimplant tissues
- E. There are no reported complications with this prosthesis.

ANSWERS

1. C (Chikunov, Doan et al. 2008; Grossmann, Nissan et al. 2009)
2. E (Grossmann, Levin et al. 2008)
3. B (Ohkubo, Kobayashi et al. 2008; Grossmann, Nissan et al. 2009)
4. A (Mijiritsky 2007; Grossmann, Levin et al. 2008)

5. A (Chikunov, Doan et al. 2008)
6. C (Kordatzis, Wright et al. 2003; Mijiritsky 2007)
7. A (Mijiritsky 2007; Grossmann, Levin et al. 2008)
8. B (Mitrani, Brudvik et al. 2003)

The authors would like to acknowledge and thank Dr. Igor Chikunov for clinical case photographs and treatment performed at New York University College of Dentistry.

References

- Chikunov, I., P. Doan et al. (2008). "Implant-retained partial overdenture with resilient attachments." *J Prosthodont* 17(2): 141–148.
- Grossmann, Y., L. Levin et al. (2008). "A retrospective case series of implants used to restore partially edentulous patients with implant-supported removable partial dentures: 31-month mean follow-up results." *Quintessence Int* 39(8): 665–671.
- Grossmann, Y., J. Nissan et al. (2009). "Clinical effectiveness of implant-supported removable partial dentures: a review of the literature and retrospective case evaluation." *J Oral Maxillofac Surg* 67(9): 1941–1946.
- Kordatzis, K., P. S. Wright et al. (2003). "Posterior mandibular residual ridge resorption in patients with conventional dentures and implant overdentures." *Int J Oral Maxillofac Implants* 18(3): 447–452.
- Mijiritsky, E. (2007). "Implants in conjunction with removable partial dentures: a literature review." *Implant Dent* 16(2): 146–154.
- Mitrani, R., J. S. Brudvik et al. (2003). "Posterior implants for distal extension removable prostheses: a retrospective study." *Int J Periodontics Restorative Dent* 23(4): 353–359.
- Ohkubo, C., M. Kobayashi et al. (2008). "Effect of implant support on distal-extension removable partial dentures: in vivo assessment." *Int J Oral Maxillofac Implants* 23(6): 1095–1101.

Case 7

Case 7

Treatment of a partially edentulous patient with fixed and removable prostheses

CASE STORY

A 72-year-old Caucasian female presents with a chief complaint of: "I need new partial dentures and a new crown, so I can chew better." She is partially edentulous in the maxilla and the mandible and has multiple fixed partial dentures. The patient has been wearing partial dentures for about 19 years and has been visiting her dentist every 6 months for routine maintenance appointments. She has controlled elevated blood pressure as well, and prefers "less stressful" dental procedures.

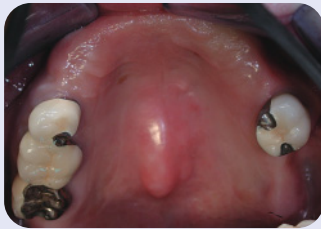

Figure 1: Preoperative maxilla.

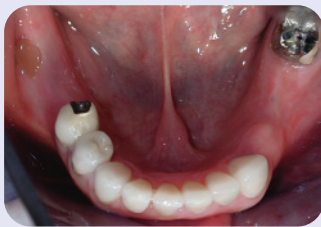

Figure 2: Preoperative mandible.

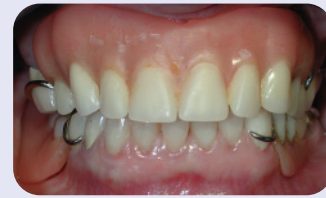

Figure 3: Preoperative presentation.

LEARNING GOALS AND OBJECTIVES

- Sequence treatment of a patient requiring a combination of fixed and removable prostheses.
- Discuss critical design elements for removable partial dentures.
- Use a surveying instrument.
- Understand parameters for abutment selection for removable partial dentures.
- Recognize and treat common postinsertion sequelae.

Medical History

- Less than favorable bone scan about 10 years ago requiring oral bisphosphonate therapy
- Moderate hypertension

Dental History

- Multiple extractions were done due to caries, periodontal disease, and failed endodontic treatment.

- First maxillary and mandibular removable partial dentures were inserted 19 years ago.
- Existing mandibular removable partial denture is uncomfortable.
- Mandibular left canine (22) was diagnosed as necrotic, requiring endodontic therapy.

Medications and Allergies

- Fosamax, 70 mg tablet once weekly
- Lasix, 40 mg twice daily

Review of Systems

- Controlled hypertension
- Controlled osteoporosis
- Vital signs:
 - Blood pressure: 130/88
 - Heart rate: 71 beats/minute
 - Respiratory rate: 14 breaths/minute

Social History

- Smoking: former 1 pack a day cigarette smoker, stopped 15 years ago
- Alcohol: occasional glass of wine
- Recreational drugs: denies having ever used them

Significant Soft Tissue Examination Findings

- Mucosa: irritated mandibular edentulous areas
- Hard palate: torus

Charting

(See Fig. 4.)

Clinical Findings/Problem List

- Partial edentulism
- Inadequate existing removable partial dentures
- Inflamed/ irritated mucosa in the edentulous regions

Diagnosis

- Partial edentulism
- Ill-fitting removable partial dentures
- Irreversible chronic periradicular periodontitis (mandibular left canine)

Clinical Decision-Making Determining Factors

- Careful clinical and radiographic evaluation of the patient and her dentition includes periodontal assessment, crown-to-root ratio, and caries assessment. All restorations must be completed

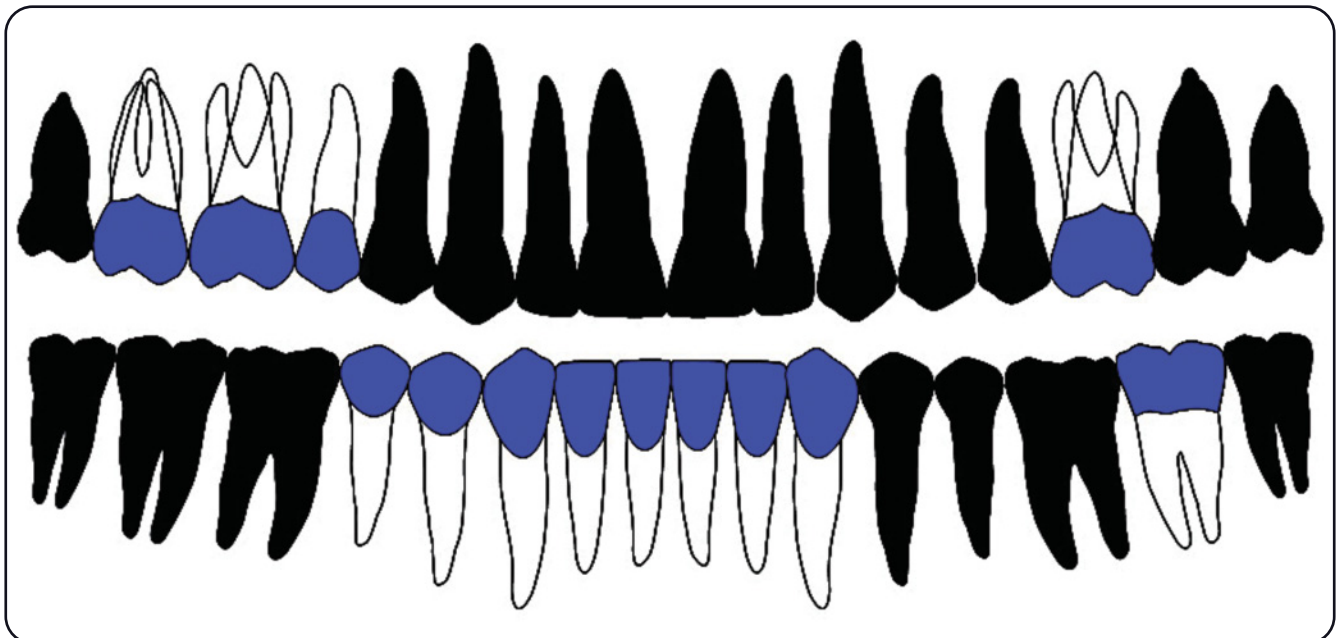


Figure 4: Dental charting.

prior to making the final impression for the removable partial dentures. These include teeth requiring restorations due to caries or defective existing restorations, fractures or endodontic therapy, and recontouring or enameloplasty. The sequence of treatment should be such that in the initial phase of treatment planning, a survey and design of the planned removable partial denture should be performed on the diagnostic casts.

- This patient had received endodontic therapy on the left mandibular canine (22). This tooth requires a cast post and core to reestablish the missing coronal tooth structures. The subsequent crown fabrication will have removable partial denture elements incorporated into its construction. This type of crown is called a survey crown and must be planned at the outset of treatment so that once the crown is delivered, it has the planned design elements incorporated into its fabrication (Kahn 1960; McCracken 1956; Mills 1960).
- Critical steps in fabricating adequate removable partial dentures:
 1. Select abutment—it should be based on periodontal and restorative prognosis of the tooth/teeth.
 2. Survey and design the study cast.
 - a. Assess occlusion.
 - b. Identify a favorable tilt.
 - c. Identify the retentive undercuts on abutment teeth and clasp assembly design.
 - d. Evaluate soft tissue undercuts that may interfere with major or minor connectors.
 - e. Determine guide planes and path of insertion. Removable partial dentures should be designed so that guide planes are present on abutment teeth adjacent to the edentulous spaces. The frictional contact of the denture against the parallel surfaces aids in retention.
 - f. Selection of the major connector should include assessment of available space between the connector and the free gingival tissue (recommended 4 mm in the mandible and 6 mm in the maxilla).

- g. Select minor connector.
 - h. Locate soft tissue stops.
3. Modify teeth.
 - a. Rest seats should be prepared in the selected abutment teeth.
 - b. Guide planes: prepared surfaces that are parallel to each other and also parallel to the path the denture takes as it is inserted and withdrawn from the mouth; these planes may be created on dental restorations or enamel surfaces.
 - c. Rest seat preparations for indirect retainers
 - d. Contour modification for idealizing survey lines and to create optimal retentive and bracing elements (Avant 1971; White 1978; Frechette 1953; Friedman 1954; Granger 1941).
 - At the insertion visit, the following must be assessed for adjustment:
 1. Intimate and accurate fit of tissue supporting areas
 2. Passive seating of the clasp assembly, which includes the rest seat, proximal plates, location of the clasp arms, and bracing (reciprocal) components
 3. Seating of the indirect retainer where applicable
 4. Occlusion
 5. Speech and aesthetics
 - Some postinsertion issues should be expected even after initial adjustments at the time of delivery. The patient must be informed that these occur and require postinsertion visits for further adjustments.
 - Oral hygiene instructions should include daily brushing of the remaining teeth and the prostheses. The patient should avoid wearing the prostheses at night and the prostheses should be kept in water when not in use. The patient should refrain from using harsh household cleansing agents and abrasives not intended for prosthesis care. These can cause corrosion and irreversible damage to the prostheses. The patient should also be asked not to make any adjustments to the denture at home (Wagner 1971; Kuebker 1984; Phoenix and DeFreest 1997).

Questions

1. When planning a "fixed-removable case," factors to be considered during the preliminary design phase are

- A. Abutment teeth selection
- B. Retention, support, and stability
- C. Periodontal health
- D. All of the above are vital for a predictable outcome.

2. What is the main function(s) of a clasp assembly in removable partial dentures?

- A. Provide resistance
- B. Provide occlusal rest seats on all posterior teeth
- C. Provide support, retention, and bracing for the RPD
- D. Provide an aesthetic outcome for the RPD

3. What is the purpose of an indirect retainer?

- A. Provide support against lifting of the denture base away from tissues during function
- B. Indirect retainer is in the form of a clasp.
- C. To relieve stress on the residual ridges
- D. All of the above

4. All the following design features of the RPD augment retention of the denture, *except*

- A. Physiologic adjustment of the framework to assure contacts with abutment teeth
- B. Using porcelain denture teeth instead of acrylic denture teeth
- C. Intimate adaptation of denture bases to the residual mucosa
- D. Presence of guide planes

5. When selecting abutment teeth for an RPD, one should consider

- A. Crown-to-root ratio
- B. Periodontal health of all teeth to be considered as abutment teeth
- C. Stress distribution in a distal extension RPD
- D. The height of contour of the tooth
- E. All are important in the abutment selection.

6. How can a dental surveyor be used to prevent problems related to the production of removable partial dentures?

- A. It can help to determine the path of insertion and removal of a removable partial denture.
- B. Location of undercuts on abutment teeth
- C. Location of soft tissue undercuts
- D. All of the above

7. Which of the following statements regarding the altered cast impression technique is *true*?

- A. Allows one to make an accurate soft tissue impression of the mandibular distal extension areas
- B. Is a technique used for tooth-borne removable partial dentures
- C. Is a recommended technique in the maxillary arch
- D. Is not technique-sensitive

8. Which of the following is considered the least favorable choice of retainer in a distal extension removable partial denture design?

- A. Aker's clasp
- B. I bar
- C. Embrasure clasp
- D. Wrought wire clasp

9. Which of the following are indications for using a lingual plate as a major connector?

- A. To support periodontally weakened teeth
- B. When there is less than 8 mm of space from the floor of the mouth to the free gingival margin, or if there is a high lingual frenum
- C. Mandibular tori are present and cannot be removed.
- D. All are reasons for use of a lingual plate as a major connector.

10. The following items should be evaluated during the final insertion visit and the postinsertion follow-up visits:

- A. Rest seats are fully seated and clasps are properly engaged.
- B. Acrylic flanges are not overextended.
- C. Occlusion is accurate.
- D. All of the above items should be evaluated and monitored.

- 10. D (Kawata, Kawaguchi et al. 2008)
- 9. D (Akaltan and Kaynak 2005)
- 8. C (Igarashi, Ogata et al. 1999)
- 7. A (Lynde, Baker et al. 1992)
- 6. D (Bezzon, Mattos et al. 1997)

- 5. E (Mizuuchi, Yatabe et al. 2002)
- 4. B (Donahue 1988)
- 3. A (Itoh, Baba et al. 2008)
- 2. C (Sato, Shimodaira et al. 2008)
- 1. D (Samet, Bundy et al. 2008)

ANSWERS

The authors would like to acknowledge and thank Dr. Edward Goldin for the clinical case photographs and treatment performed at New York University, College of Dentistry.

References

- Akaltan, F. and D. Kaynak (2005). "An evaluation of the effects of two distal extension removable partial denture designs on tooth stabilization and periodontal health." *J Oral Rehabil* 32(11): 823–9.
- Avant, W. E. (1971). "Factors that influence retention of removable partial dentures." *J Prosthet Dent* 25(3): 265–70.
- Bezzon, O. L., M. G. Mattos et al. (1997). "Surveying removable partial dentures: the importance of guiding planes and path of insertion for stability." *J Prosthet Dent* 78(4): 412–8.
- Donahue, T. J. (1988). "Factors that augment the role of direct retainers in mandibular distal-extension removable partial dentures." *J Prosthet Dent* 60(6): 696–9.
- Frechette AR. (1953) Partial denture planning with special reference to stress distribution. *J Ontario Dent Assoc* 30:318–329.
- Friedman J. (1954) "Abutment sites and spaces in partial denture case analysis." *J Prosthet Dent* 4:803–812.
- Granger ER. (1941) "Mechanical principles applied to partial denture construction." *J Am Dent Assoc* 28:1943–1951.
- Igarashi, Y., A. Ogata et al. (1999). "Stress distribution and abutment tooth mobility of distal-extension removable partial dentures with different retainers: an in vivo study." *J Oral Rehabil* 26(2): 111–6.
- Itoh, H., K. Baba et al. (2008). "Effect of direct retainer and major connector designs on RPD and abutment tooth movement dynamics." *J Oral Rehabil* 35(11): 810–5.
- Kahn, A. E. (1960). "Partial versus full coverage." *J Prosthet Dent* 10: 167–178.
- Kawata, T., T. Kawaguchi et al. (2008). "Effects of a removable partial denture and its rest location on the forces exerted on an abutment tooth in vivo." *Int J Prosthodont* 21(1): 50–2.
- Kuebker, W. A. (1984). "Denture problems: causes, diagnostic procedures, and clinical treatment. III/IV. Gaggling problems and speech problems." *Quintessence Int Dent Dig* 15(12): 1231–8.
- Lynde, T. A., P. S. Baker et al. (1992). "Simplifying the altered cast impression technique for distal-extension removable partial dentures." *J Prosthet Dent* 67(6): 891.
- McCracken, W. L. (1956). "Mouth preparations for partial dentures." *J Prosthet Dent* 6: 39–52.
- Mills, M. L. (1960). "Mouth preparation for the removable partial denture." *J Am Dent Assoc* 60: 154–9.

- Mizuuchi, W., M. Yatabe et al. (2002). "The effects of loading locations and direct retainers on the movements of the abutment tooth and denture base of removable partial dentures." *J Med Dent Sci* 49(1): 11–8.
- Phoenix, R. D. and C. F. DeFreest (1997). "An effective technique for denture border evaluation." *J Prosthodont* 6(3): 215–7.
- Samet, N., M. Bundy et al. (2008). "A systematic approach for removable partial denture design." *Gen Dent* 56(6): 526–31.
- Sato, Y., O. Shimodaira et al. (2008). "Systematic clinical evaluation and correction procedures for support of removable partial dentures." *J Prosthodont* 17(3): 228–32.
- Wagner, A. G. (1971). "Instructions for the use and care of removable partial dentures." *J Prosthet Dent* 26(5): 477–80.
- White, J. T. (1978). "Visualization of stress and strain related to removable partial denture abutments." *J Prosthet Dent* 40(2): 143–51.

WWW.HIGHDENT.IR

همیار دندانسازان و دندانپزشکان

Case 8

Case 8

Management of ectodermal dysplasia I— overdenture prostheses

Ectodermal dysplasia (ED) is an inherited condition in which there are two or more abnormalities of ectodermally derived structures. It usually affects tooth development and presents with congenitally absent teeth or teeth that are peg-shaped or cone-shaped. The enamel is often defective. Multiple denture

replacements are often needed as the child grows to restore deficient skeletal and dental structures, and dental implants may be an option in adolescence. Dental treatment is complex; a multidisciplinary approach is recommended.

CASE STORY

A 17-year-old male patient with X-linked hypohidrotic ectodermal dysplasia presents for dental rehabilitation. The chief complaints are the inability to chew efficiently and poor aesthetics.

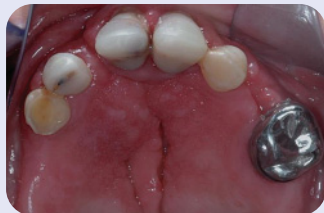

Figure 1: Preoperative maxilla.

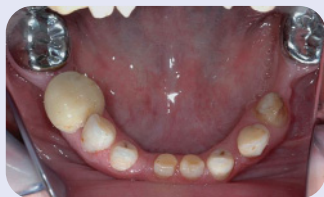

Figure 2: Preoperative mandible.

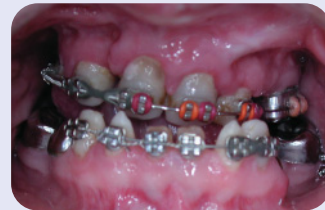

Figure 3: Preoperative presentation.

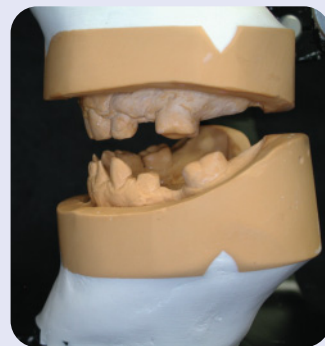

Figure 4: Preoperative mounted diagnostic casts at the vertical dimension.

LEARNING GOALS AND OBJECTIVES

- Identify facial and dental manifestations of ectodermal dysplasia (ED).
- Understand the factors considered in prosthetic rehabilitation of patients with ED.

Medical History

- Hypohidrotic ectodermal dysplasia

Dental History

- Previous dental treatments involved orthodontic treatments in efforts to align the remaining dentitions in more favorable positions for potential future prostheses.
- Difficulties with proper oral hygiene maintenance along with poorly contoured restorations resulted in further deterioration of periodontal tissues around the existing dentition.

Radiographic Findings

- Insufficient bone volume in posterior maxilla and mandible
- Periapical pathology on maxillary left canine (11)
- Periapical pathology on maxillary right central incisor (8)

Clinical Findings/Problem List

- Loss of vertical dimension of occlusion
- Poor oral hygiene
- Recurrent caries
- Defective restorations
- Reduced masticatory function
- Retained deciduous teeth
- Congenitally missing permanent teeth
- Erythematous/edematous gingival tissues
- Skeletal class III malocclusion

Diagnosis

- Ectodermal dysplasia
- Loss of vertical dimension of occlusion
- Chronic periradicular periodontitis
- Localized severe periodontitis
- Generalized moderate periodontitis
- Overcontoured/defective restorations
- Retained deciduous teeth
- Congenitally absent permanent teeth
- Caries
- Class III malocclusion

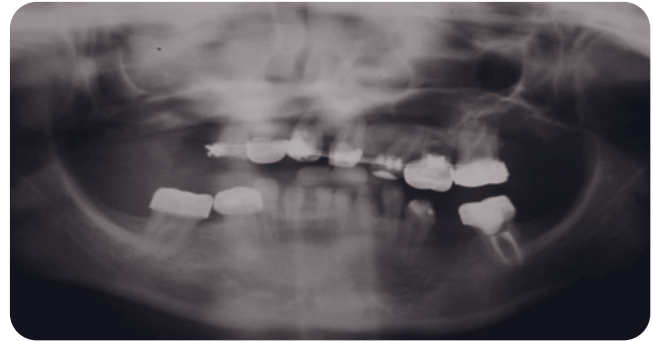


Figure 5: Panoramic radiograph.

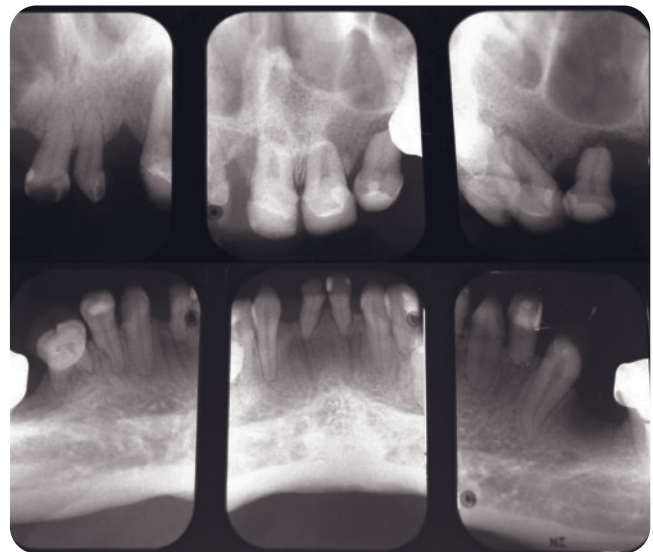


Figure 6: Periapical radiographs.

Clinical Decision-Making Determining Factors

- Ectodermal dysplasia (ED) is characterized by approximately 150 genetic disorders of aplasia or dysplasia of at least two different tissues of ectodermal origin, such as onchyodysplasia (affecting nails), hypotrichosis, (affecting hair), hypodontia (affecting teeth), or hypohidrosis (affecting sweat glands) (Kere, Srivastava et al. 1996).
- The use of dental implants and bone augmentation for patients with ED is limited. Augmented bone reduction peaks during the first 6 months and stable conditions are achieved after a period of 3 years. During the first 6 months, 33% bone resorption was observed, whereas in the following 24 months, 7% of the remaining bone was resorbed (Bell, Blakey

et al. 2002; Guckes, Scurria et al. 2002; Penarrocha-Diago, Uribe-Origone et al. 2004; Rad, Siadat et al. 2007; Worsaae, Jensen et al. 2007; Kirmeier, Gluhak et al. 2009).

- Dental intervention before school age is usually recommended to help the patients with function and aesthetics and for psychological reasons (Nunn, Carter et al. 2003).
- Two main factors affecting the success of dental treatment for ED are
 - Insufficient supported underlying mucosal tissues
 - Reduced salivary flow (Blanchaert 1998)
- Implant success rates in 96 patients over the age of 18 suffering from ectodermal dysplasia were 95% for the maxilla and 97% for the mandible. However, the severe lack of bone still is a major challenge (Guckes, Scurria et al. 2002; Kirmeier, Gluhak et al. 2009).
- Oral rehabilitation with autogenous bone grafts, followed by a delayed placement of endosteal implants and restoration with implant-supported bar-retained overdentures, is an approved approach for management of patients with ED (Verhoeven, Cune et al. 1997; Mericske-Stern, Oetterli et al. 2002; Wiltfang, Schultze-Mosgau et al. 2005; Vieira, Teixeira et al. 2007).
- The outcomes of a retrospective patient-based survey of patients with various forms of ED syndromes who received dental implant therapies revealed that there was a high rate of postoperative complications. Of the reported complications, "infections" around the implants accounted for 23%, and prosthetic complications were 19%. More importantly, when patients were asked whether they would repeat whatever forms of implant therapy they had received, 92% indicated they would (Stanford, Guckes et al. 2008).

- Given the age of the patient, and the excessive interocclusal space at the desired vertical dimension of occlusion, tooth-retained overdenture prostheses were selected as a treatment of choice.

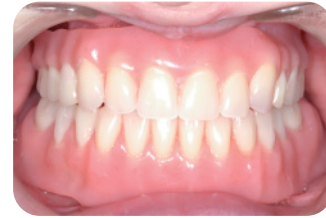

Figure 7: Postoperative presentation.

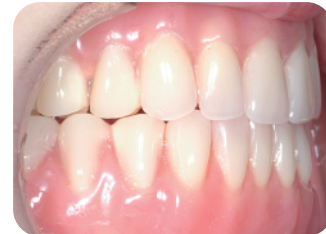

Figure 8: Postoperative, right side.

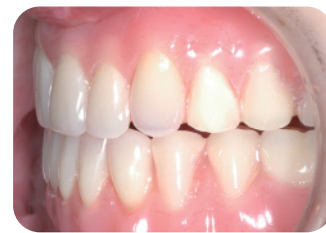

Figure 9: Postoperative, left side.

Questions

1. Ectodermal dysplasia (ED) is

- A. A hereditary disorder
- B. The most reported ED syndrome is X-linked hypohidrotic ED.
- C. Hypohidrotic ED affects males more than females.
- D. Clinical features of ED include trichondysplasia (abnormal hair), abnormal dentition, onychodysplasia (abnormal nails), and dyshidrosis (abnormal or missing sweat glands).
- E. All of the above

2. The two main clinical factors identified in patients with ectodermal dysplasia influencing the outcome of dental treatments are

- A. Adequate volume of supporting bone and adequate number of permanent dentition
- B. Acceptable dental appearance and adequate vertical dimension of occlusion
- C. Insufficient volume of supporting bone and salivary flow
- D. Poor dental appearance and adequate vertical dimension of occlusion

3. Dental manifestations of ectodermal dysplasia include all of the following *except*

- A. Normally spaced teeth
- B. Salivary hypofunction
- C. Anodontia
- D. Hypodontia

4. A survey of ED patients conducted at the National Institute of Dental and Craniofacial Research in Bethesda, Maryland, between 1986 and 1994, revealed that

- A. Most of the respondents had implant failure.
- B. Only 5% of the respondents had some form of prosthetic complication.
- C. Most of the patients preferred not to have the dental implant therapy again.
- D. Mechanical complications involved were denture fracture, loose dentures, or broken screws.

5. Although hypodontia is relatively common, severe hypodontia—that is, where six or more permanent teeth excluding third molars are absent—has a much lower reported prevalence of the order of 0.08—0.5%. This statement is

- A. True
- B. False

6. The oral care team for management of ED should include

- A. Prosthodontics
- B. Orthodontics
- C. Pediatric dentistry
- D. Oral surgery
- E. All of the above

ANSWERS

1. E (Bal, Bal et al. 2008)

2. C (Blanchaert 1998)

3. A (Stanford, Guckes et al. 2008)

4. D (Stanford, Guckes et al. 2008)

5. A (Hobkirk, Nohl et al. 2006; Rad, Siadat et al. 2007)

6. E (Hobkirk, Nohl et al. 2006)

The authors would like to acknowledge and thank Dr. Bhavani Venkatachalam for clinical case photographs and treatment performed at New York University College of Dentistry.

References

- Bal, C., B. T. Bal et al. (2008). "Treatment considerations for a patient with hypohidrotic ectodermal dysplasia: a case report." *J Contemp Dent Pract* 9(3): 128–34.
- Bell, R. B., G. H. Blakey et al. (2002). "Staged reconstruction of the severely atrophic mandible with autogenous bone graft and endosteal implants." *J Oral Maxillofac Surg* 60(10): 1135–41.
- Blanchaert, R. H. (1998). "Implants in the medically challenged patient." *Dent Clin North Am* 42(1): 35–45.
- Guckes, A. D., M. S. Scurria et al. (2002). "Prospective clinical trial of dental implants in persons with ectodermal dysplasia." *J Prosthet Dent* 88(1): 21–5.
- Hobkirk, J. A., F. Nohl et al. (2006). "The management of ectodermal dysplasia and severe hypodontia. International conference statements." *J Oral Rehabil* 33(9): 634–7.
- Kere, J., A. K. Srivastava et al. (1996). "X-linked anhidrotic (hypohidrotic) ectodermal dysplasia is caused by mutation in a novel transmembrane protein." *Nat Genet* 13(4): 409–16.
- Kirmeier, R., C. Gluhak et al. (2009). "Oral rehabilitation of adult twins with severe lack of bone due to hypohidrotic ectodermal dysplasia—a 12-month follow-up." *J Oral Maxillofac Surg* 67(1): 189–94.
- Mericske-Stern, R., M. Oetterli et al. (2002). "A follow-up study of maxillary implants supporting an overdenture: clinical and radiographic results." *Int J Oral Maxillofac Implants* 17(5): 678–86.
- Nunn, J. H., N. E. Carter et al. (2003). "The interdisciplinary management of hypodontia: background and role of paediatric dentistry." *Br Dent J* 194(5): 245–51.
- Penarrocha-Diago, M., R. Uribe-Origone et al. (2004). "Fixed rehabilitation of a patient with hypohidrotic ectodermal dysplasia using zygomatic implants." *Oral Surg Oral Med Oral Pathol Oral Radiol Endod* 98(2): 161–5.
- Rad, A. S., H. Siadat et al. (2007). "Full mouth rehabilitation of a hypohidrotic ectodermal dysplasia patient with dental implants: a clinical report." *J Prosthodont* 16(3): 209–13.
- Stanford, C. M., A. Guckes et al. (2008). "Perceptions of outcomes of implant therapy in patients with ectodermal dysplasia syndromes." *Int J Prosthodont* 21(3): 195–200.
- Verhoeven, J. W., M. S. Cune et al. (1997). "The combined use of endosteal implants and iliac crest onlay grafts in the severely atrophic mandible: a longitudinal study." *Int J Oral Maxillofac Surg* 26(5): 351–7.
- Vieira, K. A., M. S. Teixeira et al. (2007). "Prosthodontic treatment of hypohidrotic ectodermal dysplasia with complete anodontia: case report." *Quintessence Int* 38(1): 75–80.
- Wiltfang, J., S. Schultze-Mosgau et al. (2005). "Onlay augmentation versus sinuslift procedure in the treatment of the severely resorbed maxilla: a 5-year comparative longitudinal study." *Int J Oral Maxillofac Surg* 34(8): 885–9.
- Worsaae, N., B. N. Jensen et al. (2007). "Treatment of severe hypodontia-oligodontia—an interdisciplinary concept." *Int J Oral Maxillofac Surg* 36(6): 473–80.

Case 9

Case 9

Management of ectodermal dysplasia II—implant-retained removable prostheses

The use of dental implants in a growing child is not a routinely prescribed treatment approach. There is a paucity of data and studies on the growth pattern of the maxilla and mandible as it relates to the implant prosthesis in children. Since a child is still growing, placement of implants may interfere with or be affected by the continued growth of the maxilla and

mandible. Therefore, implant therapy is currently a controversial form of prosthodontic care in a growing patient. Comprehensive treatment of pediatric patients with ectodermal dysplasia is somewhat controversial because their compromised dental state can be treated with conventional prostheses.

CASE STORY

A 6-year-old male patient with Rapp-Hodgkins anhidrotic ectodermal dysplasia presents for prosthodontic management of cleft palate and complete edentulism.

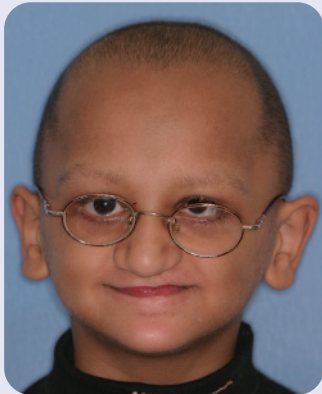


Figure 1: Frontal view.

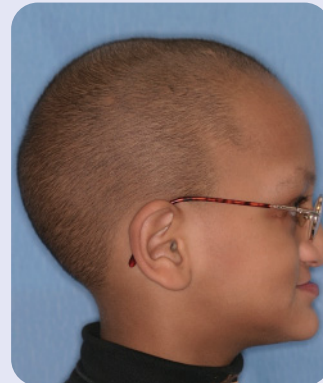

Figure 2: Lateral view.

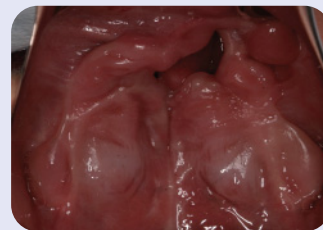

Figure 3: Maxillary occlusal view.

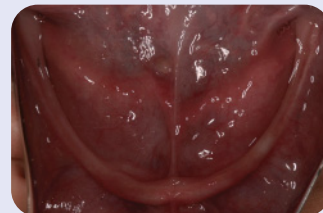

Figure 4: Mandibular occlusal view.

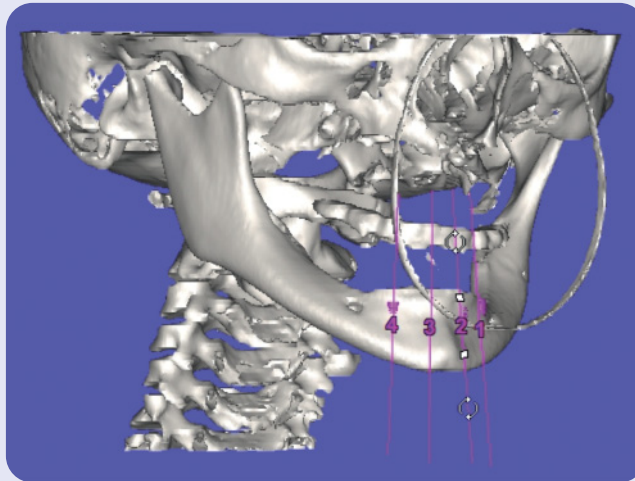


Figure 5: Computerized tomography.

LEARNING GOALS AND OBJECTIVES

- Understand the growth pattern of the maxilla and mandible in the growing patient.
- Understand the effects of anodontia and hypodontia.
- Understand the implication of implant prostheses in a growing child.
- Describe the importance of a maintenance program for young patients with ectodermal dysplasia with implant prostheses.

Medical History

- Rapp-Hodgkins anhidrotic ectodermal dysplasia

Dental History

- No previous dental treatment

Clinical Findings/Problem List

- Anodontia
- Cleft palate with oroantral fistula
- Edentulism
- Presence of mandibular tooth bud

Radiographic Findings

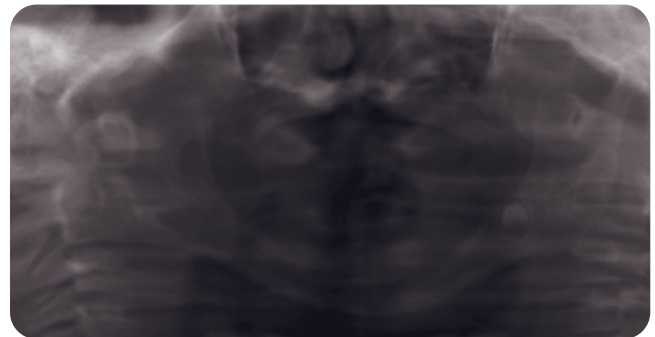


Figure 6: Panoramic radiograph.

Diagnosis

- Rapp-Hodgkins anhidrotic ectodermal dysplasia
- Anodontia
- Cleft palate

Clinical Decision-Making Determining Factors

- Anodontia refers to congenital absence of all teeth.
- Hypodontia is defined as partial congenital absence of teeth.
- Oral traits of ED may be expressed as anodontia or hypodontia with or without cleft lip and palate. Anodontia also manifests itself by lack of alveolar ridge development.

- Implant-supported prostheses or fixed partial dentures are avoided in young and actively growing patients because rigid fixed partial dentures could interfere with jaw growth, especially if the design crosses the midline (Pigno, Blackman et al. 1996).
- The use of implants placed after age 15 years for girls and 18 years for boys were shown to have the most predictable prognosis. Because of the variation in growth among individuals, a prosthesis that provides retrievability is recommended for children. This facilitates and allows for adjustments related to growth and development (Cronin, Oesterle et al. 1994, 1998).
- Mandibular growth:
 - The transverse growth of the mandible in the anterior region is finished before 1 year of age (Bjork 1964; Becktor, Becktor et al. 2001; Sharma and Vargervik 2006).
 - The influence of edentulism on the growth of the mandible is not well understood. However, the insufficient vertical growth of the lower face and a reduced mandibular plane angle were shown to result from the congenitally missing teeth in the region (Sarnas and Rune 1983; Kjaer, Kocsis et al. 1994; Nodal, Kjaer et al. 1994).
 - Implants placed between mental foramina at ages 6 and 9 were followed over a 7- to 11-year-period. The growth analysis indicated that implants placed in this region followed normal downward and forward growth of the mandible without submergence of implants. This indicates that, implant placement in this region may be a viable treatment approach in growing children (Kearns, Sharma et al. 1999; Becktor, Becktor et al. 2001; Guckes, Scurria et al. 2002).
- Maxillary growth (Bjork and Skieller 1977; Becktor, Becktor et al. 2001):
 - Vertical increase in the maxilla is the result of growth in the alveolar process and eruption of teeth.
 - Sagittal growth of the maxilla occurs by apposition of bone in the posterior part.
 - Transverse growth of the normal maxilla in a healthy child occurs by apposition of bone in the midpalatal suture area. Therefore, rigid connection with fixed prostheses over these areas should be avoided in a growing child.
 - Severe impaction of osseointegrated dental implants in the growing maxilla in connection with remodeling of the nasal floor and hard palate can occur. It has been postulated that implants in the

alveolus of a young, growing maxilla may become significantly buried in bone and their apical portions exposed as the nasal floor and maxillary sinuses remodel (Oesterle, Cronin et al. 1993; Cronin and Oesterle 1998).

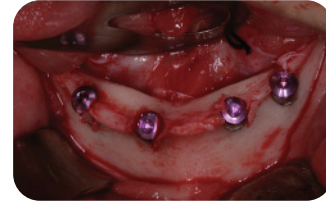


Figure 7: Surgical placement of implants.

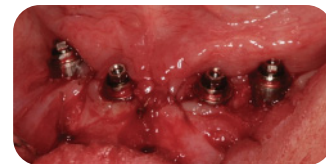

Figure 8: Implants placed in the mandible.

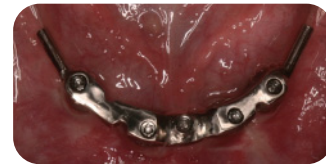

Figure 9: Mandibular bar.

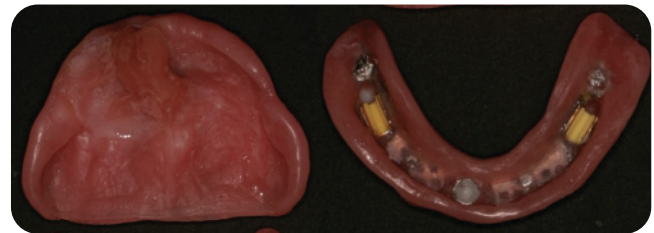

Figure 10: Maxillary and mandibular prostheses.



Figure 11: Posttreatment front view.

Questions

1. What is the direction of growth for the maxilla?

- A. Downward and forward
- B. Relocation of the nasal floor and maxillary sinus in a superior direction
- C. Upward and forward
- D. Upward only

2. What is the direction of growth for the mandible?

- A. Downward and forward
- B. Clockwise forward rotation
- C. Bone apposition superior to the symphysis
- D. Upward and forward

3. According to the growth analysis, implants placed between mental foramina are likely to

- A. Result in angulation problems after 5 years
- B. Follow the forward growth of the mandible without angulation problems
- C. Be displaced distally
- D. Become buried under the mandibular bone

4. Osseointegrated endosseous maxillary implants adjacent to the natural teeth were shown to result in submerged implants due to the following *except*

- A. The continued eruption of the neighboring teeth
- B. The associated growth of the alveolus bone around implants
- C. The intrusion of implants

5. Posterior transversal enlargement of the maxilla

- A. Mostly occurs in the midpalatal suture
- B. Enlarges 3.5 times relative to the anterior maxilla
- C. Should caution clinicians not to involve rigid connection over the midpalate suture
- D. All of the above

6. Placement of dental implants in growing children has the lowest risk in which of the following region(s) of the mandible:

- A. Molar regions
- B. Anterior region between mental foramina
- C. Premolar regions
- D. None of the above

7. The transverse growth in the anterior mandibular region is shown to be completed by

- A. Age 1
- B. Age 5
- C. Age 10
- D. Age 15

8. Implants placed in the anterior region of the maxilla are likely to

- A. Be buried in bone completely
- B. Have the apical portion of the implants exposed
- C. Have the coronal portion of implants buried
- D. Have hyperocclusion

9. What is the recommended prosthodontic recall schedule for a growing child with ectodermal dysplasia?

- A. Every 3 months
- B. Every 4 months
- C. Every 5 months
- D. Every 6–12 months

ANSWERS

1. A (Becktor, Becktor et al. 2001)
2. A (Becktor, Becktor et al. 2001)
3. B (Guckes, McCarthy et al. 1997)
4. C (Thilander, Odman et al. 1994; Thilander, Odman et al. 1999)

5. D (Becktor, Becktor et al. 2001)
6. B (Becktor, Becktor et al. 2001)
7. A (Becktor, Becktor et al. 2001)
8. C (Cronin and Oesterle 1998)
9. D (Pigno, Blackman et al. 1996)

The authors would like to acknowledge and thank Dr. Robert Berg for clinical case photographs and treatment performed.

References

- Becktor, K. B., J. P. Becktor et al. (2001). "Growth analysis of a patient with ectodermal dysplasia treated with endosseous implants: a case report." *Int J Oral Maxillofac Implants* 16(6): 864–874.
- Bjork, A. (1964). "Sutural growth of the upper face studied by the implant method." *Rep Congr Eur Orthod Soc* 40: 49–65.
- Bjork, A. and V. Skieller (1977). "Growth of the maxilla in three dimensions as revealed radiographically by the implant method." *Br J Orthod* 4(2): 53–64.
- Cronin, R. J., Jr. and L. J. Oesterle (1998). "Implant use in growing patients. Treatment planning concerns." *Dent Clin North Am* 42(1): 1–34.
- Cronin, R. J., Jr., L. J. Oesterle et al. (1994). "Mandibular implants and the growing patient." *Int J Oral Maxillofac Implants* 9(1): 55–62.
- Guckes, A. D., G. R. McCarthy et al. (1997). "Use of endosseous implants in a 3-year-old child with ectodermal dysplasia: case report and 5-year follow-up." *Pediatr Dent* 19(4): 282–285.
- Guckes, A. D., M. S. Scurria et al. (2002). "Prospective clinical trial of dental implants in persons with ectodermal dysplasia." *J Prosthet Dent* 88(1): 21–25.
- Kearns, G., A. Sharma et al. (1999). "Placement of endosseous implants in children and adolescents with hereditary ectodermal dysplasia." *Oral Surg Oral Med Oral Pathol Oral Radiol Endod* 88(1): 5–10.
- Kjaer, I., G. Kocsis et al. (1994). "Aetiological aspects of mandibular tooth agenesis—focusing on the role of nerve, oral mucosa, and supporting tissues." *Eur J Orthod* 16(5): 371–375.
- Nodal, M., I. Kjaer et al. (1994). "Craniofacial morphology in patients with multiple congenitally missing permanent teeth." *Eur J Orthod* 16(2): 104–109.
- Oesterle, L. J., R. J. Cronin, Jr. et al. (1993). "Maxillary implants and the growing patient." *Int J Oral Maxillofac Implants* 8(4): 377–387.
- Pigno, M. A., R. B. Blackman et al. (1996). "Prosthetic management of ectodermal dysplasia: a review of the literature." *J Prosthet Dent* 76(5): 541–545.
- Sarnas, K. V. and B. Rune (1983). "The facial profile in advanced hypodontia: a mixed longitudinal study of 141 children." *Eur J Orthod* 5(2): 133–143.
- Sharma, A. B. and K. Vargervik (2006). "Using implants for the growing child." *J Calif Dent Assoc* 34(9): 719–724.
- Thilander, B., J. Odman et al. (1994). "Osseointegrated implants in adolescents. An alternative in replacing missing teeth?" *Eur J Orthod* 16(2): 84–95.
- Thilander, B., J. Odman et al. (1999). "Single implants in the upper incisor region and their relationship to the adjacent teeth. An 8-year follow-up study." *Clin Oral Implants Res* 10(5): 346–355.

Case 10

Case 10

Management of ectodermal dysplasia III—a multidisciplinary approach

The ectodermal dysplasias (EDs) are inherited disorders of the embryonic ectoderm. These abnormalities of ectodermal derived structures can affect teeth, nails, skin, hair and sweat glands. The management of adults with ectodermal dysplasia who have not been adequately treated in childhood may present with complex oral presentation and may require multidisciplinary treatment approaches. Long-standing abnormal growth of the maxilla and mandible with an insufficient number of remaining teeth often has a psychological impact on the patient.

CASE STORY

A 25-year-old male presents to the clinic with the chief complaint of “I was born without many teeth. I need to eat and want to be healthy.” The patient used to wear a removable partial denture during childhood until the age of 12.

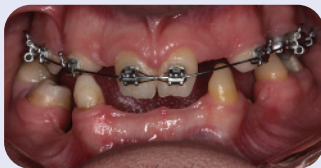
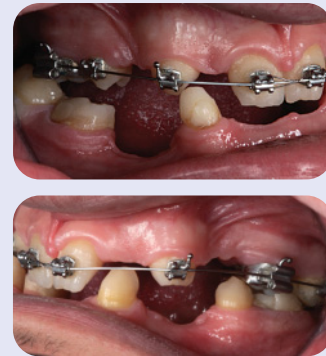
Figure 1: Preprosthetic treatment maximum intercuspation (MI).



Figures 2 and 3: Preprosthetic treatment left and MI right.

LEARNING GOALS AND OBJECTIVES

- Identify the consequences of untreated ectodermal dysplasia.
- Discuss the importance of diagnostic mock-up procedures to assess the degree of an underdeveloped maxilla and mandible.
- Understand the determining factors in assessing desired vertical dimension of occlusion.
- Understand the determining factors affecting the facial profile.

Medical History

- History of tonsillectomy at age 10
- Hypohidrotic ectodermal dysplasia

Dental History

- Removable partial denture (RPD) during childhood, discontinued by age 12

Clinical Findings/Problem List

- Missing teeth
- Excessive loss of vertical dimension
- Insufficient width of maxillary alveolar ridges
- Knife-edge mandibular ridges
- High frenum attachment level
- Concave facial profile
- Insufficient posterior contacts
- Poor crown-to-root ratio at the existing vertical dimension of occlusion (VDO)
- Limited interarch space at the existing VDO
- Midline discrepancy

Clinical and Radiographic Findings

- Root-canal treated mandibular molars
- Large pulps
- Defective existing restorations
- Hypodivergent mandibular plane
- Deficient lower 1/3 of face height

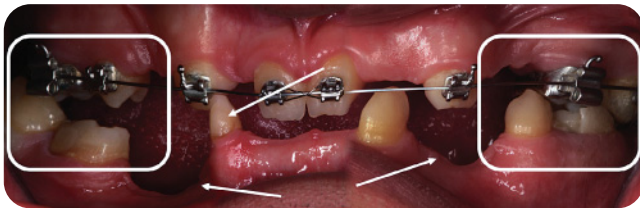


Figure 4: Front view.

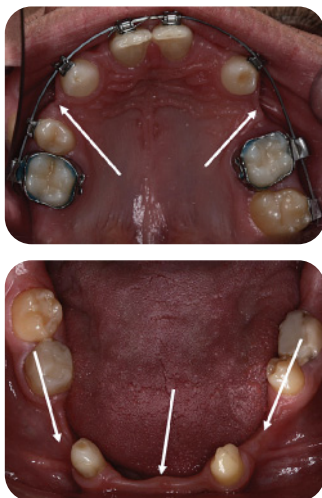


Figure 5 and 6: Maxillary and mandibular occlusal views.

Diagnosis

- Ectodermal dysplasia (ED)
- Partial edentulism
- Excessive interocclusal space at the desired (restored) VDO
- Midline discrepancy

Clinical Decision-Making Determining Factors

- The initial determination of optimal desired vertical dimension of occlusion based on the aesthetics and phonetics is essential in assessing restorability of remaining dentition.
- The determination of volume of soft tissue support required for proper development of facial profile should begin with mock-up prostheses without soft tissue elements in order to accurately evaluate the need for soft tissue support.

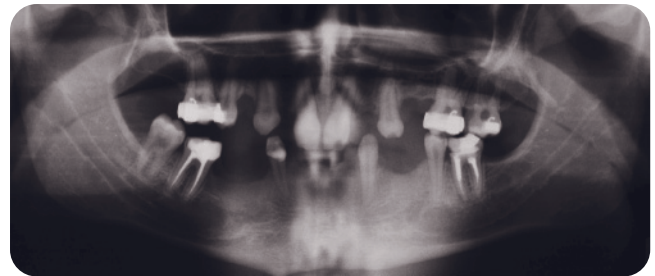


Figure 7: Panoramic radiograph.

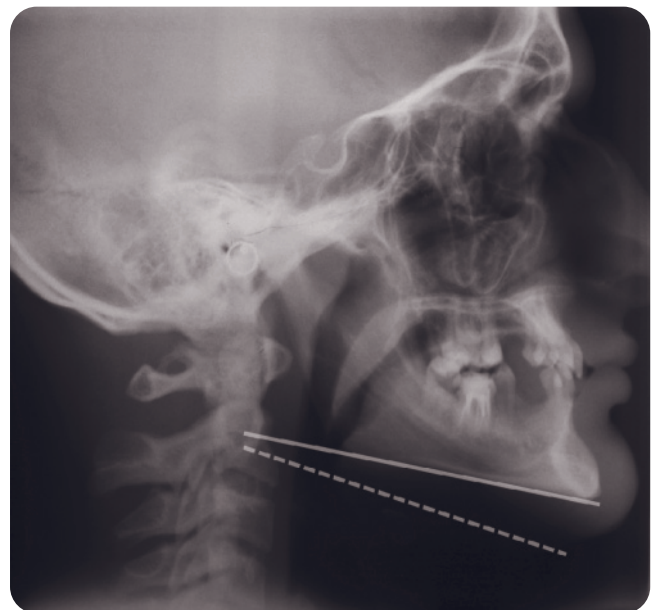

Figure 8: Cephalometric radiograph (lateral view).

CASE 10

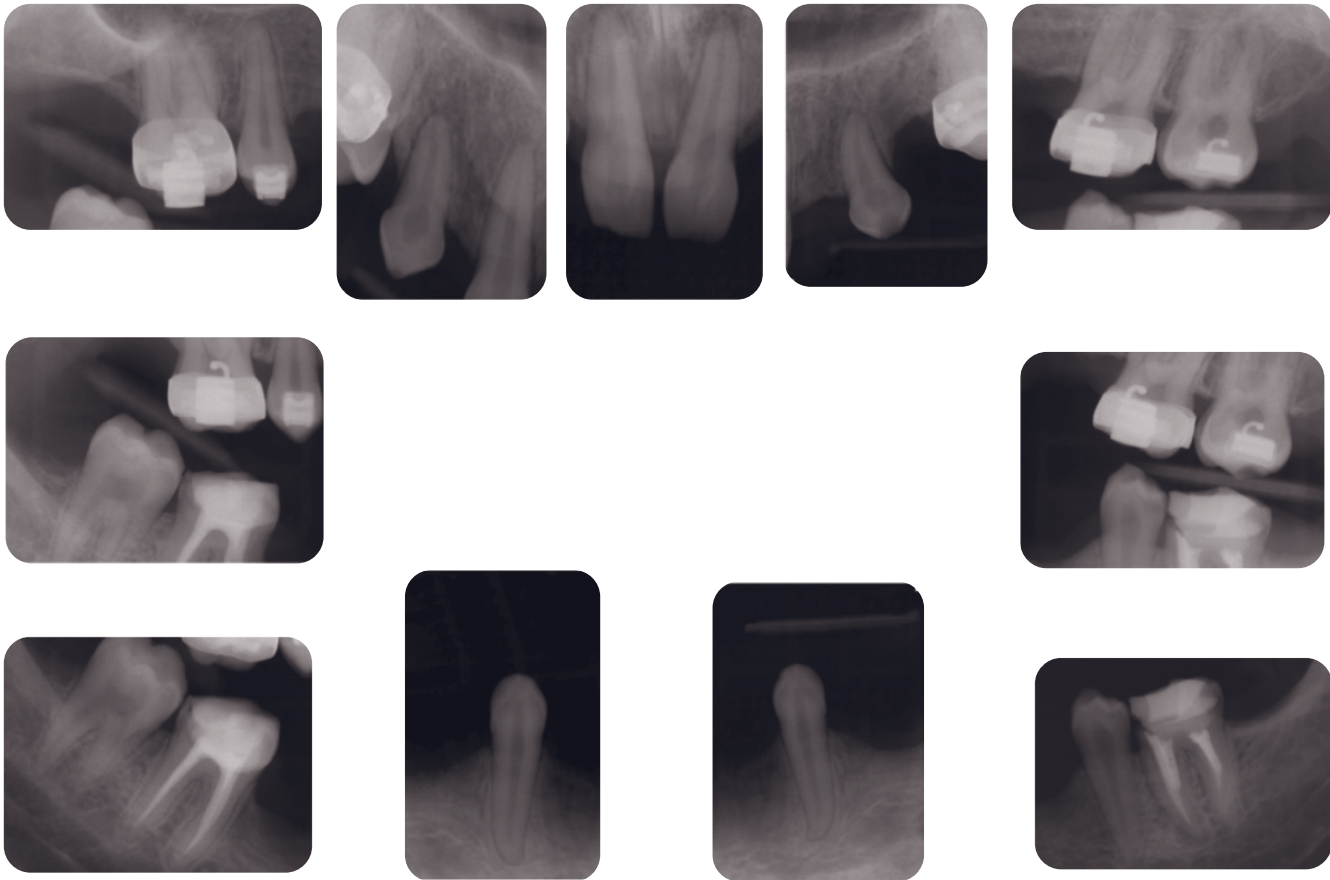
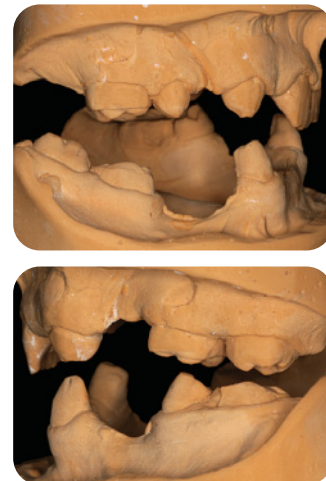


Figure 9: Full mouth series radiographs.

- Adult ectodermal dysplasia patients with no previous dental treatment often result in excessive loss of vertical dimension of occlusion with excessive interarch space. Consequently, the use of fixed prostheses is not feasible because of the poor crown/prosthesis-to-root ratios (Pigno, Blackman et al. 1996). Therefore, treatment approaches, including removable prostheses with or without involvements of implants, are indicated to restore function, facial form, and aesthetics. Such treatment may include the use of overdentures and/or overlay removable partial dentures utilizing the existing dentition to preserve alveolar bone height (Crum 1980).
- The involvement of a prosthodontic team prior to initiating orthodontic and/or surgical treatment is important when determining the need for preprosthetic procedures.



Figures 10 and 11: Diagnostic casts at the desired vertical dimension.

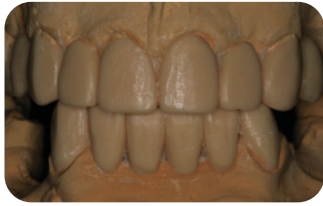

Figure 12: Diagnostic wax-up.

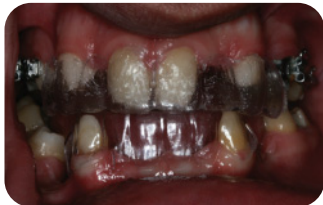

Figure 13: Vacuum-formed matrix of the diagnostic wax-up.

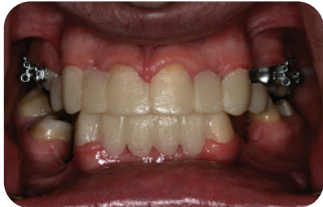

Figure 14: Mock-up prostheses made with vacuum-formed matrix.

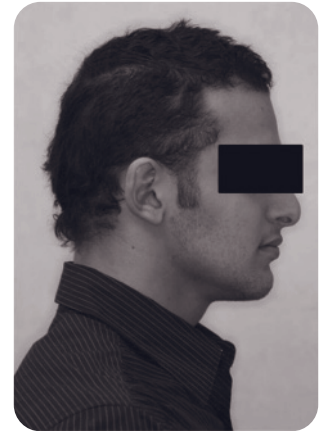
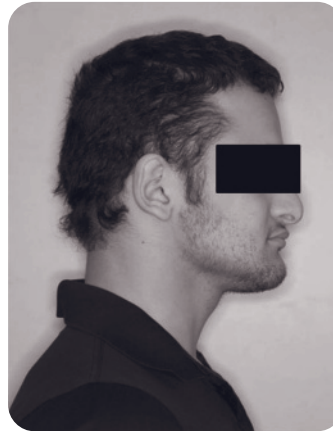
Figure 15: Before and after restoration of vertical dimension of occlusion.

Questions

1. In hypohidrotic ectodermal dysplasia patients,

- A. Sweat glands are absent or significantly decreased.
- B. Sweat glands are normal.
- C. Sensitivity to cold is displayed.
- D. X-linked dominant trait is present.

2. The growth analysis of a patient with hypohidrotic ectodermal dysplasia shows

- A. Maxillary growth being less than mandibular growth in the sagittal direction
- B. Class III skeletal relation
- C. Low angle vertical growth pattern
- D. All of the above

3. The use of dental implants for the rehabilitation of prepubertal patients is shown to have a positive effect on the growth of the craniofacial complex.

- A. True
- B. False

4. What would be the limiting factor(s) for the habilitation of the maxilla with dental implant in patients with ectodermal dysplasia?

- A. Inadequate bone volume
- B. Inadequate blood supply
- C. Excessive interarch space resulting in compromised implant-to-prosthesis ratio
- D. All of the above

5. What is a minimally acceptable crown/prosthesis-to-root ratio?

- A. 1:2
- B. 1:1
- C. 1:3
- D. 1:4

6. Initiation of dental treatment for a child with ectodermal dysplasia should begin

- A. Preferably before the child begins school
- B. At age of 16–17
- C. After the completion of jaw growth
- D. At birth

7. In a study of psychosocial effects of osseointegrated dental implants, psychosocial well-being of patients after the implant therapy was shown to have

- A. Clinically significant improvements on self-esteem
- B. Clinically significant improvements on psychological distress
- C. No effect on psychosocial well-being
- D. A negative effect on self-esteem

8. Outcome assessment of implant therapy in patients with ectodermal dysplasia reported that

- A. There was a high rate of postoperative complications.
- B. Types of reported complications by patients were “infection” around implants and prosthetic complications.
- C. Regardless of the patient-reported complications, more than 90% of patients were satisfied with the implant therapy provided.
- D. All of the above

ANSWERS

1. A (Guckes, Scurria et al. 2002)

2. D (Alcan, Basa et al. 2006)

3. B (Guckes, Scurria et al. 2002)

4. D (Guckes, Roberts et al. 1998; Guckes, Scurria et al. 2002)

8. D (Stanford, Guckes et al. 2008)

7. B (Kent and Johns 1991)

6. A (Nowak 1988; Till and Marques 1992)

5. B (Reynolds 1968; Brown 1973)

The authors would like to acknowledge and thank Dr. Aaron Schwartzman for clinical case photographs and treatment performed at New York University College of Dentistry.

References

- Alcan, T., S. Basa et al. (2006). "Growth analysis of a patient with ectodermal dysplasia treated with endosseous implants: 6-year follow-up." *J Oral Rehabil* 33(3): 175–182.
- Brown, M. H. (1973). "Causes and prevention of fixed prosthodontic failure." *J Prosthet Dent* 30(4): 617–622.
- Crum, R. J. (1980). Rationale for the retention of teeth for overdentures. *Overdenture 2nd ed.* A. A. Brewer, Morrow, R. M., St Louis, Mosby: 3–11.
- Guckes, A. D., M. W. Roberts et al. (1998). "Pattern of permanent teeth present in individuals with ectodermal dysplasia and severe hypodontia suggests treatment with dental implants." *Pediatr Dent* 20(4): 278–280.
- Guckes, A. D., M. S. Scurria et al. (2002). "Prospective clinical trial of dental implants in persons with ectodermal dysplasia." *J Prosthet Dent* 88(1): 21–25.
- Kent, G. and R. Johns (1991). "Controlled longitudinal study on the psychological effects of osseointegrated dental implants." *Int J Oral Maxillofac Implants* 6(4): 470–474.
- Nowak, A. J. (1988). "Dental treatment for patients with ectodermal dysplasias." *Birth Defects Orig Artic Ser* 24(2): 243–252.
- Pigno, M. A., R. B. Blackman et al. (1996). "Prosthodontic management of ectodermal dysplasia: a review of the literature." *J Prosthet Dent* 76(5): 541–545.
- Reynolds, J. M. (1968). "Abutment selection for fixed prosthodontics." *J Prosthet Dent* 19(5): 483–488.
- Stanford, C. M., A. Guckes et al. (2008). "Perceptions of outcomes of implant therapy in patients with ectodermal dysplasia syndromes." *Int J Prosthodont* 21(3): 195–200.
- Till, M. J. and A. P. Marques (1992). "Ectodermal dysplasia: treatment considerations and case reports." *Northwest Dent* 71(3): 25–28.

WWW.HIGHDENT.IR

همیار دندانسازان و دندانپزشکان

Case 11

Case 11

Management of a fractured central incisor I—mild

A common case of a fractured central incisor requiring a conservative (minimally invasive) Class IV partial porcelain laminate veneer is presented.

CASE STORY

A 23-year-old female presents to the dental office with a chief complaint of: "I chipped my front tooth and need it fixed." She had a bonded restoration initially placed 4 years ago and replaced once, due to discoloration of the composite resin restoration. The patient reports that the restoration broke while eating cereal. She has inquired about "new materials" seeking a more "natural look." For more information regarding anterior restorations, refer to Cases 12–15.

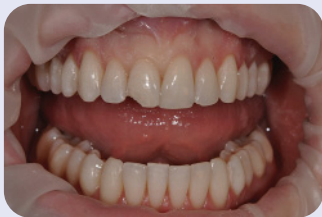

Figure 1: Pretreatment view.

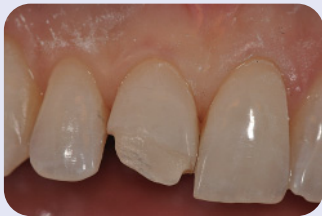

Figure 2: Prepared right central incisor (8).

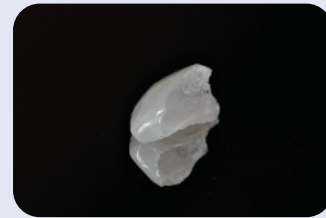

Figure 3: Porcelain laminate veneer.

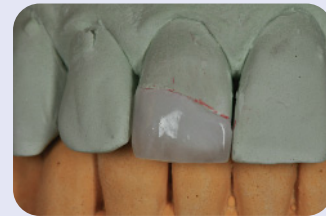

Figure 4: Porcelain laminate veneer on the master cast.

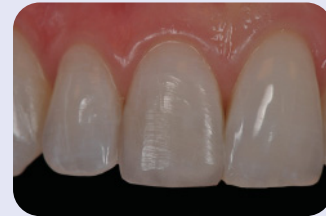

Figure 5: Porcelain laminate veneer post cementation.

LEARNING GOALS AND OBJECTIVES

- Provide an aesthetic restoration using minimally invasive techniques.
- Discuss color matching
- Restore form, function, and aesthetics
- Care and maintenance for a porcelain laminate veneer (PLV)

Medical History

- Herpes labialis, since the age of 19

Dental History

- Good oral hygiene
- No restorative needs other than what is presented with right central incisor (8)
- Low caries index

Medications and Allergies

- Acyclovir as needed during the prodromal stage of a herpetic outbreak
- No known drug allergies

Review of Systems

- Vital signs:
 - Blood pressure: 120/80
 - Heart rate: 70 beats/minute
 - Respiration rate: 16 breaths/minute

Social History

- Smoking: never smoked
- Alcohol: social drinker—"an occasional glass of wine"
- Recreational drugs: denies having ever used them

Extraoral Examination

- No significant findings

Soft Tissue Examination

- No significant findings

Clinical Findings/Problem List

- Class IV fracture of the maxillary right central incisor (8)
- Anterior aesthetics due to failed resin restoration on maxillary right central incisor (8)

Diagnosis

- Class IV dental fracture of maxillary right central incisor (8)

Clinical Decision-Making Determining Factors

- It is often preferable to provide an aesthetic result using minimally invasive techniques. The current evidence is that the veneered porcelain etched to intact and prepared enamel offers the advantages of increased strength, color stability, and aesthetics as compared to composite veneers (Garber 1989; Hui, Williams et al. 1991; Nordbo, Rygh-Thoresen et al. 1994; Zarone).
- The challenging aspects of anterior restorations are an accurate porcelain shade selection and communication of this critical color matching to the technician. There are many factors that affect shade selection. It has been described that the hydration of teeth can have a major impact on the shade selected. It typically takes natural teeth 10 minutes to dehydrate with a perceptible change in shade and up to 2 hours to rehydrate. It is therefore critical that shade selection is performed at the outset of treatment and prior to any tooth preparation or dehydration (Riley, Sanderson et al. 1986).
- The other factors that affect the shade selection include the presence of ambient daylight (Exner 1991) and shade selection technique. Newer data indicate that the spectrophotometric methods have a greater potential of accuracy than visual methods (Judeh and Al-Wahadni 2009). The use of digital photography and computers also indicate a greater accuracy over visual techniques (Schropp 2009). However, all available techniques have limitations.
- Postinsertion care and maintenance for porcelain laminate veneers is a critical part of the success of the restoration. One way to protect/maintain the integrity of these PLV restorations has been with the use of an occlusal guard. The literature supports that postinsertion maintenance is the key to preservation and longevity of anterior restorations. This includes proper hygiene, including proper toothbrushing techniques, use of dental floss, and oral rinses (Barham, Mayhew et al. 1983; Strassler and Nathanson 1989).
- It is recommended that the occlusal contacts remain on natural tooth structure and not on the PLV or the marginal interface with the natural tooth (Ibsen and Yu 1989).

Questions

1. The patient wishes to “bleach” her teeth prior to the restoration of her central incisor. It is recommended that she whitens with a prescription 10% carbamide peroxide whitening solution for 2–4 weeks using custom fabricated trays. How long after this treatment should you wait for the shade to stabilize before you begin preparation, impression, and shade selection?

- A. 2 days
- B. 2 months
- C. 2 weeks
- D. 1 week

2. You have discussed the options of full coverage (crown), partial coverage (PLV), or direct placed composite resin with your patient. What is an advantage of using a porcelain veneer over the direct placement of composite?

- A. Porcelain’s optic properties are closer to natural tooth structure than composite resin.
- B. Composite resin is more color stable.
- C. Cost
- D. PLV is a single-visit procedure.

3. To achieve optimum aesthetics, a bevel can be placed at the finish line to

- A. Increase surface bonding area.
- B. Provide a blend zone.
- C. Provide increased strength.
- D. (A) and (B)

4. Which of the following steps is suggested when planning for PLV?

- A. A diagnostic wax-up
- B. Mount the casts
- C. Shade selection
- D. All of the above

5. Which of the following occlusal relationships may pose a contraindication for placement of a PLV restoration?

- A. Class I occlusion
- B. Edge-to-edge anterior tooth relationship
- C. Class II occlusion
- D. Anterior open bite

6. To assure proper lingual restorative contour, which phonetic sound(s) will best help determine the adequate space necessary for proper speech?

- A. “m”
- B. “f” and “v”
- C. “s”
- D. All of the above

7. When designing a smile, what are some of the extraoral references to be considered and evaluated?

- A. Facial midline
- B. Soft tissue symmetry
- C. Dental midline
- D. Amount of gingival display/smile line

8. What is the proper sequence of order when bonding the PLV to tooth structure?

- A. Apply silane to the veneer and tooth prior to bonding the PLV.
- B. Apply silane to the internal surface of the veneer, add bonding resin to the internal surface of the veneer, and then proceed with the bonding procedure.
- C. Pumice the internal surface of the PLV.
- D. All are valid sequences.

9. Which of the following is a possible cause of porcelain fracture?

- A. Occlusion
- B. Contamination during the bonding process
- C. Inadequate porcelain thickness
- D. All are correct.

10. To protect the PLV restorations, which of the following is true:

- A. Maintain good oral hygiene and wear a night guard.
- B. Avoid excessive occlusal forces.
- C. Occlusal contacts should not be placed on the restoration and natural tooth structure interface.
- D. All of the above

ANSWERS

1. D (Haywood 1997)

2. A (Strassler 2007)

3. D (Bichacho 1995; Van Meerbeek 2008)

4. D (Barreto, Shiu et al. 1986)

5. B (Bello and Jarvis 1997)

6. C (Pound 1977)

7. A (Denehy 2000; Dietschi 2008)

8. B (Sorensen, Kang et al. 1991)

9. D (Stacey 1993; Magne and Belser 2003)

10. D (Barghi and McAlister 1998; Calamia and Calamia 2007)

The authors would like to acknowledge and thank Dr. Alberto Ambriz for clinical case photographs and treatment performed at New York University College of Dentistry.

References

- Barghi, N. and E. McAlister (1998). "Porcelain for veneers." *J Esthet Dent* 10(4): 191–197.
- Barham, T. P., Jr., R. B. Mayhew et al. (1983). "Gingival response to laminate veneer restorations." *Oper Dent* 8(4): 122–129.
- Barreto, M. T., A. Shiu et al. (1986). "Anterior porcelain laminate veneers: clinical and laboratory procedures." *Quintessence Dent Technol* 10(8): 493–499.
- Bello, A. and R. H. Jarvis (1997). "A review of esthetic alternatives for the restoration of anterior teeth." *J Prosthet Dent* 78(5): 437–440.
- Bichacho, N. (1995). "Porcelain laminates: integrated concepts in treating diverse aesthetic defects." *Pract Periodontics Aesthet Dent* 7(3): 13–23; quiz 23.
- Calamia, J. R. and C. S. Calamia (2007). "Porcelain laminate veneers: reasons for 25 years of success." *Dent Clin North Am* 51(2): 399–417, ix.
- Denehy, G. E. (2000). "A direct approach to restore anterior teeth." *Am J Dent* 13(Spec No): 55D–59D.
- Dietschi, D. (2008). "Optimizing smile composition and esthetics with resin composites and other conservative esthetic procedures." *Eur J Esthet Dent* 3(1): 14–29.
- Exner, H. V. (1991). "Predictability of color matching and the possibilities for enhancement of ceramic laminate veneers." *J Prosthet Dent* 65(5): 619–622.
- Garber, D. A. (1989). "Direct composite veneers versus etched porcelain laminate veneers." *Dent Clin North Am* 33(2): 301–304.
- Haywood, V. B. (1997). "Nightguard vital bleaching: current concepts and research." *Journal of the American Dental Association* 128 Suppl: 19S–25S.
- Hui, K. K., B. Williams et al. (1991). "A comparative assessment of the strengths of porcelain veneers for incisor teeth dependent on their design characteristics." *Br Dent J* 171(2): 51–55.
- Ibsen, R. L. and X. Y. Yu (1989). "Establishing cuspid-guided occlusion with bonded porcelain." *J Esthet Dent* 1(3): 80–85.
- Judeh, A. and A. Al-Wahadni (2009). "A comparison between conventional visual and spectrophotometric methods for shade selection." *Quintessence Int* 40(9): e69–79.
- Magne, P. and U. C. Belser (2003). "Porcelain versus composite inlays/onlays: effects of mechanical loads on stress distribution, adhesion, and crown flexure." *Int J Periodontics Restorative Dent* 23(6): 543–555.
- Nordbo, H., N. Rygh-Thoresen et al. (1994). "Clinical performance of porcelain laminate veneers without incisal overlapping: 3-year results." *J Dent* 22(6): 342–345.
- Pound, E. (1977). "Let /S/ be your guide." *J Prosthet Dent* 38(5): 482–489.

- Riley, E. J., I. R. Sanderson et al. (1986). "Shade determination, communication, and realization: a novel approach." *Quintessence Int* 17(11): 739–744.
- Schropp, L. (2009). "Shade matching assisted by digital photography and computer software." *J Prosthodont* 18(3): 235–241.
- Sorensen, J. A., S. K. Kang et al. (1991). "Porcelain-composite interface microleakage with various porcelain surface treatments." *Dent Mater* 7(2): 118–123.
- Stacey, G. D. (1993). "A shear stress analysis of the bonding of porcelain veneers to enamel." *J Prosthet Dent* 70(5): 395–402.
- Strassler, H. E. (2007). "Minimally invasive porcelain veneers: indications for a conservative esthetic dentistry treatment modality." *Gen Dent* 55(7): 686–94.
- Strassler, H. E. and D. Nathanson (1989). "Clinical evaluation of etched porcelain veneers over a period of 18 to 42 months." *J Esthet Dent* 1(1): 21–28.
- Van Meerbeek, B. (2008). "Mechanisms of resin adhesion: Dentin and enamel bonding." *Func Restor Dent* 2(1): 18–25.
- Zarone, F., E. Epifania et al. (2006). "Dynamometric assessment of the mechanical resistance of porcelain veneers related to tooth preparation: a comparison between two techniques." *J Prosthet Dent* 95(5): 354–363.

Case 12

Case 12

Management of a fractured central incisor II—moderate

Management of a fractured central incisor requiring a conservative (minimally invasive) Class IV partial porcelain laminate veneer is presented.

CASE STORY

A 26-year-old male presents to the dental office with the following chief complaint: "I broke my front tooth and need it fixed." He had a bonded restoration placed at age 14 that has since been replaced twice, but it broke off when he accidentally bit on his fork. He is seeking "a better material," and has inquired about a material that is strong and would give him a more "natural look."

For more information regarding anterior restorations, refer to Cases 11–15.

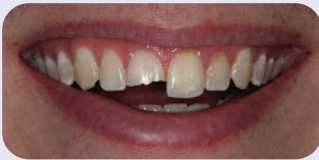

Figure 1: Preoperative class IV fracture maxillary right central incisor (8).

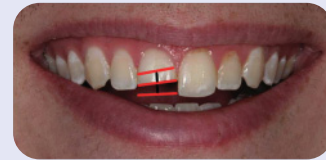

Figure 2: Bonding surface should be equal to or exceed the amount of tooth structure being replaced.

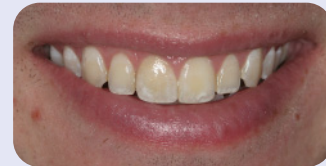

Figure 3: Final restoration.

LEARNING GOALS AND OBJECTIVES

- Provide an aesthetic result using minimally invasive techniques.
- Color matching
- Restore form, function, and aesthetics.
- Care and maintenance for a porcelain laminate veneer (PLV)

Medical History

- No significant findings

Dental History

- Sporadic dental visits that the patient blames on his busy work schedule

- Oral hygiene is fair.
- Caries index is low.

Medications and Allergies

- Inhaler used for seasonal allergies (as needed)
- Food allergy to eggs and egg products

Review of Systems

- Vital signs:
 - Blood pressure: 120/78
 - Heart rate: 68 beats/minute
 - Respiration rate: 18 breaths/minute

Social History

- Smoking: no history
- Alcohol: patient is a social drinker—approximately 6–8 beers per week
- Recreational drugs: No history

Significant Extraoral Findings

- No significant findings

Significant Soft Tissue Findings

- Lips: appear dry, symmetrical, and normal shape, size, and color

Clinical Findings/Problem List

- Anterior aesthetics, due to class IV fracture
- Critical color matching in a highly visible oral area
- To restore form, function, and aesthetics

Diagnosis

- Class IV fracture of the maxillary central incisor (8)
- Discoloration of enamel due to hypocalcification spots

Clinical Decision-Making Determining Factors

- There is often a need to provide an aesthetic result using minimally invasive techniques and contemporary restorative materials. The current evidence is that the veneered porcelain etched to intact and prepared enamel offers the advantages of increased strength, color stability, and aesthetics as compared to composite veneers (Strassler 2007; Spear and Holloway 2008).
- Consider the optical affects of metamerism during the critical color matching phase of treatment.

Metamerism occurs when two samples appear identical under one set of viewing conditions, but not under another set of conditions. This is very relevant during the shade selection process—because under one light source the shade may appear to be a match, and yet under a different light environment it may appear mismatched. Therefore it is recommended to select the shade of the restorative material under a corrective light environment (O'Brien 1985; Kim, Lee et al. 2007).

- Several other factors can influence shade selection and these should be completely understood, especially during critical color matching in a highly visible area (Dagg, O'Connell et al. 2004). Of the many factors described in the literature that affect tooth color and therefore restoration color selection, hydration of teeth can impact the shade selected. It typically takes natural teeth about 10 minutes to dehydrate with a perceptible change in shade and up to 2 hours to rehydrate. It is therefore critical that shade selection is performed at the outset of treatment and prior to any tooth preparation (Riley, Sanderson et al. 1986). Additional factors that affect the shade selection are the presence of ambient daylight (Exner 1991) and shade selection technique. Newer data indicate that the spectrophotometric methods have a greater potential of accuracy than visual methods (Judeh and Al-Wahadni 2009). The use of digital photography and computers also indicates a greater accuracy over visual techniques (Wee, Kang et al. 2005; Schropp 2009).
- Postinsertion care and maintenance for a PLV with a mouth guard is a critical part of the success of the restoration. One way to protect/maintain the integrity of these PLV restorations has been with the use of an occlusal/mouth guard. Maintenance includes proper hygiene; to include proper toothbrushing techniques, use of dental floss, and oral rinses (Strassler and Nathanson 1989).
- Patient selection and studying the occlusal pattern of the patient are also critical for longevity of the PLV restoration. The occlusal contacts should remain on natural tooth structure and not the veneer or at the margin interface between natural tooth structure and veneer (Ibsen and Yu 1989; Van Meerbeek 2008).

Questions

1. If this patient is interested in whitening his teeth, which of the following statements is most accurate?

- A. Tooth whitening should occur only after the tooth is restored.
- B. Tooth whitening should occur prior to final cementation of the restoration.
- C. Tooth whitening should occur first; then wait a week for color stabilization; then choose the shade for the restoration.
- D. Tooth whitening is a contraindicated dental therapy when a bonded restoration is planned.

2. The ideal condition during shade selection includes

- A. Choosing final shades on sunny days only
- B. Using only a composite shade guide
- C. Using a corrective light source that burns at 5,500 degrees K
- D. Using a corrective light source that burns at 3,500 degrees K

3. Which of the following statements describes the phenomenon of metamerism?

- A. The shade of porcelain selected will appear the same under different light sources.
- B. The shade of porcelain selected will appear different in natural daylight versus under a fluorescent light source.
- C. The proper color-corrected light source should be blue.
- D. The light source should burn at 5,000 degrees K.

4. The aesthetic success of treatment depends on the correct diagnosis, a well-thought-out treatment plan that is sequenced properly, and sound clinical and laboratory procedures. Which of the following statements further supports the success of the case?

- A. Diagnostic wax-up
- B. Proper postoperative follow up
- C. Healthy gingival tissues
- D. Conservative preparation of the tooth
- E. All contribute to the success of the case.

5. The internal surface of the porcelain laminate veneer usually comes back from the laboratory with an internal etch. Application of silane agent to the internal surface of the veneer serves which purpose?

- A. It is a cement used only for veneers.
- B. It is a coupler and aids in the bonding process.
- C. It protects against open margins.
- D. It preserves the porcelain shade.

6. In the fracture of a clinical crown that does not involve the pulp, the pulp most often survives without further complications. The following statement best explains this:

- A. The damage is to the periodontal ligament only.
- B. When the tooth fractures, the force is dissipated and is not transmitted to the root or periodontal ligament.
- C. The pulp tissue regenerates posttrauma.
- D. The bone absorbs all the force during trauma.

7. The cement shade can influence the color of the final porcelain laminate veneer for the maxillary central incisor (8) restoration. What is the most conservative method to minimize this perceptible color difference?

- A. Use an opaque luting resin bonding system.
- B. Use a luting resin system that has "try-in" pastes to help confirm the accuracy of the shade prior to final cementation.
- C. Always use an opacous type of porcelain.
- D. Veneer more than just the one maxillary central incisor (8) to guarantee that all anterior teeth match.

8. Occlusion is an important factor to evaluate when planning to restore in the anterior sextant with PLVs. Forces of occlusion may add additional stress on the tooth and the restoration. Which of the following occlusal relationships may pose a contraindication?

- A. Class I occlusion
- B. Anterior open bite
- C. Edge-to-edge anterior tooth relationship
- D. Class III occlusion

9. In general, PLVs can be used for all of the following *except*

- A. To change the shape of a tooth
- B. To change the shade of teeth
- C. When greater than 60% of tooth is fractured
- D. To replace an existing composite veneer

10. Which of the following is the least likely cause of porcelain fracture?

- A. Occlusion
- B. Inadequate porcelain thickness
- C. Brand of porcelain
- D. Undercut in the preparation

ANSWERS

- 1. C (Haywood 1997)
- 2. C (O'Brien 1985; Kim, Lee et al. 2007)
- 3. B (Kim, Lee et al. 2007)
- 4. E (Gurel 2003; Gurel 2007)
- 5. B (Sorensen, Kang et al. 1991; Barghi 2000)

- 6. B (Abou-Rass 1982)
- 7. B (Bello and Jarvis 1997; Conrad, Seong et al. 2007)
- 8. C (Stacey 1993)
- 9. C (Bichacho 1995)
- 10. C (Stacey 1993)

The authors would like to acknowledge and thank Dr. Ryan Sellinger for clinical case photographs and treatment performed.

References

Abou-Rass, M. (1982). "The stressed pulp condition: an endodontic-restorative diagnostic concept." *J Prosthet Dent* 48(3): 264–267.

Barghi, N. (2000). "To silanate or not to silanate: making a clinical decision." *Compend Contin Educ Dent* 21(8): 659–662, 664; quiz 666.

Bello, A. and R. H. Jarvis (1997). "A review of esthetic alternatives for the restoration of anterior teeth." *J Prosthet Dent* 78(5): 437–440.

Bichacho, N. (1995). "Porcelain laminates: integrated concepts in treating diverse aesthetic defects." *Pract Periodontics Aesthet Dent* 7(3): 13–23; quiz 23.

- Conrad, H. J., W. J. Seong et al. (2007). "Current ceramic materials and systems with clinical recommendations: a systematic review." *J Prosthet Dent* 98(5): 389–404.
- Dagg, H., B. O'Connell et al. (2004). "The influence of some different factors on the accuracy of shade selection." *J Oral Rehabil* 31(9): 900–904.
- Exner, H. V. (1991). "Predictability of color matching and the possibilities for enhancement of ceramic laminate veneers." *J Prosthet Dent* 65(5): 619–622.
- Gurel, G. (2003). "Predictable, precise, and repeatable tooth preparation for porcelain laminate veneers." *Pract Proced Aesthet Dent* 15(1): 17–24; quiz 26.
- Gurel, G. (2007). "Porcelain laminate veneers: minimal tooth preparation by design." *Dent Clin North Am* 51(2): 419–431, ix.
- Haywood, V. B. (1997). "Nightguard vital bleaching: current concepts and research." *JADA* 128 Suppl: 19S–25S.
- Ibsen, R. L. and X. Y. Yu (1989). "Establishing cuspid-guided occlusion with bonded porcelain." *J Esthet Dent* 1(3): 80–85.
- Judeh, A. and A. Al-Wahadni (2009). "A comparison between conventional visual and spectrophotometric methods for shade selection." *Quintessence Int* 40(9): e69–79.
- Kim, S. H., Y. K. Lee et al. (2007). "Metameric effect between dental porcelain and porcelain repairing resin composite." *Dent Mater* 23(3): 374–379.
- O'Brien, W. J. (1985). "Double layer effect and other optical phenomena related to esthetics." *Dent Clin North Am* 29(4): 667–672.
- Riley, E. J., I. R. Sanderson et al. (1986). "Shade determination, communication, and realization: a novel approach." *Quintessence Int* 17(11): 739–744.
- Schropp, L. (2009). "Shade matching assisted by digital photography and computer software." *J Prosthodont* 18(3): 235–241.
- Sorensen, J. A., S. K. Kang et al. (1991). "Porcelain-composite interface microleakage with various porcelain surface treatments." *Dent Mater* 7(2): 118–123.
- Spear, F. and J. Holloway (2008). "Which all-ceramic system is optimal for anterior esthetics?" *Journal of the American Dental Association* 139 Suppl: 19S–24S.
- Stacey, G. D. (1993). "A shear stress analysis of the bonding of porcelain veneers to enamel." *J Prosthet Dent* 70(5): 395–402.
- Strassler, H. E. (2007). "Minimally invasive porcelain veneers: indications for a conservative esthetic dentistry treatment modality." *Gen Dent* 55(7): 686–94.
- Strassler, H. E. and D. Nathanson (1989). "Clinical evaluation of etched porcelain veneers over a period of 18 to 42 months." *J Esthet Dent* 1(1): 21–28.
- Van Meerbeek, B. (2008). "Mechanisms of resin adhesion: Dentin and enamel bonding." *Func Restor Dent* 2(1): 18–25.
- Wee, A. G., E. Y. Kang et al. (2005). "Clinical color match of porcelain visual shade-matching systems." *J Esthet Restor Dent* 17(6): 351–357; discussion 358.

Case 13

Case 13

Management of a fractured central incisor III—severe

A case of traumatic multiple anterior teeth fractures, involving a lateral incisor and a central incisor requiring

endodontics, dowel/core buildup, and all-ceramic crowns is presented.

CASE STORY

A 30-year-old male presents to the prosthodontist's office with the following chief complaint: "I was in a fight and got my two front teeth broken and need them fixed." He was referred to the prosthodontist after his primary/general dentist performed root

endodontic treatment on both the lateral incisor (7) and the central incisor (8). He had had regular dental treatment since childhood. His oral hygiene is fair and his caries index is low.

For more information regarding anterior restorations, refer to Cases 11–15.

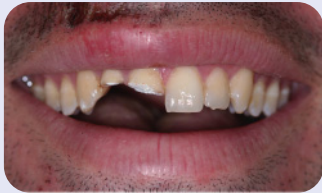

Figure 1: Pretreatment fractured right lateral and central incisors (7 and 8).

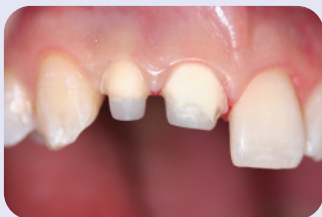

Figure 2: Core buildup and preparation of fractured teeth; finish line is a chamfer.

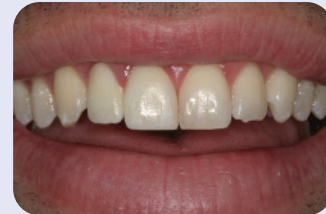

Figure 3: Provisional restorations.

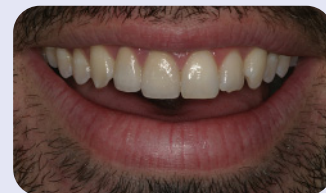

Figure 4: Final restorations.

LEARNING GOALS AND OBJECTIVES

- Provide an aesthetic result using contemporary restorative materials and techniques.
- Critical color matching
- Discussion of tooth whitening techniques
- Care and maintenance for all-ceramic, full-coverage restorations

Medical History

- Peptic ulcer disease (PUD) treated and in remission

Dental History

- Fair to good oral hygiene
- Routine nonsignificant dental treatment
- Low caries index

Medications and Allergies

- Antacid-Mylanta (as needed)
- Multivitamin

Review of Systems

- Vital signs:
 - Blood pressure: 110/78
 - Heart rate: 68 beats/minute
 - Respiration rate: 18 breaths/minute

Social History

- Smoking: quit smoking 6 months ago—1 pack/day history
- Alcohol: drinks alcohol, 3–5 beers weekly

Significant Extraoral Findings

- No significant findings

Significant Soft Tissue Findings

- Lips: healing laceration above the area of 7 and 8

Clinical Findings/Problem List

- Anterior aesthetics
- Coronal fractures of the right lateral and central incisors (7 and 8)
- Long-term discoloration of endodontically treated teeth

Diagnosis

- Nonvital and fractured right lateral and central incisors (7 and 8)

Clinical Decision-Making Determining Factors

- In a highly visible area—"The Aesthetic Zone"—the literature points to the following factors in the treatment planning phase of dental reconstruction: preparation design, location of the finish line, color matching of tooth structure to the shade of porcelain, the optical affects of porcelain thickness and the optical effects that may occur as a result of the luting cement. It is especially important to understand the optical effects of the luting agent chosen when cementing all-ceramic partial or full-coverage restorations (Koutayas, Kakaboura et al. 2003; Federlin, Schmidt et al. 2004; Chang, Da Silva et al. 2009; Terzioglu, Yilmaz et al. 2009).
- Consideration of future discoloration of endodontically treated teeth and available tooth whitening techniques to be performed, prior to final color matching of all ceramic crowns and/ or porcelain laminate veneers is a factor that has to be considered in all aesthetic restorations.
- The causes for the discoloration can vary in etiology, clinical presentation, localization, and severity. It can be defined as being extrinsic or intrinsic on the basis of clinical presentation and etiology. Different whitening materials and techniques to lighten discolored endodontically treated teeth have been described in the dental literature. An effective initial method to address intrinsic staining is commonly known as a "walking" whitening technique. In this method, the endodontic treatment should be completed first; and a cervical seal, usually with a glass ionomer cement, must be established. The thermocatalytic technique involves placement of a whitening agent (superoxyl in 30–35% concentration, H₂O₂ and heat) into the pulp chamber and then application of heat using a heated metal instrument. Additional whitening agent is then placed on a cotton pellet and left in the core structure of the tooth area for 2–7 days. External whitening of endodontically treated teeth with an in-office technique requires the use of a higher hydrogen peroxide concentration gel. It might be a supplement to the walking whitening technique, and/or at home tray whitening technique. The prognosis of whitened nonvital teeth varies with regard to color stability, so it is important to consider the possible future aesthetic complications. These complications include further discoloration that may become visible through all-ceramic restorations.
- When a patient desires to whiten/lighten their natural dentition, tooth whitening of the neighboring

teeth should be done prior to final shade selection of the restorative material (porcelain or composite). Sufficient postwhitening time should be allotted to assure color stabilization. Proper sequencing of treatment is therefore key (Haywood 1997; Carrillo, Arredondo Trevino et al. 1998; Attin, Paque et al. 2003; Ishikawa-Nagai, Terui et al. 2004; Dietschi 2006; Plotino, Buono et al. 2008).

- Ceramic shade selection and critical color matching can provide challenges. Natural teeth vary greatly in color and form and light transmission. It is only possible to replicate in porcelain/ceramic what has been distinguished, understood, and communicated in the shade-matching process of the natural dentition.

- The use of porcelain visual shade-matching systems may result in a clinically acceptable color match of the final restoration(s). Color-match evaluation of final restorations should be accomplished through a consensus between the dentist, the patient, and the dental technician where possible (Wee, Monaghan et al. 2002; Wee, Kang et al. 2005; Da Silva, Park et al. 2008).
- In any dental restoration or reconstruction, considerations to form and function are as vital as the aesthetic result. Therefore, routine evaluation of the occlusion prior to treatment, using study casts, is recommended. Occlusion has been determined to be a key factor in the longevity of these restorations (Ibsen and Yu 1989; Vence 2007).

Questions

1. After emergency patient care, which of the following treatment sequences is recommended?

- Mount study casts, diagnostic wax-up, preparation, and provisionalize
- Preparation and provisionalization only
- Crown-lengthening procedure, preparation, and provisionalization
- Crown-lengthening procedure, endodontics, and then preparation and provisionalization

2. The following are aesthetic dowel options except

- Alumina ceramic post
- Glass (Empress) post
- Cast metal post
- Zirconia ceramic post

3. When planning an aesthetic reconstruction, the following options can aid in creating optimal aesthetics:

- Diagnostic wax-up
- Computer imaging
- Studying old photos of the patient
- All of the above

4. In a fractured central incisor, if the remaining tooth structure is insufficient to adequately retain a restoration:

- Use pins to aid in the buildup of the core.
- Prophylactic endodontic treatment should be considered.
- Cut in retention channels.
- No additional treatment is needed.

5. When considering the anterior restoration of nonvital discolored teeth, which of the following techniques can be utilized to lighten the tooth structure prior to choosing the shade of the final restorative material?

- In-office whitening only
- Walking whitening technique, followed by tray-whitening technique
- Covering the tooth with a lighter shade composite
- At-home tooth whitening only

6. In the fracture of a coronal portion of a tooth, the pulp may not be involved and survives without further complications. The following statement best explains this:

- A. The damage is to the periodontal ligament only.
- B. When the crown fractures, the force is dissipated and is not transmitted to the root or periodontal ligament.
- C. The pulp tissue regenerates posttrauma.
- D. The bone absorbs all the force during trauma.

7. The following crown types should be considered when restoring anterior teeth:

- A. All-ceramic crowns
- B. Porcelain fused to metal crowns
- C. Captek crowns
- D. All can be good options.

8. The following item(s) should be considered when treatment planning an anterior restoration *except*

- A. Preparation design, finish line
- B. Shade selection method
- C. Type of ceramic
- D. Type of luting cement
- E. All are vital to the success of the case.

9. Which of the following statements is accurate?

- A. The luting cement can cause a perceptible color difference in the final restoration.
- B. The thickness of the porcelain has no effect on color stability of the restoration.
- C. Cement shades do not affect the shade of the final restoration.
- D. All-ceramic systems share the same optical properties.

10. Proper maintenance of all-ceramic anterior restorations is achieved by:

- A. Wearing an occlusal guard
- B. Maintaining appropriate recall visits
- C. Proper oral hygiene regimen
- D. All are correct.

ANSWERS

- 1. A (Dietsch, Jacoby et al. 2000)
- 2. C (Conrad, Seong et al. 2007)
- 3. D (Bonnard, Hermans et al. 2001; Gianadda 2001)
- 4. B (Dietsch, Duc et al. 2007; Van Meerbeek 2008)
- 5. B (Plotino, Buono et al. 2008)

- 6. B (Abou-Rass 1982)
- 7. D (Bello and Jarvis 1997)
- 8. E (Federlin, Schmidt et al. 2004)
- 9. A (Da Silva, Park et al. 2008)
- 10. D (Andersson, Razzoog et al. 1998; Oden, Andersson et al. 1998)

The authors would like to acknowledge and thank Dr. Ryan Sellinger for clinical case photographs and treatment performed.

References

- Abou-Rass, M. (1982). "The stressed pulp condition: an endodontic-restorative diagnostic concept." *J Prosthet Dent* 48(3): 264–267.
- Andersson, M., M. E. Razzoog et al. (1998). "Procera: a new way to achieve an all-ceramic crown." *Quintessence Int* 29(5): 285–296.
- Attin, T., F. Paque et al. (2003). "Review of the current status of tooth whitening with the walking bleach technique." *Int Endod J* 36(5): 313–329.
- Bello, A. and R. H. Jarvis (1997). "A review of esthetic alternatives for the restoration of anterior teeth." *J Prosthet Dent* 78(5): 437–440.
- Bonnard, P., M. Hermans et al. (2001). "Anterior esthetic rehabilitation on teeth and dental implants optimized with Procera technology: a case report." *J Esthet Restor Dent* 13(3): 163–171.
- Carrillo, A., M. V. Arredondo Trevino et al. (1998). "Simultaneous bleaching of vital teeth and an open-chamber nonvital tooth with 10% carbamide peroxide." *Quintessence Int* 29(10): 643–648.
- Chang, J., J. D. Da Silva et al. (2009). "The optical effect of composite luting cement on all ceramic crowns." *J Dent* 37(12): 937–943.
- Conrad, H. J., W. J. Seong et al. (2007). "Current ceramic materials and systems with clinical recommendations: a systematic review." *J Prosthet Dent* 98(5): 389–404.
- Da Silva, J. D., S. E. Park et al. (2008). "Clinical performance of a newly developed spectrophotometric system on tooth color reproduction." *J Prosthet Dent* 99(5): 361–368.
- Dietschi, D. (2006). "Nonvital bleaching: general considerations and report of two failure cases." *Eur J Esthet Dent* 1(1): 52–61.
- Dietschi, D., O. Duc et al. (2007). "Biomechanical considerations for the restoration of endodontically treated teeth: a systematic review of the literature—Part 1. Composition and micro- and macrostructure alterations." *Quintessence Int* 38(9): 733–743.
- Dietschi, D., T. Jacoby et al. (2000). "Treatment of traumatic injuries in the front teeth: restorative aspects in crown fractures." *Pract Periodontics Aesthet Dent* 12(8): 751–758; quiz 760.
- Federlin, M., S. Schmidt et al. (2004). "Partial ceramic crowns: influence of preparation design and luting material on internal adaptation." *Oper Dent* 29(5): 560–570.
- Gianadda, R. (2001). "Achieving an aesthetic smile design with integrated single- and multi-unit metal-free restorations." *Dent Today* 20(6): 42–46.
- Haywood, V. B. (1997). "Nightguard vital bleaching: current concepts and research." *Journal of the American Dental Association* 128 Suppl: 19S–25S.
- Ibsen, R. L. and X. Y. Yu (1989). "Establishing cuspid-guided occlusion with bonded porcelain." *J Esthet Dent* 1(3): 80–85.
- Ishikawa-Nagai, S., T. Terui et al. (2004). "Comparison of effectiveness of two 10% carbamide peroxide tooth-bleaching systems using spectrophotometric measurements." *J Esthet Restor Dent* 16(6): 368–375.
- Koutayas, S. O., A. Kakaboura et al. (2003). "Colorimetric evaluation of the influence of five different restorative materials on the color of veneered densely sintered alumina." *J Esthet Restor Dent* 15(6): 353–360; discussion 361.
- Oden, A., M. Andersson et al. (1998). "Five-year clinical evaluation of Procera AllCeram crowns." *J Prosthet Dent* 80(4): 450–456.
- Plotino, G., L. Buono et al. (2008). "Nonvital tooth bleaching: a review of the literature and clinical procedures." *J Endod* 34(4): 394–407.
- Terzioglu, H., B. Yilmaz et al. (2009). "The effect of different shades of specific luting agents and IPS empress ceramic thickness on overall color." *Int J Periodontics Restor Dent* 29(5): 499–505.
- Van Meerbeek, B. (2008). "Mechanisms of resin adhesion: Dentin and enamel bonding." *Func Restor Dent* 2(1): 18–25.
- Vence, B. S. (2007). "Predictable esthetics through functional design: the role of harmonious disclusion." *J Esthet Restor Dent* 19(4): 185–191; discussion 192.
- Wee, A. G., E. Y. Kang et al. (2005). "Clinical color match of porcelain visual shade-matching systems." *J Esthet Restor Dent* 17(6): 351–357; discussion 358.
- Wee, A. G., P. Monaghan et al. (2002). "Variation in color between intended matched shade and fabricated shade of dental porcelain." *J Prosthet Dent* 87(6): 657–666.

Case 14

Case 14

Rehabilitation of anterior teeth I—combination of complete and partial coverage restorations

This case discusses improving/idealizing tooth position, tooth proportion, and tooth color in the maxillary anterior sextant using porcelain laminate veneers (PLV) and all-ceramic, full-coverage restorations. In this case

Procera alumina crowns were placed on the maxillary lateral incisors (7 and 10), and PLVs were placed on the central incisors (8 and 9).

CASE STORY

A 33-year-old male presents to the dental office with a chief complaint of “I am not happy with my smile and the position of my front teeth and I want a quick solution.” He continues to explain that

orthodontic treatment was recommended in his early teens, but at that time finances did not allow for this option.

For more information regarding anterior restorations, refer to Cases 11–15.

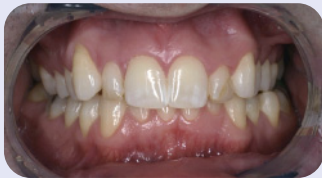

Figure 1: Pretreatment frontal view.

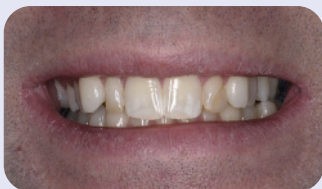

Figure 2: Pretreatment incisal display.

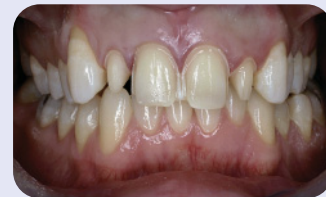

Figure 3: Tooth preparation completed: central incisors for PLV, lateral incisors for full-coverage crowns.

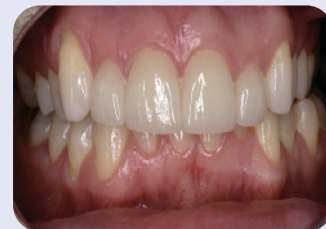

Figure 4: Final restorations.

LEARNING GOALS AND OBJECTIVES

- Provide an aesthetic result to idealize tooth position/arrangement and tooth shape and shade, using contemporary restorative materials.
- Care and maintenance for a PLV and all-ceramic, full-coverage restorations

Medical History

- No contributory findings noted

Dental History

- The patient received routine preventive dental care, which included biannual exams, prophylaxis care, and routine radiographs.
- His oral hygiene is good and his caries index is low.

Medications and Allergies

- Takes 1 multivitamin daily
- Penicillin allergy
- Sulfa allergy

Review of Systems

- Vital signs:
 - Blood pressure: 118/78
 - Heart rate: 70 beats/minute
 - Respiration rate: 16 breaths/minute

Social History

- Smoking: no history of smoking or recreational drug use
- Alcohol: patient is a social drinker—approximately 4 glasses of wine per week

Significant Extraoral Findings

- No significant findings

Significant Soft Tissue Findings

- Lips appear a bit dry, symmetrical, and normal shape, size, and color

Clinical Findings/Problem List

- Misaligned maxillary incisors
- Tooth proportions

Diagnosis

- Misaligned maxillary teeth

Clinical Decision-Making Determining Factors

- To provide the patient with an aesthetic result without orthodontic intervention, proper diagnosis, thorough evaluation, and a comprehensive treatment planning are fundamental. This case report presents the strategy of a comprehensive evaluation, diagnosis, and treatment focusing on the patient's slightly compromised position and discoloration of the anterior maxillary dentition. Orthodontic treatment to align teeth is often not a preferred option for the adult patient, due to a variety of reasons, most commonly time and cost of treatment (Rosenstiel, Ward et al. 2000; Terry and McGuire 2002).
- The veneering of teeth can correct both tooth size and position discrepancies by providing an illusion of alignment of the maxillary central incisors (Snow 1999; Ward 2007).
- As mentioned in previous chapters (11–13), the biggest challenges in anterior aesthetic cases are obtaining an accurate porcelain shade selection and the clear communication of this critical color matching to the dental laboratory technician. Optical effects of porcelain shade selection—such as metamerism, the variables associated with the luting cements, and the many ceramic types available—can cause major aesthetic hurdles for the restorative dentist. The preparation depth and thickness of the porcelain can also add to the challenges (Exner 1991; Chang, Da Silva et al. 2009; Terzioglu, Yilmaz et al. 2009).
- Postinsertion care and maintenance for porcelain laminate veneers are critical parts of the success of the restoration. One way to protect/maintain the integrity of these PLV restorations has been with the use of an occlusal guard. Also important is proper hygiene to include proper toothbrushing techniques, use of dental floss, and oral rinses (Strassler and Nathanson 1989).

Questions

1. All of the following are indications for using porcelain laminate veneers (PLVs) *except*

- A. To mask minimal discoloration in multiple teeth
- B. To change the size/shape of a tooth's proportion
- C. To alter the position of a tooth relative to the ideal arch form
- D. To provide an alternative to full-coverage restorations

2. Which of the following is *not* a contraindication for using porcelain laminate veneers?

- A. Severe crowding of teeth
- B. Class I occlusal scheme
- C. Insufficient coronal tooth structure remaining
- D. Actively erupting teeth in an adolescent patient

3. The positional relationship of the lateral incisors, in this case lingually positioned to the overlapping centrals, can cause aesthetic compromises. What can be done to minimize this?

- A. Take preoperative photos.
- B. Review preoperative mounted study casts.
- C. Do a diagnostic wax-up of proposed new maxillary anterior incisor scheme while considering the rule of golden proportions.
- D. All options are correct.

4. The following is a feature of an alumina Procera crown:

- A. Accuracy of fit
- B. Beveled finish lines for added retention
- C. Can be altered internally to adjust fit
- D. Fit very tight on both the master cast and the prepared tooth

5. When is an alumina Procera crown indicated?

- A. For teeth that have short clinical crowns
- B. Where an aesthetic outcome is desired
- C. Only when it opposes such restorations in the opposing arch
- D. For patients with severe vertical overlap of the anterior teeth

6. All of the following statements are requirements of a tooth preparation margin for all-ceramic crowns *except*

- A. Smooth margins without unsupported enamel
- B. Can be sub- or supragingival
- C. Chamfer and a bevel for increased retention
- D. Deep chamfer

7. With regard to the surrounding periodontal structures, which of the following statements are true?

- A. Periodontal health and contour must be considered during the treatment planning phase to achieve an aesthetic result.
- B. Soft tissue removal can always improve symmetrical periodontal contours prior to the impression-making phase of treatment.
- C. Clinical crown lengthening can always be performed to restore periodontal health prior to the impression-making phase of treatment.
- D. Soft tissue management is important only after all restorations are placed.

8. With regard to incisal reductions, the following statement is true:

- A. Incisal reduction for an all-ceramic crown should be 1.5–2.0 mm.
- B. Minimal reduction is needed for an all-ceramic crown because there is no metal substructure.
- C. Incisal reduction for an all-ceramic crown should be 3.0 mm.
- D. Incisal reduction is dependent only on the height of the clinical crown.

9. Which of the following statements is accurate regarding cementation of an all-ceramic restoration?

- A. The luting cement can cause a perceptible color difference in the final restoration.
- B. Cement shades change color after cementation.
- C. Cement shades do not affect the shade of the final restoration.
- D. Cement shades change color in the presence of moisture.

10. To protect the PLV restorations and the all-ceramic crowns, the following is true:

- A. Maintain good oral hygiene.
- B. Avoid excessive occlusal forces.
- C. Protect restorations with an occlusal guard.
- D. All of the above

ANSWERS

- 1. D (Rosenstiel, Ward et al. 2000; Strassler 2007)
- 2. B (Goldstein 1998)
- 3. D (Snow 1999)
- 4. A (Andersson, Razzoog et al. 1998)
- 5. B (Christensen 1999)

- 6. C (Oilo, Tornquist et al. 2003)
- 7. A (Barham, Mayhew et al. 1983)
- 8. A (Andersson, Razzoog et al. 1998)
- 9. A (Da Silva, Park et al. 2008)
- 10. D (Barghi and McAlister 1998; Calamia and Calamia 2007)

The authors would like to acknowledge and thank Dr. Igor Chikunov for clinical case photographs and treatment performed at New York University College of Dentistry.

References

- Andersson, M., M. E. Razzoog et al. (1998). "Procera: a new way to achieve an all-ceramic crown." *Quintessence Int* 29(5): 285–296.
- Barghi, N. and E. McAlister (1998). "Porcelain for veneers." *J Esthet Dent* 10(4): 191–197.
- Barham, T. P., Jr., R. B. Mayhew et al. (1983). "Gingival response to laminate veneer restorations." *Oper Dent* 8(4): 122–129.
- Calamia, J. R. and C. S. Calamia (2007). "Porcelain laminate veneers: reasons for 25 years of success." *Dent Clin North Am* 51(2): 399–417, ix.
- Chang, J., J. D. Da Silva et al. (2009). "The optical effect of composite luting cement on all ceramic crowns." *J Dent* 37(12): 937–943.
- Christensen, G. J. (1999). "Porcelain-fused-to-metal vs. nonmetal crowns." *Journal of the American Dental Association* 130(3): 409–411.
- Da Silva, J. D., S. E. Park et al. (2008). "Clinical performance of a newly developed spectrophotometric system on tooth color reproduction." *J Prosthet Dent* 99(5): 361–368.
- Exner, H. V. (1991). "Predictability of color matching and the possibilities for enhancement of ceramic laminate veneers." *J Prosthet Dent* 65(5): 619–622.
- Goldstein, R. E. (1998). *Esthetics in dentistry*. Hamilton, Ont., B. C. Decker.
- Oilo, G., A. Tornquist et al. (2003). "All-ceramic crowns and preparation characteristics: a mathematic approach." *Int J Prosthodont* 16(3): 301–306.
- Rosenstiel, S. F., D. H. Ward et al. (2000). "Dentists' preferences of anterior tooth proportion—a web-based study." *J Prosthodont* 9(3): 123–136.
- Snow, S. R. (1999). "Esthetic smile analysis of maxillary anterior tooth width: the golden percentage." *J Esthet Dent* 11(4): 177–184.

- Strassler, H. E. (2007). "Minimally invasive porcelain veneers: indications for a conservative esthetic dentistry treatment modality." *Gen Dent* 55(7): 686.
- Strassler, H. E. and D. Nathanson (1989). "Clinical evaluation of etched porcelain veneers over a period of 18 to 42 months." *J Esthet Dent* 1(1): 21–28.
- Terry, D. A. and M. McGuire (2002). "The perio-aesthetic-restorative approach for anterior reconstruction—Part II: Restorative treatment." *Pract Proced Aesthet Dent* 14(5): 363–369; quiz 370.
- Terzioglu, H., B. Yilmaz et al. (2009). "The effect of different shades of specific luting agents and IPS empress ceramic thickness on overall color." *Int J Periodontics Restorative Dent* 29(5): 499–505.
- Ward, D. H. (2007). "A study of dentists' preferred maxillary anterior tooth width proportions: comparing the recurring esthetic dental proportion to other mathematical and naturally occurring proportions." *J Esthet Restor Dent* 19(6): 324–337.

Case 15

Case 15

Rehabilitation of anterior teeth II—partial coverage restorations

This case discusses replacing failing composite veneer restorations with porcelain laminate veneers for maxillary central and lateral incisors.

CASE STORY

A 44-year-old male presents to the dental office with a chief complaint of “I want porcelain veneers to replace my bonding.” The patient had been going to the same dentist since he was about 10 years old and he has had the current restorations for over 20 years. His dentist recently passed away, and the patient is now seeking treatment. He was just

promoted in his job and is “very visible” in his new position. He was never really happy with his resin restorations, but he liked his dentist so much that he was uncomfortable telling him. He also did not have the financial means previously. He is asking for “new materials” to give him a more “natural look.” For more information regarding anterior restorations, refer to Cases 11–14.

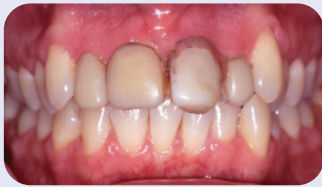

Figure 1: Pretreatment presentation.

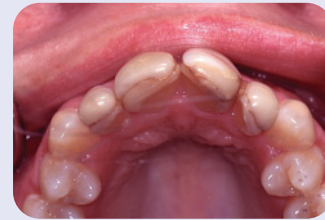

Figure 3: Pretreatment maxillary occlusal view.

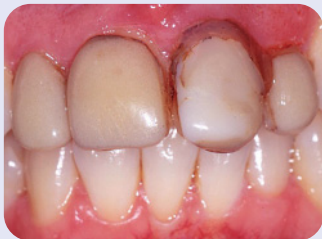

Figure 2: Pretreatment, central and lateral incisors.

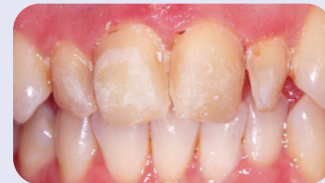

Figure 4: Central and lateral incisors after removal of existing restorations.

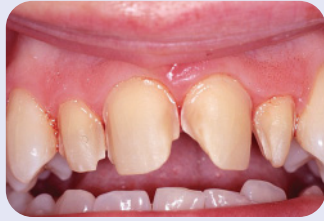

Figure 5: Preparations.

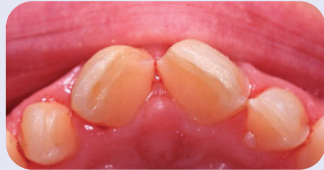

Figure 6: Lingual view of prepared teeth.

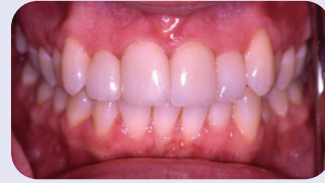

Figure 7: Final restorations.

LEARNING GOALS AND OBJECTIVES

- Provide an aesthetic result using minimally invasive techniques and contemporary restorative materials.
- Idealize arch form.
- Critical color matching
- Restoring form, function, and aesthetics
- Care and maintenance for a porcelain laminate veneer

Medical History

- Grave's disease

Dental History

- Regular dental visits since youth
- Multiple fillings and resin veneers placed over the past 30 years

Medications and Allergies

- 25mcg l-thyroxine
- No known drug allergies

Review of Systems

- Vital signs:
 - Blood pressure: 130/88
 - Heart rate: 68 beats/minute
 - Respiration rate: 20 breaths/minute

Social History

- Smoking: never smoked
- Alcohol: social drinker
- Recreational drugs: denies any recreational drug use

Significant Extraoral Findings

- No significant findings

Significant Soft Tissue Findings

- No significant findings

Clinical Findings/Problem List

- Anterior aesthetics, due to failing and mismatched composite resin restorations
- Misaligned maxillary incisors

Diagnosis

- Failing resin restorations
- Misaligned maxillary teeth

Clinical Decision-Making Determining Factors

- This clinical case report describes the replacement of composite resin veneers to porcelain laminate veneers (PLV) to address the management of a patient's aesthetic concerns, while achieving an ideal arch form, a better shade match, and a more predictable long term aesthetic result (Magne and Belser 2004).
- A diagnostic/mock-up can assist in the success of the final outcome of the case. The mock-up should be mounted on a semi-adjustable articulator to aid in the evaluation of occlusion, as well as ideal tooth size/contour, and assist the patient with treatment understanding and acceptance (Magne and Belser 2004).
- Proper diagnosis, thorough evaluation, and a comprehensive treatment plan are fundamental to restoring each patient's oral health and aesthetic concerns. This case report presents a strategy of

comprehensive evaluation, diagnosis, and treatment focusing on the patient's compromised teeth positions and discoloration of the maxillary anterior dentition. Orthodontic treatment to align teeth is often not a viable option for the adult patient, due to a variety of reasons. Restorative and preventive protocols were utilized to achieve optimal form, function, and aesthetic results (Terry and McGuire 2002; Sarver and Ackerman 2003a,b).

- The current evidence is that the veneered porcelain etched to intact and prepared enamel offers the advantages of increased strength, color stability, and aesthetics as compared to composite veneers. In this case PLVs can provide an illusion of alignment of the maxillary central incisors. Orthodontic therapy was offered to the patient, but the patient declined (Garber 1989; Hui, Williams et al. 1991).
- The most challenging aspects of anterior restorations are an accurate porcelain shade selection and communication of this color to the technician. This is a multifactor challenge. Optical effects of porcelain shade selection, the variables associated with the luting cements, and the many ceramics available can cause major aesthetic hurdles for the restorative dentist. The preparation and thickness of the porcelain can add to the complexity (Da Silva, Park et al. 2008; Terzioglu, Yilmaz et al. 2009).

- It has also been described that the hydration of teeth can have a major impact on the shade selected. It typically takes natural teeth about 10 minutes to dehydrate with a perceptible change in shade and up to 2 hours to rehydrate. It is therefore critical that shade selection is performed at the outset of treatment and prior to any tooth preparation (Riley, Sanderson et al. 1986). Other factors that affect the shade selection include the presence of ambient daylight (Exner 1991) and shade selection technique. Newer data indicate that the spectrophotometric methods have a greater potential of accuracy than visual methods (Judeh and Al-Wahadni 2009). The use of digital photography and computers also demonstrates a greater accuracy over visual techniques (Schropp 2009). However, all techniques available have limitations.
- Postinsertion care and maintenance for porcelain laminate veneers are critical parts of the success of the restoration. One way to protect/maintain the integrity of these PLV restorations has been with the use of an occlusal/mouth guard.
- Methods of proper oral hygiene include proper toothbrushing techniques, use of dental floss, and oral rinses (Strassler and Nathanson 1989).

Questions

1. All of the following are considered minimally invasive procedures to restore anterior aesthetics *except*

- A. Direct composite bonded restorations
- B. All-ceramic crowns
- C. Tooth whitening
- D. Use of porcelain laminate veneers

2. Porcelain veneering of anterior teeth has the following advantages over direct composite bonded restorations *except*

- A. The color of a porcelain laminate veneer is more predictable over time.
- B. The porcelain laminate veneer is often a single appointment procedure.
- C. The porcelain laminate veneer reflects and refracts light similarly to natural tooth structure.
- D. The luting cement can further assist in shade matching because it can come in different shades and alter the final shade as needed.

3. Direct composite bonding or bonded porcelain veneers are both good choices for anterior aesthetically demanding restorations. Which statement below is most accurate?

- A. Bonded porcelain veneers are not very conservative restorations.
- B. Direct composite restorations are aesthetic, conservative, and reliable, but they demand technical and artistic skills and have limited longevity.
- C. Bonded porcelain veneers can have excellent aesthetics and can always be performed without additional tooth preparation.
- D. Direct composite restorations always require tooth preparation to achieve maximum aesthetic results.

4. Bonded porcelain veneers can have excellent aesthetics but require which of the following:

- A. Generally need additional tooth preparation
- B. Require lab support
- C. Impression making
- D. An insertion visit (2-step procedure)
- E. All are correct.

5. Which of the following best describes the correct sequence of treatment when replacing anterior composite bonded restorations to porcelain laminated veneers?

- A. Remove the composite bonded restorations and any decay, whiten teeth using tray whitening for 2–4 weeks, idealize tooth prep, establish a finish line, make a final impression, and fabricate provisional restorations.
- B. Remove the composite bonded restorations and any decay, whiten teeth using tray whitening for 2–4 weeks, and make a final impression. A provisional restoration is not necessary.
- C. Remove the composite bonded restoration only, make a final impression, and fabricate provisional restorations.
- D. Whiten teeth using tray whitening for 2–4 weeks, remove the composite bonded restorations and any decay, idealize tooth prep, establish a finish line, make a final impression, and fabricate provisional restorations.

6. When planning a porcelain laminate veneer restoration, all of the following can aid in an aesthetic outcome *except*

- A. Mock wax-up
- B. Silicone index to check reduction of preparations
- C. Good laboratory communication with the ceramist
- D. Proper shade selection
- E. Relying on cement for final shade correction

7. When planning to idealize arch form, tooth size, shade, and shape with PLVs, the use of diagnostic provisionals can aid in the following:

- A. Evaluation of aesthetics
- B. Evaluation of function
- C. Evaluation of phonetics
- D. All of the above

8. Porcelain laminate veneers (PLVs) are considered a conservative dental restoration. The following statement is accurate with regard to the preparation:

- A. Minimal facial preparation can be .5mm–.75 mm.
- B. All veneers have a 360-degree finish line.
- C. Veneers always require tooth preparation.
- D. The luting cement damages tooth structure.

9. Which of the following factor(s) have to be considered to avoid fracture/failure of porcelain laminate veneers?

- A. Tooth preparation/finish line design
- B. Strength and type of ceramic used
- C. Occlusion
- D. A and B only
- E. A, B, and C

ANSWERS

1. B (Dietschi 2008)
2. B (Strassler 2007)
3. B (Dunn 1994)
4. E (Bello and Jarvis 1997)
5. D (Weinstein 1988)

6. E (Gurel 2007)
7. D (Gurel 2007)
8. A (Edelhoff and Sorensen 2002)
9. E (Castelnuovo, Tjan et al. 2000)

The authors would like to acknowledge and thank Dr. Stella Oh for clinical case photographs and treatment performed at New York University College of Dentistry.

References

- Bello, A. and R. H. Jarvis (1997). "A review of esthetic alternatives for the restoration of anterior teeth." *J Prosthet Dent* 78(5): 437–440.
- Castelnuovo, J., A. H. Tjan et al. (2000). "Fracture load and mode of failure of ceramic veneers with different preparations." *J Prosthet Dent* 83(2): 171–180.
- Da Silva, J. D., S. E. Park et al. (2008). "Clinical performance of a newly developed spectrophotometric system on tooth color reproduction." *J Prosthet Dent* 99(5): 361–368.
- Dietschi, D. (2008). "Optimizing smile composition and esthetics with resin composites and other conservative esthetic procedures." *Eur J Esthet Dent* 3(1): 14–29.
- Dunn, J. (1994). "Direct composite or bonded porcelain: a clinical choice for anterior aesthetics." *J Calif Dent Assoc* 22(4): 73–76, 78, 80–81 passim.
- Edelhoff, D. and J. A. Sorensen (2002). "Tooth structure removal associated with various preparation designs for anterior teeth." *J Prosthet Dent* 87(5): 503–509.
- Exner, H. V. (1991). "Predictability of color matching and the possibilities for enhancement of ceramic laminate veneers." *J Prosthet Dent* 65(5): 619–622.
- Garber, D. A. (1989). "Direct composite veneers versus etched porcelain laminate veneers." *Dent Clin North Am* 33(2): 301–304.
- Gurel, G. (2007). "Porcelain laminate veneers: minimal tooth preparation by design." *Dent Clin North Am* 51(2): 419–431, ix.
- Hui, K. K., B. Williams et al. (1991). "A comparative assessment of the strengths of porcelain veneers for incisor teeth dependent on their design characteristics." *Br Dent J* 171(2): 51–55.
- Judeh, A. and A. Al-Wahadni (2009). "A comparison between conventional visual and spectrophotometric methods for shade selection." *Quintessence Int* 40(9): e69–79.
- Magne, P. and U. C. Belser (2004). "Novel porcelain laminate preparation approach driven by a diagnostic mock-up." *J Esthet Restor Dent* 16(1): 7–16; discussion 17–18.
- Riley, E. J., I. R. Sanderson et al. (1986). "Shade determination, communication, and realization: a novel approach." *Quintessence Int* 17(11): 739–744.
- Sarver, D. M. and M. B. Ackerman (2003a). "Dynamic smile visualization and quantification: part 1. Evolution of the concept and dynamic records for smile capture." *Am J Orthod Dentofacial Orthop* 124(1): 4–12.
- Sarver, D. M. and M. B. Ackerman (2003b). "Dynamic smile visualization and quantification: Part 2. Smile analysis and treatment strategies." *Am J Orthod Dentofacial Orthop* 124(2): 116–127.
- Schropp, L. (2009). "Shade matching assisted by digital photography and computer software." *J Prosthodont* 18(3): 235–241.
- Strassler, H. E. (2007). "Minimally invasive porcelain veneers: indications for a conservative esthetic dentistry treatment modality." *Gen Dent* 55(7): 686–694; quiz 695–696, 712.
- Strassler, H. E. and D. Nathanson (1989). "Clinical evaluation of etched porcelain veneers over a period of 18 to 42 months." *J Esthet Dent* 1(1): 21–28.
- Terry, D. A. and M. McGuire (2002). "The perio-aesthetic-restorative approach for anterior reconstruction—Part II: Restorative treatment." *Pract Proced Aesthet Dent* 14(5): 363–369; quiz 370.
- Terzioglu, H., B. Yilmaz et al. (2009). "The effect of different shades of specific luting agents and IPS empress ceramic thickness on overall color." *Int J Periodontics Restorative Dent* 29(5): 499–505.
- Weinstein, A. R. (1988). "Anterior composite resins and veneers: treatment planning, preparation, and finishing." *Journal of the American Dental Association* 117(4): 38E–45E.

Case 16

Case 16

Rehabilitation of anterior teeth requiring orthodontic extrusion

CASE STORY

A 48-year-old female patient presents with a carious left lateral incisor (10); she requests extraction and placement of a single-unit implant and restoration. The patient reports that this was the treatment prescribed by her previous dentist. The patient presents with a restoration on the left central incisor with a cantilever unit for the lateral incisor serving as a provisional restoration. The lateral incisor is carious and has no remaining tooth structure above the gingival margin. After thorough clinical and radiographic examination, an alternative treatment option was presented to the patient: orthodontic extrusion of the lateral incisor and restoration of the tooth with a conventional crown.

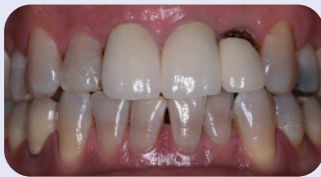

Figure 1: Pretreatment presentation.

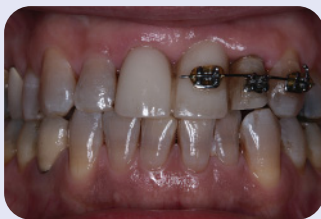

Figure 2: Orthodontic treatment.

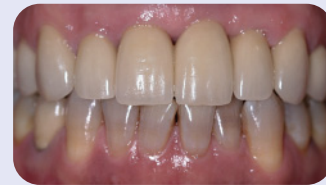

Figure 3: Posttreatment presentation.

LEARNING GOALS AND OBJECTIVES

- Indications and contraindications of orthodontic extrusion
- Site development for future implant placement

Medical History

- No significant medical history reported

Dental History

- Multiple direct restorations
- Trauma in the anterior maxilla 23 years ago

Medications and Allergies

- No medications
- No known drug allergies

Review of Systems

- Vital signs:
 - Blood pressure: 120/80
 - Heart rate: 80 beats/minute
 - Respiration rate: 16 breaths/minute

Social History

- No significant findings

Significant Soft Tissue Examination Findings

- No significant findings

Significant Clinical Findings/Problem List

- Fracture of coronal tooth structure maxillary left lateral incisor
- Caries maxillary left lateral incisor
- Provisional restoration maxillary left central and lateral incisors (9 and 10)

Diagnosis

- Caries
- Inadequate coronal tooth structure

Clinical Decision-Making Determining Factors

- The lack of crown height may be due to a number of different clinical situations such as fracture of the tooth, caries, and previous excessive tooth preparation. Increase of clinical crown height may be achieved through periodontal surgery (i.e., crown-lengthening procedures) or via orthodontic extrusion of the tooth.
- In certain clinical situations, crown lengthening may be contraindicated. For example, osseous recontouring of the tooth in question may lead to an unfavorable crown-to-root ratio, an aesthetic compromise, or scar tissue formation after surgery. In such situations, orthodontic extrusion may be indicated (Potashnick and Rosenberg 1982).
- Orthodontic extrusion involves vertical forced movement of a tooth, which in turn stimulates apposition of crestal bone. The gingiva and alveolar bone move vertically along with the tooth. This movement should not be done in a rapid fashion because the periodontal ligament may become

damaged and the tooth may become ankylosed.

Excess mobility may also result from rapid extrusive movement. Extrusion at a rate of about 1 mm or less per week is recommended (Cronin and Wardle 1981; Bach, Baylard et al. 2004; Proffit, Fields et al. 2007).

- Indications for orthodontic extrusion include
 - Subgingival caries, fracture, perforation, or root resorption
 - Biologic width considerations
 - Implant site development
 - Exposure of impacted teeth
- Contraindications to orthodontic extrusion include
 - Root proximity wherein extrusion would cause inadequate embrasure space between adjacent teeth
 - Ankylosed teeth
 - Unfavorable resultant crown-to-root ratio (i.e., insufficient root length)
 - Resultant furcation involvement
- Some issues that should be considered in case selection are that a period of several weeks of orthodontic retention may be indicated after extrusion and, furthermore, that periodontal surgery may be required to correct gingival contours prior to finalization of restorations. Patients must be made aware of these facts prior to start of treatment (Cronin and Wardle 1981; Bach, Baylard et al. 2004).
- A multidisciplinary approach to orthodontic tooth extrusion is key. This mode of treatment requires the collaboration of the endodontist, the periodontist, the prosthodontist, and the orthodontist. The treating clinician must be comfortable with all aspects of treatment in order for the outcome to be successful (Poi, Cardoso Lde et al. 2007).

Questions

1. Which of the following is a disadvantage of the orthodontic extrusion technique?

- A. Compromised aesthetics
- B. Possible caries formation
- C. Soft tissue trauma
- D. Compromised oral hygiene
- E. All of the above

2. A possible complication with orthodontic eruption of posterior teeth is

- A. Exposure of the furcation area
- B. Exposure of the apex of the tooth
- C. Chronic inflammatory reaction
- D. The need for root amputation

3. What is the ideal crown-to-root ratio?

- A. 1:2
- B. 1:1
- C. 2:3
- D. 2:1

4. What is the minimally acceptable crown-to-root ratio?

- A. 1:2
- B. 1:1
- C. 2:3
- D. 2:1

5. Which of the following is the advantage provided by orthodontic extrusion for an implant site development?

- A. Resolution of inflammation at developed implant site
- B. Formation of newly keratinized tissue
- C. Increased patient acceptance over traditional grafting methods
- D. Harmony of gingival zenith as a result of the extrusion process

6. If successful endodontic treatment of the affected tooth cannot be accomplished prior to the start of extrusion, what is the recommended course of treatment?

- A. Extraction of the tooth
- B. Pulpectomy and placement of temporary medicament until future endodontic therapy completion
- C. Provisionalization with no endodontic therapy
- D. Treatment with broad spectrum systemic antibiotics to ward off any possible infections until after extrusion is completed

7. Orthodontic extrusion is sometimes indicated in cases of traumatic tooth fracture. Horizontal root fractures comprise what percent of all dental injuries?

- A. 3%
- B. 10%
- C. 25%
- D. 50%

8. A recent study of traumatic dental injuries found that the most common cause of dental trauma (in the study population) was

- A. Automobile accidents
- B. Trip and fall accidents
- C. Bicycle fall accidents
- D. Trauma from personal attack/injury

9. A possible benefit with orthodontic eruption of anterior teeth is

- A. Creating a more favorable crown-to-root ratio
- B. Exposing a less-stained root surface area that is more aesthetic
- C. Minimal scar tissue formation
- D. Creating tighter root proximity

10. The physiologic process by which orthodontic extrusion occurs involves

- A. A pathologic condition
- B. An aseptic inflammatory response
- C. A septic inflammatory response
- D. Appositional bone resorption at the apex of the tooth being moved

ANSWERS

- 1. E (Ziskind, Schmidt et al. 1998)
- 2. A (Potashnick and Rosenberg 1982)
- 3. C (Shillingburg 1997)
- 4. B (Shillingburg 1997)
- 5. B (Bach, Baylard et al. 2004)

- 6. B (Proffit, Fields et al. 2007)
- 7. A (Canoglu, Gungor et al. 2007)
- 8. C (Castro, Poi et al. 2005)
- 9. C (Potashnick and Rosenberg 1982)
- 10. B (Holst, Nkenke et al. 2009)

The authors would like to acknowledge and thank Dr. Ryan Sellinger for clinical case photographs and treatment performed.

References

- Bach, N., J. F. Baylard et al. (2004). "Orthodontic extrusion: periodontal considerations and applications." *J Can Dent Assoc* 70(11): 775–780.
- Canoglu, H., H. C. Gungor et al. (2007). "Management of cervical root fracture using orthodontic extrusion and crown reattachment: a case report." *Oral Surg, Oral Med, Oral Pathol, Oral Radiol, Endod* 104(3): e46–49.
- Castro, J. C., W. R. Poi et al. (2005). "Analysis of the crown fractures and crown-root fractures due to dental trauma assisted by the Integrated Clinic from 1992 to 2002." *Dent Traumatol* 21(3): 121–126.
- Cronin, R. J. and W. L. Wardle (1981). "Prosthodontic management of vertical root extrusion." *J Prosthet Dent* 46(5): 498–504.
- Holst, A. I., E. Nkenke et al. (2009). "Prosthetic considerations for orthodontic implant site development in the adult patient." *J Oral Maxillofac Surg* 67(11 Suppl): 82–88.
- Poi, W. R., C. Cardoso Lde et al. (2007). "Multidisciplinary treatment approach for crown fracture and crown-root fracture—a case report." *Dent Traumatol* 23(1): 51–55.
- Potashnick, S. R. and E. S. Rosenberg (1982). "Forced eruption: principles in periodontics and restorative dentistry." *J Prosthet Dent* 48(2): 141–148.
- Proffit, W. R., H. W. Fields et al. (2007). *Contemporary orthodontics*. St. Louis, Mosby Elsevier.
- Shillingburg, H. T. (1997). *Fundamentals of fixed prosthodontics*. Chicago, Quintessence Pub. Co.
- Ziskind, D., A. Schmidt et al. (1998). "Forced eruption technique: rationale and clinical report." *J Prosthet Dent* 79(3): 246–248.

WWW.HIGHDENT.IR

همیار دندانسازان و دندانپزشکان

Case 17

Case 17

Management of severe crowding— a multidisciplinary approach

CASE STORY

A 22-year-old male patient presents with the chief complaint of “I need a checkup and braces.” The patient reports that he has had severe crowding in the maxillary anterior region for as long as he can recall. His previous dentist told him that he had “a gum problem” and that he needed treatment before he could receive any orthodontic treatment. The patient is highly motivated to improve his oral condition.

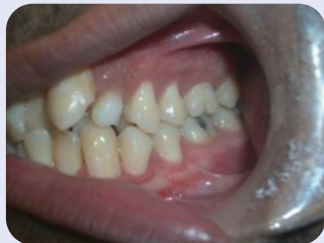

Figure 1: Preoperative left side.

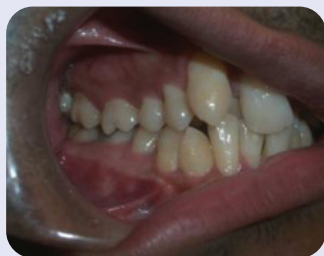

Figure 2: Preoperative right side.

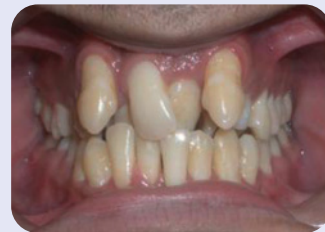

Figure 3: Preoperative presentation.

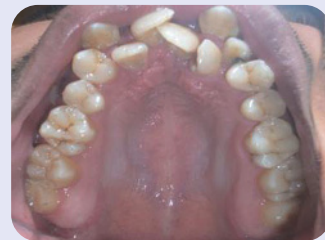

Figure 4: Preoperative maxilla.

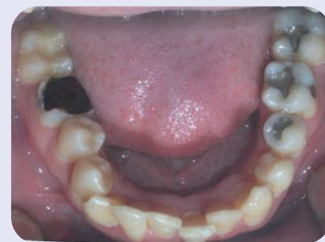

Figure 5: Preoperative mandible.

LEARNING GOALS AND OBJECTIVES

- To recognize the need for a multidisciplinary approach to treatment—specifically, the need for periodontal considerations prior to orthodontic and prosthodontic treatment
- To understand the need for proper tooth alignment
- To understand the influence of periodontal health on restorative outcomes

Medical History

- No significant findings

Review of Systems

- Vital signs:
 - Blood pressure: 110/72
 - Heart rate: 68 beats/minute
 - Respiration rate: 15 breaths/minute

Significant Intraoral Examination Findings

- Gingival inflammation and recession, especially in the maxillary anterior region
- Retained maxillary left primary lateral incisor (G)

Radiographic Findings**Clinical Findings/Problem List**

- Caries:
 - Maxillary right second molar (2) O
 - Maxillary right first molar (3) O
 - Maxillary right second premolar (4) O
 - Maxillary right first premolar (5) O
 - Maxillary left second premolar (13) O
 - Maxillary left first molar (14) OL
 - Maxillary left second molar (15) OL
 - Mandibular right first molar (30) O (recurrent)
 - Mandibular right second molar (31) O
- Retention of primary teeth
- Severe anterior crowding and cross-bite
- Periodontal condition
 - Fair oral hygiene
 - Chronic generalized moderate periodontitis
 - Localized severe periodontitis (mandibular anterior region)
 - Vertical bone defects in the following areas
 - Mandibular left second molar (18M)
 - Mandibular right second premolar (29D)
 - Mandibular right second molar (31M)
- Occlusion
 - Class I molar occlusion
 - Class II canine malocclusion

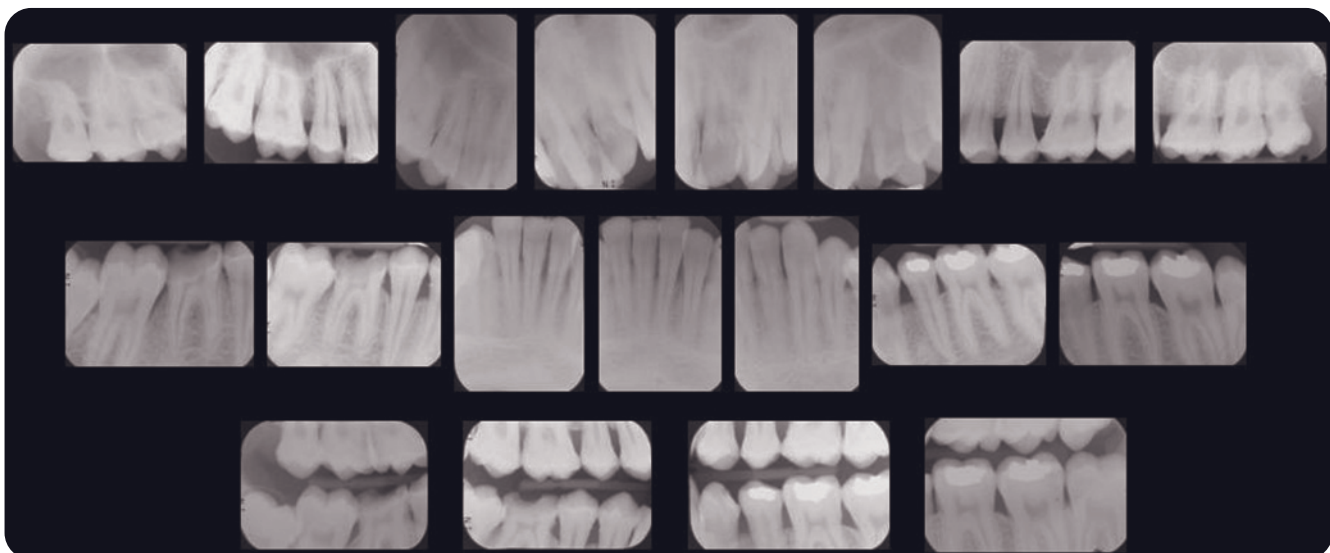


Figure 6: Full mouth series of radiographs.

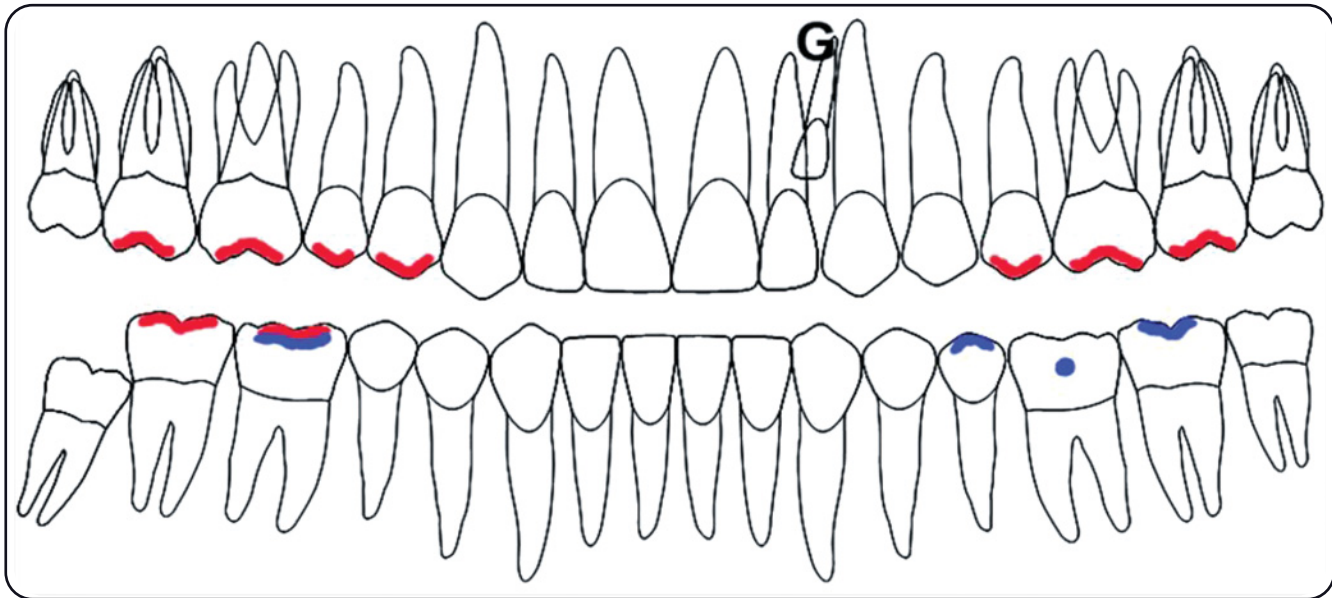


Figure 7: Dental charting.

Charting

Diagnosis

- Caries
- Chronic localized moderate periodontitis
- Severe anterior crowding and cross-bite

Clinical Decision-Making Determining Factors

- When treating a patient with complex aesthetic challenges, a multidisciplinary approach is often necessary. With the help of the orthodontist, the periodontist, and the prosthodontist, a treatment plan can be developed for all stages of treatment. Diagnostic wax-ups and mock composite restorations can usually be created to guide the clinicians in their treatment. However, in more complex cases, a simple diagnostic wax-up is not possible. This presents a great challenge for the overall vision of the treatment plan. To address this challenge, models can be created and manually sectioned, and teeth can be measured and replaced in more ideal positions; or digital models can be created with the help of computerized measuring systems. These techniques can facilitate interdisciplinary communication and treatment planning (Kuo and Miller 2003; Sandler, Sira et al. 2005; Waldman 2008).
- Several parameters have been typically discussed in evaluation of anterior aesthetics. These parameters include incisal edge show, profile and lip support,

- midline, labiolingual inclination, occlusal plane, gingival level/biotype, and the location of papillae. Despite the level of difficulty in this patient's clinical presentation, these parameters need to be evaluated and developed before proceeding with treatment (Strassler and Garber 1999; Spear, Kokich et al. 2006).
- Evaluation for placement of a single unit implant involves assessment of several factors including but not limited to medical history, periodontal condition, condition of adjacent teeth, and occlusion. A thorough assessment of the patient and his/her oral condition is required prior to the start of implant therapy (Rose, Salama et al. 1995; Tarnow, Elian et al. 2003; Funato, Salama et al. 2007).
- Compromised periodontium is not necessarily a contraindication for orthodontic tooth movement in the adult patient if proper preventive measures are taken. Periodontal inflammation and active disease should be eliminated prior to the start of orthodontic treatment and maintained during treatment. After completion of therapy, periodontal maintenance and good oral hygiene are essential (Ong, Wang et al. 1998).
- In treatment of cases with extremely compromised dentition and aesthetics, it is imperative to establish realistic treatment objectives and expectations. The patient should be thoroughly informed of treatment decisions, and a clear treatment sequence should be established by all members of the multidisciplinary team in order to avoid establishment of unrealistic expectations (Kokich and Spear 1997).

Questions

1. During the initial interview phase of treatment planning, this young adult patient reports that he wishes to have "a Hollywood smile." This statement indicates possible unrealistic treatment expectations from this patient and prompts a discussion about treatment goals and outcomes. What are some diagnostic aids that should be utilized in having this discussion with the patient?

- A. Radiographs
- B. Mounted diagnostic casts
- C. Dental charting
- D. Photographs
- E. B and D

2. Aesthetics is an objective science involving the points of view of the dentist and the patient. A comparison of the aesthetic evaluation of dentists versus patients resulted in which of the following findings?

- A. There was a significant difference between the evaluation of dentists and patients.
- B. There was no difference between the evaluations of men and women.
- C. Men were less likely to pinpoint aesthetic imperfections.
- D. A and B only
- E. A and C only

3. Predictability of the aesthetic outcome of this patient's treatment, prior to any initial orthodontic therapy, is very difficult due to the severe crowding in the anterior maxilla. In a typical case presentation, a diagnostic setup is a great aid to the dentist, the patient and the laboratory technician. What are some of the uses of a diagnostic setup?

- A. Tool for discussion of treatment outcomes and expectations
- B. Guideline for tooth preparation
- C. Guideline for fabrication of provisionals
- D. Guideline for fabrication of definitive prosthesis
- E. All of the above

4. Managing a patient undergoing multidisciplinary treatment is a challenging task, especially when treatment requires the aid of many specialists. Some guidelines that should be established to ensure success are

- A. Establishment of a treatment plan and sequence and communication at the end of the treatment
- B. Aesthetic evaluation and communication at the end of the treatment
- C. Establishment of a treatment plan and sequence, aesthetic and periodontal evaluation, progress radiographs, constant communication
- D. Establishment of a treatment plan as you go along and constant communication
- E. None of the above

5. In establishing aesthetic outcomes for the anterior maxilla, some practitioners apply the "golden proportion." This proportion relates to the widths of the teeth. The golden proportion ratio is

- A. 1:1.618
- B. 1:3.14
- C. 1:1
- D. 1:2

6. Which of the following clinical parameters should be evaluated prior to making a decision on whether to preserve or to extract the mandibular right first molar (30) in this patient?

- A. Opposing occlusion
- B. Amount of remaining tooth structure
- C. Prognosis of adjacent teeth
- D. Location of surgical landmarks
- E. All of the above

7. After thorough evaluation of the mandibular right first molar (30), the tooth is deemed to be unrestorable and is scheduled for an extraction. What is the most important factor in deciding to place a single-unit implant instead of a three-unit fixed partial denture to restore the edentulous area?

- A. Patient's age
- B. Unrestored adjacent teeth
- C. Overall periodontal condition
- D. Orthodontic therapy
- E. Patient finances

8. During the excavation of the occlusal caries on the maxillary right first molar (3), there is an exposure of the pulp, necessitating endodontic therapy. What is the most important factor in deciding on the type of final restoration for this tooth?

- A. Amount of remaining tooth structure
- B. Opposing occlusion
- C. Patient's age
- D. Patient's preferences
- E. Patient's finances

ANSWERS

1. E (Shillingburg 1997)
2. D (Brisman 1980)
3. E (Kuo and Miller 2003)
4. C (Kokich and Spear 1997)
5. A (Levin 1978)

6. E (Davaranah, Martinez et al. 2000)
7. B (Iqbal and Kim 2007; Salinas and Eckert 2007; Torabinejad, Anderson et al. 2007; Zitzmann, Margolin et al. 2008)
8. A (Aquilino and Caplan 2002; Goodacre 2004; Morgano, Rodrigues et al. 2004)

The authors would like to acknowledge and thank Drs. Euna Yoo and Sarita Ojha for clinical case photographs and treatment performed at New York University College of Dentistry.

References

- Aquilino, S. A. and D. J. Caplan (2002). "Relationship between crown placement and the survival of endodontically treated teeth." *J Prosthet Dent* 87(3): 256–63.
- Brisman, A. S. (1980). "Esthetics: a comparison of dentists' and patients' concepts." *J Am Dent Assoc* 100(3): 345–52.
- Davaranah, M., H. Martinez et al. (2000). "To conserve or implant: which choice of therapy?" *Int J Periodontics Restorative Dent* 20(4): 412–22.
- Funato, A., M. A. Salama et al. (2007). "Timing, positioning, and sequential staging in esthetic implant therapy: a four-dimensional perspective." *Int J Periodontics Restorative Dent* 27(4): 313–23.
- Goodacre, C. J. (2004). "Five factors to be considered when restoring endodontically treated teeth." *Pract Proced Aesthet Dent* 16(6): 457–62.
- Iqbal, M. K. and S. Kim (2007). "For teeth requiring endodontic treatment, what are the differences in outcomes of restored endodontically treated teeth compared to implant-supported restorations?" *Int J Oral Maxillofac Implants* 22 Suppl: 96–116.
- Kokich, V. G. and F. M. Spear (1997). "Guidelines for managing the orthodontic-restorative patient." *Semin Orthod* 3(1): 3–20.
- Kuo, E. and R. J. Miller (2003). "Automated custom-manufacturing technology in orthodontics." *Am J Orthod Dentofacial Orthop* 123(5): 578–81.
- Levin, E. I. (1978). "Dental esthetics and the golden proportion." *J Prosthet Dent* 40(3): 244–52.
- Morgano, S. M., A. H. Rodrigues et al. (2004). "Restoration of endodontically treated teeth." *Dent Clin North Am* 48(2): vi, 397–416.
- Ong, M. A., H. L. Wang et al. (1998). "Interrelationship between periodontics and adult orthodontics." *J Clin Periodontol* 25(4): 271–7.
- Rose, L. F., H. Salama et al. (1995). "Treatment planning and site development for the implant-assisted periodontal reconstruction." *Compend Contin Educ Dent* 16(8): 726, 728, 730 passim; quiz 742.
- Salinas, T. J. and S. E. Eckert (2007). "In patients requiring single-tooth replacement, what are the outcomes of implant—as compared to tooth-supported restorations?" *Int J Oral Maxillofac Implants* 22 Suppl: 71–95.

- Sandler, J., S. Sira et al. (2005). "Photographic 'Kesling set-up.'" *J Orthod* 32(2): 85–8.
- Shillingburg, H. T. (1997). *Fundamentals of fixed prosthodontics*. Chicago, Quintessence Pub. Co.
- Spear, F. M., V. G. Kokich et al. (2006). "Interdisciplinary management of anterior dental esthetics." *J Am Dent Assoc* 137(2): 160–9.
- Strassler, H. E. and D. A. Garber (1999). "Anterior esthetic considerations when splinting teeth." *Dent Clin North Am* 43(1): 167–78, vii.
- Tarnow, D., N. Elian et al. (2003). "Vertical distance from the crest of bone to the height of the interproximal papilla between adjacent implants." *J Periodontol* 74(12): 1785–8.
- Torabinejad, M., P. Anderson et al. (2007). "Outcomes of root canal treatment and restoration, implant-supported single crowns, fixed partial dentures, and extraction without replacement: a systematic review." *J Prosthet Dent* 98(4): 285–311.
- Waldman, A. B. (2008). "Smile design for the adolescent patient—interdisciplinary management of anterior tooth size discrepancies." *J Calif Dent Assoc* 36(5): 365–72.
- Zitzmann, N. U., M. D. Margolin et al. (2008). "Patient assessment and diagnosis in implant treatment." *Aust Dent J* 53 Suppl 1: S3–10.

WWW.HIGHDENT.IR

همیار دندانسازان و دندانپزشکان

Case 18

Case 18

Management of a patient with maxillary canine transposition

CASE STORY

A 15-year-old Hispanic male patient presents with anterior aesthetic concerns due to clinically absent maxillary central incisors and transposed maxillary canines with lateral incisors (i.e., the patient's maxillary canines are in the central incisor position). The patient's chief complaint is the following: "I would like a normal smile. The kids at school call me a vampire and make fun of me." The patient is congenitally missing the maxillary central incisors (8 and 9). He has a low caries index with several sound class I amalgam restorations. The patient's mandibular teeth are intact.

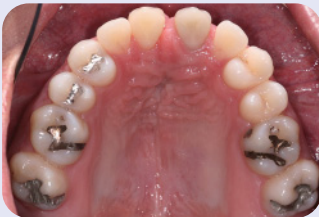

Figure 1: Preoperative maxilla.

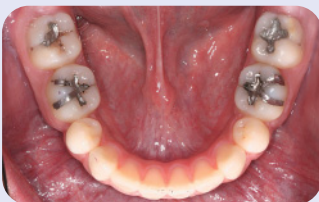

Figure 2: Preoperative mandible.

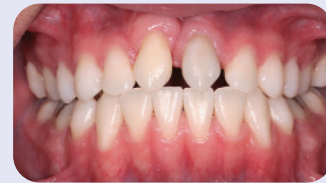

Figure 3: Preoperative presentation.

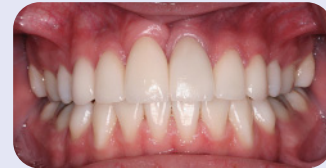

Figure 4: Postoperative presentation.

LEARNING GOALS AND OBJECTIVES

- To diagnose and manage transposition
- To evaluate and establish aesthetic parameters
- To establish parameters for tooth preparation for porcelain laminate veneers
- To select appropriate materials for porcelain laminate veneer therapy

Medical History

- No significant medical conditions
- Seasonal allergies

Dental History

- Regular dental visits since the age of 5 years
- No parafunctional oral habits

- Brushes two times daily, does not floss, but does rinse with an over-the-counter fluoride mouth rinse
- Recently received class I amalgam restorations in mandibular molars, maxillary molars, and premolars
- Reports a "normal" diet with minimal snacking and few sweets

Medications and Allergies

- No known drug allergies

Review of Systems

- No significant findings
- Vital signs:
 - Blood pressure: 110/72
 - Heart rate: 72 beats/minute
 - Respiratory rate: 16 breaths/minute

Social History

- Attends high school
- Smoking: denies any use of tobacco
- Alcohol: denies any use of alcohol or recreational drugs
- Denies any use of tobacco

Extraoral Examination

- Head: normocephalic, symmetric, no masses or scars
- Neck: within normal limits
- Muscles: within normal limits
- Lymph nodes: within normal limits
- TMJ: No clicks, pops, or tenderness: normal range of motion, no deviation on opening or closing

Soft Tissue Examination

- Lips: moist, symmetrical, and normal shape, size, and color
- Mucosa: pink with slight inflammation, patent Stenson's duct, no masses, scars, or lesions
- Hard palate: normal size, shape, and rugae present
- Soft palate: normal size and shape
- Frena: within normal limits
- Tongue: Normal size and shape, no masses, scars, or lesions
- Saliva: normal flow and consistency
- Floor of mouth: within normal limits; patent Wharton's duct; no masses, scars, or lesions
- Oral cancer screening: negative for clinical signs of oral cancer

Charting

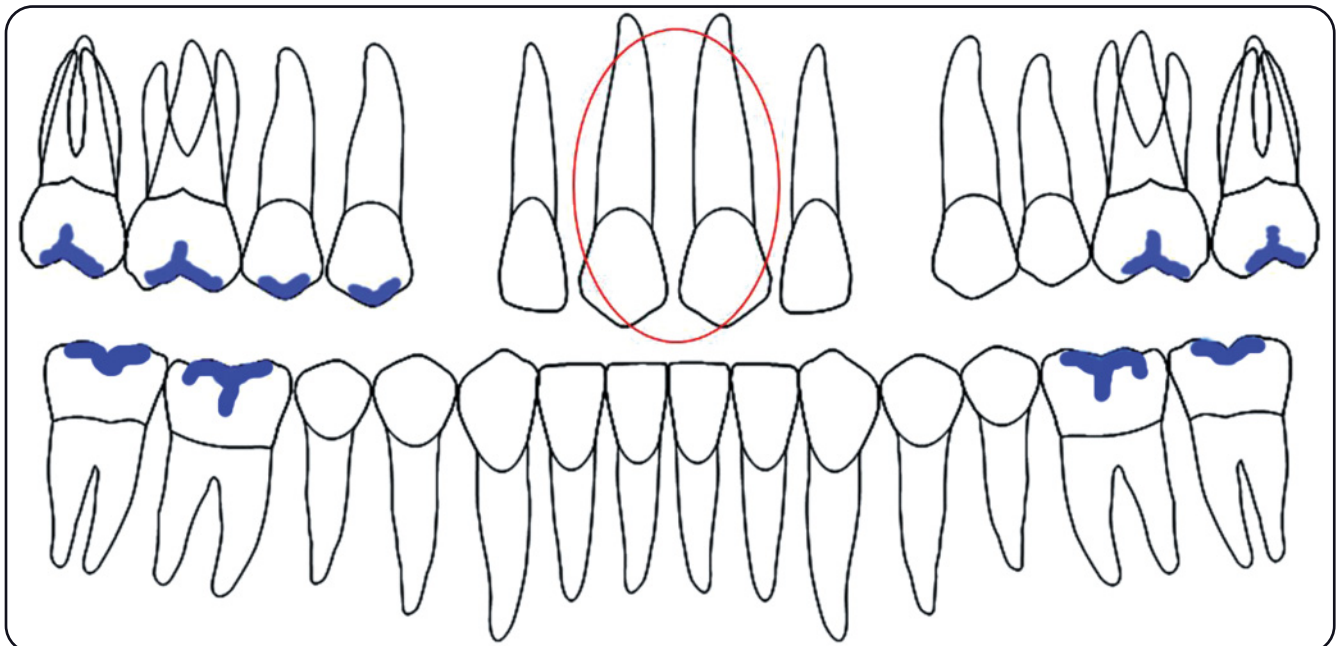


Figure 5: Dental charting.

Clinical Findings/Problem List

- Poor oral hygiene
- Aesthetics
- Transposition—rotated and missing teeth

Diagnosis

- Generalized mild gingivitis
- Transposition of maxillary canines (6 and 11)
- Missing maxillary central incisors (8 and 9)

Clinical Decision-Making Determining Factors

- Transposition is a form of ectopic eruption in which there is a positional substitution of two permanent teeth, typically within the same quadrant. There are two types of transpositions:
 - Complete transposition: both the crown and root of the tooth are transposed
 - Partial transposition: the root remains in the normal position.
- In this complete transposition case, a great aesthetic concern is presented. The treatment of these patients frequently requires a multidisciplinary treatment approach to achieve clinical success (Shapira and Kufte 2001; Ohshima, Nagai et al. 2007).
- It is helpful to consider the following factors in smile analysis when planning and phasing reconstructive treatment:
 - Extraoral frame and reference:
 - Vertical references: facial and dental midlines
 - Horizontal references: hairline, eyebrows, interpupillary line, commissural line, lip line, incisal plane, gingival exposure
 - Sagittal references: profile convexity, lip protrusion, amount of chin
 - Intraoral proportion (golden proportion): Treatment options to consider for congenitally transposed or missing teeth are either to create space for the replacement of teeth or to eliminate space orthodontically and correct teeth shape prosthetically. Prosthetic correction of the tooth anatomy is achieved by complete or partial

coverage restorations depending on the condition of the existing teeth. The golden proportion rule describes proportionality of teeth in relation to each other and is a good starting guide in reestablishing aesthetics. In this case the proportion of the desired width of the lateral incisor to the central incisor would be 1:1.618.

Other general factors to consider in the reconstruction phase are amount of incisal display, upper lip position, relationship of maxillary teeth to the lower lip, tooth size, axial inclination, anterior plane of occlusion, tooth shade, amount of gingival exposure, soft tissue symmetry and contour.

- Phonetics: The position and contour of the maxillary anterior teeth is dictated by aesthetics and phonetics. Important phonetic parameters are the pronunciation of
 - Fricative ("f" and "v") sounds—the edge of the maxillary central incisors should contact the wet and dry border of the lower lip when viewed in patient's profile.
 - Sibilant ("s") sounds—when a patient phonates sibilant sounds (i.e., counting from sixty to seventy) the proximity of the maxillary and mandibular anterior teeth is such that they should not contact and should show a clearance of at least 1–2 mm. This distance is necessary for proper speech and is commonly known as minimum speech distance or closest speaking space. This guide can be used as a determinant of tooth length.
 - These together with display of 1/3 of incisal crown at rest help determine the ideal proportion and length of maxillary anterior teeth.
- Provisionalization: Adjustments to the provisionals should be made until a clinically acceptable outcome has been achieved and the patient's aesthetic needs have been attained using the above-mentioned guidelines (Preston 1976; Pound 1977; Ricketts 1981; Kokich, Nappen et al. 1984; Fayz, Eslami et al. 1987; Silverman 2001; Sarver and Ackerman 2003; Jahangiri, Luu et al. 2006).

Questions

1. During the initial patient exam, it was observed that the positions of the maxillary canines and central incisors are reversed. The relative position of these two teeth represents a common form of

- A. Germination
- B. Malposition
- C. Transposition
- D. Apposition

2. Misaligned teeth often present an aesthetic compromise that may or may not be corrected by restorations. Which of the following can be helpful in preoperative planning?

- A. Diagnostic casts
- B. Diagnostic wax-ups
- C. Orthodontic evaluation
- D. All of the above

3. All of the following are clinical indications for porcelain veneer placement *except*

- A. Tooth color modification
- B. Contour modification
- C. Tooth position modification
- D. Tooth replacement

4. Which of the following occlusal relationships poses the greatest risk for fracture with porcelain veneers?

- A. Class I occlusion
- B. Edge-to-edge anterior tooth relationship
- C. Class II occlusion, division I
- D. Anterior open bite

5. When placing porcelain laminate veneers to mask tooth discoloration, what factors should be considered?

- A. Suggest tooth whitening prior to final shade selection.
- B. Use an opaque resin cement to help mask the discoloration.
- C. Use an opacious type of porcelain.
- D. All of the above

6. When considering porcelain laminate veneer therapy during the diagnostic phase, what extra-oral factors should be considered?

- A. Facial midline
- B. Soft tissue symmetry
- C. Dental midline
- D. Amount of gingival display

7. When considering porcelain laminate veneer therapy(s) during the diagnostic phase, what intraoral factors should be considered?

- A. Incisive papilla
- B. Position of the philtrum
- C. Soft tissue symmetry, contour, and the amount of gingival display
- D. Amount of gingival pigmentation

8. When considering phonetics, which sound(s) helps to determine the appropriate vertical dimension of occlusion?

- A. "ch"
- B. "f" and "v"
- C. "s"
- D. All of the above

9. When considering phonetics, which sound(s) helps to determine the appropriate incisor length?

- A. "m"
- B. "ch"
- C. "s"
- D. All of the above

10. True or False: An occlusal guard should be constructed after insertion of porcelain laminate veneers to help protect the restorations and the opposing dentition.

- A. True
- B. False

ANSWERS

1. C (Bhaskar 1977; Jahangiri, Luu et al. 2006)
2. D (Shapira and Kuflinec 2001; Demir, Basciftci et al. 2002)
3. D (Calamia 1985; Shapira and Kuflinec 2001)
4. B (Crispin 1994)
5. D (Exner 1991)

6. A (Christensen 1985; Sarver and Ackerman 2003; Charchut and Ferguson 2002)
7. C (Christensen 1985; Magne and Belser 2004)
8. C (Pound 1977)
9. C (Pound 1977)
10. True (Goldstein 1998)

The authors would like to acknowledge and thank Dr. Barbara Jurim for the clinical case photographs and treatment performed at New York University, College of Dentistry.

References

- Bhaskar, S. N. (1977). *Synopsis of oral pathology*. Saint Louis, Mosby.
- Calamia, J. R. (1985). "Etched porcelain veneers: the current state of the art." *Quintessence Int* 16(1): 5–12.
- Charchut, S., Ferguson M. (2002). "Achieving excellence in the predoctoral clinic: a porcelain veneer case report." *J Cosmet Dent* 18(1).
- Christensen, G. J. (1985). "Veneering of teeth. State of the art." *Dent Clin North Am* 29(2): 373–91.
- Crispin B. J. (1994) *Contemporary esthetic dentistry: practice fundamentals*, Tokyo, Quintessence Publishing Co.
- Demir, A., F. A. Basciftci et al. (2002). "Maxillary canine transposition." *J Clin Orthod* 36(1): 35–7.
- Exner, H. V. (1991). "Predictability of color matching and the possibilities for enhancement of ceramic laminate veneers." *J Prosthet Dent* 65(5): 619–22.
- Fayz, F., A. Eslami et al. (1987). "Use of anterior teeth measurements in determining occlusal vertical dimension." *J Prosthet Dent* 58(3): 317–22.
- Goldstein, R. E. (1998). *Esthetics in dentistry*. Hamilton, Ont., B. C. Decker.
- Jahangiri, L., L. Luu et al. (2006). "A multidisciplinary approach for treating congenitally transposed canines: a clinical report." *J Prosthet Dent* 95(6): 413–6.
- Kokich, V. G., D. L. Nappen et al. (1984). "Gingival contour and clinical crown length: their effect on the esthetic appearance of maxillary anterior teeth." *Am J Orthod* 86(2): 89–94.
- Magne, P. and U. C. Belser (2004). "Novel porcelain laminate preparation approach driven by a diagnostic mock-up." *J Esthet Restor Dent* 16(1): 7–16; discussion 17–8.
- Ohayama, H., S. Nagai et al. (2007). "Recreating an esthetic smile: a multidisciplinary approach." *Int J Periodontics Restorative Dent* 27(1): 61–9.
- Pound, E. (1977). "Let /S/ be your guide." *J Prosthet Dent* 38(5): 482–9.
- Preston, J. D. (1976). "A systematic approach to the control of esthetic form." *J Prosthet Dent* 35(4): 393–402.
- Ricketts, R. M. (1981). "The golden divider." *J Clin Orthod* 15(11): 752–9.
- Sarver, D. M. and M. B. Ackerman (2003). "Dynamic smile visualization and quantification: Part 2. Smile analysis and treatment strategies." *Am J Orthod Dentofacial Orthop* 124(2): 116–27.
- Shapira, Y. and M. M. Kuflinec (2001). "Maxillary tooth transpositions: characteristic features and accompanying dental anomalies." *Am J Orthod Dentofacial Orthop* 119(2): 127–34.
- Silverman, M. M. (2001). "The speaking method in measuring vertical dimension. 1952." *J Prosthet Dent* 85(5): 427–31.

Case 19

Case 19

Management of a patient with loss of posterior support

CASE STORY

A 51-year-old female presents with failing fixed partial dentures. Her chief complaint is "My teeth are breaking and I have nothing to chew on."

The patient has lost her posterior teeth due to caries, failed endodontic treatment, and periodontal disease. Her previous restorations were placed approximately 11 years ago in the maxilla. The deterioration of her condition started about 1 year ago, when the fixed partial denture in the maxillary right side failed. She had noticed a slight discomfort prior to this event.

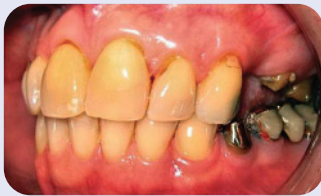

Figure 1: Preoperative left side.

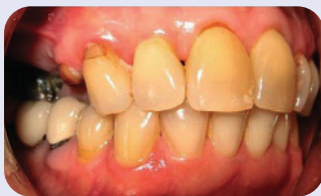

Figure 2: Preoperative right side.

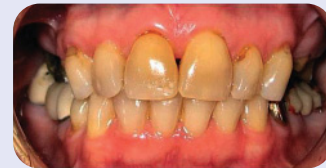

Figure 3: Preoperative presentation.

LEARNING GOALS AND OBJECTIVES

- To recognize the consequences of loss of posterior support
- To apply appropriate treatment modalities in a partially edentulous patient

Medical History

- Hypertension
- Hypercholesterolemia

Dental History

- Multiple extractions due to caries, failed endodontic treatment, and periodontal disease
- Fracture and loss of maxillary fixed partial denture 1 year ago
- Last dental visit was approximately 1.5 years ago when she was advised that some of her restorations needed to be replaced due to caries. Patient was not able to follow up with the planned dental work prescribed by her dentist.

Medications and Allergies

- Norvasc—5mg daily
- Lipitor—20mg daily
- No known drug allergies

Review of Systems

- Blood pressure and cholesterol levels are well controlled
- Vital signs:
 - Blood pressure: 130/88
 - Heart rate: 68 beats/minute
 - Respiration rate: 16 breaths per minute

Social History

- Alcohol: occasional social use
- Recreational drugs: denies ever using any

Extraoral Examination

- Muscles: slightly tender/sore
- TMJ: Left side clicks; patient experiences tenderness upon closing and opening; relatively normal range of motion; no deviations noted upon opening and closing

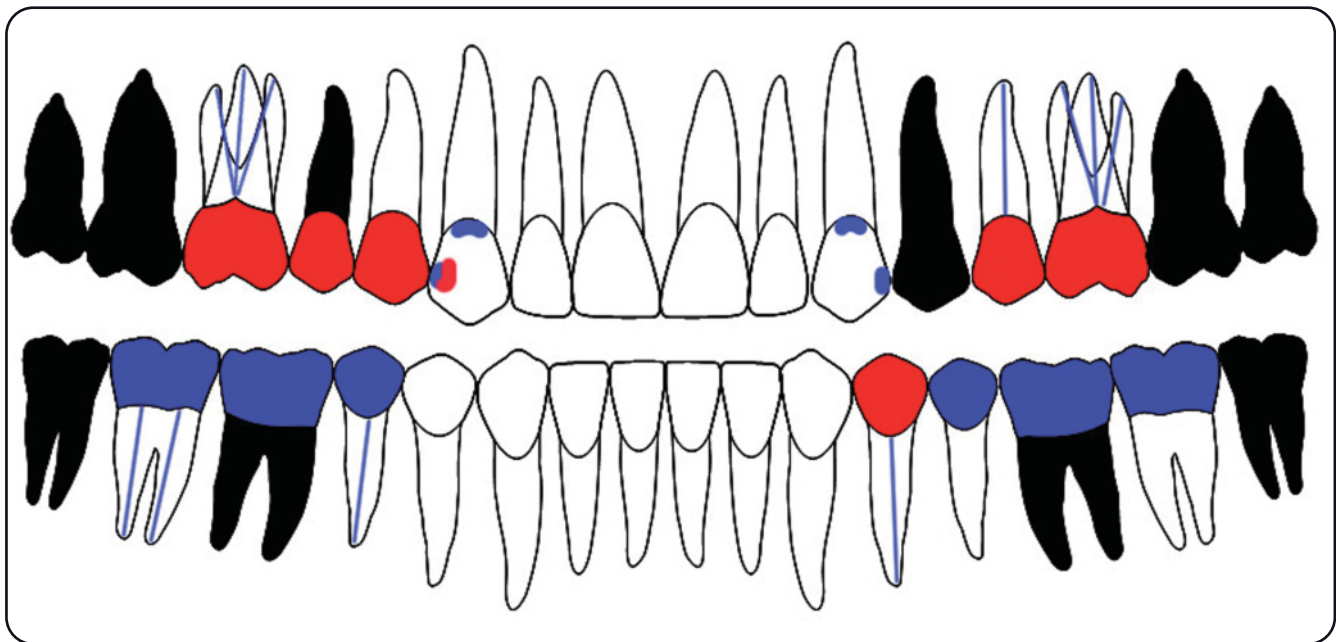
Charting

Figure 4: Dental charting.

Clinical Findings/Problem List

- Partial edentulism
- Failing existing restorations
- Inadequate oral hygiene
- Poor masticatory function
- Loss of posterior support

Radiographic Findings

(See Figs. 5, 6, and 7.)

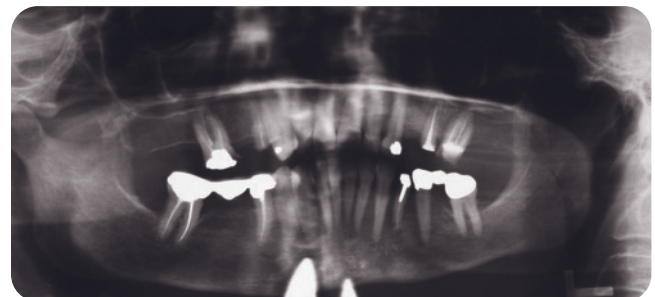


Figure 5: Panoramic radiograph.

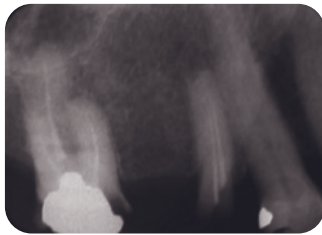


Figure 6: Caries, into furcation area of molar, periapical pathology, and root resorption on premolar.

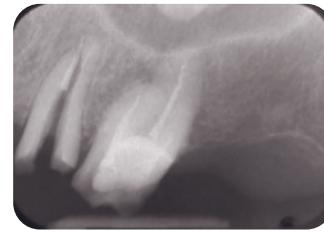


Figure 7: Periapical pathology and root fracture.

Diagnosis

- Loss of posterior support
- Generalized mild periodontitis
- Caries
- Multiple root fractures
- Reduced salivary flow

Clinical Decision-Making Determining Factors

- The loss of posterior teeth may result in compromised function and aesthetics. Establishment of a stable posterior occlusion is thought to be of significant importance in stabilizing the anterior dentition. In this case, the long term prognosis for the remaining maxillary anterior teeth is compromised without posterior support. In this patient's case, it is necessary to extract the maxillary posterior remaining teeth (2, 4, 13, and 14) because they are not restorable due to extensive caries, fractures, and periodontal disease. It is vital to restore these posterior missing teeth with a transitional removable partial denture as an interim prosthesis during treatment. This will aid in reestablishing posterior support as well as the proper plane of occlusion. The method of restoration of missing teeth is dictated by the patient's health, age, dietary habits, oral hygiene practices, condition of the existing dentition, and finances (Walton, Gardner et al. 1986; Binkley and Binkley 1987).
- Prosthetic rehabilitation of a patient with missing posterior teeth should include proper

provisionalization. The patient should remain in provisionals long enough for reevaluation of form, function, and aesthetic components of the interim prosthesis. The prosthesis should be adjusted as needed, prior to fabrication and delivery of the final prosthesis. This will allow for evaluation of temporomandibular joint comfort as well as function of the muscles of mastication as the patient adapts to the new occlusal scheme (Reynolds 1968; Kaplan 1985; Verrett 2001).

- Decreased salivary flow/dry mouth secondary to prescribed medications is a common side effect. The decrease of salivary flow can cause rampant caries and oral candidiasis, which can ultimately result in tooth loss and occlusal disharmony. The causes of xerostomia are numerous. The main causes of xerostomia include medication, radiation, and Sjögren's syndrome. Management of this condition includes good hydration, optimal oral hygiene, and the use of saliva inducers such as lozenges or gum (Edgar 1990).
- Effective treatment outcomes of extensive restorations for patients with chronic salivary hypofunction requires a combination of continuous dental decay prevention and treatment, salivary flow stimulation, recognition and treatment of chronic oral candidiasis, and/or the selective use of saliva substitutes (Axelsson 1990).

Questions

1. When replacing failed restorations, it is important to understand the etiology of the failure.

Which item(s) below is *not* an etiologic factor?

- A. Decreased salivary flow, resulting in recurrent caries
- B. Type of ceramic chosen and shade selected
- C. Periodontal breakdown, causing tooth mobility
- D. Occlusal discrepancies

2. Endodontically treated abutment teeth that have been restored with a post, core, and crown are subject to high incidence of

- A. The need for an apicoectomy
- B. Periodontal disease
- C. Recurrent caries
- D. Root fracture

3. When determining the restorability of an abutment tooth, which of the following statements is *false*?

- A. All caries should be removed first to evaluate whether the remaining tooth structure can support a prosthesis.
- B. The crown-to-root ratio and the angulation of the abutment should be adequate.
- C. Periodontal health should be evaluated.
- D. The tooth should be vital.

4. Factors to consider when evaluating a patient's occlusion includes all of the following *except*

- A. Missing teeth
- B. Drifting, tipping, or supraeruption of teeth
- C. Carious loss of tooth structure
- D. Metal occlusal contacts

5. Which of the following are factors to be considered when reestablishing the plane of occlusion with a removable partial denture?

- A. Vertical maxillomandibular relationship
- B. Horizontal maxillomandibular relationship
- C. Cuspal inclination
- D. All are important.

6. When treatment planning for fixed partial dentures, what information *cannot* be ascertained by diagnostic casts alone?

- A. The inclination of the abutment teeth
- B. The presence of periodontal pockets and the crown-to-root ratio of potential abutment teeth
- C. Mesialdistal drifting of teeth with respect to the rest of the arch
- D. Interocclusal space

7. The minimum crown-to-root ratio of a tooth to be utilized as an abutment for a fixed partial denture is

- A. 1:1
- B. 2:1
- C. 3:1
- D. 4:1

8. Possible choices for reestablishing posterior occlusion in this case include all of the following *except*

- A. Bilateral distal extension cast partial denture
- B. Bilateral implant-supported fixed partial dentures
- C. Single-unit implants bilaterally
- D. Fixed partial dentures

ANSWERS

1. B (Valderhaug and Heloe 1977; Walton, Gardner et al. 1986; De Backer, Van Maele et al. 2008)
2. D (Reichen-Graden and Lang 1989; Heffernan, Martin et al. 2003)
3. D (Reynolds 1968; Kabcenell 1975)
4. D (Kaplan 1985)

5. D (Baraban 1962; Beckett 1954)
6. B (Reynolds 1968)
7. A (Reynolds 1968; Brehm 1973)
8. D (Brehm 1973; Kabcenell 1975; Ohyama, Nagai et al. 2007)

The authors would like to acknowledge and thank Group Practices at New York University College of Dentistry for clinical case photographs.

References

- Axelsson, P. (1990). "Method for determining caries risk." *Phillip J* 7(4): 181–7.
- Baraban D. J. (1962). "Establishing centric relation and vertical dimension in occlusal rehabilitation." *J Prosthet Dent* 12: 1157–1165.
- Beckett L. S. (1954). "Accurate occlusal relations in partial denture construction." *J Prosthet Dent* 4: 487–495.
- Binkley, T. K. and C. J. Binkley (1987). "A practical approach to full mouth rehabilitation." *J Prosthet Dent* 57(3): 261–6.
- Brehm, T. W. (1973). "Diagnosis and treatment planning for fixed prosthodontics." *J Prosthet Dent* 30(6): 876–81.
- De Backer, H., G. Van Maele et al. (2008). "An up to 20-year retrospective study of 4-unit fixed dental prostheses for the replacement of 2 missing adjacent teeth." *Int J Prosthodont* 21(3): 259–66.
- Edgar, W. M. (1990). "Saliva and dental health. Clinical implications of saliva: report of a consensus meeting." *Br Dent J* 169(3–4): 96–8.
- Heffernan, M., W. Martin et al. (2003). "Prognosis of endodontically treated teeth? Point." *Quintessence Int* 34(7): 558–60.
- Kabcenell, J. L. (1975). "Planning for individualized prosthetic treatment." *J Prosthet Dent* 34(4): 389–92.
- Kaplan, P. (1985). "Drifting, tipping, supraeruption, and segmental alveolar bone growth." *J Prosthet Dent* 54(2): 280–3.
- Ohyama, H., S. Nagai et al. (2007). "Recreating an esthetic smile: a multidisciplinary approach." *Int J Periodontics Restorative Dent* 27(1): 61–9.
- Reichen-Graden, S. and N. P. Lang (1989). "Periodontal and pulpal conditions of abutment teeth. Status after four to eight years following the incorporation of fixed reconstructions." *Schweiz Monatsschr Zahnmed* 99(12): 1381–5.
- Reynolds, J. M. (1968). "Abutment selection for fixed prosthodontics." *J Prosthet Dent* 19(5): 483–8.
- Valderhaug, J. and L. A. Heloe (1977). "Oral hygiene in a group of supervised patients with fixed prostheses." *J Periodontol* 48(4): 221–4.
- Verrett, R. G. (2001). "Analyzing the etiology of an extremely worn dentition." *J Prosthodont* 10(4): 224–33.
- Walton, J. N., F. M. Gardner et al. (1986). "A survey of crown and fixed partial denture failures: length of service and reasons for replacement." *J Prosthet Dent* 56(4): 416–21.

Case 20

Case 20

Management of the consequences of partial edentulism

CASE STORY

A 46-year-old male patient presents with the chief complaint of "I need some teeth in the lower right side, and I was also told I need a crown on a tooth that had a root canal." About 5 years ago, the patient had first and second molars on his mandibular right side (30 and 31) removed due to extensive decay. Endodontic therapy was completed on his maxillary left first molar (14) at that time; however, no definitive restoration was placed on the tooth. The patient also expresses interest in a more aesthetic smile.

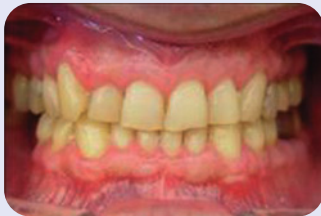

Figure 1: Preoperative presentation.

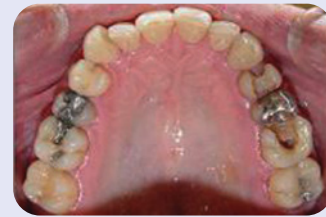

Figure 2: Preoperative maxilla.

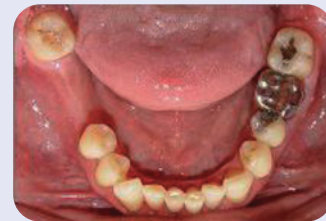

Figure 3: Preoperative mandible.

Radiographic Findings

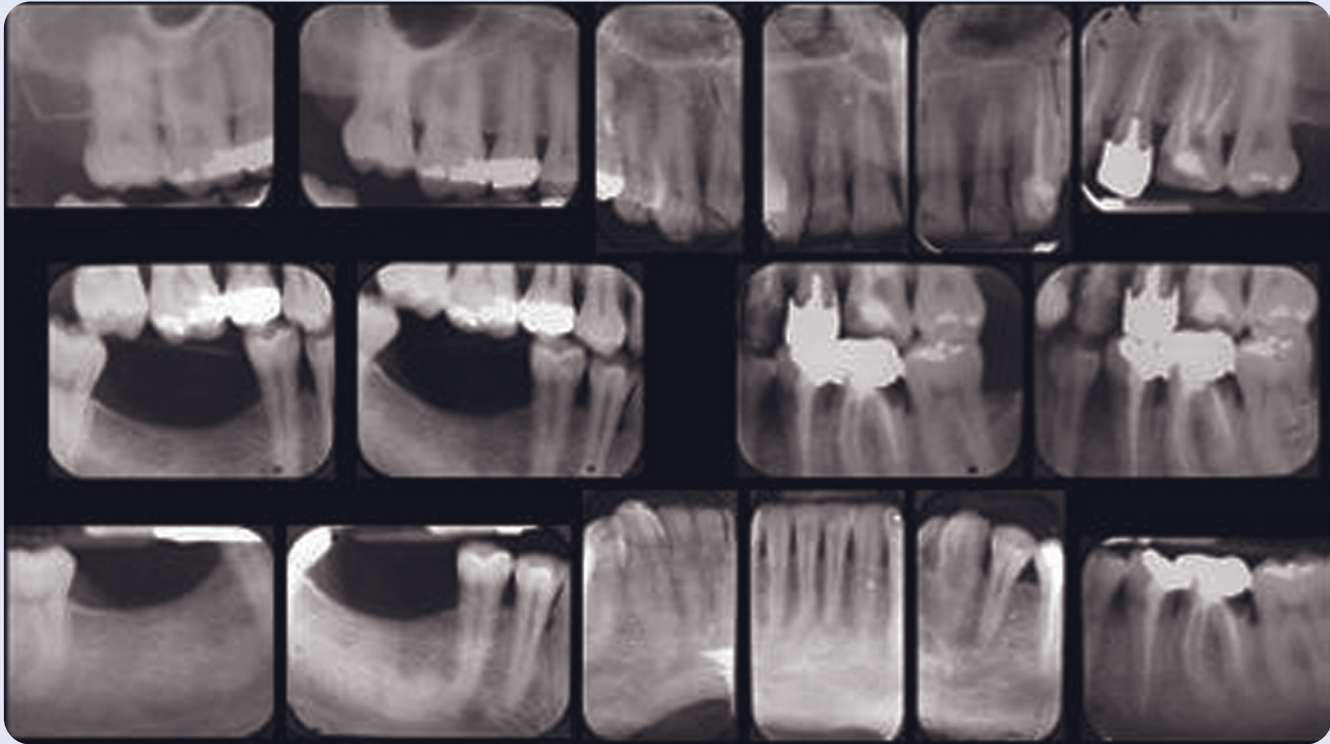


Figure 4: Preoperative full mouth series of radiographs.

LEARNING GOALS AND OBJECTIVES

- Understanding the sequelae of excessive tooth wear
- Evaluation of treatment options for nonrestorable teeth
- Evaluation and planning for correction of supraeruption of teeth
- Evaluation of aesthetics

Medical History

- No significant findings

Dental History

- Patient received regular dental care until about 5 years ago.

- History of restorative and endodontic therapy and extractions
- No history of orthodontic or periodontic therapy
- Patient brushes only before sleep and does not floss.

Medications and Allergies

- No medications
- No known drug allergies

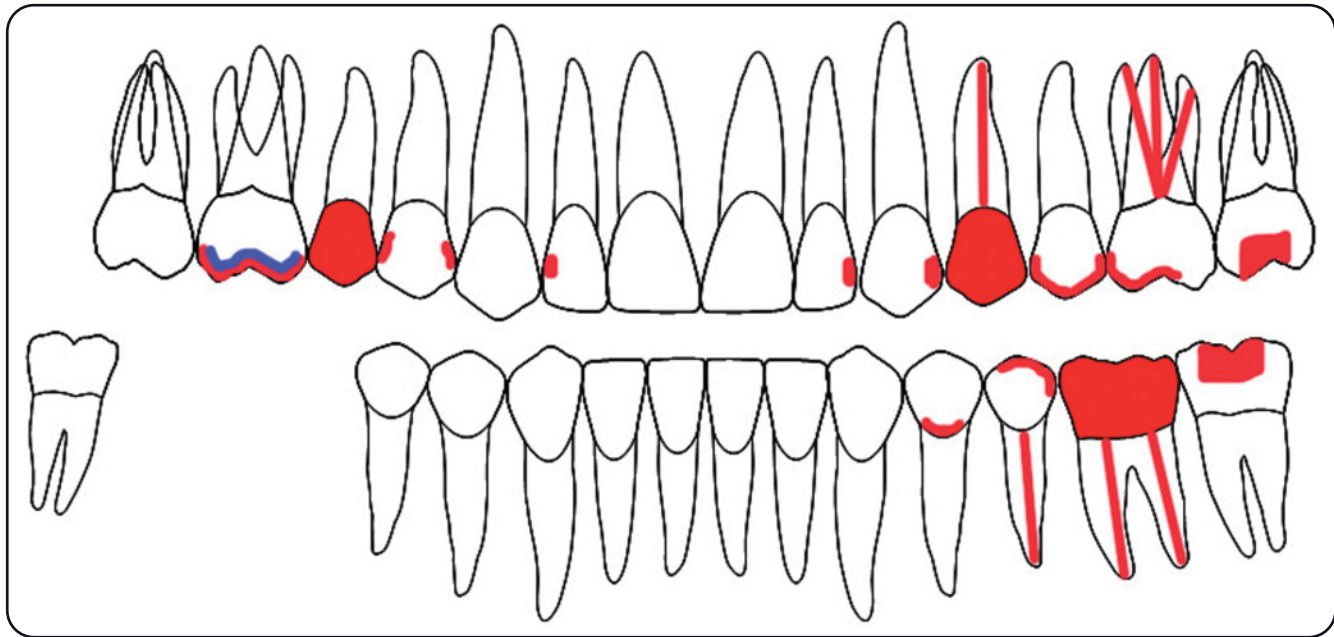


Figure 5: Dental charting.

Charting

Significant Clinical Findings/Problem List

- Plaque-induced gingivitis
- Missing teeth: maxillary third molars (1, 16), mandibular left third molar (17), mandibular right first and second molars (30, 31)
- Caries:
 - Maxillary right first molar—3MOD
 - Maxillary right second premolar—4 open margin
 - Maxillary right first premolar—5MD
 - Maxillary right lateral incisor—7D
 - Maxillary left lateral incisor—10M
 - Maxillary left canine—11D
 - Maxillary left first premolar—12MOD
 - Maxillary left second premolar—13MOD
 - Maxillary left first molar—14MO
 - Maxillary left second molar—15OL
 - Mandibular left second molar—18OB
 - Mandibular left first molar—19DO
 - Mandibular left second premolar—20DO
 - Mandibular left first premolar—21B
- Inadequate endodontic therapy: maxillary left first premolar and first molar (12, 14) and mandibular left first molar and second premolar (19, 20)

Diagnosis

- Partial edentulism
- Plaque-induced gingivitis
- Caries

- Inadequate restorations
- Inadequate endodontic therapy

Clinical Decision-Making Determining Factors

- In determining restorability of a single tooth, several prognostic factors must be considered. These factors include endodontic retreatment, periodontal procedures, and amount of remaining tooth structure after caries excavation. The overall dental treatment of the patient also should be taken into consideration (Torabinejad, Anderson et al. 2007; Salinas and Eckert 2007; Balevi 2008).
- In considering the prognosis and restorability of teeth, several factors have to be considered:
 - Prognosis of endodontic retreatment of a tooth without apical periodontitis—studies have shown more than 90% survival rate of these teeth after a 4–6-year follow-up.
 - Whether the tooth will require a crown-lengthening procedure for placement of restoration without violation of the biologic width.
 - Prognosis of the tooth following exposure of the furcation area after crown-lengthening procedure—teeth with furcation involvement are difficult to maintain by the patient and the dental professional because access for hygiene is limited.
 - A crown-lengthening procedure for a tooth with poor prognosis would compromise bone volume in a future implant site.

- The amount of remaining tooth structure will be compromised after removal of previous restoration and caries excavation (Farzaneh, Abitbol et al. 2004; Friedman and Mor 2004; Newman, Takei et al. 2006).
- Management of tooth wear is an integral part of treatment planning. The pattern, etiology, and severity must be considered prior to completion of a treatment plan. Depending on the severity of the condition, more or less aggressive treatment is required (Verrett 2001; Turner and Missirlan 1984).
- In analyzing anterior aesthetics, a diagnostic wax-up is often employed in order to guide treatment planning and treatment itself. A diagnostic wax-up can provide crucial information for all parties involved in treatment and can allow for a more efficient and predictable treatment outcome (Kois, Schmidt et al. 2008).
- Supraeruption of unopposed teeth poses a treatment challenge when it results in compromised interocclusal space and plane of occlusion. This phenomenon must be addressed in the comprehensive treatment plan in order to ensure successful treatment (Kaplan 1985).

Questions

1. Considering the factors mentioned above (in “Clinical Decision-Making Determining Factors”), would restoration of the left mandibular first molar be advised?

- A. Yes, because endodontic prognosis is favorable despite poor periodontal and restorative prognosis.
- B. Yes, because periodontal maintenance will be easy.
- C. No, because the overall periodontal and restorative prognosis of the tooth will be poor.
- D. No, only because periodontal prognosis is poor.

2. After evaluation of the endodontic, periodontal, and restorative prognosis of the mandibular left first molar (19), it is decided that the tooth is unrestorable. What is a possible restorative treatment option for this area?

- A. Single-unit implant for mandibular left first molar (19)
- B. Fixed partial denture from the second molar to the second premolar (18-X-20), including a dowel and core for the second premolar
- C. Removable partial denture to replace missing molars on the right and left sides (19, 30, 31)
- D. All are possible options.

3. After discussing treatment options for the edentulous areas in the mandible, the patient is most interested in replacing the teeth with endosseous implants and implant crowns. What evaluation criteria will need to be examined in order to determine suitability for implant placement in the mandible?

- A. Height of available bone
- B. Buccolingual and mesiodistal width of available bone
- C. Location of the mandibular canal
- D. Existence of osseous pathology
- E. All of the above

4. This patient exhibits signs of wear, limited to the edges of the anterior teeth. It is determined that the patient has attrition of the anterior teeth. Attrition is best described as

- A. Mechanical wear of the dentition usually caused by masticatory or parafunctional habits
- B. Mechanical wear of teeth caused by chewing on objects
- C. Chemical wear of teeth caused by acidic processes of a bacterial infection
- D. Chemical wear of teeth caused by acidic food intake
- E. Chemical wear of teeth caused by acid regurgitation due to gastrointestinal disorders

5. In order to manage the minimal attrition of the anterior teeth in this patient with no loss of vertical dimension, what treatment may be recommended?

- A. Full coverage restorations on the maxillary anterior teeth
- B. Full coverage restorations on the maxillary and mandibular anterior teeth
- C. Full coverage of all teeth in the maxilla and mandible
- D. Fabrication of a occlusal appliance to minimize the effects of parafunctional habit

6. In addressing the patient's desire for better aesthetics of the anterior teeth, a diagnostic wax-up is created. Which is a use of a diagnostic wax-up?

- A. Depiction of treatment outcomes for patient education
- B. Use as a guide for fabrication of provisionals
- C. Use as a guide for tooth preparation
- D. Use for communication with the lab
- E. All of the above

7. Part of the comprehensive treatment plan for this patient will include porcelain laminate veneers for the maxillary anterior teeth (6–11). What factors will reduce the risk for veneer fracture?

- A. Tooth reduction extending into dentin
- B. Occlusal contacts to be maintained on unprepared natural teeth
- C. Subgingival margins
- D. Preparation wrapping to the palatal on the mesial and distal surfaces

8. An unopposed maxillary right first molar (3) has slightly supraerupted. What should be done ideally to restore the plane of occlusion, considering the mandibular right quadrant will be restored as well?

- A. Extract the tooth and replace with an implant and implant crown.
- B. Orthodontically intrude the tooth.
- C. Place a partial coverage restoration with ideal contours to correct the occlusal discrepancy.
- D. The tooth should not be treated because the discrepancy will not affect the treatment outcome.

9. Supposing that successful endodontic retreatment was achieved for the maxillary left second premolar (13), a new dowel and core is required. In preparing the dowel space, a minimum of 4–5 mm of gutta percha must remain at the apex in order to maintain the apical seal. For best results, what other guideline should be used? (See Fig. 7.)

- A. The dowel should be shorter than the clinical crown.
- B. The diameter of the dowel should be at least half of the diameter of the tooth.
- C. The dowel should be equal to or longer than the clinical crown.
- D. The dowel should be smooth and tapered.

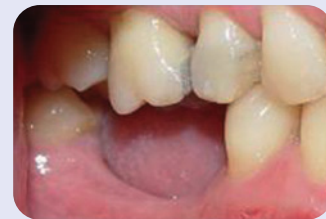

Figure 6: Supraeruption of maxillary right first molar.

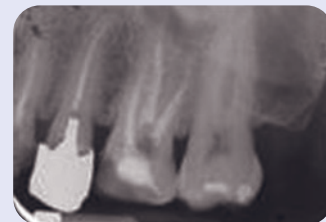

Figure 7: Periapical radiograph of maxillary left side.

ANSWERS

1. C (Farzaneh, Abitbol et al. 2004; Friedman and Mor 2004; Newman, Takei et al. 2006)
2. D (Torabinejad, Anderson et al. 2007; Salinas and Eckert 2007; Balevi 2008)
3. E (Misch 1999)
4. A (Verrett 2001)

5. D (Macedo, Silva et al. 2007)
6. E (Magne, Magne et al. 1996)
7. B (Sadowsky 2006)
8. C (Kaplan 1985) (Okeson 1998)
9. C (Shillingburg 1997)

The authors would like to acknowledge and thank Group Practices at New York University College of Dentistry for clinical case photographs.

References

- Balevi, B. (2008). "Root canal therapy, fixed partial dentures and implant-supported crowns, have similar short term survival rates." *Evid Based Dent* 9(1): 15–7.
- Farzaneh, M., S. Abitbol et al. (2004). "Treatment outcome in endodontics: the Toronto study. Phases I and II: Orthograde retreatment." *J Endod* 30(9): 627–33.
- Friedman, S. and C. Mor (2004). "The success of endodontic therapy—healing and functionality." *J Calif Dent Assoc* 32(6): 493–503.
- Kaplan, P. (1985). "Drifting, tipping, supraeruption, and segmental alveolar bone growth." *J Prosthet Dent* 54(2): 280–3.
- Kois, D. E., K. K. Schmidt et al. (2008). "Esthetic templates for complex restorative cases: rationale and management." *J Esthet Restor Dent* 20(4): 239–48; discussion 249–50.
- Macedo, C. R., A. B. Silva et al. (2007). "Occlusal splints for treating sleep bruxism (tooth grinding)." *Cochrane Database Syst Rev* (4): CD005514.
- Magne, P., M. Magne et al. (1996). "The diagnostic template: a key element to the comprehensive esthetic treatment concept." *Int J Periodontics Restorative Dent* 16(6): 560–9.
- Misch, C. E. (1999). *Contemporary implant dentistry*. St. Louis, Mosby.
- Newman, M. G., H. H. Takei et al. (2006). *Carranza's clinical periodontology*. St. Louis, Saunders/Elsevier.
- Okeson, J. P. (1998). *Management of temporomandibular disorders and occlusion*. St. Louis, Mosby.
- Sadowsky, S. J. (2006). "An overview of treatment considerations for esthetic restorations: a review of the literature." *J Prosthet Dent* 96(6): 433–42.
- Salinas, T. J. and S. E. Eckert (2007). "In patients requiring single-tooth replacement, what are the outcomes of implant- as compared to tooth-supported restorations?" *Int J Oral Maxillofac Implants* 22 Suppl: 71–95.
- Shillingburg, H. T. (1997). *Fundamentals of fixed prosthodontics*. Chicago, Quintessence Pub. Co.
- Torabinejad, M., P. Anderson et al. (2007). "Outcomes of root canal treatment and restoration, implant-supported single crowns, fixed partial dentures, and extraction without replacement: a systematic review." *J Prosthet Dent* 98(4): 285–311.
- Turner, K. A. and D. M. Missirlian (1984). "Restoration of the extremely worn dentition." *J Prosthet Dent* 52(4): 467–74.
- Verrett, R. G. (2001). "Analyzing the etiology of an extremely worn dentition." *J Prosthodont* 10(4): 224–33.

WWW.HIGHDENT.IR

همیار دندانسازان و دندانپزشکان

Case 21

Case 21

Management of worn dentition I—resulting from dental malocclusion

Accurate diagnosis of a malocclusion is essential in determining the proper treatment approach and timing of treatment. The presented case shows the combined effects of malocclusion with tooth wear. In this

chapter, the effects of class III malocclusion, etiology of tooth wear, and treatment approaches are discussed.

CASE STORY

A 45-year-old male patient presents with a chief complaint of “I need to fix my front teeth.” The patient is very concerned with his broken restorations, which had been placed about 1 year ago.

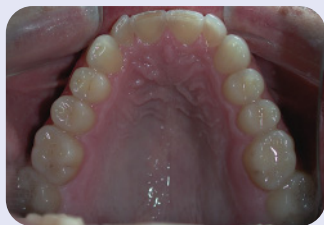

Figure 1: Preoperative maxilla.

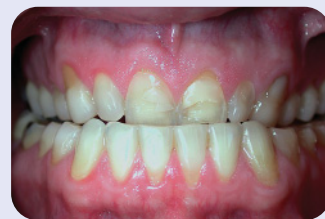

Figure 3: Preoperative presentation.

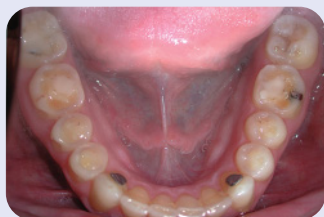

Figure 2: Preoperative mandible.

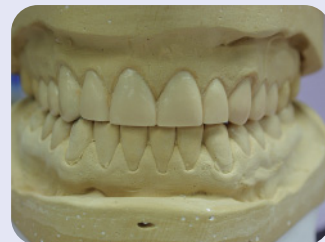

Figure 4: Diagnostic wax-up.

LEARNING GOALS AND OBJECTIVES

- Understand the etiology of tooth wear.
- Understand the different types of wear patterns.
- Identify the clinical criteria for pseudo-class III malocclusion.
- Understand the factors considered in selection of restorative materials for patients exhibiting tooth wear.
- Recognize the advantages of a canine-guided occlusal scheme.

Medical History

- No significant findings

Dental History

- In the past years, the tooth wear had frequently been treated with resin and veneer restorations.
- These restorations were failing, and the patient was seeking more long-term treatment options for functional and aesthetic concerns.

Clinical Findings/Problem List

- Fractured restoration on maxillary right and left central incisors and maxillary left lateral incisor (8, 9, and 10)
- Wear facets on occlusal surfaces of mandibular posterior teeth
- Interview of patient regarding the dietary pattern revealed high frequency of soft drink intake
- Maxillary and mandibular midlines are not coincident

Diagnosis

- Pseudo-class III malocclusion
- Defective restorations on maxillary anterior teeth
- Tooth wear, possibly due to occlusal trauma in the maxillary anterior region
- Mandibular posterior tooth wear due to erosion
- Loss of vertical dimension of occlusion by 2 mm

Clinical Decision-Making Determining Factors

- The characteristics of class III malocclusion can be separated into
 - Skeletal components with a combination of an underdeveloped maxilla and an overdeveloped mandible

- Dentoalveolar components with proclined maxillary incisors
- Retroclined mandibular incisors to achieve dentoalveolar compensation
- The detection of the cause of the discrepancy is essential in developing appropriate treatment (Ngan, Hu et al. 1997; Rabie and Gu 2000).
- Although the dentoskeletal characteristics for pseudo-class III malocclusion are not clearly defined, pseudo-class III malocclusion has been identified with anterior reverse articulation as a result of mandibular displacement. The interference seen in the incisors in pseudo-class III malocclusion is thought to be a result of the retroclined maxillary incisors and proclined mandibular incisors as compared to a true skeletal discrepancy in a class III malocclusion (Lee 1978).
- The treatment of the patient with a class III malocclusion depends on the age at which the patient presents for treatment. Poor aesthetics is often the main reason for seeking treatment (Moss 1976).
- “Tooth surface loss” or “tooth wear” refers to the pathological loss of tooth tissue by a disease process other than dental caries. Tooth wear can be categorized into attrition, erosion, and abrasion:
 - Attrition is defined as the loss of enamel, dentin, or restoration by tooth-to-tooth contact.
 - Erosion is the loss of dental hard tissues by chemical action not involving bacteria. Eating disorders, such as anorexia and bulimia nervosa, or acid reflux and regurgitation are associated with erosion. Dietary components, such as carbonated soft drinks, fruit, and fruit juices, can also be the causes of erosion, especially related to the increased frequency of intake.
 - Abrasion is the loss of tooth structure from factors other than tooth contact (Eccles 1982; Bartlett, Evans et al. 1996; Litonjua, Bush et al. 2004).
- If attrition is the only cause of tooth wear, the wear facets will appear shiny and flat sharp-edged, and produce a similar amount of wear on the opposing teeth (Spear 2008).
- Chemical erosion in which posterior tooth surface loss is greatest at the mandibular first molar and second premolar areas has been associated with holding carbonated soft drinks in the mouth and/or swishing (Verrett 2001).
- Determination of the etiology of chemical wear should involve identification of the wear pattern (Verrett 2001):

- Greater anterior tooth wear, as compared to posterior tooth wear, on the lingual surfaces is associated with chronic regurgitation, eating disorder, gastric acid reflux, and chronic alcoholism.
- Greater anterior tooth wear, as compared to posterior tooth wear, on the facial surfaces of maxillary anterior teeth is related to fruit sucking.
- Greater posterior tooth wear, as compared to anterior tooth wear, on all occlusal surfaces is associated with soda swishing and fruit mauling.
- Selection of an occlusal scheme for fixed restorations is based on the principles of mutually protected occlusion and anterior guidance. Many studies demonstrated that muscle activity decreased in a canine-guided occlusal scheme versus group-function guidance (Shupe, Mohamed et al. 1984; Miralles, Bull et al. 1989; Thornton 1990).
- Patients exhibiting clinical signs and symptoms of parafunctional habits restored with restorations are recommended to have an occlusal device as a part of the postoperative maintenance program. Maxillary occlusal splint with anterior guidance is shown to decrease electromyographic activity of the masseter and temporalis muscles, suggesting that it may act as a protective device against further tooth wear and restoration wear (Jemt, Lundquist et al. 2004).
- Gold (high-noble metal) alloy restorations are shown to wear at approximately the same rate as enamel. Porcelain surfaces must be highly polished and smoothly glazed to reduce damage to opposing teeth and restorations. Resin composite materials are shown to form deep microcracks under cyclic loading (Yip, Smales et al. 2004).
- Vertical dimension of occlusion (VDO) is defined as the distance between two selected points: one on a fixed and one on a movable member. Determination of appropriate VDO is important because if VDO is excessive, tightness of facial muscles and development of temporomandibular disorder can occur. Methods for determining VDO include swallowing, phonetics, patient's own tactile perception, preextraction records, electromyography, aesthetics, and use of cephalometrics. These methods help clinicians to determine a range of resting vertical dimension from which point a range of freeway space (interocclusal space) is subtracted for phonetics and required space for elected prosthesis design (Douglas and Maritato 1965; Silverman 1967; Pound 1977; Tallgren, Lang et al.

1980; Turner and Missirlian 1984; Ramp, Ramp et al. 1999; Yabushita, Zeredo et al. 2005; Yabushita, Zeredo et al. 2005; Koka 2007; Pokorny, Wiens et al. 2008).

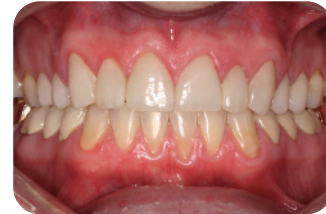

Figure 5: Postoperative presentation.

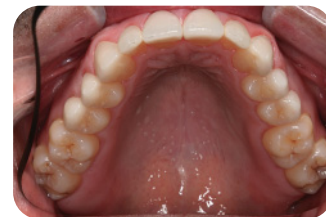

Figure 6: Postoperative maxilla.

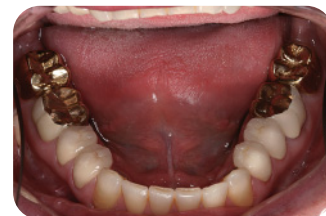

Figure 7: Postoperative mandible.

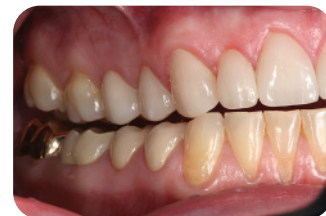

Figure 8: Laterotrusive, right lateral view.

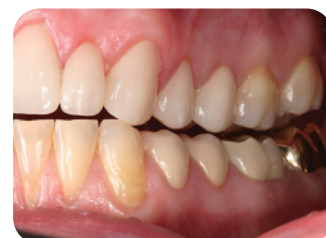

Figure 9: Laterotrusive, left lateral view.

Questions

1. Regarding parafunctional habits and tooth wear, which of the following statements is *incorrect*?

- A. Any unusual activity other than chewing, swallowing, breathing, and speaking is considered a parafunction.
- B. Parafunction could result from psychosocial factors.
- C. Parafunction could be associated with a medical or drug-related condition such as Parkinson's disease.
- D. There is a universally accepted system for classifying the severity of tooth wear.

2. Which of the following statements regarding bruxism is *incorrect*?

- A. There is no strong evidence for a cause-and-effect relationship between bruxism and myofacial pain/temporomandibular disorders.
- B. Occlusal adjustment does not result in discontinuation of bruxism.
- C. Presence of an attrition pattern can be used to determine etiology.
- D. It was shown that the prevalence of nocturnal bruxism decreases after 50 years of age.

3. The majority of laboratory studies support the hypothesis that a combination of erosion and abrasion increases wear.

- A. True
- B. False

4. Which of the following statements regarding erosion is *true*?

- A. Passive regurgitation in gastroesophageal reflux disease (GERD) and chronic vomiting in chronic alcoholism have all been associated with acidic dissolution of dental hard tissues.
- B. Acidic medicaments have been reported not to predispose teeth to dental erosion.
- C. Early enamel erosion shows a rough and dull appearance.
- D. Toothbrushing immediately after vomiting or regurgitation is recommended to achieve remineralization.

5. Which of the following occlusal schemes is shown to reduce masticatory muscle activity?

- A. Bilateral balanced occlusion
- B. Group function
- C. Canine guidance
- D. Occlusion is not related to masticatory activity.

6. A comparison of tooth and ceramic wear against all-ceramic, metal-ceramic, and pressed ceramic materials has shown that:

- A. A mismatch of wear rates between teeth and restoration has minimal effect on wear rate of enamel.
- B. Metal-ceramic restoration wore at about the same rate as enamel.
- C. The outer layer and final surface finish of dental ceramic has no effect on the wear pattern of enamel.
- D. All of the above

7. Occlusal devices are often used to protect restorations and the natural dentition. Comparison of the effects of hard and soft occlusal devices on nocturnal bruxism showed:

- A. Hard occlusal devices significantly reduced muscle activity.
- B. Soft occlusal devices were effective in reducing muscle activity.
- C. There was no significant difference between the hard and soft occlusal devices therapy.
- D. Hard occlusal devices were not effective in reducing muscle activity.

8. The occlusal device thickness of 3 mm versus 6 mm on the muscle activities of the temporal muscles and masseter muscles:

- A. Decreased with 6 mm thick occlusal device
- B. Increased with 3 mm thick occlusal device
- C. Worsened as compared to the no-treatment group with a 6 mm thick occlusal device
- D. There was no significant difference between the no-treatment group versus the 3 mm thick occlusal device therapy group.

ANSWERS

1. D (Dao, Lund et al. 1994; Lavigne and Kato 2003; Koyano, Tsukiyama et al. 2005)
2. D (Sellingman, Pullinger et al. 1988; Koyano, Tsukiyama et al. 2005)
3. A (Amaechi, Higham et al. 2003; Hooper, West et al. 2003; Azzopardi, Bartlett et al. 2004)

4. A (Amaechi and Higham 2005)
5. C (Jemt, Lundquist et al. 2004; Pokorny, Wiens et al. 2008)
6. B (Etman, Woolford et al. 2008)
7. A (Okeson 1987)
8. C (Abekura, Yokomura et al. 2008)

The authors would like to acknowledge and thank Dr. Ryan Sellinger for clinical case photographs and treatment performed at New York University College of Dentistry.

References

- Abekura, H., M. Yokomura et al. (2008). "The initial effects of occlusal splint vertical thickness on the nocturnal EMG activities of masticatory muscles in subjects with a bruxism habit." *Int J Prosthodont* 21(2): 116–20.
- Amaechi, B. T. and S. M. Higham (2005). "Dental erosion: possible approaches to prevention and control." *J Dent* 33(3): 243–52.
- Amaechi, B. T., S. M. Higham et al. (2003). "Influence of abrasion in clinical manifestation of human dental erosion." *J Oral Rehabil* 30(4): 407–13.
- Azzopardi, A., D. W. Bartlett et al. (2004). "The surface effects of erosion and abrasion on dentine with and without a protective layer." *Br Dent J* 196(6): 351–4; discussion 339.
- Bartlett, D. W., D. F. Evans et al. (1996). "The relationship between gastro-oesophageal reflux disease and dental erosion." *J Oral Rehabil* 23(5): 289–97.
- Dao, T. T., J. P. Lund et al. (1994). "Comparison of pain and quality of life in bruxers and patients with myofascial pain of the masticatory muscles." *J Orofac Pain* 8(4): 350–6.
- Douglas, J. R. and F. R. Maritato (1965). "'Open Rest,' a new concept in the selection of the vertical dimension of occlusion." *J Prosthet Dent* 15(5): 850–6.
- Eccles, J. D. (1982). "Tooth surface loss from abrasion, attrition and erosion." *Dent Update* 9(7): 373–4, 376–8, 380–1.
- Etman, M. K., M. Woolford et al. (2008). "Quantitative measurement of tooth and ceramic wear: in vivo study." *Int J Prosthodont* 21(3): 245–52.
- Hooper, S., N. X. West et al. (2003). "Investigation of erosion and abrasion on enamel and dentine: a model in situ using toothpastes of different abrasivity." *J Clin Periodontol* 30(9): 802–8.
- Jemt, T., S. Lundquist et al. (2004). "Group function or canine protection. 1982." *J Prosthet Dent* 91(5): 403–8.
- J Prosthet Dent (2005). "The glossary of prosthodontic terms." *J Prosthet Dent* 94(1): 10–92.
- Koka, S. (2007). "Vertical dimension of occlusion." *Int J Prosthodont* 20(4): 342.
- Koyano, K., Y. Tsukiyama et al. (2005). "Local factors associated with parafunction and prosthodontics." *Int J Prosthodont* 18(4): 293–4.
- Lavigne, G. and T. Kato (2003). "Usual and unusual orofacial motor activities associated with tooth wear." *Int J Prosthodont* 16 Suppl: 80–2; discussion 89–90.
- Lee, B. D. (1978). "Correction of crossbite." *Dent Clin North Am* 22(4): 647–68.
- Litonjua, L. A., P. J. Bush et al. (2004). "Effects of occlusal load on cervical lesions." *J Oral Rehabil* 31(3): 225–32.
- Miralles, R., R. Bull et al. (1989). "Influence of balanced occlusion and canine guidance on electromyographic activity of elevator muscles in complete denture wearers." *J Prosthet Dent* 61(4): 494–8.
- Moss, J. P. (1976). "The problem of the class iii malocclusion." *Proc R Soc Med* 69(12): 913–22.
- Ngan, P., A. M. Hu et al. (1997). "Treatment of Class III problems begins with differential diagnosis of anterior crossbites." *Pediatr Dent* 19(6): 386–95.
- Okeson, J. P. (1987). "The effects of hard and soft occlusal splints on nocturnal bruxism." *J Am Dent Assoc* 114(6): 788–91.
- Pokorny, P. H., J. P. Wiens et al. (2008). "Occlusion for fixed prosthodontics: a historical perspective of the gnathological influence." *J Prosthet Dent* 99(4): 299–313.
- Pound, E. (1977). "Let /S/ be your guide." *J Prosthet Dent* 38(5): 482–9.
- Rabie, A. B. and Y. Gu (2000). "Diagnostic criteria for pseudo-Class III malocclusion." *Am J Orthod Dentofacial Orthop* 117(1): 1–9.
- Ramp, M. H., L. C. Ramp et al. (1999). "Vertical height loss: an investigation of four restorative materials opposing enamel." *J Prosthodont* 8(4): 252–7.

- Seligman, D. A., A. G. Pullinger et al. (1988). "The prevalence of dental attrition and its association with factors of age, gender, occlusion, and TMJ symptomatology." *J Dent Res* 67(10): 1323-33.
- Shupe, R. J., S. E. Mohamed et al. (1984). "Effects of occlusal guidance on jaw muscle activity." *J Prosthet Dent* 51(6): 811-8.
- Silverman, S. I. (1967). "Physiologic factors in complete denture esthetics." *Dent Clin North Am*: 115-22.
- Spear, F. (2008). "A patient with severe wear on the anterior teeth and minimal wear on the posterior teeth." *J Am Dent Assoc* 139(10): 1399-403.
- Tallgren, A., B. R. Lang et al. (1980). "Roentgen cephalometric analysis of ridge resorption and changes in jaw and occlusal relationships in immediate complete denture wearers." *J Oral Rehabil* 7(1): 77-94.
- Thornton, L. J. (1990). "Anterior guidance: group function/ canine guidance. A literature review." *J Prosthet Dent* 64(4): 479-82.
- Turner, K. A. and D. M. Missirlian (1984). "Restoration of the extremely worn dentition." *J Prosthet Dent* 52(4): 467-74.
- Verrett, R. G. (2001). "Analyzing the etiology of an extremely worn dentition." *J Prosthodont* 10(4): 224-33.
- Yabushita, T., J. L. Zeredo et al. (2005). "Role of occlusal vertical dimension in spindle function." *J Dent Res* 84(3): 245-9.
- Yip, K. H., R. J. Smales et al. (2004). "Differential wear of teeth and restorative materials: clinical implications." *Int J Prosthodont* 17(3): 350-6.

WWW.HIGHDENT.IR

همیار دندانسازان و دندانپزشکان

Case 22

Case 22

Management of worn dentition II—localized severe wear

Restoration of extremely worn dentition requires careful assessment of etiology. In selecting the appropriate treatment for this condition, assessment of

vertical dimension of occlusion, space required for restorative materials, and characteristics of restorative materials should be considered.

CASE STORY

A 67-year-old Caucasian female presents with a chief complaint of “I am here because my lower front teeth are wearing away.” The patient presents with extremely worn dentition and is unhappy with the appearance of her teeth and her smile and with the color of her remaining teeth.

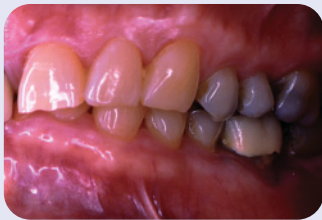

Figure 1: Preoperative left.

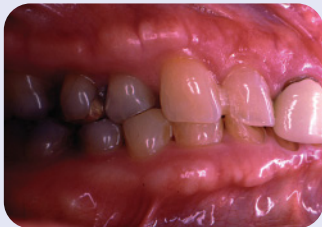

Figure 2: Preoperative right.

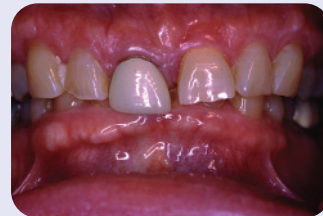

Figure 3: Preoperative frontal.

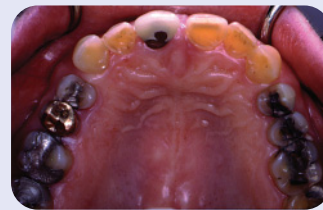

Figure 4: Preoperative maxilla.

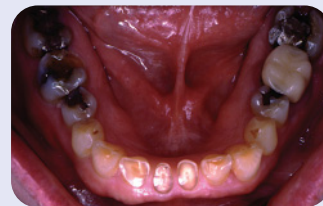

Figure 5: Preoperative mandible.

LEARNING GOALS AND OBJECTIVES

- Manage treatment of patient with worn dentition.
- Assess vertical dimension of occlusion.
- Criteria for establishment of an occlusal scheme
- Establish parameters to predict long-term success of restorations.

Medical History

- The patient reported to be in good health with no signs or symptoms of any systemic disease.

Dental History

- Under the care of a general dentist for the past 10 years
- Routine dental visits throughout much of her life
- Third molar extractions at 23 years of age
- Multiple restorations
- Metal ceramic crown on maxillary right central incisor (8), 8 years ago
- Endodontic therapy on mandibular left second and first molars (18 and 19)
- Root resection of mandibular left first molar (19), 10 years ago

Significant Soft Tissue Examination Findings

- Hyperplastic maxillary labial frenum
- The temporomandibular joints examination was within normal limits.

Clinical Findings/Problem List

- Maxillary palatal torus
- Mandibular bilateral lingual tori
- Labial and buccal exostoses bilaterally in the maxilla
- Generalized wear facets with severe attrition on mandibular incisors
- Maxillary right central incisor (8) supraerupted, aesthetically displeasing with existing metal ceramic crown
- Maxillary left central incisor (9) presented with abrasion on the incisal edge due to the repeated usage of toothpicks
- Multiple defective existing amalgam restorations
- Maxillary right first premolar (5) presented with a gold onlay
- Caries
- Fractured lingual wall of mandibular right first and second molars (30 and 31)

- Class I malocclusion by Angle's classification was observed with 100% vertical overlap and 0% horizontal overlap
- 4–5mm of loss of vertical dimension of occlusion
- Periodontal evaluation revealed generalized erythematous and edematous gingival tissues; bulbous free gingival margin; generalized pocket depths ranging 2–5mm; and localized deep pocket depths ranging 7–9mm around mandibular left molars (18 and 19); mobility was generally class I to class II except mandibular left second molar (18) that exhibited class III mobility.

Radiographic Findings

- The trabecular bone pattern was generally normal except in the area of the mandibular left molars (18 and 19)—periapical radiolucency and distal vertical radiolucency were evident, respectively. These teeth also showed widened periodontal ligament space
- There was generalized mild horizontal bone loss and localized severe horizontal and vertical bone loss around mandibular left molars (18 and 19).
- Maxillary left lateral incisor (10) showed apical root resorption.
- The crown-to-root ratio ranged from 1:1 to 1:1.5.

Diagnosis

- Generalized mild to moderate gingivitis
- Generalized mild chronic periodontitis
- Localized severe chronic periodontitis in association with a vertical root fracture on mandibular left molar (18)
- Chronic periradicular periodontitis on mandibular left second and second molars (19 and 18)
- Caries
- Defective restorations
- Abrasion and attrition
- Loss of occlusal vertical dimension
- Parafunctional habits—bruxism and clenching
- Exostoses
- Maxillary palatal and mandibular tori
- Class I malocclusion

Clinical Decision-Making Determining Factors

- Evaluation of vertical dimension of occlusion for therapeutic purposes should define absence or presence of interocclusal space for the proposed treatment (Weinberg 1982).
- Excessive vertical dimension can result in clenching of teeth, muscle fatigue, soreness of teeth,

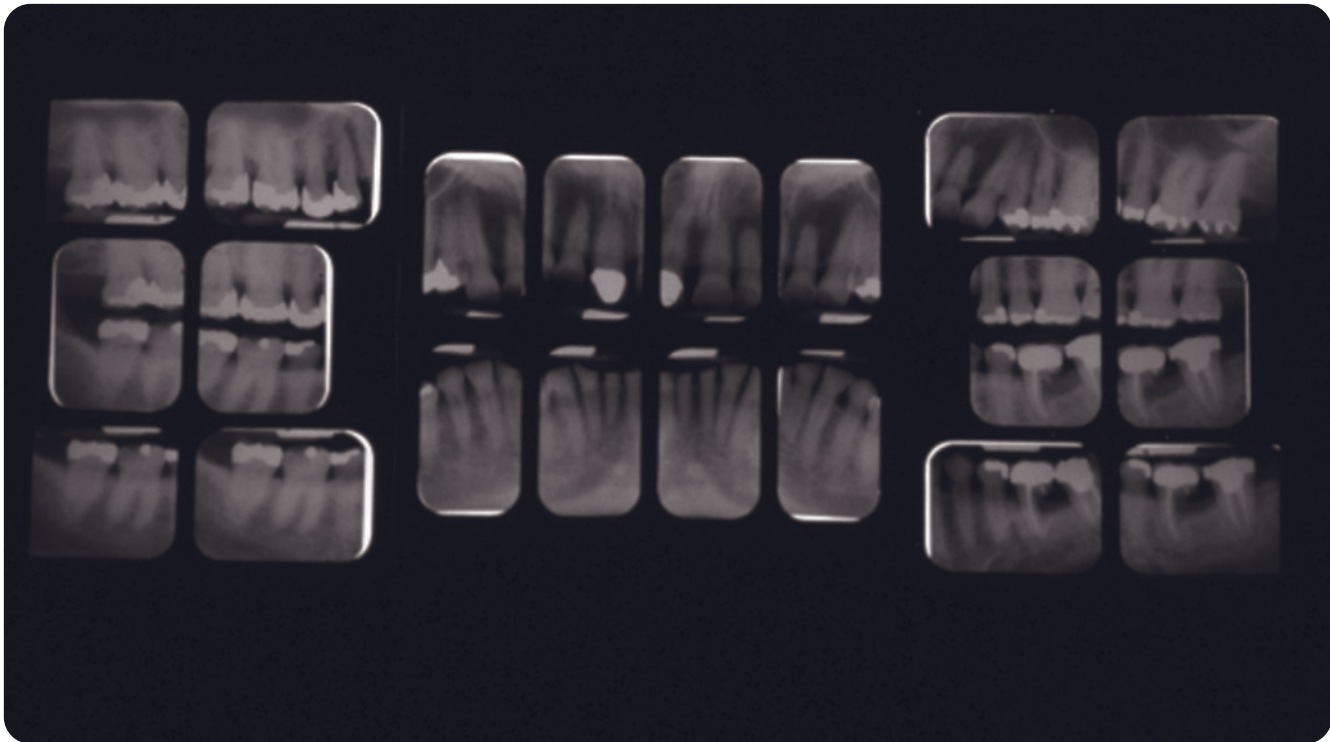


Figure 6: Preoperative full mouth series.

fractured porcelain, occlusal instability, and continued wear (Turner and Missirlan 1984).

- Extensive attrition of anterior teeth often occurs when malpositioned teeth or occlusal interferences are present (Turner and Missirlan 1984).
- Gold alloy opposing porcelain has been demonstrated to have the least amount of abrasive wear on both gold and porcelain surfaces (Kadokawa, Suzuki et al. 2006).
- The 10-year probability of survival for fixed partial dentures has been reported to be 89.1% (95% confidence interval [CI]: 81–93.8%); the probability of success is reported to be 71.1% (95% CI: 47.7–85.2%). The 10-year risk for caries and periodontitis leading to fixed partial denture loss was 2.6% and 0.7%, respectively. The 10-year risk for loss of retention was 6.4%, for abutment fracture 2.1%, and for material fractures 3.2% (Pjetursson, Tan et al. 2004).
- Exostoses are commonly observed in patients exhibiting parafunctional habits. This finding is typically inconsequential in treatment planning.
- Due to the loss of vertical dimension of occlusion (VDO), the restoration of VDO was required to

create the space necessary to restore the aesthetics and functions. The patient was rehabilitated with full coverage fixed restorations and implant-supported crowns.

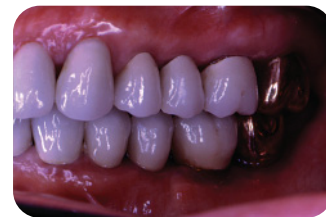

Figure 7: Postoperative left.

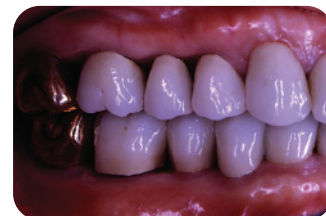

Figure 8: Postoperative right.

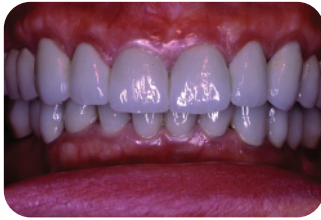
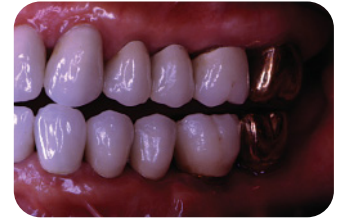
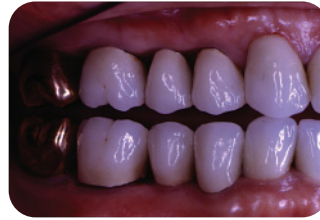Figure 9: Postoperative.



Figures 10 and 11: Postoperative laterotrusion.

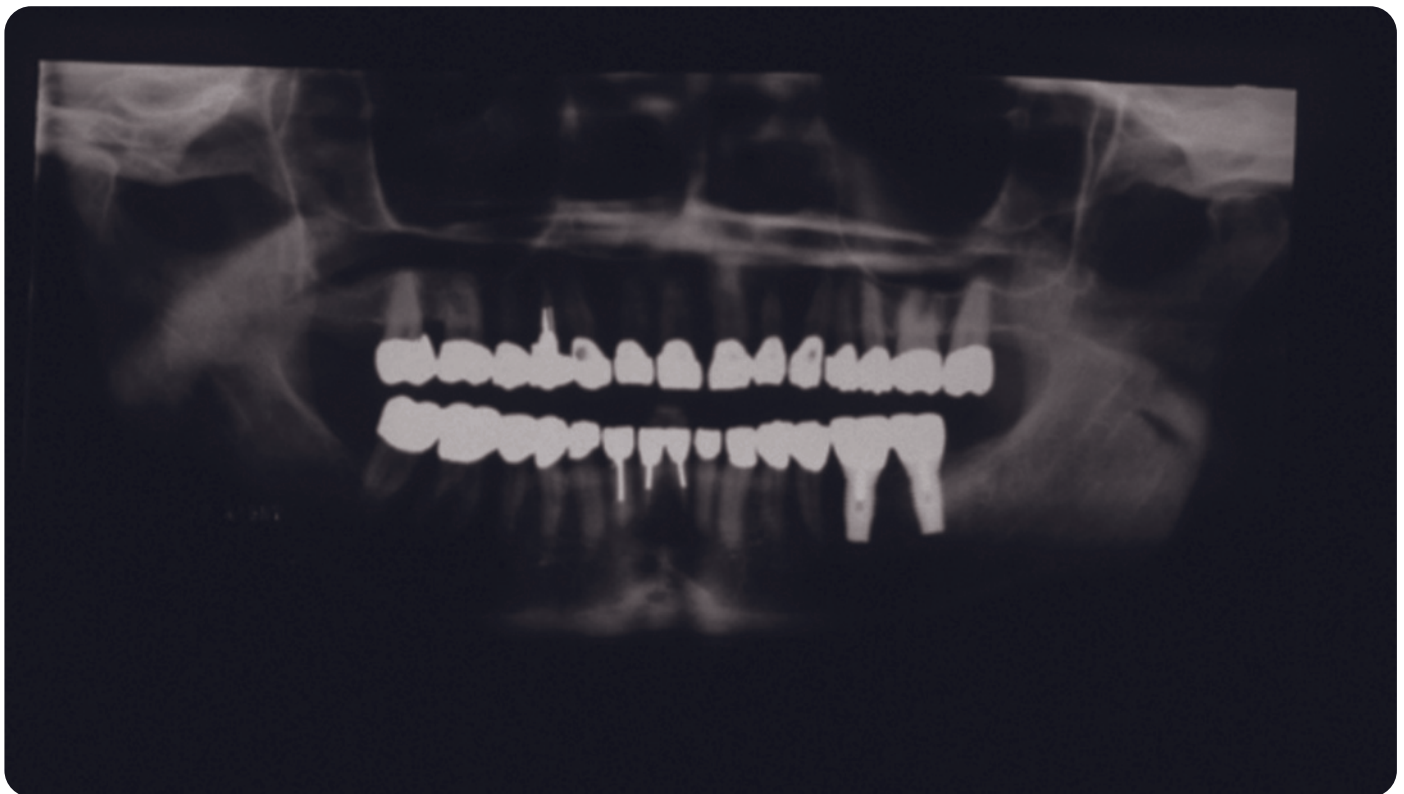


Figure 12: Postoperative panoramic radiograph.

Questions

1. During the initial interview of a patient exhibiting extremely worn dentition, which of the following should be discussed to analyze the etiology of the worn dentition?

- A. Health history
- B. Patient's dietary pattern
- C. Potential occupational factor
- D. Wear history
- E. All of the above

2. Mechanical wear affecting primarily the anterior teeth is an indication of all of the following *except*

- A. Posterior tooth loss
- B. Malposition
- C. Occlusal interferences
- D. Chronic bruxism

3. What is the most common all-ceramic crown complication?

- A. Caries
- B. Loss of retention
- C. Periodontal disease
- D. Fracture of restoration
- E. Pulpal health

4. When evaluating vertical dimension of occlusion, method(s) can be utilized?

- A. Phonetics
- B. Facial appearance
- C. Evaluation of posterior support
- D. Interocclusal space
- E. All of the above

5. When determining the need for crown lengthening procedure to provide adequate incisocervical length for the preparations, what is the minimal incisocervical tooth preparation height given 10–20 degrees of total occlusal convergence angle?

- A. 2 mm
- B. 3 mm
- C. 4 mm
- D. 5 mm

6. The amount of space required for restoration of vertical dimension of occlusion should be calculated during the diagnostic phase. Which of the following method(s) should be utilized?

- A. Properly articulated diagnostic casts in maximum intercuspation
- B. A diagnostic wax-up of treatment-planned prostheses
- C. A and B
- D. None of the above

7. In treating this patient, the dentition with inadequate remaining tooth structure with favorable periodontal support was given elective endodontic treatment with post and core build-up. Considering the fracture resistance of endodontically treated teeth, which of the following is *incorrect*?

- A. Endodontically treated teeth with a uniform 2 mm ferrule were more fracture resistant than those with 0.5 mm ferrule.
- B. A minimum of 1.5 mm ferrule is recommended for the effectiveness of ferrule.
- C. A minimum of 0.5 mm ferrule is recommended for the effectiveness of ferrule.
- D. A uniform ferrule of 2 mm may be an important factor for endodontically treated incisors.

8. The mandibular left molars (18 and 19) were determined to be nonrestorable due to the extent of fractures. Implant restorations were selected to restore this area. When treatment planning for implant restoration, which of the following risk factor(s) is an absolute contraindication?

- A. History of breast cancer
- B. Diabetes
- C. Osteoporosis
- D. Hormone therapy
- E. None of the above

9. What is the minimum amount of space required between a natural tooth and an implant to ensure adequate blood supply to the natural dentition?

- A. 1.5–2 mm
- B. 3 mm
- C. 4 mm
- D. 5 mm

10. In the treatment of this patient, two implants were planned in the area of the mandibular left molars (18 and 19). What is the recommended distance between the two adjacent implants to preserve interimplant bone levels?

- A. 2 mm
- B. 3 mm
- C. 4 mm
- D. 5 mm

ANSWERS

1. E (Verrett 2001)
2. D (Verrett 2001)
3. D (Goodacre, Bernal et al. 2003)
4. E (Turner and Missirlian 1984)
5. B (Goodacre, Campagni et al. 2001)

6. B (Alsiyabi, Felton et al. 2005)
7. C (Tan, Aquilino et al. 2005; Stankiewicz and Wilson 2002)
8. E (Moy, Medina et al. 2005)
9. A (Misch 2005)
10. B (Tarnow, Cho et al. 2000)

The authors would like to acknowledge and thank Dr. Mijin Choi for clinical case photographs and treatment performed.

References

- Alsiyabi, A. S., D. A. Felton et al. (2005). "The role of abutment-attachment selection in resolving inadequate interarch distance: a clinical report." *J Prosthodont* 14(3): 184–90.
- Goodacre, C. J., G. Bernal et al. (2003). "Clinical complications with implants and implant prostheses." *J Prosthet Dent* 90(2): 121–32.
- Goodacre, C. J., W. V. Campagni et al. (2001). "Tooth preparations for complete crowns: an art form based on scientific principles." *J Prosthet Dent* 85(4): 363–76.
- Kadokawa, A., S. Suzuki et al. (2006). "Wear evaluation of porcelain opposing gold, composite resin, and enamel." *J Prosthet Dent* 96(4): 258–65.
- Misch, C. E. (2005). *Dental implant prosthetics*. St. Louis, Mosby.
- Moy, P. K., D. Medina et al. (2005). "Dental implant failure rates and associated risk factors." *Int J Oral Maxillofac Implants* 20(4): 569–77.
- Pjetursson, B. E., K. Tan et al. (2004). "A systematic review of the survival and complication rates of fixed partial dentures (FPDs) after an observation period of at least 5 years." *Clin Oral Implants Res* 15(6): 625–42.
- Stankiewicz, N. R. and P. R. Wilson (2002). "The ferrule effect: a literature review." *Int Endod J* 35(7): 575–81.
- Tan, P. L., S. A. Aquilino et al. (2005). "In vitro fracture resistance of endodontically treated central incisors with varying ferrule heights and configurations." *J Prosthet Dent* 93(4): 331–6.
- Tarnow, D. P., S. C. Cho et al. (2000). "The effect of inter-implant distance on the height of inter-implant bone crest." *J Periodontol* 71(4): 546–9.
- Turner, K. A. and D. M. Missirlian (1984). "Restoration of the extremely worn dentition." *J Prosthet Dent* 52(4): 467–74.
- Verrett, R. G. (2001). "Analyzing the etiology of an extremely worn dentition." *J Prosthodont* 10(4): 224–33.
- Weinberg, L. A. (1982). "Vertical dimension: a research and clinical analysis." *J Prosthet Dent* 47(3): 290–302.

WWW.HIGHDENT.IR

همیار دندانسازان و دندانپزشکان

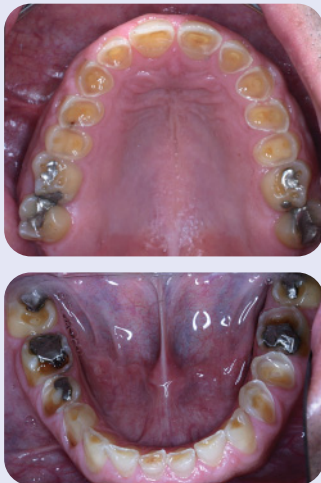Case 23

Case 23

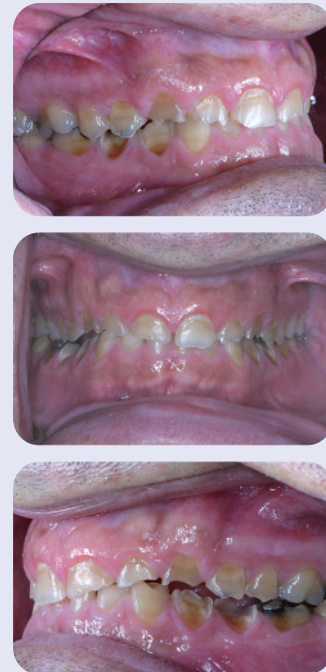Management of worn dentition III—generalized severe wear

CASE STORY

A 42-year-old male patient presents with a chief complaint of: “I am not happy with the way my teeth look.” Intraoral examination reveals extreme wear of multiple surfaces of most teeth in the patient’s maxillary and mandibular jaws. The patient denies any history of gastroesophageal regurgitation of any kind. After several interviews to determine the etiology of the patient’s dental condition, it is revealed that the patient drinks excessive amounts of soft drinks and swishes the soft drinks in his mouth.



Figures 1 and 2: Pretreatment occlusal views.



Figures 3, 4, and 5: Pretreatment maximum intercuspation.

LEARNING GOALS AND OBJECTIVES

- Determining etiology of severe and unusual tooth wear
- Association of dental erosion and acidic soft drinks

Medical History

- No significant findings

Dental History

- History of operative dentistry—amalgam restorations on posterior dentition

Medications and Allergies

- No medications
- No known drug allergies

Review of Systems

- Vital signs:
 - Blood pressure: 120/80
 - Heart rate: 74 beats/minute
 - Respiration rate: 16 breaths/minute

Social History

- No history of bulimia
- No history of alcohol, tobacco, or drug abuse

Significant Soft Tissue Examination Findings

- No significant findings

Charting

(See Fig. 6.)

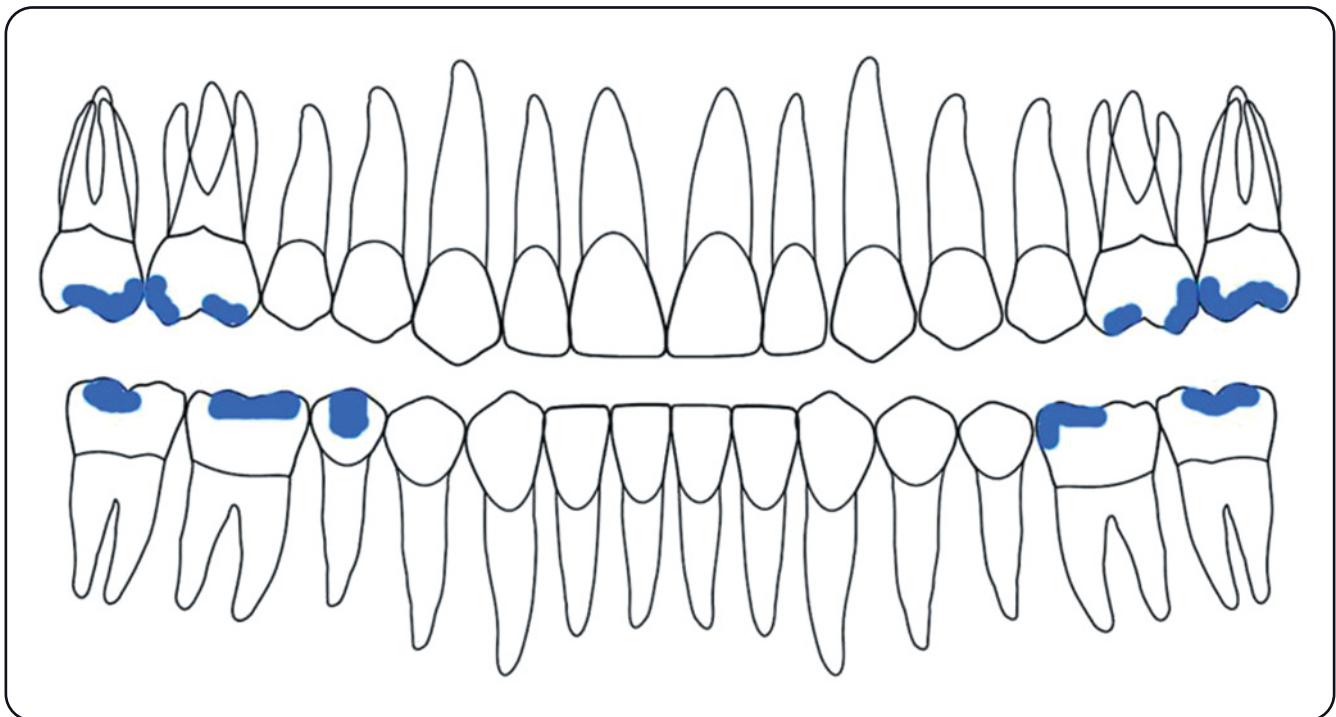


Figure 6: Dental charting.

Significant Clinical Findings/Problem List

- Erosion of occlusal/incisal/buccal surfaces of the following teeth:
 - Maxillary right and left first molars (3 and 14)
 - Maxillary right and left first and second premolars (4, 5, 12 and 13)
 - Maxillary right and left canines (6 and 11)
 - Maxillary incisors (7, 8, 9 and 10)
 - Mandibular left and right first and second molars (18, 19, 30 and 31)
 - Mandibular left and right first and second premolars (20, 21, 28 and 29)
 - Mandibular left and right canines (22 and 27)
 - Mandibular incisors (23, 24, 25 and 26)
- Caries: mesial surface maxillary right first premolar (5)

Radiographs

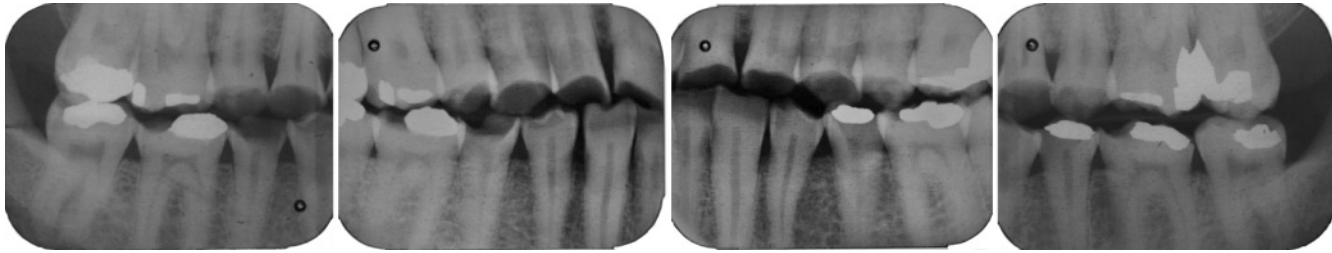


Figure 7: Bitewing radiographs.

Diagnosis

- Severe erosion
- Caries

Clinical Decision-Making Determining Factors

- Dental erosion is described as loss of tooth structure as a result of a chemical process that can involve intrinsic and/or extrinsic factors (described below). The process does not involve a bacterial component. Depending on the chemical process involved in the erosive process, different erosive patterns can be seen. For example, erosion from chronic regurgitation (as is the case with bulimia) typically results in erosion of the lingual surfaces of the maxillary teeth, especially in the anterior region. The patient described here presents with severe erosion of the following areas:
 - Incisal surfaces of the maxillary and mandibular anterior teeth
 - Lingual surfaces of the maxillary anterior teeth
 - Occlusal surfaces of all posterior teeth (except maxillary second molars)
 - Buccal surfaces of the maxillary premolars
 - Buccal surfaces of the mandibular canines, premolars, and first molars
- The pattern of erosion noted here is highly unusual and not commonly described in the literature. A thorough patient interview is critical in diagnosing and treatment planning cases that involve erosion. The following items should be reviewed with the patient as contributing factors to erosion:
 - Diet
 - Gastroesophageal conditions (such as reflux disease)
 - Drugs or medications

- Salivary gland dysfunction
- Environmental causes
- The patient described here denied any history of regurgitation (self-induced or otherwise). The patient also reported no occupational or environmental causes and no history of drug use, and salivary flow was normal. When interviewed about his dietary habits, it was discovered that he drinks a large amount of diet soft drinks and tends to “swish” the drink in his mouth before swallowing. It was determined that this was the etiology of the erosion patterns (Lussi 1996; Verrett 2001).
- Intrinsic versus extrinsic factors: intrinsic factors contributing to dental erosion are ones that involve chronic exposure of the teeth to gastric acid either as a result of a gastroesophageal reflux disorder or self-induced vomiting. Reduced salivary flow rate is also considered an intrinsic factor. Extrinsic factors include diet, environmental exposure, medication, drugs, and habits. Environmental factors such as chronic exposure to acidic fumes or gas-chlorinated swimming pool water are rare but must be investigated as possible contributing factors to dental erosion. Acidic foods and drinks are the most common extrinsic factors involved with dental erosion. Not only is the acidity of the food/drink important, but the method and frequency of ingestion also should be investigated. The diagnosis of the etiology of erosion for the patient presented here is chronic ingestion and swishing of diet soft drink, 3–4 times per day (Jarvinen, Rytomaa et al. 1991; Scheutzel 1996; Zero 1996; Hattab and Yassin 2000).
- Soft drinks are convenient and readily available to children and adults even in the most destitute of countries. They offer a quick and easy thirst quencher and even provide caffeine to those who

may be dependent on it. Several studies have shown that the rate of soft drink consumption is steadily rising among children and adults. Soft drink consumption lowers the pH in the mouth, which in turns leads to loss of tooth structure with chronic exposure. The amount of time the drink is in the mouth, the frequency of exposure to the drink, the

method of drinking, and number of years of exposure all contribute to the severity of erosion in the individual patient (ten Cate and Imfeld 1996; al-Hiyasat, Saunders et al. 1998; Johansson 2002; Johansson, Lingstrom et al. 2004; Devlin, Bassiouny et al. 2006).

Questions

1. A patient presents with severe wear of his posterior dentition. In trying to determine the etiology of the wear, it is important to first determine whether the cause is a mechanical or a chemical one. Which of the following is seen only in patients with chemical wear of their teeth?

- A. Buccal cervical lesions
- B. Fractured cusps
- C. Rampant caries
- D. "Amalgam islands"

2. According to a study by Johansson et al., what was shown to be the "safest" method of drinking a soft drink (i.e., least damaging to the dental structures)?

- A. Gulping
- B. Long sipping
- C. Holding
- D. Short sipping

3. Ironically, a healthier lifestyle may set up a chain of events leading to dental erosion. Increased amounts of strenuous exercise, for example, can lead to dehydration and xerostomia. What other sequel may be expected from increased amounts of exercise that may lead to erosion of teeth?

- A. Clenching of teeth during strenuous exercise
- B. Increased intake of water
- C. Increased intake of acidic sports drinks
- D. Increased grinding of teeth due to increased energy

4. A rare condition has been reported in the dental literature in which patients regurgitate recently ingested food, chew the food again, and then re-swallow it. The behavior can be repeated several times until regurgitation is no longer possible. Patients are usually very secretive about this behavior and are embarrassed to reveal it openly. What is this condition called?

- A. Regurgitation
- B. Rumination
- C. Recycling
- D. Purging

5. A thorough patient examination including a detailed history is the key in diagnosis of cases of severe erosion. What is the best method to help determine contributing factors for a patient with severe erosion?

- A. A daily diet log
- B. Contacting the patient's pharmacist for a list of medications
- C. Referring the patient to a psychologist prior to start of dental treatment
- D. Having the patient determine the etiology

6. Extrinsic factors that can contribute to dental erosion can include occupational exposure to acidic materials. Which of the following occupations may present a risk for dental erosion?

- A. Professional wine tasting
- B. Swimming pool maintenance
- C. Laboratory technician working with *Streptococcus Mutans* bacteria
- D. High-stress job on Wall Street

7. What component of acidic soft drinks is most likely to cause the drop in pH in the oral environment?

- A. Maleic acid
- B. Hydrochloric acid
- C. Citric acid
- D. Sulfuric acid

8. It has been shown that salivary gland dysfunction can contribute to dental erosion. The reduced rate of salivary flow contributes to the erosive process because it leads to

- A. An increased amount of food debris, which allows for bacterial proliferation
- B. More grinding by the patient to clear the oral contents
- C. The reduced ability of the saliva to buffer the oral environment, which in turn leads to lower, more acidic pH
- D. Xerostomia, which in turn leads to increased pH

9. Abfraction lesions are typically noted on the cervical region of the buccal surfaces of teeth. They are thought to be caused by mechanical loading of teeth, which causes wedge-shaped lesions in the cervical areas. These lesions are usually misdiagnosed as

- A. Erosion
- B. Attrition
- C. Abrasion
- D. Occlusal trauma

ANSWERS

1. D (Verrett 2001)
2. A (Johansson, Lingstrom et al. 2004)
3. C (Zero 1996)
4. B (Scheutzel 1996)
5. A (Lussi 1996)

6. A (Jarvinen, Rytomaa et al. 1991; Zero 1996)
7. C (Jarvinen, Rytomaa et al. 1991; ten Cate and Imfeld 1996)
8. C (Lussi 1996; Scheutzel 1996)
9. C (Verrett 2001)

The authors would like to acknowledge and thank Dr. Anthony Lambrakos for clinical case photographs and treatment performed at New York University College of Dentistry.

References

- al-Hiyasat, A. S., W. P. Saunders et al. (1998). "The effect of a carbonated beverage on the wear of human enamel and dental ceramics." *J Prosthodont* 7(1): 2–12.
- Devlin, H., M. A. Bassiouny et al. (2006). "Hardness of enamel exposed to Coca-Cola and artificial saliva." *J Oral Rehabil* 33(1): 26–30.
- Hattab, F. N. and O. M. Yassin (2000). "Etiology and diagnosis of tooth wear: a literature review and presentation of selected cases." *Int J Prosthodont* 13(2): 101–107.
- Jarvinen, V. K., Rytomaa, II et al. (1991). "Risk factors in dental erosion." *J Dent Res* 70(6): 942–947.
- Johansson, A. K. (2002). "On dental erosion and associated factors." *Swed Dent J Suppl* (156): 1–77.
- Johansson, A. K., P. Lingstrom et al. (2004). "Influence of drinking method on tooth-surface pH in relation to dental erosion." *Eur J Oral Sci* 112(6): 484–489.
- Lussi, A. (1996). "Dental erosion clinical diagnosis and case history taking." *Eur J Oral Sci* 104(2 (Pt 2)): 191–198.
- Scheutzel, P. (1996). "Etiology of dental erosion—intrinsic factors." *Eur J Oral Sci* 104(2 (Pt 2)): 178–190.
- ten Cate, J. M. and T. Imfeld (1996). "Dental erosion, summary." *Eur J Oral Sci* 104(2 (Pt 2)): 241–244.
- Verrett, R. G. (2001). "Analyzing the etiology of an extremely worn dentition." *J Prosthodont* 10(4): 224–233.
- Zero, D. T. (1996). "Etiology of dental erosion—extrinsic factors." *Eur J Oral Sci* 104(2 (Pt 2)): 162–177.

Case 24

Case 24

Implant therapy versus endodontic therapy

The questions deliberated by many clinicians and researchers in efforts to determine treatment modalities that will provide an acceptable long-term prognosis may include the following: 1) Do endodontically treated teeth and restorations have poor long-term prognoses when compared to the implant therapy? 2) What is the

longevity of fixed partial dentures versus an implant-supported single crown? 3) Is tooth replacement necessary following the extraction? Clinical analysis based on the available scientific evidence surrounding these questions will help clinicians to decide whether to retain or to extract the remaining dentition.

CASE STORY

A 52-year-old male presents with dislodged provisional restorations in his hand. The patient stated that he cannot chew anymore and that he is seeking help.

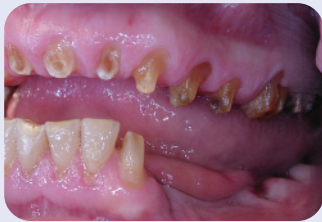

Figure 1: Preoperative left side.

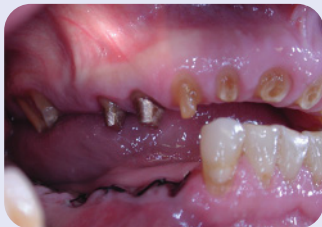

Figure 2: Preoperative right side.

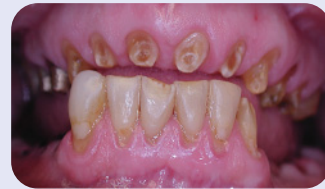

Figure 3: Preoperative presentation.

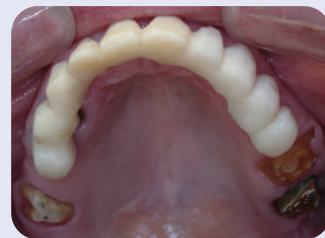

Figure 4: Preoperative maxilla with existing provisional.

LEARNING GOALS AND OBJECTIVES

- Comparison of Implant therapy versus endodontically treated teeth with restorations
- Define ferrule.
- Understand the factors influencing prognosis of endodontically treated teeth.
- Understand clinical parameters influencing fracture resistance of endodontically treated teeth.

Medical History

- Controlled hypertension

Dental History

- The patient began his initial dental treatments about 4 years ago due to extensive carious lesions on his remaining teeth.
- He was unable to complete the treatment and developed further carious lesions on mandibular posterior teeth.
- The patient was recently treated with extractions of mandibular posterior teeth through a dental

emergency clinic and was advised to seek definitive care.

Clinical Findings/Problem List

- Dislodged maxillary provisional restorations
- Furcation caries on maxillary right second molar (3) and left first and second molars (14 and 15)
- Fractured maxillary right central and lateral incisors (7 and 8); fractured maxillary left central and lateral incisors (7, 9, and 10)
- Recurrent caries on maxillary left premolars (12 and 13)
- Recurrent caries on maxillary canines (6 and 11)
- Generalized mobility of the maxillary teeth
- Missing maxillary right first molar
- Missing mandibular posterior teeth

Radiographic Findings

(See Fig. 5.)

Diagnosis

- Recurrent caries
- Fractured maxillary teeth
- Defective post and core restorations

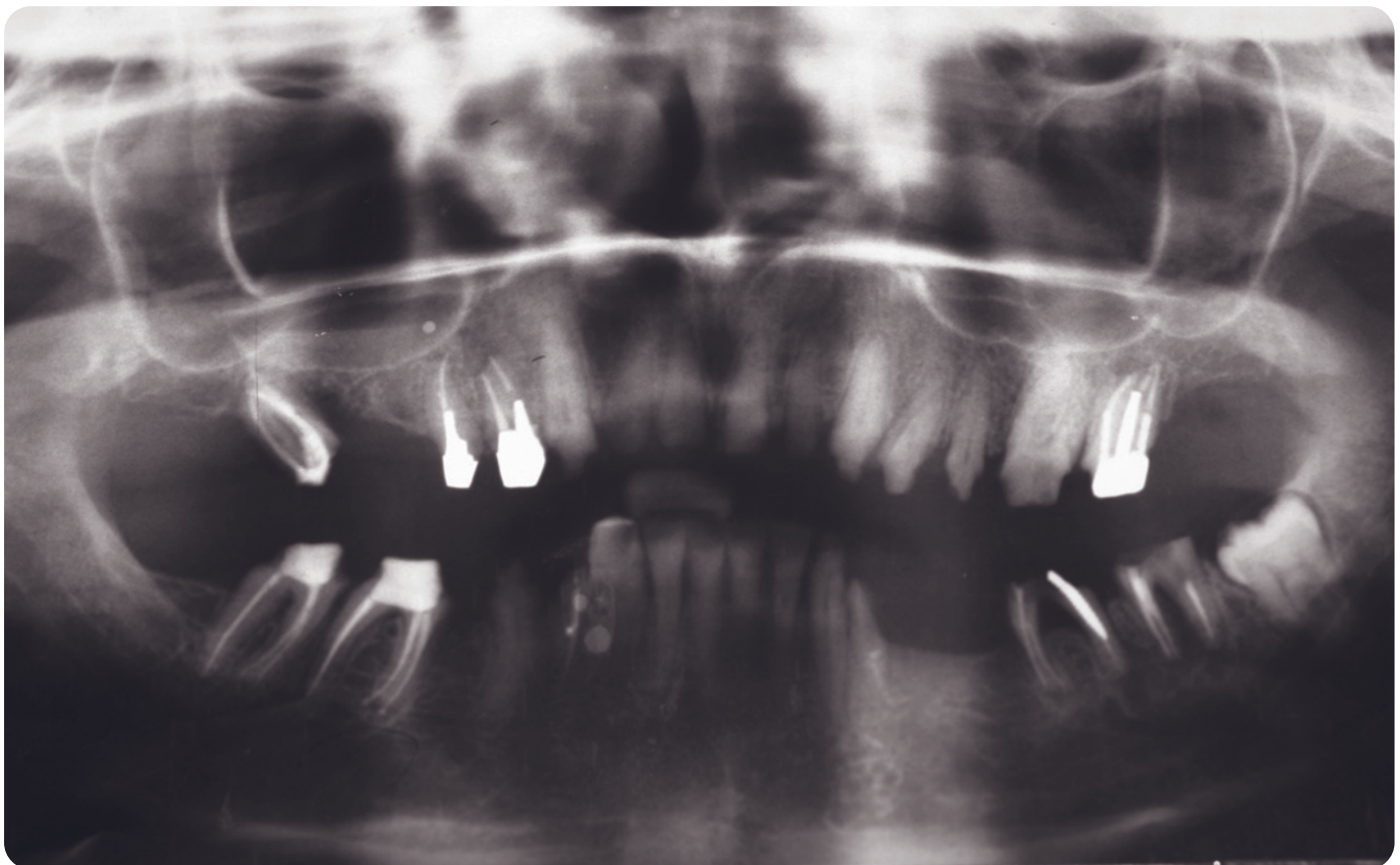


Figure 5: Panoramic radiograph prior to extraction of mandibular posterior teeth.

- Maxillary and mandibular partial edentulism
- Generalized moderate to severe periodontitis on maxillary remaining dentition

Clinical Decision-Making Determining Factors

- Determination of an appropriate treatment modality for structurally compromised teeth requires analytic assessment of factors related to the long-term prognosis.
- Direct comparison of the replacement of a single tooth with implants and initial nonsurgical endodontic treatment showed successes of 73.5% and 82.1%, respectively, suggesting that restored endodontically treated teeth and single-tooth implant restorations have similar failure rates. However, the implant group showed a longer average and median time of function (Doyle, Hodges et al. 2006).
- Initial endodontic treatment showed high long-term survival rate for periodontally sound teeth with pulpal and/or periapical pathosis. Equivalent long-term survival rates have also been reported for extraction and replacement of the missing tooth with an implant-supported restoration. Substantially lower long-term survival rates have been reported for extraction and replacement of the missing tooth with fixed partial dentures (Torabinejad, Anderson et al. 2007).
- Crown design, preservation of tooth structure, and amount of occlusal forces have direct impact on the longevity and prognosis of the restored tooth (Fernandes and Dessai 2001).
- Factors that influence the fracture resistance of a tooth include the following: post length, post diameter, amount of remaining dentin, post material, post adaptability, post design, cement, core material, core and crown design, biocompatibility of post material, use of treated tooth, and occlusal load exerted on restored tooth (Fernandes and Dessai 2001).
- Ferrule is defined as a metal band or ring used to fit the root or crown of a tooth; any short tube or brushing for making a tight joint as described in "The Glossary of Prosthodontic Terms." It describes the amount of remaining coronal tooth structure above the margin design (J Prosthet Dent 2005).
- The displacement and rotation of the crown is reduced when the ferrule height reached is a uniform 1.5mm (Ichim, Kuzmanovic et al. 2006).
- Based on the currently available data, the survival rate of endodontically treated teeth restored with crowns and that of implant-supported restorations are shown to be comparable. However, it was also clearly shown that the success of an endodontically treated tooth is highly dependent on the amount of remaining tooth structure. When the tooth structures are further compromised due to recurrent caries along with redevelopment of periapical pathosis secondary to the previous endodontic therapy, the long-term prognosis of such teeth is highly decreased. Therefore, the treatment decision was made for extraction of remaining maxillary dentition. Subsequently, the patient was provided with implant-supported prostheses (Fernandes, Shetty et al. 2003; Torabinejad, Anderson et al. 2007; Arunpraditkul, Saengsanon et al. 2009).

Questions

1. Technical failures in connection with fixed prosthodontics are often caused by fatigue fractures. Regarding the "fatigue fracture," which of the following statements is *incorrect*?

- A. The abutments, cement, and reconstruction are all subjected to stress caused by occlusal forces.
- B. Fatigue fracture may occur at the weakest point or where the maximum stress occurs. The weakest point is frequently in connection with endodontically treated teeth restored with posts and cores.
- C. Nonaxial forces are a risk for fatigue fracture of teeth, cement, and restorative material.
- D. Favorable occlusal prosthesis design is probably less important for survival of structurally compromised endodontically treated teeth than is the type of post used.

2. A ferrule

- A. Increases the mechanical resistance of a post/core/crown restoration
- B. Is defined as "a metal band or ring used to fit around the root or crown of a tooth," which implies a metal band, provided by a complete crown, interfacing with 360 degrees of complete circumferential tooth structure between the core and preparation finish line
- C. Of 2.0 mm height beneficially increases fracture resistance
- D. The presence of remaining coronal tooth structure between the core and preparation finish line is more important for fracture resistance of endodontically treated teeth than post length or type.
- E. All of the above are correct.

3. On the endodontically treated teeth with varying degree of ferrule,

- A. Root fracture was the predominant mode of failure with the presence of ferrule.
- B. In the nonferrule group, debonding failures were predominant.
- C. In the nonferrule group, root fractures were predominant.
- D. For restored endodontically treated teeth that do not have complete circumferential tooth structure between the core and preparation finish line, the location of the remaining coronal tooth structure may affect their fracture resistance.

4. When an edentulous space is maintained without a replacement restoration or a prosthesis, which of the following is shown to be *true*?

- A. Moderately shortened dental arches had little impact on occlusal stability, tooth loading, temporomandibular disorders, interdental spacing, periodontal disease, patient comfort, or masticatory performance.
- B. Loss of a single posterior tooth, creating an interrupted dental arch or bounded posterior space, had significant effect on shifting, decrease in alveolar support, or loss of adjacent teeth.
- C. Provision of a fixed partial denture was associated with a modestly improved survival rate of adjacent teeth.
- D. Loss of teeth had considerable psychosocial impact.

5. A recent systematic review comparing the clinical outcomes of restored endodontically treated teeth with those of implant-supported restorations concluded that

- A. Survival rates of restored endodontically treated teeth and single implants did significantly differ.
- B. The decision to treat a tooth endodontically or replace it with an implant must be based on factors other than the treatment outcomes of the procedures themselves.
- C. Survival rates of restored endodontically treated teeth were higher.
- D. Survival rates of single implants were higher.

3. C (Ng, al-Bayat et al. 2004; Ng, Dumbrigue et al. 2006; Pereira, de Ornelas et al. 2006)
 4. B (Torabinejad, Anderson et al. 2007)
 5. B (Iqbal 2007)
 6. D (Lin, Wang et al. 2008)

6. Concerning maxillary and mandibular posterior implants,

- A. A 95% survival rate for mandibular implants and a 65–85% survival rate for maxillary implants were reported.
- B. Bone quality and favorable loading are important factors for success of implant-supported restorations.
- C. Minimum thickness of 1 mm of surrounding bone is required for optimal osseointegration.
- D. Stress to the implant is primarily affected by implant position.
- E. All of the above

1. D (Torbjörner and Fransson 2004)
 2. E (Milot and Stein 1992; Isidor, Brondum et al. 1999; Ng, al-Bayat et al. 2004; Ng, Dumbrigue et al. 2006; Ichim, Kuzmanovic et al. 2006)

ANSWERS

The authors would like to acknowledge and thank Dr. Guadalupe Garcia for clinical case photographs and treatment performed at New York University College of Dentistry.

References

- Arunpraditkul, S., S. Saengsanon et al. (2009). "Fracture resistance of endodontically treated teeth: three walls versus four walls of remaining coronal tooth structure." *J Prosthodont* 18(1): 49–53.
- Doyle, S. L., J. S. Hodges et al. (2006). "Retrospective cross sectional comparison of initial nonsurgical endodontic treatment and single-tooth implants." *J Endod* 32(9): 822–7.
- Fernandes, A. S. and G. S. Dessai (2001). "Factors affecting the fracture resistance of post-core reconstructed teeth: a review." *Int J Prosthodont* 14(4): 355–63.
- Fernandes, A. S., S. Shetty et al. (2003). "Factors determining post selection: a literature review." *J Prosthet Dent* 90(6): 556–62.
- Ichim, I., D. V. Kuzmanovic et al. (2006). "A finite element analysis of ferrule design on restoration resistance and distribution of stress within a root." *Int Endod J* 39(6): 443–52.
- Iqbal, M. K. (2007). "For teeth requiring endodontic treatment, what are the differences in outcomes of restored endodontically treated teeth compared to implant-supported restorations?" *Int J Oral Maxillofac Implants* 22(Suppl.): 96–116.
- Isidor, F., K. Brondum et al. (1999). "The influence of post length and crown ferrule length on the resistance to cyclic loading of bovine teeth with prefabricated titanium posts." *Int J Prosthodont* 12(1): 78–82.
- J Prosthet Dent. (2005). "The glossary of prosthodontic terms." *J Prosthet Dent* 94(1): 10–92.
- Lin, C. L., J. C. Wang et al. (2008). "Biomechanical response of implant systems placed in the maxillary posterior region under various conditions of angulation, bone density, and loading." *Int J Oral Maxillofac Implants* 23(1): 57–64.
- Milot, P. and R. S. Stein (1992). "Root fracture in endodontically treated teeth related to post selection and crown design." *J Prosthet Dent* 68(3): 428–35.
- Ng, C. C., M. I. al-Bayat et al. (2004). "Effect of no ferrule on failure of teeth restored with bonded posts and cores." *Gen Dent* 52(2): 143–6.
- Ng, C. C., H. B. Dumbrigue et al. (2006). "Influence of remaining coronal tooth structure location on the fracture resistance of restored endodontically treated anterior teeth." *J Prosthet Dent* 95(4): 290–6.
- Pereira, J. R., F. de Ornelas et al. (2006). "Effect of a crown ferrule on the fracture resistance of endodontically treated teeth restored with prefabricated posts." *J Prosthet Dent* 95(1): 50–4.
- Torabinejad, M., P. Anderson et al. (2007). "Outcomes of root canal treatment and restoration, implant-supported single crowns, fixed partial dentures, and extraction without replacement: a systematic review." *J Prosthet Dent* 98(4): 285–311.
- Torbjörner, A. and B. Fransson (2004). "A literature review on the prosthetic treatment of structurally compromised teeth." *Int J Prosthodont* 17(3): 369–76.

Case 25

Case 25

Management of endodontically treated teeth

CASE STORY

A 42-year-old male patient presents with a chief complaint of "I would like to finish a root canal on the lower left side and I need a general checkup." The patient had endodontic therapy started on the mandibular left second molar (18) about 3 years ago but did not return to his previous dentist to complete the procedure. The patient had regular dental care for the first 25 years of his life but has neglected his care for the past 17 years. His oral

health is generally poor because he has not had any dental treatment for the past 3 years. The patient presents with xerostomia secondary to current medications.

Note:

To focus the case discussion, the emphasis on this case description will be on local treatment needs in the mandibular left region.

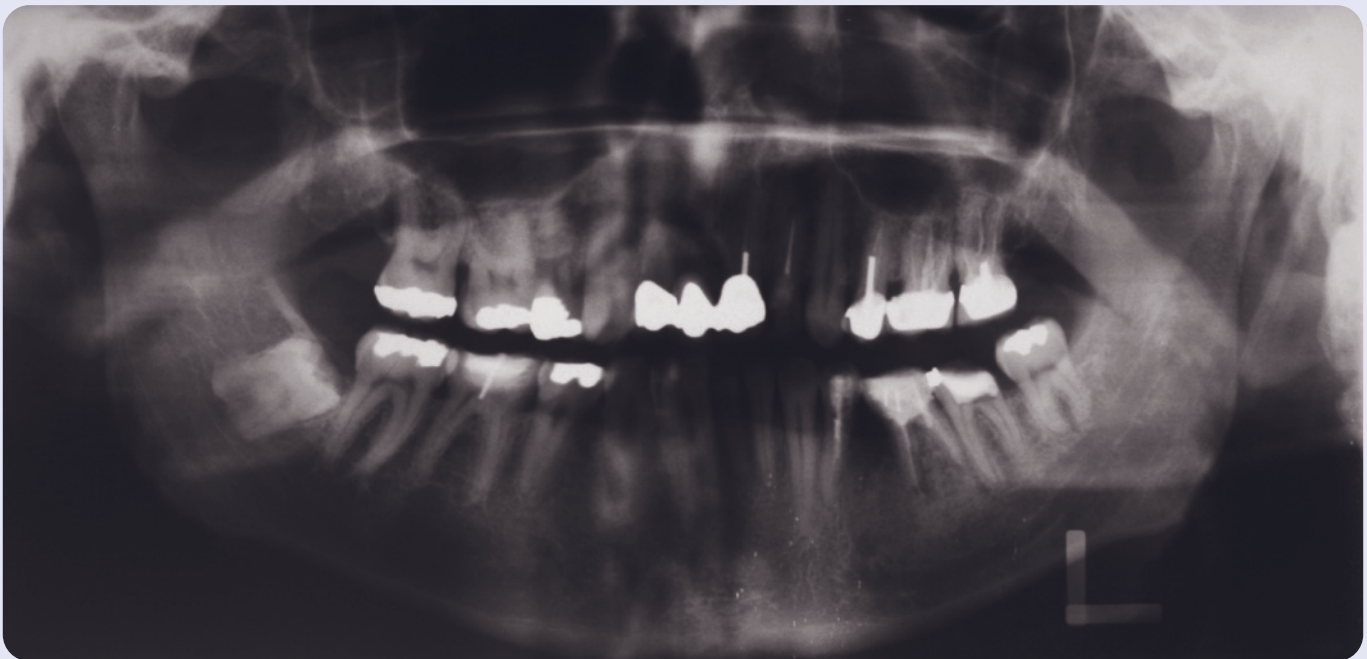


Figure 1: Preoperative panoramic radiograph.

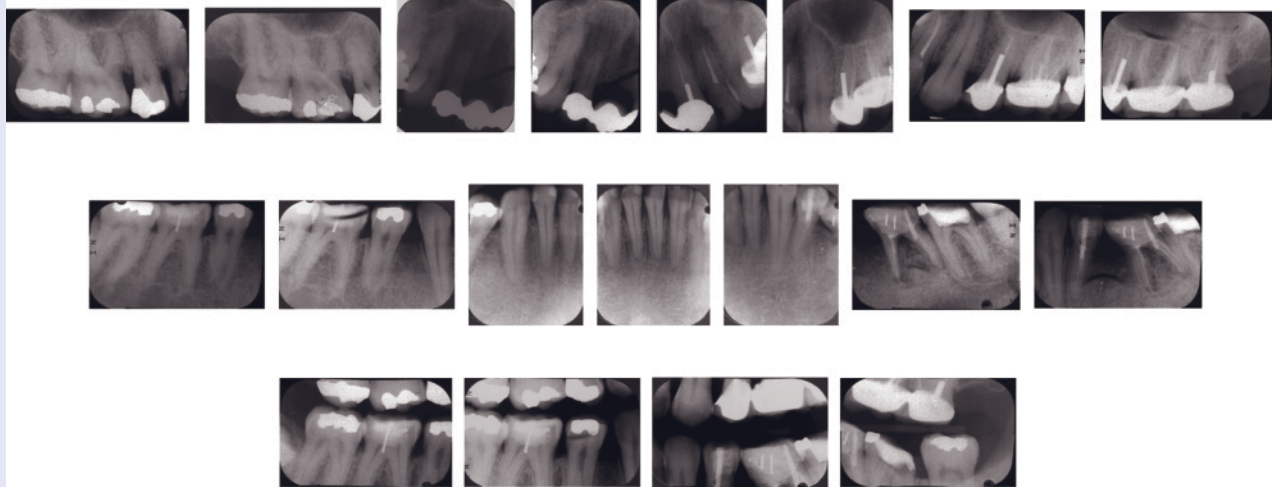


Figure 2: Preoperative full mouth series of radiographs.

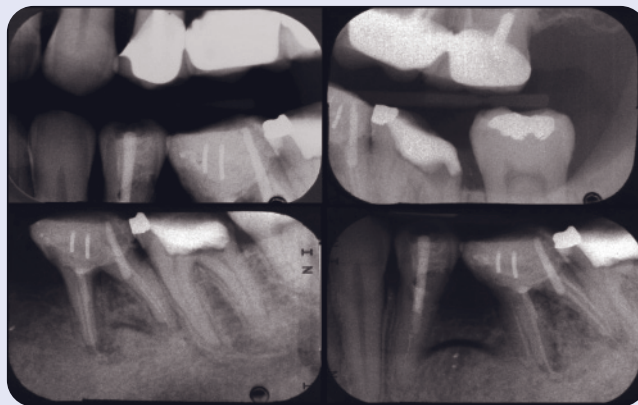


Figure 3: Radiographs of mandibular left posterior dentition.

LEARNING GOALS AND OBJECTIVES

- Identify the sequelae of xerostomia.
- Understand treatment limitations due to xerostomia.
- Understand preventive measures for patients with xerostomia.
- Restore endodontically treated teeth.
- Make treatment decisions regarding management of a limited edentulous area.

Medical History

- Hepatitis C
- Hypertension

- Depression
- Hypertriglyceridemia

Dental History

- Extractions: maxillary third molars (1, 16) and all four first premolars (5, 12, 21, 28) for orthodontic treatment
- Endodontic therapy: maxillary left central and lateral incisors (9, 10), left maxillary second premolar and first and second molars (13, 14, 15), and mandibular left first molar and second premolar (19, 20)
- Restorative therapy: Fixed partial denture maxillary right lateral incisor through to left central incisor (7–9); most teeth have direct restorations.

Medications and Allergies

- Lexapro: for treatment of hepatitis C (side effect–xerostomia)
- Lipitor: for treatment of hypertriglyceridemia
- Atenolol: for treatment of hypertension (side effect–xerostomia)
- Wellbutrin: for treatment of depression (side effect–xerostomia)

Review of Systems

- Vital signs:
 - Blood pressure: 130/84
 - Heart rate: 68 beats/minute
 - Respiratory rate: 19 breaths/minute

Social History

- Smoking: 1 pack per day for 25 years
- Recreational drugs: marijuana

Significant Extraoral Examination Findings

- No significant findings

Significant Soft Tissue Examination Findings

- Saliva: decreased flow, thick consistency

Charting**Clinical Findings/Problem List (list limited to mandibular left quadrant)**

- Poor oral hygiene
- Xerostomia
- Plaque-induced gingivitis
- Localized chronic periodontal disease: mandibular left first molar (19)
- Incomplete endodontic therapy: mandibular left second molar (18)
- Caries: mandibular left third molar (17MO), mandibular left first molar (19DO)
- Inadequate endodontic therapy: mandibular left first molar and first premolar (19, 21)

Diagnosis

- Caries
- Inadequate/defective restorations
- Inadequate endodontic therapy
- Plaque-induced gingivitis and localized chronic periodontal disease

Clinical Decision-Making Determining Factors

- Prognosis of endodontic retreatment is of major concern when treatment planning. Other factors that influence restorability of a tooth are periodontal condition, crown-to-root ratio, and the amount of

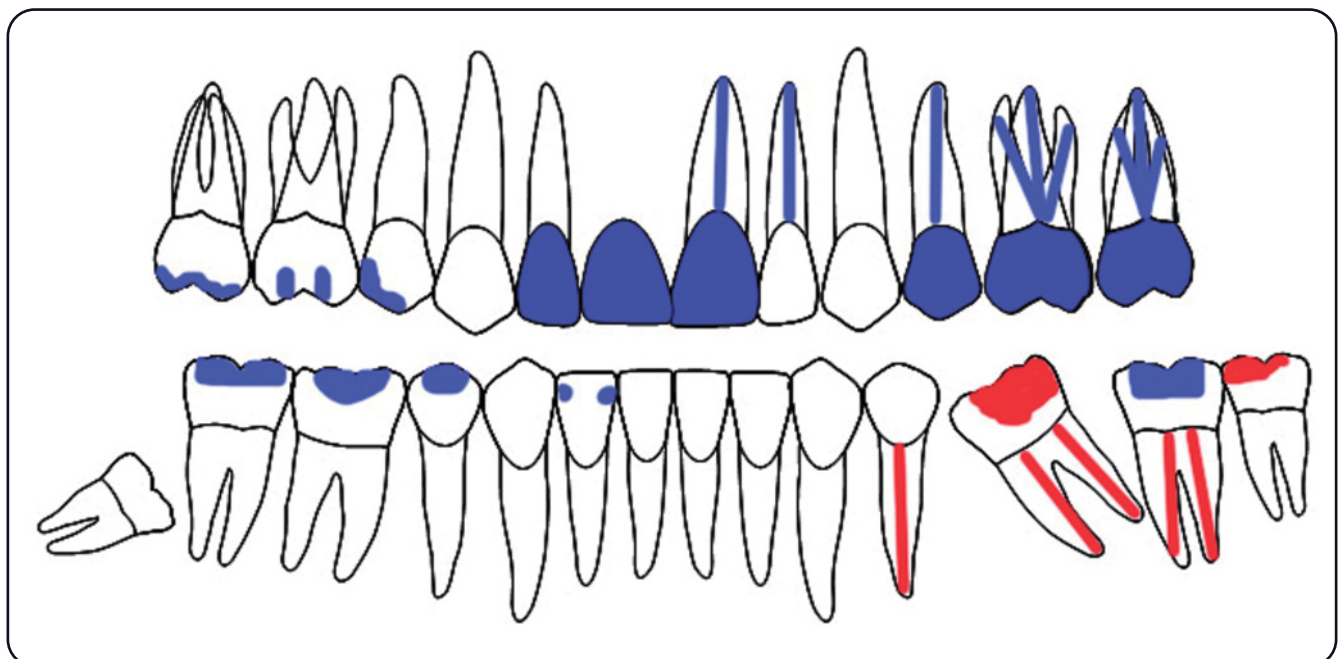


Figure 4: Dental charting.

remaining tooth structure. The prognosis of endosseous implants offers a favorable treatment option for cases with poor prognosis following endodontic and periodontal therapy (Kao 2008; Sjogren, Hagglund et al. 1990).

- Xerostomia has a significantly negative effect on prognosis of restorations and the general oral health of the patient. Xerostomia-inducing medications necessitate development of a treatment plan that includes provisions for management of xerostomia as well as incorporation of hygienic restorations that allow for easy home care and maintenance (Ship, Pillemer et al. 2002).
- The common sequela of xerostomia is the development of caries on the root surfaces of teeth. Control of the caries process can consist of reinforcement of oral hygiene, fluoride-releasing restorative materials, use of fluoride, and xylitol-containing products. It is imperative that a caries control protocol be instituted for this patient (Burgess and Gallo 2002).
- Periodontal disease has been associated with cardiovascular disease, therefore making its

treatment of paramount importance—especially in a patient with existing cardiovascular issues. Dental treatment for this patient can result in overall improved health. In conjunction with improved oral hygiene and smoking cessation, the patient stands to benefit on multiple levels (ADA 2008; Lamster, DePaola et al. 2008).

- An effective smoking cessation program including counseling and nicotine replacement therapy (in the form of gum, transdermal patch, inhaler, lozenges, or nasal spray) is recommended for this patient. With the help of nicotine replacement therapy, an increased rate of quitting (by 50–70%) has been demonstrated. Smoking cessation will not only enhance the overall health of the patient but also may improve the prognosis of dental treatment (Stead, Perera et al. 2008).
- Crown-to-root ratio of abutment teeth for fixed partial dentures: It has been recommended that a crown-to-root ratio of 2:3 is optimal for good long-term prognosis of an abutment tooth. A minimum of 1:1 ratio is required if all other prognostic criteria are favorable (Shillingburg 1997).

Questions

1. One of the common sequela of xerostomia is caries formation. The treatment of choice in such cases is daily use of fluoridated dentifrice and other topical fluoride applications. Frequent recalls and close monitoring of patients with xerostomia can also help early detection and control of the caries process. What other problem can arise in patients with xerostomia?

- A. Systemic bacterial infection
- B. Oral candidiasis
- C. Periodontal disease
- D. Hypertension

2. Given the patient's use of multiple medications that cause xerostomia, what other step(s) should be considered in the development of a prosthodontic treatment plan for this patient?

- A. Nutritional counseling
- B. Discussion with medical doctor for substitution of current medications with alternate medications that do not cause xerostomia
- C. Increase of fluid intake
- D. Use of salivary gland stimulators or artificial saliva substitutes
- E. All of the above

3. In planning treatment for the mandibular left first premolar (21), the following factors are taken into consideration: crown-to-root ratio, endodontic retreatment, assessment of amount of remaining tooth structure after excavation of caries, and overall treatment plan for the mandibular arch. Of major concern is the success rate/prognosis of the tooth after endodontic retreatment. Studies have shown that

- A. Retreatment can cause a significant reduction of survival of the tooth.
- B. Retreatment should only be attempted surgically.
- C. Retreatment of the canal is not needed unless a fracture is suspected.
- D. Retreatment should never be attempted due to poor prognosis.

4. After initial endodontic treatment by the previous dentist, the mandibular left first premolar (21) was not restored with a dowel or a crown. Studies have demonstrated which of the following regarding endodontically treated posterior teeth?

- A. In posterior teeth, the use of prefabricated dowels significantly increases failure rates as compared to the use of cast dowels.
- B. There is no clinically significant difference in survival rates of teeth restored with full coverage or without full coverage restorations.
- C. Teeth that received dowels with full coverage restorations had a higher survival rate than teeth restored with only full coverage restorations.
- D. Teeth that did not receive full coverage restorations had a lower survival rate as compared to posterior teeth that did receive full coverage restorations.

5. In deciding the proper course of treatment in the mandibular left posterior area, several options must be considered. The following are possible options:

- Maintain mandibular left premolar and molars (18, 19, and 21) with proper periodontal and endodontic therapy and full coverage restorations.
- Remove mandibular left premolar and molars (18, 19, and 21) and replace with an RPD.
- Remove mandibular left premolar and molars (18, 19, and 21) and replace with implant-supported fixed restorations.

The patient is concerned about the options and seeks your advice on the prognosis of the molars, especially mandibular left first molar (19)—his previous dentist had mentioned that tooth 19 was in poor condition. What is your advice to the patient regarding this tooth?

- A. Simple periodontal therapy will result in good prognosis of the tooth and it should not be extracted.
- B. Periodontal surgery is required, which will result in good prognosis of the tooth, and it should not be extracted.
- C. Due to extensive bone loss extending into the furcation area, existing failed endodontic therapy, and large existing restoration, the tooth is hopeless and should be extracted.
- D. After surgical periodontal therapy and endodontic retreatment, the tooth will have a good prognosis only if it is not used as an abutment for a fixed partial denture.

6. The mandibular left first molar (19) has been determined to be unrestorable and is scheduled for extraction. What factor(s) should be considered when assessing the area for the option of implant placement?

- A. Location of the mandibular canal
- B. Buccolingual width of bone in the edentulous area
- C. Mesiodistal length of bone in the edentulous area
- D. Vertical position of the opposing dentition
- E. All of the above

7. After successful endodontic retreatment and periodontal treatment, a new coronal restoration is planned for mandibular left first premolar (21). There is enough coronal tooth structure for use of a prefabricated dowel and core buildup. What other preparation feature would ensure successful long-term prognosis for this tooth?

- A. Establishment of a ferrule
- B. Apical gutta percha seal of 2 mm
- C. Use of resin-reinforced glass ionomer cement
- D. Use of an all-ceramic full-coverage restoration
- E. All of the above

8. In considering all treatment options for a posterior edentulous area, the discussion of a removable partial denture ensues. Which of the following statements is correct regarding the choice between a removable partial denture versus a fixed partial denture?

- A. Studies have shown that the survival rate of teeth adjacent to edentulous areas restored by removable partial dentures was greater than those replaced by nothing.
- B. Studies have shown that the survival rate of teeth adjacent to edentulous areas restored by fixed partial dentures was greater than those replaced by implant restorations.
- C. Studies have shown that the survival rate of teeth adjacent to edentulous areas restored by nothing was greater than those replaced by removable partial dentures.
- D. Studies have shown that the survival rate of teeth adjacent to edentulous areas restored by fixed partial dentures was greater than those replaced by removable partial dentures.
- E. Studies have shown that the survival rate of teeth adjacent to edentulous areas restored by removable partial dentures was greater than those replaced by fixed partial dentures.

9. Several studies have been conducted investigating patient attitudes and satisfaction with implant prostheses. The overwhelming outcome of these studies is that patient satisfaction with implant prostheses is significantly greater than with other prostheses. The most common reason for tooth replacement with implant prostheses is

- A. Improved proprioception
- B. Improved eating/chewing ability
- C. Improved aesthetics
- D. Improved self-esteem

ANSWERS

1. B (Ship, Pillemer et al. 2002)
2. E (Diaz-Arnold and Marek 2002)
3. A (Sjogren, Hagglund et al. 1990)
4. D (Sorensen and Martinoff 1984)
5. C (Kao 2008)

6. E (Misch 1999)
7. A (Morgano and Brackett 1999)
8. D (Aquilino, Shugars et al. 2001; John, Micheelis et al. 2004)
9. B (Yi, Carlsson et al. 2001; Pjetursson, Karoussis et al. 2005)

The authors would like to acknowledge and thank Dr. Amogh Velangi for clinical case photographs and treatment performed at New York University College of Dentistry.

References

- American Dental Association. Oral Health Topics A–Z: Oral-Systemic Health—Your Health and Your Overall Health. www.ada.org/public/topics/oralsystemic.asp. Accessed Jan. 16, 2008.
- Aquilino, S. A., D. A. Shugars et al. (2001). "Ten-year survival rates of teeth adjacent to treated and untreated posterior bounded edentulous spaces." *J Prosthet Dent* 85(5): 455–60.
- Burgess, J. O. and J. R. Gallo (2002). "Treating root-surface caries." *Dent Clin North Am* 46(2): 385–404, vii–viii.
- Diaz-Arnold, A. M. and C. A. Marek (2002). "The impact of saliva on patient care: A literature review." *J Prosthet Dent* 88(3): 337–43.
- Goodacre, C. J., G. Bernal et al. (2003). "Clinical complications with implants and implant prostheses." *J Prosthet Dent* 90(2): 121–32.
- John, M. T., W. Micheelis et al. (2004). "[Reference values in oral health-related quality of life for the abbreviated version of the Oral Health Impact Profile]." *Schweiz Monatsschr Zahnmed* 114(8): 784–91.
- Kao, R. T. (2008). "Strategic extraction: a paradigm shift that is changing our profession." *J Periodontol* 79(6): 971–7.
- Lamster, I. B., D. P. DePaola et al. (2008). "The relationship of periodontal disease to diseases and disorders at distant sites: communication to health care professionals and patients." *J Am Dent Assoc* 139(10): 1389–97.
- Misch, C. E. (1999). *Contemporary implant dentistry*. St. Louis, Mosby.
- Morgano, S. M. and S. E. Brackett (1999). "Foundation restorations in fixed prosthodontics: current knowledge and future needs." *J Prosthet Dent* 82(6): 643–57.
- Pjetursson, B. E., I. Karoussis et al. (2005). "Patients' satisfaction following implant therapy. A 10-year prospective cohort study." *Clin Oral Implants Res* 16(2): 185–93.
- Shillingburg, H. T. (1997). *Fundamentals of fixed prosthodontics*. Chicago, Quintessence Pub. Co.
- Ship, J. A., S. R. Pillemer et al. (2002). "Xerostomia and the geriatric patient." *J Am Geriatr Soc* 50(3): 535–43.
- Sjogren, U., B. Hagglund et al. (1990). "Factors affecting the long-term results of endodontic treatment." *J Endod* 16(10): 498–504.
- Sorensen, J. A. and J. T. Martinoff (1984). "Intracoronary reinforcement and coronal coverage: a study of endodontically treated teeth." *J Prosthet Dent* 51(6): 780–4.
- Stead, L. F., R. Perera et al. (2008). "Nicotine replacement therapy for smoking cessation." *Cochrane Database Syst Rev* (1): CD000146.
- Yi, S. W., G. E. Carlsson et al. (2001). "Patient evaluation of treatment with fixed implant-supported partial dentures." *J Oral Rehabil* 28(11): 998–1002.

Case 26

Case 26

Prognostic indicators for strategic extractions in a full mouth rehabilitation

With increasing emphasis on evidence-based practice, the decision-making for an appropriate comprehensive treatment plan is a complicated process due to many

confounding factors. In this chapter, various treatment approaches are discussed for the rehabilitation of partially edentulous arches.

CASE STORY

A 45-year-old female patient presents not having been to a dentist for more than 5 years. Her chief complaint was "I would like to have better looking teeth." The patient has been receiving sporadic dental treatments during the past 10 years. She stated that the teeth were lost due to extensive decay resulting in abscesses requiring extractions.

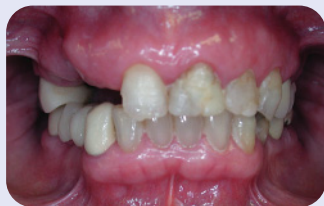

Figure 1: Preoperative presentation.

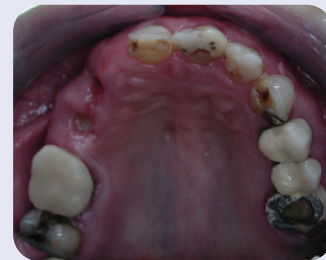

Figure 2: Preoperative maxilla.

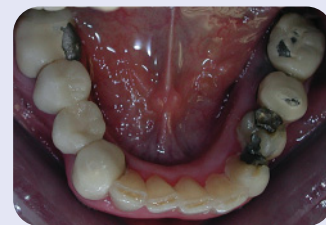

Figure 3: Preoperative mandible.

LEARNING GOALS AND OBJECTIVES

- To plan treatment for a full mouth rehabilitation on severely compromised dentition
- Strategic extraction
- Prognostic determinants for periodontal stability
- Survival rate of endodontically treated teeth
- Survival of fixed partial dentures
- Prosthetic complications of implant-supported/retained prostheses

Medical History

- No contributory findings noted

Dental History

- Sporadic dental treatments during the past 10 years

Clinical Findings/Problem List

- Partially edentulous maxilla: missing maxillary right first premolar, canine, lateral incisor (5, 6, and 7)
- Partially edentulous mandible: missing mandibular right first and second premolars (28 and 29)
- Multiple defective existing restorations
- Presence of clinical mobility on maxillary right first molar (3) with recurrent caries
- Grade 2 furcation involvement on mandibular left first molar (19)
- Poor oral hygiene
- Moderate to severe plaque and calculus accumulation
- Presence of endodontically treated teeth with recurrent caries

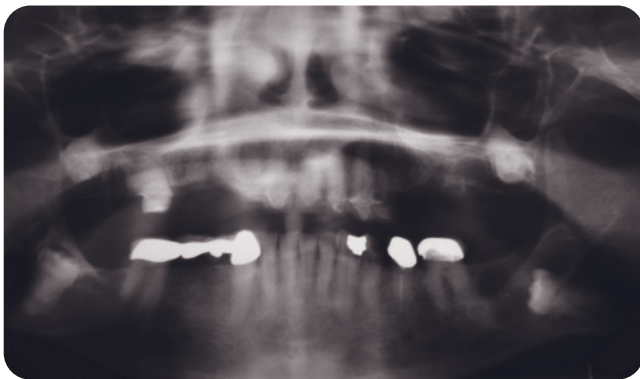
Radiographic Findings

Figure 4: Radiograph after extractions of 2, 5, 6, 7, 12 to 15.

Diagnosis

- Maxillary and mandibular partial edentulism
- Defective existing restorations

- Recurrent caries
- Chronic generalized moderate periodontitis

Clinical Decision-Making Determining Factors

- The severity of bleeding on probing, probing depth, and tooth mobility are important in determining clinical parameters. However, these parameters are only valid predictors for teeth with good prognoses. (Nordland, Garrett et al. 1987; Badersten, Nilvrus et al. 1990; Claffey and Egelberg 1995).
- Several retrospective studies suggested furcation involvement was one of the main reasons for tooth loss. In a review of therapeutic outcomes, retention rates of furcated teeth ranged from 43–98%, suggesting that the actual retention rate is better than the long-term predicted prognosis (Hirschfeld and Wasserman 1978; McFall 1982; Becker, Berg et al. 1984).
- In a systematic review of the endodontic literature, the survival rate after endodontic treatment followed by coronal restoration ranged from 81.2–100% over 3–25 years (Iqbal 2007).
- Endodontic retreatment can significantly reduce the 97% success rate seen with initial endodontic therapy.
- Surgical retreatment of a poorly endodontically filled tooth can reduce the success rate by as much as 13–29% (Molven, Halse et al. 2002; Farzaneh, Abitbol et al. 2004; Friedman and Mor 2004).
- If available bone height and width are insufficient, socket or ridge preservation, guided bone regeneration, and distraction osteogenesis can be effective ridge-enhancement techniques prior to implant placement (Fiorellini and Nevins 2003; Wallace, Froum et al. 2003).
- For the treatment of this patient, the remaining posterior teeth except the mandibular right first molar (30) were extracted due to its poor periodontal prognosis with either the presence of furcation involvement and/or recurrent caries. Then, the maxillary and mandibular edentulous spaces were restored with implant-supported fixed restorations.

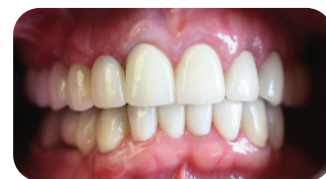

Figure 5: Postoperative presentation.

Questions

1. Loss of vertical dimension of occlusion can be observed when

- A. There is loss of posterior support.
- B. There is absence of compensatory continuous eruption of teeth.
- C. There is excessive parafunctional habit.
- D. All of the above

2. Modification of centric occlusion anatomy is the recommended approach for reduction of occlusal loading in implant therapy. The following statements pertain to this theory *except*

- A. Horizontal 0.5mm area of centric contact
- B. Area of centric contacts produces lateral occlusal forces.
- C. This concept is based on the differential mobility between implant and natural dentition.
- D. Reduction of occlusal loading can also be achieved by increasing the vertical overlap in the anterior teeth.

3. Strategic extraction refers to the removal of a tooth or root to enhance the status and prognosis of an adjacent tooth or the overall prosthetic treatment plan. Which of the following statements regarding "strategic extraction" is *incorrect*?

- A. Predicting individual tooth prognosis is usually based on clinical and radiographic parameters.
- B. Clinical parameters that are effective in predicting teeth with good prognosis are ineffective for poor and questionable prognoses.
- C. The predicting accuracy for teeth with a good prognosis is reported as 81% after 8 years, but this decreased to 35% for teeth with an initial prognosis of less than good.
- D. The long-term retention of teeth with questionable prognoses is high.

4. Which of the following statements regarding bruxism and dental implants is *correct*?

- A. There is significant evidence of the possible cause-and-effect relationship between bruxism and implant failure.
- B. The lack of consistent evidence is due to the large variation in the literature in terms of both the technical and biological aspects of study material.
- C. To protect the implant system from lateral components of the occlusal forces, multiple contacts as close to the center of the implant are recommended.

5. The maximum vertical forces on implants in the premolar region during habitual mastication are reported to vary from

- A. 30–59 N
- B. 60–120 N
- C. 121–240 N
- D. 241–520 N

6. Using clinical parameters as predictors of periodontal disease progression has been extensively studied. Which of the following parameters is the best predictor?

- A. Bleeding on probing
- B. Furcation involvement
- C. Plaque index
- D. Mobility
- E. All of the above

7. Most prosthetic complications are related to the use of implants with overdentures and fixed removable prostheses versus implant-supported fixed restorations.

- A. True
- B. False

8. The survival rates of endodontically treated teeth were reported to be

- A. Statistically similar to implant restorations
- B. Higher than implant restorations
- C. Independent of the type of coronal restoration
- D. Dependent on the amount of remaining coronal tooth structure

ANSWERS

1. D (Turner and Missirlian 1984)
2. B (Weinberg 2001)
3. D (Kao 2008)
4. B (Lobbezoo, Brouwers et al. 2006)

5. B (Lobbezoo, Brouwers et al. 2006)
6. A (Lang, Adler et al. 1990; Ericsson, Giargia et al. 1993; McGuire and Nunn 1996; Kao 2008)
7. A (Goodacre, Bernal et al. 2003)
8. D (Iqbal 2007)

The authors would like to acknowledge and thank Dr. Bhavani Venkatachalam for the clinical case photographs and treatment performed at New York University, College of Dentistry.

References

- Badersten, A., R. Nilvrus et al. (1990). "Scores of plaque, bleeding, suppuration and probing depth to predict probing attachment loss. 5 years of observation following nonsurgical periodontal therapy." *J Clin Periodontol* 17: 108–114.
- Becker, W., L. Berg et al. (1984). "The long-term evaluation of periodontal treatment and maintenance in 95 patients." *Int J Periodontics Restorative Dent* 4: 54–71.
- Claffey, N. and J. Egelberg (1995). "Clinical indicators of probing attachment loss following initial periodontal treatment in advanced periodontitis patients." *J Clin Periodontol* 22: 690–696.
- Ericsson, I., M. Giargia et al. (1993). "Progression of periodontal tissue destruction at splinted/non-splinted teeth. An experimental study in the dog." *J Clin Periodontol* 20(10): 693–698.
- Farzaneh, M., S Abitbol et al. (2004). "Treatment outcome in endodontics: The Toronto Study. Phase I and II: Orthograde retreatment." *J Endod* 30: 627–633.
- Fiorellini, J. P. and M. Nevins (2003). "Localized ridge augmentation/preservation. A systematic review." *Ann Periodontol* 2003: 321–327.
- Friedman, S. and C. Mor (2004). "The success of endodontic therapy—Healing and functionality." *J Calif Dent Assoc* 32: 493–503.
- Goodacre, C. J., G. Bernal et al. (2003). "Clinical complications with implants and implant prostheses." *J Prosthet Dent* 90(2): 121–132.
- Hirschfeld, L. and B. Wasserman (1978). "A long-term survey of tooth loss in 600 treated periodontal patients." *J Periodontol* 49: 225–237.
- Iqbal, M. K. (2007). "For teeth requiring endodontic treatment, what are the differences in outcomes of restored endodontically treated teeth compared to implant-supported restorations?" *Int J Oral Maxillofac Implants* 22(Suppl.): 96–116.
- Kao, R. T. (2008). "Strategic extraction: a paradigm shift that is changing our profession." *J Periodontol* 79(6): 971–977.
- Lang, N. P., R. Adler et al. (1990). "Absence of bleeding on probing. An indicator of periodontal stability." *J Clin Periodontol* 17(10): 714–721.
- Lobbezoo, F., J. E. Brouwers et al. (2006). "Dental implants in patients with bruxing habits." *J Oral Rehabil* 33(2): 152–159.
- McFall, Jr., W. T. (1982). "Tooth loss in 100 treated patients with periodontal disease. A long-term study." *J Periodontol* 53: 539–549.
- McGuire, M. K. and M. E. Nunn (1996). "Prognosis versus actual outcome. II. The effectiveness of clinical parameters in developing an accurate prognosis." *J Periodontol* 67(7): 658–665.

Molven, O., A. Halse et al. (2002). "Periapical changes following root-canal treatment observed 20–27 years postoperatively." *Int Endod J* 35: 784–790.

Nordland, P., S. Garrett et al. (1987). "The effect of plaque control and root debridement in molar teeth." *J Clin Periodontol* 14(231–236).

Turner, K. A. and D. M. Missirlian (1984). "Restoration of the extremely worn dentition." *J Prosthet Dent* 52(4): 467–474.

Wallace, S. S., S. J. Froum et al. (2003). "Effect of maxillary sinus augmentation on the survival of endosseous dental implants. A systematic review." *Ann Periodontol* 8: 328–343.

Weinberg, L. A. (2001). "Therapeutic biomechanics concepts and clinical procedures to reduce implant loading. Part II: therapeutic differential loading." *J Oral Implantol* 27(6): 302–310.

Case 27

Case 27

Treatment of a patient with implant-supported fixed complete denture prostheses

Selection of appropriate design of prostheses that can be maintained requires understanding of the mechanical properties of prostheses, oral physiology, and anatomy. This combined knowledge will help clinicians

make treatment decisions that will succeed. In this chapter, implant-supported prostheses and smoking habit and their effect on the overall long-term treatment success are discussed.

CASE STORY

A 43-year-old female presents with the chief complaint of "I cannot chew with my back teeth."

The patient was very concerned with aesthetics and the fit of her mandibular partial denture, and she wanted a more stable prosthesis for her mandible.

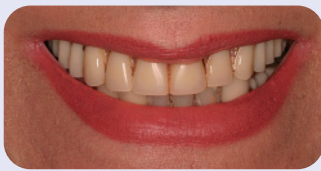

Figure 1: Pretreatment frontal view.

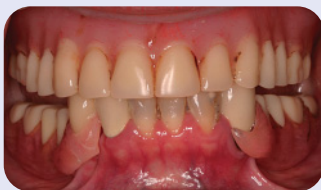

Figure 2: Pretreatment frontal intraoral view.

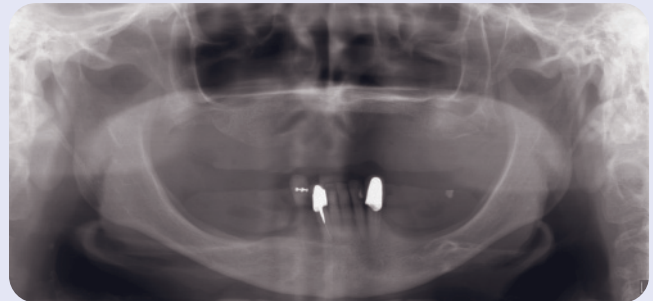

Figure 3: Panoramic radiograph.

LEARNING GOALS AND OBJECTIVES

- Identify the common complications in implant-supported fixed completed denture prostheses.
- Identify factors influencing the generated preload between the implant and implant-abutment.
- Learn the effect of smoking on osseointegration of dental implants in the maxilla and mandible.

Medical History

- No significant findings

Dental History

- The existing prostheses were made 5 years ago.

Social History

- Smoking: for the past 20 years, 1 pack per day

Clinical Findings/Problem list

- Smoking habit
- Inadequate maxillary complete denture
- Inadequate posterior occlusion with the existing prostheses
- Severely resorbed mandibular posterior ridge
- Periodontally compromised remaining mandibular dentition

Radiographic Findings

- Widening of periodontal ligament (PDL) space
- Generalized bone loss around the remaining mandibular dentition

Diagnosis

- Complete edentulism in maxilla
- Defective restorations and prostheses
- Recurrent caries
- Chronic moderate to severe adult periodontitis

Clinical Decision-Making Determining Factors

- The use of implant-supported fixed complete denture prostheses has been shown as a viable option for rehabilitating the missing soft and hard tissue structures (Naert, Quirynen et al. 1992).
- A common and frequently reported complication of implant-supported prostheses is loosening of abutment or prosthetic screws (Jemt 1991; Naert, Quirynen et al. 1992; Goodacre, Bernal et al. 2003).
- Preload refers to the degree of tightness of a screw-in implant. The key factors influencing preload are the applied torque and coefficient of friction between the screw threads and implant (Guda, Ross et al. 2008).
- The reduction of coefficient of friction on abutment screws can generate greater preload values (Martin, Woody et al. 2001).
- The maintenance of initially generated preload is influenced by the passive-fit of implant-supported

framework and careful control of occlusion (Adell, Lekholm et al. 1981; Kallus and Bessing 1994).

- Smoking, especially during the healing phase, has been associated with a higher implant failure rate (Bain and Moy 1993; Lambert, Morris et al. 2000; Bain, Weng et al. 2002).
- The risks of implant failures and biological complications with and without accompanying augmentation procedures was found to be significantly increased in smokers compared with nonsmokers (Klokkevold and Han 2007; Abt 2009).
- Use of surface-treated implants has been suggested in smokers and was shown to have less impact on the prognosis of implants (Bain, Weng et al. 2002; Kumar, Jaffin et al. 2002; Abt 2009).
- Complete and temporary smoking cessation at the time of healing have been shown to reduce the negative effect of smoking on bone healing around implant (Bain 1996; Cesar-Neto, Benatti et al. 2005).

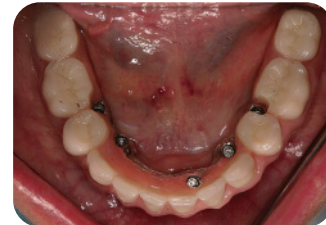

Figure 4: Mandibular prosthesis intraoral view.

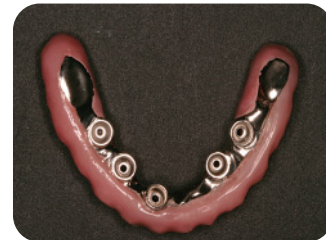

Figure 5: Mandibular prosthesis, intaglio surface.

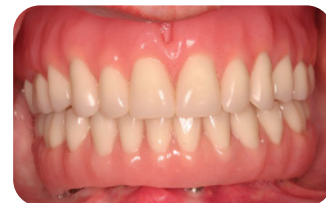

Figure 6: Posttreatment intraoral frontal view.

Questions

1. The key factor(s) in successful long-term implant-supported fixed prosthesis is/are

- A. Appropriate long-term maintenance program
- B. Stability of prosthesis
- C. Passive fit of implant components
- D. All of the above

2. Regarding the cantilevered full-arch implant-supported fixed prosthesis and the gold abutment screws, which of the following statements is *incorrect*?

- A. No differences in screw tightness were found among different implant positions.
- B. Pivoting of the prosthesis was detected only when all screws within the prosthesis are loose.
- C. Loss of clamping force between the gold cylinders and gold screws may be the result of the discrepancy between framework and abutments.
- D. There were differences in screw tightness when different implant positions were present.

3. Passive fit of a screw-retained prosthesis can be evaluated by

- A. Testing of framework elevation under tension from each of the gold screws tightened one at a time
- B. Periotest
- C. Reverse torque test
- D. Mobility test

4. Preload generated between the abutment screws and implants can be improved by

- A. Enhancing surfaces on abutment screws that reduce the coefficient of friction
- B. Increasing the coefficient of friction between the surfaces
- C. Allowing multiple tightening and loosening of the screw
- D. Applying lower torque

5. With regard to smoking and dental implants, which of the following statements is *incorrect*?

- A. Smoking can reduce the osseointegration success.
- B. Success rate of dental implants between the smoking group and nonsmoking group with surface-modified implants significantly differed.
- C. Smoking decreases tissue oxygenation.
- D. Machined surface implants appear to have higher failure rate in smokers.

6. The recommended smoking cessation protocol for implant surgery is

- A. Complete cessation of smoking 1 week before and 8 weeks after the initial implant placement
- B. Complete cessation of smoking after the initial implant placement
- C. Complete cessation of smoking 2 weeks prior to initial implant placement
- D. Complete cessation of smoking 2 weeks before and 4 weeks after the initial implant placement

7. The effect of smoking on implant success and survival appeared to be more pronounced in

- A. Type I bone
- B. Type II bone
- C. Type III bone
- D. Type IV bone

8. The recommended occlusal concept for a conventional maxillary complete denture opposing mandibular implant-supported fixed complete denture is

- A. Mutually protected occlusion
- B. Canine guidance
- C. Unilateral balanced occlusion
- D. Bilateral balanced occlusion

9. The following are the signs of occlusal overload on implants *except*

- A. Screw loosening/fracture
- B. Bone loss
- C. Prosthesis fracture
- D. Periimplantitis

ANSWERS

1. D (Adell, Lekholm et al. 1981; Kallus and Bessing 1994)
2. D (Kallus and Bessing 1994)
3. A (Jemt 1991)
4. A (Martin, Woody et al. 2001; Guda, Ross et al. 2008)

5. B (Kumar, Jaffin et al. 2002; Bain, Weng et al. 2002; Moy, Medina et al. 2005)
6. A (Bain 1996)
7. D (Klokkevold and Han 2007)
8. D (Wismeijer, van Waas et al. 1995)
9. D (Kim, Oh et al. 2005)

The authors would like to acknowledge and thank Dr. Robert Berg for clinical case photographs and treatment performed.

References

- Abt, E. (2009). "Smoking increases dental implant failures and complications." *Evid Based Dent* 10(3): 79–80.
- Adell, R., U. Lekholm et al. (1981). "A 15-year study of osseointegrated implants in the treatment of the edentulous jaw." *Int J Oral Surg* 10(6): 387–416.
- Bain, C. A. (1996). "Smoking and implant failure—benefits of a smoking cessation protocol." *Int J Oral Maxillofac Implants* 11(6): 756–759.
- Bain, C. A. and P. K. Moy (1993). "The association between the failure of dental implants and cigarette smoking." *Int J Oral Maxillofac Implants* 8(6): 609–615.
- Bain, C. A., D. Weng et al. (2002). "A meta-analysis evaluating the risk for implant failure in patients who smoke." *Compend Contin Educ Dent* 23(8): 695–699, 702, 704 passim; quiz 708.
- Cesar-Neto, J. B., B. B. Benatti et al. (2005). "Bone density around titanium implants may benefit from smoking cessation: a histologic study in rats." *Int J Oral Maxillofac Implants* 20(5): 713–719.
- Cesar-Neto, J. B., B. B. Benatti et al. (2005). "Bone filling around titanium implants may benefit from smoking cessation: a histologic study in rats." *J Periodontol* 76(9): 1476–1481.
- Goodacre, C. J., G. Bernal et al. (2003). "Clinical complications with implants and implant prostheses." *J Prosthet Dent* 90(2): 121–132.
- Guda, T., T. A. Ross et al. (2008). "Probabilistic analysis of preload in the abutment screw of a dental implant complex." *J Prosthet Dent* 100(3): 183–193.
- Jemt, T. (1991). "Failures and complications in 391 consecutively inserted fixed prostheses supported by Branemark implants in edentulous jaws: a study of treatment from the time of prosthesis placement to the first annual checkup." *Int J Oral Maxillofac Implants* 6(3): 270–276.
- Kallus, T. and C. Bessing (1994). "Loose gold screws frequently occur in full-arch fixed prostheses supported by osseointegrated implants after 5 years." *Int J Oral Maxillofac Implants* 9(2): 169–178.
- Kim, Y., T. J. Oh et al. (2005). "Occlusal considerations in implant therapy: clinical guidelines with biomechanical rationale." *Clin Oral Implants Res* 16(1): 26–35.
- Klokkevold, P. R. and T. J. Han (2007). "How do smoking, diabetes, and periodontitis affect outcomes of implant treatment?" *Int J Oral Maxillofac Implants* 22 Suppl: 173–202.
- Kumar, A., R. A. Jaffin et al. (2002). "The effect of smoking on achieving osseointegration of surface-modified implants: a clinical report." *Int J Oral Maxillofac Implants* 17(6): 816–819.
- Lambert, P. M., H. F. Morris et al. (2000). "The influence of smoking on 3-year clinical success of osseointegrated dental implants." *Ann Periodontol* 5(1): 79–89.
- Martin, W. C., R. D. Woody et al. (2001). "Implant abutment screw rotations and preloads for four different screw materials and surfaces." *J Prosthet Dent* 86(1): 24–32.
- Moy, P. K., D. Medina et al. (2005). "Dental implant failure rates and associated risk factors." *Int J Oral Maxillofac Implants* 20(4): 569–577.
- Naert, I., M. Quirynen et al. (1992). "A six-year prosthodontic study of 509 consecutively inserted implants for the treatment of partial edentulism." *J Prosthet Dent* 67(2): 236–245.
- Naert, I., M. Quirynen et al. (1992). "A study of 589 consecutive implants supporting complete fixed prostheses. Part II: Prosthetic aspects." *J Prosthet Dent* 68(6): 949–956.
- Wismeijer, D., M. A. van Waas et al. (1995). "Factors to consider in selecting an occlusal concept for patients with implants in the edentulous mandible." *J Prosthet Dent* 74(4): 380–384.

WWW.HIGHDENT.IR

همیار دندانسازان و دندانپزشکان

Case 28

Case 28

Full mouth rehabilitation—implant-supported prostheses I

Restoration of a completely edentulous maxilla requires a comprehensive evaluation of soft and hard tissues in order to determine the appropriate treatment modality for replacement of missing structures with the best functional and aesthetic result.

CASE STORY

A 57-year-old female with failing extensive previous dental restorations presents to restore function and aesthetics. She complains of tooth sensitivity and aesthetic concerns of the existing restorations.

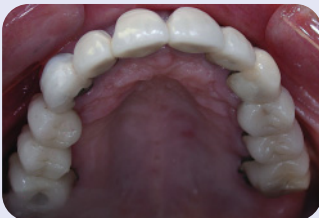

Figure 1: Preoperative maxilla.

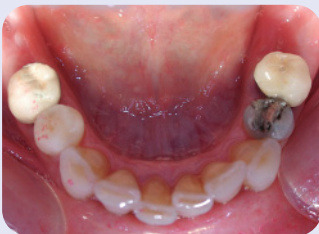

Figure 2: Preoperative mandible.

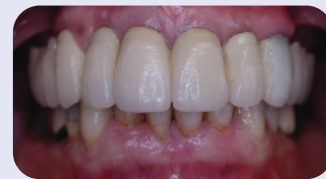

Figure 3: Preoperative presentation.

LEARNING GOALS AND OBJECTIVES

- Longevity of fixed restorations
- Advantages and disadvantages of implant-supported fixed detachable prostheses
- Significance of posterior support
- Implant therapy success in the maxillary region
- Number of implants desired for maxillary implant-supported restoration
- Anterior-posterior spread for implant-supported prosthesis
- Evaluation of soft and hard tissue volume to support a prosthesis

Medical History

- No significant contributory findings

Dental History

- Maxillary long-span fixed partial denture, inserted 7 years ago
- Mandibular single-unit restorations, inserted 7 years ago
- Patient is experiencing tooth sensitivity and is dissatisfied with function and aesthetics.

Clinical Findings/Problem List

- Caries
- Partial edentulism
- Multiple defective restorations
- Fair oral hygiene with presence of mobility on existing maxillary prostheses

Radiographic Findings

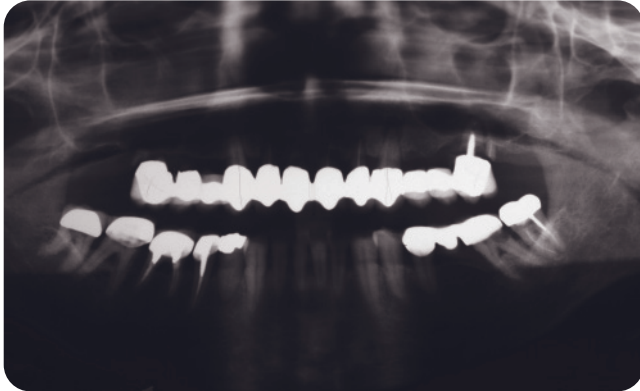


Figure 4: Preoperative panoramic radiograph prior to extraction of mandibular molars.

Diagnosis

- Defective restorations
- Maxillary and mandibular partial edentulism
- Generalized moderate periodontitis
- Caries

Clinical Decision-Making Determining Factors

- In restoring the edentulous maxilla, several prosthesis designs, such as implant-supported fixed restorations, implant-supported fixed complete denture prosthesis, and implant-retained removable prosthesis should be considered. The amount of soft and hard tissue loss and position, distribution, and number of implants play important roles in determining definitive prosthesis design. The ultimate goal of the proposed treatment plan should be to restore the biological architectures while achieving optimal oral function and aesthetic outcome without overloading the prosthesis (Zitzmann 1999):
 - When considering the length of cantilever distal to the most posterior implants, a minimum anterior-posterior spread (AP) of 10mm has been suggested to provide a biomechanically acceptable cantilever length (Ranger 1989).
 - Maximum cantilever length includes use of anterior-posterior spread (AP) greater than 10mm,

or 1.5–2 times the AP (McAlarney and Stavropoulos 2000).

- For 5 and 6 implants, the resultant cantilever length–anterior-posterior spread, an average of 1.5 ratio is recommended (McAlarney and Stavropoulos 2000).
- Determination of maxillary incisor plane/aesthetic plane of the planned prosthesis relative to the maxillary alveolar ridge position is a critical step in selecting definitive prosthesis design:
 - After the extraction of teeth, the alveolar ridges undergo a continuous resorption. The resorption pattern in the maxilla is cranially and medially directed. This results in a palatal position of the anterior maxilla (Atwood 1979; Desjardins 1992).
 - Facial parameters such as facial support, lip support, smile line, and upper lip length should be assessed during the extraoral examination phase (Zitzmann 1999).
 - The desired maxillary incisal plane should not infringe on the closest speaking space.
 - The principles of complete denture prosthesis fabrication are applied in determining the appropriate vertical dimension required for restorative space and in preparing the diagnostic setup.
 - When evaluating a patient's aesthetics, certain parameters help guide the position of maxillary anterior teeth. In patients with short upper lips, up to 4mm of the maxillary central incisors can be visible with lips at rest. Average maxillary lip lengths of 21–25mm can lead to a display of up to 2.2 mm of teeth. Extremely long upper lips (31–35 mm) can cover almost the entire length of the incisors displaying 0.25 mm (Vig 1978).
 - The average smile displays about 75–100% of maxillary incisors. The evaluation of the smile for implant prosthesis in the maxilla is recommended to be performed with an anterior flangeless prosthesis. When the alveolar ridge is displayed during smiling, the use of a buccal flange in a removable prosthesis is advised to prevent aesthetic problems (Tjan, Miller et al. 1984; Taylor 1991).
 - The incisal edge of the central incisors should contact the vermillion border of the lower lip when an "f" sound is pronounced (Burnett and Clifford 1992, 1993; Burnett 1994).
- The factors influencing selection of the type of implant-supported (screw-retained implant prosthesis versus cement-retained) fixed prostheses are 1) ease of fabrication and cost, 2) passivity of the

framework, 3) retention, 4) occlusion, 5) aesthetics, 6) ease of delivery, and 7) retrievability (Michalak, Hirayama et al. 2003).

- When evaluating the space required for suitable implant-supported or retained prosthesis, the position and volume of available bone in relation to the potential definitive prosthesis design should be assessed first.
- The use of the buccal and/or palatal flange is determined during the tooth arrangement try-in stage by taking into consideration the smile line, the need for facial support, and phonetic requirements. Based on the volume of hard and soft tissue that requires replacement, the prosthesis design should be determined (Zitzmann 1999).
- Due to insufficient number of remaining maxillary dentitions that are restorable, it was determined to extract the maxillary teeth. The remaining mandibular posterior teeth were extracted due to the extensive carious lesions. Further evaluation of the maxilla revealed the need for a prosthesis with flanges in order to support extra oral tissues properly. Based on this determination, a fixed complete denture prosthesis design was selected for the maxillary arch. The mandibular posterior teeth were restored with implant-supported fixed restorations up to first molars. Furthermore, an occlusal device was fabricated over the mandibular restorations to protect the prosthesis and restorations.

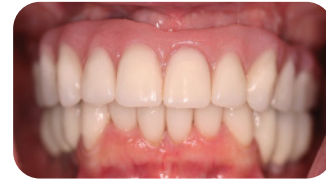

Figure 5: Postoperative presentation.

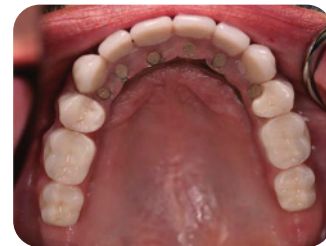

Figure 6: Postoperative maxilla.

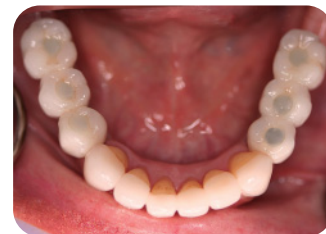

Figure 7: Postoperative mandible.

Questions

1. Anterior-posterior (AP) spread is often referred to as an indication of the ability to cantilever in completely implant-supported prostheses. The cantilever length–anterior-posterior spread ratio is determined based on the following:

- A. Maximum cantilever can be increased by decreasing the AP (offset).
- B. Adherence to the calculated cantilever may sometimes lead to prostheses that are biomechanically unacceptable.
- C. Clinical implant distributions and the relationship between cantilever length and AP spread is linear but related to the number of implants.
- D. The use of a ratio of 2 is appropriate only for 5 and 6 implant cases.

2. Nonpassively fitting framework implant-supported prosthesis can lead to

- A. Bone loss
- B. Development of microflora at the gap between the implant and the abutment
- C. Loosening or fracture of the screw and implant fracture
- D. All of the above

3. Which of the following statements regarding the screw-retained and cement-retained prostheses is correct?

- A. The absence of passive fit of cement-retained superstructures results in greater stress concentrations around the implant in comparison to screw-retained prostheses.
- B. Screw-retained prostheses have exhibited significantly smaller marginal opening than cement-retained prostheses.
- C. Implant fracture due to framework misfit is the most common complication in both the screw-retained and cement-retained prostheses.
- D. Most implant fractures due to framework misfit occurred toward the apex of implant in both the screw-retained and cement-retained prostheses.

4. Regarding maxillary fixed-detachable prosthesis:

- A. It helps to enhance aesthetics and phonetics.
- B. A design allowing for 1.5mm of minimum space between the prosthesis and the soft tissue is to ensure optimal aesthetics.
- C. Early designs had reported aesthetic changes as a routine complication.
- D. The profile of the prosthesis uses a framework design with supragingival abutment emergence.

5. Extraoral clinical examination should include facial parameters such as facial support, lip support, smile line, and upper lip length. When evaluating the need for maxillary extraoral soft tissue support, the following should be considered:

- A. In the dentate maxilla, lip support is primarily derived from the alveolar ridge shape and the clinical crown contour of the maxillary incisors.
- B. In the edentulous maxilla, the resorption pattern is cranially and medially directed so that a palatal position of the anterior maxilla frequently appears.
- C. A denture or denture setup in wax should be used to confirm proper tooth position, border extension, and interarch relationship.
- D. All of the above are correct.

6. Regarding the irreversible complications of fixed partial dentures (FPD) that are short-span or long-span:

- A. Caries was the main reason for failure.
- B. The use of root canal-treated abutment showed significantly more failure in both short-span and long-span FPDs.
- C. A statistically significant difference was found between the survival of short-span and long-span FPDs.
- D. A reversible complication of short-span FPDs within the first 2 years will lead to an irreversible complication.
- E. All of the above are correct.

7. The approximal bone crest reduction between the implant and the adjacent tooth is significantly influenced

- A. By the horizontal distance between the edge of the implant platform and the neighboring tooth
- B. By the vertical implant platform position in relation to the adjacent tooth
- C. By the existing crestal bone level prior to the implant placement
- D. By the absence and presence of periodontal disease

ANSWERS

1. C (McAlarney and Stavropoulos 2000)
2. D (Michalakakis, Hirayama et al. 2003)
3. B (Guichet, Caputo et al. 2000; Michalakakis, Hirayama et al. 2003)
4. A (Jemt 1991; Schnitman 1999; Bedrossian, Sullivan et al. 2008)

5. D (Zitzmann 1999; Bedrossian, Sullivan et al. 2008)
6. E (De Backer, Van Maele et al. 2008)
7. A (Krennmair, Piehslinger et al. 2003)

The authors would like to acknowledge and thank Dr. Guadalupe Garcia for the clinical case photographs and treatment performed at New York University College of Dentistry.

References

- Atwood, D. A. (1979). "Bone loss of edentulous alveolar ridges." *J Periodontol* 50(4 Spec No): 11–21.
- Bedrossian, E. S., R.M. Sullivan et al. (2008). "Fixed-prosthetic implant restoration of the edentulous maxilla: a systematic pretreatment evaluation method." *J Oral Maxillofac Surg* 66(1): 112–22.
- Burnett, C. A. (1994). "Reproducibility of the speech envelope and interocclusal dimensions in dentate subjects." *Int J Prosthodont* 7(6): 543–8.
- Burnett, C. A. and T. J. Clifford (1992). "A preliminary investigation into the effect of increased occlusal vertical dimension on mandibular movement during speech." *J Dent* 20(4): 221–4.
- Burnett, C. A. and T. J. Clifford (1993). "Closest speaking space during the production of sibilant sounds and its value in establishing the vertical dimension of occlusion." *J Dent Res* 72(6): 964–7.
- De Backer, H., G. Van Maele et al. (2008). "Long-term results of short-span versus long-span fixed dental prostheses: an up to 20-year retrospective study." *Int J Prosthodont* 21(1): 75–85.
- Desjardins, R. P. (1992). "Prosthesis design for osseointegrated implants in the edentulous maxilla." *Int J Oral Maxillofac Implants* 7: 311–20.
- Guichet, D. L., A. A. Caputo et al. (2000). "Passivity of fit and marginal opening in screw- or cement-retained implant fixed partial denture designs." *Int J Oral Maxillofac Implants* 15: 239–46.
- Jemt, T. (1991). "Failures and complications in 391 consecutively inserted fixed prostheses supported by Branemark implants in edentulous jaws: a study of treatment from the time of prosthesis placement to the first annual checkup." *Int J Oral Maxillofac Implants* 6(3): 270–6.
- Krennmair, G., E. Piehslinger et al. (2003). "Status of teeth adjacent to single-tooth implants." *Int J Prosthodont* 16(5): 524–8.
- McAlarney, M. E. and D. N. Stavropoulos (2000). "Theoretical cantilever lengths versus clinical variables in fifty-five clinical cases." *J Prosthet Dent* 83(3): 332–43.
- Michalakakis, K. X., H. Hirayama et al. (2003). "Cement-retained versus screw-retained implant restorations: a critical review." *Int J Oral Maxillofac Implants* 18(5): 719–28.
- Ranger, B., T. Jemt et al. (1989). "Forces and moments on Branemark implants." *Int J Oral Maxillofac Implants* 4(3): 241–47.
- Schnitman, P. A. (1999). "The profile prosthesis: an aesthetic fixed implant-supported restoration for the resorbed maxilla." *Pract Periodontics Aesthet Dent* 11(1): 143–51.
- Taylor, T. D. (1991). "Fixed implant rehabilitation for the edentulous maxilla." *Int J Oral Maxillofac Implants* 6(3): 329–37.
- Tjan, A. H., G. D. Miller et al. (1984). "Some esthetic factors in a smile." *J Prosthet Dent* 51(1): 24–8.
- Vig, R. G. and G. C. Brundo (1978). "The kinetics of anterior tooth display." *J Prosthet Dent* 39: 502–504.
- Zitzmann, N. U. and C. P. Marinello (1999). "Treatment plan for restoring the edentulous maxilla with implant-supported restorations: Removable overdenture versus fixed partial denture design." *J Prosthet Dent* 82(2): 188–96.

Case 29

Case 29

Full mouth rehabilitation—implant-supported prostheses II

CASE STORY

A 53-year-old partially edentulous male patient presents with a chief complaint of “I’m tired of wearing removable dentures and would really like to have something that doesn’t come in and out of my mouth.” The patient has been edentulous for 5 years, having lost his teeth mostly due to caries and neglect. After thorough diagnostic assessment, it was determined that this patient is a suitable candidate for fixed prostheses on endosseous implants. The decision was made to keep the patient’s last remaining tooth (mandibular left 3rd molar, 17) because the patient was reluctant to allow its extraction for personal reasons.

Six implants were placed in each arch in locations determined in consultation with the oral surgeon. The definitive prostheses will be metal-resin implant fixed complete denture or sometimes known as implant-supported complete prosthesis. Treatment planning and sequencing will be discussed for this

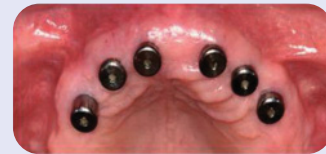

Figure 1: Postsurgical presentation of maxilla.

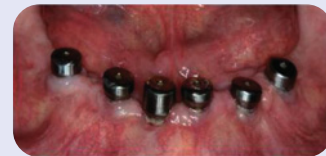

Figure 2: Postsurgical presentation of mandible.

patient, including some laboratory procedures that are involved in planning complex treatments such as the one presented here.

The figures above show the patient’s clinical presentation after implant placement and second stage surgery.

LEARNING GOALS AND OBJECTIVES

- Sequence of treatment planning for implant-supported fixed complete denture
- Diagnostic imaging and treatment planning for implant placement
- Selection of appropriate impression technique
- Discussion of possible posttreatment prosthetic complications

Medical History

- No significant findings

Dental History

- Multiple carious lesions requiring extensive restoration
- Extraction of hopeless and unrestorable teeth

Medications and Allergies

- No medications
- No known drug allergies

Clinical Cases in Prosthodontics, Leila Jahangiri, Marjan Moghadam, Mijin Choi, and Michael Ferguson, © 2011 Blackwell Publishing Ltd.

Review of Systems

- Vital signs:
 - Blood pressure: 120/80
 - Heart rate: 68 beats/minute
 - Respiration rate: 16 breaths/minute

Social History

- No significant findings

Significant Soft Tissue Examination Findings

- No significant findings

Significant Clinical Findings/Problem List

- Partial edentulism
- Unsatisfactory existing removable prostheses

Radiographs

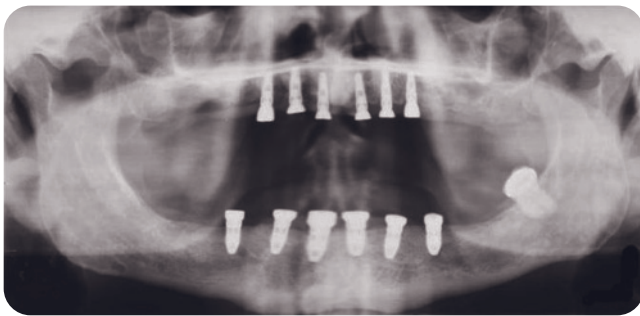


Figure 3: Postsurgical panoramic radiograph.

Diagnosis

- Mandibular partial edentulism

Clinical Decision-Making Determining Factors

- Maxillary complete edentulism
- In preparation for surgical placement of endosseous implants, several diagnostic procedures must be completed. Two crucial procedures that will determine prosthetic and surgical outcomes are
 - Radiographic examination of the remaining residual ridges
 - Assessment of interarch space to determine whether adequate space exists for prostheses and implant components
- Radiographic examination may include 2-dimensional assessment such as a panoramic radiograph or a 3-dimensional assessment with a computed tomography (CT). Conventional CT scans for use in

treatment planning for dental implant placement are thought to be associated with excessive exposure to radiation. The recent development of cone beam volumetric tomography (CBVT) has alleviated concerns of excess exposure to radiation in implant treatment planning. The average exposure in CBVT is about 12.0 microsieverts as opposed to about 480–720 microsieverts in conventional CT scans and about 48 microsieverts in panoramic radiographs. Additionally, the CBVT machines are more convenient for in-office use and more affordable as compared to conventional CT machines. As there are many anatomic structures in both the maxilla and the mandible that should be considered in planning for placement of implants, it is recommended in this patient's particular situation that a CBVT scan be performed (Misch 1999; Harris, Buser et al. 2002; Ziegler, Woertche et al. 2002).

- Assessment of interarch space is critical in order to make sure that there is adequate space for all prosthetic components. Patients who have been edentulous for a long time or who have suffered from severe periodontal bone loss typically have adequate interarch space because they have had significant ridge resorption. In patients who have recently become edentulous, a thorough evaluation of the interarch space is critical. This can be done with the aid of a diagnostic artificial tooth arrangement. The diagnostic arrangement is then indexed (shown in Figures 4 and 5 with a silicone putty material). The denture bases are then removed, the index is replaced onto the casts, and tooth position is evaluated relative to the location of the residual ridge (Sadowsky 1997; Filho, Mazaro et al. 2009). The same artificial tooth arrangement information in conjunction with the radiographic assessments will help determine the most suitable positions for implants.

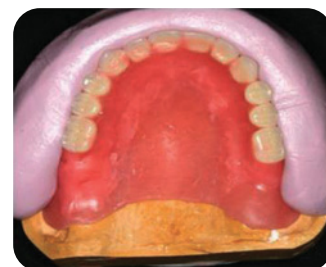

Figure 4: Maxillary diagnostic arrangement with index.

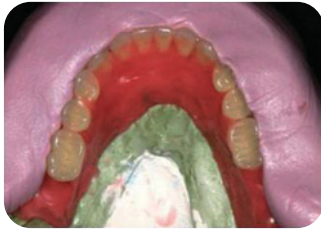

Figure 5: Mandibular diagnostic arrangement with index.

- After implants were placed, the following steps were taken in fabrication of the maxillary and mandibular prostheses:
 - Implant-level definitive impressions were made (see discussion below).
 - Implant-secured record bases were used for recording the centric relation at the appropriate vertical dimension of occlusion.
 - The casts were mounted in centric relation on a semiadjustable articulator.
 - Artificial tooth arrangement was reestablished and verified in the patient as being functional and acceptable.
 - Verification included vertical dimension of occlusion, centric relation, aesthetics, phonetics, and patient's acceptance.
 - An index of the artificial tooth arrangement was made to evaluate denture tooth position in relation to implant location and to confirm adequate space for prosthetic components.

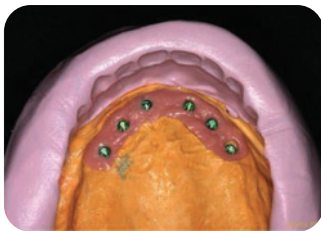


Figure 6: Maxillary definitive cast with index.

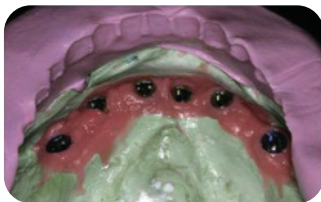

Figure 7: Mandibular definitive cast with index.

- Metal frameworks were fabricated and tried in for passive fit.
- Artificial teeth were rearranged onto the metal framework and tried in to reconfirm vertical

dimension of occlusion, centric relation, aesthetics, and phonetics.

- The prostheses were processed and delivered (Zarb, Bolender et al. 2004).
- Accuracy of the implant-level definitive impression is clearly critical for complex treatments such as the one presented here. An inaccurate impression may require the clinician to section and solder the metal framework—which may lead to an area of weakness in the metal framework, not to mention the extra time and cost involved. Misfit or lack of passive fit can compromise not only the prosthetic outcome of treatment but also may jeopardize the osseointegrated implants and lead to their failure. Several studies, including a recent systematic review, have shown that when making impressions for multiple implants, splinting the implant impression copings together with acrylic resin leads to a more accurate impression. Additionally, the use of the pickup technique (i.e., open tray technique) is more accurate when impressing multiple units (Lee, So et al. 2008; Walker, Ries et al. 2008; Filho, Mazaro et al. 2009; Lee, Heo et al. 2009).

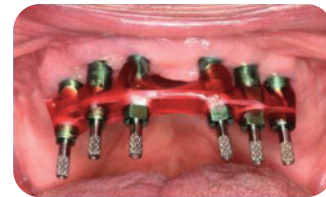


Figure 8: Maxillary pick-up impression copings splinted with autopolymerizing acrylic resin material.

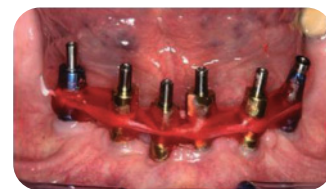

Figure 9: Mandibular pick-up impression copings splinted with autopolymerizing acrylic resin material.

- An inherent problem with the cast metal framework utilized in such treatments is the possibility of metal shrinkage. This may necessitate sectioning and soldering the framework until passive and accurate seating of the framework is achieved on the implants. With the advent of computer-assisted design and computer-assisted manufacturing technology (CAD/CAM), this problem has been

eliminated. With more sophisticated software and most sophisticated milling capabilities, the metal framework for such restorations can be milled by a machine, thereby eliminating issues of casting errors (Carr and Stewart 1993; Riedy, Lang et al. 1997; Torsello, di Torresanto et al. 2008).

- Discussion of possible posttreatment prosthetic complications should be done prior to the start of complex treatment such as the one undertaken with this patient. The patient must be made aware of issues that might arise after the prosthesis has been in function for some time. Studies have shown that there are several common possible prosthetic complications related to fixed complete dental prostheses. These include

- Implant screw loosening, fracture, or stripping
- Framework fracture
- Artificial tooth fracture, wear
- Acrylic resin fracture
- Any of these complications may lead to the need for repair or replacement of the prosthesis. Wear of teeth and resin fracture are commonly encountered and should be expected. Proper home care and recall visits can help identify and address these before a failure and help minimize the incidence of complications. The patient should also be advised of oral hygiene requirements as well as possible implant complications (Attard and Zarb 2004; Malament and Neeser 2004; Al Jabbari, Fournelle et al. 2008; Purcell, McGlumphy et al. 2008).

Questions

1. What is the definition of anterior-posterior distance (also known as "AP spread")?

- Distance from the most distal implants on each side to the center of the most anterior implant
- Distance between the two most distal implants
- Distance between the two most anterior implants
- Total distance from the most distal implant on one side of the arch to the most distal implant on the other side of the arch

2. What is the significance of the anterior-posterior distance in fabricating fixed complete prostheses (assuming the patient exhibits no signs of para-functional habits)?

- Smaller anterior-posterior distance allows for larger posterior teeth to be placed for improvement of chewing efficiency.
- Larger anterior-posterior distance allows for a reduction in the number of required implants.
- Larger anterior-posterior distance allows for further extension of distal cantilever to replace missing posterior teeth.
- Smaller anterior-posterior distance allows for a reduction of gagging in sensitive patients.

3. One of the most important and unique diagnostic capabilities afforded by the use of computed tomography is

- Ability to see anatomic landmarks
- Reduction of radiation to the patient
- Differentiation between hard and soft tissues
- Ability to see nerve fibers in key areas

4. When referring to radiation safety, what does the term ALARA mean?

- As low as reasonably achievable
- As long as reasonably allowed
- As long as reasonably accurate
- As little as recognizably accurate

5. The minimum amount of space recommended for successful placement of implant components and fixed complete denture prosthesis is

- 10 mm
- 12 mm
- 15 mm
- 18 mm

6. Which of the following materials is recommended for making definitive implant-level impressions for fixed complete prostheses?

- A. Irreversible hydrocolloid
- B. Polyether
- C. Reversible hydrocolloid
- D. Polysulfide

7. What material is commonly used for retention of the autopolymerizing acrylic resin to splint the implant impression copings prior to making the definitive impression?

- A. Dental floss
- B. Toothpick
- C. Extra impression copings
- D. None

8. How is passive fit best evaluated during try-in of the metal framework of the fixed complete prosthesis?

- A. Tactile sensation
- B. Radiographic verification
- C. One-screw test
- D. Patient reporting comfort after prosthesis is attached to the implants

9. What has been found to be the most common complication related to the resin portion of the implant-supported complete prosthesis?

- A. Screw fracture
- B. Metal framework fracture
- C. Screw loosening
- D. Need for replacement of artificial teeth

10. With regard to the prosthetic complications with artificial teeth in metal-resin implant-supported complete prosthesis, which is the most common finding?

- A. Tooth wear in anterior artificial teeth and tooth fracture in posterior artificial teeth
- B. Tooth fracture in anterior artificial teeth and tooth wear in posterior artificial teeth
- C. Tooth fracture in both the anterior and posterior artificial teeth
- D. Tooth wear in both the anterior and posterior artificial teeth

ANSWERS

1. A (English 1990; Misch 1999)
2. C (English 1990; Misch 1999)
3. C (Misch 1999)
4. A (Harris, Buser et al. 2002)
5. D (Wong 2002)
6. B (Lee, So et al. 2008)

7. A (Filho, Mazaro et al. 2009)
8. C (Jemt 1991; Purcell, McGlumphy et al. 2008)
9. D (Purcell, McGlumphy et al. 2008; Gallucci, Doughie et al. 2009)
10. B (Purcell, McGlumphy et al. 2008)

The authors would like to acknowledge and thank Dr. Won-Gun Chang for clinical case photographs and treatment performed at New York University College of Dentistry.

References

Al Jabbari, Y. S., R. Fournelle et al. (2008). "Mechanical behavior and failure analysis of prosthetic retaining screws after long-term use in vivo. Part 4: Failure analysis of 10

fractured retaining screws retrieved from three patients." *J Prosthodont* 17(3): 201–210.
 Attard, N. J. and G. A. Zarb (2004). "Long-term treatment outcomes in edentulous patients with implant-fixed prostheses: the Toronto study." *Int J Prosthodont* 17(4): 417–424.
 Carr, A. B. and R. B. Stewart (1993). "Full-arch implant framework casting accuracy: preliminary in vitro observation for in vivo testing." *J Prosthodont* 2(1): 2–8.

- English, C. E. (1990). "Critical A-P spread." *Implant Soc* 1(1): 2-3.
- Filho, H. G., J. V. Mazaro et al. (2009). "Accuracy of impression techniques for implants. Part 2—comparison of splinting techniques." *J Prosthodont* 18(2): 172-176.
- Gallucci, G. O., C. B. Doughtie et al. (2009). "Five-year results of fixed implant-supported rehabilitations with distal cantilevers for the edentulous mandible." *Clin Oral Implants Res* 20(6): 601-607.
- Harris, D., D. Buser et al. (2002). "E.A.O. guidelines for the use of diagnostic imaging in implant dentistry. A consensus workshop organized by the European Association for Osseointegration in Trinity College Dublin." *Clin Oral Implants Res* 13(5): 566-570.
- Jemt, T. (1991). "Failures and complications in 391 consecutively inserted fixed prostheses supported by Branemark implants in edentulous jaws: a study of treatment from the time of prosthesis placement to the first annual checkup." *Int J Oral Maxillofac Implants* 6(3): 270-276.
- Lee, H., J. S. So et al. (2008). "The accuracy of implant impressions: a systematic review." *J Prosthet Dent* 100(4): 285-291.
- Lee, Y. J., S. J. Heo et al. (2009). "Accuracy of different impression techniques for internal-connection implants." *Int J Oral Maxillofac Implants* 24(5): 823-830.
- Malament, K. A. and S. Neeser (2004). "Prosthodontic management of ridge deficiencies." *Dent Clin North Am* 48(3): 735-744, vii.
- Misch, C. E. (1999). *Contemporary implant dentistry*. St. Louis, Mosby.
- Purcell, B. A., E. A. McGlumphy et al. (2008). "Prosthetic complications in mandibular metal-resin implant-fixed complete dental prostheses: a 5- to 9-year analysis." *Int J Oral Maxillofac Implants* 23(5): 847-857.
- Riedy, S. J., B. R. Lang et al. (1997). "Fit of implant frameworks fabricated by different techniques." *J Prosthet Dent* 78(6): 596-604.
- Sadowsky, S. J. (1997). "The implant-supported prosthesis for the edentulous arch: design considerations." *J Prosthet Dent* 78(1): 28-33.
- Torsello, F., V. M. di Torresanto et al. (2008). "Evaluation of the marginal precision of one-piece complete arch titanium frameworks fabricated using five different methods for implant-supported restorations." *Clin Oral Implants Res* 19(8): 772-779.
- Walker, M. P., D. Ries et al. (2008). "Implant cast accuracy as a function of impression techniques and impression material viscosity." *Int J Oral Maxillofac Implants* 23(4): 669-674.
- Wong, K. M. (2002). "Clinical Techniques in Prosthodontics." *Compendium of* 23(8): 750-756.
- Zarb, G. A., C. L. Bolender et al. (2004). *Prosthodontic treatment for edentulous patients: complete dentures and implant-supported prostheses*. St. Louis, Mosby.
- Ziegler, C. M., R. Woertche et al. (2002). "Clinical indications for digital volume tomography in oral and maxillofacial surgery." *Dentomaxillofac Radiol* 31(2): 126-130.

WWW.HIGHDENT.IR

همیار دندانسازان و دندانپزشکان

Case 30

Case 30

Full mouth rehabilitation—implant-supported, screw-retained prostheses

Selection of a type of implant-supported prosthesis requires comprehensive understanding of biological and mechanical (prosthetic) limitation of each prosthetic design. Number and length of implants, distribution of implants, available interarch space, quality and type of underlying bone, presence of parafunctional habit, maintainability, and retrievability are the factors influencing this decision-making process.

CASE STORY

A 43-year-old female concerned with deteriorating dental condition presents for comprehensive treatment. The patient was mainly concerned with inability to chew due to the lack of maxillary posterior teeth. She expressed a strong interest in dental implant therapy due to her unsuccessful previous experience with a maxillary removable partial denture.

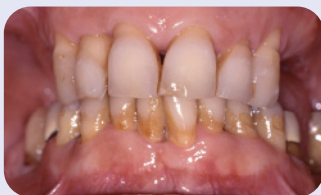
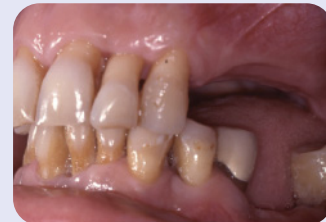
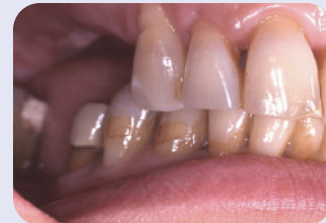Figure 1: Pretreatment front view.



Figures 2 and 3: Pretreatment right and left views.

LEARNING GOALS AND OBJECTIVES

- Identify the advantages and disadvantages of screw-retained implant-supported fixed partial dentures.
- Identify the indications for screw-retained implant-supported fixed partial dentures.

Medical History

- No significant findings

Dental History

- The patient reported a long-standing history of periodontal disease and loss of maxillary posterior teeth due to the severe bone loss. Upon the loss of posterior occlusion, a previous dentist provided a

transitional partial denture, but the patient could not tolerate the prosthesis.

Clinical Findings/Problem List

- Missing maxillary premolars (tooth numbers 4, 5, 12, 13), molars (tooth numbers 1, 2, 3, 14, 15, 16), and mandibular molars (tooth numbers 18, 19, 30, 31)
- Supraerupted mandibular molars
- Defective restorations
- Caries
- Generalized 3–5mm recession
- Suppuration in mandibular anterior region
- Wear facets (abrasion, attrition, and abfraction)
- Generalized clinical mobility ranging from 2+ to 3
- Limited posterior interarch space due to supraeruption of remaining mandibular posterior teeth
- Generalized $\geq 50\%$ attachment loss
- Localized $>70\%$ attachment loss in mandibular anterior and molar regions

Diagnosis

- Generalized chronic moderate to severe periodontitis
- Caries
- Occlusal discrepancy
- Partial edentulism
- Defective restorations
- Limited posterior interarch space due to supraeruption of remaining mandibular posterior teeth

Clinical Decision-Making Determining Factors

- Success of implant-supported prostheses is based on dynamic multifactorial issues. During treatment planning, high risk factors, such as insufficient number of implants relative to arch length, shorter length of implants, poorly distributed implants, limited interarch space, poor implant-to-restoration ratio, poor quality and type of underlying bone, and presence of parafunctional habit drive clinicians to incorporate retrievable elements to be part of the prosthesis design. Screw-retained implant-supported prosthesis is often selected in the presence of such clinical findings (Bragger, Aeschlimann et al. 2001; Michalakis, Hirayama et al. 2003; De Boever, Keersmaekers et al. 2006; Salvi and Bragger 2009).
- In studies of failure and complication rates of screw-retained prostheses some have shown higher prosthetic complication rates, such as screw loosening. It can be postulated that the complication rate in screw-retained prostheses may have

improved due to better internal connections and screw designs, as is evidenced by some studies having shown similar complication rates in screw-retained and cementable prostheses (Bragger, Aeschlimann et al. 2001; Vigolo, Givani et al. 2004; De Boever, Keersmaekers et al. 2006; Nedir, Bischof et al. 2006; Salvi and Bragger 2009).

- Based on studies of the retention mechanism (cemented versus screw-retained) of implant-supported prostheses, the retention mechanism does not appear to increase the risk of implant failure and complication (Salvi and Bragger 2009).
- Implant length-to-height of prosthesis ratio and number of implants supporting fixed partial dentures have been shown to have a significant influence on the successful implant survival rate (Salvi and Bragger 2009).

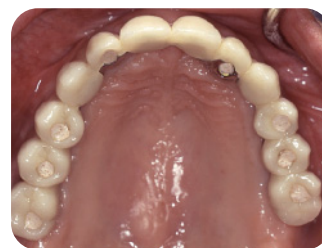

Figure 4: Posttreatment maxillary occlusal view.

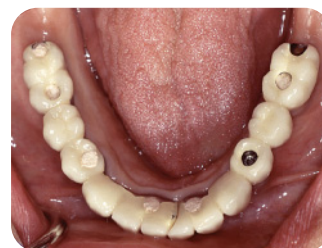

Figure 5: Posttreatment mandibular occlusal view.

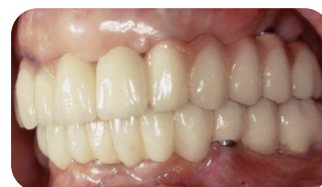
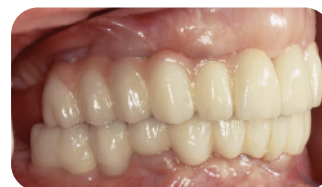
Figure 6 and 7: Posttreatment right and left side views.

- The selection of cement-versus screw-retained design should be based on factors other than the need for improved implant survival rate. The indications for use of screw-retained full arch prosthesis include
 - Compromised interarch space is limiting the utilization of multiple sub- and supra-structures.
 - Retrievability is the major concern for oral hygiene maintenance.
 - Retrievability is highly desired for prosthesis repair/ maintenance.
 - Higher risk of implant failure is a concern due to insufficient number, length, and distribution of implants and poor quality and quantity of bone.

Questions

1. The disadvantage of a screw-retained prosthesis is

- A. Retrievability
- B. Lower prosthetic (mechanical) complication
- C. Repair and maintenance
- D. Disrupted occlusal morphology

2. What is the primary cause of screw loosening?

- A. Type of occlusal scheme
- B. Presence or absence of cross-arch stabilization
- C. Poorly fitting prosthesis
- D. Type of screw

3. Achieving passive fit of a framework is a significant factor for prosthetic success. Which of the following is shown to be the most accurate impression technique that will result in the preservation of implant position?

- A. Open-tray pickup
- B. Closed-tray transfer (repositioning)
- C. Open-tray transfer (repositioning)
- D. Closed-tray pickup

4. Preloads generated by repeated tightening of custom abutment screws can vary. The highest torque value is

- A. First torque
- B. Second torque
- C. Fourth torque
- D. Seventh torque

5. Presence of parafunctional habit has been shown to result in

- A. Greater implant osseointegration failure
- B. Greater prosthetic technical failure, such as fracture of prosthesis
- C. Increased risk of aesthetic failure
- D. Less implant failure

ANSWERS

1. D (Zarone, Sorrentino et al. 2007)
2. C (Zarb and Schmitt 1990; Jemt, Linden et al. 1992; Kallus and Bessing 1994)
3. A (Carr 1991; Barrett, de Rijk et al. 1993; Daoudi, Setchell et al. 2001; Michalakakis, Hirayama et al. 2003)

4. B (Byrne, Jacobs et al. 2006)
5. B (Brägger, Aeschliemann et al. 2001)

The authors would like to acknowledge and thank Dr. Stella Oh for clinical case photographs and treatment performed at New York University College of Dentistry.

References

- Barrett, M. G., W. G. de Rijk et al. (1993). "The accuracy of six impression techniques for osseointegrated implants." *J Prosthodont* 2(2): 75–82.
- Bragger, U., S. Aeschlimann et al. (2001). "Biological and technical complications and failures with fixed partial dentures (FPD) on implants and teeth after four to five years of function." *Clin Oral Implants Res* 12(1): 26–34.
- Byrne, D., S. Jacobs et al. (2006). "Preloads generated with repeated tightening in three types of screws used in dental implant assemblies." *J Prosthodont* 15(3): 164–171.
- Carr, A. B. (1991). "Comparison of impression techniques for a five-implant mandibular model." *Int J Oral Maxillofac Implants* 6(4): 448–455.
- Daoudi, M. F., D. J. Setchell et al. (2001). "A laboratory investigation of the accuracy of two impression techniques for single-tooth implants." *Int J Prosthodont* 14(2): 152–158.
- De Boever, A. L., K. Keersmaekers et al. (2006). "Prosthetic complications in fixed endosseous implant-borne reconstructions after an observation period of at least 40 months." *J Oral Rehabil* 33(11): 833–839.
- Jemt, T., B. Linden et al. (1992). "Failures and complications in 127 consecutively placed fixed partial prostheses supported by Branemark implants: from prosthetic treatment to first annual checkup." *Int J Oral Maxillofac Implants* 7(1): 40–44.
- Kallus, T. and C. Bessing (1994). "Loose gold screws frequently occur in full-arch fixed prostheses supported by osseointegrated implants after 5 years." *Int J Oral Maxillofac Implants* 9(2): 169–178.
- Michalakis, K. X., H. Hirayama et al. (2003). "Cement-retained versus screw-retained implant restorations: a critical review." *Int J Oral Maxillofac Implants* 18(5): 719–728.
- Nedir, R., M. Bischof et al. (2006). "Prosthetic complications with dental implants: from an up-to-8-year experience in private practice." *Int J Oral Maxillofac Implants* 21(6): 919–928.
- Salvi, G. E. and U. Bragger (2009). "Mechanical and technical risks in implant therapy." *Int J Oral Maxillofac Implants* 24 Suppl: 69–85.
- Vigolo, P., A. Givani et al. (2004). "Cemented versus screw-retained implant-supported single-tooth crowns: a 4-year prospective clinical study." *Int J Oral Maxillofac Implants* 19(2): 260–265.
- Zarb, G. A. and A. Schmitt (1990). "The longitudinal clinical effectiveness of osseointegrated dental implants: the Toronto study. Part III: Problems and complications encountered." *J Prosthet Dent* 64(2): 185–194.
- Zarone, F., R. Sorrentino et al. (2007). "Fracture resistance of implant-supported screw- versus cement-retained porcelain fused to metal single crowns: SEM fractographic analysis." *Dent Mater* 23(3): 296–301.

WWW.HIGHDENT.IR

همیار دندانسازان و دندانپزشکان

Case 31

Case 31

Full mouth rehabilitation—implant-supported, cementable fixed prostheses

Implant placement with compromised angulations may necessitate the use of custom abutments with cementable metal superstructure for fabrication of implant-supported fixed prostheses. These prostheses require careful consideration to prevent mechanical failure and assure long-term success.

CASE STORY

A 55-year-old male with a history of extensive dental treatments presents to the clinic with multiple dental infections requiring immediate extractions. After urgent dental care, a comprehensive dental treatment plan was initiated to restore function and aesthetics.

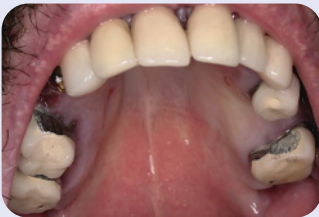

Figure 1: Pretreatment maxillary occlusal view.

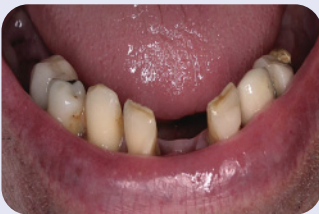

Figure 2: Pretreatment mandibular occlusal view.

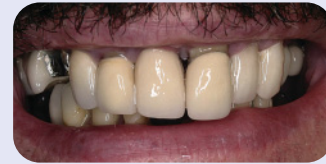

Figure 3: Pretreatment frontal view.

LEARNING GOALS AND OBJECTIVES

- Recognize and understand the indications for the custom abutments and cementable implant-supported fixed prostheses.
- Understand the importance of passive fit of framework design.
- Understand the rationale for selecting luting agents for a cementable implant-supported fixed prosthesis.

Medical History

- No significant findings

Dental History

- The presented patient previously received extensive dental treatments, and has neglected his oral hygiene for many years. The failing restorations and extensive decay have resulted in infection and loss of teeth. The inadequate occlusion and posterior support made it necessary for the patient to seek dental treatment.

Clinical Findings/Problem List

- Supraerupted maxillary and mandibular anterior teeth
- Missing maxillary right third molar, premolars, maxillary left second premolar, second and third molars, mandibular right and left molars, mandibular left first premolar (tooth numbers 1, 4, 5, 13, 15, 16, 17, 18, 19, 20, 24, 25, 30, 31, and 32)
- Restorations with open margins

Radiographic Findings

(See Fig. 4.)

Diagnosis

- Generalized chronic moderate adult periodontitis
- Localized chronic severe adult periodontitis
- Caries
- Defective restorations
- Occlusal plane discrepancy
- Partial edentulism
- Class II malocclusion

Clinical Decision-Making Determining Factors

- The degree of implant misalignments can significantly influence the selection of prosthesis design for proper implant load distribution, aesthetics, and maintenance. In the presence of excessive misalignments, a screw-retained fixed complete denture prosthesis may not be an option due to the unfavorable positions of screw access channels. In such cases, the use of individual custom abutments and cementable metal superstructure may be an option (Lewis, Beumer et al. 1988; Preiskel and Tsolka 1997; Zitzmann and Marinello 1999).

- Selection of types of abutment and framework design should be determined after the evaluation of position and contour of definitive prosthesis through a complete wax-up and provisional restorations (Zitzmann and Marinello 2002).
- The index of a wax-up and/or a provisional restoration should be utilized to assess the implant positions and angulations relative to the position and contour of definitive restorations (Zitzmann and Marinello 1999, 2002).
- Favorable stress distribution on implants has a positive effect on the long-term prognosis of implant restorations/prostheses by reducing fracture complications involving implant and implant components. Therefore, achieving passive fit of the prosthesis is one of the key factors in having a successful implant restoration/prosthesis. The extent of prosthesis can affect passive fit. Passively fitting cement-retained prostheses have been shown to be viable treatments with favorable stress distribution on implants (Assif, Marshak et al. 1996; Jemt and Book 1996; Guichet, Caputo et al. 2000).
- Lack of retrievability is a major disadvantage of cement-retained implant prostheses. To address the retrievability, the use of a provisional cement instead of a permanent cement remains controversial. The cement selection for implant restoration/prostheses can be based on the need for retrievability, extent of prosthesis, and retention/resistance form of implant substructure. In the presence of compromised retention and resistance form in implant substructure/abutment design, the use of provisional cement can increase the risk of dislodgement and lead to complications (Agar, Cameron et al. 1997; Squier, Agar et al. 2001).

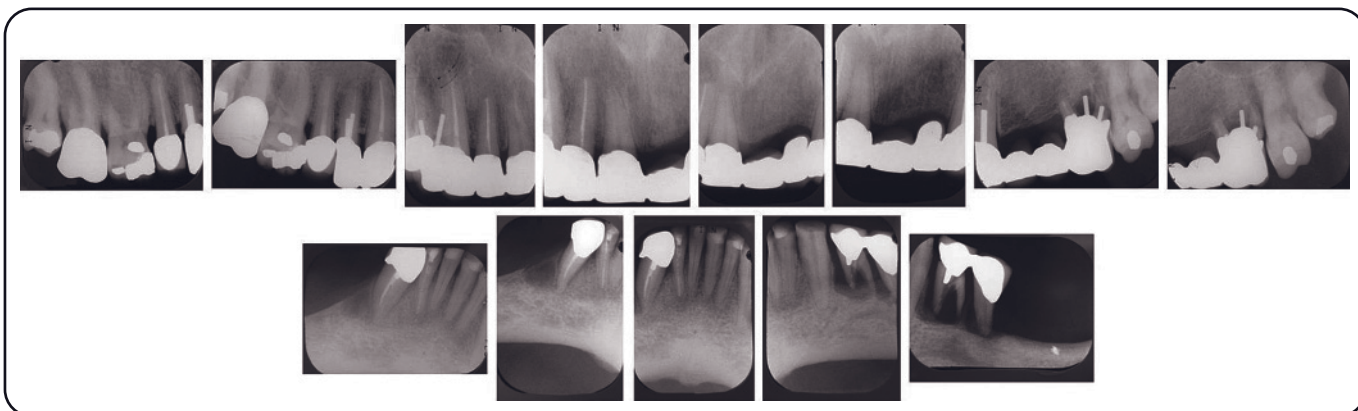
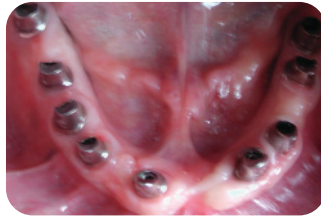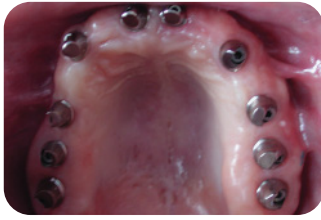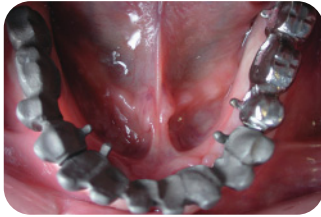


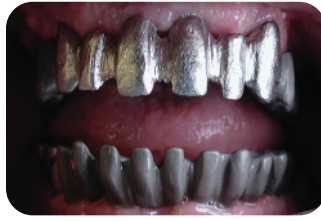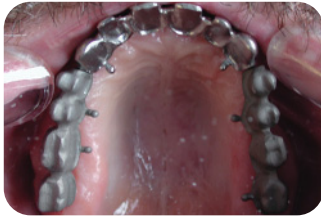Figure 4: Full mouth series of radiographs.

CASE 31



Figures 5 and 6: Maxillary and mandibular abutments in place.



Figures 7, 8, and 9: Metal try-in; maxillary, front, and mandibular views.

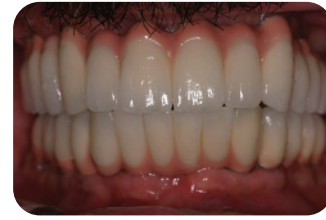

Figure 10: Posttreatment frontal view.

Questions

1. When determining the implant substructure and superstructure design, which of the following record(s) must be present?

- A. Shade
- B. Implant angulations
- C. Index of definitive restoration/prosthesis plan
- D. B and C

2. Which of the following is a disadvantage of cementable implant-retained prostheses?

- A. Retrievalability
- B. Aesthetics
- C. Passivity
- D. Possibilities of implant angulation correction

3. Which of the following luting agents has been shown to have the greatest retention in implant restorations?

- A. Resin cement
- B. Glass ionomer cement
- C. Zinc phosphate cement
- D. Resin-reinforced glass ionomer cement

4. Which of the following luting agents has been shown to have the least retention in implant restorations?

- A. Resin cement
- B. Glass ionomer and zinc oxide noneugenol cement
- C. Zinc phosphate cement
- D. Resin-reinforced glass ionomer cement

5. The measure of interfacial discrepancy between the implant components thought to be questionable or unacceptable is equal to or greater than

- A. 10 μ m
- B. 20 μ m
- C. 30 μ m
- D. 40 μ m

6. Which of the following statements is *incorrect*?

- A. No significant correlation has been found between the prosthetic misfit and bone loss around implants when bone volume and quality are not compromised.
- B. No data is available regarding the effect of prosthetic misfit on the implants in compromised bone.
- C. Significant correlation is found between the prosthetic misfit and bone loss around implants.
- D. The correlation between misfit and bone loss around implants is observed only in the maxillary arch.

7. Which of the following implant prosthesis designs has been shown to have better stress distribution on implants?

- A. Screw-retained implant prostheses
- B. Cement-retained implant prostheses
- C. Implant-retained overdentures
- D. Implant-retained fixed complete dentures

ANSWERS

1. D (Zitzmann and Marinello 1999)
2. A (Agar, Cameron et al. 1997)
3. A (Squier, Agar et al. 2001)
4. B (Squier, Agar et al. 2001)

5. C (Assif, Marshak et al. 1996)
6. C (Jemt and Book 1996; Guichet, Caputo et al. 2000)
7. B (Guichet, Caputo et al. 2000)

The authors would like to acknowledge and thank Dr. Stella Oh for clinical case photographs and treatment performed at New York University College of Dentistry.

References

- Agar, J. R., S. M. Cameron et al. (1997). "Cement removal from restorations luted to titanium abutments with simulated subgingival margins." *J Prosthet Dent* 78(1): 43–47.
- Assif, D., B. Marshak et al. (1996). "Accuracy of implant impression techniques." *Int J Oral Maxillofac Implants* 11(2): 216–222.
- Assif, D., B. Marshak et al. (1996). "Analysis of load transfer and stress distribution by an implant-supported fixed partial denture." *J Prosthet Dent* 75(3): 285–291.
- Guichet, D. L., A. A. Caputo et al. (2000). "Passivity of fit and marginal opening in screw- or cement-retained implant fixed partial denture designs." *Int J Oral Maxillofac Implants* 15(2): 239–246.
- Jemt, T. and K. Book (1996). "Prosthesis misfit and marginal bone loss in edentulous implant patients." *Int J Oral Maxillofac Implants* 11(5): 620–625.
- Lewis, S., J. Beumer, 3rd et al. (1988). "The 'UCLA' abutment." *Int J Oral Maxillofac Implants* 3(3): 183–189.
- Preiskel, H. W. and P. Tsolka (1997). "The DIA anatomic abutment system and telescopic prostheses: a clinical report." *Int J Oral Maxillofac Implants* 12(5): 628–633.
- Squier, R. S., J. R. Agar et al. (2001). "Retentiveness of dental cements used with metallic implant components." *Int J Oral Maxillofac Implants* 16(6): 793–798.
- Zitzmann, N. U. and C. P. Marinello (1999). "Clinical and technical aspects of implant-supported restorations in the edentulous maxilla: the fixed partial denture design." *Int J Prosthodont* 12(4): 307–312.
- Zitzmann, N. U. and C. P. Marinello (2002). "A review of clinical and technical considerations for fixed and removable implant prostheses in the edentulous mandible." *Int J Prosthodont* 15(1): 65–72.

Case 32

Case 32

Full mouth rehabilitation—combination of implant and tooth-supported fixed prostheses

In the presence of anatomical limitations, selecting a treatment approach between the placement of implants with preprosthetic surgery and use of natural dentition with implants requires careful consideration and understanding of the biology of the implant system and natural teeth.

CASE STORY

A 75-year-old male presents with the chief complaint of “I need major work.” Extensive conformational dental treatments were previously rendered, including multiple restorations, acrylic veneered-fixed partial denture, and mandibular overlay-removable partial denture.

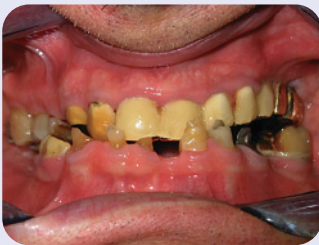
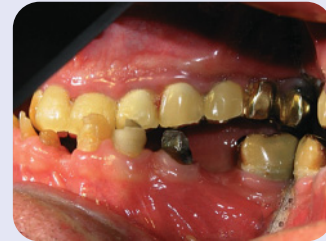
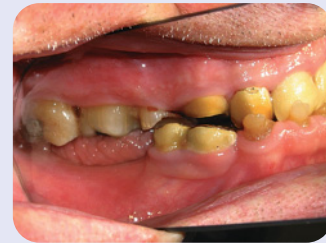Figure 1: Pretreatment front view.



Figures 2 and 3: Pretreatment left and right views.

LEARNING GOALS AND OBJECTIVES

- Understand the difference in biomechanical characteristics of osseointegrated implant and natural tooth.
- Identify the potential complications involving the combination implant-to-tooth fixed partial denture.

Medical History

- No contributory finding noted

Dental History

- Conformational dental treatments over the years

Clinical Findings/Problem List

- Generalized wear patterns (attrition and abrasion)
- 15mm loss of vertical dimension of occlusion
- Overcontoured restorations
- Generalized moderate to severe plaque and calculus accumulation
- Bleeding upon probing
- Generalized grade 2+ clinical mobility except the maxillary right quadrant
- Inadequate posterior support
- Absence of anterior guidance
- Occlusal plane discrepancy

Radiographic Findings

- Caries
- Moderate to severe bone loss
- Furcation involvement
- Widened PDL
- Defective restorations (open margins and overcontoured restorations)

Diagnosis

- Defective existing restorations and prostheses
- Caries
- Loss of vertical dimension of occlusion
- Generalized moderate to severe adult periodontitis
- Partial edentulism
- Parafunctional habit
- Pseudo-class III malocclusion

Clinical Decision-Making Determining Factors

- Biomechanical characteristics of a natural tooth (Cohen and Orenstein 1994) include its ability to exhibit and tolerate minor movement of 50–200 μ m. This is as a result of the presence of periodontal ligaments and their viscoelastic properties.
- Osseointegrated implants (Ericsson, Glantz et al. 1988) show approximately 10 μ m of mobility that results from the flexure and elastic deformation of surrounding bone when subjected to forces.
- When implants are rigidly connected to natural tooth/teeth, there is an observed greater bone loss around the implant. This suggests that implant overload and bone loss may result from the natural tooth acting as a cantilever (Skalak 1983; Ericsson, Lekholm et al. 1986; Sullivan 1986). Use of nonrigid connectors in the implant-teeth fixed partial denture system has also shown to be unfavorable and places stress on the implant system and prosthesis (Lin, Chang et al. 2006). Although there is a lack of consensus on this issue, current clinical evidence indicates the presence of greater risks and complications where implants and teeth are connected.
- Intrusion of the natural tooth has been observed in fixed partial dentures where implant and natural teeth abutments are connected (Mathews, Breeding et al. 1991; Cho and Chee 1992; Sheets and

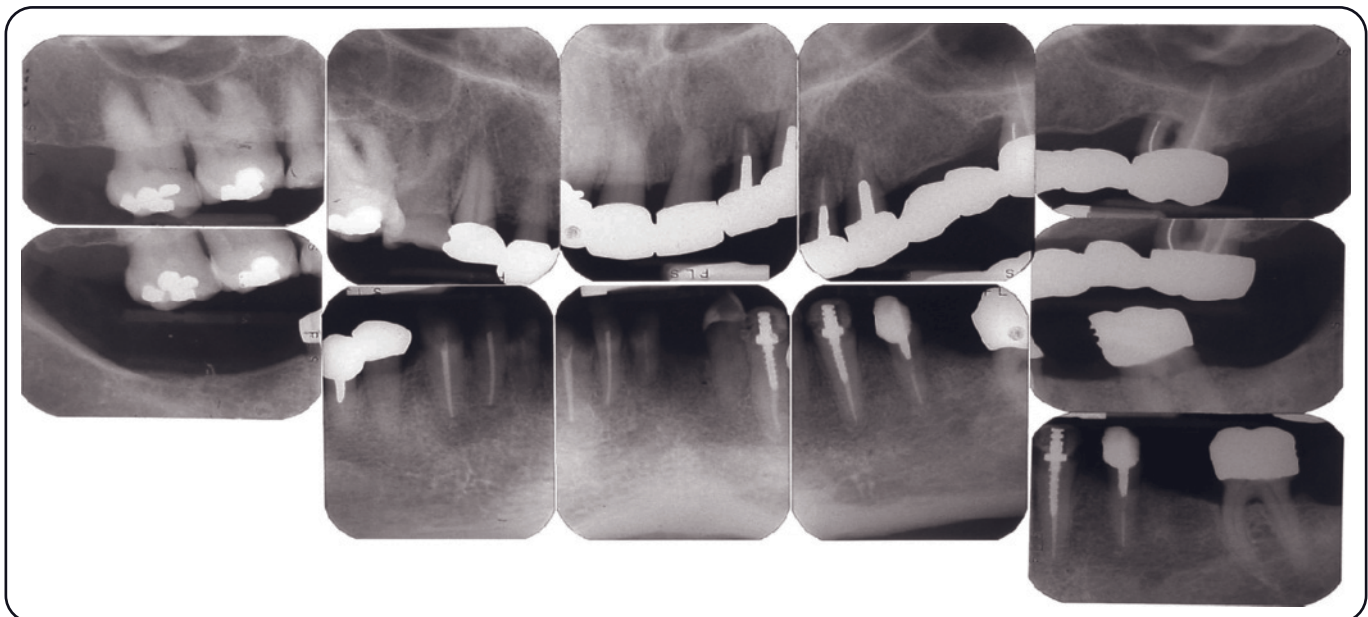


Figure 4: Periapical radiographs.

CASE 32

Earthmann 1993; Pesun 1997). This phenomenon is explained by the biomechanical incompatibility of the presence of periodontal ligament on teeth and lack of it on osseointegrated implants.

- A 15-year follow-up study has reported a significantly (X3) more marginal bone loss in tooth-implant connected versus free-standing prostheses (Naert, Duyck et al. 2001). A free-standing fixed partial denture is recommended as the first treatment of choice (Naert, Duyck et al. 2001).

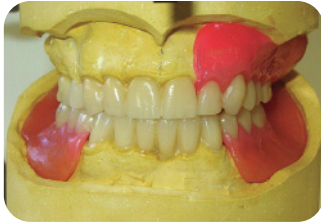
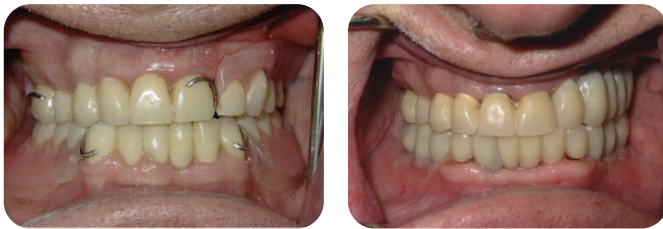

Figure 5: Diagnostic wax-up.

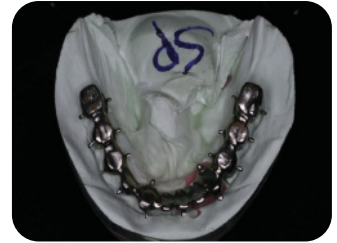


Figures 6 and 7: Provisional prostheses.

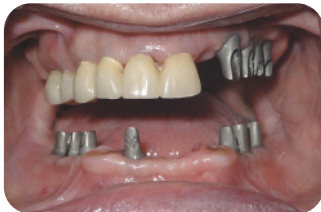

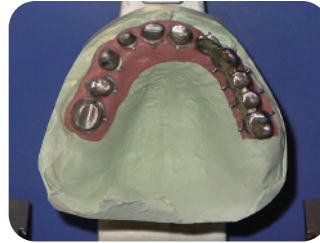Figure 8: Abutment try-in.

- Based on the clinical and radiographic findings, maxillary right first molar, first premolar, canine, and incisors (teeth 3, 5, 6, 7, 8, and 9) were determined to have fair prognosis. The remaining teeth were extracted due to poor-to-hopeless periodontal and prosthodontic prognosis. The treatment decision was made to rehabilitate the patient with conventional tooth-supported fixed partial denture and implant-supported fixed partial denture without connection between the natural teeth and implants.



Figures 9 and 10: Maxillary and mandibular master casts.

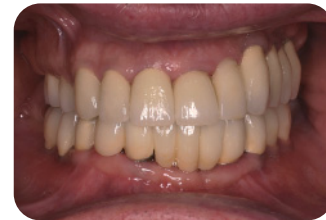

Figure 11: Posttreatment frontal view.

Questions

1. Which of the following best describes the mobility characteristics of osseointegrated implants?

- A. Viscoelastic
- B. Flexure and elastic deformation
- C. $>60\mu\text{m}$
- D. $>200\mu\text{m}$

2. What is the most significant factor causing complications in the combined implant-to-tooth fixed partial denture?

- A. Surface characteristics
- B. Prosthesis design
- C. Dissimilar mobility
- D. Occlusal load pattern

3. What is the most common complication observed in the combined implant-to-tooth fixed partial denture?

- A. Framework fracture
- B. Loss of tooth
- C. Implant failure
- D. Intrusion of natural teeth

4. Which of the following can affect the occlusal load distribution?

- A. Magnitude of occlusal force during chewing
- B. Prosthesis connector design
- C. Periodontal ligaments
- D. All of the above

5. Which of the following lever systems is most detrimental to dental prostheses?

- A. Class 1 (Seesaw)
- B. Class 2 (Wheelbarrow)
- C. Class 3 (Jaw)

6. Lever arms producing torque can cause

- A. Mechanical failure of the prosthesis
- B. Bone fracture
- C. Failure of the implant
- D. All of the above

7. Which of the following statements is *correct* regarding the bone level around implants rigidly connected to a natural tooth?

- A. Significant difference in implant bone loss was found between prostheses connected to teeth compared to that of freestanding implant-supported prostheses.
- B. There was a greater bone loss around the natural tooth.
- C. There was a lesser bone loss around the implant.

8. The etiology of intrusion of a natural tooth, observed in a fixed partial denture supported both by implant and natural tooth, has not been established. This statement is

- A. True
- B. False

ANSWERS

1. B (Ericsson, Glantz et al. 1988; Cohen and Orenstein 1994)
2. C (Lin, Chang et al. 2006)
3. D (English 1993; Rieder and Parel 1993)
4. D (Sheets and Earthmann 1993; Lin, Chang et al. 2006)

5. A (Skalak 1983)
6. D (Skalak 1983)
7. A (Gunné, Astrand et al. 1999)
8. A (Rieder and Parel 1993; García and Oesterle 1998)

The authors would like to acknowledge and thank Dr. Igor Chikunov for clinical case photographs and treatment performed at New York University College of Dentistry.

References

- Cho, G. C. and W. W. Chee (1992). "Apparent intrusion of natural teeth under an implant-supported prosthesis: a clinical report." *J Prosthet Dent* 68(1): 3–5.
- Cohen, S. R. and J. H. Orenstein (1994). "The use of attachments in combination implant and natural-tooth fixed partial dentures: a technical report." *Int J Oral Maxillofac Implants* 9(2): 230–234.
- English, C. E. (1993). "Implant-supported versus implant-natural-tooth-supported fixed partial dentures." *J Dent Symp* 1: 10–15.
- Ericsson, I., P. O. Glantz et al. (1988). "Use of implants in restorative therapy in patients with reduced periodontal tissue support." *Quintessence Int* 19(11): 801–807.
- Ericsson, I., U. Lekholm et al. (1986). "A clinical evaluation of fixed-bridge restorations supported by the combination of teeth and osseointegrated titanium implants." *J Clin Periodontol* 13(4): 307–312.
- Garcia, L. T. and L. J. Oesterle (1998). "Natural tooth intrusion phenomenon with implants: a survey." *Int J Oral Maxillofac Implants* 13(2): 227–231.
- Gunne, J., P. Astrand et al. (1999). "Tooth-implant and implant supported fixed partial dentures: a 10-year report." *Int J Prosthodont* 12(3): 216–221.
- Lin, C. L., S. H. Chang et al. (2006). "Mechanical interactions of an implant/tooth-supported system under different periodontal supports and number of splinted teeth with rigid and non-rigid connections." *J Dent* 34(9): 682–691.
- Mathews, M. F., L. C. Breeding et al. (1991). "The effect of connector design on cement retention in an implant and natural tooth-supported fixed partial denture." *J Prosthet Dent* 65(6): 822–827.
- Naert, I. E., J. A. Duyck et al. (2001). "Freestanding and tooth-implant connected prostheses in the treatment of partially edentulous patients Part II: An up to 15-years radiographic evaluation." *Clin Oral Implants Res* 12(3): 245–251.
- Pesun, I. J. (1997). "Intrusion of teeth in the combination implant-to-natural-tooth fixed partial denture: a review of the theories." *J Prosthodont* 6(4): 268–277.
- Rieder, C. E. and S. M. Parel (1993). "A survey of natural tooth abutment intrusion with implant-connected fixed partial dentures." *Int J Periodontics Restorative Dent* 13(4): 334–347.
- Sheets, C. G. and J. C. Earthmann (1993). "Natural tooth intrusion and reversal in implant-assisted prosthesis: evidence of and a hypothesis for the occurrence." *J Prosthet Dent* 70(6): 513–520.
- Skalak, R. (1983). "Biomechanical considerations in osseointegrated prostheses." *J Prosthet Dent* 49(6): 843–848.
- Sullivan, D. Y. (1986). "Prosthetic considerations for the utilization of osseointegrated fixtures in the partially edentulous arch." *Int J Oral Maxillofac Implants* 1(1): 39–45.

Case 33

Case 33

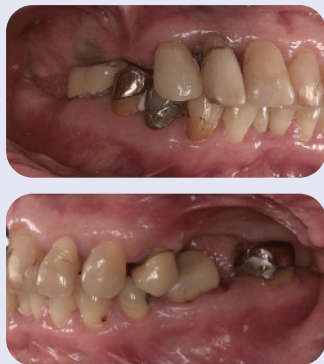Full mouth rehabilitation—combination of implant and tooth-supported fixed and removable prostheses

The rehabilitation of the edentulous maxilla with a good long-term prognosis requires planning with a thorough consideration of the biologic limitations such as poor bone quality and volume. Final determination

of the proper treatment plan decision involving number of implants, implant type, implant distribution, and prosthesis design should be based on the available scientific evidence.

CASE STORY

A 52-year-old patient with a long history of previous dental treatment presents with a chief complaint of “I’ve had recurrent infections associated with my teeth. I’ve fallen into a pattern of ‘fix it and then pull it.’ I can’t bite and I’m ready to make a commitment to fix it.”



Figures 1 and 2: Pretreatment left and right lateral views.

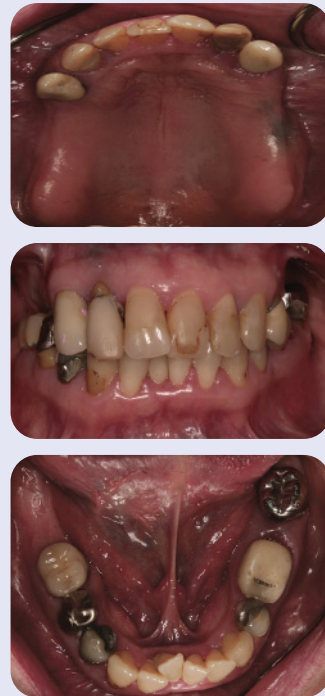

Figure 3, 4, and 5: Pretreatment occlusal and frontal views.

LEARNING GOALS AND OBJECTIVES

- Understand the biological limitations of the maxillary edentulous arch.
- Understand the factors influencing the determination of treatment for the edentulous maxilla.
- Understand the required space for the milled-bar retained implant-supported prosthesis.

Medical History

- History of hysterectomy

Dental History

- The patient was treated with a removable partial denture (RPD) and restorations. However, the patient did not wear her RPD and functioned without posterior teeth for many years.

Clinical Findings/Problem List

- Caries on the mandibular left first and third molars (17 and 19)
- Diastema between the maxillary left canine and premolar (11 and 12)
- Mesial drift of the mandibular left first and third molars (17 and 19)
- Crowding of anterior mandibular teeth
- Missing maxillary and mandibular posterior teeth
- Class 2+ mobility for the remaining maxillary teeth
- Class 2 furcation involvement for the mandibular right first molar (30)
- Class 3 furcation involvement for the mandibular left first molar (19)

Radiographic Findings

- Periapical radiolucency of the maxillary right and left lateral incisors, mandibular left third molar and mandibular right first molar (7, 10, 17, and 30)

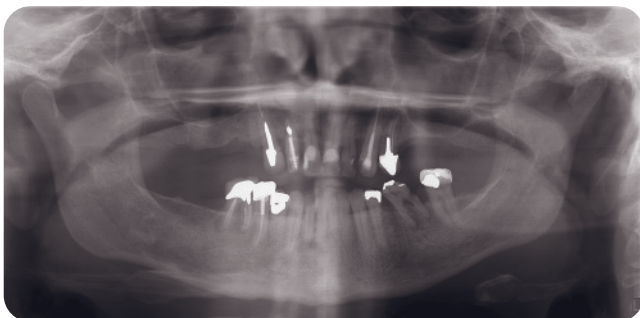


Figure 6: Panoramic radiograph.

- Generalized moderate/severe horizontal bone loss with severe localized angular bone loss
- Maxillary sinus pneumatization

Diagnosis

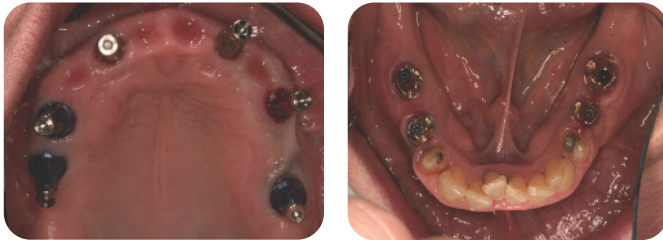- Partial edentulism
- Caries
- Chronic irreversible periradicular periodontitis
- Moderate to severe chronic periodontitis of maxillary teeth
- Moderate chronic periodontitis of mandibular teeth
- Defective restorations
- Overcontoured restorations
- Occlusal plane discrepancy
- Mandibular posterior segmental alveolar growth

Clinical Decision-Making Determining Factors

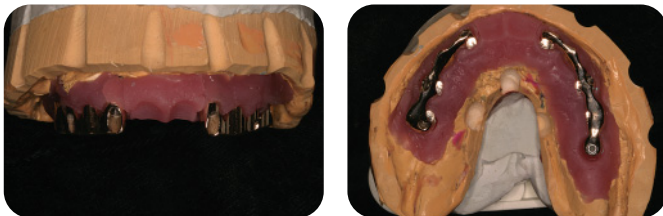
- Success of implant-supported prosthesis restorations/prostheses is largely influenced by bone quality, systemic condition of a patient, implant length, implant type, implant distribution, implant number, and prosthesis design (Goodacre, Kan et al. 1999; Goodacre, Bernal et al. 2003; Lambert, Weber et al. 2009).
- Type III and IV bone are often seen in the maxilla (Jaffin and Berman 1991; Goodacre, Bernal et al. 2003; Jemt and Johansson 2006).
- Implant losses in the maxilla have been shown to be higher than that in the mandible (Zarb and Zarb 1985; Goodacre, Bernal et al. 2003).
- The survival rates for implants placed in edentulous maxillary native bone have been shown to be statistically significantly higher than implants placed in augmented bone (Att, Bernhart et al. 2009; Lambert, Weber et al. 2009).
- In the study of influence of prosthesis designs on survival rate of maxillary implants used in the rehabilitation of edentulous maxilla, the conventional implant-supported fixed partial dentures and the implant-supported fixed complete dentures have not shown a statistically significant difference (Lambert, Weber et al. 2009).
- Maxillary prostheses with ≥ 6 implants have shown a higher prosthetic survival rate than those with < 6 implants (Jaffin and Berman 1991; Lambert, Weber et al. 2009).
- Prosthetic survival rates have been shown to be significantly lower when implants were placed solely anterior to the first premolar region than for those placed with an anterior-posterior distribution (Lambert, Weber et al. 2009).

CASE 33

- Passive fit of prostheses, repair, and maintenance issues are important factors influencing overall survival of implant-supported prostheses along with the number and distribution of implants involved and prosthesis design (Zitzmann and Marinello 2000; Tipton 2002).
- Precision milled-bar retained removable implant-supported fixed partial denture design allows for (Brudvik and Chigurupati 2002; Tipton 2002):
 - Cross-arch stabilization of angulated implants
 - Replacement of hard and soft tissues
 - Removability of prosthesis for improved maintenance
- A minimum of 12mm of space should be available for precision milled-bar retained prostheses



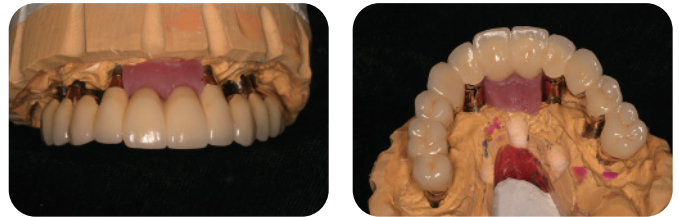Figures 7 and 8: Impression copings in place.



Figures 9 and 10: Maxillary milled bars.

(Andersson, Carlsson et al. 1996; Ercoli, Graser et al. 1998).

- Based on the clinical findings, the remaining maxillary teeth and mandibular molars were determined to have poor prognosis. After consideration of the number of implants, implant distribution, surgical limitations resulting in implant angulations, and the available soft tissue volume and support, the milled-bar retained implant-supported fixed prosthesis was selected for the rehabilitation of this patient's maxillary arch. In the mandibular arch, conventional porcelain-fused-to-metal restorations and implant-supported fixed partial dentures in posterior regions, following the extraction of posterior teeth, were planned.



Figures 11 and 12: Final prostheses.

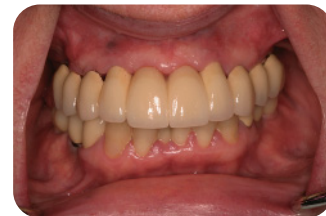

Figure 13: Posttreatment frontal view.

Questions

1. Which of the following bone types are mostly seen in the maxillary arch?

- A. Type I and II
- B. Type II and III
- C. Type I and III
- D. Type III and IV

2. What is the minimum recommended number of implants in the maxillary arch for an implant-supported fixed prosthesis?

- A. 2
- B. 5
- C. 6
- D. 8

3. What is the minimum recommended interocclusal space for the milled-bar retained implant-supported fixed prosthesis?

- A. 8mm
- B. 9mm
- C. 10mm
- D. 12mm

4. What is the advantage of the milled-bar retained implant-supported fixed prosthesis?

- A. Retrievability
- B. Aesthetics
- C. Cross-arch stabilization
- D. Precision fit
- E. All of the above

5. True or False: Distribution of implants in the edentulous maxilla affects the prosthetic survival rate.

- A. True
- B. False

6. When quality of bone is a compromising factor for the long-term success, which of the following should be considered?

- A. Increase the number of implants involved.
- B. Use systemic medication to improve the bone density.
- C. Use shorter implants.
- D. Establish group function occlusion only.

7. Early implant failures are associated with

- A. Inappropriate surgical technique
- B. Premature loading
- C. Poor bone quality
- D. Infection
- E. All of the above

8. Which of the following prostheses have shown a higher implant failure rate?

- A. Mandibular implant-retained overdenture
- B. Maxillary implant-retained overdenture
- C. Maxillary implant-supported fixed partial denture
- D. Mandibular implant-supported fixed partial denture

9. Regarding the implant length and implant loss, which of the following implant lengths have shown an overall higher failure rate?

- A. 13mm
- B. 12mm
- C. 11mm
- D. 10mm

ANSWERS

1. D (Jaffin and Berman 1991)
2. C (Jemt and Johansson 2006; Lambert, Weber et al. 2009)
3. D (Andersson, Carlsson et al. 1996; Ercoli, Graser et al. 1998)
4. E (Tipton 2002)

5. A (Lambert, Weber et al. 2009)
6. A (Sadovsky 2007)
7. E (Cochran 1996)
8. B (Goodacre, Bernal et al. 2003)
9. D (Jemt and Lekholm 1995; Friberg, Grondahl et al. 2000; Testori, Wiseman et al. 2001)

The authors would like to acknowledge and thank Dr. Robert Berg for clinical case photographs and treatment performed.

References

- Andersson, M., L. Carlsson et al. (1996). "Accuracy of machine milling and spark erosion with a CAD/CAM system." *J Prosthet Dent* 76(2): 187–193.
- Att, W., J. Bernhart et al. (2009). "Fixed rehabilitation of the edentulous maxilla: possibilities and clinical outcome." *J Oral Maxillofac Surg* 67(11 Suppl): 60–73.
- Brudvik, J. S. and K. Chigurupati (2002). "The milled implant bar: an alternative to spark erosion." *J Can Dent Assoc* 68(8): 485–488.
- Cochran, D. (1996). "Implant therapy I." *Ann Periodontol* 1(1): 707–791.
- Ercoli, C., G. N. Graser et al. (1998). "Alternative procedure for making a metal suprastructure in a milled bar implant-supported overdenture." *J Prosthet Dent* 80(2): 253–258.
- Friberg, B., K. Grondahl et al. (2000). "Long-term follow-up of severely atrophic edentulous mandibles reconstructed with short Branemark implants." *Clin Implant Dent Relat Res* 2(4): 184–189.
- Goodacre, C. J., G. Bernal et al. (2003). "Clinical complications with implants and implant prostheses." *J Prosthet Dent* 90(2): 121–132.
- Goodacre, C. J., J. Y. Kan et al. (1999). "Clinical complications of osseointegrated implants." *J Prosthet Dent* 81(5): 537–552.
- Jaffin, R. A. and C. L. Berman (1991). "The excessive loss of Branemark fixtures in type IV bone: a 5-year analysis." *J Periodontol* 62(1): 2–4.
- Jemt, T. and J. Johansson (2006). "Implant treatment in the edentulous maxillae: a 15-year follow-up study on 76 consecutive patients provided with fixed prostheses." *Clin Implant Dent Relat Res* 8(2): 61–69.
- Jemt, T. and U. Lekholm (1995). "Implant treatment in edentulous maxillae: a 5-year follow-up report on patients with different degrees of jaw resorption." *Int J Oral Maxillofac Implants* 10(3): 303–311.
- Lambert, F. E., H. P. Weber et al. (2009). "Descriptive analysis of implant and prosthodontic survival rates with fixed implant-supported rehabilitations in the edentulous maxilla." *J Periodontol* 80(8): 1220–1230.
- Sadovsky, S. J. (2007). "Treatment considerations for maxillary implant overdentures: a systematic review." *J Prosthet Dent* Jun; 97(6):340–348. Review.
- Testori, T., L. Wiseman et al. (2001). "A prospective multicenter clinical study of the Osseotite implant: four-year interim report." *Int J Oral Maxillofac Implants* 16(2): 193–200.
- Tipton, P. A. (2002). "The milled bar-retained removable bridge implant-supported prosthesis: a treatment alternative for the edentulous maxilla." *J Esthet Restor Dent* 14(4): 208–216.
- Zarb, G. A. and F. L. Zarb (1985). "Tissue integrated dental prostheses." *Quintessence Int* 16(1): 39–42.
- Zitzmann, N. U. and C. P. Marinello (2000). "Treatment outcomes of fixed or removable implant-supported prostheses in the edentulous maxilla. Part II: clinical findings." *J Prosthet Dent* 83(4): 434–442.

Case 34

Case 34

Management of a patient with bulimia

CASE STORY

A 42-year-old female patient presents with the chief complaint of "I'm not happy with the way my teeth look." The patient reports that she has neglected her teeth for the past 20 years and has not received dental treatment other than emergency dental care. The patient exhibits poor oral hygiene and reports that she brushes only occasionally.

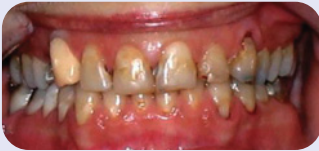

Figure 1: Preoperative presentation.

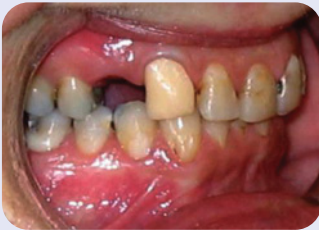

Figure 2: Preoperative right side.

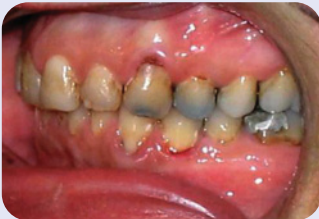

Figure 3: Preoperative left side.

LEARNING GOALS AND OBJECTIVES

- Identify signs of bulimia.
- Understand treatment limitations in patients with bulimia.
- Provide appropriate dental interventions to control future damage.

Medical History

- Bulimia: from 1982–1990

Medications and Allergies

- Methadone 30 mg: for management of previous drug addiction

Social History

- Smoking: one pack of cigarettes per day, for the past 30 years
- Alcohol: drinks alcohol occasionally
- Recreational drugs: previous drug addiction and currently in drug rehabilitation program

Charting

(See Fig. 4.)

Clinical Findings/Problem List

- Generalized gingivitis, moderate localized calculus, mild localized periodontitis
- Evidence of erosion
- Caries: extensive decay in all four quadrants
 - Maxillary right second molar (2) DOL
 - Maxillary right first molar (3) MOD
 - Maxillary right canine (6) L
 - Maxillary lateral incisors (7–10) MD
 - Maxillary left canine (11) B, L
 - Maxillary left first premolar (12) MOD
 - Maxillary left second premolar (13) MOD
 - Maxillary left first molar (14) MODL
 - Mandibular left first molar (19) MO
 - Mandibular left second premolar (20) MOD
 - Mandibular left first premolar (21) MOD

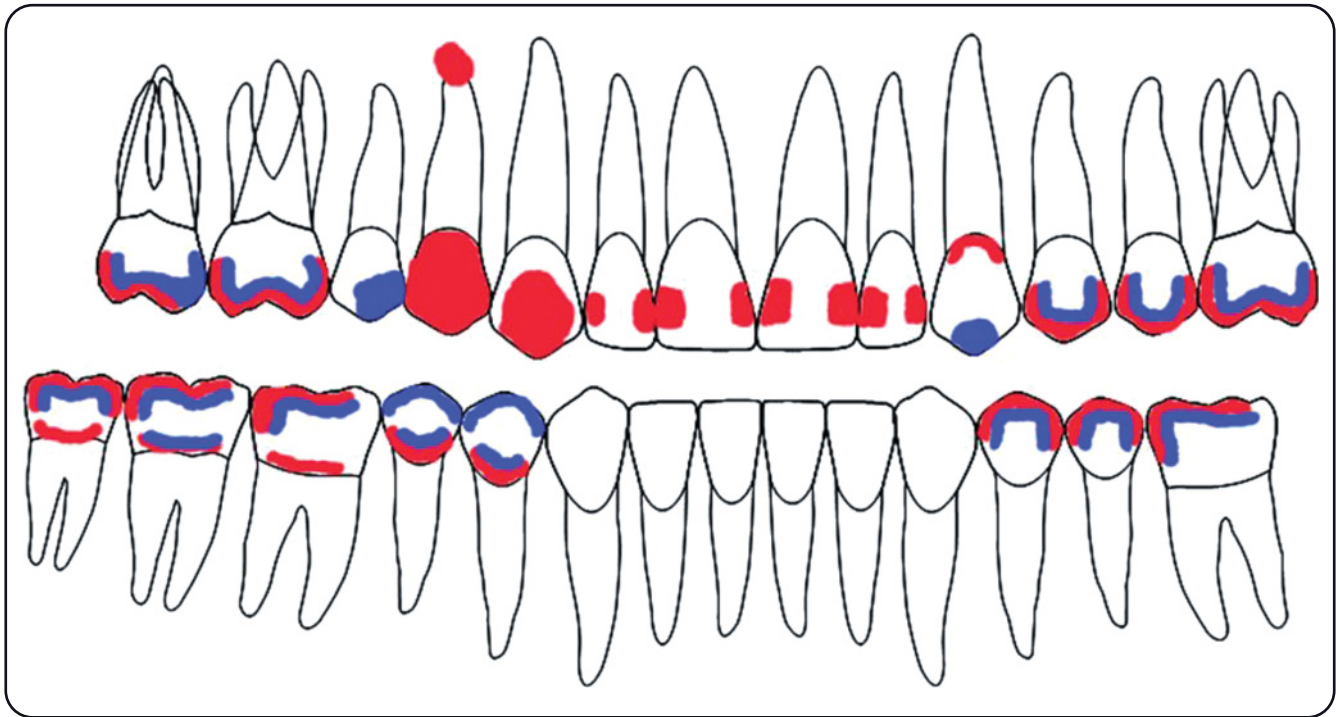


Figure 4: Dental charting.

- Mandibular right first premolar (28) B
- Mandibular right second premolar (29) B
- Mandibular right first molar (30) B, DO
- Mandibular right second molar (31) B, DO
- Mandibular right third molar (32) B, MOD
- Missing teeth: Maxillary third molars (1, 16), maxillary left second molar (15), mandibular left second and third molars (17, 18)
- Nonrestorable: Maxillary right second premolar (5)
- Apical periodontitis: Maxillary right second premolar and canine (5, 6)

Radiographic Findings

(See Figs. 5 and 6.)

Diagnosis

- Generalized gingivitis, moderate localized calculus, mild localized periodontitis
- Partial edentulism
- Caries
- Inadequate restorations
- Apical periodontitis
- Erosion

Clinical Decision-Making Determining Factors

- Bulimia is an eating disorder in which the patient, typically female, is preoccupied with her weight and

body image. The patient often goes through periods of consuming large amounts of food (bingeing) and then trying to rid herself of the food through self-induced vomiting or the use of laxatives (purging). The chronic exposure of the teeth to the gastrointestinal acid may result in damage, the severity of which depends on the frequency of vomiting. The patient's status and control of the disorder should be assessed prior to start of any dental treatment (Kavoura, Kourtis et al. 2005).

- Dental caries may occur as a result of plaque buildup. The plaque contains bacteria that can produce acid from fermenting sugars in the plaque such as sucrose and glucose. This causes a drop in pH that can lead to demineralization of the tooth surface. If this process goes unchecked, the pH drop can result in a breakdown of the enamel and the start of caries formation (Kidd and Joyston-Bechal 1997).
- In patients with bulimia, the average pH of vomit has been recorded as 2.9–5.0, mean pH of 3.8. Enamel demineralization can occur at pH of 5.5. The synergistic effect of plaque bacteria and decreased oral pH due to bulimia creates an environment for the caries process to progress rapidly (Milosevic, Brodie et al. 1997; Faine 2003).

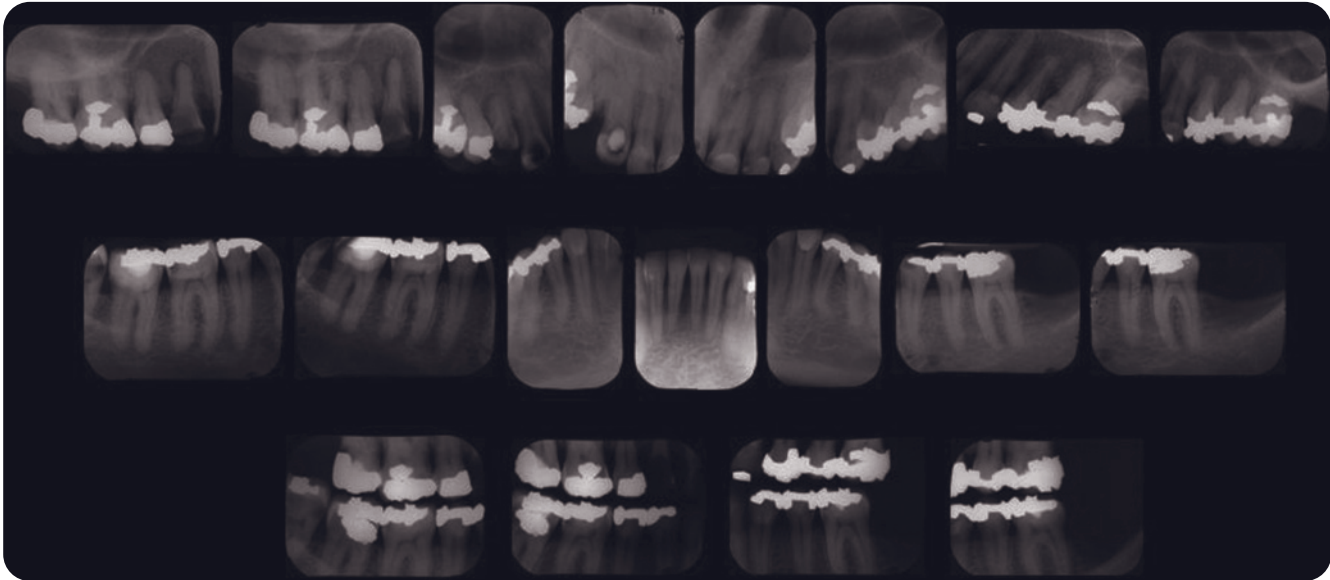


Figure 5: Full mouth series of radiographs.

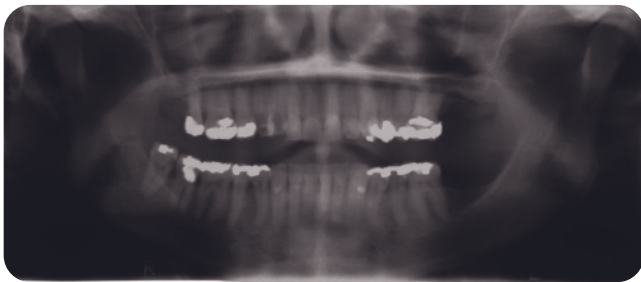


Figure 6: Panoramic radiograph.

- Plaque control and overall improvement of oral hygiene is essential for the successful outcome of prosthetic treatment for this patient. Assessment of the patient's motivation for improvement should include the level of improvement of oral hygiene. Definitive prosthetic treatment should not be undertaken unless the patient demonstrates a high level of compliance (Faine 2003).

Questions

1. Dental findings in patients with bulimia are

- Erosion of the lingual and occlusal surfaces of the maxillary teeth
- High rate of caries
- Xerostomia
- Enlarged parotid gland
- All of the above

2. What is erosion?

- Loss of tooth structure through oral habit involving a foreign object
- Loss of tooth structure through a bacterial chemical process
- Loss of tooth structure through a nonbacterial chemical process
- Loss of tooth structure through mechanical grinding action

3. Cessation of smoking should be included in this patient's plan for oral rehabilitation. This may include the use of counseling and nicotine replacement therapy (NRT). NRT can be in the form of gum, transdermal patch, inhaler, lozenges, or nasal spray. The use of NRT has demonstrated an increased rate of quitting by what percentage?

- A. 10–30%
- B. 30–50%
- C. 50–70%
- D. 70–90%

4. Recommendations for management of a dental patient with bulimia must first involve the discontinuation of the binge-purge behavior through psychological evaluation and psychotherapy. Preventive treatment to control and neutralize the oral pH has been recommended in the form of which of the following:

- A. Fluoride rinses and trays for home use
- B. Use of alkaline mouth rinse after vomiting
- C. Use of soft toothbrush and improved oral hygiene
- D. Sugar-free gum and candy to stimulate salivary flow
- E. All of the above

5. The maxillary right second premolar (5) is nonrestorable and will be extracted. (See Fig. 7.) You are considering the use of an endosseous implant for the management of that edentulous area. Implants in patients with bulimia have not been thoroughly studied. Only case reports exist in the dental literature. What oral finding is most likely to be a contraindication for the use of implants in this patient?

- A. High caries index
- B. Poor oral hygiene
- C. Low oral pH
- D. Tooth erosion

6. Porcelain laminate veneers on the lingual surfaces of maxillary anterior teeth have been prescribed by some clinicians to restore form and to protect those highly susceptible areas from further acidic damage. What may present as the greatest problem with this treatment option?

- A. Breakdown of the adhesive resin
- B. Need for endodontic therapy
- C. Wear of the mandibular anterior teeth
- D. Increased sensitivity

7. Complex restorative treatment should be avoided in patients with bulimia unless a more conservative alternative is not possible. What is the primary reason for this recommendation?

- A. Relapse of bulimic behavior is common.
- B. Patient compliance with complex treatment is often poor.
- C. The poor periodontal prognosis of most bulimic patients contraindicates complex treatment.
- D. Treatment will have additional psychological effects.

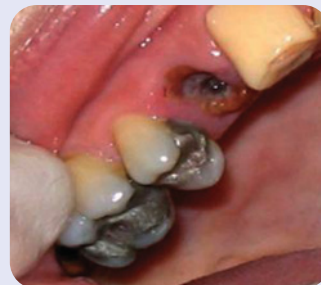

Figure 7: Nonrestorable maxillary right second premolar.

8. Initial therapy for patients with more severe bulimia includes which of the following?

- A. No dental treatment should be offered until bulimic behavior is controlled.
- B. Full mouth provisional restorations should be fabricated until bulimic behavior is controlled.
- C. Management of pain due to dentin exposure should be provided until bulimic behavior is controlled.
- D. Buildup of missing tooth structures in composite resin should be done provisionally until bulimic behavior is controlled.

9. A (Roberts and Li 1987)
 8. C (Brown and Bonifazi 1993)
 7. A (Little 2002)
 6. C (Hastings 1996)

9. In a study on clinical findings in patients suffering from bulimia, Roberts and Li found which of the following to be true regarding the periodontal health of their patients?

- A. Periodontal health is near normal.
- B. Periodontal health is improved because of acidic oral conditions.
- C. Periodontal health is severely compromised.

- ANSWERS
 1. E (Little 2002)
 2. C (Verrett 2001)
 3. C (Stead, Perera et al. 2008)
 4. E (Faine 2003)
 5. B (Ambard and Mueninghoff 2002; Scully, Hobkirk et al. 2007)

The authors would like to acknowledge and thank Dr. Shadi Abedin and other students of Dr. Meeker and Associates for clinical case photographs and treatment performed at New York University College of Dentistry.

References

- Ambard, A. and L. Mueninghoff (2002). "Rehabilitation of a bulimic patient using endosteal implants." *J Prosthodont* 11(3): 176–80.
- Brown, S. and D. Z. Bonifazi (1993). "An overview of anorexia and bulimia nervosa, and the impact of eating disorders on the oral cavity." *Compendium* 14(12): 1594, 1596–1602, 1604–8; quiz 1608.
- Faine, M. P. (2003). "Recognition and management of eating disorders in the dental office." *Dent Clin North Am* 47(2): 395–410.
- Hastings, J. H. (1996). "Conservative restoration of function and aesthetics in a bulimic patient: a case report." *Pract Periodontics Aesthet Dent* 8(8): 729–36; quiz 738.
- Kavoura, V., S. G. Kourtis et al. (2005). "Full-mouth rehabilitation of a patient with bulimia nervosa. A case report." *Quintessence Int* 36(7–8): 501–10.
- Kidd, E. A. M. and S. Joyston-Bechal (1997). *Essentials of dental caries: the disease and its management*. Oxford, New York, Oxford University Press.
- Little, J. W. (2002). *Dental management of the medically compromised patient*. St. Louis, Mosby.
- Little, J. W. (2002). "Eating disorders: dental implications." *Oral Surg Oral Med Oral Pathol Oral Radiol Endod* 93(2): 138–43.
- Milosevic, A., D. A. Brodie et al. (1997). "Dental erosion, oral hygiene, and nutrition in eating disorders." *Int J Eat Disord* 21(2): 195–9.
- Roberts, M. W. and S. H. Li (1987). "Oral findings in anorexia nervosa and bulimia nervosa: a study of 47 cases." *J Am Dent Assoc* 115(3): 407–10.
- Scully, C., J. Hobkirk et al. (2007). "Dental endosseous implants in the medically compromised patient." *J Oral Rehabil* 34(8): 590–9.
- Stead, L. F., R. Perera et al. (2008). "Nicotine replacement therapy for smoking cessation." *Cochrane Database Syst Rev* (1): CD000146.
- Verrett, R. G. (2001). "Analyzing the etiology of an extremely worn dentition." *J Prosthodont* 10(4): 224–33.

Case 35

Case 35

Management of oral manifestations of methamphetamine abuse

Methamphetamine use is estimated at 10.4 million people in the United States and over 35 million people worldwide. Amphetamines are generally prescribed to control weight and to treat attention deficit disorder and narcolepsy, as well as for treatment-resistant depression. Poor oral hygiene, xerostomia, and rampant caries are associated with patients with methamphetamine abuse.

CASE STORY

A 28-year-old female patient presents for comprehensive treatment. She expressed her concerns with poor appearance of her teeth and bleeding gingival tissues.

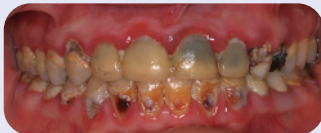

Figure 1: Preoperative presentation.

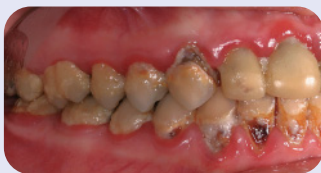

Figure 2: Preoperative right side.

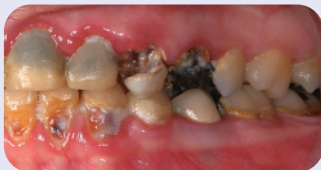

Figure 3: Preoperative left side.

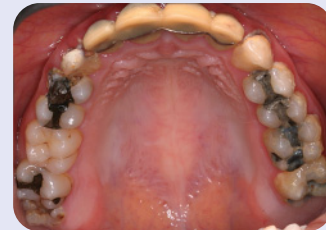

Figure 4: Preoperative maxilla.

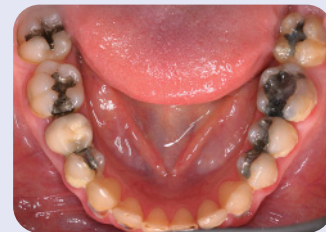

Figure 5: Preoperative mandible.

LEARNING GOALS AND OBJECTIVES

- Understand potential systemic side effects of methamphetamine abuse.
- Understand the etiology of methamphetamine-induced oral manifestations.
- Learn important factors in treating the oral complications related to methamphetamine abuse.

Medical History

- History of methamphetamine abuse about 5 years ago

Dental History

- Even though the patient had frequent dental visits over the past 3 years, she reported suffering from dry mouth, caries and bleeding gingival tissues.

Clinical Findings/Problem List

- Generalized rampant caries on the existing dentition
- Generalized moderate to severe plaque accumulation
- Generalized erythematous and edematous gingival tissue
- Existing provisional restorations on the maxillary anterior teeth

Radiographic Findings

(See Fig. 6.)

Diagnosis

- Poor oral hygiene
- Generalized moderate to severe periodontitis
- Rampant caries
- Xerostomia
- Methamphetamine abuse

Clinical Decision-Making Determining Factors

- Methamphetamine is a white, odorless powder that can be further purified into the “ice” form that is usually smoked and very addictive. Methamphetamine-induced dopamine release in the brain causes a rush of pleasure. The side effects of methamphetamine abuse include cardiac dysrhythmias, hypertension, and tachypnea. Methamphetamine is structurally related to epinephrine and can increase both systolic and diastolic blood pressures. Methamphetamine also causes cognitive and emotional changes including paranoia, anxiety, depression, irritability, hallucinations, mood swings, and violent behavior. Psychosis and paranoia can persist for years after methamphetamine use is stopped (Seiden,

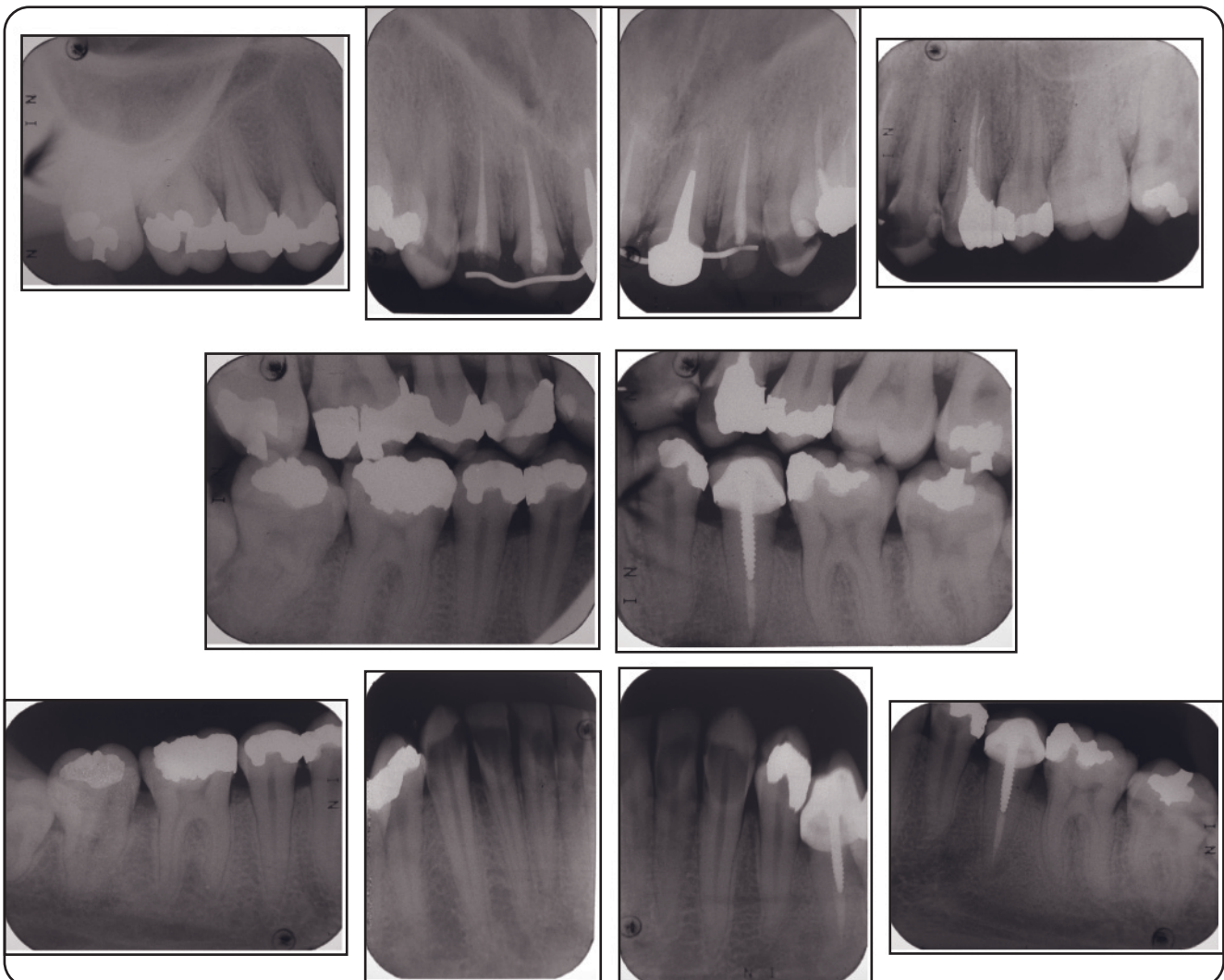


Figure 6: Full mouth series of radiographs.

Fischman et al. 1976; Davidson, Gow et al. 2001; Hamamoto and Rhodus 2009; Goodchild and Donaldson 2007).

- Xerostomia, rampant caries, bad taste, bruxism, and muscle trismus are common dental complications related to methamphetamine abuse (McGrath and Chan 2005; Donaldson and Goodchild 2006; Shaner, Kimmes et al. 2006; Hamamoto and Rhodus 2009).
- Reduction of unstimulated salivary flow due to decreased salivary secretion by inhibitory alpha-2 receptors results in saliva rich in protein, causing the patient's sensation of dryness (Goodchild and Donaldson 2007).
- The caries in chronic methamphetamine users is unique in that it mostly involves the buccal smooth surface of the teeth and the interproximal surfaces of the anterior teeth. The caries caused by methamphetamine abuse progress more slowly (Rhodus and Little 2005; Goodchild and Donaldson 2007).
- Methamphetamine's duration of action can be up to 24 hours. If the patient has used methamphetamine within the last 24 hours, the vasoconstrictor in the local anesthetic could result in increased risk for cardiac dysrhythmias, hypertension, myocardial infarction, and cerebrovascular accidents (Hamamoto and Rhodus 2009).

- Frequent oral hygiene instruction and prophylaxis are very important for controlling progression of caries. Dietary counseling to reduce carbohydrate-rich soft drinks and the use of fluoride via trays and rinses should be part of dental management.

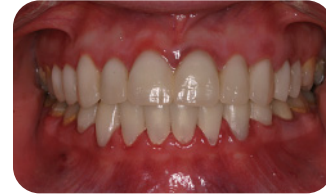

Figure 7: Provisional restorations.

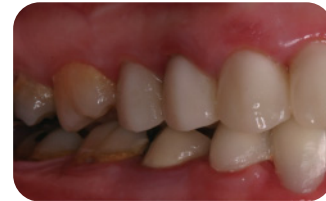

Figure 8: Provisional restorations right side.

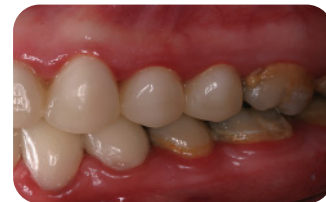

Figure 9: Provisional restorations left side.

Questions

1. The most important factor in treating patients with methamphetamine-induced rampant caries is

- Fabrication of new restorations
- Discontinuation of use of methamphetamine
- Frequent dental visits
- Fabrication of occlusal device

2. Methamphetamine can cause

- Increase in systolic pressure
- Increase in diastolic pressure
- Dry mouth
- All of the above

3. Methamphetamine's duration of action is

- Up to 24 h
- Up to 48 h
- Up to 72 h
- Up to a month

4. Oral manifestation of methamphetamine abuse includes

- Xerostomia
- Rampant caries
- Bruxism
- Trismus
- All of the above

ANSWERS

1. B (Hamamoto and Rhodus 2009)
2. D (Goodchild and Donaldson 2007)
3. A (Hamamoto and Rhodus 2009)

4. E (Donaldson and Goodchild 2006; Goodchild and Donaldson 2007; Hamamoto and Rhodus 2009)

The authors would like to acknowledge and thank Dr. Ryan Sellinger for clinical case photographs and treatment performed at New York University College of Dentistry.

References

- Davidson, C., A. J. Gow et al. (2001). "Methamphetamine neurotoxicity: necrotic and apoptotic mechanisms and relevance to human abuse and treatment." *Brain Res Brain Res Rev* 36(1): 1–22.
- Donaldson, M. and J. H. Goodchild (2006). "Oral health of the methamphetamine abuser." *Am J Health Syst Pharm* 63(21): 2078–82.
- Goodchild, J. H. and M. Donaldson (2007). "Methamphetamine abuse and dentistry: a review of the literature and presentation of a clinical case." *Quintessence Int* 38(7): 583–90.
- Hamamoto, D. T. and N. L. Rhodus (2009). "Methamphetamine abuse and dentistry." *Oral Dis* 15(1): 27–37.
- McGrath, C. and B. Chan (2005). "Oral health sensations associated with illicit drug abuse." *Br Dent J* 198(3): 159–62; discussion 147; quiz 174.
- Rhodus, N. L. and J. W. Little (2005). "Methamphetamine abuse and 'meth mouth.'" *Northwest Dent* 84(5): 29, 31, 33–7.
- Seiden, L. S., M. W. Fischman et al. (1976). "Long-term methamphetamine induced changes in brain catecholamines in tolerant rhesus monkeys." *Drug Alcohol Depend* 1(3): 215–9.
- Shaner, J. W., N. Kimmes et al. (2006). "'Meth mouth': rampant caries in methamphetamine abusers." *AIDS Patient Care STDS* 20(3): 146–50.

WWW.HIGHDENT.IR

همیار دندانسازان و دندانپزشکان

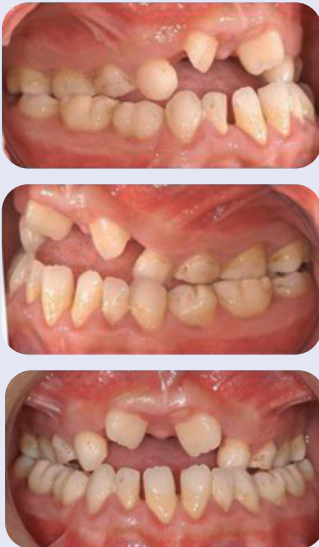Case 36

Case 36

Management of cleidocranial dysplasia I—treatment of an adolescent patient

CASE STORY

A 17-year-old male patient presents with a chief complaint of “I don’t like the way my teeth look, and I would like to have a nice smile.” The patient is accompanied by his mother (see Case 37) and has been diagnosed with cleidocranial dysplasia (CCD). The patient has received only palliative and emergency care for his dental condition and no formal management plan has been pursued for the treatment of CCD.



Figures 1, 2, and 3: Right, left, and maximum intercuspation.

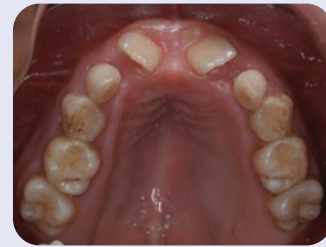

Figure 4: Maxillary occlusal view.

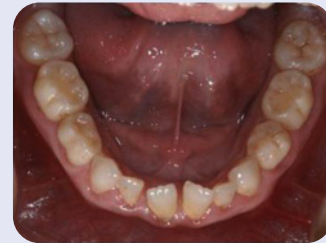

Figure 5: Mandibular occlusal view.

LEARNING GOALS AND OBJECTIVES

- To recognize signs of CCD
- To discuss treatment approaches for a young patient with CCD
- To understand the advantages and disadvantages of various treatment options
- To manage CCD dental treatment with a multidisciplinary approach

Medical History

- Cleidocranial dysplasia

Dental History

- Palliative treatment including extraction of mobile primary teeth

Medications and Allergies

- No medications
- No known drug allergies

Review of Systems

- Vital signs:
 - Blood pressure: 120/78
 - Heart rate: 70 beats/minute
 - Respiration rate: 16 breaths/minute

Significant Soft Tissue Examination Findings

- No significant findings

Significant Clinical Findings/Problem List

- Anterior open bite
- Bilateral posterior cross-bite
- Underdeveloped maxilla, class III malocclusion
- Retention of primary teeth

- Supernumerary teeth
- Poor anterior aesthetics
- Plaque accumulation
- Deficiency in speech

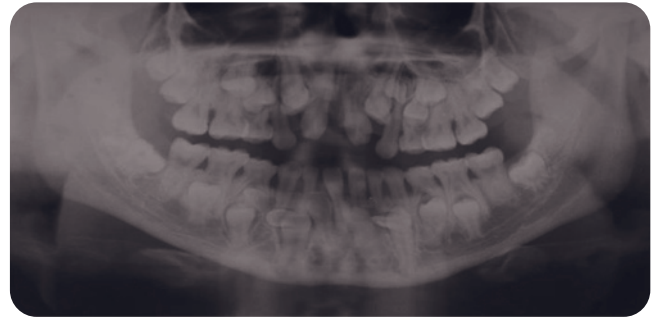
Radiographic Findings

Figure 6: Panoramic radiograph.

Charting

(See Fig. 7.)

Diagnosis

- Cleidocranial dysplasia
- Deficient aesthetics

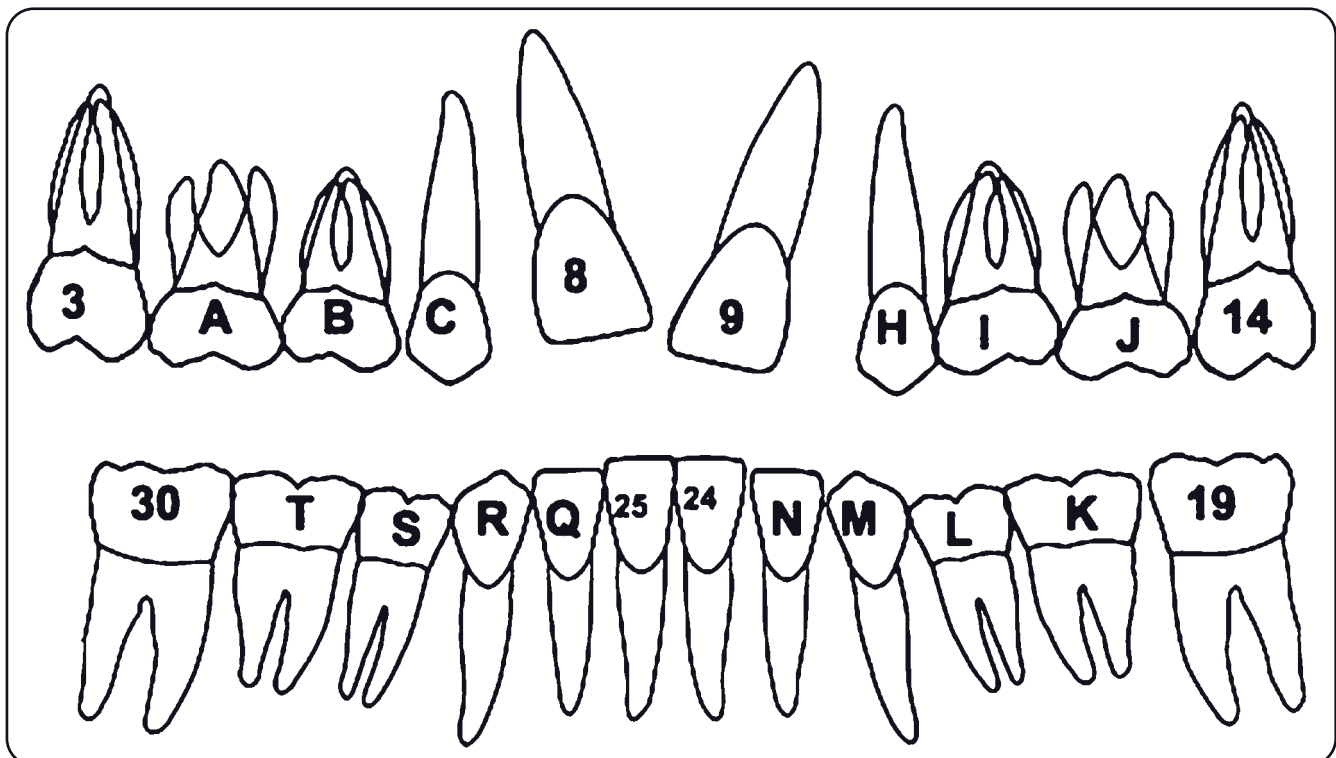


Figure 7: Dental charting of erupted teeth.

Clinical Decision-Making Determining Factors

- Cleidocranial dysplasia (CCD) is an autosomal dominant condition that is genetically inherited. The patient presented here has inherited this condition from his mother (see Case 37). The genetic condition affects bone growth, often causing aplasia (defective development) or hypoplasia (incomplete or underdevelopment) of bones undergoing intramembranous ossification. The general appearance of a person presenting with CCD is typically frontal, parietal, and occipital bossing; underdevelopment of the maxilla; and a brachycephalic appearance of the skull. The clavicles are among the bones commonly affected by this condition (Gonzalez Lopez, Ortiz Solalinde et al. 2004; Angle and Rebellato 2005; Bratu 2005),
- Dental findings in patients with CCD may include class III jaw relationship, underdeveloped maxilla, overretention of deciduous teeth, failure or delayed eruption of permanent teeth, multiple supernumerary teeth, and cyst formation. Because dental complications have a direct effect on the patient's quality of life, CCD patients are often in extensive dental treatment that includes multiple disciplines (Golan, Baumert et al. 2004; Angle and Rebellato 2005; Bratu 2005).
- Typical treatment of patients with CCD involves a combination of oral surgery and orthodontics followed by prosthetic treatment as needed. There are several approaches to the staging of the surgical and orthodontic treatments. One of the most common approaches, known as the Jerusalem approach, requires the removal of deciduous and supernumerary teeth and active eruption of the permanent dentition. More specifically, during the first stage of treatment, which occurs typically around the dental age of 7–8, the anterior deciduous teeth and supernumerary teeth are surgically removed. The permanent incisors are exposed and bonded attachments are placed to facilitate the eruption and alignment of the permanent incisors.
- During the second stage of this approach, which occurs during the dental age of 10–11, the remaining deciduous and supernumerary teeth are removed. The unerupted premolars and canines are exposed and brought into proper position by forced eruption. The posterior teeth provide anchorage during stage one, and the anterior teeth as well as the first molars provide anchorage during stage two (Becker, Lustmann et al. 1997; Becker, Shteyer et al. 1997).
- Other approaches to treatment of patients with CCD include the Toronto-Melbourne approach and the Belfast-Hamburg approach. In the former approach, the deciduous teeth are initially removed and exposure of unerupted permanent teeth is delayed until after the permanent first molars have spontaneously erupted. This approach requires several small surgeries. In the latter approach, all surgery is limited to one session where all deciduous and supernumerary teeth are removed and all permanent teeth are exposed and allowed to erupt either spontaneously or with the aid of orthodontic appliances (Becker, Lustmann et al. 1997; Becker, Shteyer et al. 1997).
- Early intervention is key in management of patients with cleidocranial dysplasia. Our patient was unable to receive the care he needed at the more typical age of 10–12. He presented for treatment at the age of 17. As the patient ages, the success rate of treatment can decrease. Some factors that contribute to the decrease in predictability in treatment outcomes with increased age include obstruction by advanced development of supernumerary teeth, increased displacement of permanent teeth, poor root development of permanent teeth, ankylosis of teeth that require movement, and the closure of the apices of teeth requiring active eruption (Jensen and Kreiborg 1990).

Questions

1. Cleidocranial dysplasia is

- A. A congenital disorder
- B. An acquired disorder
- C. A disorder affecting the elderly
- D. A disorder affecting only the oral/dental structures

2. Management of CCD involves a multidisciplinary approach due to complexity of the patient presentation. Team members usually include the orthodontist, oral and maxillofacial surgeon, and the restorative dentist. At what point should the restorative dentist become involved in treatment of these patients?

- A. From the outset because the restorative treatment plan can help guide surgical and orthodontic treatment
- B. After the first series of extractions where the permanent dentition is exposed
- C. After the completion of the surgical and orthodontic phases
- D. There is usually no need for restorative treatment if the surgical and orthodontic phases are executed properly.

3. Dental features of cleidocranial dysplasia include all of the following *except*

- A. Cyst formation of unerupted teeth
- B. Retention of deciduous teeth
- C. Missing secondary dentition
- D. Delayed eruption of secondary dentition

4. The physical features of cleidocranial dysplasia include all of the following *except*

- A. Missing clavicles
- B. Tall and lanky stature
- C. Frontal bossing
- D. Underdeveloped maxilla

5. A staged orthodontics treatment approach is one in which the anterior permanent dentition is guided into proper occlusion and followed by the posterior permanent dentition. According to Daskalogiannakis et al., what is the main advantage of a two-stage approach to the treatment of patients with cleidocranial dysplasia?

- A. Shortened treatment time
- B. Ability to maintain the patient's existing occlusal vertical dimension
- C. Ability to avoid maxillofacial surgery
- D. There is no advantage to this treatment modality versus the others.

6. The RUNX2 gene on the short arm of chromosome 6 had been found to be the master gene in the formation of bone and dental tissues. It is a defect on this gene that causes cleidocranial dysplasia. How can this information be used in the treatment of patients suffering from cleidocranial dysplasia?

- A. Genetic testing is not needed because manifestation of signs are early enough that they do not evade diagnosis.
- B. Genetic testing should be reserved for patients with a familial history of cleidocranial dysplasia.
- C. Genetic diagnosis of these patients can lead to early detection and early intervention.
- D. Genetic testing is too invasive: the risks do not outweigh the benefits.

7. Early intervention in management of patients with cleidocranial dysplasia is key. Which of the following is the reason for this?

- A. The patient will not remember the trauma of the surgical procedures.
- B. Due to incomplete growth of facial bones, treatment outcomes are more favorable.
- C. Lack of closure of tooth apices allows for more successful active eruption.
- D. All of the above

8. In patients with CCD, the deciduous dentition often requires extraction followed by orthodontic intervention for active eruption of permanent dentition into occlusion. Why is this necessary?

- A. Removal of deciduous teeth does not necessarily lead to eruption of permanent dentition in CCD patients.
- B. To ensure proper bone formation after eruption of permanent dentition is achieved
- C. To ensure proper alignment of the permanent dentition after extraction of the deciduous dentition
- D. To ensure development of soft tissues surrounding the permanent teeth

- 8. A (Angle and Rebellato 2005)
- 7. C (Jensen and Kreiborg 1990)
- 6. C (Golan, Baumert et al. 2003)
- 5. B (Daskalogiannakis, Piedade et al. 2006)

- 4. B (Daskalogiannakis, Piedade et al. 2006)
- 3. C (Angle and Rebellato 2005)
- 2. A (Angle and Rebellato 2005)
- 1. A (Angle and Rebellato 2005)

ANSWERS

The authors would like to acknowledge and thank Dr. Tonino Ciocca and Dr. Mohammad Alavi for clinical case photographs taken at New York University College of Dentistry.

References

- Angle, A. D. and J. Rebellato (2005). "Dental team management for a patient with cleidocranial dysostosis." *Am J Orthod Dentofacial Orthop* 128(1): 110–117.
- Becker, A., J. Lustmann et al. (1997). "Cleidocranial dysplasia: Part 1—General principles of the orthodontic and surgical treatment modality." *Am J Orthod Dentofacial Orthop* 111(1): 28–33.
- Becker, A., A. Shteyer et al. (1997). "Cleidocranial dysplasia: Part 2—Treatment protocol for the orthodontic and surgical modality." *Am J Orthod Dentofacial Orthop* 111(2): 173–183.
- Bratu, D. P. (2005). "Oral Manifestation in Cleidocranial Dysplasia." *TMJ* 55(4): 379–385.
- Daskalogiannakis, J., L. Piedade et al. (2006). "Cleidocranial dysplasia: 2 generations of management." *J Can Dent Assoc* 72(4): 337–342.
- Golan, I., U. Baumert et al. (2003). "Dentomaxillofacial variability of cleidocranial dysplasia: clinicoradiological presentation and systematic review." *Dentomaxillofac Radiol* 32(6): 347–354.
- Golan, I., U. Baumert et al. (2004). "Early craniofacial signs of cleidocranial dysplasia." *Int J Paediatr Dent* 14(1): 49–53.
- Gonzalez Lopez, B. S., C. Ortiz Solalinde et al. (2004). "Cleido cranial dysplasia: report of a family." *J Oral Sci* 46(4): 259–266.
- Jensen, B. L. and S. Kreiborg (1990). "Development of the dentition in cleidocranial dysplasia." *J Oral Pathol Med* 19(2): 89–93.

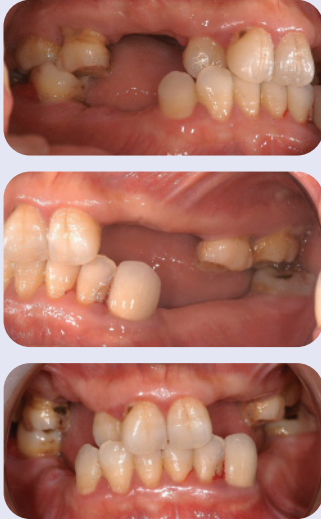Case 37

Case 37

Management of cleidocranial dysplasia II— treatment of an adult patient

CASE STORY

A 49-year-old female patient presents with a chief complaint of “I want to be able to smile without feeling self-conscious.” The patient is diagnosed with cleidocranial dysplasia (CCD). Her dental treatment has typically involved extraction of mobile or carious teeth and replacement of missing teeth with removable prostheses. See Case 36 for presentation of this patient’s son.



Figures 1, 2, and 3: Right, left, and maximum intercuspitation.

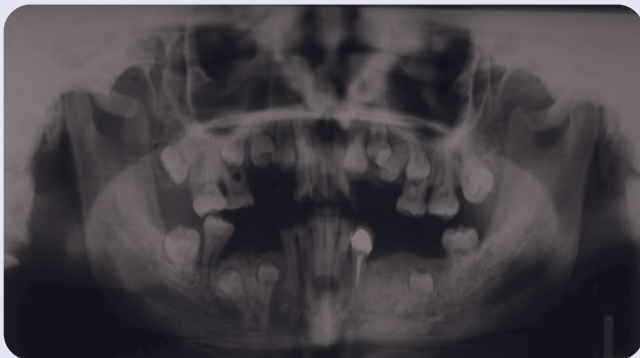


Figure 4: Panoramic radiograph.

Clinical Cases in Prosthodontics, Leila Jahangiri, Marjan Moghadam, Mijin Choi, and Michael Ferguson, © 2011 Blackwell Publishing Ltd.

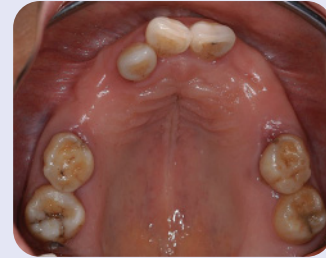

Figure 5: Maxillary occlusal view.

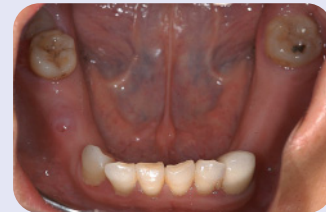

Figure 6: Mandibular occlusal view.

LEARNING GOALS AND OBJECTIVES

- To recognize signs of cleidocranial dysplasia (CCD)
- To discuss treatment approaches for an adult patient with CCD
- To understand the advantages and disadvantages of various treatment options
- To manage CCD dental treatment with a multidisciplinary approach

Medical History

- Cleidocranial dysplasia

Dental History

- Extraction of mobile or nonrestorable teeth
- Endodontic therapy of mandibular left canine
- Removable partial dentures
- Full coverage metal-ceramic restorations

Medications and Allergies

- Birth control pills
- No known drug allergies

Review of Systems

- Vital signs:
 - Blood pressure: 122/80
 - Heart rate: 72 beats/minute
 - Respiration rate: 16 breaths/minute

Soft Tissue Examination Findings

- No significant findings

Charting

(See Fig. 7.)

Significant Clinical Findings/Problem List

- Partial edentulism
- Reverse articulation—left posterior
- Reverse articulation—anterior, involving maxillary right lateral incisor (7)
- Periodontal disease, including but not limited to furcation involvement of maxillary primary left and right second molars (A and J)
- Class II mobility of mandibular right first molar (30)
- Periapical pathology and pain of mandibular left canine (22)

Diagnosis

- Cleidocranial dysplasia
- Partial edentulism
- Periradicular periodontitis
- Anterior and posterior cross articulation
- Localized severe periodontal disease

Clinical Decision-Making Determining Factors

- Cleidocranial dysplasia (*cleido* refers to the collar bone, *cranial* refers to the head, and *dysplasia* refers to abnormal forming) is an autosomal dominant condition that is often genetically inherited. The patient presented in this case story did not inherit the condition from either parent. It is reported that of all cleidocranial dysplasia cases, the majority are genetically inherited, but up to one-third can be spontaneous genetic mutations. This patient has also passed CCD on to her son (see Case 36). It is transmitted as an autosomal dominant trait. CCD is caused by mutation in the runX2 gene on chromosome 6p21. The genetic condition affects bone growth, often causing aplasia (defective development) or hypoplasia (incomplete or underdevelopment) of bones undergoing intramembranous ossification. The general appearance of a person presenting with CCD is frontal, parietal, and occipital bossing; underdevelopment of the maxilla; and a brachycephalic appearance of the skull. The clavicles

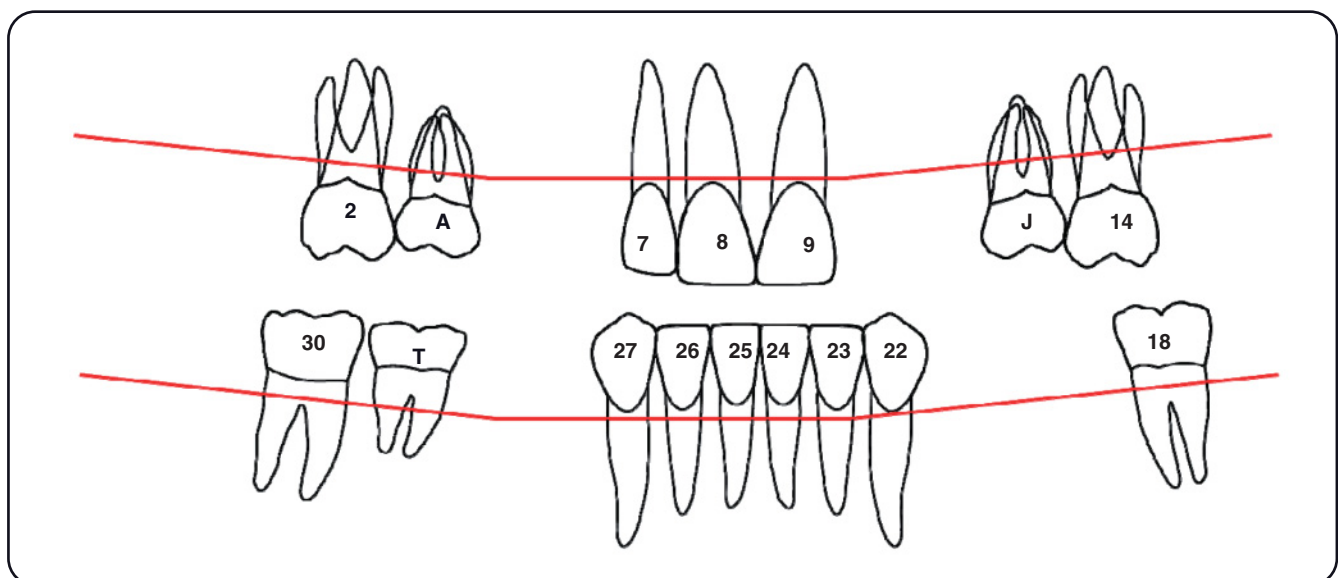


Figure 7: Dental charting.

are among the bones commonly affected by this condition (Gonzalez Lopez, Ortiz Solalinde et al. 2004; Angle and Rebellato 2005; Bratu 2005).

- Dental problems are typically the most significant problems in CCD patients and may include class III jaw relationship, underdeveloped maxilla, overretention of deciduous teeth, delayed eruption of permanent teeth, failure of eruption of permanent dentition, multiple supernumerary teeth, and cyst formation. Because dental complications have a direct effect on their quality of life, CCD patients are often involved in extensive dental treatment that includes multiple disciplines (Golan, Baumert et al. 2004; Angle and Rebellato 2005; Bratu 2005).
- Typical treatment of patients with CCD involves an aggressive combination of oral surgery and orthodontics followed by prosthetic treatment as needed, starting at a young age before the complete development of the roots of permanent teeth (See Case 36). Treatment of adult patients typically involves restoration of defective teeth and

replacement of missing teeth with removable or implant prostheses (Jensen and Kreiborg 1990).

- The patient presented here did not have access to proper medical care at an early age and was not diagnosed with CCD until her midtwenties. The treatment that she received was geared toward management of emergencies via extractions and endodontic therapy rather than a more comprehensive treatment plan. The patient was unable to receive this type of treatment at the more typical age of 10–12 years. She presents for treatment at the age of 49. The patient's age presents a great challenge in treatment planning and management. There is a paucity of evidence and sufficient number of case reports with data on treatment of these patients with osseointegrated implants. The limitations with implant options include presence of unerupted teeth in the underlying bone, as well as osseointegration outcome with aplastic and hypoplastic alveolar bone (Petropoulos, Balshi et al. 2004).

Questions

1. What is the greatest challenge to orthodontic treatment of an adult patient with CCD?

- Lack of adequate number of teeth for anchorage
- Poor quality of bone leading to periodontal disease in adulthood
- Poor quality of bone leading to increased rate of tooth mobility
- High caries rate leading to tooth loss

2. One of the most significant challenges involved with treatment of an adult patient with CCD is

- Inadequate/delayed healing due to worsening of the CCD condition with age
- Poor bone quality leading to failure of abutment teeth used for fixed or removable prostheses
- Adult onset chronic periodontal disease
- Difficult recovery after extensive surgical procedures

3. If early access to comprehensive treatment is limited, the patient with CCD usually receives palliative dental care typically consisting of extraction of mobile or carious teeth. The most detrimental result of receiving only palliative treatment can be

- Psychological strain for the CCD patient
- Supraeruption of impacted teeth
- Fewer treatment options due to loss of key abutment teeth
- Continued growth of the mandible leading to prognathism in the adult

4. After consultation with different dental disciplines and considering the difficulties of extracting the mandibular right premolars (28 and 29), the treatment plan for the patient's mandibular arch includes extraction of right first molar (30) due to hopeless periodontal prognosis. Considering the patient's age and the condition of the remaining teeth, what type of prosthesis is recommended for replacement of the missing teeth in the mandible?

- A. Implant placement in the mandibular left region and provision of an implant-retained removable partial denture
- B. Conventional fixed partial dentures
- C. Removal of mandibular teeth and fabrication of implant-retained fixed partial dentures
- D. Removable complete denture after extraction of all remaining teeth

5. The treatment plan for the patient's maxillary arch has been determined with the input of the periodontist. It is determined that all of the remaining maxillary teeth will be maintained. The prosthetic treatment plan includes a removable partial denture. What is the prime concern about fabrication of the removable partial denture for this patient?

- A. High caries risk of the remaining abutment teeth
- B. Long-term prognosis of remaining abutment teeth
- C. Eruption of the impacted supernumerary under pressure of the removable partial denture
- D. Intrusion of abutment teeth due to poor quality of supporting bone

6. The use of dental implants may be controversial for CCD patients because

- A. Permanent teeth may be difficult to extract due to malformed teeth.
- B. Permanent teeth may be difficult to extract due to their deep unerupted positions.
- C. Extraction of teeth may lead to inadequate bony ridges for implant placement.
- D. All of the above

ANSWERS

- 1. A (Kuroda, Yanagita et al. 2007)
- 2. D (Angle and Rebellato 2005)
- 3. C (Butterworth 1999)

- 4. A (Butterworth 1999)
- 5. B (Stewart, Rudd et al. 1983)
- 6. D (The National Craniofacial Association)

The authors would like to acknowledge and thank Dr. Tonino Ciocca and Dr. Mohammad Alavi for clinical case photographs and treatment performed at New York University College of Dentistry.

References

- Angle, A. D. and J. Rebellato (2005). "Dental team management for a patient with cleidocranial dysostosis." *Am J Orthod Dentofacial Orthop* 128(1): 110–117.
- Bratu, D. P. (2005). "Oral manifestation in cleidocranial dysplasia." *TMJ* 55(4): 379–385.
- Butterworth, C. (1999). "Cleidocranial dysplasia: modern concepts of treatment and a report of an orthodontic resistant case requiring a restorative solution." *Dent Update* 26(10): 458–462.
- Golan, I., U. Baumert et al. (2004). "Early craniofacial signs of cleidocranial dysplasia." *Int J Paediatr Dent* 14(1): 49–53.
- Gonzalez Lopez, B. S., C. Ortiz Solalinde et al. (2004). "Cleido cranial dysplasia: report of a family." *J Oral Sci* 46(4): 259–266.
- Jensen, B. L. and S. Kreiborg (1990). "Development of the dentition in cleidocranial dysplasia." *J Oral Pathol Med* 19(2): 89–93.
- Kuroda, S., T. Yanagita et al. (2007). "Titanium screw anchorage for traction of many impacted teeth in a patient with cleidocranial dysplasia." *Am J Orthod Dentofacial Orthop* 131(5): 666–669.
- Petropoulos, V. C., T. J. Balshi et al. (2004). "Treatment of a patient with cleidocranial dysplasia using osseointegrated implants: a patient report." *Int J Oral Maxillofac Implants* 19(2): 282–287.
- Stewart, K. L., K. D. Rudd et al. (1983). *Clinical removable partial prosthodontics*. St. Louis, Mosby.
- The National Craniofacial Association: <http://www.faces-cranio.org/Disord/CCD.htm>

Index

Page numbers followed by f denote photographs.

A

- Abrasion, tooth wear from, 139
- Abutment tooth, crown-to-root ratio for, 169
- Acquiring information, 4–6
- The Aesthetic Zone, 87
- American College of Prosthodontists (ACP), 29
- American Dental Association
 - Center for Evidence-Based Dentistry, 5, 6
 - on clinical recommendations, 4
 - on Evidence-Based Practice, 3
 - on systematic review, 4
- AMSTAR, 6
- Ankylosis of teeth in cleidocranial dysplasia, 238
- Anterior-posterior spread, 187
- Anterior teeth rehabilitation
 - combination of complete and partial coverage restorations (case 14), 92–96
 - answers, 95
 - case story, 92, 92f
 - clinical decision-making determining factors, 93
 - clinical findings/problem list, 93
 - dental history, 93
 - diagnosis, 93
 - learning goals and objectives, 93
 - medical history, 93
 - medications and allergies, 93
 - photographs
 - central and lateral incisors after removal of existing restorations, 98f
 - final restorations, 99f
 - lingual view of prepared teeth, 99f
 - preparations, 99f
 - pretreatment, central and lateral incisors, 98f
 - pretreatment maxillary occlusal view, 98f
 - pretreatment presentation, 98f
 - questions, 100–101
 - review of systems, 99
 - significant extraoral findings, 99
 - significant soft tissue findings, 99
 - social history, 99
 - requiring orthodontic extrusion (case 16), 104–107
 - answers, 107
 - case story, 104, 104f
 - clinical decision-making determining factors, 105
 - dental history, 104
 - diagnosis, 105
 - learning goals and objectives, 104
 - medical history, 104
 - medications and allergies, 104
 - significant soft tissue findings, 93
 - social history, 93
- partial coverage restorations (case 15), 98–102
 - answers, 102
 - case story, 98, 98f, 99f
 - clinical decision-making determining factors, 99–100
 - clinical findings/problem list, 99
 - dental history, 99
 - diagnosis, 99
 - learning goals and objectives, 99
 - medical history, 99
 - medications and allergies, 99
 - photographs
 - central and lateral incisors after removal of existing restorations, 98f
 - final restorations, 99f
 - lingual view of prepared teeth, 99f
 - preparations, 99f
 - pretreatment, central and lateral incisors, 98f
 - pretreatment maxillary occlusal view, 98f
 - pretreatment presentation, 98f
 - questions, 100–101
 - review of systems, 99
 - significant extraoral findings, 99
 - significant soft tissue findings, 99
 - social history, 99

photographs
 orthodontic treatment, 104f
 posttreatment presentation, 104f
 pretreatment presentation, 104f
 questions, 106–107
 review of systems, 104
 significant clinical findings/problem list, 105
 significant soft tissue examination findings, 105
 social history, 104
 Application of knowledge, 6
 Appraisal of evidence/information, 6
 Asking the “right” question, 3–4
 Assessment, 6
 Attrition, tooth wear and, 139, 148

B

Belfast-Hamburg approach, to cleidocranial dysplasia treatment, 238
 Biomechanical characteristics of natural tooth, 213
 Bleaching, 87–88
 Bone grafts, for residual ridge enhancement, 30
 Bone loss, with tooth-implant connected prostheses, 213, 214
 Bone type classification, 17
 Bulimia (case 34), 224–228
 answers, 228
 case story, 224, 224f
 charting, 225f
 clinical decision-making determining factors-226, 225
 clinical findings/problem list, 224–225
 diagnosis, 225
 learning goals and objectives, 224
 medical history, 224
 medications and allergies, 224
 photographs
 full mouth radiographs, 226f
 panoramic radiograph, 226f
 preop left side, 224f
 preop presentation, 224f
 preop right side, 224f
 questions, 226–228
 radiographic findings, 226f
 social history, 224

C

Candidiasis, 24, 126
 Canine transposition. *See* Maxillary canine transposition (case 18)
 Cantilever length, 187
 Cardiovascular disease, association with periodontal disease, 169

Caries
 in chronic methamphetamine users, 232
 plaque buildup and, 225
 as sequela to xerostomia, 169
 CASP (Critical Appraisal Skills Programme), 6
 CBVT (cone beam volumetric tomography), 193
 CCD. *See* Cleidocranial dysplasia (CCD)
 Cementable fixed prostheses, implant-supported (case 31), 206–210
 Center for Evidence-Based Dentistry, American Dental Association, 5, 6
 Central incisor. *See* Fractured central incisor
 Centre for Evidence-Based Dentistry, 6
 Ceramic crown
 combination of complete and partial coverage restorations (case 14), 92–96
 for fractured central incisor, 86–88
 shade selection and color matching, 88
 Cleidocranial dysplasia (CCD)
 inheritance of, 238, 243
 treatment of an adolescent patient (case 36), 236–240
 answers, 240
 case story, 236, 236f
 charting, 237f
 clinical decision-making determining factors, 238
 dental history, 237
 diagnosis, 237
 learning goals and objectives, 236
 medical history, 237
 medications and allergies, 237
 photographs
 mandibular occlusal, 236f
 maxillary occlusal, 236f
 right, left, and maximum intercuspation), 236f
 questions, 239–240
 radiographic findings, 237f
 review of systems, 237
 significant soft tissue examination findings, 237
 treatment of an adult patient (case 37), 242–246
 answers, 245
 case story, 242, 242f
 charting, 243f
 clinical decision-making determining factors, 243–244
 dental history, 242–243
 diagnosis, 243
 learning goals and objectives, 242
 medical history, 242
 medications and allergies, 243

photographs
 mandibular occlusal, 242f
 maxillary occlusal, 242f
 panoramic radiograph, 242f
 right, left, and maximum intercuspation, 242f
 questions, 244–245
 review of systems, 243
 significant clinical findings/problem list, 243
 significant soft tissue examination findings, 243
 Clinical recommendation, ADA position on, 4
 Cochrane Library, 5
 Cohort studies, 5, 5f
 Color matching
 for ceramic crowns, 88
 for porcelain laminate veneer (PLV), 75, 81, 88
 Combination syndrome, patient with (case 3), 22–26
 answers, 26
 case story, 22, 22f
 charting, 23f
 clinical decision-making determining factors, 23–24
 clinical findings/problem list, 23
 dental history, 23
 diagnosis, 23
 learning goals and objectives, 23
 medical history, 23
 medications and allergies, 23
 photographs
 final artificial tooth arrangement and try-in, 22f
 preop, 22f
 preop maxilla, 22f
 questions, 24–25
 review of systems, 23
 significant soft tissue examination findings, 23
 social history, 23
 syndrome characteristics, 24
 Computed tomography (CT), 193
 Cone beam volumetric tomography (CBVT), 193
 Critical Appraisal Skills Programme (CASP), 6
 Crowding, multidisciplinary approach to severe
 (case 17), 110–115
 answers, 114
 case story, 110, 110f
 charting, 111, 111f
 clinical decision-making determining factors, 112
 clinical findings/problem list, 111
 diagnosis, 112
 learning goals and objectives, 111
 medical history, 111
 photographs
 preop left side, 110f
 preop mandible, 110f

 preop maxilla, 110f
 preop presentation, 110f
 preop right side, 110f
 questions, 113–114
 radiographic findings, 112f
 review of systems, 111
 significant intraoral examination findings, 111
 Crown. *See* Ceramic crown
 Crown height, increasing, 105
 Crown-to-root ratio for abutment tooth, 169
 CT (computed tomography), 193

D

Dentures

 conventional complete denture prostheses (case 1),
 10–14
 implant-retained removable partial denture prosthesis
 (case 6), 40–44
 implant-supported fixed complete denture
 prostheses (case 27), 180–183
 overdenture
 ectodermal dysplasia (case 8), 54–58
 edentulous patient with two-implant-retained
 mandibular overdenture (case 2), 16–20
 10-year probability of survival for fixed partial
 dentures, 148
 Discoloration, reasons for, 87
 “Dowel Dilemma,” application of PICO format to, 4,
 5–6
 Dry mouth, 126, 230, 232

E

EBP. *See* Evidence-Based Practice (EBP)
 Ectodermal dysplasia (ED)
 hypohidrotic, 55
 implant-retained removable prostheses (case 9),
 60–64
 answers, 64
 case story, 60, 60f–61f
 clinical decision-making determining factors,
 61–62, 62f
 clinical findings/problem list, 61
 dental history, 61
 diagnosis, 61
 learning goals and objectives, 61
 medical history, 61
 photographs
 computerized tomography, 61f
 front view, 60f
 implants placed in the mandible, 62f
 mandibular arch during treatment, 62f

- mandibular occlusal view, 61f
- maxillary and mandibular prostheses, 62f
- maxillary occlusal view, 60f
- panoramic radiograph, 61f
- posttreatment front view, 62f
- side view, 60f
- surgical placement of implants, 62f
- questions, 63
- radiographic findings, 61f
- multidisciplinary approach (case 10), 66–71
 - answers, 70
 - case story, 66, 66f
 - clinical decision-making determining factors, 67–68
 - clinical findings/problem list, 67
 - dental history, 67
 - diagnosis, 67
 - learning goals and objectives, 66
 - medical history, 66
 - photographs
 - before and after change in vertical dimension of occlusion, 69f
 - cephalometric radiograph—lateral view, 67
 - diagnostic casts, 69f
 - diagnostic wax-up, 68f
 - frontal view, 67f
 - full mouth series radiographs, 68f
 - intraoral guides, 68f
 - maxillary and mandibular occlusal views, 67
 - panoramic radiograph, 67
 - preprosthetic treatment left and right MI, 66f
 - preprosthetic treatment maximum intercuspation (MI), 66f
 - provisional restorations, 69f
 - questions, 69–70
 - radiographic findings, 67, 67f–68f
- overdenture prostheses (case 8), 54–58
 - answers, 57
 - case story, 54, 54f
 - clinical decision-making determining factors, 55–56
 - clinical findings/problem list, 55
 - dental history, 55
 - diagnosis, 55
 - learning goals and objectives, 55
 - medical history, 55
 - photographs
 - panoramic radiograph, 55f
 - periapical radiographs, 55f
 - postop, left side, 56f
 - postop, right side, 56f
 - postop presentation, 56f
 - preop mandible, 54f
 - preop maxilla, 54f
 - preop mounted diagnostic casts, 54f
 - preop presentation, 54f
 - questions, 57
 - radiographic findings, 55, 55f
- Rapp-Hodgkins anhidrotic, 61
- Edentulous patient. *See also* Full mouth rehabilitation; Partially edentulous patient
 - classification system, American College of Prosthodontists (ACP), 29
 - with conventional complete denture prostheses (case 1), 10–14
 - answers, 14
 - case story, 10, 10f
 - clinical decision-making determining factors, 11–12
 - clinical findings/problem list, 11
 - dental history, 10
 - diagnosis, 11
 - extraoral examination, 11
 - learning goals and objectives, 10
 - medical history, 10
 - medications and allergies, 10
 - photographs
 - completed dentures, 12f
 - preop, 10f
 - questions, 12–13
 - review of systems, 10
 - social history, 10–11
 - soft tissue examination, 11
 - with severely atrophic mandible (case 4), 28–32
 - answers, 32
 - case story, 28, 28f
 - clinical decision-making determining factors, 29–30
 - dental history, 28
 - diagnosis, 29
 - learning goals and objectives, 28
 - medical history, 28
 - medications and allergies, 28
 - photographs
 - panoramic radiograph, 29f
 - pretreatment mandible, lateral view, 28f
 - pretreatment mandible, occlusal view, 28f
 - questions, 30–31
 - radiographs, 29f
 - review of systems, 28
 - significant clinical findings/problem list, 28
 - significant soft tissue examination findings, 28
 - social history, 28
 - with two-implant-retained mandibular overdenture (case 2), 16–20
 - answers, 20

- case history, 16, 16f
- case story, 16
- clinical decision-making determining factors, 17
- clinical findings/problem list, 17
- dental history, 16
- diagnosis, 17
- learning goals and objectives, 16
- medical history, 16
- medications and allergies, 16
- photographs
 - postop, 18f
 - preop, 16f
- questions, 18–19
- review of systems, 17
- significant soft tissue examination findings, 17
- social history, 17
- Endodontics
 - implant therapy *versus* endodontic therapy (case 24), 160–164
 - answers, 163
 - case story, 160, 160f
 - clinical decision-making determining factors, 161–162
 - clinical findings/problem list, 161
 - diagnosis, 161
 - learning goals and objectives, 161
 - medical history, 161
 - photographs
 - panoramic radiograph, 161f
 - preop left side, 160f
 - preop maxilla with existing provisional, 160f
 - preop presentation, 160f
 - preop right side, 160f
 - questions, 162–163
 - radiographic findings, 161f
 - management of endodontically treated teeth (case 25), 166–172
 - answers, 172
 - case story, 166, 166f
 - charting, 168f
 - clinical decision-making determining factors, 168–169
 - clinical findings/problem list, 168
 - dental history, 167
 - diagnosis, 168
 - learning goals and objectives, 167
 - medical history, 167
 - medications and allergies, 168
 - photographs
 - preop full mouth radiographs, 167f
 - preop panoramic radiograph, 166f
 - radiographs of mandibular left posterior dentition, 167f
 - questions, 169–171
 - review of systems, 168
 - significant extraoral examination findings, 168
 - significant soft tissue examination findings, 168
 - social history, 168
 - retreatment, success rate after, 175
 - survival rate after treatment followed by coronal restoration, 175
 - Erosion, tooth wear from, 139, 156
 - Evidence-Based Dentistry* (journal), 6
 - Evidence-Based Practice (EBP), 3–6
 - description of, 3
 - process steps
 - step 1 (Ask), 3–4
 - step 2 (Acquire), 4–6
 - step 3 (Appraise), 6
 - step 4 (Apply), 6
 - step 5 (Assess), 6
 - therapy question, evidence structure for, 4, 5f
 - Exostoses, 148
 - Extractions, prognostic indicators for strategic in full mouth rehabilitation (case 26), 174–178
 - Extrusion. *See* Orthodontic extrusion
- F**
 - Ferrule, defined, 162
 - Florid cemento-osseous dysplasia (FCOD) (case 5), 34–38
 - answers, 38
 - case story, 34, 34f–35f
 - clinical decision-making determining factors, 36
 - clinical findings/problem list, 36
 - dental history, 36
 - diagnosis, 36
 - learning goals and objectives, 36
 - medical history, 36
 - photographs
 - maxillary and mandibular occlusal views, 35f
 - maxillary prosthesis, 36f
 - panoramic radiograph, 35f
 - patient profile throughout treatment, 36f
 - periapical radiographs, 35f
 - posttreatment front view, 36f
 - pretreatment front view, 34f
 - pretreatment maximum intercuspation, 34f
 - pretreatment side view, 34f, 35f
 - prosthesis remounted, 36f
 - questions, 37
 - radiographic findings, 35f, 36

- Fractured central incisor
 mild (case 11), 74–78
 answers, 77
 case story, 74, 74f
 clinical decision-making determining factors, 75–76
 clinical findings/problem list, 75
 dental history, 75
 diagnosis, 75
 extraoral examination, 75
 learning goals and objectives, 75
 medical history, 75
 medications and allergies, 75
 photographs
 porcelain laminate veneer, 74f
 porcelain laminate veneer intraoral, 74f
 porcelain laminate veneer on the master cast, 74f
 prepared right central incisor, 74f
 pretreatment view, 74f
 questions, 76–77
 review of systems, 75
 social history, 75
 soft tissue examination, 75
 moderate (case 12), 80–84
 answers, 83
 case study, 80, 80f
 clinical decision-making determining factors, 81
 dental history, 80–81
 diagnosis, 81
 learning goals and objectives, 80
 medical history, 80
 medications and allergies, 81
 photographs
 bonding surface should be equal to or exceed the amount of tooth structure being replaced, 80f
 final restoration, 80f
 preop class IV fracture maxillary right central incisor, 80f
 questions, 82–83
 review of systems, 81
 significant extraoral findings, 81
 significant soft tissue findings, 81
 social history, 81
 severe (case 13), 86–90
 answers, 89
 case story, 86, 86f
 clinical decision-making determining factors, 87–88
 clinical findings/problem list, 87
 dental history, 87
 diagnosis, 87
 learning goals and objectives, 87
 medical history, 87
 medications and allergies, 87
 photographs
 core buildup and preparation of fractured teeth; finish line is a deep chamfer, 86f
 final restorations, 86f
 pretreatment fractured right lateral and central incisors, 86f
 provisional restorations, 86f
 questions, 88–89
 review of systems, 87
 significant extraoral findings, 87
 significant soft tissue findings, 87
 social history, 87
 Fricative sounds, 11, 120
 Full mouth rehabilitation
 combination of implant and tooth-supported
 fixed and removable prostheses (case 33), 218–222
 answers, 221
 case story, 218, 218f
 clinical decision-making determining factors, 219–220
 clinical findings/ problem list, 219
 dental history, 219
 diagnosis, 219
 learning goals and objectives, 219
 medical history, 219
 photographs
 final prostheses, 220f
 impression copings in place, 220f
 maxillary milled bars, 220f
 panoramic radiograph, 219f
 posttreatment front view, 220f
 pretreatment left and right sides, 218f
 pretreatment occlusal and front views, 218f
 questions, 220–221
 radiographic findings, 219, 219f
 combination of implant and tooth-supported fixed prostheses (case 32), 212–216
 answers, 215
 case story, 212, 212f
 clinical decision-making determining factors, 213–214
 clinical findings/problem list, 213
 dental history, 212
 diagnosis, 213
 learning goals and objectives, 212
 medical history, 212

- photographs
 - abutment try-in, 214f
 - diagnostic wax-up, 214f
 - maxillary and mandibular master casts, 214f
 - periapical radiographs, 213f
 - posttreatment front view, 214f
 - pretreatment front view, 212f
 - pretreatment left and right views, 212f
 - provisional prostheses, 214f
- questions, 214–215
- radiographic findings, 213, 213f
- implant-supported, cementable fixed prostheses
 - (case 31), 206–210
 - answers, 209
 - case story, 206, 206f
 - clinical decision-making determining factors, 207
 - clinical findings/problem list, 207
 - dental history, 206
 - diagnosis, 207
 - learning goals and objectives, 206
 - medical history, 206
 - photographs
 - full mouth series of radiographs, 207f
 - maxillary and mandibular abutments in place, 208f
 - metal try-in, maxillary, front, and mandibular views, 208f
 - posttreatment front view, 208f
 - pretreatment front view, 206f
 - pretreatment mandibular occlusal view, 206f
 - pretreatment maxillary occlusal view, 206f
 - questions, 208–209
 - radiographic findings, 207f
- implant-supported, screw-retained prostheses
 - (case 30), 200–203
 - answers, 202
 - case story, 200, 200f
 - clinical decision-making determining factors, 201–202
 - clinical findings/problem list, 201
 - dental history, 200–201
 - diagnosis, 201
 - learning goals and objectives, 200
 - medical history, 200
 - photographs
 - posttreatment left and right side views, 201f
 - posttreatment mandibular occlusal view, 201f
 - posttreatment maxillary occlusal view, 201f
 - pretreatment front view, 200f
 - pretreatment left and right, 200f
 - questions, 202
 - radiographic findings, 201
- implant-supported prostheses (case 28), 186–190
 - answers, 190
 - case story, 186, 186f
 - clinical decision-making determining factors, 187–188
 - clinical findings/problem list, 187
 - dental history, 186
 - diagnosis, 187
 - learning goals and objectives, 186
 - medical history, 186
 - photographs
 - postop mandible, 188f
 - postop maxilla, 188f
 - postop presentation, 188f
 - preop mandible, 186f
 - preop maxilla, 186f
 - preop panoramic radiograph, 187f
 - preop presentation, 186f
 - questions, 188–189
 - radiographic findings, 187f
- implant-supported prostheses (case 29), 192–197
 - answers, 196
 - case story, 192, 192f
 - clinical decision-making determining factors, 193–195
 - dental history, 192
 - diagnosis, 193
 - learning goals and objectives, 192
 - medical history, 192
 - medications and allergies, 192
 - photographs
 - mandibular definitive cast with index, 194f
 - mandibular diagnostic arrangement with index, 194f
 - mandibular impression copings splinted with autopolymerizing acrylic resin material, 194f
 - maxillary definitive cast with index, 194f
 - maxillary diagnostic arrangement with index, 193f
 - maxillary impression copings splinted with autopolymerizing acrylic resin material, 194f
 - postsurgical panoramic radiograph, 193f
 - postsurgical presentation of mandible, 192f
 - postsurgical presentation of maxilla, 192f
 - questions, 195–196
 - radiograph, 193f
 - review of systems, 193
 - significant clinical findings/problem list, 193
 - significant soft tissue examination findings, 193
 - social history, 193

prognostic indicators for strategic extractions
 (case 26), 174–178
 answers, 177
 case story, 174, 174f
 clinical decision-making determining factors,
 175
 clinical findings/problem list, 175
 dental history, 175
 diagnosis, 175
 learning goals and objectives, 175
 medical history, 175
 photographs
 postop presentation, 175f
 preop mandible, 174f
 preop maxilla, 174f
 preop presentation, 174f
 questions, 176–177
 radiographic findings, 175f
 Furcated teeth, retention rates for, 175

G

Golden proportion rule, 120
 Gold restorations, wear of, 140, 148
 Guidelines, 5, 5f

H

Hydrogen peroxide gel, 87

I

Implant-retained removable partial denture (IRRPD)
 prosthesis (case 6), 40–44
 answers, 44
 case story, 40, 40f
 charting, 41f
 clinical decision-making determining factors, 41–42,
 42f
 dental history, 41
 diagnosis, 41
 learning goals and objectives, 41
 medical history, 41
 medications and allergies, 41
 photographs
 design of removable partial denture, 42f
 implant-retained removable partial denture, 40f
 posttreatment maxilla with implant-retained
 removable partial denture, 40f
 posttreatment smile, 40f
 removable partial denture framework, 42f
 questions, 43–44
 review of systems, 41
 significant clinical findings/problem list, 41

significant soft tissue examination findings, 41
 social history, 41
 Implant-retained removable prostheses
 ectodermal dysplasia (ED) (case 9), 60–64
 partial denture (IRRPD) prosthesis (case 6), 40–44
 Implant-supported fixed complete denture prostheses
 (case 27), 180–183
 answers, 183
 case story, 180, 180f
 clinical decision-making determining factors, 181
 clinical findings/problem list, 181
 dental history, 181
 diagnosis, 181
 learning goals and objectives, 180
 medical history, 181
 photographs
 mandibular prosthesis intaglio surface, 181f
 mandibular prosthesis intraoral view, 181f
 panoramic radiograph, 180f
 posttreatment intraoral front view, 181f
 pretreatment front intraoral view, 180f
 pretreatment front view, 180f
 questions, 182
 radiographic findings, 180f, 181
 social history, 181
 Implant-supported prostheses
 cementable fixed prostheses (case 31), 206–210
 combination of implant and tooth-supported
 fixed and removable prostheses (case 33),
 218–222
 combination of implant and tooth-supported fixed
 prostheses (case 32), 212–216
 fixed complete denture prostheses (case 27),
 180–183
 full mouth rehabilitation (case 28), 186–190
 full mouth rehabilitation (case 29), 192–197
 screw-retained prostheses (case 30), 200–203
 Implant therapy *versus* endodontic therapy (case 24),
 160–164
 answers, 163
 case story, 160, 160f
 clinical decision-making determining factors,
 161–162
 clinical findings/problem list, 161
 diagnosis, 161
 learning goals and objectives, 161
 medical history, 161
 photographs
 panoramic radiograph, 161f
 preop left side, 160f
 preop maxilla with existing provisional, 160f

preop presentation, 160f
 preop right side, 160f
 questions, 162–163
 radiographic findings, 161f
 Impression, accuracy of, 194
 IRRPDs (implant-retained removable partial dentures)
 (case 6), 40–44

J

Jerusalem approach, to cleidocranial dysplasia
 treatment, 238
Journal of Evidence-Based Dental Practice, 6

M

Malocclusion
 pseudo-class III, 139
 worn dentition resulting from (case 21), 138–143
 Mandible, severely atrophic (case 4), 28–32
 Mandibular growth, 62
 Mandibular overdenture, two-implant-retained (case 2),
 16–20
 Maxilla
 canine transposition (case 18), 118–122
 milled-bar retained implant-supported fixed
 prosthesis (case 33), 186–190
 restoration of completely edentulous (case 28),
 186–190
 Maxillary canine transposition (case 18), 118–122
 answers, 122
 case story, 118, 118f
 charting, 119f
 clinical decision-making determining factors, 120
 clinical findings/problem list, 120
 dental history, 118–119
 diagnosis, 120
 extraoral examination, 119
 learning goals and objectives, 118
 medical history, 118
 medications and allergies, 119
 photographs
 postop presentation, 118f
 preop mandible, 118f
 preop maxilla, 118f
 preop presentation, 118f
 questions, 121
 review of systems, 119
 social history, 119
 soft tissue examination, 119
 Maxillary growth, 62
 Maxillary occlusal splint, 140
 Medical Subject Heading (MeSH) database, 6

Metamerism, 81, 93
 Methamphetamine abuse, oral manifestations of
 (case 35), 230–233
 answers, 233
 case story, 230, 230f
 clinical decision-making determining factors,
 231–232
 clinical findings/problem list, 231
 dental history, 230
 diagnosis, 231
 learning goals and objectives, 230
 medical history, 230
 photographs
 preop left side, 230f
 preop mandible, 230f
 preop maxilla, 230f
 preop presentation, 230f
 preop right side, 230f
 provisionalization, 232f
 provisionals left side, 232f
 provisionals right side, 232f
 questions, 232
 radiographic findings, 231f
 Mobility, of osseointegrated implants, 213

N

Natural tooth, biomechanical characteristics of, 213
 Nicotine replacement therapy, 169
 Nystatin, 24

O

Oral hygiene, 225–226, 232
 Orthodontic extrusion
 case 16, 104–107
 contraindications for, 105
 indications for, 105
 Osseointegration, bone type and, 17
 Overdenture
 ectodermal dysplasia (case 8), 54–58
 edentulous patient with two-implant-retained
 mandibular overdenture (case 2), 16–20

P

Partial coverage restorations, anterior teeth
 rehabilitation with
 case 14, 92–96
 case 15, 98–102
 Partially edentulous patient
 with fixed and removable prostheses (case 7), 46–50
 answers, 50
 case story, 46, 46f

- charting, 47f
- clinical decision-making determining factors, 47–48
- clinical findings/problem list, 47
- dental history, 46–47
- diagnosis, 47
- learning goals and objectives, 46
- medical history, 46
- medications and allergies, 47
- photographs
 - preop mandible, 46f
 - preop maxilla, 46f
 - preop presentation, 46f
- questions, 49–50
- review of systems, 47
- significant soft tissue examination findings, 47
- social history, 47
- with implant-retained removable partial denture
 - prosthesis (case 6), 40–44
 - answers, 44
 - case story, 40, 40f
 - charting, 41f
 - clinical decision-making determining factors, 41–42, 42f
 - dental history, 41
 - diagnosis, 41
 - learning goals and objectives, 41
 - medical history, 41
 - medications and allergies, 41
 - photographs
 - design of removable partial denture, 42f
 - implant-retained removable partial denture, 40f
 - posttreatment maxilla with implant-retained removable partial denture, 40f
 - posttreatment smile, 40f
 - removable partial denture framework, 42f
 - questions, 43–44
 - review of systems, 41
 - significant clinical findings/problem list, 41
 - significant soft tissue examination findings, 41
 - social history, 41
- management of consequences (case 20), 130–135
 - answers, 135
 - case story, 130, 130f
 - charting, 132f
 - clinical decision-making determining factors, 132–133
 - dental history, 131
 - diagnosis, 132
 - learning goals and objectives, 131
 - medical history, 131
 - medications and allergies, 131
- photographs
 - preop full mouth radiographs, 131f
 - preop mandible, 130f
 - preop maxilla, 130f
 - preop presentation, 130f
- questions, 133–134
- significant clinical findings/problem list, 132
- strategic extractions, prognostic indicators for in full mouth rehabilitation (case 26), 174–178
- Phonetics
 - fricative sounds, 11, 120
 - sibilant sounds, 11, 120
- PICO format, 4
- Plaque, 225–226
- Porcelain laminate veneer (PLV)
 - color matching/shade selection, 75, 81, 88, 100
 - combination of complete and partial coverage restorations (case 14), 92–96
 - for management of fractured central incisor-mild (case 11), 74–77
 - for management of fractured central incisor-moderate (case 12), 8083
 - postinsertion management of, 75, 100
 - for replacement of composite veneer restorations on anterior teeth (case 15), 98–102
- Posterior support, loss of (case 19), 124–128
 - answers, 128
 - case story, 124, 124f
 - charting, 125f
 - clinical decision-making determining factors, 126
 - clinical findings/problem list, 125
 - dental history, 124
 - diagnosis, 126
 - extraoral examination, 125
 - learning goals and objectives, 124
 - medical history, 124
 - medications and allergies, 125
 - photographs
 - caries, into furcation area of molar, periapical pathology, and root resorption on premolar, 126f
 - panoramic radiograph, 125f
 - periapical pathology and root fracture, 126f
 - preop left side, 124f
 - preop presentation, 124f
 - preop right side, 124f
 - questions, 127
 - radiographic findings, 125f, 126f
 - review of systems, 125
 - social history, 125
- Preload, 181

PRISMA (Preferred Reporting Items for Systemic Reviews and Meta-Analyses) Statement, 6
PubMed, 5, 6

R

Randomized control trials, 5, 5f
Regurgitation, self-induced, 156
Removable partial denture (RPD) prosthesis
 critical steps in fabricating, 48
 implant-retained (case 6), 40–44
Research design, 4, 4t, 5f
Residual ridge resorption, 30
Retracted tongue position, 29–30
Retruded tongue position, 29–30

S

Salivary flow, decreased, 126, 156, 232
Screw-retained prostheses, implant-supported
 (case 30), 200–203
Searching for information, 4–6.
Secondary literature, 6
Shade selection
 ceramic dental restoration, 88
 for porcelain laminate veneer (PLV), 75, 81, 100
Sibilant sounds, 11, 120
Smile, percentage of maxillary incisors displayed in,
 187
Smoking
 association with implant failure, 181
 cessation, 169, 181
Soft drinks, tooth wear and, 139, 154–157
Supernumerary teeth in cleidocranial dysplasia,
 238
Superoxyl, 87
Systematic reviews, 4, 5f

T

Therapy question, evidence structure for, 4, 5f
Tongue position, retracted/retruded, 29–30
Tooth wear
 abrasion, 139
 attrition, 139, 148
 erosion, 139, 156
 generalized severe wear (case 23), 154–158
 localized severe wear (case 22), 146–151
 resulting from dental malocclusion (case 21),
 138–143
 soft drinks and, 139, 154–157
 wear pattern, 139–140, 156
Toronto-Melbourne approach, to cleidocranial dysplasia
 treatment, 238

Transposition. *See* Maxillary canine transposition
 (case 18)

V

Validity, 6
Vertical dimension of occlusion (VDO), 11, 140,
 147–148
Vestibuloplasty, 30
Vomiting, self-induced, 156, 225

W

“Walking” bleach technique, 87
Worn dentition
 generalized severe wear (case 23), 154–158
 answers, 158
 case story, 154, 154f
 charting, 155f
 clinical decision-making determining factors,
 156–157
 dental history, 155
 diagnosis, 156
 learning goals and objectives, 155
 medical history, 155
 medications and allergies, 155
 photographs
 bitewing radiographs, 156f
 pretreatment maximum intercuspation, 154f
 pretreatment occlusal view, 154f
 questions, 157–158
 review of systems, 155
 significant clinical findings/problem list, 155
 significant soft tissue examination findings,
 155–156
 social history, 155
 localized severe wear (case 22), 146–151
 answers, 150
 case story, 146, 146f
 clinical decision-making determining factors,
 147–148
 clinical findings/problem list, 147
 dental history, 147
 diagnosis, 147
 learning goals and objectives, 147
 medical history, 147
 photographs
 postop, 148f
 postop laterotrusive, 149f
 postop left, 149f
 postop panoramic radiograph, 149f
 postop right, 148f
 preop frontal, 146f

INDEX

preop full mouth radiographs, 148f
 preop left, 146f
 preop mandible, 146f
 preop maxilla, 146f
 preop right, 146f
 questions, 149–150
 radiographic findings, 147, 148f
 significant soft tissue examination findings,
 147
 resulting from dental malocclusion (case 21),
 138–143
 answers, 142
 case story, 138, 138f
 clinical decision-making determining factors,
 139–140
 clinical findings/problem list, 139
 dental history, 139

diagnosis, 139
 learning goals and objectives, 139
 medical history, 139
 photographs
 diagnostic wax-up, 138f
 laterotrusive left, 140f
 laterotrusive right, 140f
 postop mandible, 140f
 postop maxilla, 140f
 postop presentation, 140f
 preop mandible, 138f
 preop maxilla, 138f
 preop presentation, 138f
 questions, 141

X

Xerostomia, 126, 169, 232