The Science and Art of

Porcelain Laminate Veneers

Galip Gürel

quintessence books

Highdent laboratory

مرکز تخصصی پروتزهای دندانی

های دنت

طراحی و ساخت انواع پروتزهای دندانی بویژه ایمپلنت

برگزار کننده دوره های آموزشی تخصصی و جامع دندانسازی و ...

با ما همراه باشید ...

WWW.HIGHDENTLAB.COM

The Science and Art of

Porcelain Laminate Veneers

A smile reflects a person's inner self. A sparkling smile in harmony with the lips and face crowns the beauty of that person's character. As each smile is unique to that person, a beautiful smile should be one that is so suitable to the face and character of that particular patient that it appears to be perfectly natural.

Based on scientific fundamentals, each case of esthetic dentistry is a work of art which creates beauty through a diverse and unique combination of skills, with the subtle personal touch of the esthetic dentist to add the finishing touch. The dentist's perception, talent, artistic flare and skills in listening to the specific desires of his or her patient help to create a smile that suits the face and personality of each individual patient. If this were not so, all smiles would only be impersonally constructed prototypes.

Hundreds of scientific references have been used to present to you a book on "evidence-based dentistry". After reading this book, you will have been exposed to numerous comprehensive cases and will have gained access to valuable knowledge on all details of the PLV process.

The Science and Art of

Porcelain Laminate Veneers

Galip Gurel

Quintessence Publishing Co. Ltd.

London, Chicago, Berlin, Copenhagen, Tokyo, Paris, Barcelona, Milano, Sao Paulo, New Delhi, Moscow, Prague, Warsaw and Istanbul

همیار دندانسازان و دندانپزشکان
لابراتوار دندانسازی های دنت

British Library Cataloguing in Publication Data

Gurel, Galip
The science and art of porcelain laminate veneers
1. Dental ceramics 2. Dental veneers 3. Dentistry - Aesthetic aspects
I. Title
617.6'95

ISBN 1850970602

© 2003 Quintessence Publishing Co. Ltd.

All rights reserved. This book or any part thereof may not be reproduced, stored in a retrieval system, or transmitted in any form or by any means, electronic, mechanical, photocopying, or otherwise, without prior written permission of the publisher.

Illustrations: Dr. Rainer Landsee in collaboration with Zoeller & Karrer, Konstanz, Germany
Lithography: S & T scan, Berlin, Germany
Printing and Binding: Bosch-Druck GmbH, Ergolding, Germany

Printed in Germany

ISBN 1-85097-060-2

instagram.com/high_dent www.highdentlab.com t.me/highdent

Contributors

Jean-Franqois Roulet, Prof. Dr. med. dent.
Ivoclar Vivavent AG
Schaan, Liechtenstein

Claude R. Rufenacht, Dr. med. dent.
Periodontal Prosthesis and Esthetic Dentistry Practice
Geneva, Switzerland

Stephen J. Chu, DMD, MSD, CDT, MDT
Director, Advanced Program in Aesthetic Dentistry
Clinical Associate Professor
Department of Implant Dentistry
New York University College of Dentistry
New York, USA

Korkud Demirel
Professor of Periodontology
Department of Periodontology
School of Dentistry
University of Istanbul
Istanbul, Turkey

Frank Celenza Jr, DDS
Orthodontist, Periodontist
Clinical Associate Professor
New York University, College of Dentistry
New York, USA

Cathy Jameson, PhD
President and CEO of Jameson Management, Inc.
Davis, Oklahoma, USA

To Berna and Ali

Foreword

Not that long ago dentists were mostly relied upon for the relief of pain and the restoration of decayed teeth. Everyone dreaded a trip to the dentist. A visit was associated with pain and one frequently left the office with teeth filled with silver amalgam, the generic restoration available at the time.

Esthetics, such an integral part of our lives today, was barely at the periphery of dental concerns. There were, of course, a handful of dentists who exercised the available esthetic dental options, but these options were time consuming, expensive and, unfortunately, frequently unattractive.

Change was inevitable. Awakened to beauty by the media, the public became aware of the importance of a beautiful smile. The dental profession, conscious of this growing demand, began a search for cosmetic restorations. Change came gradually. Many techniques and materials were tried and discarded. Progress was halting, often two steps forward and one step back.

1970 saw our first major breakthrough. Tooth bonding, a technique that rapidly, painlessly and much less expensively madeteeth cosmetically beautiful, was born. Bonding, however, as extraordinary as it was, had a much greater effect on the dental profession than its originators ever imagined. It was a catalyst to a revolution. Dentistry would be changed forever. Bonded bridges, porcelain laminates and, infinitely stronger and more stable, all-porcelain crowns were just its immediate derivatives. Beyond that the profession expanded its perimeters.

Improvements in maintaining teeth both endodontically and periodontically were enhanced. Missing teeth were no longer automatically replaced with removable dentures - implants often rendered dentures unnecessary. A new era had arrived - a revolution in patient care with no end in sight.

And that is why this book is so valuable and important. It has circumscribed this revolution and detailed all the important changes that have occurred in our profession.

Nonetheless, my rationale for this foreword is not my appreciation of the book, but my respect for its author and his accomplishments. Dr. Galip Gurel, involved in a profession whose values were noble but antiquated, has in a relatively short time span changed Turkish dentistry.

Esthetic dentistry, although flourishing elsewhere, was unknown in Turkey. Dr. Gurel left his homeland to learn these revolutionary techniques,

but beyond learning them, he mastered them. He is currently lecturing and teaching dentists all overthe world and his modem office is improving smiles daily. His efforts, beyond bolstering his reputation, have not only elevated the prestige of Turkish dentistry but have paved the way for recognition and appreciation of Turkey all over the world.

It was a monumental task Dr. Galip Gurel undertook, and after reading his book I find he has completed it exceptionally well, and I am certain that everyone who reads it will both appreciate and benefit from it.

Irwin Smigel, DDS

Acknowledgements

I have found that it is impossible truly to appreciate just how difficult it is to write a book. In fact, I now believe that only the writer, their family and those people of their inner circle can fully understand this daunting task. When I decided to undertake writing this book, I did not know how demanding and time-consuming a task it would be. The more that I researched, the deeper I was drawn into the material, and as I was drawn into it this incredible well of knowledge opened before me. It was actually difficult finally to stop myself and to filter through it all, while adding my own experiences and clinical work along with the photos and drawings to complete this book. The final task of arranging all this in the most presentable way possible in order to make it more readable for my colleagues was my most challenging undertaking. The key to this achievement was undoubtably the successful teamwork throughout this project.

To start with, I must thank my wife Berna and my son Ali for supporting me in everything that I have ever done until now. However, I want especially to thank them for their exceptional patience during my absences over the last 18 months and for the love and understanding that they have shown to me throughout the preparation of this book.

In loving memory, I would like to express my graditudeto my grandmother Tomi, who has passed away, but remains the most influential person in my life. She brought me up and laid the foundation for all that I have accomplished in my life. My only regret is that she is not here to share this moment with me.

I am eternally grateful to my mother Gungbr and my father Gultekin Gurel, my idols in the dental profession, whom I may not have been able to choose as my parents but who proved to be the greatest gift God could have given me, and who were not only the driving force in my choice of this profession but the foundations of my hard working, honesty and happiness.

I must of course extend my thanks to my dearest brother Gurcan and his family, every one of my patients, my friends and my associates for their tolerance and understanding during my obession with this book.

Being a private practitioner and lecturing all over the world, the task of writing a book that requires a lot of scientific research and clinical work to support. It could not have been accomplished without the help of my associates, who were of great assistance and support in every way. I would therefore like to extend my gratitude to those associates who have been involved in each case and who have worked closely together with me for years. I would especially like to thank Dr. Kubel Iltan, Dr. Birgul Yerusalmi and

Acknowledgements

Dr. Talin Qitak for their limitless assistance, dedication and patience. I am also grateful to Dr. Ipek Cenkgiler, Dr. Elif Ay and Dr. Elif Ozcan for their sincere efforts and support.

Dentistry, and especially esthetic dentistry, requires a solid team effort and it is for this reason that I have tried to share with you the smallest possible details about every aspect of esthetic dentistry. I have been very lucky to have many valuable colleagues, each a star in their specialty, who have made time in their extremely demanding professional lives to share with us the details of their techniques in their contributions to this book. I cannot thank each of them enough for their work in summarizing, as they have for us, their areas of specialty, which are very complex and broad topics. I have had the honor of the contributions of Prof. Dr. Roulet on adhesion, Dr. Claude Rufenacht on occlusion, Dr. Stephen Chu on color, Dr. Korkud Demirel on periodontology, Dr. Frank Celenza on orthodontics and Cathy Jameson on patient education. I cannot thank my colleagues enough for their work in making each of their specialties so pleasing and clear for us to read.

My everlasting thanks go to my dear Nancy Barlas and Laura K. Franklin, who with their knowledge and effort and unfailing drive worked with me to edit my texts into a more easily readable and understandable state.

It is impossible to separate prosthodontics from the lab technician and especially so in a book on PLVs, as each case I have shared with you ultimately is the product of a ceramic specialist. I would like to thank the ceramists with whom I work in great harmony every day in my daily practice and who have discussed each of the cases with me. These valuable colleagues and their teams deserve my sincere thanks: Gerard Ubassy, Jason Kim, Michael Magne, Adrian Jurim and Hakan Akbayar.

I am particularly grateful to my assistant Sinan Yildirim for all his wonderfully supportive technical assistance and to my secretaries Nalan Ince and Sevtap, and to my clinical assistants, Yasemin, Filiz, Zulfiye, Nurhan and Ayse, who form the backbone of my clinic and who shouldered so much of this production process.

I would like to express my appreciation to Tamer Yilmaz for the wonderful photograph that was used for our cover and to Joelle Imamoglu for her valuable assistance and artistic flare in her design of the cover.

A very special thanks to all my supportive patients and especially those who showed exemplary patience during the photographing of their dental work and allowed me to share these photographs with you for this scientific record.

I am deeply appreciative of Dr. Rainer Landsee for his illustrations that have added so much to this book. I am also grateful to Peter Sielaff and his team for their editing and for their attention to each and every page of this volume.

I am eternally grateful to Horst-Wolfgang Haase, who was the person who originally gave methe idea of writing this book and encouraged meto undertake such a challenging project, and finally to Quintessence for arranging this collaboration.

Dr. Galip Gurel

Preface

The appreciation and pleasure that we all derive from observing anything beautiful is part of basic human nature. A beautiful image conjures positive thoughts and feelings towards someone and also provides that person with a good self-image and gives them self-confidence.

The same applies to a person's spiritual and physical esthetics. I think that the coherence of physical and esthetical appearance, as well as being at peace with oneself, is what is known as "well being". Within the foundation of all these ideas, rather than the exaggeration of artificiality, we aim to achieve a plain, more natural appearance that brings out the innate good thoughts and feelings of humans. As the natural span of life has been prolonged in ourtime, so have changed the concepts of "middle aged", which is now percieved as young, and "old age", which no longer seems old to us. Parallel to this phenomenon are people now in search of a younger, more attractive, dynamic and youthful appearance.

Creative people who are gifted in terms of artistic talents, with a traditional culture enriched by internationally flavored gusto and who sense and enjoy the beautiful details of living, tend to offer other people the opportunity to appreciate pleasures that are hard to explain. This is clearly seen in music, fine arts, fashion and other social activities. The aim is to present these beautiful touches and feelings to people as if they had actually been present in their lives for years.

Just as walking and running are part of man's nature, so is laughter. The most prominent expression of joy even for the blind or deaf is through their laughter. So it only follows that a beautiful smile should accompany this laughter. When we consider "esthetic dentistry" within this framework, a well-planned and beautifully achieved smile is without doubt one of the major elements in the concept of this total image of "well being".

A sparkling smile, in coherence with the lips and face, reflects a person's character and life: a smile, individual to only that person, forever present with them and so natural that it appears always to have been a part of them.

This book was written to help the esthetic dentist in treating unesthetic alignment, color, shape or form of the teeth—in other words, enhancing the smile while enforcing function and occlusion. The book examines porcelain laminate veneers, the most successful non-invasive, prosthodontic application of dentistry in this decade, with all its pros and cons. When designed and delivered properly, PLVs are not only the most sparkling, natural, man-made form of esthetic dentistry but they do not appear in any way to be anything but innate, as if they were always a part of that person and their personality.

Preface

We have used hundreds of scientific references to present to you a book on "evidence-based dentistry". After working for 15 years with my mentors and with other successful dentists from the world of esthetic dentistry, and with the support of their research and help, I have developed some new techniques which I hope will make a contribution to the PLV world - specifically, Chapter 7, which has been designed as an atlas, and the sections involving teeth preparation for APR (Aesthetic Pre-recontouring) and APT (Aesthetic Pre-evaluative Temporaries), which I feel will become a part of all general practitioners' daily applications. I believe minimum tooth preparation is one of the most sensitive steps in PLV applications. I am sure that you will read with great interest about the techniques for nearly 100% accuracy in this process.

Chapters 3,4 and 5, on the important topics of adhesion, color and occlusion, are written by doctors who are unequaled in their field. In addition, the supporting specialties in the periodontic, orthodontic, and patient education chapters were written by specialists in those fields.

The expectations the esthetic dentist has of the lab technician mean that we must fully understand the process of the production of PLVs in the laboratory. Some of the world's foremost ceramists have prepared photographs and illustrations of pressable ceramics, feldspathic refractory die, and platinium foil—all techniques which are clearly explained in Chapters 7, 9, and 10.

After reading this book you will have a very comprehensive and in-depth knowledge of the PLV process. Esthetic dentistry is an "art form", which provides us with a youthful, pleasing, alluring and beautiful smile that can only be achieved through a combination of the esthetic dentist's perception, talent and artistic flare along with theirfull understanding of the patient's desires. Otherwise, all smiles would be the same prototype, with no personalization and character to them.

If you do everything right, no jobs are more rewarding than those of the esthetic dentistry team of dentist, specialist, technician and patient. I wish you all the best for successful clinical work and professional satisfaction.

Dr. Galip Gurel

Contents

Contributors 5

Foreword 7

Acknowledgements 9

Preface 11

1 Esthetic Dentistry 19

Galip Gurel

Definition 19
Ceramics 30
Porcelain Laminate Veneers 32
Porcelain Materials for Veneers 37
The Esthetic Dentist 41
Teamwork 44
Communication 47

2 Smile Design 59

Galip Gurel

Introduction 59
Mid-line 61
Incisal Length 63
Zenith Points 67
Gingival Health and Interdental Embrasures 71
Gingival Levels and Harmony 72
Tooth Axis 75
Interdental Contact Areas (ICA) and Points (ICP) 76
Incisal Embrasures 78
Individual and Collective Tooth Dimensions 79

Tooth Character 86
Shape and Position of the Teeth 90
Color of Teeth 91
Sex, Personality and the Age Factor 93
Gradation 99
Symmetry and Balance 100
Smile Line 101
Conclusion 109

3 Adhesion 113

Jean-Frangois Roulet, Uwe Blunck, RalfJanda

Introduction 113
Substrates 115
Adhesive Technique 120
Product Recommendation for Bonding Veneers 126
The Need for Bonding Ceramics 127
The Benefit of Bonding for Veneers 128
Conclusion 131

4 Porcelain-Bonded Restoration and Function 135

Claude R. Rufenacht

Introduction 135
The Tooth-Porcelain-Bonded Restoration Complex 138
Porcelain-Bonded Restoration and Pulpal Health 139
Occlusion 139
Function 140
Incising 146
Lateral Chewing 148
Dysfunction 150
Conclusion 153

5 Color 157

Stephen J. Chu

Introduction 157
Color 159
Color Perception 165
Contrast Effects 172
Shade Guide Systems 182
Impact of Materials and Material Science on Color 190
Clinical Applications - Ceramic Laminate Veneer Color Matching 198
Clinical Tips for Ceramic Laminate Veneer Shade Selection 203
Conclusion 204

6 Periodontal Considerations in Esthetic Treatment Planning 207

Korkud Demirel, Galip Gurel

Introduction 207
Periodontal Tissues in Health 209
Esthetic Periodontal Problems 216

7 Atlas of Porcelain Laminate Veneers 231

Galip Gurel

Determining the Essentials 231
Pre-Operative Evaluation (Analyzing the Smile) 234
Treatment Planning 236
Composite Mock-up 238
Laboratory Communication 1 239
Aesthetic Pre-recontouring (APR) 243
Aesthetic Pre-evaluative Temporaries (APTs) 246
Actual Material Preparation (AMP) 253
Facial Preparation 258
Gingival Preparation 263
Proximal Preparation 268
Interproximal Preparation 273
Incisal Preparation 277
Lingual Preparation 281
Finishing the Preparation 285
Shade Selection 288
Impression Making 291
Facebow Transfer 296
Bite Registration 297
Provisionals 297
Laboratory Communication 2 302
Try-in 309
Bonding 317
Treating the Interior PLV Surface 318
Adhesive Application 322
Finishing and Polishing 331
Postoperative Longevity 332

8 Failures 345

Galip Gurel

Introduction 345
Esthetic Failures 347
Mechanical Problems 351
Adhesive Problems 352
Failures Due to Internal or External Forces 352

Color Change 356
Glazing and Polishing 357
Aging 357
Micro leakage 358
Margin Preparation 358
Lack of Marginal Fit 359
Tissue Management 360
Isolation 360
Incomplete Polymerization 361
Biological Failures 361
Improper Finishing 363
Occlusal Failures 364
Conclusion 366

9 Porcelain Laminate Veneers for Diastema Closure 369

Galip Gurel

Introduction 369
Technique 373
Cervical and Gingivoproximal Preparation 377
Limits 380
Interproximal Contact Area 380
Lab Procedures with Empress 380
Bonding 389
Details 390

10 Porcelain Laminate Veneers for Tetracycline Discoloration 393

Galip Gurel

Introduction 393
Laboratory Communication 1 395
Laboratory Study Preparation for Laminate Veneers 398
Laboratory Communication 2 407
Conclusion 415

11 Adjunctive Orthodontics, as Related to Periodontics and Aesthetic Dentistry 417

Frank Celenza, Jr.

Introduction 417
Biological Basis for Tooth Movement 419
Basic Appliance Design 423
Adjunctive Tooth Movement as related to Aesthetic Dentistry 426
Orthodontic Retention 439
Conclusion 443

12 Periodontal Treatment and Porcelain Laminate Veneers 445

Galip Gurel, Korkud Demirel

Introduction 445
Crown Lengthening 447
"Gummy Smile" 455
Negative Dental Composition 460
Excessive Soft Tissue Display 462

13 **Special Considerations 465**

Galip Gurel

Introduction 465
Patient Education 467
Laboratory Procedures 479
Reverse Color Gradation 481
Multicolored Teeth 493

14 Patient Education and the Management of Esthetic Dentistry: A Team Approach 497

Cathy Jameson

"Total Care" 497
Practice-Building and Patient-Education Strategies 499
Effective Case Presentations 504
The Use of Visual Aids 511
Financial Options 515
Conclusion 517

Index 519



'Emotions...

'Dear *Dr, Qilrel,

1 had an amazing e?(perience today, I had driven to a business appointment in my city. Once I have arrived and was parked, I dropped the mirror in my car, so that I could check my hair and lipstick to make sure that I was presentable for my meeting.

<<cWhat is so amazing about that?", you may be asking, 'Well, when I looted in the mirr I thought that the person looking at me was pretty, I am thirty-two years old. Other people have espoused my attractiveness, But, until today, I didn't see it. Until today, I had never seen my own reflection and been pleased, 'But, today, I saw a different persom'Today, the person looking bacf^atmein the mirror- me - was pretty.

The only thing that has changed is my smile, you changed my smile, I came to you for a conference about a smile makeover, and you listened to me as I told you how much I disliked my smile and my teeth, you didn't tease me, make fun of me or tell me I was foolish for thinking poorly of my teeth,you simply andcaringly listened, And you performed magic[1],! Or at least that's what it seems like to mel

I love my smile and the porcelain laminate veneers that cover the old teeth and have given my smile a much, needed correction andlift, Ifeelyounger, more confident, more attractive and more self-confident, iHow can I ever thankyou? you have touched me - and my life - in a very special way, I will be forever grateful.

Sincerely,
fr,Arasil

Esthetic Dentistry

Galip Gurel

Definition

"All human desires are in some way related to beauty."[1]

The term "esthetics" is borrowed from the Greek word "aesthesia", which means sensation or sensibility. It can be defined as "belonging to the appreciation of the beautiful". Esthete - the noun form of the same word - may be used to describe a person who enjoys or perceives a pleasant sensation. Similarly, the meaning of the term in adjective form indicates ability to respond to beauty in art or nature.[2] The relation of this term to dentistry has been differentiated from the word "cosmetic", which is derived from the Greek word "kosmos", or adornment. It is further stated that esthetic dentistry enhances the natural beauty of the mouth and face and that the term is used specifically to imply an improved relationship rather than a superficial one.[3]



In dentistry, these phrases can be confusing. By virtue of naming anything "cosmetic", the immediate perception left in the patient's mind is the enhancement of beauty alone. However, the author believes that esthetic or cosmetic dentistry - regardless of the name - serve the same purpose. Through technological advances, it is now possible conservatively to enhance and strengthen the health and function of a patient's appearance and smile. The true understanding of all aspects of comprehensive esthetic/cosmetic dentistry and the integration of the philosophical triad of "health, function and beauty" will assist the dentist in providing optimal dental care.[4] The philosophy of esthetic dentistry can be defined as the process of providing the most convincing natural dentition possible, while maintaining it to the highest of standards.[5] Owing to the vast improvements in dental technology, materials and techniques, most of the procedures that were thought to be primarily cosmetic have been found to be quite durable as well.

In this changing world, the appearance or packaging of everything is important. A pleasing appearance is important not only socially and romantically, but also economically, for it has been found that attractive people tend to get the better jobs.[6] It is no longer a matter of conceit, but rather a necessity to pay close attention to one's appearance not only for the individual's self-confidence but also for the image he or she portrays to others. Studies on self-worth have shown that poor body image is the primary factor in self-rejection. It logically follows that the face - which is the most noticeable part of our whole appearance - has become essential to the patient's overall esthetic appearance (Fig 1-1).[7] The size and the mobility of the mouth make it the most dominant feature of the face, but it is the patient's personality, along with the strength and harmony of the other facial features, that will determine how dominant the mouth will be in the total composition.[8]

The dominance of a dental composition may be amplified by rendering it more visible. Increasing the crown size or/and using lighterteeth, placing them more anteriorly or increasing the exposed gingival length, may produce this effect. It is for that reason that the teeth and smile play a major role in whether we perceive the face of an individual as attractive or not. It is now possible for the esthetic dentist to "beautify" the patient's smile while creating a more "youthful" appearance.

Dentofacial Attractiveness

The importance of dentofacial attractiveness to the psychosocial well-being[9] of an individual has been well established.[10] As an attractive smile has always been the focal point of attention in any esthetic procedure, the esthetic dentist seeks not only to improve the esthetic appearance of the patient, but also to improve the patient's self-esteem.[11] The positive effects of a restoration on the patient's smile, appearance, self-esteem and general mental health should not be underestimated. The influence of a beautiful smile on our overall facial esthetics, well-being and self-image is quite obvious. A display of pleasing intact dentition is the key element in the creation of an attractive smile.[12]

The recognition of these factors and the increase in the number of patients seeking to improve their appearance (Fig 1-2) have compelled the dental profession to address more challenges in esthetic dentistry and to respond to the needs of their patients. The influence of the smile on facial esthetics is well recognized by society. It can be said that "better smiles are being equated with better living". In 1936, *Pilkington* defined dental esthetics as "the science of copying or harmonizing our work with that of nature, making our art inconspicuous".[13]

A beautiful smile seems to reflect a certain style of living, and the enhancement of facial beauty is one of the primary goals of patients seeking elective dental care. The lower one-third of the face has a major impact on the perception of facial esthetics, and the role of a beautiful smile is, therefore, undeniable (Fig 1-3). Once the ideal relationship between the restoration and the facial soft tissues is achieved, improvements in natural beauty can be expected to follow. With the ever-increasing importance that the media, patients, and society in general place on appearance, an

Fig 1-1 The proportional display of naturally arranged teeth always has a positive impact on a beautiful smile.

Fig 1-2a, b (a, b) Patients may present unesthetic as well as unhealthy teeth, With the new advances in materials and techniques it is now possible to treat what was once considered an impossible-looking case, thereby improving the health, esthetics and self-esteem of the patient. An unattractive smile, esthetically enhanced eight years ago. Today's materials allow us to deliver even more natural-looking teeth and smiles.



Fig 1-3a-c Facial esthetics are always related to the anterior dentition of an attractive smile (a), but even an attractive smile can be further improved with the relatively new techniques, like bleaching (Opalescence 20%, Ultradent), (b). Note the difference between the upper and lower teeth (c), and the brighter smile impact on the face.

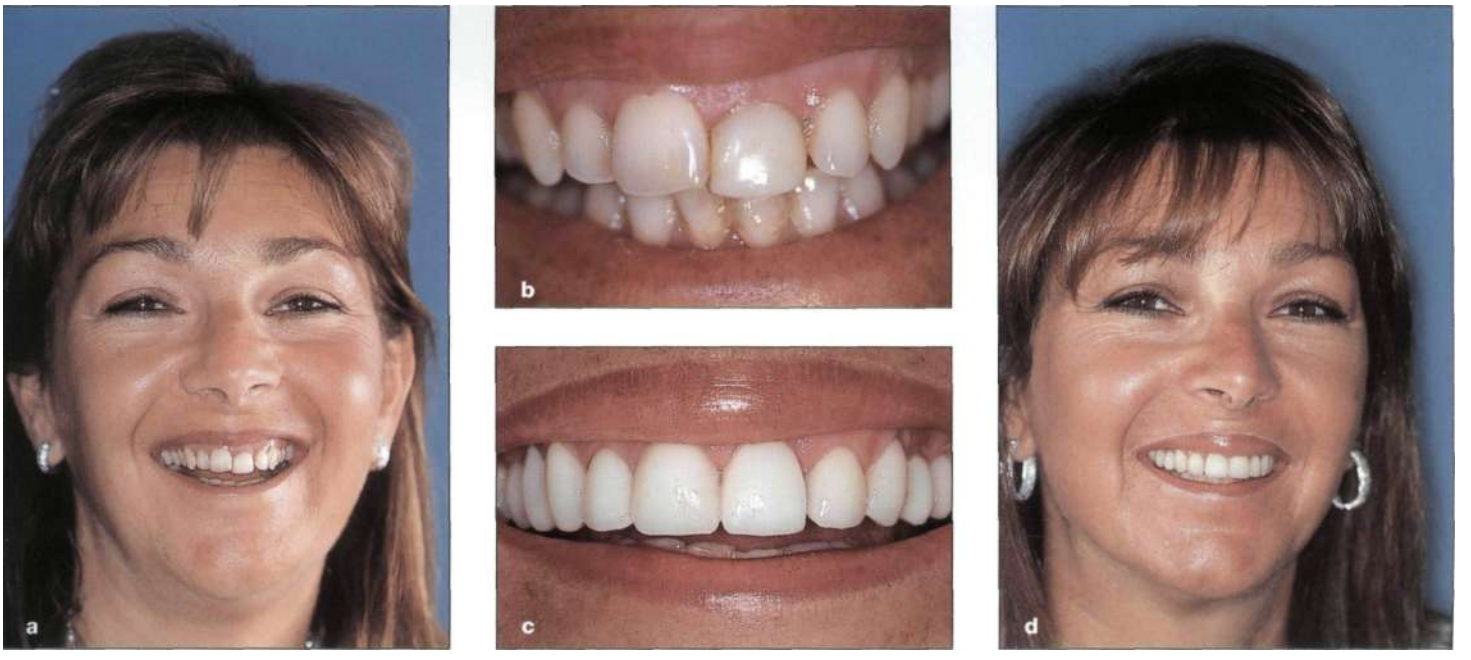

Fig 1-4a-d (a, b) Healthy teeth may be disproportionately aligned and so may not display their optimal esthetic appearance, (c) A new smile design. The irregularities of the soft and hard tissues have been corrected. The dark buccal corridors are eliminated with slightly overcontoured porcelain laminate veneers placed on the premolars. Balance, symmetry and an improved arch form have been successfully achieved.

even greater emphasis is now put on of elective esthetic dentistry. By improving deficient facial proportion and integumental form, surgeons, orthodontists and restorative dentists have the unique opportunity to address these esthetic needs while creating a pleasing smile.[14]

Need for Esthetic Dentistry

As the popularity of esthetic dentistry increases, growing numbers of patients are seeking treatment for the improvement of unesthetic anterior dentition (Fig 1-4).[15] Earlier focus on the mere restoration of carious teeth has shifted to treatment for enhancement of the esthetic appearance of already healthy teeth.[16] The professional approach to dentistry has changed rapidly. The acceleration in dental, ceramic and bonding material development has made conservative tooth preparation and restorative procedures possible that were never imaginable before (Fig 1-5). These new techniques enable the clinician to achieve cosmetic improvements and esthetically pleasing results.[17-20] Dentists are excited about the positive impact a beautiful smile has on the social, psychological and emotional lives of our patients.

New Face or Concept of Dentistry

The entire concept of dentistry has changed dramatically over the last 30 years, and an entirely new era of restorative dentistry has begun. Practice has moved out of the classic era of dentistry, when the extraction of teeth was a common procedure, and has moved into the age of conservative restoration with minimal invasive procedures. These procedures are becoming simpler and even more conservative with every passing day. Less-aggressive tooth preparation will arrive at more predictable results. The more conservative the tooth preparation done, the fewer traumas to the teeth, and the less postoperative discomfort experienced by the patient. As esthetic procedures are generally elective procedures, clinicians should strive to make the experience as pleasant as possible for their patients. The traditional role of the dentist in the past was to correct or repair the teeth and if that

Fig 1-5a-d (a, b) Advances in dental technology now allow the clinician to improve patient appearance with minimally invasive techniques (c, d). Note that all upper and lower dentitions have been treated with porcelain laminate veneers. Even severely decayed teeth (b) can be restored successfully with porcelain laminate veneers: improving health, function and esthetics.

proved to be impossible, to remove them, leaving an older generation of people with partial or even total tooth loss.[21]

Today, the goal to retain all natural teeth intact is achievable. It is now feasible for patients to preserve their teeth through proper maintenance, good oral hygiene, the use of fluoride as a preventive measure against caries and improved restorative materials and techniques. The active preventive measures of the clinicians along with the patients' increased information and knowledge of dental care have increased the lifespan of natural teeth. Today, the dental profession strives not only to preserve healthy teeth with proper function, but also to create and enhance teeth that are esthetically pleasing as well.

Another positive factor in the patient's desire for more esthetic teeth is that by visiting the dentist to seek better appearance in their teeth, they make a trip to the dentist that they would not have made otherwise and therefore benefit by having theirteeth thoroughly examined. This is one of the greatest services we, as healthcare professionals, can provide. Instead of merely imparting information to our patients concerning their oral health, we can now provide enhancement of the quality of their smile. It improves the profession's reputation in the public eye and increases the number of patients who would otherwise not visit the dental office regularly. All of us have encountered patients who have not been to the dentist for several years but suddenly appear in the office because they are interested in "tooth whitening". Once in the office, they can be persuaded to accept other necessary periodontal or restorative treatment.[22] During the actual diagnostic examination that takes place prior to treatment, various problems that would otherwise have remained undetected and untreated can be diagnosed and treated before they become major problems (Fig 1-6).[21]

It was not very long ago that a visit to the dentist was provoked by an emergencysituation, such as a painful tooth or a swollen face. Trips to the dentist were only out of necessity. Frequently, the procedures following these emergency visits were gross restorative solutions. By contrast, recent developments in dentistry have changed these visits to "want-based" treatment.[22,23] Visits to the dentist now tend to be esthetically motivat-

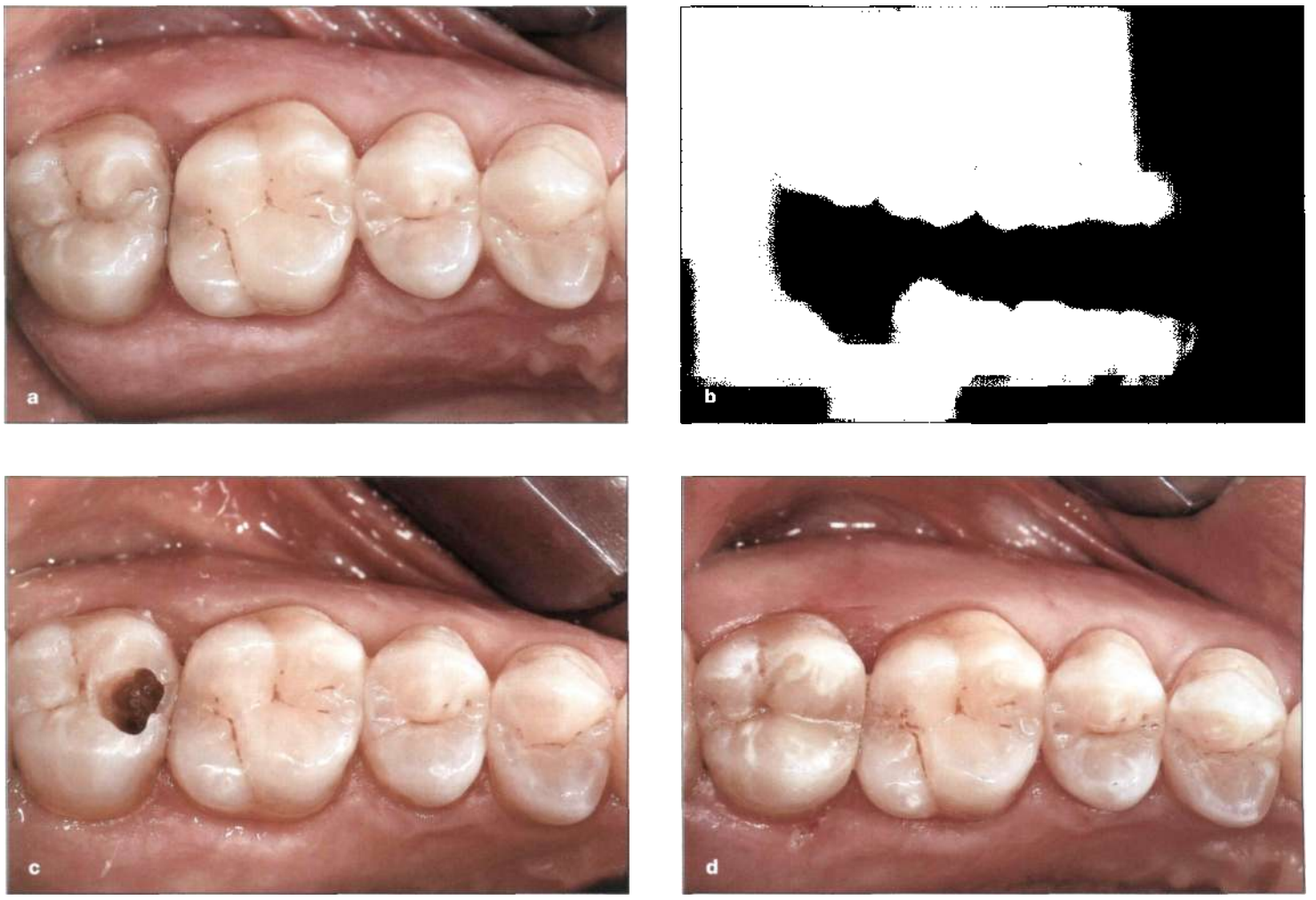

Fig 1-6a-d If the patient does not visit a dentist regularly, defects may remain undetected. Here they are discovered when the patient sought esthetic dental treatment, (a) The patient remains unaware of any interproximal defects, unless pain ensues. As no discoloration is seen on the enamel of tooth #17(2) (b), x-rays are required for detection, (c) Note the extent of the defect and (d) the restored esthetics and function.

ed. Esthetic dentistry has opened an entirely new world for most clinicians, and changed the lives of hundreds of thousands of patients in a positive way.[22] Likewise, the image of dentistry has evolved from one of pain relief and functional restorations, to the sophisticated esthetic perception the profession enjoys today.[24]

During the last decade, a large portion of the treatment protocol of dentists has entailed more and more esthetic dentistry. It is estimated that as many as 50% of individuals seeking dental care are actually seeking esthetic self-improvement.[25] In an esthetic-conscious society, where "beautiful" tends to create the image of someone "good" and "successful", individuals are prepared to invest in the improvement of their teeth and, therefore, their appearance. Not all of these patients require major treatment and some may in fact suffice with routine procedures, such as bleaching, composites and laminate veneers to achieve the desired effect (Fig 1-7). All phases of anatomic and clinical dental practice, including orthodontics, oral surgery, periodontics and prosthodontics, may be involved in the process of esthetic dentistry. It is because these treatments can be performed with minimally prepared teeth that it is possible to enhance the existing healthy oral environment through elective procedures in contemporary esthetic practice.

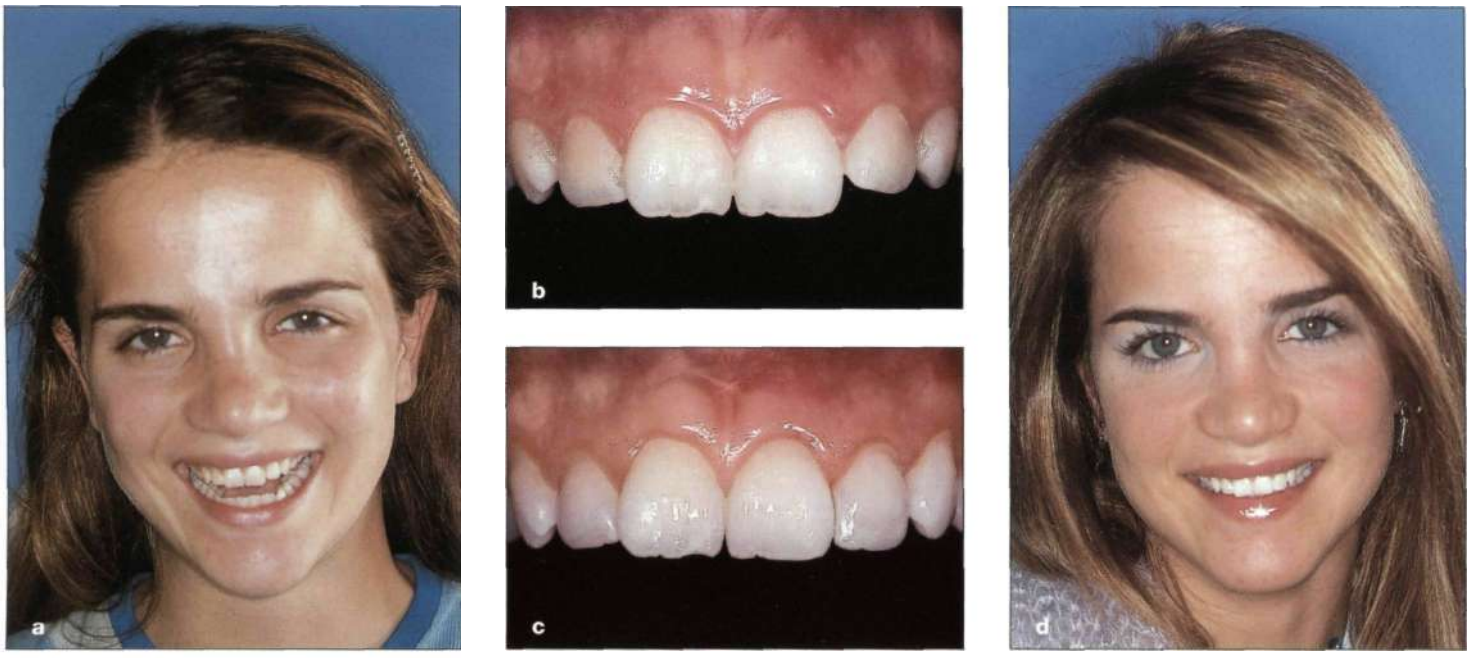

Fig 1-7a-d (a, b) To improve the esthetics, aggressive treatment methods are not always required. A patient complaining about her dark-colored, short teeth, presents requesting esthetic improvement without any invasive techniques, (c) Simple gingival surgery is performed to alter the gingival levels, thereby increasing the length of the short teeth. The teeth are bleached and the protruding maxillary left lateral incisor recontoured and restored with a composite material. Note the change in the length and color of the whole maxillary arch, as well as the change of the form and appearance of left maxillary lateral, (d) Especially for young patients, when the overall facial appearance needs to be improved, such minimal invasive techniques should be utilized. And even with these minimal changes, the whole facial beauty can be tremendously increased.

Subjective Criteria

There is nothing quite as personal as each patient's own perception of esthetics. Numerous factors, such as the region in which the patient lives, the media and fashions to which they are exposed, may all serve to influence their perception of esthetics. However, there are accepted norms by which the dentist is guided when creating an esthetically pleasing smile (see the section on Smile Design). These norms take into consideration the general appearance of the patient, including even such minute details as the specific particulars of a single tooth. However, no matter what the norms are, the preferences of the patient and their own image of theirsmile must be given careful consideration.[26]

When the overall dental appearance is considered, several factors of significance, such as the color, shape, position, quality of the existing restorations, and the general arrangement of the dentition should be noted, especially focusing on the particulars of the anterior teeth. Each factor may be considered individually, but all components must be both compatible and in harmony in order to produce the final esthetic result. Esthetics, as it is perceived today, not only encompasses beauty and harmony but naturalness as well. Consequently, there is no fixed standard and we must recognize that esthetic perception is influenced by the mood of the times and regional differences as well.[27] The difficulty with esthetic judgement is that the objective criteria are not always absolute. Esthetic judgement depends on the subjective feelings and interpretations of the observer, with racial, ethnic and cultural factors playing a significant role (Fig 1-8). Surprisingly enough, despite what most dentists believe, only 30%-40% of adults with nonharmonious teeth are actually unhappy with theirsmiles.[26] Hence, if the patient is comfortable with their existing smile, there may be no reason to change it, even if it is not the "loveliest in the world". Female patients are more likely to seek oral rehabilitation to

Fig 1-8a, b Esthetic judgement rests on subjective criteria depending on racial, ethnic and cultural factors, (a) Gold is still preferred in some parts of the world, (b) A variety of restorative materials can also be used. The missing part of tooth #11(8) is restored with a removable metal restoration.

improve their esthetics than male patients;[28] research shows that nearly 60% of esthetic patients are female.[29-32]

Esthetics and Function

In esthetic approaches, the patient's self-image, personality and personal relationships must be taken into consideration. A successful result is only possible when all of these factors have been included in the evaluation and treatment plan. The expansion of esthetic and cosmetic dentistry has been so extensive that it now encompasses everything related to dental appearance. There is no doubt that the great strides in adhesive materials have broadened the scope of dentistry from what was once a health and function-based practice, to a substantially more esthetic conscious style of dentistry.[33] While striving for finer esthetic appearance, careful attention to the requirements of function is essential.[34]

Therefore, it is the esthetic dentist's responsibility to provide treatment that is esthetically pleasing, functional, as well as biocompatible.[35] Esthetic dentistry is the art of dentistry in its purest form. The purpose is not to sacrifice function, but to use it as the foundation for esthetic treatments.[36] The dentist must strive to achieve final restorations that have a natural appearance and that integrate harmoniously with the proper soft tissue architecture that has been meticulously

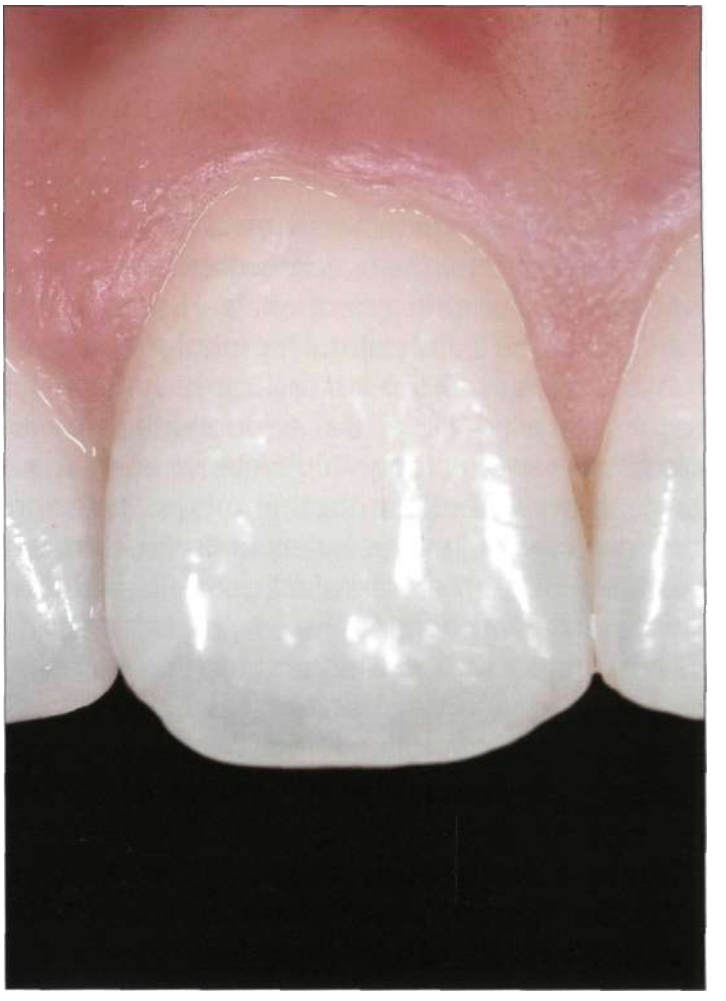

Fig 1-9 Current materials and application knowledge, combined with the artistic abilities of the dentist and laboratory technician, provide restorations that are natural in appearance and integrate harmoniously with the proper soft tissue architecture. It is difficult to differentiate this porcelain laminate veneer restoration from a natural tooth.



Fig 1-10 In the past, the achievement of either esthetics or function required the sacrifice of the other. Whenever function was the predominant requirement, esthetics had to be compromised. Today's materials and treatment approaches permit the clinician to achieve both goals simultaneously.

controlled throughout the restorative procedure (Fig 1-9).

When these requirements are adhered to and the desired relation between esthetics and function is achieved, the patient will feel more beautiful. Adherence to the natural morphologic state of the tooth is a prerequisite for successful esthetic results. Investigations of the functional mechanisms of the stomatognathic system have discovered that respect for tooth morphology and delicate application of a variety of parameters are required in the restorative approach to achieve good occlusion and optimal esthetic results.[37] The materials and techniques must be carefully selected to ensure that the restorations will sufficiently withstand the forces of occlusion and mastication while providing long-term function.[38]

In the past, function and esthetics often acted as two competing components in the restorative process. The overall impression was that whenever function was to be established, esthetics would have to be sacrificed; similarly, when esthetics was of prime importance, function would be compromised. These standards are no longer valid and it is now possible to improve them simultaneously. The esthetic dentist has achieved the finest form of dentistry when these two components are successfully performed in harmony (Fig 1-10), creating restorations that are indistinguishable from the natural dentition.[39]

Personal Expectations

When we observe a person's face we judge the appearance of their smile based on the subjective evaluation of the characteristics we see.[40] The viewer's response to what is seen is actually a psychological response to the interpretation of physiological processes. This is the basic science of visual perception.[41] Whether what they see is perceived as pleasant or unpleasant will be influenced to some extent by cultural factors. As dentists, we are responsible for transforming this visual concept into the appropriate desired esthetic response. Our awareness and perception of the facial features must be continually modified, expanded, and developed.[42]

The anterior oral region and dental esthetics are of universal concern and of primary importance to all dentists. Topographic facial anatomy, which is the study of facial features and characteristics, isthe method by which we recognize and distinguish one individual from another. Every individual has unique facial characteristics, including those of their smiles. According to the definition of esthetics, a smile is something very

Fig 1-11a, b (a) Existing amalgam restorations replaced (b) with porcelain onlays. In the existing restorations, the emphasis was on function, sacrificing the esthetics. Note the crack lines on the amalgam. It is impossible to distinguish the porcelain onlay restorations from natural teeth, which enhances both function and esthetics.

personal, relating directly to that person's facial structure, gender, style, and character. Therefore, when considering esthetic dentistry, patients should never limit themselves to the smile they see in a photograph. Similarly, the esthetic dentist should not be restricted by specific requirements, such as those in the Golden Proportion, but rather consider them as useful guidelines to create a smile that best suits that particular patient's personal appearance (see Chapter 2). The accepted standard of "beauty" in individuals, in any society today, is subject to an incredible amount of influence from magazines, television and ethnic, racial, and environmental surroundings.[9-10] It is necessary to keep a healthy balance between the maintenance of the perfect appearance and a philosophy of life that includes physical and psychological factors.

Effects of Media and Fashion

We are all influenced by those around us. Just as we perceive and recognize a new fashion in clothing, we are also influenced by representations of beauty.[43-45] Television, magazines, motion pictures and other media contribute their daily influence. Therefore, as the perception of beauty is constantly subject to change, the concept of the "ideal" smile does not seem actually to exist.[46-47] However, the esthetic dentist cannot become a reproducer of "trendy" smiles that are subject to the whims of the media and in constant change. Some patients arrive with requests that are impossible to fulfill and it is up to the dentist to present a reasonable treatment approach to arrive at an acceptable and achievable final result. Saying that, the concept of esthetics from the professional aspect of proportion, harmony and beauty should always betaken into consideration; however, the public eye and its perception of beauty and facial esthetics must not be excluded in the attempt to find a reasonable approach in creating a smile that is a natural extension of the patient's inherited facial state. These clinical circumstances may be encountered when a patient arrives with a stack of photographs of the latest models and film actresses or actors and requests a "smile" that will never suit his/her face or personality.

Natural-looking Restorations

The objective in the fabrication of any dental prosthesis is to provide a restoration that fits harmoniously into the facial composition, while hoping to emulate the previously existing teeth, gingiva, mucosa, soft tissue and bone as closely as possible, providing that these components previously existed in esthetic harmony. In an optimal restoration, the observer should not be

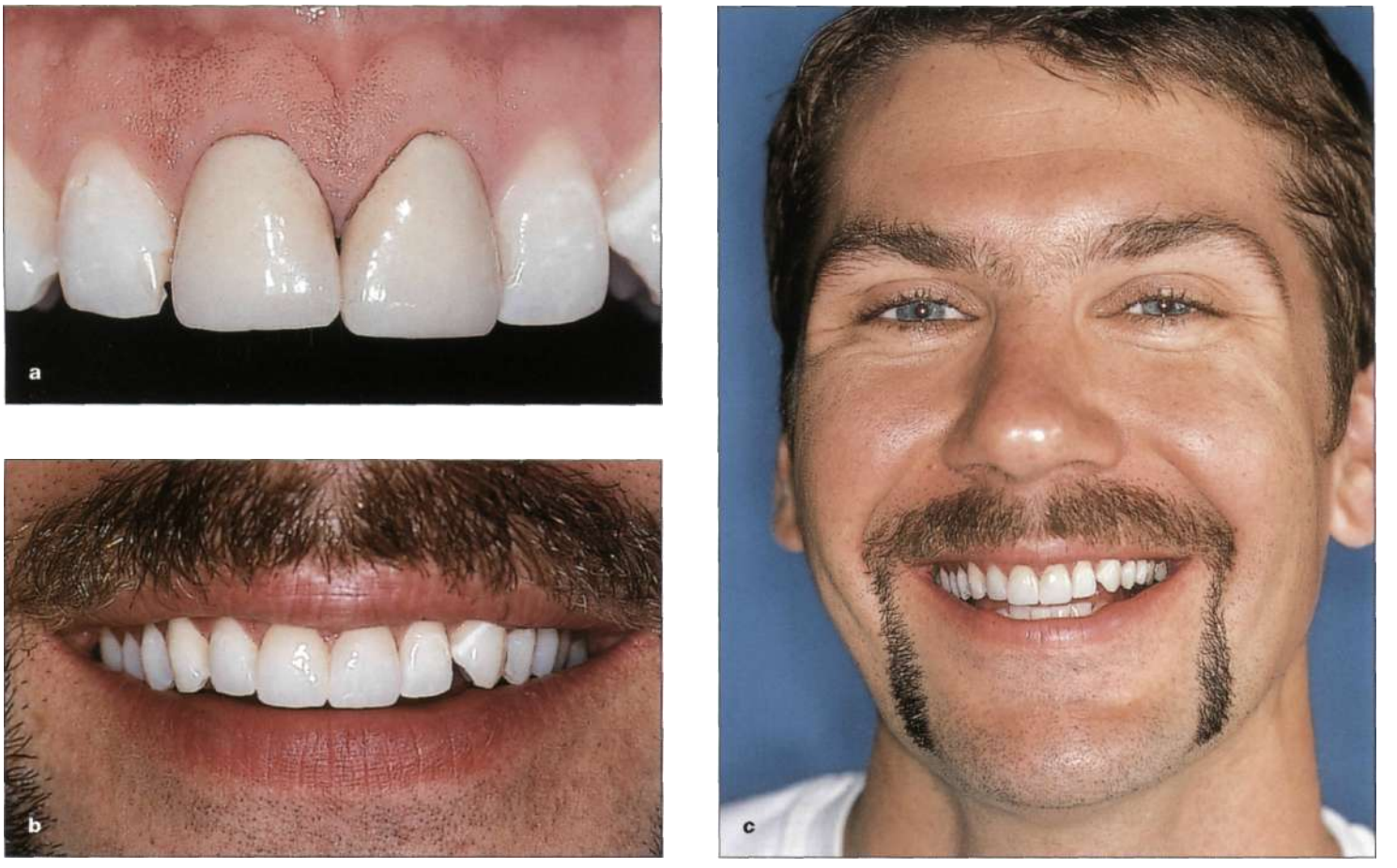

Fig 1-12a-c (a) Iatrogenic factors may affect the smile. Two porcelain-f used-to-metal restorations exhibit an unesthetic appearance, (b) They have been replaced by all-ceramic crowns and the remaining teeth bleached, (c) Even though the asymmetrical gingival levels are not altered, an overall esthetic integration of the crowns into the facial appearance is achieved through the use of correct placement, texture, color and form. In order further to improve the esthetics, the inciso-mesial embrasure of tooth #23(11) could have been closed with a restorative material. However, since the patient has asked to retain his natural-looking smile, it is kept as it is.

able to recognize the presence of a replacement (Fig 1-11). The patient and the observer should perceive the restorative result as entirely natural.[48] The continuing esthetic evolution has fostered a growing need for materials and application techniques that can augmentthe armamentarium for esthetic design. Some patients may complain that their new restorations are not "esthetically pleasing" owing to the fact that their friends or relatives failed to notice their new teeth from "miles away". The reason for this is that we have succeeded in achieving esthetic harmony by adhering to the natural morphologic state. Some patients may go as far as to ask the clinician to spoil this naturally pleasing smile. Therefore, it is essential to keep in mind that "esthetic values" vary not only from nation to nation but from individual to individual as well.[49,50]

The author's philosophy on natural-appearing esthetics is that even if treatment necessitates drastic changes in the dental composition, it should not be obvious to the observer that alterations were made but rather the observer should simply recognize a very positive improvement in the smile and overall facial appearance (Fig 1-12).

Ceramics

The utilization of porcelain as a restorative material began a new era in esthetic dentistry. By today's standards, the early porcelains were rather primitive and of low value. Upon recognition of the potential use of porcelain in esthetic

dentistry, various modifications and enhancements were made to render the material applicable for dental restorations. The history of porcelain follows a specific direction in approach.[51] The first major improvement in esthetic materials, especially in the translucency of all porcelain crowns, was introduced by *Vines* et al. in 1958.[52] He developed porcelain powders suitable for vacuum firing or low-pressure air firing. *Weinstein* et al. first discovered the bonding of porcelain-to-gold alloys by means of vacuum firing in the early 1960s.[53] In addition to these developments, the introduction of gap-graded finer powders, that could be vacuum fired, started a new era in dental esthetics. Owing to the ability to layer and carve porcelain, clinicians and laboratory technicians became more aware of the esthetic significance of light transmission as well as the changes in refractive indices and reflection from opaque porcelains.[54]

In 1965, *McLean* and *Hughes* described sintered alumina that was originally used for the fabrication of crowns, small fixed partial dentures, and individual and custom-built pontics for use in restorative dentistry in the form of prefabricated profiles.[55] Owing to excessive shrinkage, it was impossible to manufacture custom-made high alumina copings for porcelain crowns. The first commercial porcelain was marketed in 1966, and more than 30 years after its introduction porcelain still remains on the market today.[51] In 1968, *MacCulloch,* who first described the methods used for making artificial teeth, veneers and crowns in glass ceramic, utilized this approach.[56] The desired shade modifications, however, were only possible with surface colorants that had a tendency to erode after a certain period of time. Despite its esthetic appearance, porcelain was prone to fracture and required direct resin bonding with an acid-etch technique.

In the 1970s, colorless metal ceramic crowns were fabricated with newly improved techniques, and commercial shoulder porcelains were developed. They had higher firing temperatures and increased resistance to pyroplastic flows that caused minimal distortions when the veneer porcelains were fired.[51] At that time, the goal of eliminating the gold coping and replacing it with high-strength ceramic was not yet achieved. In 1976, *McLean* and *Seed* developed the first commercially possible foil-reinforced crown system.[57] The dental porcelain could be strengthened by the dispersion of ceramic crystals of high strength and elastic modulus within the glassy matrix. McLean and Hughes used this method to develop the first aluminous porcelains for the fabrication of crowns.[55] These reinforced porcelains had strengths of up to 180 MPa - approximately double that of the more conventional feldspathic materials. Electroforming and the use of tin oxide coatings for the attachment of a conventional metal-bonding porcelain was reported *by Rogers* in 1979, and a number of foil systems were marketed in the 1980s.[58]

Slip casting, or the science of preparing stable suspensions and fabricating structures, was accomplished by building a solid layer on the surface of a porous mold where the capillary forces absorb the liquid. *Sadoun* refined *Count von Schwerin's* slip casting technique[59] in a paper given at the International Conference on Dental Ceramics held at Leeds Castle, England in 1989. These changes produced high-strength coping, and was marketed under the name of In-Ceram. It was not a pure ceramic and represented a step forward in achieving strengths of upto 630 MPa.[60] In-Ceram made it possible for the laboratory technicians to make advancements in the esthetics of anterior crowns, without losing strength. Undoubtedly, this work deserves a notable place in the history of dental ceramics.

In 1993,/\nc/ersor? and *Oden* described a technique for manufacturing individual all-ceramic crowns made up of densely sintered high-purity alumina.[61] However, the color of sintered alumina may vary according to the firing conditions, presenting a serious disadvantage. Similarly, when compared to regular or aluminous dental porcelains, the sintered alumina is a more difficult material to control.

At the Dental Institute of the University of Zurich, Wohlwend developed and marketed a material for the bonding of porcelain that used the principle of leucite crystal dispersion.[62] This material, Empress, consists of leucite crystals that are only a few microns in size and are produced

by controlled crystallization in a special glass that contains nucleating agents.

Ceramic materials have now become the mainstay of esthetic dentistry. Rapid advances in the quality of ceramics and ceramic technology have made it possible forthe manufacturers to emulate nature more effectively than ever before. Despite the rapid advances in ceramic technology, the ultimate failure or success of a ceramic restoration is related directly to the expertise of the dentist and his team of technicians. Ceramic material that is used for all ceramic restorations is bonded to the teeth without the support of a metal substructure. Typically, it is reinforced porcelain, designed to withstand the forces of occlusion.[63]

Porcelain Laminate Veneers

Translucent ceramics were first used for clinical purposes as early as 1862, and ceramic veneers were used more frequently in the 1920s and 1930s.[64*65] |n 1938, *Pincus* actually attempted to use a denture adhesive to bond the veneers to the teeth,66 but at that time they were too fragile, as the adhesives available were neither strong nor durable.[67] In 1955, *Buonocore* published an article describing the "acid-etch technique",[68] where a micro-chemical "interlock" was achieved through "acid-etching" the enamel and forming a resistant bond between the composites and inorganic enamel. Subsequently, transparent luting resins replaced the plaque zinc oxyphosphate cement for ceramic inlays. Without any disturbance from an opaque material, light transmission improved, and esthetically pleasing results were achieved.[69]

All-Ceramic versus Porcelain-Fused-to-Metal Restorations

From the initial introduction of porcelain, the use of it in porcelain-fused-to-metal (PFM) applications has achieved the most popularity. Through the years, this system has proved to be beneficial not only for use in the posterior region but also in the anterior, where esthetics are an especially important issue. Even today, there are a considerable number of dentists who are still using PFMs in the anterior regions to achieve better esthetics. However, this technique, or the metal used, impairs the transmission of light.[70] If the gingival tissues are thin, the marginal soft tissues near the metal collars that have been placed subgingival^ may appear to be dark (Fig 1-13). Since the ceramic layer is quite thin and opaque, this is a common occurrence, interfering with the transmission of light through the labial gingival tissues, owing to the shadows created by the porcelain-fused-to-metal restorations with labial butt joint designs. When there is no metal coping, natural teeth, all-porcelain jackets, and cast glass ceramic crowns allow light transmission. All-ceramic restorations require the removal of large amounts of sound dental tissue in order to provide adequate space for the placement of the jacket crown of optimal thickness over the prepared tooth.[70,71]

Until the 1980s, esthetic dentistry was concerned primarily with the close replication of the tooth structure. In the last two decades, several modifications of porcelain-fused-to-metal crown restorations were developed and incorporated within the all-porcelain systems.[53,72] The improved physical properties of these systems, combined with advancements in adhesive technology, such as enamel bonding,[68] dentin bonding,[73] porcelain etching, and silanization[74-75] facilitated the reproduction of new prosthodontic treatment modalities.[76] Clinicians, ceramic technicians, manufacturers, and researchers have striven to produce a substitute artificial enamel, intimately bonded to the dental tissue, for teeth that lack shape, color, or structure, while attempting to retain the maximum amount of healthy intact tooth structure and not exceeding a reasonable financial expenditure.[77]

PLVs

With the recent increase in patients' demands for esthetic restorations in the anterior as well as

Fig 1-13 When porcelain-fused-to-metal restorations are used on dentition with thin gingival tissue, the dark color of the metal may create a reflection, thereby creating an unesthetic appearance.

Fig 1-14 Research has shown that when porcelain laminate veneers are properly prepared, produced, and finished, an increase of the crevicular fluid decreases the plaque index and plaque bacteria vitality. Note the gingival health around the biologically integrated porcelain laminate veneers.

the posterior regions, it has become necessary to develop new materials that combine the strength and the resistance that are essential in the posterior region, along with the esthetic qualities desired in the anterior region.[78] Porcelain laminate veneers (PLVs) have become the esthetic alternative to ceramic crowns and the traditional porcelain-fused-to-metal.[79] Smiles can be transformed painlessly, conservatively and quickly with dramatic, long-lasting results with the successful use of the porcelain laminate veneer. Porcelain veneers are now the restorative choice for esthetics in numerous clinical circumstances that would have resulted in the use of full crowns in the past. Tissue response is excellent, and the finished surface is very similar to the natural tooth. Veneers exhibit natural fluorescence and absorb, reflect, and transmit light exactly as does the natural tooth structure. Patients are highly enthusiastic about these restorations that represent a conservative treatment that enhances patient self-image.[3]

The subsequent introduction of special acid-etching techniques improved the long-term retention of veneers.[80-82] *Horn*[83] and *Simonsen* and *Calamia,*[84] for example, increased interest in porcelain veneers. They were influential in demonstrating that the bond strength of hydrofluoric acid-etched and silanated veneer to the luting resin composite is generally greater than the bond strength of the same luting resin to the etched enamel surface.[75]

Minimal Tissue Response

Perhaps one of the most important advantages of porcelain laminate veneer is that the periodontal reaction is minimal. The smoothly finished margins help to maintain good periodontal health and oral hygiene (Fig 1-14).[85]-[86] Various studies have been performed. One of them established that the porcelain-fused-to-metal tissue response is similar to that of the veneers; yet, another found that there was considerably less inflammation with porcelain veneers than with porcelain-fused-to-metal (PFM) restorations.[28]-[31] In another particular study, *Kourkouata* et al. found that after the porcelain veneer restoration was completed, there was an increase in cervicular fluid; similarly, there was asignificant decrease in plaque index and plaque bacteria vitality.[87] When selecting a treatment, longevity is a major concern. A more invasive procedure will result in a higher riskto the tooth and ultimately a more expensive treatment.

Ceramic and metal-ceramic crowns require a considerable removal of the natural tooth structure, thereby increasing the risk. The subsequent increase in interest in less invasive procedures is therefore inevitable.

State of the Art

The dental profession has always been in search of restorations that have a "natural" appearance but are, at the same time, long lasting. In the past, the lack of appropriate dental materials rendered this impossible.[35] However, advances in porcelain veneers and bonding materials now offer a variety of selections in treatment, with long-lasting restorations and improved quality in esthetic results.[3-88-101]

Porcelain veneers are to be considered the "state of the art" in esthetic dentistry, providing abundant advantages over any previous form of veneer system. They are excellent in terms of their appearance and durability, and the actual procedure does not disturb the soft tissue or the adjoining periodontium. Since their introduction almost 20 years ago, porcelain veneers have become the flagship of most esthetics-based practices.

Strength

Owing to their ceramic thinness (0.3-0.5mm), the porcelain veneers can be easily fractured before they are even bonded, similar to kitchen or bathroom tiles. However, once bonded on a solid foundation, they integrate with the tooth structure and become extremely durable, in vitro and in vivo. If all conditions have been adhered to and the appropriate bonding composite has been selected, the dentist will achieve successful results. The patient's satisfaction is bound to be high as this medium ensures long-term maintenance, good gingival health and excellent oral hygiene. Prior to the recent popularity of porcelain laminate veneer application; full crowns were the earlier esthetic restorations for the anterior region. Preparation for full crowns involved removal of large amounts of enamel, and these invasive procedures often adversely affected the periodontal tissues and pulp.[102-104] When it was proven that function and esthetics could be achieved with porcelain laminate veneers and without the removal of large amounts of intact tooth structure, porcelain veneers became the restorative material of choice in addressing the most challenging aspects of esthetic dentistry by integrating the individual restorations into the adjacent natural dentition.

Enamel Replacement

Recent major breakthroughs in bonding materials and their predictable retention of porcelain to the tooth surface have added an entirely new dimension to the field of esthetic dentistry.[105-106] The introduction of multi-step total etch adhesive systems was made possible by the progress made in the bonding to the enamel and dentine capabilities.[102-104] Porcelain laminate veneer restorations, bonded with the latest generation of adhesive systems, are capable of achieving biological compatibility and function, while attaining a comparable esthetic result. We all agree that the natural human enamel would be the best restorative material to use, if that were possible[79] - but porcelain laminate veneers, being the closest material to natural human enamel, are the least destructive to the adjoining tissues. These characteristics have established the porcelain veneers as the preferred restorative material preserving the enamel, which is ultimately the most valuable part of the tooth. Numerous authors have suggested that the a minimal thickness for tooth preparation for ceramic veneers should be no more than 0.5 mm.[64-65-107] In practice, however, the actual approximate thickness of a porcelain laminate veneer is 0.4 to 0.7 mm, which closely resembles that of the natural tooth enamel. As the quality of porcelain veneers has improved, their popularity has increased, owing to the technique's ability to preserve larger portions of the natural enamel by offering a conservative alternative to full coverage crowns.

Biological Acceptance

Evaluation of published data has shown that porcelain laminate veneers are biologically acceptable to the body owing to their increased chemical stability, lesser cytotoxicity and reduced risk of causing irritation or sensitivity.[108,109] Other advantages of porcelain veneer that have been supported by studies include the reduced plaque build-up and its easy removal.[110-113] Even the bacterial plaque vitality on these surfaces was found to be considerably reduced.[114] *Quirynen* et al. found that only minimal plaque is retained by the porcelain veneers, less than on any other type of material, including natural enamel. The reduced plaque retention is a direct result of the smoothly glazed surface of the porcelain that discourages plaque adherence.[115] The positive effects of porcelain veneers on the marginal gingival tissues are supported by extensive studies and cannot be negated.[30,31,65,81,116]

Application and Case Selection

Although alltechniques may havetheir limitations, porcelain laminate veneers have remained the most esthetic of all the ceramic materials. Awareness of the porcelain characteristics and a careful selection of the cases will enhance the overall success of the restorative treatment.[117] Ceramic veneers may be applied in any number of instances, ranging from the restoration of small proximal lesions and moderate incisal chipping to the cosmetic repairs of developmental defects on the facial surface of the tooth or even to the otherwise intact anterior teeth that have been damaged by severe staining. They have also been successfully used to close diastemata, correct misalignment, and to cover discolored or misshapen teeth. For esthetically unacceptable teeth, porcelain laminate veneers offer a restorative technique using ceramic material that has an enamel mass and translucency to ensure a natural esthetic result with a conservative preparation.

In the more severe clinical circumstances that involve fractured incisors and nonvital teeth, the improvements made in the development of adhesion offer the porcelain veneers as a viable alternative treatment.[118] Along with the revolution in materials, the actual tooth preparation procedures have changed considerably as well. Extensive guidelines are now available to prepare the tooth for partial coverage. Application can be determined by the amount of remaining tooth structure, removal of diseased dental structures, and the space available for a restoration that provides not only form but function as well (see Chapter 7).[119]

Longevity

The union of etched enamel and porcelain, combined with the bonding composite resin-luting agent with a silane coupling agent, enables the dentist to perform restorations that are solid as well as long lasting. The long-term data is encouraging and reports a high success rate for this form of treatment. Materials used in the 1980s are now considered primitive, whereas the restorations made with laminate veneers even 15 years ago have shown a high rate of success, increasing interest and widespread acceptance[68-120,121] (Fig 1-15). Porcelain laminate veneers are continually gaining respect as the best and most durable restorative treatment, while patients and dentists alike are delighted with the esthetic results and the minimal tooth preparation required.[31,66,122-125] As esthetic dentists are becoming increasingly confident of its application to a variety of clinical cases, the survival rate of laminate veneers reported in literature ranges anywhere from 18 months to 15 years.[85] *Friedman* reports in another study that of the 3,500 porcelain veneers that were placed over a 15-year period, 93% of the cases were successful.[126]

Translucency

Since ceramic restorations allowthetransmission of light in a manner similar to that of the natural tooth structure, most of these systems offer the potential for superior esthetics. The inherent translucency of the material itself is the superior

Fig 1-15 The longevity of porcelain laminate veneer restorations has been demonstrated by their service in function and esthetics for years, even though the quality of the earlier material is not comparable to that available today. Note thecurrent status of porcelain laminate veneers that were placed 12 years ago.

Fig 1-16 Using a translucent layer during the laboratory stage can enhance the depth and vitality of the veneers. With adequate communication of information from the clinician, a skillful laboratory technician can judge the amount of translucency porcelain that should be applied over the veneer surface, especially the incisal edges (Technician *Gerard Ubassy).*

characteristic of porcelain laminate veneers. It adds depth of translucency and lighttransmission to the restored tooth, regardless of the depth of its application (Fig 1-16).[127] These translucent materials allow light to be transmitted into the tooth without causing undesirable tissue darkening adjacent to the restorations. If the shade of the porcelain is close enough for a clear resin composite to be used for cementation, impressive results can be achieved.[128]

Porcelain Laminate Veneers versus Composite Restorations

It is possible to use composite restorations instead of porcelain laminate veneers to cover up tooth discolorations or unesthetic forms. However, the longevity of composites is questionable as they are susceptible to discoloration, marginal fractures and wear. Consequently, any esthetic result requiring long-term durability will be compromised;[129,130] while porcelain veneers are superior in esthetic quality and longevity. The biocompatibility and nonporous surface of the porcelain that prevents plaque adherence has increased its popularity and usage.[131] Furthermore, the applicability of the supragingival preparation technique, used in most veneer restorations, ensures excellent periodontal health. As a result, the porcelain laminate veneers have an important role as a solution to both functional and esthetic challenges.

Functional Corrections

In addition to esthetic restorations, porcelain veneers are a favorable choice for treatment of occlusal deficiencies and for the reestablishment of correct guidance during excursive movements.[132] As *Friedman* reports, porcelain veneers provide functional strength as well as esthetic results.[133] Porcelain laminate veneers can be used as an alternative treatment to guarantee the least reduction of the tooth structure while achieving the most perfect fit. Clinical and laboratory fabrications should be performed in concert to provide a result that is both functional and esthetic.



Fig 1-17 First generation of Empress reinforced with leucite crystals.The leucite crystals are responsible for strength. They reflect and scatterthelightthrough the glass matrix, which helps keep the vitality and translucency.



Fig 1-18 Surface of lithium dissilicate after being treated with HFA. A high amount of crystal can be seen, which will stop crack propagation. These crystals not only make the porcelain stronger but it keeps the translucency.

Porcelain Materials for Veneers

Several porcelain materials can be used for the fabrication of veneers and they can be classified into five groups: castable glass ceramic; heat-pressed ceramic; computer-aided manufacturing (CAD/CAM) processed factory produced ingots; feldspathic porcelain baked in the traditional water-slurry method; and feldspathic porcelain over foil-matrix with refractory die technique. Each system has its own advantages and disadvantages.[127] The feldspathic porcelain is the most commonly used porcelain today (either fabricated over the refectory die or the platinum foil) as well as the pressable ceramics. Their esthetic qualities and results may vary. Most veneers can be made from both pressable ceramics and the low-fusing feldspathic porcelain with the platinum foil technique.[134,135]

Pressable Ceramics

Pressable ceramics were successfully launched onto the market approximately 10 years ago. Since their introduction, many similar products have been introduced and have since flooded the market. This was a consequence of the acceptance and reliability of the system of pressable ceramics made of pre-sintered ingots, offering a variety of advantages (Fig 1-17).

The ingots are made of a silicate glass matrix and sometimes contain a crystal phase range, depending on the type of product. The mechanical and physical results of this material show their best results in vivo. In later stages, new developments like Empress 2 even increased the mechanical and optical benefits (Fig 1-18). This product line represents a new type of material, which does not resemble the Empress leucite glass-ceramics.

The following simplified definition of glass-ceramics should help distinguish them from other related materials such as glasses and sintered ceramics/porcelains: "a glass-ceramic is a glassy crystalline material that consists of at least one glass phase and one crystalline phase. The base material for the product is glass, in which crystals are formed by controlled nucleation and crystallization. The finished glass-ceramic product is characterized by at least one type of special crystal that is embedded in at least one glass matrix."



Fig 1-19 Layering technique for Empress 2. The SEM picture shows the perfect interface of which the layering porcelain fluor apatite is diffused into the core material lithium dissilicate.

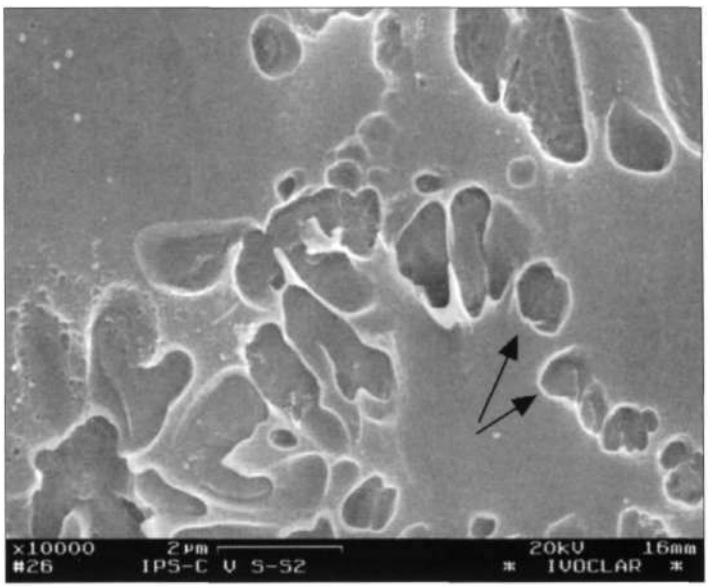

Fig 1-20 The matrix of a feldspathic porcelain with a high amount of glass. Some single crystals are visible. Crack propagation can be easier owing to the high amount of glass matrix. These materials are highly translucent.

Methods

To produce restorations with the Pressable System, special equipment is required. It is very important to adhere to one system-brand and that your choice includes all the requested tools. The pressing machine, special investment and ingots, as well as additional items such as die material for shade control, are all key points. The more complete the system is, the safer and more exact the results will be.

The technician will simply model the object in wax and invest it. The muffles are preheated and, depending on the restorations, either one or two or multiple ingots will be placed into the muffle. The pressing procedure today is fully automatic and controlled with hi-tech electronics. The technician gets the best fitting object after divesting the muffle, which, depending on the chosen technique, may only need to be painted or layered (Fig 1-19).

Advantages
1. Safe
2. Highly esthetic
3. Less work time
4. Firm fit
5. Long-term success
6. Large indications

Disadvantages
1. Relatively high equipment costs

Feldspathic Porcelain

The use of 0.3 mm thickness is possible with feldspathic porcelain, allowing the esthetic dentist to remove only a minimal amount of the natural enamel in preparation. However, this quality can prove disadvantageous as its very thinness renders the veneer brittle, and porcelain particles may cause micro porosities that create low flexural strength[127] (Fig 1-20).

Refraction Die Method (RDM)

Just as with the foil technique, RDM is not a technique that has been reinvented or offers a modern lab high-end technology, but rather gives the technician a solution that avoids the use of extra hardware. It is worth considering as its correct usage offers attractive esthetic results.

These products are mostly made from sinter porcelain. The materials themselves do not generally carry crystals in high quantity if the origin is natural amorph raw material. The porcelain ceramics used for this material do not commonly show outstanding physical properties.

The method consists of duplicating the die by using addition silicones or other accurate, precise impression materials. To pour out the impression, refractory, phosphate-bonded material will commonly be used. Although setting time and the sintering process in preheating furnaces are time consuming, they are crucial steps.

Finally, to apply the ceramic on the die we have to immerse the model in water and seal the surface. The next steps are to build up the dentin, modifiers and incisals according to each case. The firings, including correction, staining and glazing are always done without removing the object from the die. Only at the end can the refractory die be removed by using glass beads in the sandblaster. The final fit must be rechecked on the master model.

Advantages
1. Low hardware costs
2. Highly esthetic results
3. Creativity

Disadvantages
1. Technique sensitive
2. Time-consuming
3. Shrinkage/fit
4. Limited indications

Foil-Matrix Technique

The foil-matrix technique has been used for decades and was one of the first in this field. Several published articles and technical instruction books explain the technique in detail.

Platinum foil is used as a support for core porcelain. The core material requires reinforcement, with products such as aluminous core porcelains. The following layers are dentin enamel porcelain, which is compatible to the reinforced core.

The foil-matrix technique does not require a large quantity of expensive tools. The technician must accurately apply athin (0.025 mm) foil which must be adapted perfectly and squeezed tightly at the joints. The core porcelain has to be applied and baked. The thickness of core porcelain after firing determines its stability and strength. There will always be shrinkage that will require compensation as well as some difficulties in the marginal fit that are unavoidable.

Advantages
1. Low hardware costs
2. Quick
3. Acceptable esthetic

Disadvantages
1. Limited indications
2. Quiet opaque core
3. Handling must be trained

The greatest flexural strength is found in the castable glass ceramic and heat-pressed leucite-reinforced ceramic, when the thickness is no less than 0.5 mm.[136]

Computer aided design/milling (CAD/CAM)

In comparison to all the other systems, the CAD/CAM or copy-milling techniques create a mean interfacial gap between the actual tooth structure and the restoration that is considerably wider than that of the other systems.[137,138]

This technology for metal-free restorations has become increasingly popular and reliable. In the last few years, several systems have shown that CAD/CAM-produced restorations are accurate enough to be used in the modern clinic. Different material compositions have been used.

Aluminum reinforced matrix, zirconium and leucite ceramics were the most frequently used materials in the past. Some CAD/CAM systems have been used in the dental clinic (Cerec).

Next-generation CAD/CAM units are being introduced, and will be able to prepare any kind of geometry; the indications for which they can be used are virtually limitless.

Owing to the large size of this unit, access to the equipment is generally scanning or through



Fig 1-21 Picture of a highly reinforced zirconium dioxide with over 1,000 Megapascal flexural strength. Due to the special means of production, this material can also keep its translucency. Note the compact structure of the material. Under normal circumstances chances of crack propagation is minimal.



Fig 1-22 For CAD-CAM produced framework such as in the figure, layering material does need to be developed. The picture shows a material with fluor-apatite crystals which is one of the possible choices. The geometry of these crystals is similar to natural enamel in scattering and breaking the light.

the impression or die. A specialist will feed the clinical information into the software with all the related details concerning the preparation parameters. Centers will be set up so that all the necessary information about each case can be collected, produced and distributed.

The results are perfectly fitting restorations, of exactly 5 micron. Outstanding results can be expected. These new materials, which are colored and translucent, will join compatible layering ceramic to conclude the restoration. This technique is very promising as it excludes the human fault rate with the production of a core or frame.

On the other hand, it gives technicians the chance to concentrate their creativity totally on the build-up (Figs 1-21 and 1-22).

Advantages
1. High esthetic
2. Quick
3. Very large indications
4. Safe

Disadvantages
1. Units are expensive

Porcelain Selection

In clinical practice, the personal experience and esthetic performance of the clinician play major roles in the selection of porcelain and in the final outcome. However, no matter which porcelain material is used, when they are applied properly, most of the materials exhibit high strength. The techniques adopted and the ceramic materials employed by the technician also affect the final esthetic outcome. Some technicians may produce only a small number of ceramics each day - care which is reflected in the restorations. By contrast, others prefer more straightforward fabrication and the potential for high-volume production, andthis will influencetheir choice of techniques and materials. In the hands of a talented ceramist, satisfactory results can be achieved. The choice will depend on the commitment of the dentist, their adherence to excellence, and the financial circumstances of the patient.

Technical Sensitivity

The unique characteristics of this particular restorative treatment and its application require

special consideration. The highly technical sensitivity of the porcelain laminate veneers may present a so-called "downside" (see Chapters 7, 9 and 10). The success of the porcelain veneers is related directly to the expertise of the technical application, just like other newtechniques that are used in dentistry tod ay. Meticulous attention to the correct sequence of application will ensure successful results. When properly utilized, these techniques present several distinct advantages. The reliability and longevity of porcelain laminate veneers mean they will become more popular and have a vital role in esthetic dentistry. This increasing popularity will place demands for further development of the technical preparation, application, and especially of the color matching and masking methods.[139-145]

The Esthetic Dentist

Esthetics, more than any other area in dentistry, is based on individual perception.[146-147] The rationale of the clinician is generally the most important factor in success. Sound scientific knowledge alone is not enough to ensure the success of any prosthodontic procedure and indeed the wisdom of a dentist is required. Sensible selections of suitable physiologic or morphologic variations that are appropriate for each individual are primarily the responsibility of the clinician. Sensibility is not innate; it must be acquired through diligenttraining and continuous observation.[148] A dentist must therefore acquire and develop the artistic talents necessary to perform the most delicate procedures. The esthetic dentist must have not only a good technical understanding of artistic principles, such as the shaping of teeth and the creation of illusions, but also the knowledge and expertise in their application to clinical esthetic dentistry. The goal should be to establish a biologically compatible dentition that is esthetically acceptable to the patient.[149-150]

Creativity and technical skills are required to become an accomplished esthetic dentist and to attain successful therapeutic results. An accomplished clinician must be able to design a smile or modify a flawed display in such an artistic way that the patient perceives it as pleasing and attractive.[36] A creative manipulation of tooth dimensions and color can changethe smile dramatically (Fig 1-23). Artificial materials can be used to create an illusion, and the contrivance of reality may be used to create a restorative change that is perceived by each patient as beautiful. The advent of bonding has furnished the resources to attach composite resins and porcelain in their numerous shades to the tooth surface, enabling theconcealmentof imperfect teeth by creating an esthetic illusion.[151-152]

The Esthetic Dentist as a Designer

As a successful architect takes various aspects into consideration while designing a building, similarly the esthetic dentist must focus not only on form and function but also the personality, gender, occupation and even the life-style of the patient. The smile is a reflection of that individual. It is important, therefore, to communicate with the patient about all aspects of the treatment. The clinician must fully comprehend what any particular procedure will mean for that particular patient. The anticipated final result must be absolutely clear to the clinician and if deemed necessary, the esthetic dentist should not hesitate to refer a patient to a colleague for a second opinion or treatment. This will establish positive patient/dentist relations, and it is an ethically correct approach. As the quality and standards of esthetic dentistry improve, so will the image and reputation of the esthetic dentist.[36] The dentist must be aware of the limitations of each technique and the materials used. They must personally have superior knowledge of tooth preparation and of the specific material used as well as the ability to be able to execute the finishing touches for the best possible result.[153] Excellence has been defined as "the possession of good qualities or skill in an eminent or unusual degree". In striving for perfection, the esthetic dentist should be willing to expect excellence as a final result.[154]

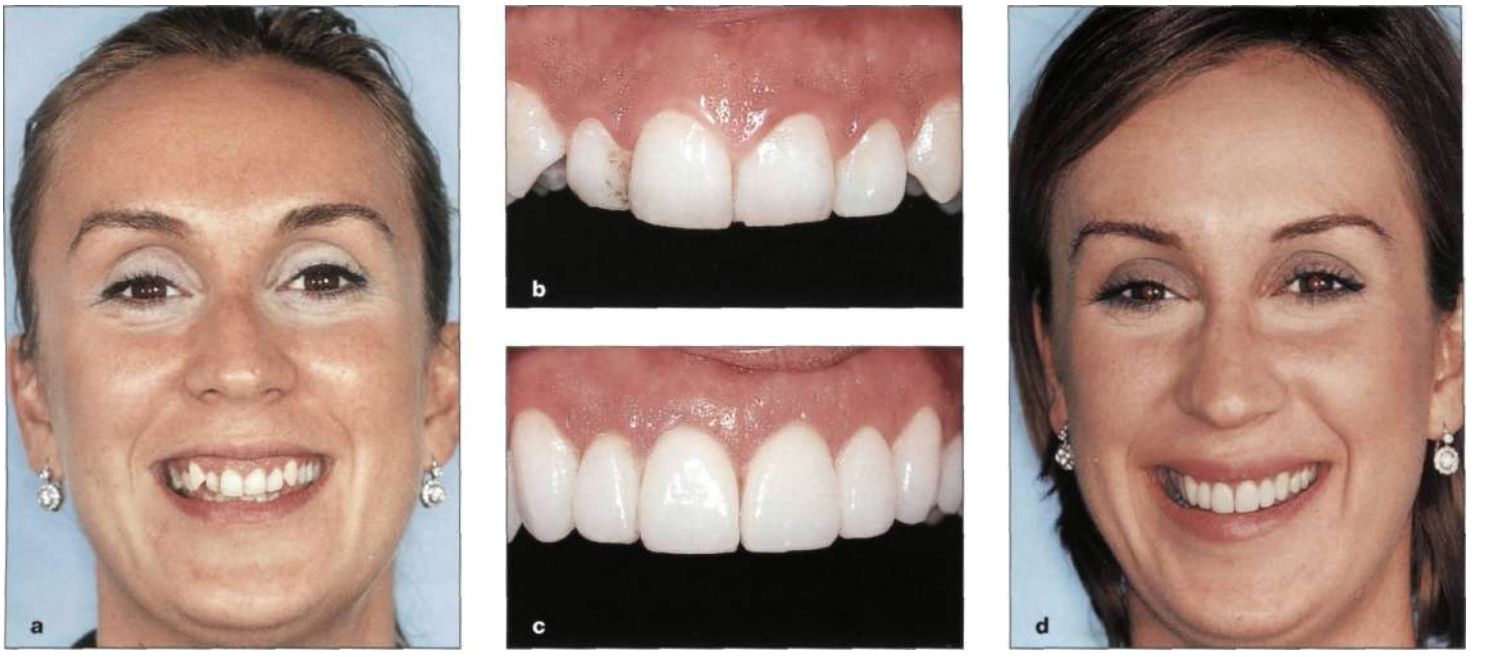

Fig 1-23a-d View of an unattractive smile with healthy teeth (a). The final result should be visualized at the first appointment: (b) If gingival alteration is required, a periodontist may be consulted in advance; (c) when the gingival asymmetries are leveled adequately, the vertical dimensions of the tooth are adjusted accordingly; (d) porcelain laminate veneers are used to correct the third dimension and the bucco-lingual discrepancies. A natural smile is achieved that blends into the facial composition, even though the PLVs applied 9 years ago were monochromatic.

The techniques adopted and material to be used are ultimately the decisions of the clinician. An awareness of the quality of material and its suitability for the particular patient must be determined prior to the initiation of treatment. Sound judgement, a desire to improve one's technical skills, and keeping abreast of the new products that are available should be combined with the most important quality a dentist can possess, the vision or perception of natural esthetics. If the design is successful, there should be no "whiter than white" color emanating from the dentition, or excessive length that can be seen from miles away. When the restoration combines proper function and harmony with its environment, an esthetic pleasure should be felt when observing the smile.

Advanced Training

Until the dentist is familiar with new products or "advanced materials", discretion should be exercised in their use. The new and changing concepts involved in esthetic dentistry, along with the rapid advancements made in the field of restorative materials, require "being up to date" while continuing one's training and education. Failure correctly to apply new techniques that the field now offers may be a cause for dissatisfaction or disappointment.[155] The basics of dentistry are taught in the universities; however, a good dentist who wants to advance in their field must keep up with the continuing advancements in the profession as well as with their training. As long as the field of dentistry produces new materials, ideas and techniques the dentist must further his/her knowledge of the on-going technology.

Creating Natural-looking Smiles

When considering an approach for a new smile design, the dentist undertakes the creation of a new but natural esthetic effect. With each restoration, the patient must be considered as a whole, instead of focusing merely on one or two teeth. Each tooth exists as part of the mouth and face, assisting in creating a smile that reflects the

patient's personality.[156] To create a restoration, harmony in the size, shape and arrangement of the teeth are required in order to enhance each patient's facial features. When the teeth, the surrounding soft tissue and the patient's facial characteristics are taken into consideration, a three-dimensional canvas is examined. The dentist must be aware of the ratio between the anteriorteeth and the surrounding tissue and analyze them to arrive at the desired result.[36]

A combination of only a few teeth may create an impact larger than the sum of the parts and an esthetic case may vary from a simple esthetic contouring of a corner of a single tooth to the complete recreation of a new smile involving the entire dentition.[156] The mouth and its physiological make-up for each individual patient must be studied carefully by the esthetic dentist, analyzing and anticipating any problems that may arise in carrying out the treatment.

No matter what treatment is undertaken, all patients believe that esthetics is the issue of primary importance even though they may not express this belief. A pleasing smile is important to the patient's morale and self-esteem while the loss of it will negatively affect self-image.[12] The anatomic structure may sometimes affect the function and therefore the esthetics. In such cases, owing to functional disorders, restorations may not be as durable as expected. An inability to achieve an optimal esthetic result may be apparent even from the start and the patient must be informed of the possibility of a compromised esthetic outcome prior to the commencement of treatment in order to prevent postoperative dissatisfaction and arguments (see Chapter 14).

Examining the Smile

When a patient arrives for esthetic treatment, they are usually enthusiastic and motivated about beginning the process. Unfortunately, they frequently arrive with a diagnosis of their own, and the esthetic dentist must be careful not to be influenced by it. It is essential that the dentist knows the relation between diagnosis and treatment planning, as well as the patient-driven difference, when diagnosing an esthetic case. It is not recommended to begin planning the treatment procedure without full knowledge of the reasons that caused the esthetic problems. Once the correct diagnosis is made, the dentist has a sound base on which to discuss the details with the patient and to propose an appropriate treatment plan.

While making these plans, the dentist should listen to what the patient says about their postoperative expectations; respecttheir ideas and arrive at the best treatment plan suitable for that particular patient. In treatment evaluation, facial muscles and characteristics are an important consideration. Photography can be a great help better to examine the smile in its various forms of laughter, smiling and speech. Unesthetic conditions, such as asymmetric gingival crests, blunted papilla or inflamed and uneven gingival lines may distract from the overall esthetic image; therefore, the importance of esthetic conditions and their relation to appearance cannot be overlooked. The dentist must believe in the final outcome of the treatment plan. The patient's new smile will be carrying the dentist's signature and will be the best source of new referrals. The patient's satisfaction with the final result in terms of both appearance and function is of vital importance. Dissatisfaction with either of these will not only be harmful to the patient's ego but also to the dentist's professional reputation.

The professional responsibilities of an esthetic dentist entail more than the correction of functional or pathologic irregularities. They require that the dentist be skillful, and also fully aware of each patient's particular problems. A complete understanding of the patient's needs, personality and psychological state will result in a more ready acceptance of the proposed treatment plan.[157]

An important element in the success of any such treatment is attention to detail. Inevitably, it is the fine details that will produce a superb result, while the same techniques applied without attention to detail may produce only average results.[36] It is the dentist who invests time in esthetic dentistry, who has the necessary artistic feeling, the eye and hand coordination, and the eye for detail that will separate him or herself from their peers.

Understanding the Patient

Some patients are "result oriented" and cannot be bothered with time-consuming imaging, discussions or long explanations. The responsive dentist must get to the point quickly, summarize the situation and make use of the appointment time. On the other hand, there are the patients who are more emotional, rather disorganized, and not interested in the details but who are quite ready to make a quick decision. It is necessary for the dentist to explain everything to the patient in an enthusiastic way and illustrate the narrative with photographs.[158] As the perception of beauty may differ from individual to individual, so it may differ from culture to culture and from one racial group to another. Basic principles of visual perception need to be developed to determine the response.

Perception

When we are consciously looking at something, the brain is trained to focus immediately on a particular object. In fact, the mind's eye tends to focus on one important object and ignore the surrounding features. When the mouth opens, and the teeth come into view, the brain automatically focuses on the teeth. However, as most people tend to speak to each other usually at a conversational distance, their attention is not focused on every detail of each individual tooth, but rather on the total symmetry, line, proportion, form and size. An esthetic dental observer must learn to focus on a particularly obvious feature of the oral region[12] (see Chapter 2).

Careful observation and the ability correctly to perceive the tooth is a matter of training where only a small degree of error is acceptable. However, errors in the perception of morphology are possible no matter how great the care exercised. Errors such as these may result from the failure of the eye to perceive an object correctly.[159] The esthetic dentist must correctly perceive what is seen in order to form the right morphology and to correct any error that may otherwise lead to serious problems.[159]

Morphological Thinking

The actual phenomenon of visual perception has not been seriously studied as a part of dental methodology. However, dental techniques and the anticipation of problems regarding possible misperceptions should be part of these studies. For that reason, it may help to take a closer look at how visual misperceptions may affect morphologic restorations. Our objective is to create artificial teeth that are as natural in appearance as possible; therefore, focusing our morphologic thinking based on natural teeth.[159] The esthetic dentist needs a keen eye that can readily distinguish natural teeth and their distinct differences one from another. Once this "eye" has been developed, the chances of successfully creating a natural-looking dentition will be greater.[159] Esthetic dentists should have a vision that leads them to strive for leadership in dentistry acquired through personal excellence, education, and integrity positively to affect the health, function, and beauty of mankind.[160]

Teamwork

Elective esthetic dentistry may be defined as the "art form" within the field of dentistry. In order to offer the highest level of patient care, the restorative team must be able to provide treatment that is not only biocompatible and functional but also predictably esthetic. As the field of esthetic dentistry continues to expand, it is essential to retain the quality of natural-looking restorations, harmoniously integrated with proper soft tissue architecture, that have been carefully and meticulously controlled throughout the duration of the restorative procedure.[35] The aim of the esthetic team should be to provide the best products and services available today, with team coordination in the diagnostic phase of the esthetic rehabilitation. The role of the esthetic dentist is to understand the needs of the patient and to formulate a plan that includes not only esthetic considerations, but also occlusal, periodontal and func-

tional requirements, while successfully relating this information to and coordinating with the specialists.

The Specialists

Successful esthetic treatment demands a competent professional team of devoted and skilled specialists. Today, we have built stronger bonds with our fellow specialists in an effort to create treatment options that address health considerations and the esthetic desires of patients. Health issues should never be compromised for the sake of beauty. This is especially important when addressing the demands of capricious patients who present unreasonable or impossible requests that only a skilled team of professionals will be qualified to handle (Fig 1-24). It is of the utmost importance to establish and maintain communication and cooperation between the patient and the technical team, so that the available options can be discussed and the appropriate treatment selected.[36]

The esthetic dentist may be considered as the captain of the team, responsible not only for meticulous artistry and skill but also for the coordination of the team. Each member of the dental team must be aware of their responsibility to one another and to their individual work. Awareness of the team's individual limitations is as important as the awareness of its qualifications. The dentist, acting as the orchestra conductor, along with the team of specialists and technicians, must provide an esthetically pleasing concert. The specialized team members may have varied perceptions of the treatment for a particular esthetic case. The role of the team captain is to select a plan and communicate the concepts to the specialists.

The esthetic dentist may want simply to alter the asymmetric gingival levels (see Chapter 6). For most of the periodontologists, the treatment is limited totissue health only, unless it has been agreed that the gingival levels be altered. This is also an example of changing the perception of a specialist.

The same thing may happen when orthodontics enters into treatment planning. For most orthodontists, their esthetic goal is achieved when the incisal edges of the incisors are equilibrated. However, as a part of the "esthetictreatment plan", the captain may want the intrusion of one of these incisally-equilibrated anteriors in order to alter an asymmetric gingival level without a periodontal approach (see Chapter 11). Thistreatment will naturally distort the already well-aligned incisal edge positions of the natural teeth. However, once the gingival levels are aligned, the altered incisal levels resulting from this treatment can be balanced with the help of the porcelain laminate veneers. Mutual respect and encouragement for constructive criticism are required under these circumstances.

The Dental Technician

It should be emphasized that the laboratory technician has a major role in the success of this delicate restorative procedure, especially in the case of porcelain laminate veneers. The success of this team is directly related to the technician's powers of observation, artistry, and the technical discipline of the other members of the team of dentists and specialists (Fig 1-25). The technician is one of the most influential members of the team and deserves most of the credit in properly finished porcelain laminate veneers.

The Patient

The patient, who is the most important member of the team, is frequently overlooked. A successful team needs to integrate the patient into the team as a responsive, contributing member to maintain the motivation and synergy. Consequently, any esthetic restorative treatment also exerts a collaborative effort between the esthetic dentist, the team and the patient. The patient must receive comprehensive information from the dentist regarding the scope, the details and the limitations of the various treatment options, in order to base their decision on a solid understanding of the situation. The patient will appreciate a true collaborative effort and fulfillment of the dental and laboratory team's responsibilities.[161]



Fig 1-24a-e (a, b) Successful teamwork is essential in achieving success in esthetic dentistry; (c)the diastemata are closed by orthodontic means, and some spaces are deliberately opened in other areas in order to create a space for a pontic; porcelain laminate veneers are used to treat the mandibular arch first (d), then continued to the maxillary arch (e). Note the total impact of a beautiful smile, that improves the alignment of the teeth as well as the self-image of the patient.



Fig 1-25 In the laboratory, the technician's observations, communicated information, and artistic talent and skill combine to achieve the optimal definitive restoration. View of the author's in-house laboratory and his chief technician Mr. Hakan Akbayar at work.

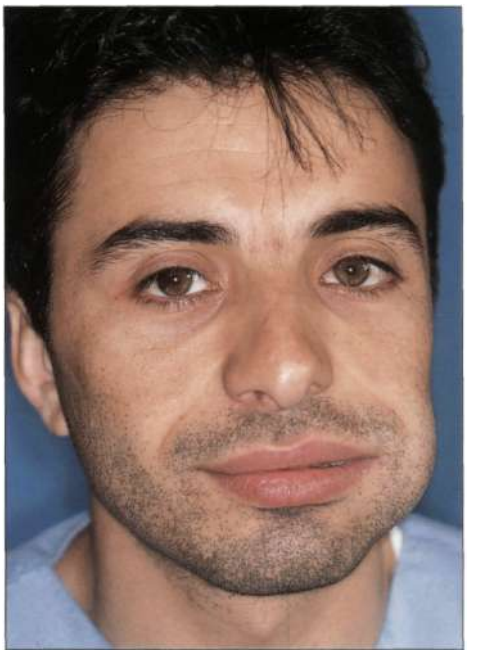

Fig 1-26 Patients who do not visit a dentist regularly may do so only when pain is already present. In such cases, the treatment suggested by the dentist for pain relief is usually accepted.

The Staff

It is not only the specialists, but the hygienist, receptionist and the assistants who play important roles. They should share the same vision and passion as the other team members, because in terms of communication the patient tends to spend more time during the treatment with the hygienist and the dental assistants than with the dentist. The staff will ask questions and share some of their expectations, since the patient is unable to speak while the dentist is working in the oral environment. When the dentist leaves the surgery, they have time to speak to the assistants and hygienist about the procedure and may need answers to some questions that have arisen. Therefore, the entire team must be well informed on everything the procedure entails and be able to answer any questions. The synergy that is created through these efforts will have a positive effect on the patient and the rest of the team (see Chapter 14).

Communication

The needs and motives of esthetic dentistry are different from conventional dentistry. Under normal circumstances, a patient visits the dentist either for a routine check-up or the treatment of a specific dental problem. If there is a tooth defect, a fractured tooth, discomfort or swelling that requires attention, a patient seeks treatment that is probably standard procedure, and there is no "need" for the dentist to confer with the patient (Fig 1-26). This clinical situation may be called "need" dentistry.[22] Most of these treatments will be "dentist driven" and the patients are often in pain or discomfort and feeling relief is their primary concern. Whatever treatment plan the dentist offers will be accepted, as there is a desperate need for something to be done to reduce the pain.[22]

However, if the patients are seeking some form of esthetic improvement, they will arrive with ideas of their own concerning how they want to see themselves upon completion of the treatment. We now face a number of totally different patient expectations, and the treatment has changed from "need" dentistry to "want" dentistry.[22]

It is essential to develop a rapport with the patient, especially in esthetic dentistry. This rapport enables the dentist to discern what the func-

tional and esthetical needs are in order to agree on an appropriate procedure. In addition to being successful in the treatment, the dentist must also be able to articulate and impart their procedural plans to the patient in such a way that they fully understand what they are about to experience. This is an additional aspect of the responsibilities to their patients, and it requires that they maintain a high level of consciousness. This aspect is important in all types of dentistry, but particularly so in esthetic dentistry.

Patient Communication

Personal communication between the dentist and patient is of the utmost importance. This rapport should be established at the first appointment and continue throughout the treatment to ensure success.[39] The field of esthetic dentistry is growing rapidly and prospective patients are becoming increasingly aware of the various innovative procedures available to them. The first meeting between the dentist and patient is vitally important to the success of the prosthetic treatment. The positive attitude of the dentist, along with the comprehensive diagnostic and communicationtechniques used, buildsthe patient's confidence in the dentist and the team and helps to establish the communication that is necessary for attaining optimal results. Patients who have developed a good rapport with their dentist also become excellent sources for referrals.[79]

The First Visit

The first visit will set the tone for the relationship between the patient and dentist. It is vitally important, therefore, to make it a positive experience for the patient. If a good relationship is initially established, it will aid in developing trust and make any other stages of the treatment process easier.[36] In private practice, most patients arrive with questions about the cost of the treatment and the time involved. Some may be hesitant to inquire, especially aboutthe cost. In offices where patients visit on a referral basis, the reluctance does not present a problem, as the patients arrive with a general idea of the approximate expenditures anticipated. In the author's experience, it is best not to use external marketing tools but rather to focus on internal marketing, which means a display of quality work supported by patient education. It will take longer to become well known compared to surgeries that have external marketing. However, as years pass and satisfied patients result in increasing referrals, a more respectable image develops.

It is important for the dentist to be a good listener and to be meticulous in recording all the pertinent information. The first appointment will also include a preliminary clinical examination. To ensure the complete confidence of a patient, the dentist must fully comprehend the motives of the patient, accurately grasp the particular dissatisfaction with the dentition, and properly interpret the changes desired. If the dentist is completely honest with the patient and conceals nothing that the procedures may entail, the patient will feel confidence in the dentist and the team, and the rapport between them will strengthen.

Success or Failure

This cooperation and communication between the patient and the dentist will determine the success or failure of the treatment. The esthetic dentist needs to be completely "in tune" with the attitude of the patient, the verbal requests, and the less-obvious nonverbal cues. The dentist who is able to generate a confident, competent and observant attitude makes the patient feel relaxed, and inspires confidence in him or herself and in the proposed treatment. The dentist's perception of a desirable smile and the style of design should be discussed with the patient and be considered along with the patient's personal thoughts on their appearance. The patient may wish to reinstate the appearance that has been established overa long period of time or may request an alteration that is totally unrealistic fortheirface. Perhaps one of the most difficult tasks is to select the right treatment in order to achieve success in esthetic dentistry. The ability to say "no" will save the dentist sleepless nights and it should also be remembered that one setback can easily erase many brilliant and successful procedures.[79] If the esthetic dentist

and patient find it difficult to agree on the objectives, it is in the best interests of everyone not to begin the treatment.

Patient Expectations

The other extreme of the clinical circumstances might be that the dentist may interpret esthetic attitudes based on their own opinions and references, rather than on the expectations of the patient.[162] This can result in a "standardized" sense of beauty, which the dentist may attempt to achieve through unnecessary restorations, causing unneeded stress. The Pocket Oxford Dictionary defines esthetics as "philosophy of beauty", and in reality the perception of beauty varies from individual to individual. There are specific criteria that dentists use to determine one tooth or one smile as more pleasing than another. However, dentists must be aware that the esthetic understanding of the patient may not be the same. The result, which may be esthetically pleasing to the dentist, may not be esthetically pleasing to the patient (Fig 1-27).[163]

The human being is a complicated creature and therefore an art as subjective as dental esthetics can be a very complicated matter. Patients arrive with their own distinct personality, family background, and own social environment. They have their own fears and desires that will affect the way they perceive their treatment. Sometimes dissatisfaction with treatment may stem from insecurities and problems. Sufficient knowledge of the individual's circumstances helps in treatment planning for potentially difficult situations. The social surroundings, as well as the family of the patient, must also be taken into consideration as they have an influence on the patient and the perception of the outcome.[79]

When the patient arrives for the first consultation they may be confused and undecided about what they actually want. It is vital that the dentist guides them and helps them to refine and formulate their particular desires, not only for the sake of their own personal satisfaction but also to avoid remaking the prosthesis owing to any possible misunderstanding. The dentist's objective should be to minimizethe problemsthat may arise

Fig 1-27 Dedicated clinicians and technicians achieve restorations that closely mimic nature. The figure presents a posterior porcelain onlay with the layering and staining effects to emulate nature. Many patients, however, may not like such effects.

from the patient's unrealistic expectations. Some patients seek extreme results to ensure that attention is drawn to their restorations. It is the dentist's responsibility to determine exactly what kind of appearance the patient wants and he or she must then correctly understand and interpret the terminology the patient uses. The self-image and treatment expectations of the patient should be thoroughly understood by the dentist in order to achieve the desired effect.[36]

Unrealistic Expectations

It is not uncommon for patients to arrive with expectations that are literally impossible to deliver, and it is up to the dentist to enlighten and educate the patient, while maintaining a healthy rapport at all times. There are a several considerations to remember. It is important to determine whether the patient intends to change the position and shape of hard and softtissuesthrough aggressive preparations or if they only require a change in tooth color. The dentist should ask the patient to complete a detailed questionnaire concerning esthetic considerations (see Chapter 14). This questionnaire acts as a supplement to standard medical questions, pinpointing esthetic possibilities and improving dentist-patient communication. It must be supported by careful clinical examination and detailed information from their dental history.[164]

To be an effective communicator, the dentist must be willing to listen to all possible fears and doubts of the patient concerning the proposed treatments. Each method considered for the treatment should be explained in detail and demonstrated, if necessary. The dentist should be optimistic but should not allow the optimism to interfere with the facts of the actual treatment. Always encourage the patient to bring photographs and share visual images better to illustrate and to generate understanding. Some patients may have afixed image in mind and these subjective expectations may reduce or eliminate the possibility of an objective and attainable treatment.[152]

There comes a point in the communication when the dentist has to make a decision. It is unwise to accept a request just because the patient wants it, and especially because the final result will carry the dentist's signature on that particular smile. The other choice is to offer objective criteria and combine the patient's and the dentist's expectations, that being perhaps the most challenging aspect of esthetic dentistry. The third solution is to be able to say NO to the demanding patient who has unrealistic expectations.

New Diagnostic Tools

Innovative diagnostic tools are available today that expedite the process and aid in communication. Internet and video conferencing reach across distances, while intraoral cameras and transmission of photographs offer information readily available for viewing, which also saves time while clarifying and illustrating the patient's condition. Although it does not replace actual communication with the patient, these diagnostic tools serve as an adjunct to the traditional restorative process.[165] In order to get an accurate image of the anticipated final restoration, a composite mock-up should be prepared. The closer the shades, resins and thicknesses are to the expected final restoration, the better the patient's perception of the final outcome will be. In cases that involve extensive reduction, closure of diastemata, or realignment with veneers, the use of a model or mock-up is essential (Fig 1-28).

A successful alteration, presented in a composite model, allows the patient to see an approximation of the final result. It is also an important exercise for the inexperienced dentist. In time, the dentist will be able to visualize the achievable final result. The experienced dentist uses composite models primarily for the benefit of the patient.[165] The author has found that the use of composite models strengthens the relationship between dentist and patient by allowing the patient to see and feel the final outcome on a three-dimensional scale, as well as testing it for pronunciation. It usefully expedites the preoperative procedure. Nevertheless, neither good communication skills nor the use of models is a guarantee that the patient will accept the proposed esthetic treatment.

Case Acceptance

The visual stimulus can help motivate the patient to arrive at a decision. However, if the patient does not have enough self-confidence, it is useful to have them bring along a friend, relative or someone who can voice an opinion and be involved in the decision-making process, while providing support and reassurance. If the patient cannot make a decision at that moment, the mock-up composites can be secured in a more retentive manner, allowing the patient to leave the office with them in place. It should be explained to the patientthatthese composites should be used only for an esthetic and not a functional trial. The patient should be advised that they might fall out at any time, and that he/she should not eat or apply force to them. The techniques for removing these devices should also be shown to the patient, so that if one mock-up becomes detached, the others can be removed to prevent the strange look of having a single unaesthetic tooth.

It is better to have these trials and explanations preoperatively rather than have your patient voice negative feelings after the procedure has been completed. The dentist acts almost like a psychologist, allowing the patient to express observations and opinions before and after the treatment, thereby avoiding unnecessary confrontations. An important factor to remember is

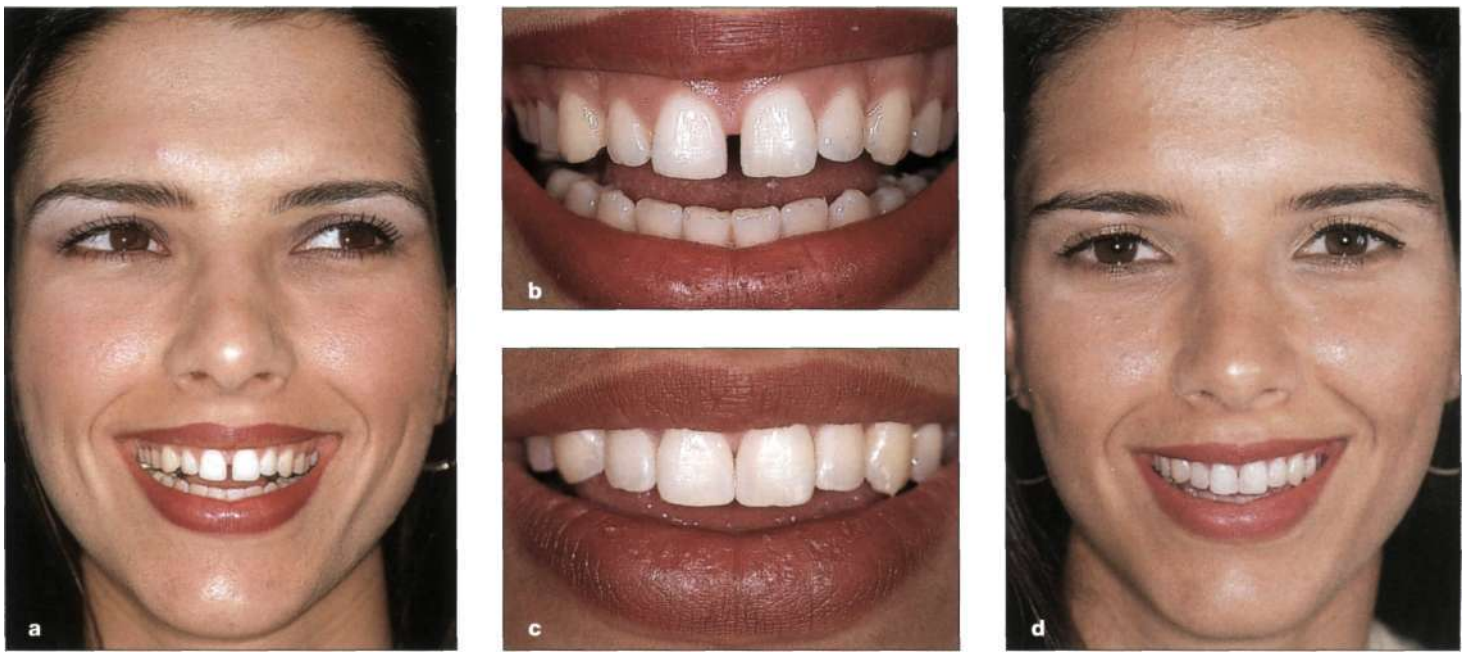

Fig 1-28a-d (a, b) While closing a diastema, both dentist and patient should review the final outcome before the final PLVs are made, (c) Composite mock-ups are simpliest and fastest. In this way the end result can be seen from the first appointment. The patient gains a full perception, including the triangular shape of the papilla between the teeth involved, (d) The final PLVs mimic the contours of the composite mock-up. Through natural integration, teeth look extremely natural.

that the patient's outlook and opinions are subjective from the outset, and it may be difficult for the dentist to influence the patient. Through preliminary discussion and attentive listening to criticism, time can be saved and subsequent unnecessary problems avoided. Unless all aspects of the treatment about to be undertaken are fully understood by the dentist and patient, the treatment should not be initiated.[36]

The area of color is a sensitive one. Despite the dentist's expertise, it is improbablethatthe patient will submit to the dentist's advice. The use of shade guides for the patient is, therefore, advisable. If the dentist is to place porcelain laminate veneers that have to be the same color as the patient's remaining intact teeth, the matter is a straightforward case. The entire responsibility rests with the dentist and the dental technician to produce veneers that match the color of the remaining teeth precisely. However, if the procedure is a completely new smile design, one that includes all maxillary and mandibular anterior teeth, the patient's ideas should betaken into consideration during the decision-making stage of the new color. The patient should then sign the shade selection, since the topic of color is a tricky one indeed, as dentists often discover through years of experience.[79]

The Esthetic Consultation

It is important to set out on the right foot. The initial examination must be thorough, with emphasis on periodontal health, caries, possible orthodontic corrections, occlusion, esthetic requirements, and the economic details of these procedures. A good rapport must be developed with the patient, and a plan made that explains all the various techniques to be used. Techniques, such as bleaching, cosmetic recontouring, porcelain veneering, direct resin bonding, or any other necessary procedures should be explained to the patient. Finally, the verbal presentation should be written as a treatment plan, with all pertinent details included and a copy should be prepared for the patient.

Clinical examples are often required to illustrate the application of visual perception to the intrao-

ral environment in order fully to comprehend why dentition, when in harmony with the facial features, creates a beautiful smile. An excellent way of communicating with the patient is through visual presentation on a three-dimensional basis. A simple presentation of some "before" and "after" cases can be enlightening. "Before" and "after" three-dimensional acrylic models or wax-ups of the patient's dentition, including color, serve to illustrate the visual effect.[166] It is the dentist's responsibility to assist the patient in formulating their often confused and unrealistic desires into realistic and achievable expectations and goals, so avoiding having to remake the prosthesis due to dissatisfaction.[79]

In search of a "media smile", some patients place great importance on the symmetry and alignment of the dentition and gingiva. Other contributing factors, such as cultural preferences, age and gender must be considered as well. The lip length should be considered, as the gingival asymmetries may be neglected in the case of a low lip line. However, even though a low lip line hides the gingival margins or asymmetries, some patients may still insist on altering the gingival levels. Or, as in the case of tetracycline discoloration, the placement of a supragingival margin can upset the patient even though the only way of seeing the margin is by lip retraction. Effective communication is essential prior to undertaking the restoration.[79]

Preoperative Evaluation

The preoperative evaluation must begin with a complete examination that includes all details concerning color, characterization and value, from the gingival to the incisal aspects. Written notes should be taken of any undesirable characteristics that may need special attention at the time of the final veneer preparation. The actual selection of the veneers will depend upon the agreement between the patient and the dentist. When designing the prosthesis, several factors must be taken into consideration. The extension of the lip movement during function and the coronal portions of the teeth that are visible at that time, along with consideration of the patient's age, are all important factors. As various observers may perceive the same image differently, the dental team must be aware of the potential problemsthat can arise when the perceptions of the patient, the dentist, or dental technician differ. It is possible that the patient may even request a certain appearance that is unsuitable, unachievable, or esthetically not optimal.[167]

Esthetic perceptions may differ owing to a lack of communication, as can be observed when some patients remain passive and allow the dentist to design a smile for them without themselves making a contribution. The actual notion of how the patient perceives their own smile may be complex, and even if an esthetic need for treatment exists, the patient may actually be content with their existing smile. Therefore, for each specific case, the dentist must understand the underlying reasons why that particular individual is seeking treatment and what result is ultimately anticipated. Alteration in any existing dental condition must be initiated only after all the needs of that particular patient have been explored and he/she has accepted all points in question.

The Risks and Benefits

The risks and benefits of any treatment should be thoroughly discussed by the patient and dentist. Even though there may be a clinical indication for a porcelain veneer treatment, it does not necessarily have to be carried out. However, once the decision is made, a full and detailed written approval from the patient should be obtained. When only verbal descriptions are used as the basis for treatment decisions, there is a considerable area for subjective interpretation. To avoid subsequent misunderstandings, exercise the proper use of visual images, models and photographs as aids in designing the restorations.

"Before" Pictures

Preoperative images serve as illustrations for the patient and dentist to clarify the differences between the initial problem and the applied solution. Extensive preoperative photographs of the patient's dentition are useful, as patients tend to

forget their original appearance and often need to be reminded. One-to-one and full-face Polaroid photographs, printouts, or digital photography should be taken prior to the treatment. The photographs are essential in order properly to communicate with the technician, and once the case is completed, some of them should be retained in the office with the patient's records and others given to the patient who may wish to show them as evidence of the improvement. Photographs of a successful treatment, to be shown either by the patient or dentist, may serve as proof of their skill in future referrals.[165]

Patient Education

Regardless of their education or social status, most patients have little knowledge of the advancements in dental technology orthe treatment techniques available. In addition to their lack of clinical information, patients are exposed to advertisements in magazines or other mass media concepts of what is "beautiful". It is therefore the dentist's responsibility to educate patients about the various techniques available today in esthetic dentistry, the current materials, and the minimally invasive treatments (see Chapter 14). Some patients may arrive with already formulated ideas and expectations about the treatment, ranging from a simple single tooth replacement to a radical change in the position, shape or color of the entire dentition. Others may arrive for a consultation or routine check-up and only find out then that they may have esthetic disorders of which they had not been previously aware. Precious time will be saved by preliminary discussion and good communication skills.

Symmetry exists if the right and left sides are mirror images of each other, despite any variations in their shapes. In restorations, dentists usually prefer to allow more irregularities than do the patients, since they provide an illusion of a more natural appearance. Dentists tend to like longer maxillary incisors, whereas patients do not. It is bestto discuss these subtle points with the patient and to develop their awareness. Almost all patients are looking for a "whiter" smile, or at least a lighter color than their existing teeth. This is especially true when they are seeking complete esthetic rehabilitation through afull mouth restoration.

If a patient has been dreaming of a perfect smile, with all-white teeth and perfect arrangement, there may be a shock in finding that the actual result of the restoration is a more natural, subtle version, with slight irregularities and a moderate whiteness of the teeth. Unless the patient has been prepared for this by their discussions with the dental team, they may be disappointed and dissatisfied. There is no doubt that this subtle variety in the arrangement of the dentition will enhance the natural look of their appearance, but it is important for the patient to understand this prior to the treatment; otherwise they may be unhappy and reject the results.[168]

Patients generally tend to select very light colors because they cannot imagine what that color will look like when actually applied to their teeth.[36] To aid in the selection of color, various dental manufacturers produce shade guides. Unfortunately, these shade guides are the size of a single tooth, and it is difficult for the dentist to explain to the patient that this shade will appear quite differently and much lighter when applied to all theirteeth. The size, proportion and position of the tooth or teeth in the arch are some of the details that influence the perception of color, and an explanation of this phenomenon to the patient prior to the commencement of treatment is necessary. To enforce verbal communication, colored waxes are used for composite wax-ups to refine the patient's esthetic perceptions. Computer imaging is also becoming increasingly important in illustrating the anticipated result.

Computer Imaging

The magic of computers and the introduction of color monitors, digital and intraoral cameras, electronic graphic tablets, and the mouse, have enabled the dental industry to advance in leaps and bounds. With the help of computers the dentist can illustrate on screen what he/she plans to do, and the patient can see immediately what the restorations will look like. The image can be printed out, saved in the computer, or saved in video

form for future reference. Some systems enable the clinician to create two images side-by-side: one the original for the initial reference and the other for simulation of various restorative procedures. Almost anything can be simulated - from bleaching, to crowning, to repairing fractured teeth, tooth lengthening, orthodontic work, or veneering. Imaging can be used for the simplest procedures, such as a gingivoplasty to correct a gummy smile, or for major orthognathic surgery, such as maxillary/mandibular realignment.[169]

Developing communication skills is important, and imaging is one way to improve them. Imaging has the potential to increase the acceptance of treatment plans that may otherwise have left question marks in the patient's mind and delayed treatment decisions. Some patients like to be able to see imaging, while others are interested only in the basic clinical facts, and here the personality of each patient becomes the deciding factor. Imaging is just one of those tools that are beneficial in illustrating and visualizing the potential results prior to treatment.

Interactive imaging is quite different because it is performed with the patient at the dentist's side. "Before" and "after" images can be somewhat limited, whereas interactive imaging enables real communication on all levels. The prints can be sent directly to the laboratory to hasten the process.[169] There are now dental laboratories that specialize in computer imaging. Dentists can email their patient's "before" pictures with a prescription of the alteration required, and the laboratory can perform the imaging. The image of an actual porcelain veneer built-up may be prepared and sent within one hour.

Imaging is not a simple system to implement and requires special considerations. The equipment is costly and requires additional personnel and adequate space. It takes time to perform the actual imaging and it is essential to provide a comfortable atmosphere in which to do it. Training the staff may be time-consuming while the capability to produce detailed imaging that may be impossible to reproduce clinically, may lead to unrealistic expectations and result in patient dissatisfaction.

Composite Models or Mock-ups

If tooth color and shape are to be enhanced by porcelain veneers, composite models are extremely useful. A major problem with diagnostictoolsisthatthey provide only atwo-dimensional plane. This limitation makes it difficult for the patient to imagine the profile, position of the lips and the effects that the restoration will have on the occlusal plane and phonetics. In order to produce undetectable porcelain veneers, careful observation of the dentition from all angles is vital and an eye for detail is essential. As Yamamoto has stated, we must train our eyes to observe the natural teeth and educate our hands to express exactly what our eyes perceive.[170] Composite models can be helpful forthose patients who seek restorations to mimic natural dentition and the supporting soft tissues. Prior to the treatment for misaligned and malformed anterior teeth, nonbonding composite additions can be effective for illustration of the final esthetic outcome. Optimized transference techniques are effective and valuable procedures that can be used to produce the perfect replica of the definitive restoration. This procedure provides for comfortable communication between the dentist and patient, and allows the artistic creation of the smile to take place through a trial-and-error designing process, until the dentist and patient are mutually satisfied.

When preparing the models, it is to the advantage of the dentist to use the same shades and veneer thickness planned for the final restorations. If the model is properly finished and polished, with close attention paid to the details of shape and texture, it can serve as a useful preview of the final result. This is especially important in determining the effect on the patient's smile, realigning the teeth with veneers, and in reducing or closing diastemata. In the case of the more demanding patients, the dentist must be honest in explaining to the patient that the clinician, the technical team, the dental materials, and the application techniques all have their limitations.

References

1. Rufenacht CR. Morphopsychology. In: Rufenacht, CR. Fundamentals of Esthetics. Chicago: Quintessence, 1990: 11-31,59-64.
2. Frush JP, Fisher RD. Introduction to dentogenic restorations. J Prosthet Dent 1955;5:586-595.
3. Nasedkin JN. Current perspectives on esthetic restorative dentistry. Part 1. Porcelain laminates. J Can Dent Assoc 1988;54:248-256.
4. Okuda WH. Resolve to recommit to excellence. AACD J 1997;Winter:2.
5. Stein H. Aesthetic color reproduction. Indep Dent 1999; July/August:65-66.
6. Goleman D, Goleman TB. Beauty's hidden equation. Am Health 1987;March.
7. Patzer GL. The Physical Attractiveness Phenomena. New York: Plenum Publishing, 1985.
8. Lombardi RE. The principles of visual perception and their clinical application to denture esthetics. J Prosthet Dent 1973;29:358-382.
9. Guerini VA. History of Dentistry from the Ancient Times until the Time of the Eighteenth Century. New York: Milford House, 1969.
10. Jarabak JR. Management of an Orthodontic Practice. St Louis, MO: Mosby, 1956.
11. Mack MR. Perspective of facial esthetics in dental treatment planning. J Prosthet Dent 1996;75:169-176.
12. Renner RP An Introduction to Dental Anatomy and Esthetics. Chicago: Quintessence, 1985:241-272.
13. Pilkington EL. Esthetics and optical illusions in dentistry. J Dent Assoc 1936;23:641-651.
14. Mack MR. Perspective of facial esthetics in dental treatment planning. J Prosthet Dent 1996;75:169-176.
15. Peumans M, Van Meerbeek B, Lambrechts P, Vanherle G. Porcelain veneers: A review of the literature. J Prosthet Dent 2000;28:163-177
16. Reinhart JW, Capiulonto ML Composite resin esthetic dentistry survey in New England. J Am Dent Assoc 1990; 120:541-544.
17. Brown LJ, Swango PA. Trends in caries: Experience in US employed adults from 1971-74 to 1985: Cross-sectional comparisons. Adv Dent Res 1993;7:52-60.
18. Johnson BD, Mulligan K, Kiyak HA, Marder M. Aging or disease? Periodontal changes and treatment considerations in the older dental patient. Geriodont 1989;8:109-118.
19. White BA, Caplon DJ, Weintraub JA. A quarter century of changes in oral health in the US. J Dent Educ 1995;59: 19-57
20. Marcus SE, Drury TR, Brown LJ, Zion GR. Tooth retention and tooth loss in the permanent dentition of adults: United States, 1988-1991. J Dent Res 1996;75 (special issue): 684-695.
21. Morley J. The role of cosmetic dentistry in restoring a youthful appearance. J Am Dent Assoc 1999;130:1166-1172.
22. Hornbrook DS. From the editor. AACD J 1997;Fall:2.
23. Rinaldi P. Simplifying anterior esthetics in the general practice. Contemp Esthet Rest Pract 2001 ;April 2001:1-6.
24. Smigel I. The non-surgical facelift. Contemp Esthet Rest Pract 2000;October:12-14.
25. Goldstein RE, Fritz M. Esthetics in dental curriculum. J Dent Ed 1981;45:355.
26. Goldstein RE, Lancaster JS. Survey of patient attitudes toward current esthetic procedures. J Prosth Dent 1984; 52:775-780.
25. Goldstein RE. Esthetics in Dentistry. 2nd ed. Hamilton, ON: BC Decker Inc, 1998:3-15.
27 Roulet J-F. Operative dentistry versus prosthodontics. In: Fischer J, Esthetics and Prosthetics. Chicago: Quintessence, 1999:101-120.
28. Karlsson S, Landahl I, Stegersjo G, Milleding P. A clinical evaluation of ceramic laminate veneers. Int J Prosthodont 1992;5:447-451.
29. Shaini FJ, Shortall ACC, Marquis PM. Clinical performance of porcelain laminates veneers. A retrospective evaluation over a period of 6.5 years. J Oral Rehabil 1997;24:553-559.
30. Kourkuata S, Walsh TF, Davis LG. The effect of porcelain laminate veneers on gingival health and bacterial plaque characteristics. J Clin Periodont 1994;21:638-640.
31. Pippin DJ, Mixon JM, Soldon-Els AP Clinical evaluation of restored maxillary incisors: Veneers vs. PFM crowns J Am Dent Assoc 1995;126:1523-1529.
32. Peumans M, Van Meerbeek B, Lambrechts P, Vuylstke-Wauters M, Vanherle G. Five-year clinical performance of porcelain veneers. Quintessence Int 1998;29:211-221.
33. Chiche GJ. The evolution of prosthodontic treatment. Pract Periodont Aesthet Dent 2000;12:94.
34. Rufenacht CR. Principles of Esthetic Integration. Chicago: Quintessence, 2000:169-240.
35. Trinkner TF, Roberts M. Anterior restoration utilizing novel all-ceramic materials. Pract Periodont Aesthet Dent 2000;12:35-37
36. Goldstein RE. Esthetics in Dentistry. 2nd ed. Hamilton, ON: BC Decker Inc, 1998:3-15.
37 Lee R. Esthetics and its relationship to function. In: Rufenacht CR. Fundamentals of Esthetics. Chicago: Quintessence, 1990:137-210.
38. Fischer J. Esthetics and Prosthetics. Chicago: Quintessence, 1999:1-30.
39. Pietrobon N, Paul S. All ceramic restorations: A challenge for anterior esthetics. J Esthet Dent 1997;9:179-186.
40. Zide MF. Evaluation of facial esthetics. JDC Dent Soc 1981;55:27
41. Lombardi RE. The principles of visual perception and their clinical application to denture esthetics. J Prosthet Dent 1973;29:358-382.
42. Renner RP. An Introduction to Dental Anatomy and Esthetics. Chicago: Quintessence, 1985:187-233.
43. Graber LW, Lucker GW. Dental esthetic self-evaluation and satisfaction. Am J Orthod 1980;77:163.
44. Hershon LE, Giddon DB. Determinants of facial profile self-perception. Am J Orthod 1980;78:279.

WWW.HIGHDENT.IR
همیار دندانسازان و دندانپزشکان

45. Spradley FL, Jacobs JD, Crowe DP. Assessment of the anterio-posterior soft-tissue counter of the lower facial third in the ideal young adult. Am J Orthod 1981 ;79:316.
46. Brigante RF. Patient assistant esthetics. J Prosthet Dent 1981;46:14.
47. Brisman AS. Esthetics: A comparison of dentists' and patients' concepts. J Am Dent Assoc 1980; 100:345.
48. Fischer J, Esthetics and Prosthetics. Chicago: Quintessence, 1999:1-31.
49. Rosenthal L, Rinaldi P. The aesthetic revolution: Minimum invasive dentistry. Dent Today 1998;17:1-4.
50. Nathanson D. Current developments in aesthetic dentistry. CurrOpin Dent 1991;1:206-211.
51. McLean JW. Evolution of dental ceramics in the twentieth century. J Prosthet Dent 2001 ;85:61-66.
52. Vines RF, Semmelman JO, Lee PW, Fonvielle FD. Mechanisms involved in securing dense, vitrified ceramics from pre-shaped partly crystalline bodies. J Am Ceram Soc 1958;41:304-308.
53. Weinstein M, Katz S, Weinstein AB. Fused porcelain-to-metal teeth. US patent 3052,982 (1962).
54. McLean JW. The science and art of dental ceramics. The nature of dental ceramics and their clinical use. Quintessence Int 1979;1:47.
55. McLean JW, Hughes TH. The reinforcement of dental porcelain with ceramic oxides. Br Dent J 1965;119:251-267.
56. MacCulloch WT Advances in dental ceramics. Br Dent J 1968;124:361-365.
57. McLean JW, Seed IR, The bonded alumina crown. 1. The bonding of platinum to aluminous dental porcelain using tin oxide coatings. Aust Dent J 1976;21:119-127.
58. Rogers OW. The dental application of electro-formed pure gold. 1. Porcelain jacket crown technique. Aust Dent J 1979;24:163-170.
59. Schwerin GB. German patents 274039 and 276244 (1910).
60. McLean JW. New dental ceramics and esthetics. J Esthet Dent 1995;7:141-149.
61. Anderson M, Oden A. A new all-ceramic crown. A dense-sintered, high-purity alumina coping with porcelain. Acta OdontScand 1993;51:59-64.
62. Wohlwend A. Vefahrenund ofen zur Herstellung von Zahnersatzteilen. European patent 0231773 (1987).
63. Miller M. Reality 2000. Houston: Reality Publishing, 2000;4:1-88.
64. Calamia JR. The etched porcelain veneer technique. NY State Dent J 1988;54:48-50.
65. Calamia JR. Clinical evaluation of etched porcelain laminate veneers. Am J Dent 1989;2:9-15.
66. Pincus CR. Building mouth personality. J South California Dent Assoc 1938;14:125-129.
67. Qualtrough AJE, Wilson NHF, Smith GA. The porcelain inlay: A historical view. Oper Dent 1990;15:61-70.
68. Buonocore MG. A simple method of increasing the adhesion of acrylic filling materials to enamel surfaces. J Dent Res 1955;34:849-853.
69. Kern M, Thomson VP. Tensile bond strength of new adhesive systems to Inceram ceramic. J Dent Res 1993; 72:369. Abstract 2124.
70. McLean JW. The science and art of dental ceramics. Bridge design and laboratory procedures in dental ceramics. Chicago: Quintessence, 1980;2.
71. Geller W, Kwiatkowski SJ. The Willi's glas crown: a new solution in the dark and shadowed zones of esthetic porcelain restorations. QDT 1987;11:233.
72. Lehner C, Mannchen R, Scharer P. Variable reduced metal support for collarless metal-ceramic crowns: A new model for strength evolution. Int J Prosthodont 1995;8:337-345.
73. Krejci I, Lutz F, Mdrmann W. Zahnfarbene adhasive Restaurationen im Seitenzahnbereich. Zurich: Eigenverlag PPK, 1998.
74. Rochette AL. A ceramic restoration bonded by etched enamel and resin for fractured incisors. J Prosthet Dent 1975;33:287-293.
75. Calamia JR, Simonsen RJ. Effect of coupling agents on bond strength of etched porcelain. J Dent Res. 1984; 63:179.
76. Studer S, Zellweger U, Scharer P. The aesthetic guidelines of the mucogingival complex for fixed prosthodontics. Pract Periodont Aesthet Dent 1996;8:333-341.
77. Magne P, Perroud R, Hotges JS, Belser UC. Clinical performance of novel-design porcelain veneers for the recovery of coronal volume and length. Int J Periodont Rest Dent 2000;20:440-457.
78. Rosenthal L. Clinical advantages of pressed ceramic restoration technology. Pract Periodont Aesthet Dent 1996;supplement.
79. Touati B, Miara P, Nathanson D. Esthetic Dentistry and Ceramic Restorations. New York: Martin Dunitz, 1999:161-214.
80. Strassler HE, Weiner S. Abstract reporting 96.4% success with 196 veneers up to 13 years, average 10 years. J Dent Res 1998;77:233.
81. Kihn PW, Barnes DM. The clinical longevity of porcelain veneers at 48 months. J Am Dent Assoc 1998; 129:747-752. Ceramco color logic veneers work well.
82. Yaman P, Qazi SR, Dennison JB, Razzoog ME. Effect of adding opaque porcelain on the final color of porcelain laminates. J Prosthet Dent 1997;77:136-140.
83. Horn HR. Porcelain laminate veneers bonded to etched enamel. Dent Clin North Am. 1983;27:271-284.
84. Simonsen RJ, Calamia JR. Tensile bond strength of etched porcelain. J Dent Res. 1983;62:297 Abstract 1154.
85. Strassler HE, Nathanson D. Clinical evaluation of etched porcelain veneers over a period of 18 to 42 months. J Esthet Dent 1989;1:21-28.
86. Rucker ML, Richter W, Macentee M, Richardson A. Porcelain and resin veneers clinically evaluated: 2-years result. J Am Dent Assoc 1990; 121:594-596.
87. Korukent S, Walsh TF, Davis LG. The effect of porcelain laminate veneers on gingival health and bacterial plaque characteristics. J Clin Periodont 1994;21:638-640.
88. Horn HR. Porcelain laminate veneers bonded to etched enamel. Dent Clin North Am. 1983;27:671-684.

WWW.HIGHDENT.IR
همیار دندانسازان و دندانپزشکان

89. Clyde JS, Gilmore A. Porcelain laminate veneers. A preliminary review. Br Dent J 1988;164:9-14.
90. Levin RP. The future of porcelain laminate veneers. J EsthetDent 1989; 1:45.
91. Goldstein RE. Diagnostic dilemma: To bond, laminate, or crown? Int J Periodont Rest Dent 1987;7:9.
92. Sorensen JA, Torres TJ. Improved color matching of metal-ceramic restorations. Part 3. Innovations in porcelain application. J Prosthet Dent 1988;59:1-7.
93. Sheets CG, Taniguehi T. Advantages and limitations in the use of porcelain veneer restorations. J Prosthet Dent 1990;64:406.
94. Chpindel P, Cristou M. Tooth preparation and fabrication of porcelain veneers using a double-layer technique. Pract Periodont Aesthet Dent 1994;6:19-30.
95. Christensen GJ. Have porcelain veneers arrived? J Am Dent Assoc 1991; 122:81.
96. Christensen GJ. Porcelain veneer update 1993. CRA Newsletter 1993; 17
97. Christensen GJ, Christensen RP. Clinical observations of porcelain veneers: A three-year report. J Esthet Dent 1991;3:174-179.
98. Nixon RL. Mandibular ceramic veneers: An examination of diverse cases integrating form, function and aesthetics. Pract Periodont Aesthet Dent 1995;1:17-28.
99. Strassler HE, Nathanson D. Clinical evaluation of etched porcelain veneers over a period of 18 to 42 months. J EsthetDent 1989;1:21-28.
100. Zappala C, Bichacho N, Prosper L. Options in aesthetic restorations: Discolorations and malformations. Problems and solutions. Pract Periodont Aesthet Dent 1994;6:43-52.
101. Fischer J, Kuntze C, Lampert F. Modified partial-coverage ceramics for anterior teeth: A new restorative method. Quintessence Int 1997;28:293-299.
102. Nakabayashi N, Kojima K, Masuhara E. The promotion of adhesion by filtration of monomers into tooth substrates. J Bio Mat Res 1982;16:265-273.
103. Van Meerbeek B, Vanherle G, Lambrechts P, Braem M. Dentin- and enamel-bonding agents. Curr Opin Dent 1992;2:117-127.
104. Pashley DH, Ciucchi B, Sano H, Horner JA. Permeability of dentin to adhesive agents. Quintessence Int 1993;24: 618-631.
105. Horn HR. Porcelain laminate veneers bonded to etched enamel. Dent Clin North Am. 1983;27:671-684.
106. McLaughlin G. Porcelain fused tooth. A new esthetic and reconstructive modality. Compend Contin Educ Dent 1984;5:430-435.
107. Weinberg IA. Tooth preparation for porcelain laminates. NY State Dent J 1989;55:25-28.
108. Anusavice KJ. Degradability of dental ceramics. Adv Dent Res 1992;6:82-89.
109. Schafer R, Kappert HF. Die chemische Lbslichkeit von Dentalkeramiken. Dtsch Zahnartzl Z 1993;48:625-628.
110. Newcomb GM. The relationship between the location of sub gingival crown margins and gingival inflammation. J Periodont 1974;45:151-154.
111. Janenko C, Smales RJ. Anterior crowns and gingival health. Aust Dent J 1979;24:225-230.
112. Chan C, Weber H. Plaque retention on restored teeth with full-ceramic crowns: Comparative study. J Prosthet Dent 1986;56:666-671.
113. Olsson J, van der Heijde Y, Holmberg K. Plaque formation in vivo and bacterial attachment in vitro on permanently hydrophobic and hydrophilic surface. Caries Res 1992; 26:428-433.
114. Hahn R, Weiger R, Netuschil L, Bruch M. Microbial accumulation and vitality on different restorative materials. Dent Mater 1993;9:312-316.
115. Quirynen M, Bollen CML. The influence of surface roughness and surface-free energy on supra- and subgingival plaque formation in man. A review of literature. J Clin Periodont 1995;22:1-14.
116. Walls AWG. The use of adhesively retained all porcelain veneers during the management of fractured and worn anterior teeth. Part 2. Clinical results after five-year follow-up. Br Dent J 1995;178:337-339.
117. Cornell DF. Ceramic Veneers: Understanding their benefits and limitations. QDT 1998;21:121-132.
118. Besler UC, Magne P, Magne M. Ceramic laminate veneers, continuous evolution of indications: J Esthet Dent 1997; 9:197-207
119. Sulikowski AV, Yoshida A. Clinical and laboratory protocol for porcelain laminate restorations on anterior teeth. QDT 2001;24:8-22.
120. Calamia JR. Etched porcelain facial veneers: A new treatment modality based on scientific and clinical evidence. NY J Dent 1983;53:255-259.
121. Horn HR. Porcelain laminate veneers bonded to etched enamel. Dent Clin North Am. 1983;27:671-684.
122. Dunne SM, Millar J. A Longitudinal study of the clinical performance of porcelain veneers. Br Dent J 1993; 175: 317-321.
123. Nortbo H, Rygh-Thoresen N, Henaugh T Clinical performance of porcelain laminate veneers without incisal overlapping. Three years' results. J Dent 1994;22:342-345.
124. Reid JS, Murray MC, Power SM. Porcelain veneers: A four-year follow-up. Rest Dent 1988: 60,62-4,66.
125. Jordan RE, Suzuki M, Senda A. Clinical evaluation of porcelain laminate veneers. A four-year recall report. J Esth Dent 1989;1:126-137
126. Friedman MJ. A fifteen-year review of porcelain veneer failure. A clinician's observations. Compend Contin Educ Dent 1998;19:625-636.
127. Giordano RA, Pelletier L, Campbell S, Prober R. Flexural strength of an infused ceramic, glass ceramic and feldspathic ceramic. J Prosthet Dent 1995;73:411-418.
128. Pameijer JHN. Onlays: Is gold still the standard? In: Degrange M, Roulet J-F. Minimally invasive restorations with bonding. Chicago: Quintessence, 1997:139-152.
129. Peumans M, Van Meerbeek B, Lambrechts P, Vanherle G. The five-year clinical performance of direct composite additions to correct tooth form and position. Part 1. Esthetic qualities. Clin Oral Invest 1997;1:12-18.

WWW.HIGHDENT.IR
همیار دندانسازان و دندانپزشکان

130. Peumans M, Van Meerbeek B, Lambrechts P, Vanherle G. The five-year clinical performance of direct composite additions to correcttooth form and position. Part 2. Marginal qualities. Clin Oral Invest 1997;1:19-26.

131. Eichner K. Einfluss von Bruckenzwischengliedem auf die Gingiva. Dtsch Zahnarztl Z 1975;30:639.

132. Mahonen KT, Virtanen KK, An alternative treatment for excessive tooth wear. A clinical report. J Prosthet Dent 1991;65:338-340.

133. Friedman M. Multiple potential of etched porcelain laminate veneers. J Am Dent Assoc 1987;115 (special issue):831-878.

134. McLaughlin G, Morrison JE. Porcelain fused to tooth: The state of the art. Rest Dent 1988;4:90-94.

135. Wildgoose DG, Winstanly RB, Van Noort R. The laboratory construction and teaching of ceramic veneers: A survey. J Dent 1997;25:119-123.

136. Dalloca LL, Demolli, U. A new esthetic material for laminate veneers: IPS-Empress. QDT 1994;17:167-171.

137 Isenberg BP, Essig ME, Leinfelder KF. Three years clinical evaluation of CAD-CAM restorations. J Esthet Dent 1992; 4:173-176.

138. Heymann HO, Bayne SC, Sturdevant JR, Wilder AD, Roberson TM. The clinical performance of CAD-CAM-generated ceramic inlays. J Am Dent Assoc 1996;127: 1171-1181.

139. Davis, BK, Aqulinio, SA, Lund, PS, Diaz-Arnold, AM, Denehy, G. Subjective evaluation of the effect of porcelain opacity on the resultant color of porcelain veneers. Int J Prosthodont 1990;3:567-572.

140. Davis BK, Scott JO, Johnston WM. Effect of porcelain shades on final shade of porcelain veneers. J Dent Res. 1991 ;70:475. Abstract 1671.

141. Davis, BK, Aqulinio, SA, Lund, PS, Diaz-Arnold, AM, Denehy, G. Subjective evaluation of the effect of porcelain opacity on the resultant color of porcelain veneers. Int J Prosthodont 1990;3:567-572.

142. Mormann WH, Link C, Lutz F. Color changes in veneer ceramics caused by bonding composite resin. Acta Med Dent Helv 1996;1:97-102.

143. Davis BK, Papcum LJ, Johnston WM. Effect of cement shade on final shade of porcelain veneers. J Dent Res 1991 ;70:297. Abstract 250.

144. Davis BK, Johnston WM, Saba RF. Kubelka-Munk theory applied to porcelain veneer systems using a colorimeter. Int J Prosthodont 1994;7:227-233.

145. Meijering AC, Roeters FJ, Mulder J, Creugers NH. Patients' satisfaction with different types of veneer restorations. J Dent 1997;25:493-497

146.Smigel I. Chancing facial contour with expert application of porcelain laminates. Dent Today 1988;7:5.

147 Rosenthal L, DiPilla RP. A simple technique for impression making, bite registration and fabricating provisionals. Post Grad Dent 2000;7:2-7

148. Rufenacht CR. Principles of Esthetic Integration. Chicago: Quintessence, 2000:63-169.

149. Gwinnett AJ. Effect of Cavity disaffection on bond strength to dentin. J Esthet Dent. 1992;4 (special issue): 11-13.

150. Rosenthal L. The state of the art in porcelain laminate veneers. Part 1. Simple cases. Esthetic Dent Update. 1991 ;2:5.

151. Tao S, Lowental U. Some personality determinants of denture preference. J Prosthet Dent 1980;44:10-12.

152.Geller W. A timeworn concept: reality or Utopia? Pract Periodont Aesthet Dent 1998;10:542-544.

153. Morley J. Critical elements for the preparation and finishing of direct and indirect anterior restorations. Contemp Esthet Dent 1997;3:1-6.

154. Glick K. In search of excellence. AACD J 1997;Fall:3.

155. Morley J. Critical elements for the preparation and finishing of direct and indirect anterior restorations. Contemp Esthet Dent 1997;3:1-6.

156. Golub-Evans J. Unity and variety: Essential ingredient of a smile design. Curr Opin Cosmet Dent 1994;2:1-5.

157 Levin RP. Patient personality assessment improves case presentation. Dent Ecom 1988;78:49-50,52,54-55.

158. Levin RP. Patient personality assessment improves case presentation. Dent Ecom 1988;78:49-50,52,54-55.

159. Yamamoto M, Miyoshi M, Kataoka S. Special Discussion. Fundamentals of esthetics: contouring techniques for metal ceramic restorations. QDT 1990/1991 ;14:10-81.

160. Crispin BJ. Segmented Reconstruction. AACD J 1997; Winter:42.

161. Drago CJ. Clinical and laboratory parameters in fixed prosthodontic treatment. J Prosthet Dent 1996;76:233-238.

162. Goldstein RE. Study of need for esthetic in dentistry. J Prosthet Dent 1969;21:589-598.

163. Feeley RT Cosmetics and the esthetic patient and laboratory communication. Oral Health 1995;85:9-12,14.

164. Levinson N. Psychological facets of esthetic dentistry: A developmental perspective. J Prosthet Dent 1990;64: 486-491.

165. Baratieri LN. Esthetics: Direct Adhesive Restoration on Fractured Anterior Teeth. Sao Paulo: Quintessence, 1998:270-312.

166. Moskowitz M, Nayyar A. Determinants of dental esthetics: A rationale for smile analysis and treatment. Compend Contin Educ Dent 1995:16:1164,1166,1186.

167 Cornell DF. Ceramic veneers: Understanding their benefits and limitations. QDT 1998;21:121-132.

168. Shillingburg Jr HT, Hobo S, Whitsett LD, Jacobi R, Brackett SE. Fundamentals of Fixed Prosthodontics. 3rd ed. Chicago: Quintessence, 1997;419-432.

169. Miller M. Reality 2000. Houston: Reality Publishing, 2000;Imaging Systems 14:315-324.

170. Yamamoto N. Metal-Ceramics: Principles and Methods of Makoto Yamamoto. Chicago: Quintessence, 1985.

WWW.HIGHDENT.IR
همیار دندانسازان و دندانپزشکان

2 Smile Design

Galip Gurel

Introduction

Esthetic dentistry is a delicate combination of scientific principles and artistic abilities. Mathematical parameters used by the dentist and the laboratory technician combine to produce an attractive esthetic appearance. However, these geometric laws must not be used mechanically; instead, they must act as guidelines for each clinical restoration.[1,2] Esthetic judgement is not an entirely objective criterion; the dentist must also consider the subjective concerns of the character and the life-style of the individual patient when designing a natural smile. Taking these criteria into account, the dentist and the dental team must then incorporate their own personal artistic abilities and their subjective feelings to create a smile. The creativity of the procedure makes each case unique and the dentist's job pleasingly varied and rewarding.

WWW.HIGHDENT.IR
همیار دندانسازان و دندانپزشکان



WWW.HIGHDENT.IR
همیار دندانسازان و دندانپزشکان

No two humans are alike in appearance and character and therefore each restoration should be designed according to a particular individual's needs and characteristics. This personalization is especially important in the restoration of the anterior teeth. With the increasing patient interest in esthetic dentistry, a need for a more thorough understanding of the esthetic principles has become apparent. The objective of this chapter is to review the "keys and pathways" to achieving a pleasant smile.

The primary elements of a beautiful smile are the teeth and therefore a sound knowledge of individual tooth forms and anatomy is the foundation of any treatment. The teeth are aligned and related to each other and to the surrounding soft tissues that act as their frames. To have a better feeling of what a beautifully designed smile is, the inner and outer edges of the individual outlines must be examined. Artists draw within a measured frame that is further defined with inner outlines and imaginary reference points, relating the parts to each other and, in turn, to the original frame. Esthetic dentistry is not very different from an artist's eye.[3-5] To achieve the best esthetic results in dentistry, we also should use "frames", "from the inside out": the line angles and axial inclinations that frame a single tooth, the gingival edge that frames the teeth, the lips that frame the teeth and gingiva, and, finally, the face that frames all these components and acts as the master or the original frame in which all the components interact in a natural or optimally restored dentition to present a pleasing and esthetic smile.

Other issues of concern are the objects, such as the teeth and gingiva, that can be termed as "static", and the lips and facial soft tissues that can be termed as dynamic or "mobile". To achieve a pleasant smile, some imaginary vertical or horizontal reference points must be used to relate these parts to each other in addition to certain phonetic references. These reference points may be the mid-line, the facial mid-line, the lip line, the commissural line, or the interpupillary line. All these structures exist in certain proportions and relations to one another and should never be isolated, but instead perceived as a whole in their total composition, and unique for each individual. The pleasant smile is perceived as harmonious only when the various lines, proportions, and structures are in visual balance with each other. The already existing status of the smile can be improved by changing these proportions, creating illusions, and minimizing the negative visual tension produced by improperly aligned teeth, gingiva, and the lips. To have a more thorough understanding of every element and the related factors, attention to detail must be exercised in all visual aspects of the dentition, analyzing each one separately and carefully.[6,7]

Mid-line

The facial mid-line is located in the center of the face, perpendicular to the interpupillary line.[8-11] It has been defined as a vertical line, drawn through the forehead, nose columella, dental mid-line, and chin.[5] It has also been referred to as the imaginary line that runs vertically from the nasion, subnasal point, interincisal point and the pogonion.[13] Heartwell defines the dental mid-line as an imaginary vertical line that does not necessarily coincide with the facial mid-line. The lingual papilla or the labial fraenum may be used as a placement landmark.[14] Ideally, the papilla between the maxillary central incisors coincides with the mid-line of the face.[15]

Observing the dynamics of a smile is the best way to visualize the dental mid-line. The space between the two maxillary central incisors appears most pleasing when observing the anterior dentition in a smile. Preferably, it should be centered between the left and right sides of the face. However, that does not necessarily mean that the dental mid-line will always coincide with the other features of the face.[16] In research conducted by *Bodden, Miller* and *Jamison,* it was statistically demonstrated that the maxillary mid-line coincided with the mid-line in 70% of cases, using the lip's philtrum as a reference guide. Their research revealed that slight deviations in the central mid-line did not necessarily compromise esthetics.[17] Moreover, it was found that the maxillary and mandibular mid-lines did not coincide

WWW.HIGHDENT.IR
همیار دندانسازان و دندانپزشکان

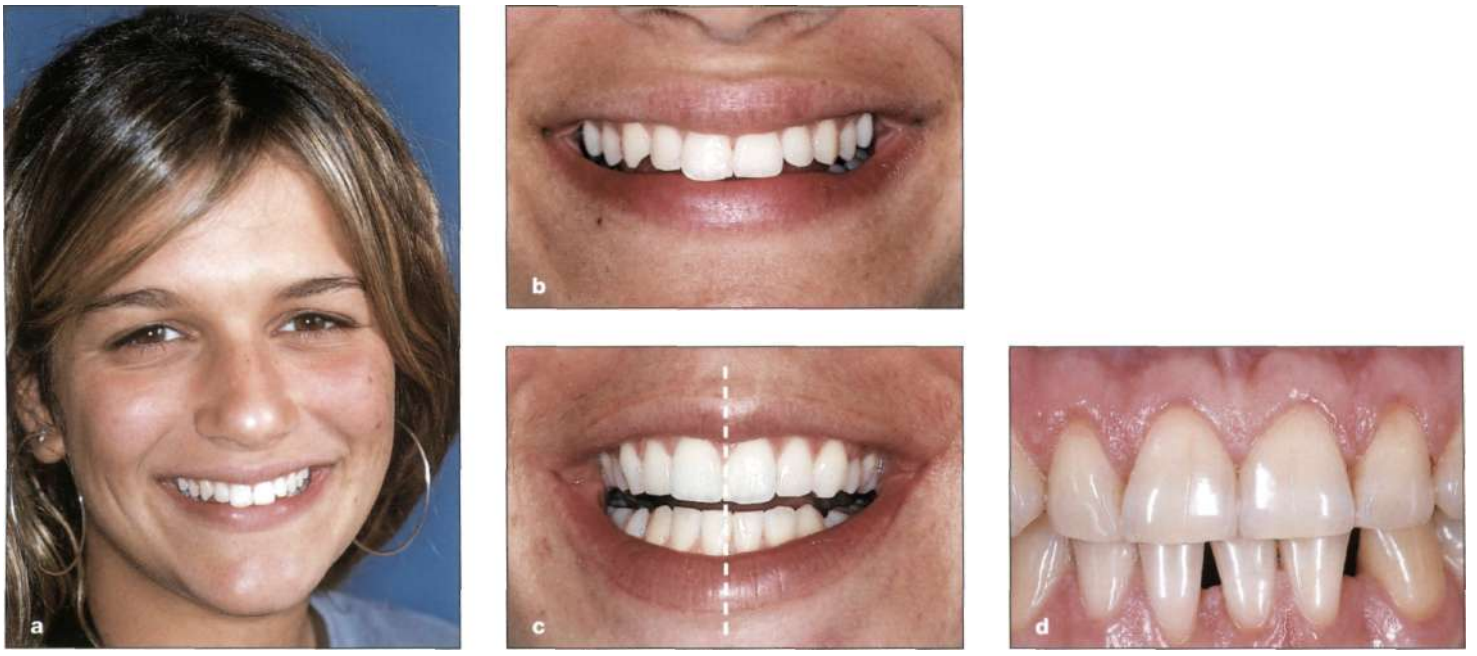

Fig 2-1 a-d (a, b) The dental mid-line is placed on the imaginary line, which is actually the facial mid-line in 70% of cases, (c) The mid-line can be slightly deviated to the right or left, when the lips" philtrum is used as a reference. This is true for 30% of the population. Slight deviations do not create visual tension nor do they affect the esthetics negatively, (d) A high percentage of the patients (as much as 75%) have mandibular mid-lines that do not coincide with the maxillary.

in 75% of the cases, demonstrating that the lower mid-line is not suitable as a reference forthe maxillary mid-line placement (Fig 2-1). However, as the mouth does not stay in a static position and the mandibular teeth are not that visible, this mismatch does not create an esthetically unpleasant appearance. Actually, this aspect is more important for the dentist because in the cases where the maxillary mid-line is lost (owing to tooth extraction, etc.), the dentist should avoid reliance on the mandibular mid-line in order to assess the maxillary mid-line.

Johnston et al. write: "In white and non-white groups of adults, the dental mid-lines of each group were found to match in less than 30% of the cases. However, as the mandibular teeth are not usually exposed while smiling, the mismatch of mid-lines does not affect the natural esthetic dentition. In esthetics, the mandibular mid-line is not of great importance. The visualization of the middle point often becomes difficult, owing to the narrowness and uniform size of the mandibular incisors."[18]

The parameters of symmetry and balance of the facial and dental mid-lines are the vectors for our esthetic appraisal. Not all patients have symmetric faces; they may even have chins or noses that are not centered, making it impossible to use them as landmarks for the facial mid-line. The left and right sides of the face, with all their variations, are not precise guidesfora geometrical division.[19] The natural appearance of the face as a whole does not influence our visual perception of the dental mid-line, even if the philtrum is off-center. However, if there is an overlap of the maxillary central incisors, or spacing owing to diastemas, they may affect the facial median line in relation to the mid-line. The dental mid-line should be right in line with the precise mid-line of the smile, which is in the center and coinciding with the symmetry of the dental composition.

Owing to the focus of attention that is naturally given to the face, any deviations in the maxillary dental mid-line in relation to the facial mid-line, as in the case of slanting, have the potential of creating a negative overall effect on the smile. The appearance of order and organization is made possible with a vertical dental mid-line.[20] The mid-line between the facial mid-line and maxillary central incisors should coincide whenever pos-

WWW.HIGHDENT.IR
همیار دندانسازان و دندانپزشکان

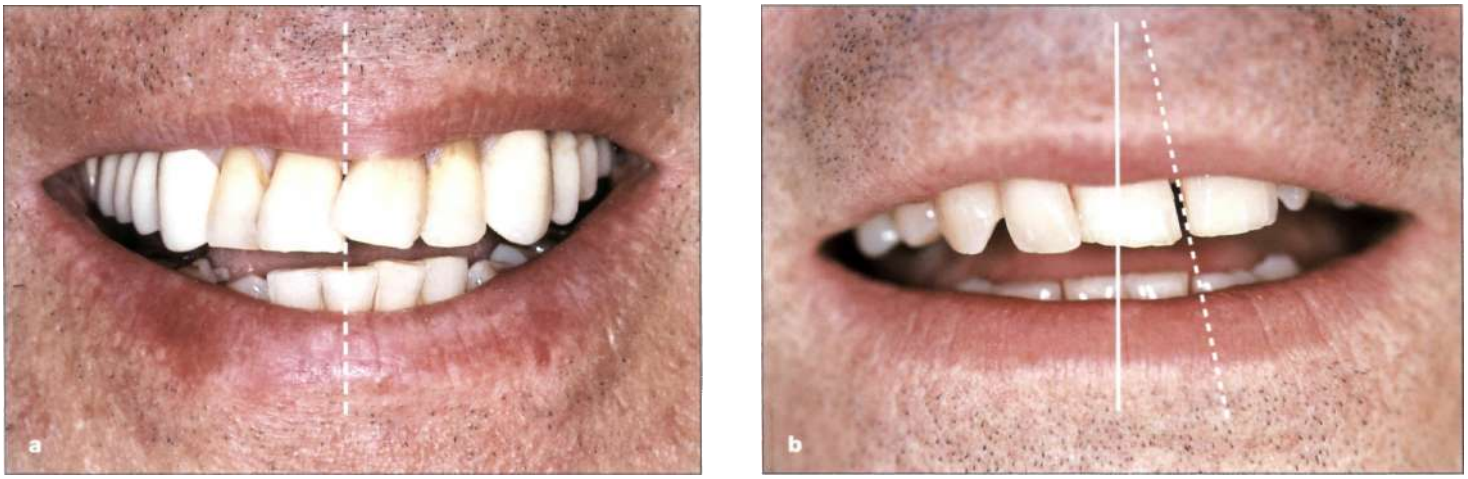

Fig 2-2a, b (a) A slanted mid-line, or a dental mid-line that is placed obliquely in relation to the facial mid-line, will always distort the symmetry, even when placed in exactly the correct position, (b) It looks even more unpleasant when it is slanted and shifted to the side at the same time.

sible.[21]-[22] In cases where the dental and facial mid-lines do not match, or are far apart, the dental mid-line should be kept perpendicular to the pupillary or horizontal lines, to prevent the illusion of asymmetry owing to an excessive right or left shift of the dental mid-line. Once it is straight, the composition will appear symmetrical or at least pleasing. Even if the mid-line is placed in the precisely correct position, and if it should happen to be oblique in relation to the facial mid-line, it will disturb the symmetry (Fig 2-2).[20] In any restored dentition, slanting is an unacceptable major flaw.[18] Therefore, the mid-line, which is the center of attraction, should be as perpendicular as possible to avoid any distortion.

Incisal Length

The incisal edge of the maxillary central incisor is the most important determinant in the creation of a smile. Once it is set, it serves to determine the proper tooth proportion and gingival level; therefore, setting the place of the incisal edge is especially important. Elongation of the incisal edge is often indicated to correct incisal wear, inadequate tooth display, or a displeasing tooth or crown proportion. To correct excessive tooth display, or a displeasing tooth or crown proportion, shortening the incisal edge may sometimes be required to compensate for unesthetic elongation created by periodontal recession. The position of the incisal edge acts asthe parameter upon which the rest of the treatment is built. Several reference teeth serve as the reference point for the correct incisal edge position for the remaining teeth.

The self-image of the patient and a desire for a dynamic and youthful appearance will determine just how prominent or noticeable a smile is desired.[23] The age and gender of the patient, along with the length and curvature of the upper lip, will determine the length of the incisal edge.[24] Average anatomic crown length values for the maxillary central incisor range from 10.4 to 11.2 mm.[25] For young patients who do not have fully erupted teeth, a semi-permanent restoration, such as a composite application, is preferable .

Once the eruption is complete, a definitive restoration can be performed to establish the tooth length. A central incisor that is not visible when the lips are at rest, but can be seen when smiling, tends to render an older appearance to the dentition. Similarly, a young smile can be achieved when the upper front teeth are lengthened. Therefore, one of the most important factors in dental esthetics is the visibility of the teeth when the mandible and lips are at rest. It is not only the form and position of the teeth, but the

WWW.HIGHDENT.IR
همیار دندانسازان و دندانپزشکان

Incisal edges showing through the lips at rest position

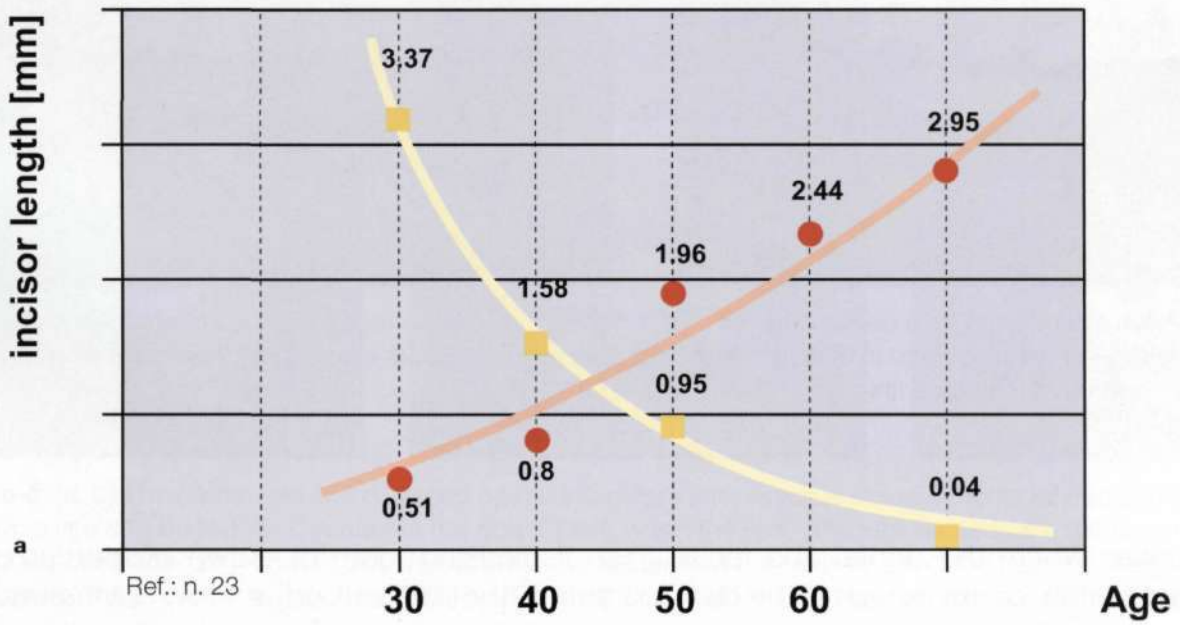

maxillary teeth

mandibular teeth display

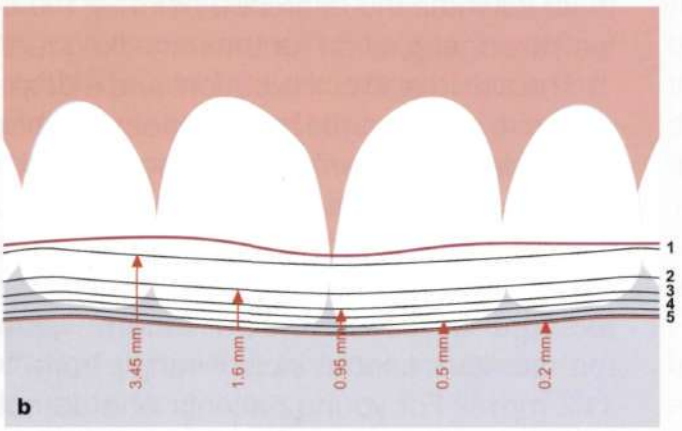

1. lip line 30 years (3.45 mm)
2. lip line 40 years (1.60 mm)
3. lip line 50 years (0.95 mm)
4. lip line 60 years (0.50 mm)
5. lip line 70 years (0.20 mm)

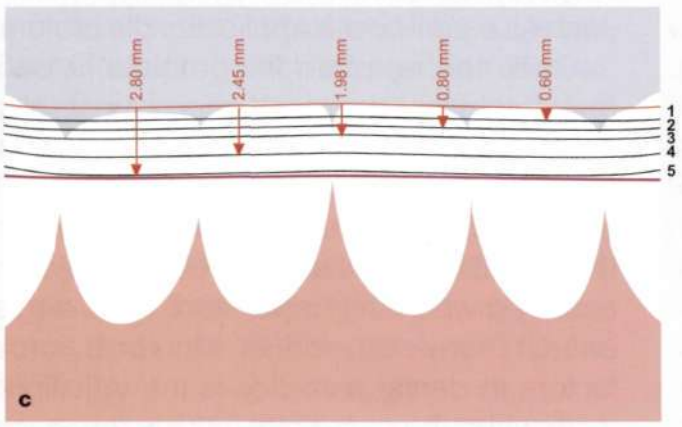

1. lip line 30 years (0.60 mm)
2. lip line 40 years (0.80 mm)
3. lip line 50 years (1.98 mm)
4. lip line 60 years (2.45 mm)
5. lip line 70 years (2.80 mm)

WWW.HIGHDENT.IR
همیار دندانسازان و دندانپزشکان

Fig 2-3a-c (a) The diagram showing the inverse proportion of tooth display between the maxillary and mandibular incisors, related to age.[45,116] (b) As people age, less incisal length is displayed. The reduced display is owing to the sagging of the upper lip, and the reduction is further increased by the incisal tooth wear, (c) In the mandibular arch, even though some incisal wear does exist, the lower tooth display increases as the muscle tone of the lower lip decreases and sags down owing to gravity.[89]

Fig 2-4a, b (a) While seated in an upright position, the patient is asked to repeat the "M" sound several times. In so doing, the lips relax, and the dentist can readily observe the incisal edge position of the lips at rest. When the "M" sound is pronounced, the lips come together, (b) After the "M" sound, the lips part in the rest position.

muscle tone and skeletal build-up that are important as well.[29]

It may happen occasionally that the incisal edge has been compromised, or that it is necessary partially to rebuild erupted central incisors. The difficulty is in determining the size of thetooth, as there is no defined landmark from which to proceed. Without this tooth of reference, the dentist must use the upper and lower lips, and the exposed portion of the teeth as the reference points.

When the mouth is slightly open, approximately 3.5 mm of the incisal portion of the maxillary teeth is visible in a 20-year-old person, while the mandibular teeth are barely visible. As age increases, the muscles become lax and slowly diminish the display of the maxillary incisors, while the visibility of mandibular incisors increases. The dentofacial plane that is exhibited in youth is permanently changed, and although it may vary from individual to individual, the degrading process is unfortunately irreversible. This laxness first appears at approximately the age of 30 to 40 years and continues to increase with each passing year.

A study has shown that there may be many variables in the lip length and, therefore, in the visible length of the incisal teeth, depending on gender, racial factors and age. In the young female, the exposure of the maxillary central incisors can be as much as 3.40 mm, with a minimum of 0.5 mm for mandibular incisor exposure. Between the ages of 30 and 40 years, mandibular incisor exposure increases while the maxillary tooth length exposure decreases (Fig 2-3).[45]

Tooth exposure is determined by muscle position, yet the restorative dentist often disregards it. Phonetic values, and the experience of the clinician, were often the determining factors for the prosthodontist when deciding the relationship between the lips and the incisal edges. It was assumed that these factors could determine the

WWW.HIGHDENT.IR
همیار دندانسازان و دندانپزشکان

Fig 2-5 The position of the incisal edges during the "E" sound is another important parameter. Under normal circumstances, a pleasing incisal edge position is centered between the upper and lower lips when the patient is asked to say "Eeeeee".

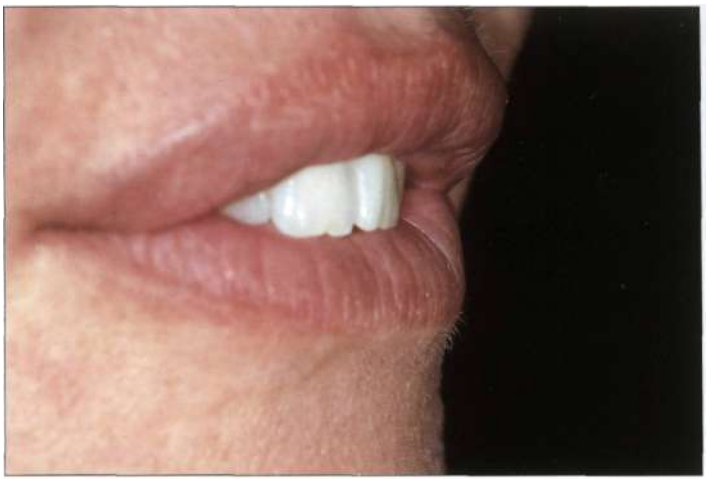

Fig 2-6 "F" and "V" sounds are used to locate the length of the incisors and the buccal lingual position of the incisal edges. While reducing these sounds, the incisal edge should be gently contracting the vermillion border of the lower lip. The length of the incisal edges can be observed from the facial aspect and from the profile the buccal lingual placement of the incisors can be evaluated.

correct position of the maxillary anterior incisors in the vertical plane.

The lips and teeth have a different position and relation for each sound that is made. The evaluation of the relationship between both dental arches and the lips will be the instrumental approach in determining this point of reference. The clinician is not basing the decision solely on esthetic factors, but also on the relation of the incisal edge to the anterior guidance and phonetics. This is especially true in determining the length of the maxillary incisors, which play an important role in the anterior guidance and phonetics. While seated in an upright position, the patient is asked to produce the "M" sound several times. When the lips relax, the dentist can observe the incisal edge position of the lips at rest. After pronunciation ceases, the lips return to the relaxed rest position for evaluation. Repetition of this sound will enable the patient to relax between producing each sound, allowing the dentist to evaluate the amount of incisal tooth displayed in the rest position (Fig 2-4).[25]

The amount of incisal tooth display may vary from individual to individual. The length of the display depends on the length of the upper lip and the age of the patient.[45] The "E" sound is another important parameter when evaluating the length of the teeth and the incisal line. The maxillary teeth should be displayed halfway between the upper and lower lip lines while forming this sound (Fig 2-5). The patient is asked to say "Eeeeee" for a few seconds so that the dentist can observe the position of the maxillary incisors.

The length and the lingual tilt of the incisal third of the maxillary central incisors are used to determine the fricative "F" and "V" sounds. To produce these sounds, the maxillary incisors must press against a slightly retracted lower lip partially to block the remaining air stream. The wet-dry line of the vermilion border of the lower lip is the location of the incisal edge for the maxillary incisors in most individuals. The correct labiolingual position and the length of the anterior teeth should enable the patient to produce the "F" sound by placing the incisal edges against the inner edge of the vermilion border of the lower lip (Fig 2-6).[30–33] During this evaluation, the buccolingual placement of the upper maxillary incisors is also evaluated. The "F" and "V" sounds should also be used to determine the superior/inferior length of the incisal edge.[33]

WWW.HIGHDENT.IR
همیار دندانسازان و دندانپزشکان

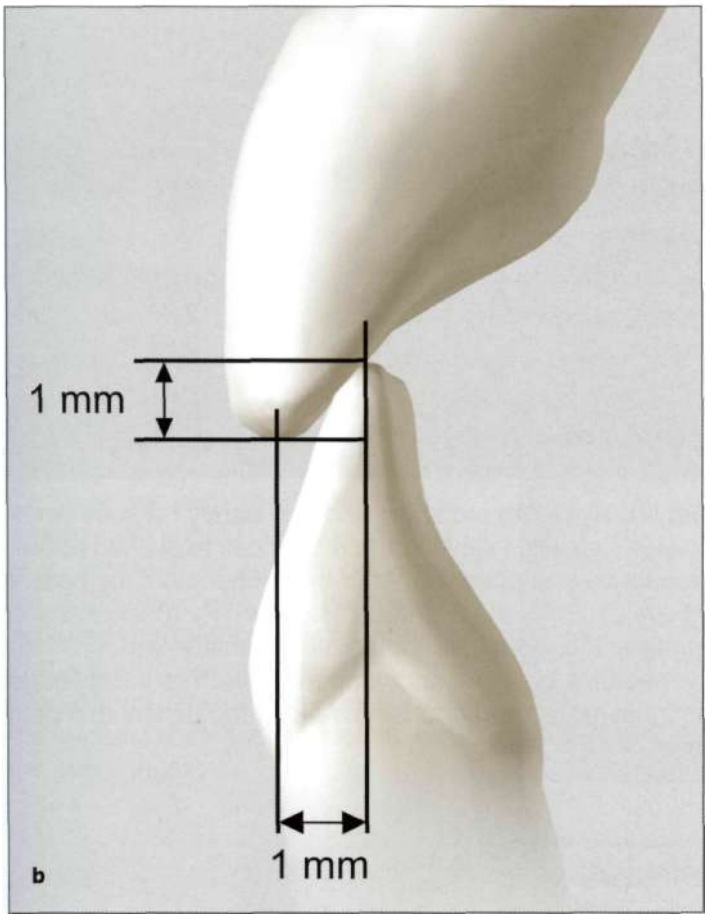

Fig 2-7a, b (a) The "S" sound is used to determine the vertical height of dimension. (This is used for fabrication of complete dentures while checking the vertical height.) For the veneers, this parameter is used to check the relation of the maxillary and mandibular teeth, (b) The mandibular incisals should be in gentle touch with the palatal surfaces of the mandibular incisors, being 1 mm behind and 1 mm below.

In cases where porcelain is used in the form of onlay veneers for premolars and molars and for the purpose of correcting the vertical height of dimension, the pronunciation of the "S" sound is of crucial importance. The vertical dimension of speech is determined by the "S" sound formation, when all teeth should be in light contact.[34] During the pronunciation of the "S" sound, the incisal edges of the mandibular incisors establish occlusal contact with the maxillary incisors owing to their position, which is 1 mm behind and 1 mm below the edges of the maxillary teeth (Fig 2-7).[32]

Whilethe maxillary teeth can be placed according to these parameters, minor differences in the height of the central and lateral incisors add vitality and dynamics to the total frame. The lateral incisors should be approximately 1 mm above the gently curved horizontal line that is shared by the incisal edges of the maxillary central incisors and the cusp tips of the canines. The positioning of the incisal edge is open to subjectivity, and the input of the patient is vital for the final decision.

Composite resin models or mock-ups of the desired length, computer imaging, diagnostic waxing, provisional restorations, and trial porcelain laminate veneertooth set-ups should be used as aids and guides for communication with the patient (Fig 2-8). Assessment of the desired crown length and a preview of the proper incisal edge are some of the factors aiding in the final decision. To achieve attractive maxillary central incisor proportions, the gingival position must be adequate; and if it is not, it can be surgically or orthodontically altered (see Chapters 11 and 12).[24]

Zenith Points

The so-called zenith points are the most apical points of the clinical crowns; which are the height of contour. Their positions are dictated by the root-form anatomy, cementoenamel junction (CEJ), and the osseous crest, where the gingiva is scalloped the most. The zenith points are generally located just distal to a line drawn vertically through the middle of each anterior tooth. The lateral

WWW.HIGHDENT.IR
همیار دندانسازان و دندانپزشکان

Fig 2-8a-d (a) The relation of the maxillary incisors to the upper lip. The teeth are short and can barely be seen when the lips are in rest position, (b) A rough composite model ("mock-up") is built, following the references explained above. It is a good communicative and educational tool, (c) The provisionals prior to polishing. After the preparation, the patient is dismissed. The provisional restorations are a helpful in-patient evaluation of the eventual restoration for functional and esthetic purposes. If the patient is pleased with the evaluation, the definitive porcelain laminate veneers can be fabricated, (d) The definitive restoration (porcelain laminate veneers), a beautiful and youthful smile. The incisal edge position is centered exactly where it should be, allowing the functional moves and apprising. Asking the patient to repeat the "M", "E", "F", and "S" sounds can identify this exact position.

Fig 2-9 The zenith points are the most apical points of the clinical crowns. They are usually placed distally, when viewed from the facial aspect. Only the lateral incisors do not abide by this rule; in the laterals, they are placed centrally.

WWW.HIGHDENT.IR
همیار دندانسازان و دندانپزشکان

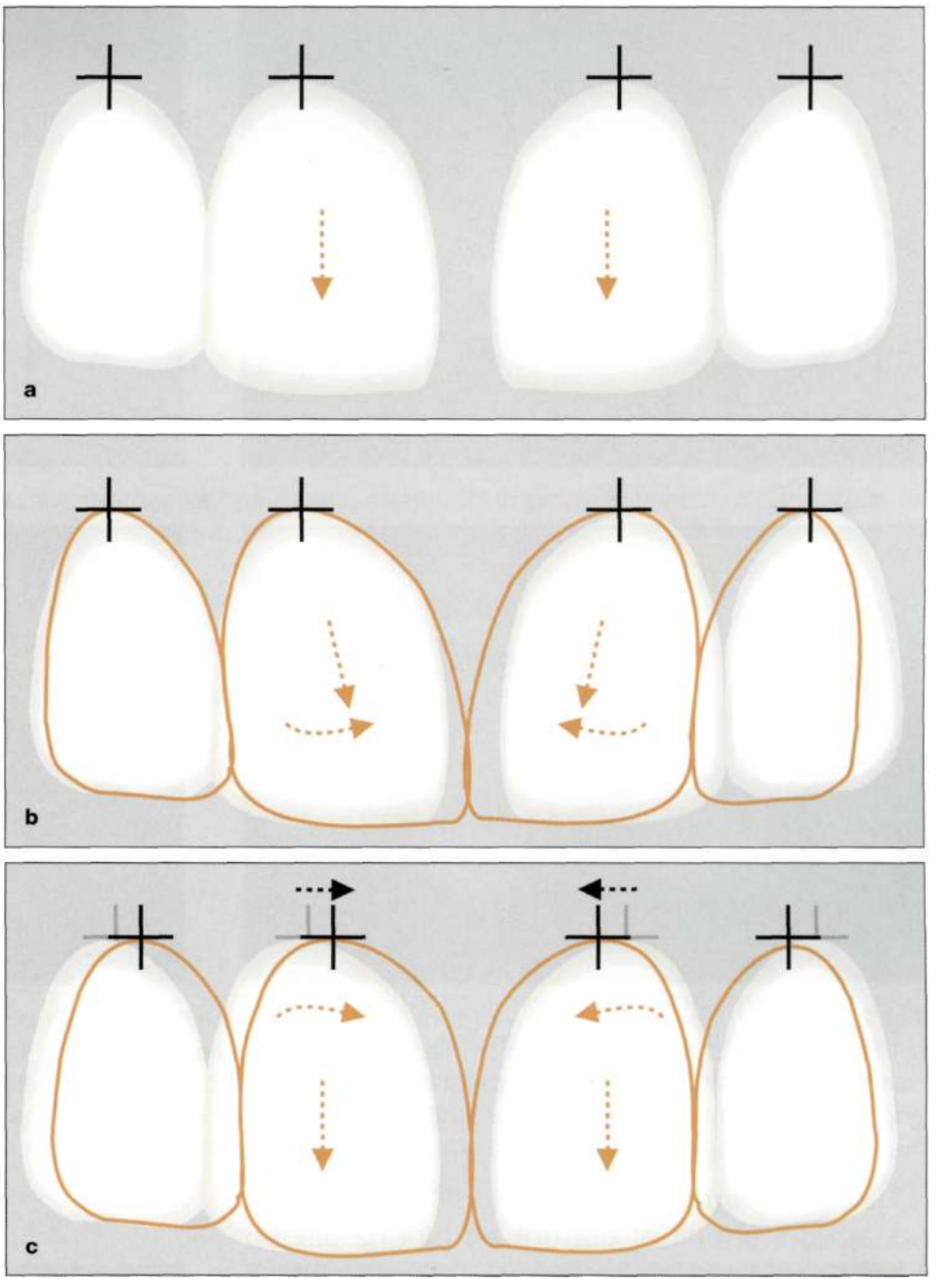

Fig 2-10a-c When closing diastemas, the zenith points should be repositioned to avoid a mesially tilted appearance, (a) Preoperative view of the zenith points in their originally correct position—slightly distal to the central incisors and in the middle of the laterals, (b) When the diastema is closed, the distal portions of the central and lateral incisors are cut down and porcelain is added to the mesial aspects of the incisors for a proportional restoration (see Chapter 9). (c) Together with the veneers, the zenith points should be moved mesially to where they should be when the diastema is closed. This can be achieved with minorgingival alteration at the time of, or prior to, the tooth preparation. The illustration shows the mesially shifted zenith points with the new veneers.

incisors are one exception to that rule, as their zenith points are placed more centrally or on the mid-line of the tooth margin (Fig 2-9).[35–37] The positions of the zenith points gain importance when closing diastemas or changing the distal or mesial tilted position of the teeth. In the case of diastema closure, if the zenith points are not moved mesially from their originally existing positions,thefinished porcelain laminate veneers may give the perception of being mesially tilted. In addition, the extreme distal positions of the gingival zeniths will result in an exaggerated triangular form.[38] To prevent these occurences and to create an illusion of bodily shifted central incisors towards the mid-line, the zenith points should also be moved mesially (Figs 2-10 and 2-11).

These are examples of moving the zenith points horizontally. In the case where the tooth needs to be shown longer or more tapered at the gingival 1/3rd, the zenith points can be moved apically (Fig 2-12). Such an apical movement obtains a triangular shape. An equilateral triangle will always appear longer in height than in width and this also proves that a tapered tooth

WWW.HIGHDENT.IR
همیار دندانسازان و دندانپزشکان

Fig 2-11a-d (a) Preoperative view of a diastema case, where the zenith points are located at their original positions, (b) The "gummy smile" is corrected by placing the gingival tissues apically. The positions of the zenith points are altered horizontally forwards, in the mesial direction, (c) The distal portions of the central and lateral incisors and the canines, by adding porcelain to the material used. Combined with a mesial shift of the zenith points, a pleasing natural effect is created, (d) Postoperative view of the horizontal shift of the zenith points. Even though large gaps have been closed with porcelain veneers, the final outcome is natural.

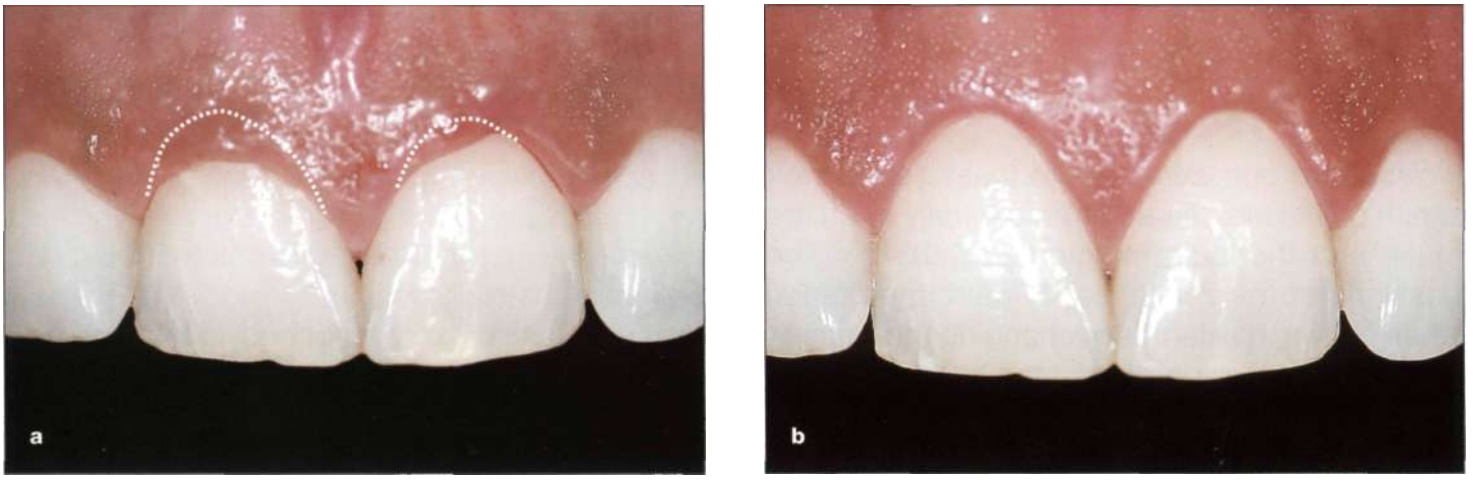

Fig 2-12a, b (a) Short teeth can be made to appear longer by carrying the zenith points further apically. (b) This rounded shape of the gingival portion is changed into a more triangular shape. The rounded gingival silhouette of the incisals is broken and an illusion of longer teeth is created.

WWW.HIGHDENT.IR
همیار دندانسازان و دندانپزشکان

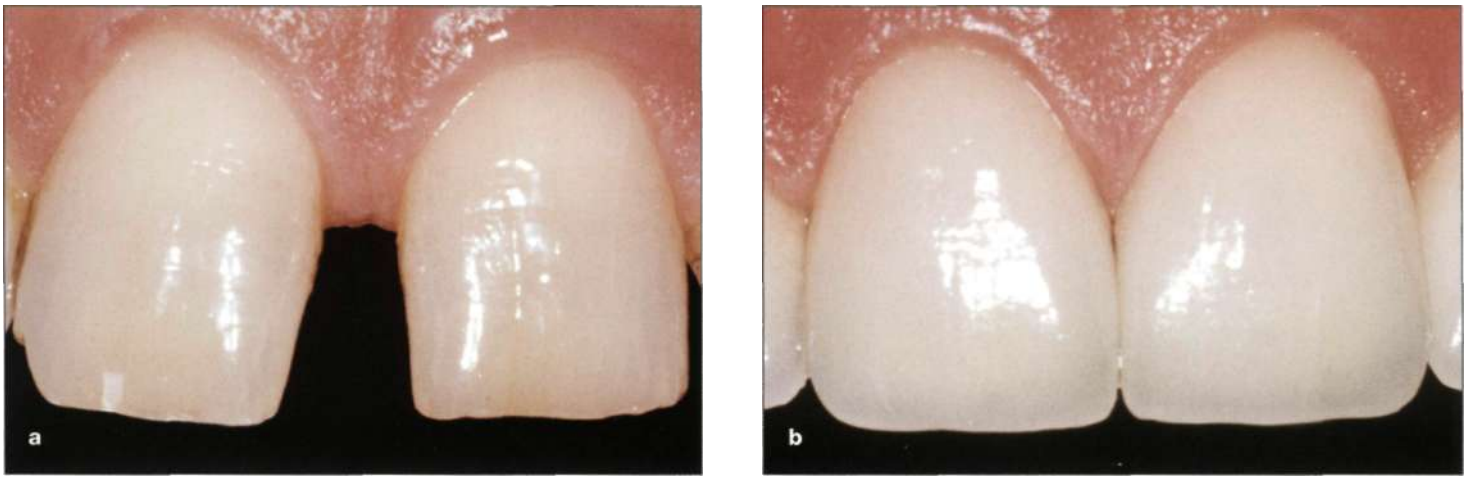

Fig 2-13a, b (a) When a diastema is present, the papilla has a blunt shape, (b) If properly treated, it can regain its natural crisp triangular form. View of a blunt, horizontally aligned appearance of the papilla is altered with custom-designed porcelain laminate veneers.

design will make the tooth seem longer than it is. This procedure should therefore be used with shorter teeth, where elongation towards the apical direction is required. Consequently, zenith points can enhance the perception of the tooth axis as well as the length and the gingival shapes, which can be achieved by horizontal or vertical alterations.

Gingival Health and Interdental Embrasures

The gingiva is normally pale in color and extends to the cementoenamel junction, forming a static frame for the teeth.[38] Healthy interdental papillae should be thin and terminate on the tooth in a knife-edged contour. The interdental papillae should form a pyramid-shaped confluence of the gingiva margin of the adjacent teeth (Fig 2-13).[24] The level of healthy gingiva is dictated by the position of the alveolar bone beneath it.[39-42] Healthy gingiva lies 3 mm away from the intact bone on the facial aspect and the tip of the stable papilla maintains a distance of 5 mm from the intercrestal bone (see Chapter 6).

The notions of "beautiful" or "ugly" are subjective ones. However, in the case of the health of the tissue, they are objective. The gingiva must always be healthy and sound (Fig 2-14). The initiation of prosthodontic treatment should be postponed until the health of the gingival tissue has been sufficiently reinstated. The postponement will allow the clinician to assess the inflammation and devise treatment and it will also allow the clinician to examine the position of the gingiva when the hypertrophic soft tissue shrinks. Once in a healthy state, the tissue must be scalloped to follow the contours of the underlying bone. The papilla should be formed to fill the interdental embrasures in a crisp triangular shape, and the design of porcelain laminate veneers should complete the closure. The esthetic harmony can be reinstated only with a healthy dentogingival complex (see Chapter 12).[44]

In some patients, healthy gingiva may show irregularities or asymmetries whereas in other cases gingival asymmetry can be the result of hypertrophic inflammation that will disappear after a routine periodontal treatment or prophylaxis. As the gingiva acts as a frame for the teeth, such irregularities will affect the final esthetic result, especially in patients with high and medium lip lines.

Trauma at an early age may impede normal tooth eruption. It may cause altered passive

WWW.HIGHDENT.IR
همیار دندانسازان و دندانپزشکان

Fig 2-14a, b (a) The initiation of the prosthodontic treatment should be postponed until the health of the gingival tissue has been reinstated. The postponement will allow the clinician to assess the inflammation and devise treatment; it will also allow the clinician to see the position of the gingiva when the hypertrophic soft tissue shrinks, (b) Once the tissue has returned to its healthy state, the gingival scallops, the position of the papilla, the zenith points, and gingival asymmetries are evaluated and porcelain laminate veneers are applied (11 years post-operative view).

Fig 2-15 The tooth may migrate incisally. If the cause is wear the tooth may erupt towards the area of wear, bringing the gingival tissue down incisally. This makes the tooth appear shorter and creates a gingival asymmetry.

eruption and result in abnormal habits and wear owing to bruxism. It is important for the dentist to obtain a thorough dental history that will help him/her to discover the factors that may have caused the gingival asymmetries (Fig 2-15). For these particular cases, the gingival levels should be altered with special care (see Chapter 12). There may also be some intragenic factors that cause the scalloped formation of the gingiva to disappear.[44] In order for the mind to register a horizontal line, a simple movement of the eye is required, whereas the registration of an undulating line demands an up and down ocular movement, which may not leave time for the appreciation of its characteristics, required to generate an esthetic appeal.[44] Such an unscalloped horizontal gingival architecture should be altered, in order to achieve an undulating appearance, by moving the zenith points apically.

Gingival Levels and Harmony

The gingival line runs parallel to the bipupillary line, which should be parallel to the canine line with a tangent through the incisal edges of both

WWW.HIGHDENT.IR
همیار دندانسازان و دندانپزشکان

Fig 2-14a, b (a) The initiation of the prosthodontic treatment should be postponed until the health of the gingival tissue has been reinstated. The postponement will allow the clinician to assess the inflammation and devise treatment; it will also allow the clinician to see the position of the gingiva when the hypertrophic soft tissue shrinks, (b) Once the tissue has returned to its healthy state, the gingival scallops, the position of the papilla, the zenith points, and gingival asymmetries are evaluated and porcelain laminate veneers are applied (11 years post-operative view).

Fig 2-15 The tooth may migrate incisally. If the cause is wear the tooth may erupt towards the area of wear, bringing the gingival tissue down incisally. This makes the tooth appear shorter and creates a gingival asymmetry.

eruption and result in abnormal habits and wear owing to bruxism. It is important for the dentist to obtain a thorough dental history that will help him/her to discover the factors that may have caused the gingival asymmetries (Fig 2-15). For these particular cases, the gingival levels should be altered with special care (see Chapter 12). There may also be some intragenic factors that cause the scalloped formation of the gingiva to disappear.[44] In order for the mind to register a horizontal line, a simple movement of the eye is required, whereas the registration of an undulating line demands an up and down ocular movement, which may not leave time for the appreciation of its characteristics, required to generate an esthetic appeal.[44] Such an unscalloped horizontal gingival architecture should be altered, in order to achieve an undulating appearance, by moving the zenith points apically.

Gingival Levels and Harmony

The gingival line runs parallel to the bipupillary line, which should be parallel to the canine line with a tangent through the incisal edges of both

WWW.HIGHDENT.IR
همیار دندانسازان و دندانپزشکان

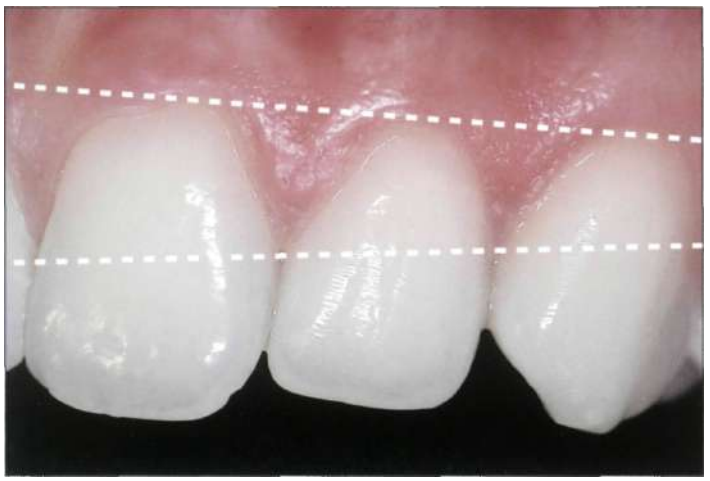

Fig 2-16 The tips of the papilla gradually follow a pattern in the apical direction, when proceeding from the anterior towards the posterior dentition, thus the volume of the gingival embrasures is getting smaller.

Fig 2-17 Nicely scalloped gingival contours. The pleasing relationship of the gingival levels (previously determined by the zenith points) should create a shallow reverse triangle *(Magne* P). The apex of the triangle (zenith point of the lateral incisor) is 0.5 to 1 mm, positioned incisally.

canines. The appropriate position and curvature of the incisal edges in conjunction with the lower lip line, and the determined correct length of the maxillary teeth, will determine the correct vertical position of the gingival line.[9,45]

The most incisally positioned portion of the gingiva is the tip of the papilla between the maxillary central incisors, which gradually assumes a more cervical position to the canine, premolar, and molar (Fig 2-16).[46] The width and height of the gingival arcade, which is to be the triangle between the zenith points and the tip of the papilla, depend upon the corresponding gingival morphotype, forming a high or low scalloped gingiva.[47]

When the zenith points of the maxillary incisors and the canines of a natural smile are followed, it is readily observed that they are not aligned on an imaginary straight line. Usually, the zenith points of the lateral incisors are 0.5 to 1 mm below those of the central incisors and canines, while the zenith points of the canines and central incisors remain on the same horizontally drawn imaginary line. This relationship of the zenith points actually forms a type of an imaginary triangle (Fig 2-17).

The angles or the depth of this triangle do not follow any rules. Any kind of triangle in which the zenith of the lateral incisors stays below will usually reflect a pleasant relationship. If the teeth are aligned on a straight line, it is an indication of high lateral zenith point placement and in some cases this display is a reversed or inverted triangle, where the gingival level of the lateral incisor is placed even more apically than the central incisor and the canines, creating an unesthetic configuration. This will affect the gingival harmony, but also result in short lateral incisors, with relatively correct proportions. If the laterals are lengthened without altering the gingival level, long laterals with the correct incisal edge position but unpleasant proportions will appear (Fig 2-18). There may be irregularities when the gingival level of the canine or central incisor is placed above or below these indications.

As observed posteriorly, gingival gradation can occur. Gingival gradation is a gradual decrease in height of the gingival outline from the canine back to the second molar.[48] This event is displayed in an architectural gradation in perspective. Owing to the palatal inclination of the premolars, the gingival tissue may be perceived as longer than it actually is.

Another condition that creates unpleasant esthetics is the appearance of a "gummy smile". It is important to determine its etiology as it may be caused by any variety of problems. It may be associated with the overgrowth of the maxilla (Fig 2-19) or it may also be owing to a high lip line

WWW.HIGHDENT.IR
همیار دندانسازان و دندانپزشکان

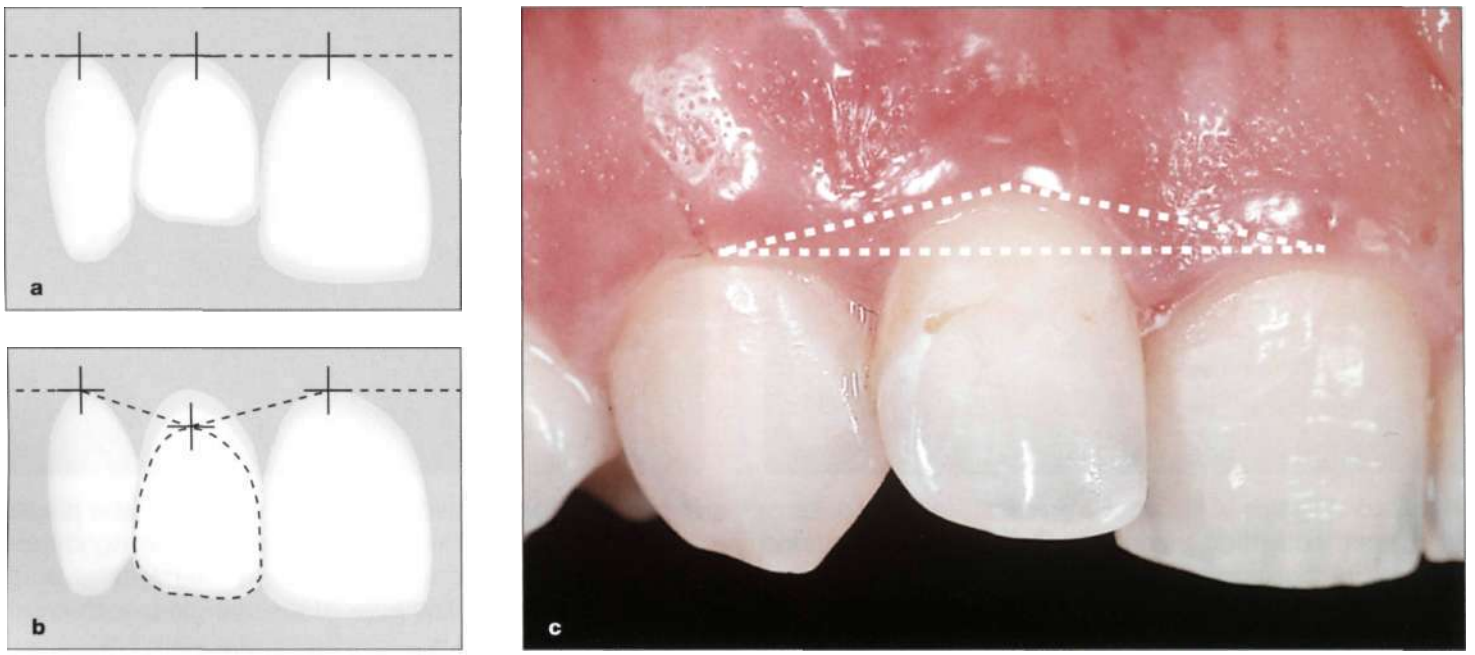

Fig 2-18a-c (a) When the zenith points are level, the gingival harmony is distorted. If the lateral incisors have not erupted properly, the length of the lateral incisors is shorter, (b) An attempt to correct the length of the lateral incisor without changing the position of its zenith point incisally will result in a longer tooth and a loss of proportion, (c) When the apex of the lateral incisor is placed more apically, the gingival relationship is totally distorted. This may happen owing to a facially positioned lateral incisor that forces the gingival level apically.

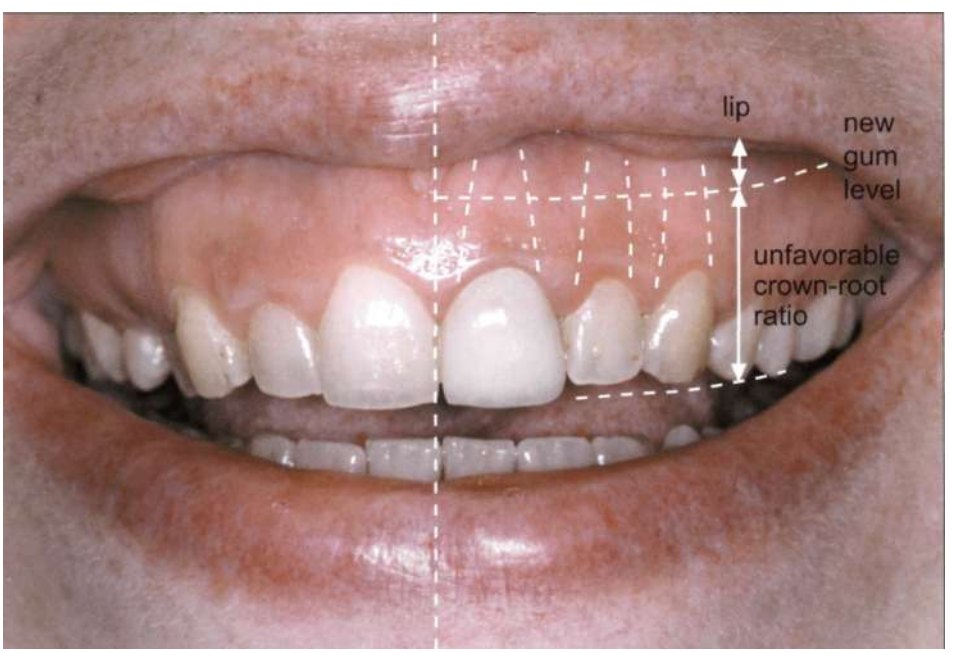

Fig 2-19 When the "gummy smile" is caused by maxillary overgrowth, the choice of the treatment is maxillofacial surgery. The gingival display exceeds 10 mm; any effort to treat this case merely by periodontal means will result in nonproportional root-crown ratios.

WWW.HIGHDENT.IR
همیار دندانسازان و دندانپزشکان

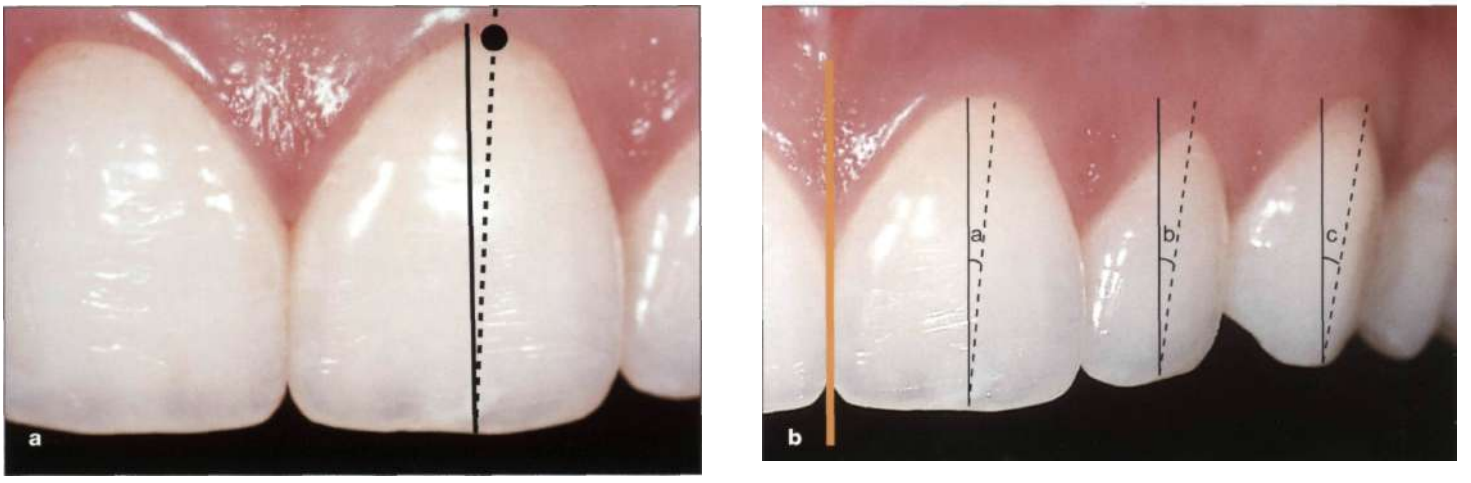

Fig 2-20a, b (a) The tooth axis of the central incisors may be positioned slightly distally towards the apex when compared to the vertical midline, (b) In comparison to central incisors, the laterals exhibit a more distal inclination towards the apex. The lateral incisors are asymmetric in a pleasing smile and can display different axial inclinations. The angle, formed between the imaginary axis of the centrallateral aspect, may be different on both sides. Note that angles a <b<c.

or altered passive eruption, which can be the primary cause for the appearance of short clinical crowns and excessive gingival display. Altered passive eruption is the condition that exists during tooth eruption, in which the gingival margin fails to recede to the cervicoenamel junction. This condition occurs in approximately 12% of the population.[49-53] A "gummy smile" or excessive gingival display can be corrected by orthognathic surgery, orthodontics, or periodontal osseous surgery.[61,63,64]

To alter unesthetic gingival disharmony, the dental specialty of esthetic periodontics has developed esthetic approaches since the early 1980s which include the removal of excessive gingiva, bone and new root coverage procedures (see chapter 12).[40,54-57] Techniques such as ridge augmentation have been included,[42-58,60] as well as site development for esthetic dental implants, and various types of gingival alterations.[25,61] The development of osseous grafting for repair of isolated esthetic deformities continues. These procedures are of critical importance to the success of creating a beautiful smile. Restorative dentists must understand the treatment options and refer patients to their periodontal team for consultation.[62]

Consequently, mucogingival surgery has been redefined as "periodontal plastic surgery" to correct or eliminate anatomic, developmental, or traumatic deformities of gingiva or alveolar mucosa.[61] As previously mentioned, the only true alteration of the gingival levels is dictated by the actual incisal positions of the maxillary anterior teeth.[65]

Tooth Axis

In an esthetic smile, the direction of the anterior teeth and the long axis follow a progression as the teeth are viewed from the mid-line towards the posterior area, creating a harmonious smile framed by the lower lip when the maxillary anterior teeth tip medially.[9] The axis of the central incisors is usually slightly tilted distally towards the apex of the tooth when compared to the mid-line, perpendicular to the interpupillary line (Fig 2-20). The most pleasing position of the central incisors labiolingually exists when the labial surface of the incisors is positioned vertically or with a slight labial axial inclination. Variations of this position will occur in individuals with different skeletal types and facial profiles.

WWW.HIGHDENT.IR
همیار دندانسازان و دندانپزشکان

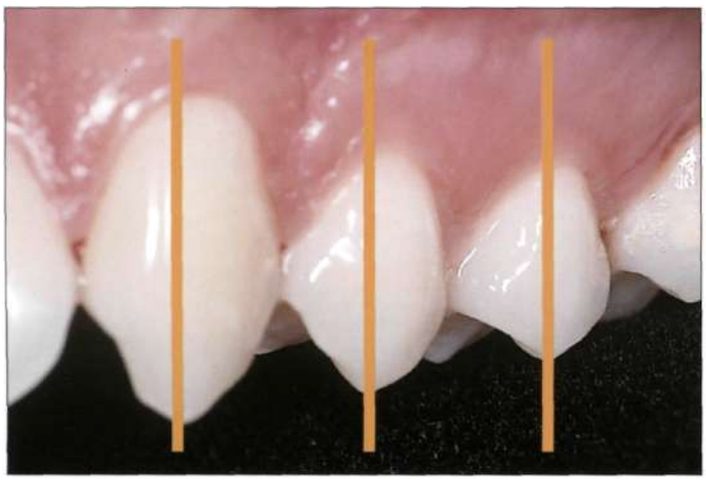

Fig 2-21 Canines and premolars follow a vertical tooth axis when viewed from the lateral aspect. However, when they are observed from the facial aspect, owing to their lingual inclinations towards the incisal edges, they impart the appearance of a distally tilted tooth towards the apex. The position of the canine dictates the front-back progression of the smile.

When the lateral incisors are considered, it is observed that the lateral incisors are inclined somewhat more distally towards the apical than the central aspect. Similarly, in most of the pleasing natural smiles, the mesiodistal axial inclination as well as the anteroposterior position of the lateral incisors is placed asymmetrically.

The canine tends to be even more distally inclined when viewed from the facial aspect. However, when viewed from the side, it has a long axis in a vertically or slightly distalled position in the dental arch (Fig 2-21). The best way to analyze tooth axis position of the canine is to relate it to certain facial formations. In the majority of cases, it follows a parallel line drawn from the corner of the mouth to the corner of the eye when smiling and, in turn, runs parallel to the vertical side of the vestibular frame.[44]

Interdental Contact Areas (ICA) and Points (ICP)

The broad zone in which two adjacent teeth appear to touch is called the interdental contact area (ICA). Observation suggests that the 50-40-30 rule, indicating the relationship between the anterior teeth, applies to 50% of the length of the maxillary central incisors and is defined as the ideal connector zone.[66] This means that 40% of the length of the central incisor is the ideal connector zone between a maxillary lateral and central incisors. When viewed from the lateral aspect, the prime connector zone between a maxillary canine and a lateral incisor is about 30% of the length of the central incisor (Fig 2-22a).[66]

In cases where the teeth are too long, it may be best to increase the vertical contact area and thereby keep the embrasures (both gingival and incisal) as narrow as possible.[67] This will enhance the perception of a relatively wider and, therefore, a relatively shorter incisor. The contact area can also be lengthened apically to close the interdental embrasure, if enough papilla cannot be obtained (Fig 2-23).[67]

The most incisal aspect of the contact area is called the contact point. After this point, the two adjacent teeth diverge, and the medial-distal contacts turn to incisal edges. When we consider the appropriate shape of the incisal teeth and their esthetically correct alignment, it is obvious thatthe interdental contact points move apically as they proceed towards the posterior area (Fig 2-22b). The contact point of the two central incisors is located in the most incisal area, owing to the almost right-angled relation of their incisal and mesial line angles. Because of the relatively rounded corners of the distoincisal aspect of the central incisor and the mesioincisal aspect of the lateral incisor, this contact point is placed more apically between the two. This contact point may display different heights, owing to their natural asymmetric position and form of the lateral incisors.

WWW.HIGHDENT.IR
همیار دندانسازان و دندانپزشکان

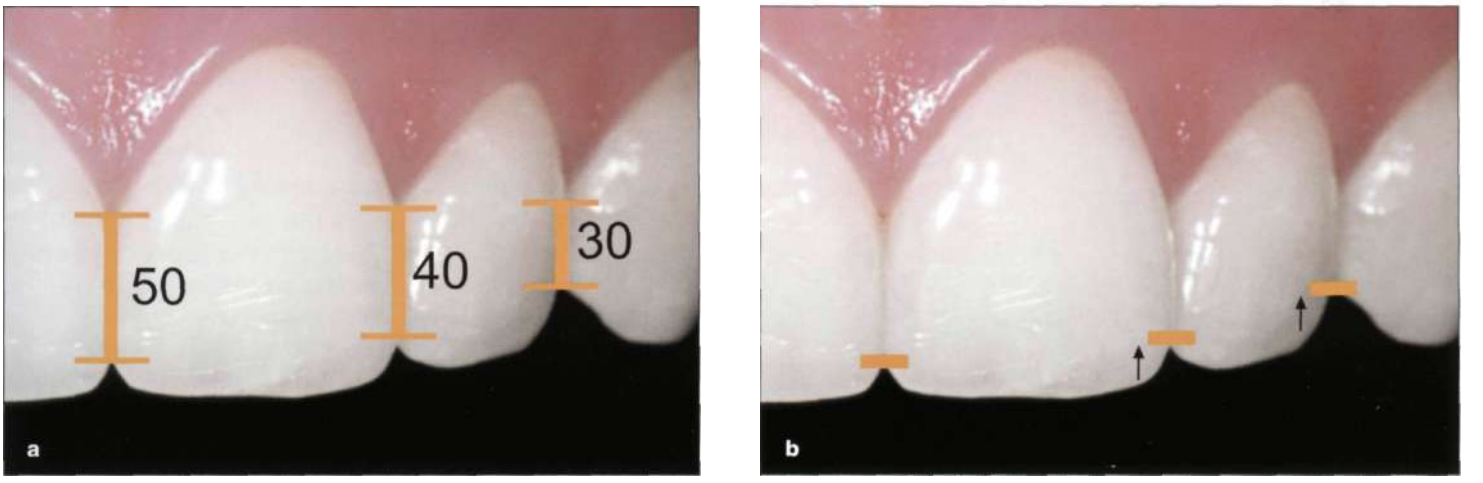

Fig 2-22a, b (a) The zone where the two teeth are in contact is called the interdental contact area. The length of this area is not the same between the incisors. The longest contact area is between the central incisors; the shortest contact is between the lateral incisor and the canine, still following a pleasing pattern, (b) The points where the interdental contact areas end, and the incisal and distal surfaces of the teeth begin to converge at the incisal edges, are called the interdental contact points. They move apically as the teeth proceed from the central incisors to the posterior area.

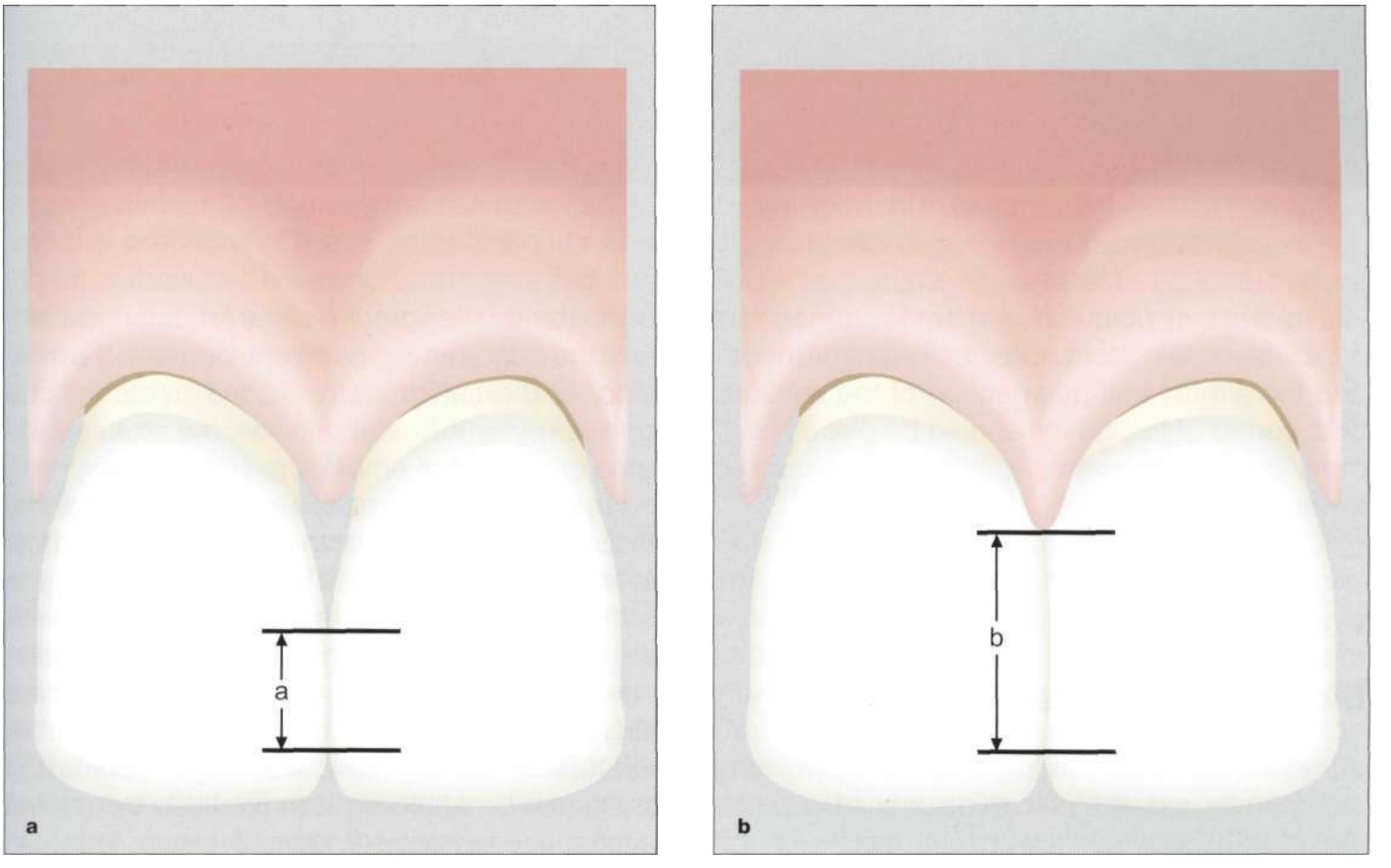

Fig 2-23a, b (a) At times, owing to the lack of adequate bone support, the new papilla cannot be generated to close the unesthetic space that appears between the teeth, (b) In such cases, the interdental contact can be moved apically to close the gap.

WWW.HIGHDENT.IR
همیار دندانسازان و دندانپزشکان

Fig 2-24a-c (a) The interdental embrasure is the smallest and sharpest in the central incisors. Continuing the observation posteriorly, the embrasures become larger and wider. Owing to the asymmetric positions of the lateral incisors, the embrasures may differ between the central and lateral incisors and the canines, (b) The size of the embrasures increases between the premolars. An angle of 90 degrees can be seen in young, unworn dentitions, (c) The incisal edge position of the lateral is placed 0.5 to 1 mm apically compared to central and canine in young dentitions.

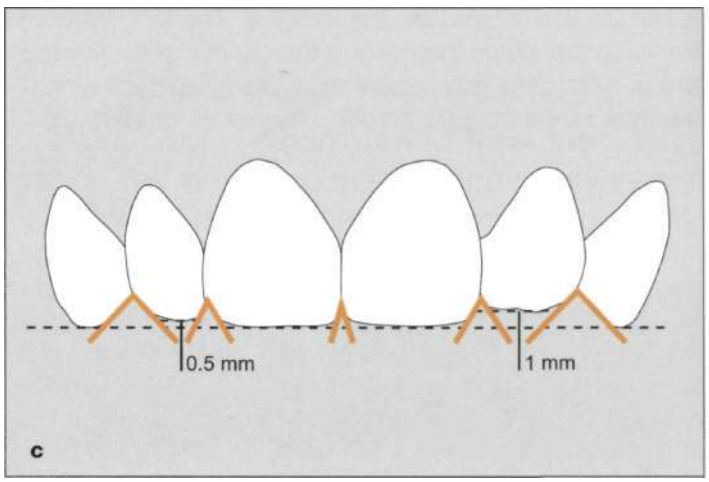

The contact points of the more-rounded corner of the distoincisal portion of the lateral incisor and the almost triangular shape of the mesioincisal corner of the canine should be placed even more apically. The same routine can be applied towards the premolars.

Incisal Embrasures

When the dental arches separate, as in speaking or in a smile, a dark area can be seen in the anterior region between the incisal edges of the maxillary and mandibular teeth. This negative space creates a contrast with the teeth that enhances the appearance of the incisal embrasures.[68] An attractive smile is defined by the pattern of silhouetting that is created by the contrast of the darker background of the oral interior, along with the edges and separations between the maxillary and anterior teeth. As the dentition progresses away from the mid-line, the size and volume of the incisal embrasures increase.

The incisal embrasures between the central incisors are the smallest in area and the sharpest in angle (Fig 2-24). Owing to the symmetric nature of the central incisors, this forms a triangle with the narrowest angle on the top. The incisal embrasures between the central and lateral incisors are larger than the incisal embrasures between the centrals, with a relatively wide angle. A pleasing smile can be achieved with relatively symmetric central and asymmetric lateral incisors. This also applies to the nature and shape of the incisal embrasures between the central and lateral incisors. These triangles should not always be symmetrical on each side, but should vary in shape (Fig 2-24c).

WWW.HIGHDENT.IR
همیار دندانسازان و دندانپزشکان

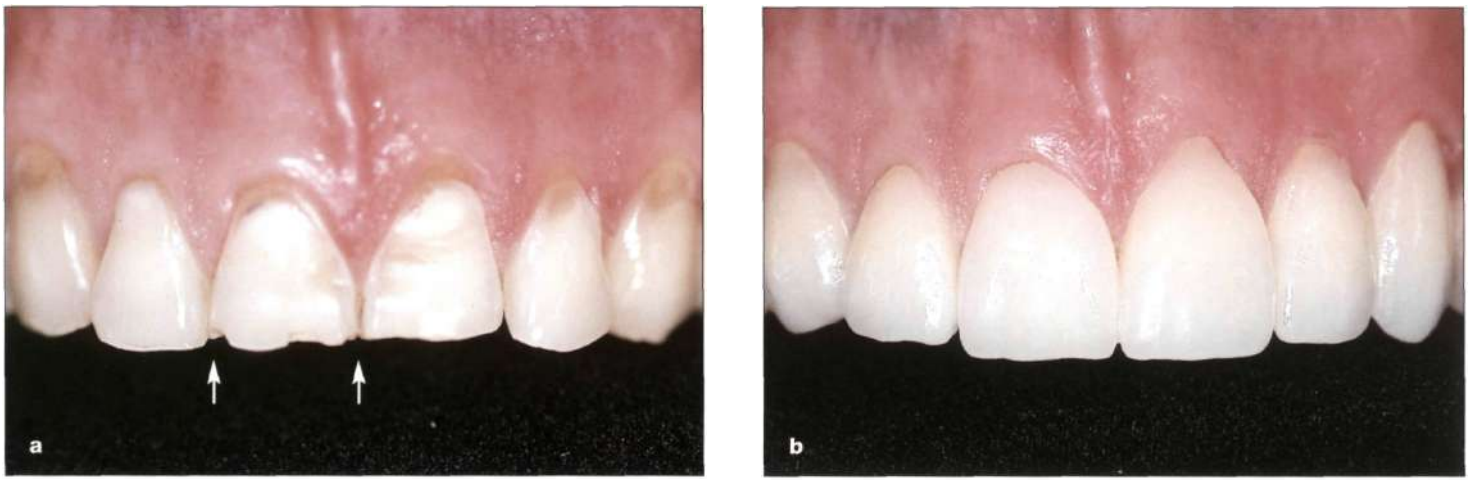

Fig 2-26a, b (a) In the aged or worn dentition, caused by the incisor loss of length, the incisal embrasures become smaller or may even disappear, (b) To create a youthful smi , these teeth have to be lengthened and the embrasures re-created.

The largest of the incisal embrasures exists between the lateral incisor and the canine. The triangle here exhibits different characteristics related to the gender of the patient. The lateral incisors of females tend to have a more rounded incisodistal corner than those of males, creating a wider canine embrasure space in women than in men. The teeth become larger in the posterior region, and the angle that forms the contact point reaches almost 90 degrees between the canine and the premolars. These contact points and incisal embrasures are important factors in determining a youthful smile. When teeth abrade from the incisal aspect by wear and age, the contact points slowly disappear, beginning from the central incisors and then the lateral, finally resulting in an aged smile (Fig 2-25).

The embrasures may also affect the perception of the length, width, and the incisal edge. A change in the shape of the incisal edge can alter the illusion of reduced or increased width. If the mesioincisal and distoincisal corners are more rounded than they should be, the tooth will be perceived as longer than its original length (Fig 2-26).[67] With the alignment of dental elements, provided with well-marked incisal spaces, an apparent reduction of the anterior segment is promoted, whereas the absence of interdental spaces in the incisal alignment (i.e. worn dentitions) simulates a straight line and results in the apparent enlargement of the anterior segment.[44]

Individual and Collective Tooth Dimensions

Relative tooth dimensions, as opposed to the original tooth form, have an input on the smile. When restoring the dentition, the primary objective is to achieve the most natural state possible, while respecting the patient's esthetic preconceptions. The maxillary central incisors are especially important in determining the size and shape of the anterior dentition and its overall visual effect. Disproportionately shaped teeth, i.e. teeth that are too long, too short, too wide or too narrow in relation to the proportion as a whole, may create facial disharmony.

Dominance

Dominance is the primary requisite for providing unity, and unity is the primary requisite for providing composition.[69] Dominating elements are supported by similarly dominant subsequent elements, bringing vigor to the composition. Consequently, in faces adorned by a beautiful smile, the dominance of the mouth exceeds the dominance of the eyes. In a harmonious anterior dentition, the maxillary central incisors dominate in shape, size and position (Fig 2-27).

A consistent arch form and correct proportion to the facial morphology are essential in the pleasing dentition. The proportion must be in harmony with the strong or weak features of

WWW.HIGHDENT.IR
همیار دندانسازان و دندانپزشکان



Fig 2-26a-c (a) In cases where there is loss of the vertical length, the embrasures become smaller (when teeth lose their individual proportions, they appear to be smaller and wider), (b) If the teeth cannot be lengthened incisally, owing to functional disturbances or the patient's wishes, the incisal embrasures and the contact points can be carried apically, making the incisal 1/3rd of the tooth narrowerand creating the illusion of longerteeth. Also, note the esthetic tooth recontouring on the incisal edges, (c) The whole impact of a beautiful smile on the face.

Fig 2-27 Relative tooth dimensions. In a pleasing smile, maxillary central incisors dominate the anterior dentition in shape, size and position.

WWW.HIGHDENT.IR
همیار دندانسازان و دندانپزشکان

Fig 2-28a-c The canine is placed too bucally, disturbing theflow of an otherwise possibly pleasing smile, (a) In some patients, even though the canine is placed on its correct arch form, it is rotated and displays the distal half, which is not pleasing, (b) Full arch treated with PLVs. The canines usually dictate the total width of the smile, even though only their mesial halves can be seen. The character and width of the buccal corridor are similarly influenced by the appearance of the canines, (c) The positive impact of a balanced smile on the facial appearance.

the individual's facial characteristics.[20,70-74] To achieve an esthetically pleasing smile, the dentist should first decide on the appearance of the central incisors, followed by the laterals and the canines. Whether in a natural or a treated dentition, the appearance of the maxillary central incisors is of critical importance to the pleasing smile. In a pleasing anterior dental composition, the canines are also vitally important teeth as they form the junction between the posterior and anterior arch segments and support the surrounding facial muscles by means of their position and investing tissues. The size and character of the buccal corridor created when a person smiles are controlled by the size and position of the canines (Fig 2-28).

The proportion of the anterior teeth, displayed in the total width of the smile, is affected by the position of these teeth. Only the mesial half of the canine can be seen from the frontal view of the most pleasing anterior dentitions. The distal half of the tooth is usually in line with the buccal sur-

WWW.HIGHDENT.IR
همیار دندانسازان و دندانپزشکان

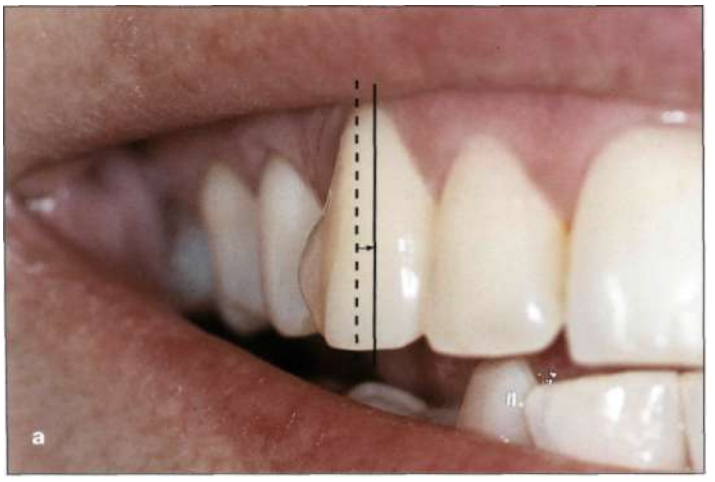

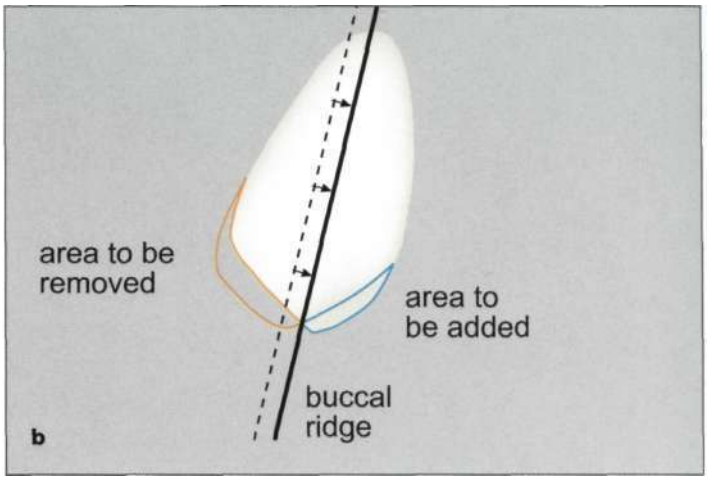

Fig 2-29a, b (a) If the canines look stronger, the buccal ridge has to be moved mesially. This will lessen the excess of the mesial half of the canine, (b) While performing the above function, the incisal edge has to be modified *{Zappala C).* The longer mesial incisal edge has to be shortened horizontally, while the distoincisal edge should be moved towards the apical area.

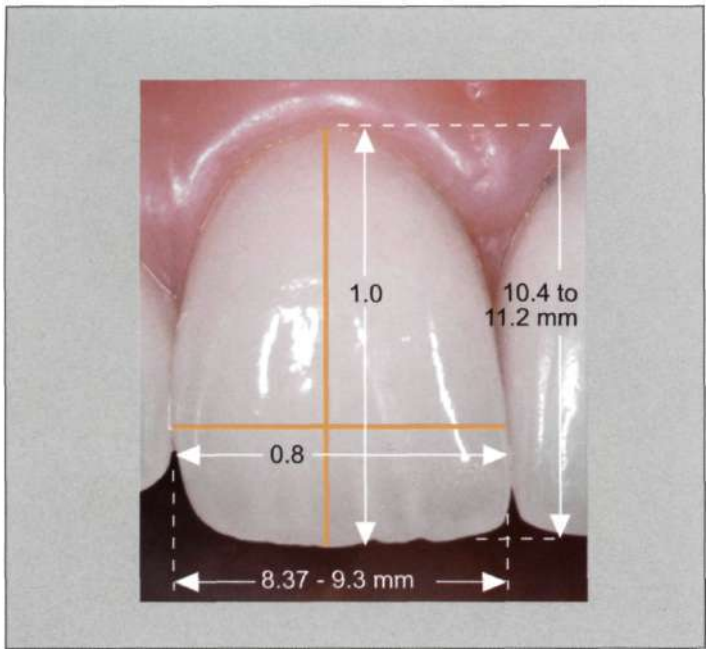

Fig 2-30 The central incisor has a proportion by itself, such as 1 to 0.7, 0.8, giving it a somewhat more rectangular silhouette. In most cases, the width of the central incisors ranges from 8.37 mm to 9.3 mm, whereas the length differs from 10.4 mm to 11.2 mm.

faces of the maxillary posterior dentition, as the canine turns in the arch. The cervical aspect is prominent as opposed to the cusp tip. Sometimes viewed from the facial aspect, even though the tooth axis of the canine follows its natural path, the canine may still look larger (see below, Single Tooth Proportion). The way to overcome this problem is to carve the buccal ridge towards the mesial aspect to eliminate the excess width of the cuspid (Fig 2-29).[67]

Single Tooth Proportion

The central incisor, as a tooth alone, should have a widthheight proportion within itself. The most pleasing width-to-length ratio for maxillary central incisors is approximately 75% to 80% in a pleasant smile. However, it has been reported that it can vary between 66% and 80%.[75] Put another way, a relation of 10:8 in lengthwidth is reasonable for the maxillary central incisors. An 85% width-to-height ratio will give a square appearance, whereas a 65% width-to-height ratio will make the teeth appear longer. There are some individuals who have a pleasant smile despite disproportionate teeth. Therefore, the elements discussed above should not be accepted as an absolute rule.[76] In a number of studies, the mesiodistal diameter of the maxillary central incisor was anywhere from 8.37 to 9.3 mm,[26,28,77,78] anc| tne cr0wn length was in the range of 10.4 to 11.2 mm (Fig 2-30).[26-28]

WWW.HIGHDENT.IR
همیار دندانسازان و دندانپزشکان

$$\frac{S}{L} = \frac{L}{S+L} = \frac{2}{1+\sqrt{5}} = 0.618$$

Fig 2-31 The mathematical formula of the golden proportion.

Fig 2-32 If the golden proportion has to be followed strictly, the ratios between the widths of the incisors should be 1.618 for the central, to 1 for the lateral, and 0.618 for the canine. The author suggests using those numbers and proportions only as valuable parameters, since in real life, symmetric and proportional smiles hardly ever exist.

Golden Proportion

The most influential factors in a harmonious anterior dentition are the size, shape and position of the maxillary central incisors. Proportion is the key to a pleasing dentition, and it should be consistent with the patient's facial features, whether they be strong or weak. In order to appear pleasing, the maxillary central incisors must be in proportion to facial morphology and consistent to the arch. The dentist must allow natural variations in form and position, and ensure that the central incisor is in harmony with the facial outline and profile forms.[20,70-73] *Lombardi* suggests that we view the patient as a whole when seeking to achieve harmony. To achieve facial harmony, the overall anterior dental composition must be approached as a whole picture, with the facial features as their frame.[79] It is only through the application of specific laws, whether knowingly or unknowingly, that visually appealing proportional relationships can be achieved.[44] Beauty is connected to numerical values, as in the relationship of harmony between two parts. Pythagoras described it as it is presented in Fig 2-31.

In dentistry the term "golden proportion" is a mathematical theorem concerning the proportions of the dentition. It is considered as the only mathematical tool for determining dominance and proportion in the arrangement of the maxillary teeth from the frontal view.[80,81] *Lombardi* was the first actually to apply this equation to dentistry[82] and *Levin* developed the principles of visual perception and their application to dental esthetics.[81] It was found that certain proportions

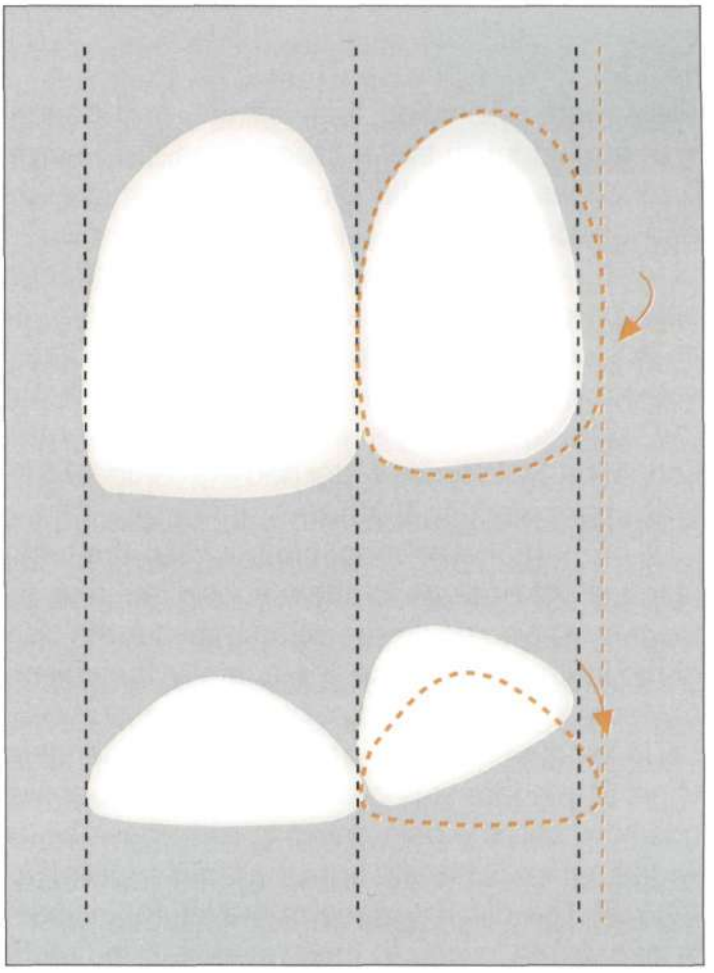

Fig 2-33 The position of the lateral incisor can affect its facial display: if the distal aspect of the lateral incisor is lingually positioned, the tooth will look narrower than its actual size (see *Goldstein,* Esthetics in Dentistry).

WWW.HIGHDENT.IR
همیار دندانسازان و دندانپزشکان

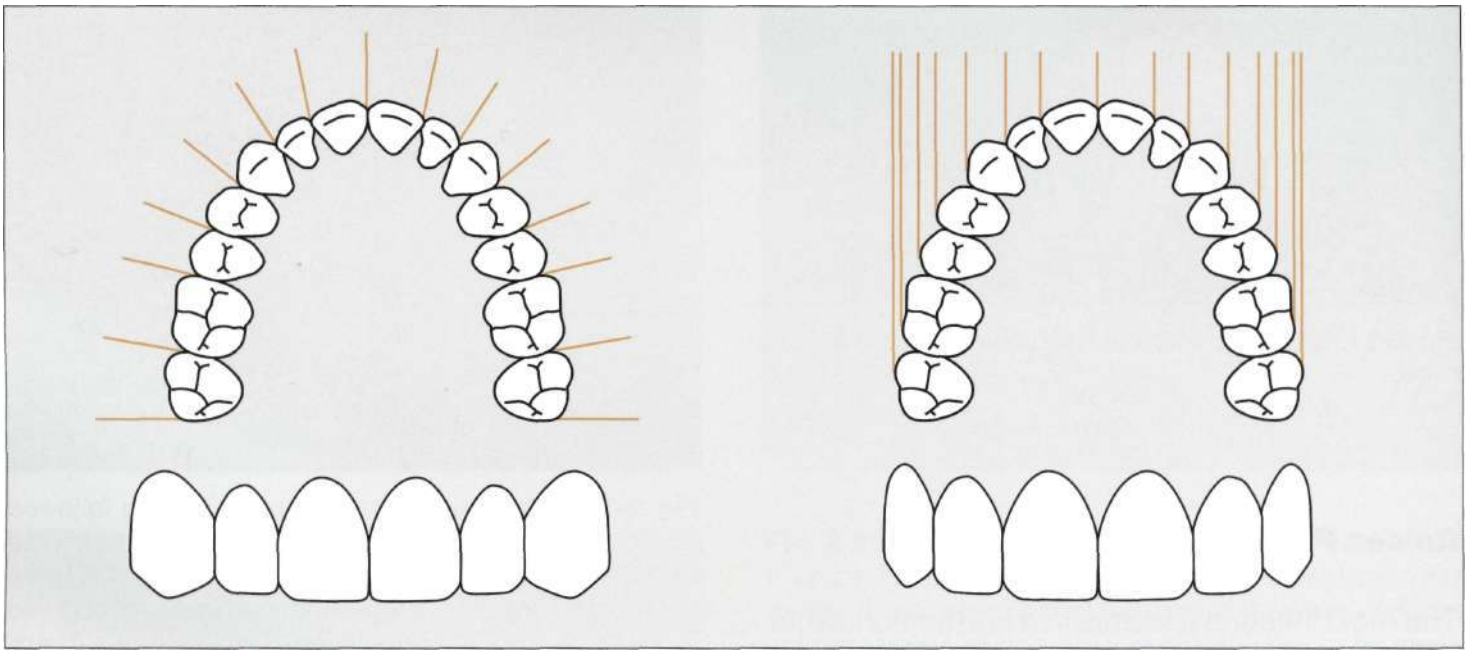

Fig 2-34a, b (a) If the teeth were to display their actual size, the distance from canine to canine would have been considerably wider and their related proportions would have been different, (b) The perception of tooth size is different when viewed from the facial aspect, owing to the placement of the teeth in the dental arch *(Ward,* Proportional smile design).

were more appealing than others, and beauty was equated with these proportions.[66] To some extent, these proportions can be defined, taught and used as the basis for the dentist's artistic plans.[83] According to this rule, if the width of each anterior tooth is approximately 60% of the size of its adjacent anterior tooth then it is considered esthetically pleasing.[84] It follows logically that if the width of the lateral incisor is 1, the central should be 1.618 times wider and the canineO. 618 times narrower (Fig 2-32).

A proportional relationship between the teeth alone is not enough to attain successful results, there must also be a proportion between the size of the teeth and the face.[85] Generally, there is an obvious contrast in the size of the lateral and central incisors when viewing the natural anterior dentition. The contrast is created by their respective positions and the differences in their mesiodistal widths, when observed from the facial aspect (Fig 2-33).[95] The distal surface of the lateral incisors is less visible, owing to their rotation in the arch, whereas the most dominant anterior teeth in the dental arch, the maxillary central incisors, can be seen in their full size.[82] It is not the actual size of the teeth, but the perceived size that these proportions were based upon, when viewed from the anterior aspect (Fig 2-34).[76]

The effects of optical illusions and perspectives may lead us to perceive an object as deformed *or* in geometric shape when it is observed from a particular position. As distance from the perceived object increases, the objects observed seem to diminish in size, and their appearance differs from reality. Therefore, it can be said that a shape is never perceived as it really exists.

If the original definition of the golden proportion is applied to dentistry, the anteriorteeth would display a relationship that is perfect and uniformly the same for everyone. Even though it sounds reasonable, it is very difficult to apply this rule because in reality patients have different arch forms as well as different lip and facial proportions. *Lombardi* stated that the "strict application of Golden Proportion is too limiting for dentistry, owing to the differences in the shape of the dental arch",[82] and he suggested using a continuous proportion, not necessarily limited to the 62% proportion. In this concept of "repeated ratio", the ratio of the widths established between central and lateral incisors must be used as the viewer proceeds distally.

WWW.HIGHDENT.IR
همیار دندانسازان و دندانپزشکان

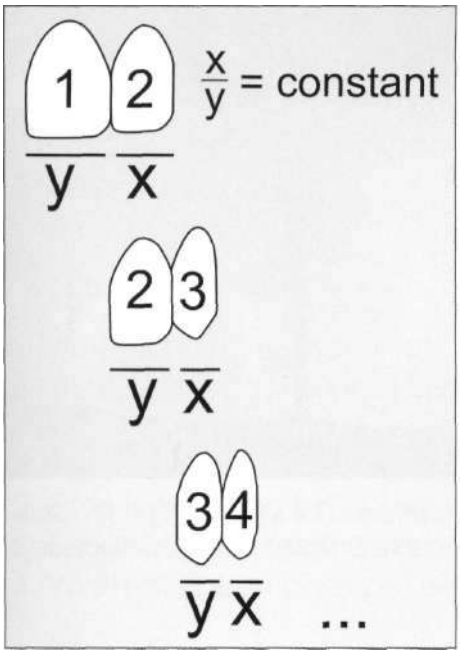

Fig 2-35 The epigraphic definition of tooth proportion, when the successive widths of two different teeth are viewed posteriorly {*Ward,* proportional smile design).

Fig 2-36 The proportions that dictate only the width of the teeth do not mean much unless they are somehow related to the height of the teeth. The teeth may still exhibit the exact golden proportions horizontally, but, owing to their short height, they may appear unesthetic.

Recently, the "recurring esthetic dental proportion" concept was introduced.[86] It states that the proportion of the successive widths of the teeth, as viewed from the frontal aspect, should remain constant as one moves distally (Fig 2-35) and rather than being locked into using the 62% proportion, the dentist may use a proportion of their own choice, as long as it remains consistent, while moving distally. The use of a recurrent esthetic proportion gives greater flexibility and is supported and enhanced by recent research conducted on the evaluation of beautiful smiles.[87] It has been found that the majority of the proportions of beautiful smiles do not coincide with the exact golden proportion formula. In this particular research, the proportions showed distinct differences between males and females, and the canines displayed a larger width in females than in males. This finding makes it clear that the strict observations of laws and rules may not only limit creativity, but may also lead to failure, considering the individual and cultural environment of the observer. Perhaps it is best to say that the golden proportion rarely exists in any natural dentition and overly strict adherence to it in order to achieve the ideal smile may be detrimental and limit creativity.[88] In the actual formulation and application of these laws and rules a marriage of science and emotion is required.[44]

Another downside of the golden proportion, as mentioned, is that it indicates only the width. However, it is generally agreed that the width alone does not mean much. Its perception is related directly to the height-width ratio and the objects next to them (Fig 2-36).[86] Therefore, the height- width ratio of the tooth within itself defines the perception of width and the natural progression of these proportions.[44] The natural smile is expected to be in harmony with the face, exhibiting different facial characteristics and dimensions. The concept of an ideal anterior dentition, or a formula to achieve harmony with a particular facial type, does not exist, and the patient's own perceptions, along with cultural and social influences, must be free to combine with the dentist's artistic abilities to achieve the finest results.[16] These formulas must be used only as guidelines and tools that the dentists integrate with their own artistic abilities and imagination.[83]

The notion of an esthetically correct standard arrangement of teeth was found to be completely inaccurate, and patients began to request

WWW.HIGHDENT.IR
همیار دندانسازان و دندانپزشکان

Fig 2-37a, b (a) Dentition of a 16-year-old teenager, (b) Aged tooth. Surface texture is affected by age. Young teeth exhibit a roughened surface texture, whereas the aged teeth have a relatively smooth surface. Children have a characteristic surface texture.

customization ratherthan standardization fortheir prosthetic restoration. Essentially, the patients themselves were responsible for the idea that beauty is best represented through the diversity that exists in the natural dentition. Accordingly, porcelain laminate veneers were fabricated with an increased focus on the charisma of the results rather than on their form and geometric alignment. These are the characteristics that impartthe youthful appearance to the smile. It can usually be seen in the proportions existing in young dentitions and smiles when compared to aged dentitions. Therefore, care should be given to evaluating the patient's age, facial appearance, style and personal expectations. An important goal of the esthetic dental treatment is to restore the dentition to the most natural state possible, within the patient's esthetic preconceptions.

Tooth Character

Surface Texture and Contour

The challenge to emulate nature and establish oral harmony is a thoroughly complex issue, particularly in anterior restorations. Knowledge of the interplay of shape, function and surface texture is the basis for esthetically appealing restorations. Surface texture affects the size, shape and position of the teeth. In esthetic restorations, the surface texture of the anterior teeth and their enamel, which becomes abraded in time, are the important factors to consider. The natural teeth of young children have a characteristic roughened texture, whereas adult teeth tend to have a smooth surface texture (Fig 2-37). This smooth texture is owing to the erosion of the enamel over a period of time.[89] Young teeth always look brighter than aged teeth. As the enamel of adult teeth becomes thinner, the hue of the dentine becomes more distinct, and the value decreases owing to the smoothened surface texture.[90] In a restored tooth, surface exturing must be similar to the adjacent natural tooth to allow the interplay of light that produces pleasant color matching.

Visual Perception

A contrast in color, shape and size allows the deflection and reflection of light from the dental surfaces and this visual perception of these reflections is somehow related to following rules:

1. The greater the contrast the greater the visibility.
2. Visibility increases with an increase in light reflection.
3. Visibility diminishes as light deflection increases.[44]

WWW.HIGHDENT.IR
همیار دندانسازان و دندانپزشکان

An esthetic effect can be created in dental treatment by using artificial materials to create an illusion. This illusion can be enhanced by artifice and reality in order to satisfy the patient's own perception of their image.[90]

Illusions

Certain conditions may alter the perception of teeth by creating illusions in the oral environment:

1. Depth can be created with shadows.
2. Prominence can be increased with light.
3. Length can be emphasized with vertical lines.
4. Width can be emphasized with horizontal lines.

Tooth contouring and color manipulation are optical principles applied in dentistry. Tooth contouring can be achieved through the manipulation of the natural grooves, angles, incisal or gingival inclines, and incisal edges, whereas the manipulation of color is performed on selected tooth surfaces, natural locations, gingival inclines and interdental areas.[91] In any restoration, the surface of the tooth's morphology is influenced by this relationship, especially in the issue of brilliance.[92] Young teeth with unworn enamel always exhibit a high surface texture with increased brightness. If the surface of the tooth or restoration is macro- and micromorphologically roughened, it will diffuse the reflected light.

The light reflected by the dental surfaces alters the perception of the size and color and the perception of the depth of a tooth on the dental arch. Teeth will seem closer, wider and lighter if the amount of light reflected is increased. Brighter teeth (therefore with high texture) appear larger and closer to the eye, and so in order to create the illusion of bringing a tooth forward, the surface texture can be increased, thereby increasing the value of the tooth. If the tooth must appear darker and more distant, the surface texture should be kept as smooth as possible. Variation in the reflection of light is required to make the teeth appear brilliant, and it can be achieved with convexities *or* cavities breaking up the surface. The brilliance exhibited in young teeth is enhanced by the surface texture, and if the value of the tooth needs to be increased, this high texture is a necessity. The natural anatomic surface must be carefully observed, and the dentist must try to achieve the same reflection of light that is reflected by the non-restored adjacent teeth surfaces.[93]

The technician should be knowledgeable of the compatibility of the porcelain selected for the planned surface texture.[94]

Misperceptions

In the case of the misperception of a crown contour, owing to a change in their outline form, it is observed that the lesser the contour, the smaller the tooth appears, and the esthetic dentist must be careful to guard against the possibility of any such misperceptions.[85]

Sometimes a tooth may look wider, even if its height and width are the same. This phenomenon is owing to the surface configuration of that tooth. Occasionally, the developmental grooves of the incisors follow a wider trajectory. In such cases, even though the tooth has the correct proportion, it is perceived as thick in width and relatively short. Altering the already existing mesial and distal line angles can also change the length perception of the tooth. The tooth can be perceived as longer if the mesial and distal line angles are moved towards the center of the facial surface (Fig 2-38).[95] Owing to wide gingival 1/3rds, the teeth may display a rough and square appearance. If the display of the smooth lines is broken, the gingival 1/3rd of the tooth appears narrower. The next step in creating a narrow appearance at the gingival 1/3rd is to prepare the tooth accordingly. These sites should be prepared somewhat deeper in order to create space for the technician, who will want to create the same effect with the porcelain laminate veneers (see below, Tooth Preparation and Fig 2-39).

An outline form misperception can be corrected, as in the case of central incisors where one is narrower than the other. To impart a wider appearance on the narrower incisor, a sharper curve is made in the distal line angle than that of the opposite tooth. If the crown's width appears to be too great, the tooth's distal outline should be shaped

WWW.HIGHDENT.IR
همیار دندانسازان و دندانپزشکان

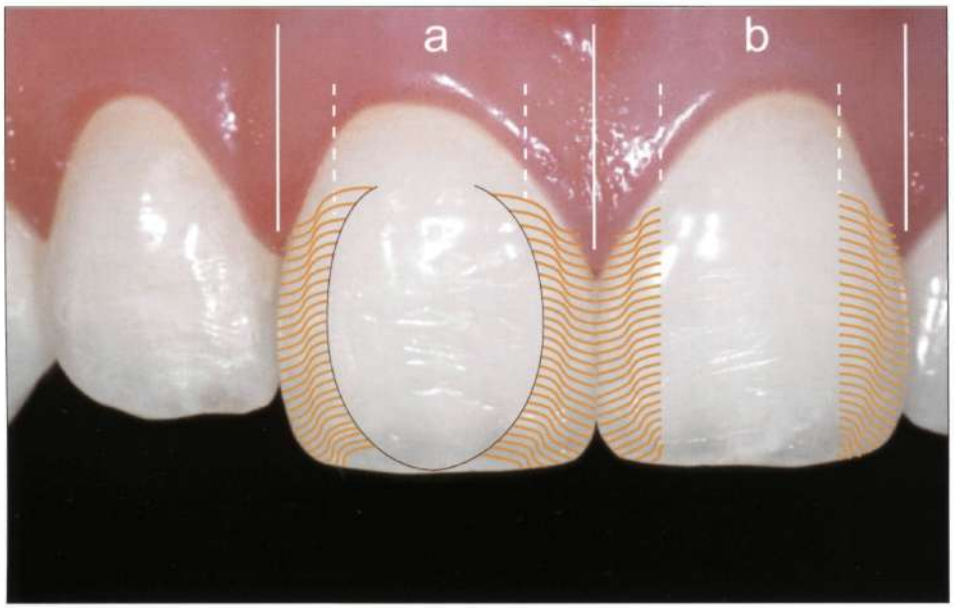

Fig 2-38 When the tooth appears wider (a), the vertical developmental grooves are moved closer, i.e. the already existing mesial and distal line angles are moved towards the center of the tooth to create the illusion of a longer tooth (b). If this procedure is insufficient, the mesioincisal and distoincisal corners of the tooth are rounded to enhance the lengthening effect.[67]

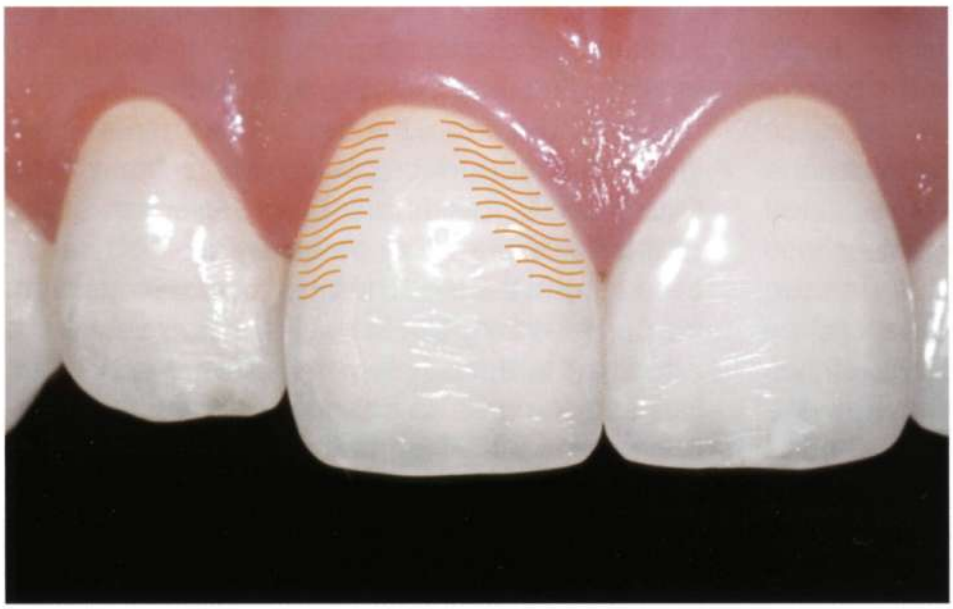

Fig 2-39 If the tooth appears wide, it can be modified from its gingival third, by breaking the mesiodistal line angles in that area. This will create a more triangular shape, thereby giving the illusion of a narrower tooth form.[67]

Fig 2-40 Vertical lines impart a narrow appearance to the objects, whereas the horizontal lines enhance the perception of the width. Two teeth of the same size may be perceived differently, owing to delicately placed horizontal or vertical grooves or internal stains in ceramic restorations.

WWW.HIGHDENT.IR
همیار دندانسازان و دندانپزشکان

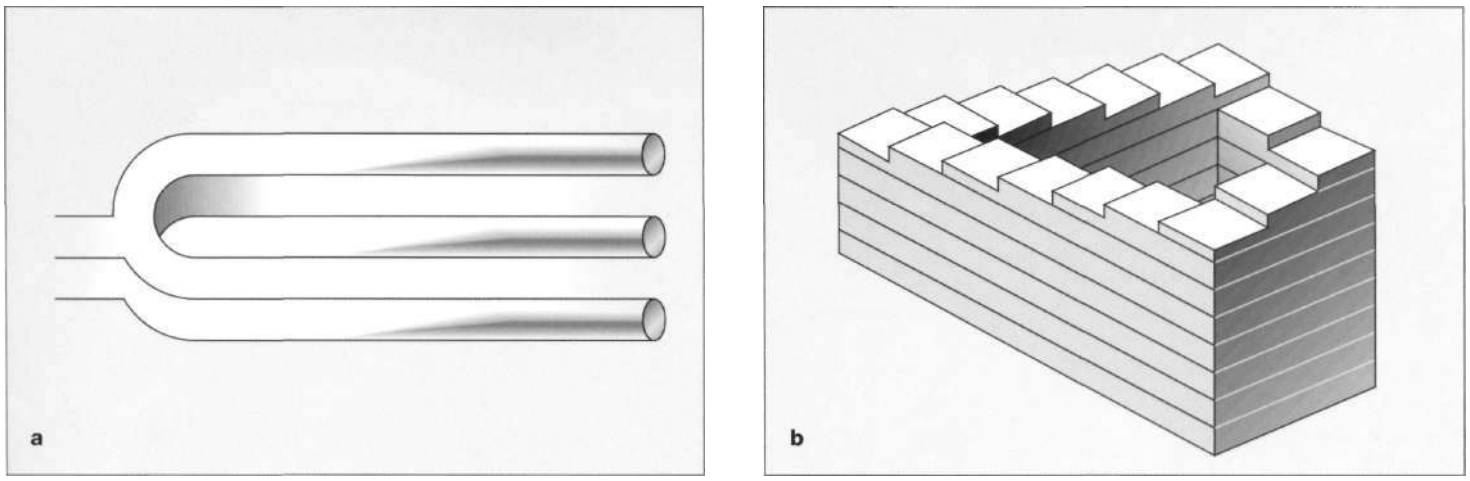

Fig 2-41a, b Power of illusion. Using the line angles, changing the internal angles and using shadows and different kinds of light reflections, creates illusions that can fool our eyes, (a) Even though there are only two extensions of the main bar, it can be perceived as having two or three prongs, depending on which side of the picture you start looking at. (b) If you keep on climbing the stairs you will do so forever!

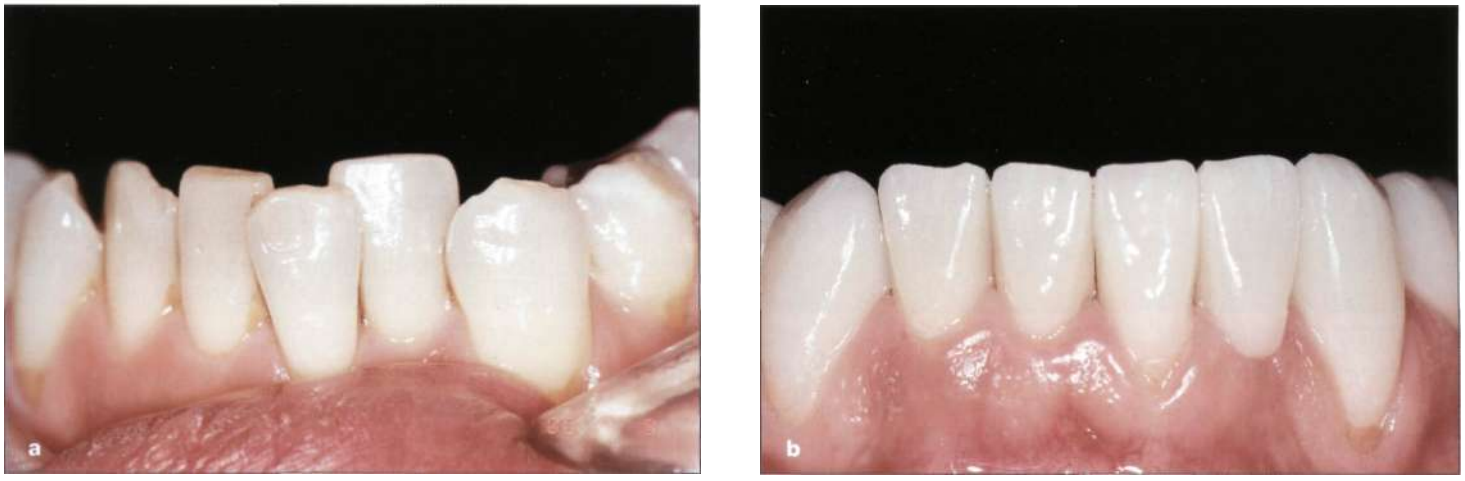

Fig 2-42, b A complicated case with crowded mandibular anteriors. Even though it seems very difficult to enhance the esthetics with porcelain laminate veneers, it is not. With careful treatment planning, delicate preparation and skillful application of porcelain laminate veneers and by using some illusive effects, the case can be treated as if there had been no crowding before.

to have a gentler curve, thereby making it appear smaller.[85]

The proportion or the orientation of the teeth can be changed readily by the influence of either vertical or horizontal lines. These can be achieved by using either different colors in different planes or by enhancing the vertical or horizontal grooves related to the surface texture. Dominance of the vertical lines will impart a longer and narrower appearance to the tooth, and the existence of horizontal lines will let the viewer perceive the tooth as wider (even if both teeth are identical) and shorter when viewed from the facial aspect (Fig 2-40). If the adjacent teeth are characterized, and the teeth in question lack characterization, they may appear artificial, causing a high reflection of light. If the shade reflection areas that control the light used to create illusions are employed properly, the restorations will appear to be natural.[95]

Changing the line angles, surface texture and lightening can create illusions that play tricks on ones eye (Fig 2-41). In this way it is being possible to correct crowded teeth, even though it seems impossible to correct with porcelain laminate veneers to begin with (Fig 2-42).

WWW.HIGHDENT.IR
همیار دندانسازان و دندانپزشکان

Fig 2-43a-c (a) Square dental arch. The maxillary incisors assume a position almost in line with the canines, (b) Ovoid dental arch. The central incisors appear along or across the curvature, whereas lateral incisors and canines are aligned with the curvature, (c) Tapered dental arch. A variety in tooth positions range from the V-shaped central incisors to the other anterior teeth that exhibit marked rotations or overlaps.

Shape and Position of the Teeth

To achieve esthetic harmony and support for the facial muscles and lips, the incisors must be correctly shaped and positioned. The perception of the tooth shape is related to the shape of the dental arch. There are three broad geometric categories of the overall alignment of the dental arch: ovoid, square, and tapered, which can be seen in numerous variations (Fig 2-43).[91] When observing the square alignment, the anterior teeth have quite literally a square appearance, with the incisal edges of these teeth basically identical and without much variation between them. It is as if the two canines have erupted parallel, and the tooth axis is straight without any labiolingual or mesiodistal inclination. The anterior triangular teeth are tapered within a triangular arch, and are protrusively inclined, while the central incisors are often labially displaced. An oval dental arch is usually made up of oval teeth, with the central incisors slightly labially displaced, and the posterior teeth on a generally contracted tooth axis with a lingually inclined incisal edge. The central incisors tend to have a distal surface that is rotated lingually.[16] Their edges are longer than those of the lateral incisors, and they also differ. The dentist is able to recognize this pattern through years of clinical observation of the natural structure of teeth.[91]

When a single incisor or a pair of incisors is being restored, adherence to the tooth's natural form is important. If homologous teeth cannot be used as a reference, then teeth from other groups may lend information as to the general shape of the tooth that was lost. The morphologic shape of the face, including the characteristics of gender and age, are useful in developing tooth form.[96]

WWW.HIGHDENT.IR
همیار دندانسازان و دندانپزشکان

Tooth Arrangement

The dental arch and position of the anterior teeth will determine the appearance of the lips and cheeks. If the dental arch is made too small, wrinkling of the skin may appear in the skin above the cheek and upper lip, as the arch is now unable to support the muscles. Similarly, axial inclinations of the teeth must also be carefully considered.[85]

Color of Teeth

The perception of the color of the teeth is influenced by the tooth's shape and its morphologic placement over the arch. Although there may not be great variation in the color of a single tooth, when the entire dental arch is carefully observed, it can be readily seen that there is a considerable variation in the color.[97] There tends to be a pattern in shade and colorfrom the mid-line of the maxillary teeth. The brightest teeth in the smile are the maxillary central incisors, and althoughthe lateral incisors are similar in hue, they are lower in color value. Of all the anterior teeth, the canines have the highest chroma saturation and the lowest value. The first and second premolars, although lighter and brighter than the canines, are quite similar to the lateral incisors in value (Fig 2-44).[98] In creating a natural appearance, it is vitally important to reproduce shade progression in any anterior dentition, even when the patient requests the lightest colors.

Characterization Via Colors

To create a natural reproduction with ceramic restorations, varying patterns of translucency must be followed. Throughout the life span, teeth are in a constant state of change. In youth, the teeth are more textured, lighter, brighter, and have a lower saturation. They also have a gingival margin at approximately the cementoenamel junction, along with light characterization that often has white hypoplastic lines or spots (Fig 2-45).[85] Depending on the age of an individual, the amount, location and quality of translucency vary. At times, the enamel of young teeth may appear transparent, owing to their exhibition of an abundance of incisal translucency. However, after years of function, the highly translucent enamel is lost as the incisal edges wear. The facial enamel becomes thinnerthrough daily functions, such as tooth brushing and eating, thereby allowing the dentine to dominate the shade of the tooth. Consequently, the teeth of older individuals tend to be lower in value and higher in chroma than those seen in younger adults (Fig 2-46).

The decision of the depth and extent of the enamel of the translucent porcelains used in restoration will be dictated by the pattern of translucency.[96,99-101] The sum of chromas that are contained and distributed over the entire tooth surface determines the mean value from which the "basic hue" or color of the tooth is identified. The color of natural teeth is related directly to the correlation of enamel, dentin and light that appear during the light wave refraction and reflection process. The high chromic saturation of the inner dentin body and low translucency are the source of the "basic hue". The varying chromas of the "basic hue" are based on intensity and can be located in different areas of the tooth, such as the middle, cervical and incisal thirds. The translucent regions of the tooth, which are a part of the "chromatic map", actually originate from the enamel that is free of interposed dentin. The cervical third contains the highest chroma, as the highest degree of saturation is found there, owing to its thinner enamel and more visible color. At the middle third, the chromas are a slightly lower. In unworn teeth at the incisal third, opalescence that is created by the translucency of the incisal and intraproximal enamel gradually replaces the "basic hue" chroma.[92]

The inner dentin body and the external enamel layer of the tooth upon illumination create the fluorescence and opalescence phenomenon. The factors determining tooth color are the varying saturation levels, which are related directly to the thickness of the inner dentin body and the translucent areas of the enamel.[92] The 3-dimensional color of the tooth that is perceived by

WWW.HIGHDENT.IR
همیار دندانسازان و دندانپزشکان

Fig2-44 The smile is enhanced with 10 maxillary veneers (ceramist *G. Ubassy).* Through close communication with the patient, the progressive pattern of color change is explained. Since the patient also wants to have the natural tooth gradation, the veneers are produced in a natural way.

Fig 2-45 Young teeth are more textured, lighter, and brighter, with low color saturation. They exhibit transparent incisal edges. The enamel surface is semi-translucent, with a slightly irregular surface. Owing to the thicker enamel and translucency, the teeth look grayish white in certain areas.

Fig 2-46 As the teeth age, the enamel becomes thinner, allowing the dentin to dominate the shade of the tooth. The value decreases, and the chroma increases.

Fig 2-47 The intensity of the basic hue can be different in various areas of the same tooth. The cervical third contains the highest chroma and the lowest value, whereas the slightly lower chromas are at the middle third. The transition to transparency at the incisal 1/3rd minimizes the chroma, thereby letting the opulence effects to take place at the incisal edge.

WWW.HIGHDENT.IR
همیار دندانسازان و دندانپزشکان

the eye, consists of delicate fluorescence and sophisticated opalescence. Fluorescence is the ability to absorb light energy and empty it in a different wavelength that creates value in the tooth. Therefore, if the value needs to be increased, more fluorescence should be added. In performing any restoration, the ultimate goal of the dentist is to make the artificial prosthesis appear natural (Fig 2-47).

To achieve a natural look, these substitutes should be created with the age, gender and personality of the patient in mind. When the restoration of an older patient is in question, the dentist must consider the fact that older teeth are naturally smoother, darker, and have a higher saturation or chroma. In the case of the lower incisors, the older teeth often exhibit flat, broad incisal edges that show a dentin core.

Life-style

As already mentioned, not only the surrounding tissues of the dentition, but the personality, character and life-style of a patient must be evaluated as a whole, as all these factors can directly affect the color of the teeth. For individuals who use red lipstick, the treatment (in terms of color) must be designed accordingly. As described by *Steven Chu* (Chapter 5), colors have complementary peers. The complementary color for red is green. Therefore, if the porcelain laminate veneers are produced withouttaking the patient's lipstick preference into consideration, when that patient uses red lipstick, the teeth will be appear greener than they actually are. To compensate for this effect, the porcelain laminate veneers must be in harmony with the red color of the lips, and red pigments should be added to porcelain.

Europe Versus North America

Another cultural point to be considered is that, until recently, Europeans favored teeth that are genetically normal, whereas Americans have always placed more value on whiter teeth. However, with the advent of bleaching, even Europeans are changing their values with a preference for whiter teeth.[102] As more and more individuals use bleaching, the proportion of whiter teeth has increased, thereby changing the entire perception of dental health. The fact that white teeth appear to be cleaner and fresher is enough to persuade any individual of their desirability. Therefore, although imitation of nature is a priority for the dentist, sensitivity to the changes in dental treatments and the possibilities that they offer, along with the change of perception that they bring with them, must always be a consideration in treatment selection. Patient perception will always tend to favor whiter colors and higher values.[92] The knowledge, experience and the personal artistic skills of the dentist will result in a full understanding of the color phenomenon. Quality laboratory work is necessary to create natural porcelain laminate veneer restorations with natural tooth arrangement and proper proportions.

Sex, Personality and the Age Factor

Lombard/' has described anterior estheticism as the personality, age and gender of the person as it is reflected in the shape and form of that individual's teeth.[82] Clinical investigations by *Frush* and *Fisher*[20,70,74] concerning the sex, personality and age (SPA) factor arrived at the norms for these investigations (Fig 2-48).[79]

The masculine orfeminine characteristics have an important effect on the esthetics of a pleasing smile. In Western culture, femininity can be expressed in terms of delicacy and softness, whereas masculinity can be expressed in terms of vigor and angularity. *Frush* and *Fisher* describe femininity in the female form as the roundness, smoothness and softness that is typical in a woman.[74] Masculinity, on the other hand, according to *Frush* and *Fisher,* is the "cuboidal, hard, muscular, vigorous appearance, which is typical of men". The aging signs seen in the facial features that often reflect masculine or feminine

WWW.HIGHDENT.IR
همیار دندانسازان و دندانپزشکان

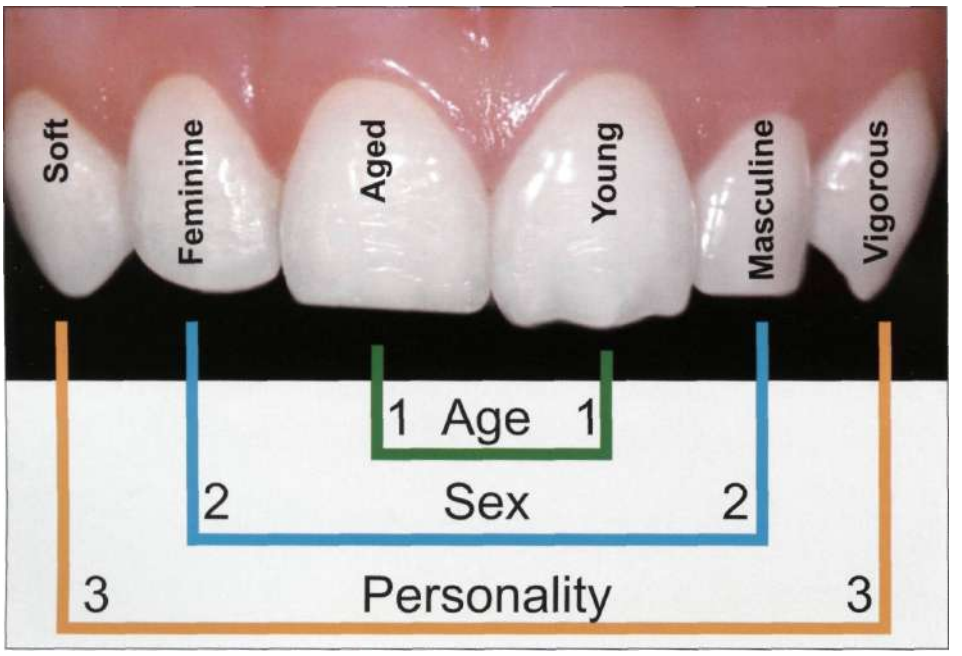

Fig 2-48 The classic chart from Lombardi, illustrating the SPA factor. Every characteristic of a single tooth may carry evidence concerning the patient's age, sex, and personality. However, when designing a new smile, factors such as cultural background, the expectations of the patientandtheirlifestyle,aswellasthe dentist's artistic ideals and values, are to be taken into consideration.

traits, can also be seen in the contours and positions of the natural dentition. If the incisal edges of the maxillary incisors, and especially the lateral, appear more rounded, than the effect is a delicate, feminine pleasing smile. These rounded softer lines add to the delicate nature of the facial features of a female.[103]

The incisal edges and transitional line angles of feminine teeth are rounded, while the edges tend to be translucent. In addition, the white hypoplastic striations can be used to give the effect or illusion of delicacy.[104] In the case of males, square incisal edges that appear to be blunt can enhance the masculine appearance.[103] This does not mean that*all the features of a male's dentition will appear according to the categories listed for masculine teeth, and, similarly, neither will the female's. It is common to find that people tend to exhibit various features of both sexes in the same dental arch.[104] There are many factors related to the interpretation of these features. Our cultural background, personal artistic ideals and esthetic values are all to be taken into consideration.[105]

The rotation of the lateral incisor's mesial surface, outward and beyond the distal surface of the central incisor can create a more delicate or softer position of the lateral when observed. Similarly, the lateral incisor may appear quite the opposite, or appear in a hard position, when it is located behind the distal surface of the central incisor.[103] In individuals of all ages, changes of character, position or color of the teeth are reflected in their dentition (see Incisal Length). When we think of the canine teeth, aggressive cartoon characters come to mind. Canines are thought of as the teeth of aferocious animal oran antisocial person's indication of hostility and anger.[106]

The design of canines may take the passive-aggressive factor into consideration, when the tone of the appearance is selected. A tooth that is longer than the ones next to it and has a pointed incisal edge will appear more aggressive. A frontal view may display a height of contour or a flat profile. A small incisal embrasure between the lateral and cupid teeth can exaggerate an aggressive look. A passive cuspid may show no aggression at all. In such cases, the tooth is usually the same length as the adjacent tooth or even shorter. The passive cuspid may have a blunt rounded tip and a convex profile, often exhibiting large incisal embrasures between the laterals and canines that create a passive appearance.[107]

WWW.HIGHDENT.IR
همیار دندانسازان و دندانپزشکان

Fig 2-49 Shortly after the eruption of the permanent dentition, the cervical line lies well beneath the gingival tissue, and the clinical crown looks square or rounded.

Young Teeth

In the younger patient, the anatomic crowns are not fully exposed shortly after the eruption of the permanent dentition, and the cervical line is well below the gingival tissue. Consequently, young unworn crown teeth tend to have a triangular or square morphology that looks almost like a square or round crown (Fig 2-49). Enamel has a refractive index of 1.62 and appears bluish white or gray when exposed to light, and presents vitality. The labial surfaces of the unworn incisal edges may appear darker owing to the thickness and translucency in this region. The underlying color of the dentin of the natural tooth affects the overall color and may cause the dentition to appear yellow or gray white. The enamel surface of a youthful dentition is semitranslucent, hard and shiny with a slightly irregular surface. Younger teeth often have white hypoplastic lines and have a lower saturation light characterization, owing to lower chroma, with a more textured, lighter, brighter and higher value. They have smaller gingival embrasures and a gingival margin at the dentoenamel junction. They also have significant incisal embrasures. The intraoral color is influenced by the color reflected onto the dental arch from the soft tissues around the tooth.[108]

Aged Teeth

Aged teeth appear triangular, even if they are square or rounded by nature. As the gingival tissues recede, the root becomes narrower than the crown and comes into sight. Aged teeth may be shorter incisally but longer gingivally, which means that less tooth will be visible when smiling. Little incisal embrasures appear on the worn incisal edges, whereas the gingival embrasures widen owing to the recession of the gingiva. Flat broad incisal edges and a dentin core are characteristic of the lower incisors. These fine details are of the utmost importance for a thorough understanding of the teeth by skilled dentists, so that their artistic skills can be used to create the necessary illusions in order to achieve a successful result.

Functional, parafunctional and occlusal wear of the enamel surface will result in changes related to age. These changes can be observed in the maxillary central incisors, canines and mandibular anterior teeth. Generalized attrition results in posterior wear of the dentition as well. Broadening of the contact areas occurs from the interproximal enamel wear between the anterior and posterior teeth, and there can be up to a 1 cm decrease in the overall anteroposterior dental arch length, as the wear becomes advanced

WWW.HIGHDENT.IR
همیار دندانسازان و دندانپزشکان

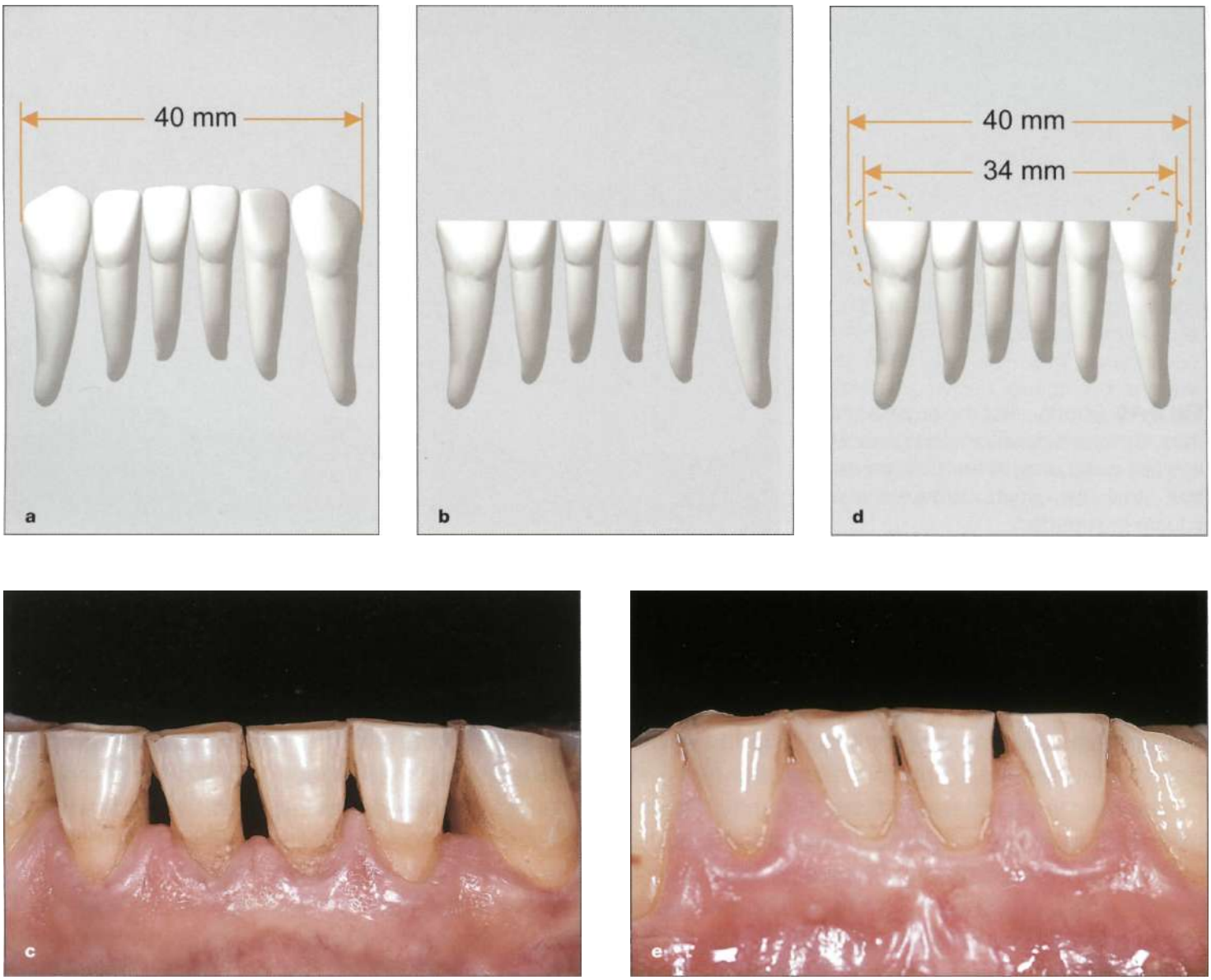

Fig 2-50a-e (a, b) Owing to wear, the length of the mandibular teeth reduces (c, d, e). As this continues to a level more apical than the "interdental contact point" (ICP), the teeth drift towards the lingual in order to preserve these contacts by narrowing the dental arch.

with age (Fig 2-50).[109] This excessive wear can eventually lead to narrowing of the teeth. For class I classification, the incisal edges of the maxillary central incisors tend to wear more cervically, affecting the lingual, ratherthan the labial enamel. Eventually, the maxillary central and lateral incisors will exhibit the same incisogingival length.[85] As the incisal wear continues, the lateral and central incisors and canines wear evenly, creating a flat incisal silhouette (Fig 2-51). This silhouette is quite characteristic of an aged occlusal plane without the incisal embrasures. Unlike the youthful smile that becomes flat and broad owing to the steep curve of the occlusal plane, the aged smile is affected by the dental attrition and changes in the tissue elasticity and facial muscle contractility.

Little or no incisal wear is characteristic of a class II incisor relationship. In patients with class II occlusion, and parafunctional habits such as bruxism or tooth grinding, the labial surfaces of the incisors tend to wear cervically. The patient's position is determined according to the individual's occlusal type, and the canine's wear-patterns tend to be similar or not flat.[103]

WWW.HIGHDENT.IR
همیار دندانسازان و دندانپزشکان

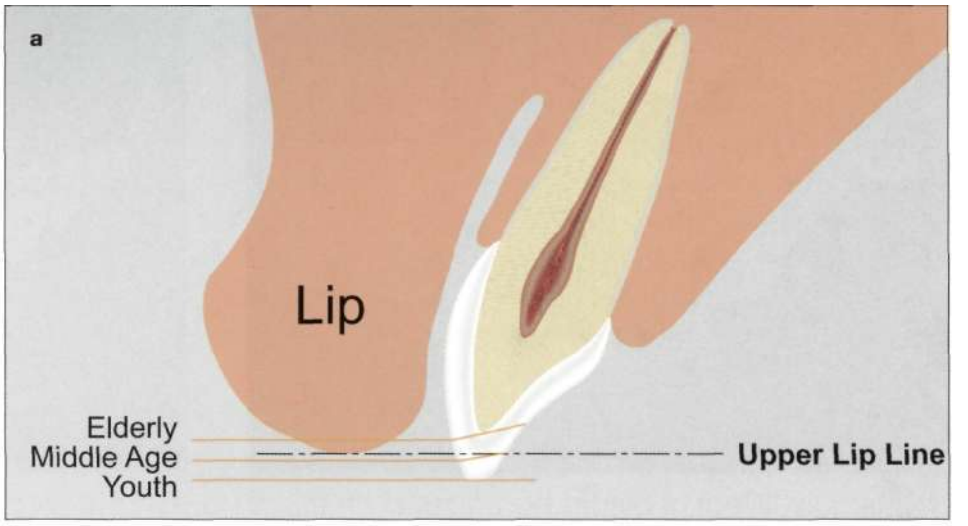

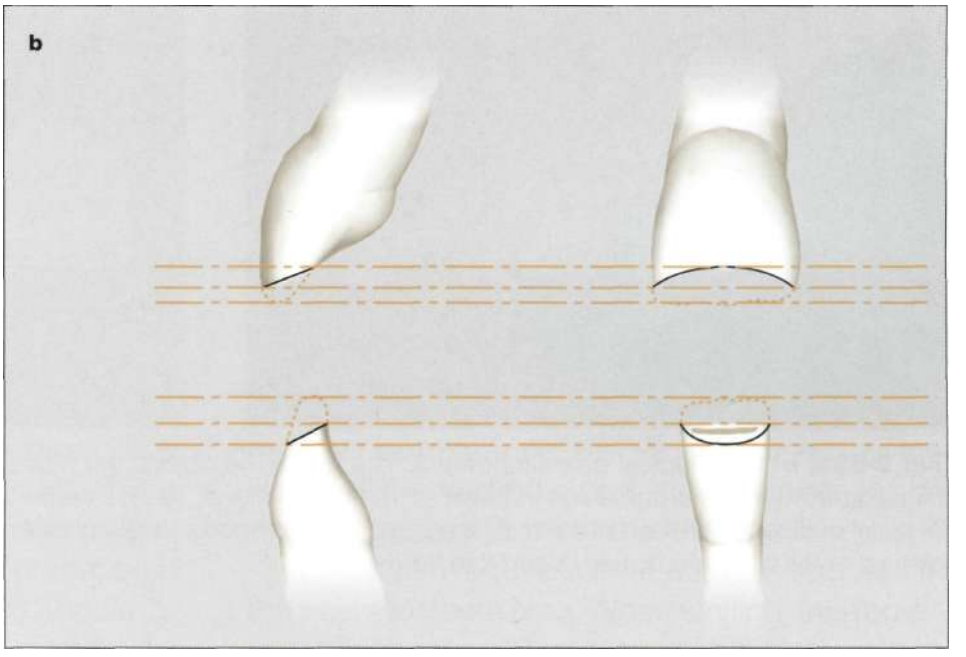

Fig 2-52a-c (a) Owing to wear, changes in tooth display occur during aging, (b, c) The loss of overall vertical dimension of occlusion will accelerate the maxillary and mandibular tooth wear.[131]

WWW.HIGHDENT.IR
همیار دندانسازان و دندانپزشکان

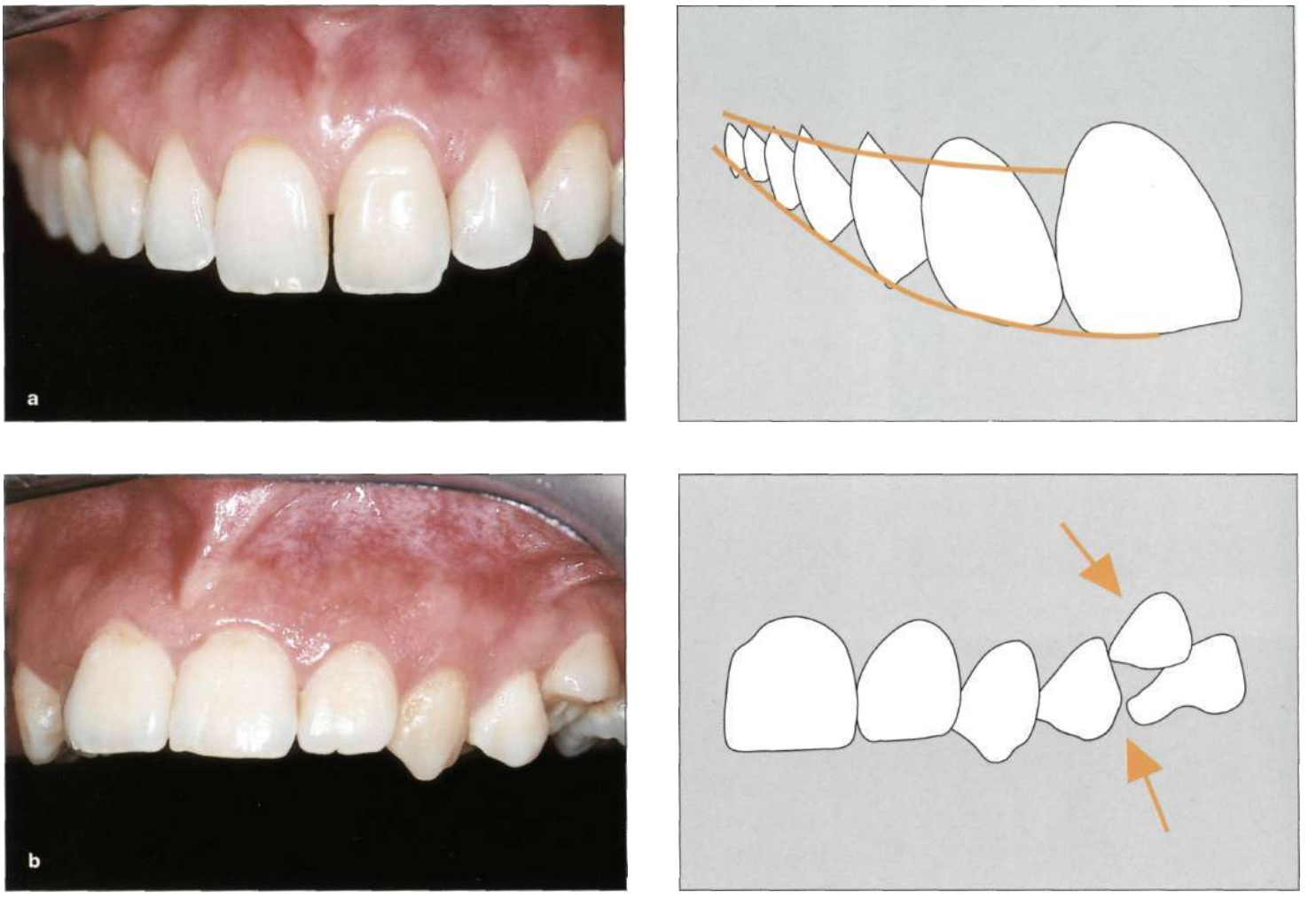

Fig 2-53a, b (a) A typical gradation effect. The larger the object, the nearer it appears to be. The natural smile has a pleasing front-back progression in terms of vertical relations. The perception of this progression requires the alignment of facial outlines and those of the incisal edges, (b) Unproportional gingival or incisal levels and the tooth inclinations and distinct color differences may distort this harmony.

The translucent enamel is lost over years of wear and function. The enamel layer becomes thinner from simple daily functions, such as tooth brushing and eating, and as a result, the dentine begins to dominate the shade. Although the reason for these changes is not fully understood, daily oral habits allow the pigments and ions to be absorbed into the teeth; in time, combining with the decreased enamel thickness, they dominate the shade of the dentition that becomes progressively darker. Changes in the underlying dentine, owing to aging or pathologically related color changes, also contribute to this phenomenon. Similarly, unlike young teeth, aged teeth exhibit higher chroma and less value.[96,99,100] The translucent porcelain, and the depth and extent of the enamel built into the restoration, will depend on the effects that needed to be incorporated related to how young the smile should be designed.[101]

These changes affect not only the appearance of the teeth, but also theirfunction. Highersurface stains and increased crown flexibility are caused by the progressive thinning of the enamel. It is possible to re-establish a youthful smile, and the appearance and function of the crown, through the restoration of the lost tooth volume. In preservation of the remaining elements of the tooth, enamel should be the priority in any treatment approach, and the degree of success of the final outcome is related directly to such preservation. Although many of the techniques used in porcelain veneer preparation actually expose the

WWW.HIGHDENT.IR
همیار دندانسازان و دندانپزشکان

dentin, enamel preservation is possible through specific techniques (see Chapter 7). As the process of aging takes place, teeth tend to drift to the middle of the face; and over a period of time crowding of the dentition becomes progressively worse.[111]

Gradation

There is a natural bilateral progression in the size and shape of the teeth from the central incisor to the most visible posterior tooth, as can be observed when the maxillary dental arch is viewed from the anterior aspect. When viewing two separate but similar objects from a distance, the one closest will appear to be the larger of the two. Despite having the same occlusogingival length, when the teeth are closer to the viewer as in the case of the central incisors, they appear larger; however, when they are further away, as in the case of the premolars, they appear smaller. In the posterior progression of the teeth, the lateral incisors and the canines tend to be proportionately reduced in size. This effect, which aids in creating an illusion and results in a pleasing dentition, is referred to as "the principle of gradation of size".[108] Any other similar structures should be introduced and aligned accordingly, creating a gradual reduction in size when viewed from the closest to the farthest. The contour and alignment of the buccal surface, incisal third, and the alignment of the incisal mesiobuccal inclines are very important. At a secondary level, the lower rate and the gingival third are the prerequisites for the front-back progression (Fig 2-52).[91]

The gradation effect may be distorted if there are colored or distorted restorations, improperly placed teeth, or differences in tooth and gingival length. The key tooth in the arch form determines this natural transition that creates the front-back perception. The most important elements in achieving this transition are the canine and the premolar positions in the buccal corridor and the gradation effect that they create. The gingival area is very important in such restorations. Frequently, it is not given the necessary consideration, and can even destroy the illusion of the front-to-back gradation. When performed improperly and when the illusion of gradation is impaired, the viewer's attention is drawn directly there in an effort to see what is actually esthetically wrong in the dentition. When viewing a smile, it is not only the teeth that should be considered, but also the illusion of depth and distance, along with the gradual elevation of the maxillary posterior occlusal plane as the teeth are followed posteriorly.[108]

The amount of light or illumination that strikes the teeth is an important aid in the illusion effect. In altering tooth illumination, the gradation effect is made possible by the negative space created by the buccal corridor or lateral negative space that exists between the buccal outline of the posterior teeth and the corner of the mouth. An illusion of depth is created in such a manner. The prosthodontist is able to manipulate these elements to enhance the characteristics of that particular patient's personality. The dark anterior "negative" space creates a clear contrast between the incisors and the lower lip in the anterior region and this color contrast, in turn, adds a dynamic external appearance[68,91-106] influenced by the width of the vestibule and the variances in the width of the arch form of the teeth.[95]

A bilaterally equal buccal corridor appears in the posterior teeth area. When smiling, this region between the buccal surfaces of the teeth on one side, and the internal surface of the cheek and the angle of the mouth on the other side, appears to darken posteriorly. The buccal corridors are occluded bythe buccolingual position of the maxillary canines, emphasizing this effect. Patients are not aware that this negative space needs to be emphasized, and yet this is the key to achieving harmony in the smile. The harmonious proportionate relationship between the facial features and the smile itself is made possible by this space.[91]

WWW.HIGHDENT.IR
همیار دندانسازان و دندانپزشکان

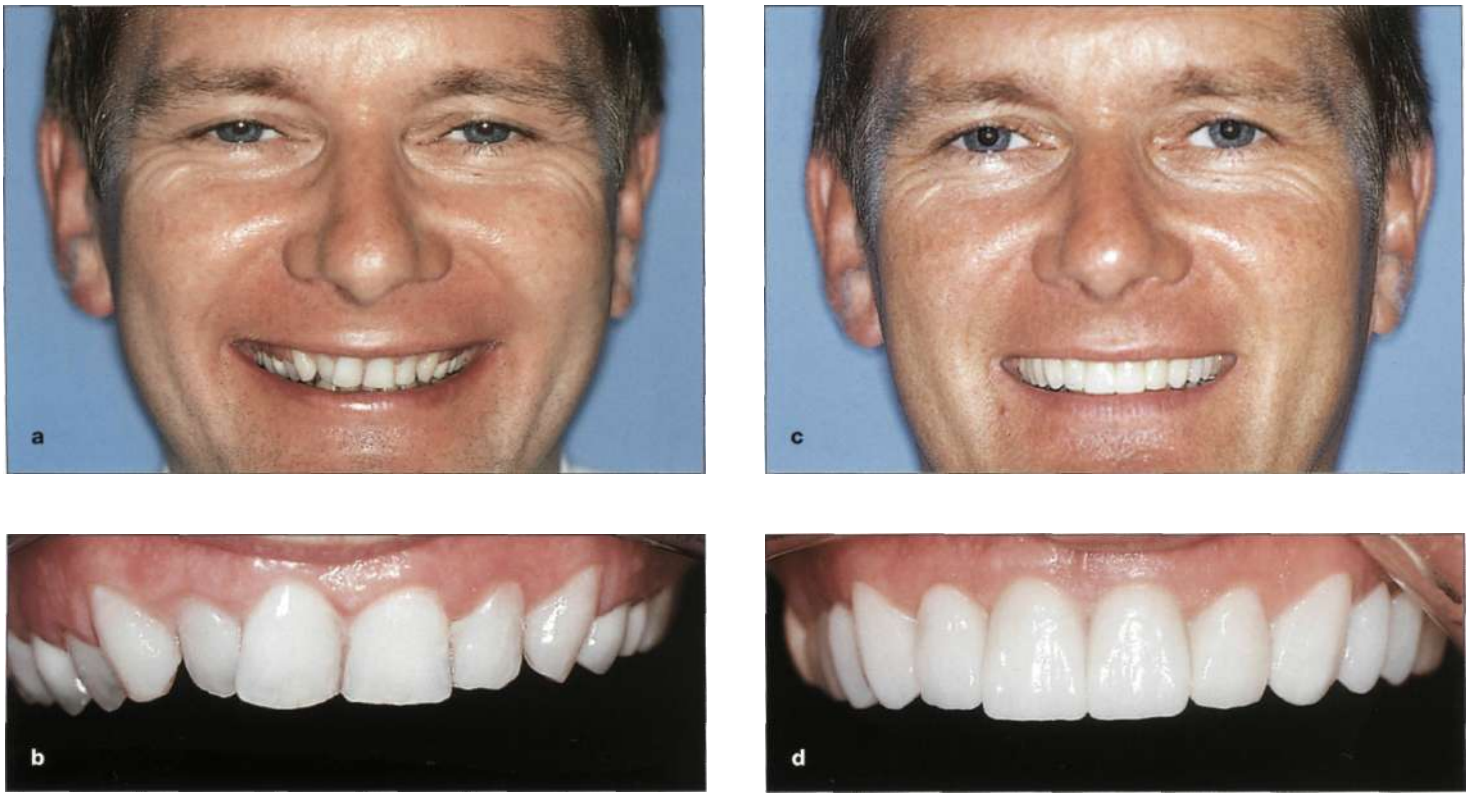

Fig 2-53a-d (a) The symmetry and balance were lost in this case, creating a negative visual tension. The disharmony of the teeth beyond the central incisors, horizontally and vertically, influences this negative tension, (b) To relieve the tension and disharmony, the gingival levels that were placed incisally must be altered apically. Following periosurgery, the vertical alignments of the premolars are corrected to improve the gradation effect. Note the extremely short premolars resto red with porcelain laminate veneers, as opposed to the natural pleasing vertical length. To provide balance and fill the buccal corridor, the lingually tilted short premolars have been slightly contoured with porcelain laminate veneers. When applied on the central incisors, symmetry is achieved. The central incisors provide the symmetry; the posterior segment provides the balance, (c, d) Balance is instated with the vertically and horizontally altered posterior teeth perception. The overall effect of the smile is totally integrated within the whole face.

Symmetry and Balance

When speaking about the esthetic beauty of a composition, symmetry and balance should always be considered. Symmetry may be explained as the harmonious arrangement of several elements with respect to each other[106] and which can be observed on both sides of a central axis. If the object displays a mirror image on both sides of the center, it can be said to have "static" symmetry. "Dynamic" symmetry refers to the condition in which two very similar but not identical halves are opposed.[106] Such minor deviations and irregularities will impart a more vital, dynamic and natural effect to the smile. Diversity adds charisma, and is an important part of beauty. A specific geometric alignment cannot create the same effect. Recognition of these characteristics has caused the restorations of individual teeth to evolve from being similar to one another to being more individualized in their appearance.[112] The nature of the human body presents a dynamic rather than a static form of symmetry, and it should be taken into consideration and applied during the fabrication of anterior restorations as well.[79,113]

Balance must be diffentiated from symmetry. Balance can be observed as the eyes move distally from the center, which is in contrast to symmetry that is centrally located. In balance, objects that are fartherfrom the center grow in importance and weight. The elements of balance should not be alike; however, when observed, they should display a comfortable, relaxing visual tension.

WWW.HIGHDENT.IR
همیار دندانسازان و دندانپزشکان

Fig 2-54 When the imaginary lines, drawn from the zenith points or the cusp tips of the canines, are not parallel to the pupillary line or horizon, an unpleasant smiling line occurs.

Balance can also be defined as the stabilizing result from the exact adjustment of opposing forces.[114] If balance cannot be achieved, the equilibrium of the composition cannot be maintained. The equilibrium and balance can be reinstated either by moving the causative element towards the line of forces until the magnitude of the visual tension is released, or by introducing an opposite element along the line of forces (Fig 2-53).[114] Since the central incisors tend to be the main focus, their asymmetry may have a negative effect on the smile, as in the case of overlapping central incisors that occupy more facial position, or in the cases where one of them is rotated facially, distorting the perception of symmetry. There are various types of asymmetric problems. Sometimes a canine may be more facially inclined or the mesial incisal angle of the central incisors may be rotated towards the opposite sides. Any of the anterior teeth may be inclined, abraded or rotated so that asymmetry occurs.[114]

Although the patients may not realize it, their perception of an attractive smile subconsciously expects a certain amount of facial symmetry. It is not enough for the smile alone to be symmetric, but the smile must also be in harmony with the facial components.[24] This pleasant relation between the teeth and lips is possible when the alignment of the commissural line (that connects the corners of the mouth) and the imaginary line (that connects the incisal tips of the maxillary canine teeth) is parallel. When these two lines are parallel to the infraorbital line and perpendicular to the facial mid-line, they reflect positively on the entire facial composition, resulting in a pleasant smile, otherwise the whole composition will be distorted (Fig 2-54). Ideally, the dental mid-line is in the center of the smile and is determined by the nature of the symmetry of the dental composition.

Smile Line

The Smile

Facial expressions are a part of our nonverbal communication, along with the less descriptive hand and body gestures. The most vivid of all our facial features is the smile,[108] as it is an extension and expression of the person as a whole. The beauty of a person's face is enhanced by a pleasant smile and reflects the virtues and qualities of that person's character.[91] The smile is one of the most expressive forms of nonverbal communication and it can convey countless emotions, from thesmall grin of embarrassmentto the widersmile of happiness and enchantment to the full-teeth dazzling smile of exhilaration. It may last for a fleeting moment or remain intense, but it reveals the emotions of happiness and joy.[68] As each stage of human life lengthens owing to better nutrition and medical care, a middle-aged person is no longer considered old and, therefore, the period of time deemed "youth" has been extended, physically and psychologically.[91]

As more and more emphasis is placed on youth, it has become a challenge for the esthetic

WWW.HIGHDENT.IR
همیار دندانسازان و دندانپزشکان

dentist to restore the aged smile. A youthful smile makes an individual feel young and improves their self-esteem. From a cultural standpoint, a prominent smile with bright teeth is synonymous with youth and dynamism.[115] In a young smile, the maxillary anterior teeth are more visible than their mandibular counterparts.[45,116] A more dynamic and youthful smile is created when the incisal embrasures become larger as the contacts are more gingivally located (see Interproximal Contacts) towards the posterior.[89] When observing a patient preoperatively, the esthetic dentist should always evaluate each case individually, since the determination of an older patient to have a young smile may lead us to create unnatural smiles.

Young smiles are whiter and brighter owing to the thickness of the enamel that keeps the darker hue of the dentin partially blocked. The heavy surface texture of the teeth scatters light, creating the perception of high value in color. Certain principles that have been explained are related to essential and structural beauty and therefore must be used in the restoration of the older individual in order to restore esthetics.[91] As beauty has always been related to youth, the media have constantly emphasized this relationship and they have created a demand for a restoration of youth.

From the patient's point of view, an anterior restoration with a perfect marginal fit and great biocompatibility of material with the surrounding healthy gingiva, may have no value unless the smile he or she expects to see is there. Even if the restoration is performed perfectly from the technical point of view, if the facial integration of the restoration is unsatisfactory (i.e. if the patient is not satisfied with the new smile), all the efforts of the dentist and the dental technician from the beginning of the case will be disregarded by the patient.[91] With the steady increase in the popularity of esthetic dentistry, smile design discipline has become an increasingly important aspect of the esthetic plan. In addition to the artistic touch, clinicians must also combine adherence to the principles used in smile design to improve the esthetics of any anterior procedure. The smile is outlined by a pleasant curvature of the upper and lower lips. The position of the angle of the mouth determines the degree of exposure of the gingiva, the width of the buccal corridor and the degree of exposure of the posterior and anterior teeth.[91]

The smile is perceived as beautiful when the fundamental dental and facial elements adhere to esthetic principles, and a harmonious integration into the patient's morpho-psychological profile creates an emotional psychological reaction.[91] The dentist who wants to create a smile design must closely observe the intact smile, the dominant position of the maxillary central incisors, and the art of the esthetic integration of the maxillary incisors in proper proportion to the face. The patient will exhibit a pleasing smile only when the quality and health of the gingiva and dental elements, together with the relation between teeth and lips, are harmoniously adapted to the face.

When smiling, the teeth are fully visible when the upper lip meets the apex of the gingiva showing the central incisors and leaving the gingiva less noticeable.[117] The teeth should be displayed to the first molar and the maxillary anterior incisal curve parallel to the lower lip. Personality traits like warmth, calmness and kindness are integral parts of what makes up an attractive smile.[91] The impact of a smile is not determined solely by the teeth but also by occlusal and engineering issues.[118] Sometimes the perception of a naturally pleasing smile with beautifully altered gingival levels and restored dentition may be distorted by the negative tension of the lips. Asymmetry, as in the case of individuals with paralysis of the lips, can be the cause of an undesired result despite all the necessary steps that have been taken to achieve the desired smile. The way in which people perceive a smile can vary from culture to culture: in North America, for example, where dental crowding is found to be very unattractive,[119] while the Europeans, on the other hand, tend to find certain irregularities quite acceptable.[121,122]

The Lips

The teeth, visible in laughter and in speech, are framed by the lips.[106] A harmonious morphologic and esthetic relationship is sought for the

WWW.HIGHDENT.IR
همیار دندانسازان و دندانپزشکان

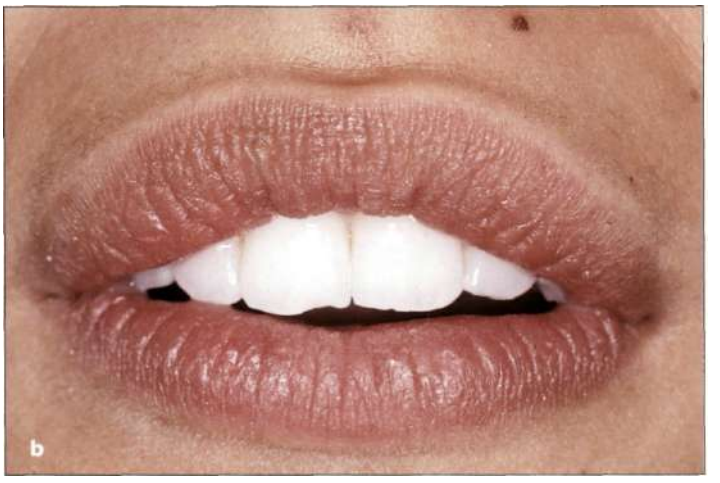

Fig 2-55a, b Lip sizes may differ from person to person, ing the appearance of the smile.

dental elements that are framed by the lips. The lips are centered in the lower third of the face and consist of nerves, vessels, labial glands and alveolartissue. The enclosing oribicularis oris muscle joins the lips superiorly to the base of the nose, laterally by the nasolabial sulci and inferiorly by the mentolabial sulcus. When compared to the upper lip, the lower lip has a tendency to be wider, fuller, longer and more elastic.[16] A vertical depression, called the "philtrum", is located on the upper lip. It proceeds superiorly on the facial skin from the tubercle of the upper lip and runs to the base of the nose. The philtrum is one of the most important landmarks when the placement of the dental mid-line is of concern (see Figs 2-1 and 2-5) The variations in lip posture may depend on racial and/or gender differences, especially in size, contour, shape, position, and in the range of exposure of the natural dentition (Fig 2-55). These variations may also occur owing to the shape, length and activity of the lips and their support, which is based on the position of the alveolar process and teeth.

When viewing a patient with class I skeletal relation and a natural detention from a lateral aspect, the external contour of the upper lip is projected beyond the lower lip. In other more severe cases such as class III malocclusion, where the lower lip may protrude beyond the upper, or the class II malocclusion, when the mandible is in a physiologic rest position with the upper lip protruding well beyond the lower, greater variations of the lips can be observed (Fig 2-56). In action or at rest, the volume of the lips, along with their length and shape, have an important role in determining tooth shape and spatial arrangement. The degree of lip protrusion or retrusion and their effect on the facial profile is important.[123-127] The dentition and the alveolar bonefurnish thetotal anatomic support of the lips, whilethe maxillary anteriorteeth supportthe lower half of the upper lip. It is actually the tooth position, as opposed to the position of the incisal edge, that establishes the position of the upper lip,[126] and this has been supported in studies that have found that in 70% of cases the support comes not from the incisal 1/3rd but the gingival 2/3rds of the maxillary incisors.[127] The maxillary teeth are the primary support for the upper lip, but it can vary according to the type or shape of the lip. The position of the lips has a greater effect on the thinner, protruding lips than those that are vertical, thick or retruding.[128]

The support of the lower lip is derived from a balance of the alveolar process and the mandibular teeth. Lip design, when approached from the morphologic aspect, is a combination of sentimental, cerebral and instinctive action, and it is related directly to its dentoalveolar support with which it is connected. The tonicity and strength of the muscular support are important, and the facial musculature will be affected by any changes made to the dentoaveolar support. Aging has a considerable effect on the muscle tone, and a

WWW.HIGHDENT.IR
همیار دندانسازان و دندانپزشکان

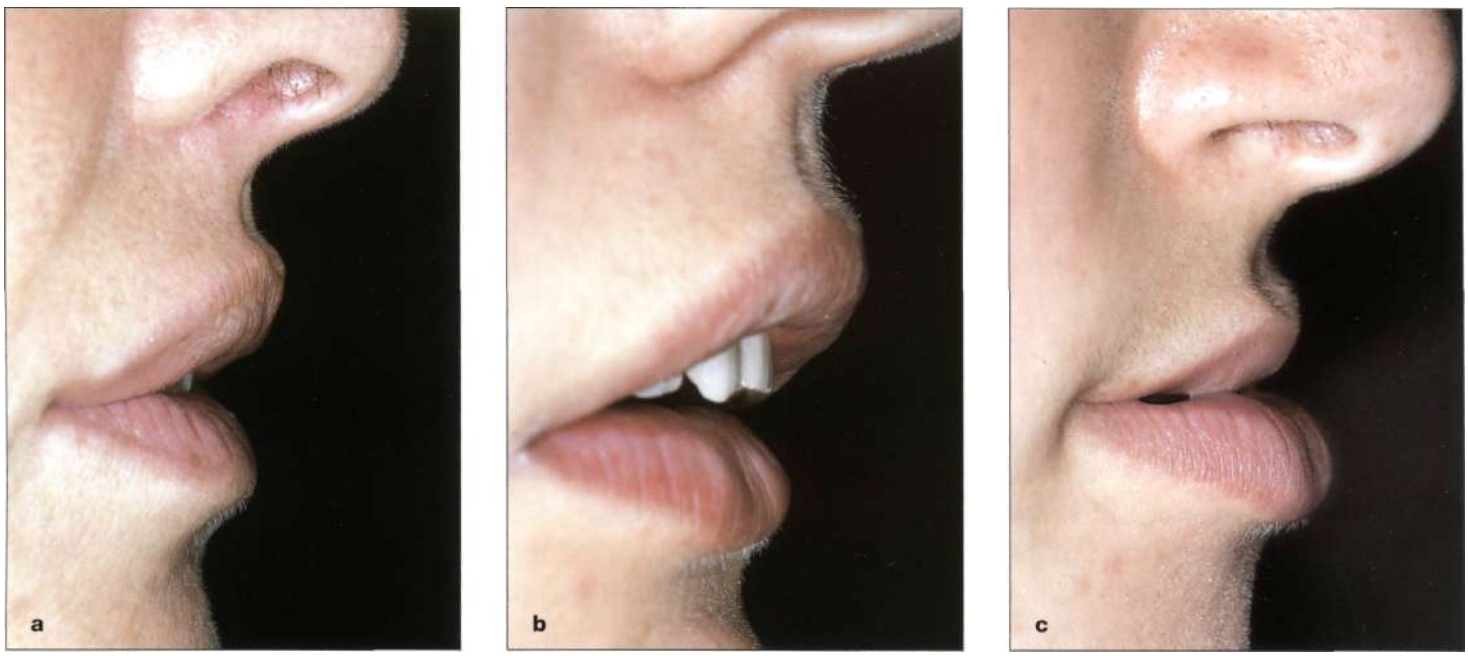

Fig 2-56a-c The lip profiles can be affected by the occlusion relationships, (a) Class I (b) Class II (c) Class

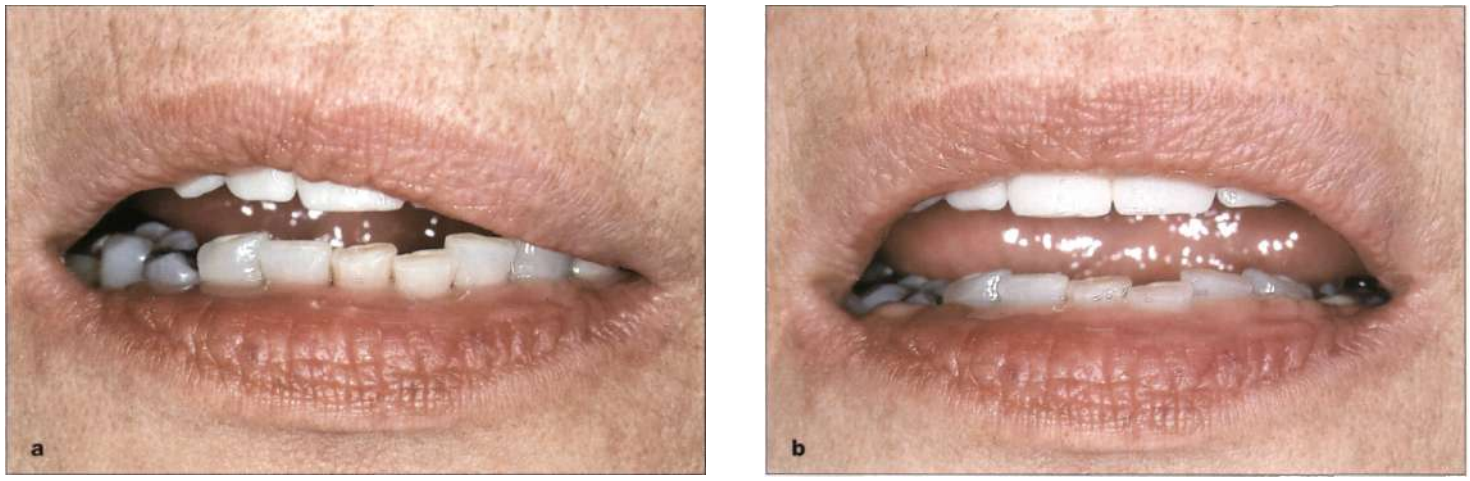

Fig 2-57a, b If the muscle tone is lost, the lips may sag owing to gravity, (a) A patient with an incisal line asymmetry; the lips are sagging towards the right. This may happen owing to the position of the head, if the smile line is to be verified with the patient on the dental chair with her head tilted to the right, (b) The same patient, with the same incisal line, in an erect position. The normal relation between the upper lip and the incisal line can now be properly observed. Note that no asymmetry actually exists.

general reduction of the tonicity and gravity causes the upper lip to elongate in the older patient. Consequently, when the lips are parted, the mandibular incisors become more prominent, and the maxillary incisors become less visible.[45] Different positions of head posture can easily change the vertical or horizontal display of lips owing to the weaker muscle tone.

Clinically, one of the most common mistakes made is the attempt to evaluate the incisal edge position when the patient is lying on the chair. This istrue especially when working with older patients who have lost lip muscle tone. Owing to the working position of the dentist when the patient is lying on the chair, the only way for the dentist to see the patient directly from the facial aspect is to ask him/her to turn their head towards the side. However, owing to muscle sag and gravity, the upper lip will move towards the side of the face that has been turned. It will usually be to the right

WWW.HIGHDENT.IR
همیار دندانسازان و دندانپزشکان

if the dentist is sitting at a 10 o'clock position. The right lateral and central incisors #7 and #8 (#12 and #11) will show more incisal edge than the left central and lateral incisors #9 and #10 (#21 and #22), because the left side of the upper lip will tend to cover the latter. The result will be an artificially inclined incisal edge position, which may mislead the perception of an inexperienced dentist. To overcome this problem, the patient should be seated in an upright position with their feet on the floor, facing the dentist and with their head perpendicular to the horizon (Fig 2-57).

Photographs from the patient's younger days will help the dentist to understand the previous tooth form and arrangement; however, they will have little use when planning the anterior smile and especially the position of the lips. The dentist must be sensitive to the patient's age and make the patient feel positive about the realistic changes that will take place.

Lip Lines (Upper and Lower)

The upper and lower lips influence a pleasing smile. Afunctional equilibrium exists between the forces and the compensatory action of the cheek musculature and the lips and therefore determines the natural tooth position. Dynamic oral movements are related to tooth support, and a relaxed tooth posture is present and independent of the tooth and alveolar process.[127]

The volume, shape and length of the lips are important parts in assessing the teeth when the lips are at rest or active.[103] The upper lip line has a significant correlation with the maxillary anterior teeth display as well as the gingiva. The lip line, its length and its curvature may vary, depending on the age of the patient and the anatomy of the face. This line also affects the level of tooth exposure when at rest. In close relation to this line is the incisal edge of the maxillary and mandibular teeth. At the same level to the bipupillary and occlusal plane is a parallel line to the angles of the mouth that confirms that the lip lines are horizontally lined up in a pleasing manner.[106] Before any restorative procedure is initiated, the lip position should be evaluated.

By their display of gingiva, the lip lines can be classified in three groups - high, medium (Fig 2-58a, b) and low (Fig 2-59a). A low lip line covers the gingiva and a considerable portion of the anterior teeth. In such cases, it is difficult to see the incisors when the lips are at rest. In fact, when the patient speaks, these teeth can barely be seen. The anterior teeth may be displayed when the patient is in full smile. For the teeth to be seen, it may be necessary to lengthen the crowns if the crown-root ratio and occlusion permit. The dentist may have to perform a major alteration in the proportions to establish a balance between the length of the lip line when at rest and when smiling (Fig 2-59).[103] In such cases, the dentist may have problems while trying to lengthen the maxillary incisors, and the result may be overlengthened teeth. It may be difficult at times to see the anterior teeth when the lips are at rest position even if the central and lateral incisors are lengthened. In the cases with gingival asymmetry, the advantage of the low lip line is that the gingival levels do not have to be altered, as they will not be seen even in a strained smile. Therefore, if the gingival levels are not symmetric, or the papilla is missing, these levels do not have to be esthetically altered and extreme care should be given to ensure the maximum health of the gingival at all times, even though it will be hidden. The low lip line should not become a coverfor poor dentistry, by hiding the gingival one-third of the restorations and the gingiva.

The classification of medium lip line applies to the lips where 1-3 mm of the incisal edges of the incisors are seen at rest. When in a full smile, the level of the upper lip extends apically to a level where the tips of the papilla and a small portion of the gingiva are displayed. A medium lip line is considered to be the most preferable.

The high lip line can be seen on a small percentage of the patients, where more than 4-5 mm of the gingiva is exposed during a moderate smile.[25] Treatment of the high upper lip line is limited. A high lip line may often appear aggressive owing to the large display of gingiva. It will adversely affect individuals who have maxillary protrusion or strong infraorbital facial musculature.[91]

WWW.HIGHDENT.IR
همیار دندانسازان و دندانپزشکان

Fig 2-58a, b Varied lip lines display different tooth lengths and gingiva; for creating a pleasing smile (a) the medium lip line is the best, (b) High or low lip line may create esthetic problems.

Fig 2-59a-i (a) Low lip line with relatively short teeth. It is not possible to see the teeth when lips are at rest or half smiling (b, c). The short length of the maxillary anteriors. The silicon index from the wax-up indicates how the teeth should be elongated, (d) The teeth are covered with the esthetic pre-evaluative temporaries (APT) (see Chapter 7) before the AMT (actual material preparation). The patient can now visualize the new length and color of her teeth. And the preparation is done over the APT. (e) Finished porcelain laminate veneers and their relation to the upper lip. Note that, even in half smile, the incisals of the anterior incisors can easily be seen, (f, g) The lip support of the porcelain laminate veneers. The upper lip stays retruded before the restoration, (h, i) the very positive impact of the new smile on the face.

WWW.HIGHDENT.IR
همیار دندانسازان و دندانپزشکان

Fig 2-59b-d

Fig 2-59e-g

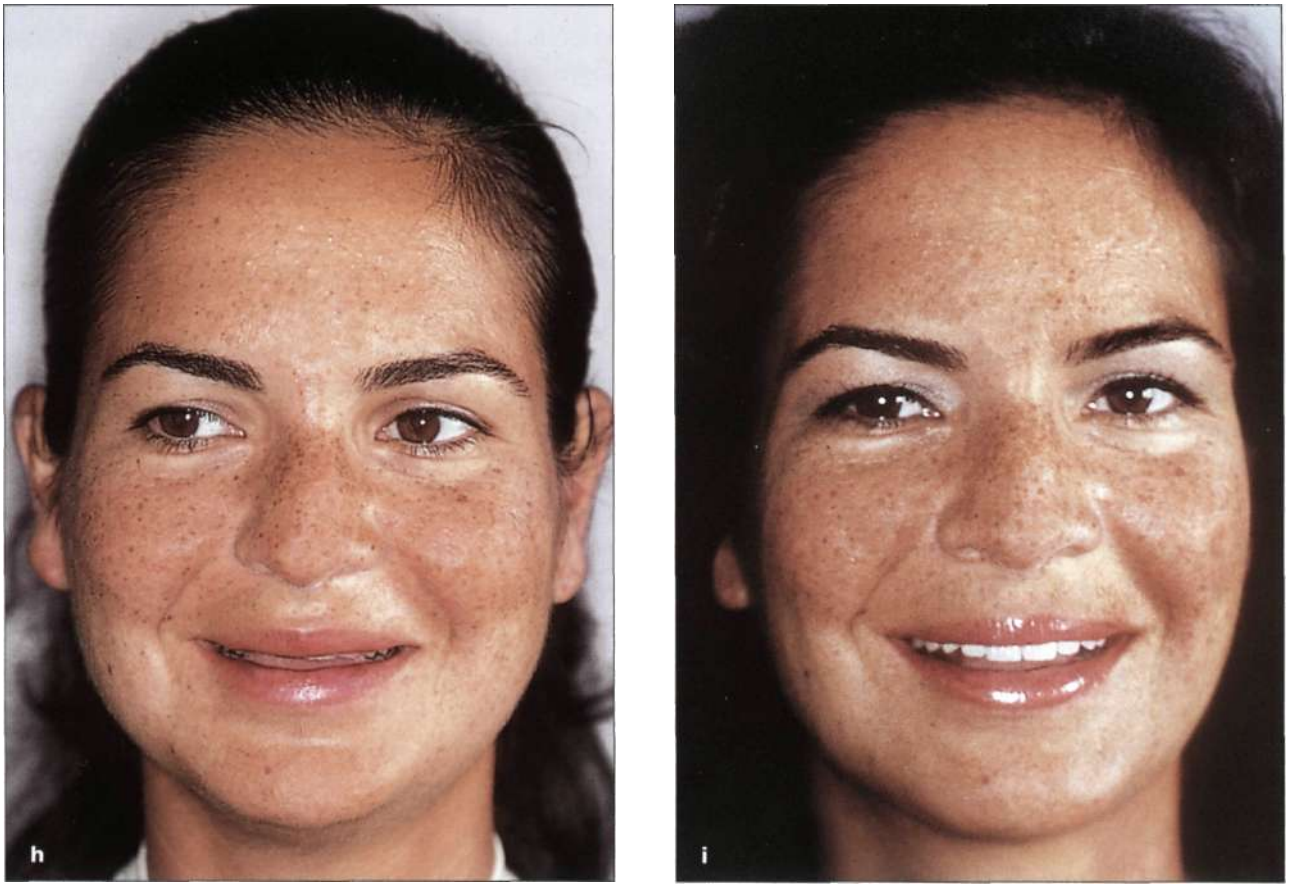

Fig 2-59h,

WWW.HIGHDENT.IR
همیار دندانسازان و دندانپزشکان

Fig 2-60a-c (a) Dark and short teeth are treated with 10 maxillary and 10 mandibular porcelain laminate veneers, (b) Owing to small and dark-colored teeth, the patient had lost the habit of smiling entirely, and the actual smile line is misjudged. Instead, the existing false smile line is taken into consideration. Since the patient liked the new appearance of the newly veneered dentition, the habit of smiling reinstated itself naturally, displaying more gingiva, (c) After 2 years, a simple gingivectomy was performed to alter the gingival levels to suit the new true smile line. The veneers are replaced accordingly. The new smile line does not exhibit any undesirable gingival tissue.

In medium and high lip lines, if the gingival display is unpleasant, such as in the case of the "gummy smile", or if gingival asymmetries are present, they should be carefully altered by the means of ortho, perio, or orthognatic surgery. The alteration should be performed only when the conditions allow and according to the esthetic demands of the patient. Even if the porcelain laminate veneers are designed esthetically, the gingival asymmetries will distort the final smile (see Chapter 10).[129] Sometimes the patient forgets how to smile owing to the unesthetic nature of their existing teeth. So even if they are asked to give a full smile, they think they are smiling extensively but they are not. Care should be paid to this aspect while restoring such cases, since after the porcelain laminate veneers are inserted, the patient will enjoy their bright and energetic appearance and start smiling more and more. And in some cases the dentist can end up wit a semi-gummy smile, which did not exist before (Fig 2-60). Therefore, this false smiling line that exists in the beginning must be carefully evaluated.[94]

Smile Line

The smile line is the lower margin of the upper lip that limits the visibility of theteeth.[130] This line also follows the edges of the maxillary anterior teeth that follow the curvature of the inner border of the lower lip. A pleasing smile is achieved when the angles of the mouth are parallel to the bipupillary line and the occlusal plane, with the tips of the canines barely touching the lower lip.[91] The lower lip curves upward and posteriorly to the corner of the mouth where it meets the upper lip. The viewer's attention is drawn to the dentition that is framed in the upward curve of the lips. As the viewer's eye is attracted to the elevation of the lower lip, it is focusing on the occlusal and incisal planes. The visible maxillary teeth have a connecting or incisal line convex, caudal and incisal that runs parallel to the upper margin of the lower lip.[91] This line can vary from individual to individual, and it is more pronounced and convex in females (Fig 2-61).

WWW.HIGHDENT.IR
همیار دندانسازان و دندانپزشکان

Fig 2-61a, b In a pleasing smile, the incisal edges of the incisors follow convex curvature, which is parallel to the lower lip. (a) The lower lip in men is fairly straight (b) when compared to the female lip. That creates a smile line that is flattering in males.

Conclusion

Esthetic procedures have the ability to alter the entire appearance of the patient by providing them with a beautiful smile. The patient gains not only a positively improved appearance, but also a potential moral "boost" that acts positively on their mental health and self-esteem. Any restoration to be performed must take into account the personality of the patient, and interpret and integrate it into the procedure. The importance of psychological factors that may enhance or affect the esthetic appearance should never be underestimated.

Although the dentist should always have a solid knowledge of the parameters that set a beautiful smile, they must also interpret and apply their own artistic skills in order to obtain a pleasing smile that is facially integrated.

WWW.HIGHDENT.IR
همیار دندانسازان و دندانپزشکان

References

1. Jenny J, Proshek JM. Visibility and prestige of occupations and the importance of dental appearance. J Can Dent Assoc 1986;12:987-989.
2. Dale BG, Aschheim KW. Esthetic Dentistry: A Clinical Approach to Techniques and Materials. Philadelphia, PA: Lea and Febiger, 1993:81-98.
3. Ramadan FA, Harrison JD. Literature review of the effectiveness of tissue displacement materials. Egypt Dent J 1970;16:271.
4. Nemetz EA, Seibly W. The use of chemical agents in gingival retraction. Gen Dent 1990;38:104-108.
5. Donovan TE, Gandara BK, Nemetz H. Review and survey of medicaments used with gingival retraction cords. J Prosthet Dent 1985;53: 525-531.
6. Gwinnett AJ. Moist vs dry dentin: Its effect on shear bond strength. Am J Dent 1992;5:127-129.
7 Moskowitz M, Nayyar A. Determinants of dental esthetics: A rationale for smile analysis and treatment. Compend Contin Educ Dent 1995;16:1164-1186.
8. Powell N, Humphreys B. Proportions of the Aesthetic Face. New York: Thieme-Stratton, 1984:2,4-9,50.
9. Lombardi RE. The principles of visual perception and their clinical application to denture esthetics. J Prosthet Dent 1973;29:358-382.
10. Cipra DL, Wall JG: Esthetics in fixed and removable prosthodontics. The composition of a smile. J Tenn Dent Assoc 1991;71:24-29.
11. Moskowitz M, Nayyar A. Determinants of dental esthetics: A rationale for smile analysis and treatment. Compend Contin Educ Dent 1995;16:1164-1186.
12. AAOMS. Dentofacial deformities: Evaluation guide 1986; 2:9.
13. Lejoyeux J. Prothese Complete. 3rd ed. Paris: Maloine, 1979.
14. Heartwell CM. Syllabus of Complete Dentures. Philadelphia, PA: Lea and Febiger, 1968.
15. Faes R. Naturliche and kunstliche obere Frontzahne. Schweiz MonatsschrZahnheilkunde 1941;51:785-801.
16. Renner RP. An Introduction to Dental Anatomy and Esthetics. Chicago: Quintessence, 1985:241-273.
17. Miller EC, Bodden WR, Jamison HC. A study of the relationship of the dental midline to the facial median line. J Prosthet Dent 1979;41:657-660.
18. Johnston CD, Burden DJ, Stevenson MR. The influence of dental midline discrepancies on dental attractiveness ratings. Eur J Orthod 1999;21:517-522.
19. Rufenacht, CR. Fundamentals of Esthetics. Chicago: Quintessence, 1990:67-134.
20. Fruch JP, Fischer RD. The dynesthetic interpretataion of the dentogenic concept. J Prosthet Dent 1958;8:560-681.
21. Morley J, Eubank J. Macroesthetic elements of smile design. J Am Dent Assoc 2001 ;132:39-45.
22. LattaGH.Themidlineanditsrelationtoanatomiclandmarks in the edentulous patient. J Prosthet Dent 1988;59:681 -683.
23. Miller LL. Porcelain crowns and porcelain laminates. Problems and solutions. Quintessence International Symposium (1991). New Orleans.
24. Chiche GJ, Pinault A. Esthetics of anterior fixed prosthodontics. Chicago: Quintessence, 1994; 13-32,53-74.
25. Allen EP. Use of mucogingival surgical procedures to enhance esthetics. Dent Clin North Am 1988;32:307.
26. Shillingburg Jr HT, Kaplan MJ, Grace CS. Tooth dimensions. A comparative study. J.South Calif Dent Assoc 1972; 40:830.
27 Bjomdal AM, Henderson WG, Skidmore AE, Kellner FH. Anatomic measurements of human teeth extracted from males between the ages of 17 and 21 years. Oral Surg Oral Med Oral Pathol 1974;38:791.
28. Woelfel JB. Dental Anatomy: Its Relevance to Dentistry. 4th ed. Philadelphia, PA: Lea and Febiger, 1990.
29. Qaltrough AJE, Burke FJT A look at dental esthetics. Quintessence Int 1994; 25:7-14.
30. Pound E. Personalized Denture Procedures. Dentists Manual. Anaheim, CA: Denar, 1973.
31. Dawson PE. Determining the determinants of occlusion. Int J Periodont Rest Dent 1983;3:9.
32. Heinlein WD. Anterior teeth: Esthetics and function. J Prosthet Dent 1980;44:389-393.
33. Robinson SC. Physiological placement of artificial anterior teeth. Can Dent J 1969;35:260-266.
34. Pound E. Let "S" be your guide. J Prosthet Dent 1977; 38:482.
35. Stein RS, Kuwata M. A dentist and a dental technologist analyze current ceramo-metal procedures. Dent Clin North Am 1977;21:729-49.
36. Kay HB. Esthetic considerations in the definitive periodontal prosthetic management of the maxillary anterior segment. Int J Periodont Rest Dent 1982;3:45-59.
37. Stein S. Periodontal dictates for esthetic ceramometal crowns. J Am Dent Assoc 1987;Dec (special issue):63E-73E.
38. Moskowitz M, Nayyar A. Determinants of dental esthetics: A rationale for smile analysis and treatment. Compend Contin Educ Dent 1995;16:1164-1186.
39. Miller Jr PD. Root coverage using a free soft tissue autogenous graft following citric acid application. 1. Technique. Int J Periodont Rest Dent 1982;2:65-70.
40. Langer B, Langer L. Subepithelial connective tissue graft technique for root coverage. J Periodont 1985;56:715-720.
41. Coslet G, Rosenberg E, Tisot R. The free autogenous gingival graft. Dent Clin North Am 1980;24:651-682.
42. Abrams L. Augmentation of deformed residual edentulous ridge for fixed prosthesis. Compend Contin Educ Dent 1980;1:205-214.
43. Tarnow DP, Magner AW, Fletcher P. The effect of the distance from the contact point to the crest of bone on the presence or absence of the interproximal dental papilla. J Periodontol 1992;63:995-996.
44. Rufenacht CR. Principles of Esthetic Integration. Chicago: Quintessence, 2000:63-168.

WWW.HIGHDENT.IR
همیار دندانسازان و دندانپزشکان

45. Vig RG, Brundo GC. The kinetics of anterior tooth display. J Prosthet Dent 1978;39:502-504.
46. Wheeler RC. Complete crown form and the periodontium. J Prosthet Dent 1961;11:722-734.
47. Weisgold A. Contours of the full crown restoration. Alpha Omega 1977;70:77-89.
48. Narcisi EM, Culp L. Diagnosis and treatment planning for ceramic restorations. 2001;45:127-142.
49. Berscheid E, Walster E, Bohrnstedt. G. Body image. The American body. A survey report. Psychol Today 1973; Nov: 119-131.
50. Calamia JR. Clinical evaluation of etched porcelain laminate veneers. Am J Dent 1989;2:9-15.
51. Strassler HE, Nathanson D. Clinical evaluation of etched porcelain veneers over a period of 18 to 42 months. J Esthet Dent 1989;1:21-28.
52. Brodbeck U. Scharer P. Ceramic inlays as lateral tooth restorations. Schweiz Monatsschr Zahnmed 1992;102: 330-340.
53. Yamashita A. A Dental Adhesive and its Clinical Application. Tokyo: Quintessence, 1983.
54. Bjorn H, Free transplantation of gingiva propla. Sven Tandlak Tidskr 1963;22:684.
55. Holbrook T Ochseinbein C. Complete coverage of the denuded root surface: A one-stage gingival graft. Int J Periodont Rest Dent 1983;3:8-27
56. Miller Jr PD. Concept of periodontal plastic surgery. Pract Periodont Aesthet Dent 1993;5:15-20.
57 Langer B, Calamia LJ. The subepithelial connective tissue graft. A new approach to the enhancement of anterior cosmetics. Int J Periodont Rest Dent 1982;2:22-33.
58. Rosenthal L. The smile lift: A new concept in aesthetic care. Part 1. Dent Today 1994; 13:66, 68-71.
59. Seibert JS. Reconstruction of deformed, partially edentulous ridges, using full thickness onlay grafts. Part 2. Prosthetic/periodontal interrelationships. Compend Contin Educ Dent 1983;4:549-562.
60. Seibert JS. Reconstruction of deformed, partially edentulous ridges, using full thickness onlay grafts. Part 1. Technique and wound healing. Compend Contin Educ Dent 1983;4:437-453.
61. Miller PD. Regenerative and reconstructive periodontal plastic surgery. Mucogingival surgery. Dent Clin North Am 1988;32:287-306.
62. Rosenthal L, Jacobs JE. The periodontal-prosthetic-esthetic connection. Con Esthet and Res Prac Jul/Aug 1999:1-4.
63. Rosenthal L. State of the art advanced porcelain laminate veneers. Part 2. Esthet Dent Update 1991 ;2:97-101.
64. Rosenthal L, Rinaldi P: The aesthetic revolution: Minimum invasive dentistry. Dent Today 1998; 17:42-44,46-47.
65. Gerber A. Complete dentures. 8. Creative and artistic tasks in complete prosthodontics. Quint Int 1975;2:45-50.
66. Morley J. A multidisciplinary approach to complex aesthetics restoration with diagnostic planning. Prac Perio Aesth Dent 2000;12:575-577
67 Goldstein RE. Esthetics in Dentistry. 2nd ed. Hamilton, ON: BC Decker Inc, 1998:133-186.
68. Matthews TG: The anatomy of a smile. J Prosthet Dent 1978;39:39-34.
69. Rufenacht CR. Fundamentals of Esthetics. Chicago: Quintessence, 1990:13-48.
70. Frush JP, Fisher RD. Introduction to dentogenic restorations. J Prosthet Dent 1955;5:586-595.
71. Frush JP, Fisher RD. How dentogenic restorations interpret the sex factor. J Prosthet Dent 1956;6:160.
72. Frush JP, Fisher RD. How dentogenic restorations interpret the sex factor. J Prosthet Dent 1956;6:441-449.
73. Frush JP, Fisher RD. The age factor in dentogenics. J Prosthet Dent 1957;7:5-13.
74. Frush JP, Fisher RD. Dentogenics: Its practical application. J Prosthet Dent 1959;9:914.
75. Gillen RJ, Schwartz RS, Hilton TJ, Evans DB. An analysis of selected normative tooth proportions. Int J Prosthodont 1994;7:415.
76. Baratieri LN. Esthetics: Direct Adhesive Restoration on Fractured Anterior Teeth. Sao Paulo: Quintessence, 1998:35-56.
77 Moores CFA, Thomsen SO, Jensen E, Yen PKJ. Mesiodistal crown diameters of the deciduous and permanent teeth in individuals. J Dent Res 1957;36:39.
78. Mavroskoufis F, Ritchie GM. Variation in size and form between left and right maxillary central incisor teeth. J Prosthet Dent 1980;43:254.
79. Lombardi RE. A method for the classification of errors in dental esthetics. J Prosthet Dent 1974;32:501.
80. Heymann HO. The artistry of conservative esthetic dentistry. J Am Dent Assoc 1987; (special issue): 14E-23E.
81. Levin EL. Dental esthetics and golden proportion. J Prosthet Dent 1978;40:244-252.
82. Lombardi RE. The principles of visual perception and their clinical application to denture esthetics. J Prosthet Dent 1973;29:358-382.
83. Richer P. Artistic Anatomy. New York: Watson-Guptill, 1971.
84. Borissavlievitch M. The Golden Number. London: Alec Tiranti, 1964.
85. Yamamoto M, Miyoshi M, Kataoka S. Special Discussion. Fundamentals of esthetics: contouring techniques for metal ceramic restorations. QDT 1990/1991 ;14:10-81.
86. Ward DH. Proportional smile design using the recurring esthetic dental proportion. Dent Clin North Am 2001; 45:143-154.
87. Sterrett JD, Oliver T, Robinson F, Fortson W, Knaak B, Russell CM. Width/length ratios of normal clinical crowns of the maxillary anterior dentition in man. J Clin Periodont 1999;26:153-157.
88. Preston JD: The golden proportion revisited. J Esthet Dent 1993;5:247-251.
89. Shillingburg Jr HT, Hobo S, Whitsett LD, Jacobi R, Brackett SE. Fundamentals of Fixed Prosthodontics. 3rd ed. Chicago: Quintessence, 1997; 419-432.
90. Tao S, Lowenthal U. Some personality determinants of denture preference. J Prosthet Dent 1980;44:10-12.
91. Rufenacht CR. Fundamentals of Esthetics. Chicago: Quintessence, 1990:9-31, 59-67, 67-134, 329-368.

WWW.HIGHDENT.IR
همیار دندانسازان و دندانپزشکان

92. Vanini L. Light and color in anterior composite restorations. Pract Periodont Aesthet Dent 1996;8:673-682.
93. Goldstein RE. Esthetics in Dentistry. 2nd ed. Hamilton, ON: BC Decker Inc, 1998:123-133.
94. Dale BG, Aschheim KW. Esthetic Dentistry: A Clinical Approach to Techniques and Materials. Philadelphia, PA: Lea and Febiger, 1993:69-78,128-149.
95. Goldstein RE. Esthetics in Dentistry. 2nd ed. Hamilton, ON: BC Decker Inc, 1998:133-186.
96. Heymann HO. The artistry of conservative esthetic dentistry. J Am Dent Assoc 1987; (special issue): 14-E-23E.
97. Golub-Evans J. Unity and variety: Essential ingredient of a smile design. Curr Opin Cosmet Dent 1994;2:1-5.
98. Goodkind RJ, Schwabacher WB. Use of a fiber-optic colorimeter for in vivo measurements of 2830 anterior teeth. J Prosthet Dent 1973;29:358-382.
99. Brisman A, Hirsch SM, Paige H, Hamburg M, Gelb M. Tooth shade preferences in older patients. Gerodontics 1985; 1:130-133.
100. Winter RR: Achieving esthetic ceramic restorations. J Calif Dent Assoc 1990; 18:21-24.
101. Kessler JC: Dentist and laboratory: Communication for success. J Am Dent Assoc 1987;115:97E-102E.
102. Feigenbaum NL. More than one reality. Pract Periodont Aesthet Dent 1999; 11:136.
103. Touati B, Miara P, Nathanson D. Esthetic Dentistry and Ceramic Restorations. New York: Martin Dunitz, 1999:139-161.
104. Bruce A Singer. Fundamentals of esthetics. In: Dale BG, Aschheim KW. Esthetic Dentistry: A Clinical Approach to Techniques and Materials. Philadelphia, PA: Lea and Febiger, 1993:5-13.
105. Renner RP. An Introduction to Dental Anatomy and Esthetics. Chicago: Quintessence, 1985:187-233.
106. Strub JR, Turp JC. Esthetics in dental prosthetics. In: Fischer J, Esthetics and Prosthetics. Chicago: Quintessence, 1999:11.
107. Morley J. Smile design. Specific considerations. CDAJ 1997;25:636.
108. Renner RP. An Introduction to Dental Anatomy and Esthetics. Chicago: Quintessence, 1985:125-166,187-233, 241-272.
109. Lammie GA, Posselt U. Progressive changes in the dentition of adults. J Periodontol 1965;36:443-454.
110. Richardson ME. A preliminary report on lower arch crowding in the mature adult. Eur J Orthod 1995;17:251-257
111. Touati B. Defining form and position. Pract Periodont Aesthet Dent 1998;10:800-803.
112. TripodakisA-P Dental Esthetics: "Oral personality" and visual perception. Quintessence Int 1987;18:405-418.
113. Geller W. Dental Ceramics and Esthetics. Chicago, 15 February 1991.
114. Goldstein RE. Change your Smile. 1st ed. Chicago: Quintessence, 1984.
115. Wichmann R. Uber Die Sichbarkeit der Front- und Seitenzahne. ZWR 1990;99:623-626.
116. Cosmetic periodontics. Reality Now 2001 ;3:43.
117 Morley J, Eubank J. Macroesthetic elements of smile design. J Am Dent Assoc 2001 ;132:39-45.
118. Graber LW, Lucker GW. Dental esthetic self-evolution and satisfaction. Am J Orthod 1980;77-163.
119. Albino JE, Cunat JJ, Fox RN, Lewis EA, Slakter MJ, Tedesco LA. Variables discriminating individuals who seek orthodontic treatment. J Dent Res. 1981;60:1661-1667; Shaw WC, Lewis HG, Robertson NR. Perception of malocclusion. Br Dent J 1975;138:211-216.
120. Prahl-Andersen B, Boersma H, van der Linden FP, Moore AW. Perceptions of dentofacial morphology by laypersons, general dentists, and orthodontists. J Am Dent Assoc. 1979;98:209-212.
121. Burstone CJ. The integumental profile. Am J Orthod 1958; 44:1.
122. Subtelny JD. A longitudinal study of soft tissue facial structures and their profile characteristics, defined in relation to underlying structures. Am J Orthod 1959;45:481.
123. Tweed CH. The diagnostic facial triangle in the control of treatment objectives. Am J Orthod 1991 ;55:651.
124. Peck H, Peck S. A concept of facial esthetics. Angle Orthod 1970;40:284.
125. Maritato FR, Douglas JR. A positive guide to anterior tooth placement. J Prosthet Dent 1964; 14:848.
126. Pound E. Applying harmony in selecting and arranging teeth. Dent Clin North Am 1962;6:241.
127 Crispin BJ, Watson JF. Margin placement of esthetic veneer crowns. Part 2. Posterior teeth visibility. J Prosthet Dent 1981;45:389-391.
128. Burstone CJ. Lip posture and its significance in treatment planning. Am J Orthod 1967;53:262-284.
129. Yamamoto M. Metal-Ceramics: Principles and Methods of Makoto Yamamoto. Chicago: Quintessence, 1985:410.
130. Burstone CJ. Lip posture and its significance in treatment planning. Am J Orthod 1967;53:262-284.
131. Yamamoto M. Metal-Ceramics: Principles and Methods of Makoto Yamamoto. Chicago: Quintessence, 1985:410.

WWW.HIGHDENT.IR
همیار دندانسازان و دندانپزشکان

3 Adhesion

Jean-Frangois Roulet, Uwe Blunck, Ralf Janda

Introduction

Adhesion has completely changed dentistry for two reasons:

- adhesion seals dentin completely, thus preventing microorganisms access to the pulp,[1]
- with adhesion, dentists do not need to rely on macroretention using undercuts or the large parallel surfaces of indirect restorations.

This shift from macroretention to microretention has promoted aesthetic and minimal invasive dentistry. Treatments we offer these days, such as bonded veneers, were unthinkable fifty years ago.[2,3]

WWW.HIGHDENT.IR
همیار دندانسازان و دندانپزشکان

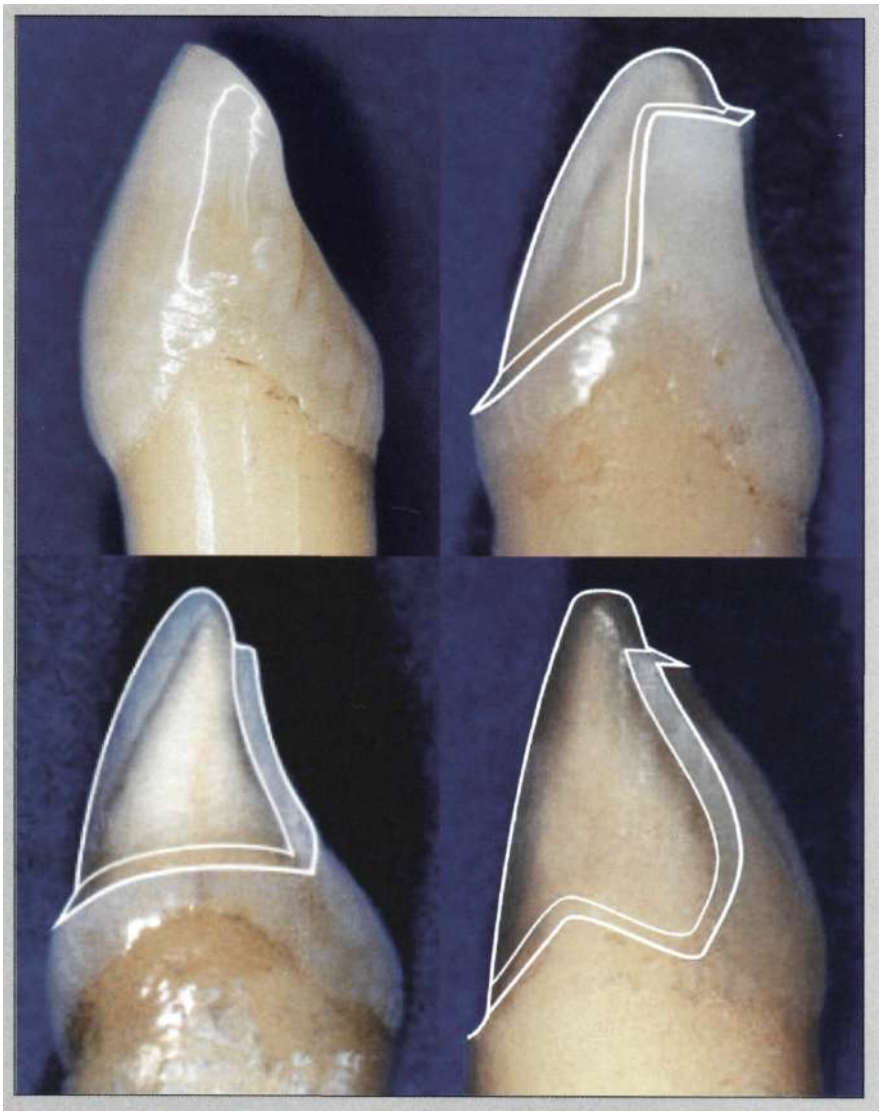

WWW.HIGHDENT.IR
همیار دندانسازان و دندانپزشکان

Substrates

Enamel

Enamel is the best mineralized tissue in the body. It consists of 95% w/w or 86% v/v of inorganic substances, mostly hydroxyapatite.[4,5] The water content is minimal and in contrast to bone, dentin and cementum, most of the water in enamel is bound to the crystals as a hydration layer. Only about one-quarter of the water is free within the organic component. The organic part consists of solvable and unsolvable proteins and a few carbohydrates and lipids (Figs 3-1 a and b).[6] The distribution of these organic components differs from area to area and is seen as the remains from the enamel matrix as it is produced by the ameloblasts. The inorganic component is mostly apatite, especially hydroxyapatite. Some calcium carbonate is also found. Fluorides are usually present in enamel, especially in the surface layers, a little less in attrition zones. The highest fluoride concentrations are found in the most superficial 50 jLim of enamel. There the concentration varies between 300 and 1,200 ppm as a function of the fluoride exposition of the individual. This is important to realize, since it is known that fluoroapatite is less soluble, and so superficial, unground enamel is more resistant to etching.

Enamel is produced by the ameloblasts, which are responsible for its structure. Corresponding to the ameloblasts and their Tomes' processes, where the enamel matrix is released from the ameloblasts, the enamel is structured in rods. These enamel rods start at the dentino-enamel junction and end approximately 30 jurn under the enamel surface, where so-called "prismless enamel" is found. There the crystallites are all densely packed and oriented perpendicularly to the surface.[7,8] The rods show a curved pattern from the center to the periphery, where they are usually arranged more or less perpendicularly to the surface. Their diameter is around 5 jam, but they have an irregular shape, which is often misinterpreted. In cross sections they may appear as a keyhole type or as a horseshoe type.[9,10] This structure is seen best if the enamel is etched with phosphoric acid (Fig 3-2).

These patterns occur because of the next substructure of enamel: the hydroxyapatite crystallites. They are produced right after the secretion of the enamel matrix. The first appearance seems to occur not as a continuum, but in discrete phases, which result in a striation of the enamel (Retzius lines). Later on the enamel undergoes a maturation, in which the crystals grow from initially 15 A (thickness) x 300 A (width) x 800-1200 A (length) to much larger ones (350 A x 800-1000 A x 1600 A). These are densely packed in mature enamel.[11,12]

Within the prisms, the orientation of the crystallites follows well-defined patterns, which are seen as a consequence of the mechanism of

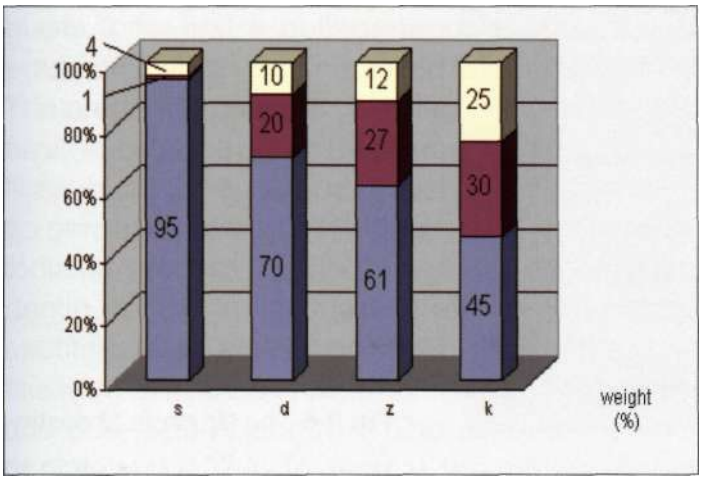

Fig 3-1a Composition of the mineralized tissues of the body by weight.

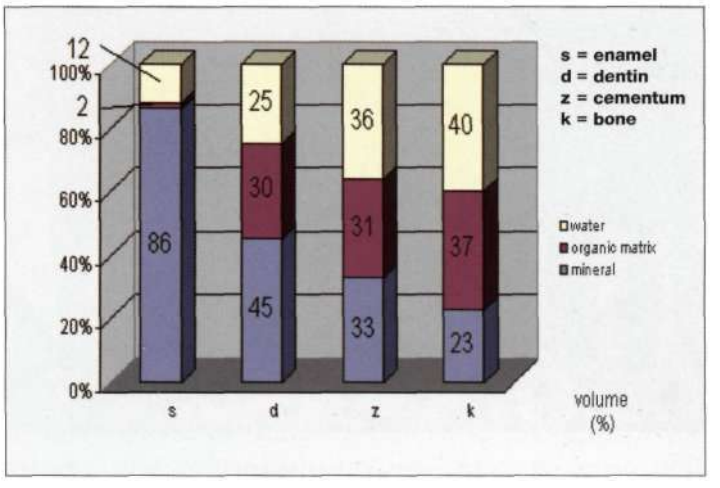

Fig 3-1 b Composition of the mineralized tissues of the body by volume *{Schroder,* Orale Strukturbiologie).

WWW.HIGHDENT.IR
همیار دندانسازان و دندانپزشکان



Fig 3-2 Enamel, cross section perpendicularly to the prism long axis. Etched with 37% phosphoric acid (SEM).

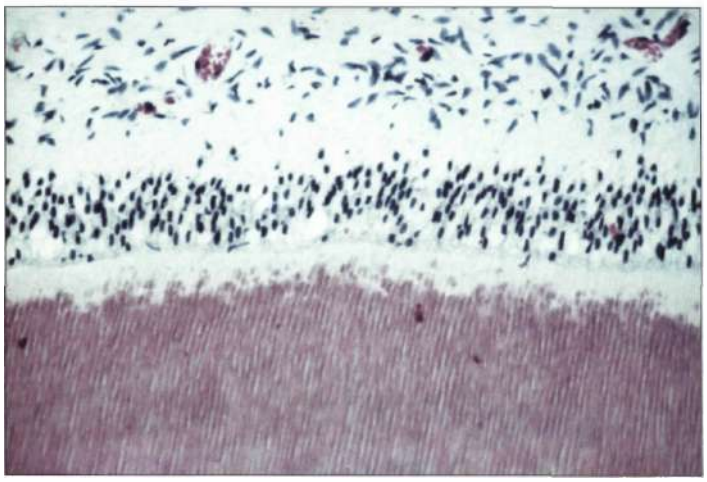

Fig 3-3 Odontoblastic layer with predentin and mineralized dentin (HE stain).

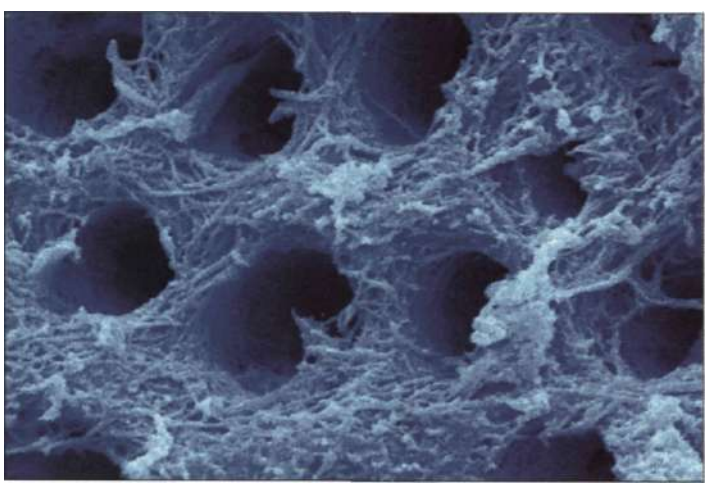

Fig 3-4 Collagen fiber network in dentin (SEM).

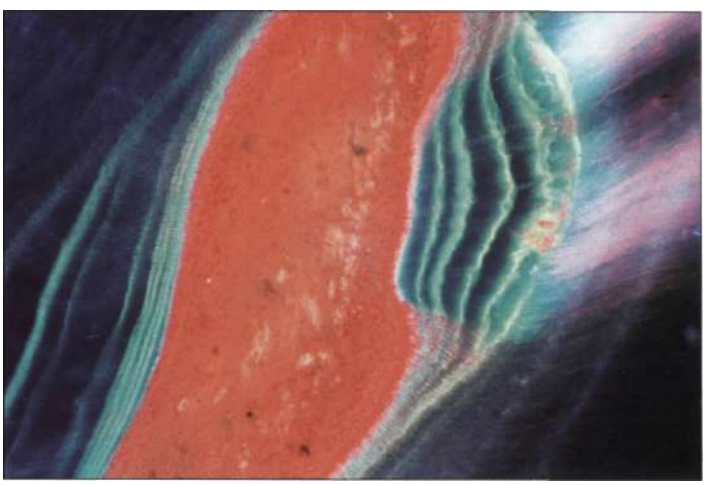

Fig 3-5 Enhanced dentin production (secondary dentin) as result of irritation. (Special stain, courtesy of *H. Stich.)*

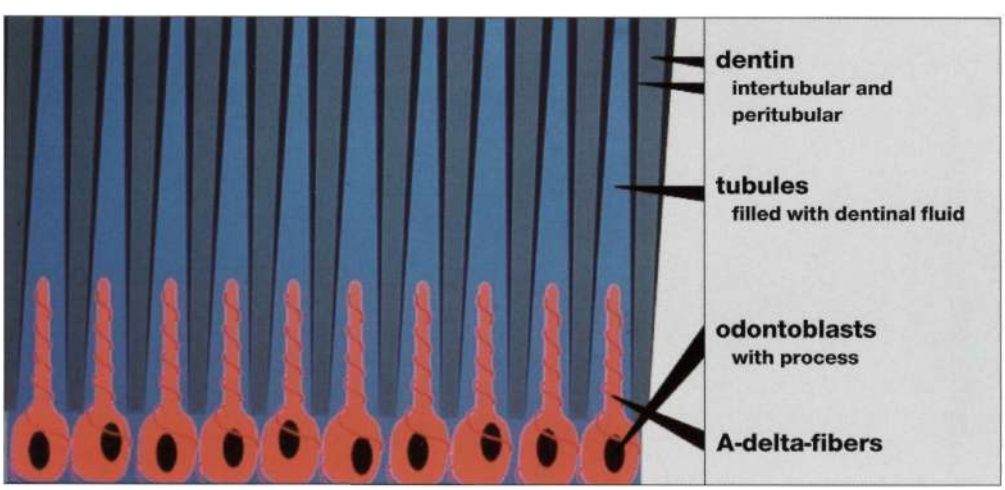

Fig 3-6 The structure of dentin.

WWW.HIGHDENT.IR
همیار دندانسازان و دندانپزشکان

the enamel production. The optical axis (c-axis = length axis) of the crystallites follows distinctive patterns, with most of the crystallites being oriented within the length axis of the prism. The difference in orientation within the prism makes the different pattern in cross sections (horseshoe v. keyhole). Since the solubility of crystals is different from their steric orientation (in the c-axis they are less soluble), etching of enamel produces an extremely rough and thus enlarged surface (Fig 3-2). The crystallites are embedded in a gelatinous, unstructured matrix, which consists only of 1 - 2 % of the total volume.[6] Since in the prismless enamel of the enamel surface all crystallites are oriented perpendicularly to the surface, this surface enamel is more resistant to etching than ground enamel, where deeper layers are exposed.

The number of prisms per surface area varies from the more centrally located enamel towards the surface.[13,14] At the tooth surface there are approximately 20,000-30,000 prisms per mm^2. At the dentin-enamel junction the density is approximately 10 % higher. These numbers correspond well with the number of odontoblasts.

Dentin

The general composition of dentin is quite different from enamel and much closer to the composition of bone (see Fig 3-1). Dentin is produced for the whole life from the odontoblasts lining the pulpal wall. This process starts during tooth formation at the dentin-enamel junction. Odontoblasts form first a collageneous matrix, called predentin, which is mineralized later on (Fig 3-3). The predentin consists of collagen b-fibrils and a basic substance rich in mucopolysaccarides. The fibrils build up a network which is mainly oriented perpendicularly to the length axis of the odontoblastic process (Fig 3-4). The calcification of the dentin occurs in the form of globuli, where the apatite crystals are laid down. The size of the crystals is small (20-25 A width, 200-300 A diameter, and 300-600 A length).[10] The shape is needle- or platelet-like.[15] As in enamel, the mineralization does not occur continuously, but in a rhythmic pattern, which leaves a striation of the dentin (v. Ebner lines). On their move away from the dentin-enamel junction, the odontoblasts leave a cellular processus behind, which remains attached to the cell. In a second phase, this odontoblastic process is used as a transport medium to build up the calcification of the wall of the odontoblastic canal leading to the highly mineralized peritubular dentin.[16] Owing to this configuration, dentin is a vital tissue, able to react against insults such as caries or other trauma (Fig 3-5). Therefore it is difficult to characterize dentin as a substrate—it is extremely inhomogeneous and variable with regard to circumstances, such as position in relation to the pulp, age and external trauma.

Overall, the structure of dentin can be described as follows (Fig 3-6). The odontoblastic process is embedded in liquid, which is in a tube (dentinal tubulus) of highly mineralized dentin called peritubular dentin. These tubes are bonded together by less-mineralized dentin called intertubular dentin. Since the arrangement of the tubuli is centripetal, the quantity per surface area varies. Most (c. 45,000 per mm^2) are found close to the pulp, while in the periphery, at the dentin-enamel junction, the number is significantly decreased, to 20,000 per mm^2.[17,18] Owing to the liquid contained in the tubuli, and the collagen content, dentin is a wet substrate; the closer we come to the pulp the more fluid from the tubules we have to expect.

The odontoblastic process also contains nerve fibers close to the body of the odontoblastic cell which are responsible for the transmission of the sensation of pain.[19-21] Every fluid movement within the odontoblastic process is transduced into pain.[22] This is the mechanism of painful tooth necks. Any process causing fluid movement within the tubulus, e.g. desiccation, temperature change or osmotic processes, will cause pain. After trauma or constant irritation, dentin may become sclerotic due to Ca-phosphate deposition within the odontoblastic process.[23-28] However, constant acid attacks may dissolve these protective "plugs".

Owing to its structure perse, and to pulpal physiology, the pulpal-dentin complex is very well equipped to fight any chemical and bacteriological insult.

WWW.HIGHDENT.IR
همیار دندانسازان و دندانپزشکان



Fig 3-7 Smear layer of prepared dentin (SEM).

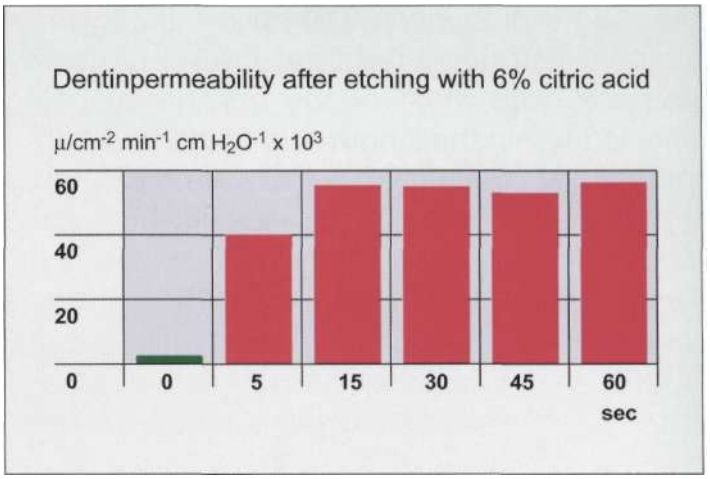

Fig 3-8 The permeability of dentin and acid etched dentin.[36]

- Within the pulp there is a slightly higher pressure (approximately 30 cm H2O) than in the environment. As a consequence, at open tubules there is an outward flow of the pulpal fluid within the tubuli, which means that every toxic agent must diffuse against this fluid stream.
- As mentioned above, tubules may calcify as a defending mechanism.
- Dentin is an excellent buffer; therefore it can absorb considerable quantities of acid.
- If any toxic agent may reach the pulp it will first encounter the very well vascularized subodontoblastic layer, where dilution can act as a countermeasure against toxic harm.
- Furthermore, the defense mechanisms are carried through blood vessels, being present in abundance in the subodontoblastic layer.

There is another issue which must be considered if dentin is to be used as a substrate for bonding: the smear layer, which is created after every instrumentation (Fig 3-7). This porous layer of about 1-7 jim is composed of hydroxyapatite and altered collagen.[29-32] The morphology and the thickness of the smear layer depend on the type of the instrument, the way it is used and on the site of the dentin.[32-33] It closes the dentinal tubules and prevents the seepage of dentinal fluid.[34] However, its most important feature is that it prevents contact between the substrate dentin and any potential adhesive. The smear layer can be easily removed by acid etching; however, this procedure also removes the smear plugs in the tubules, thus increasing the dentin permeability (Fig 3-8).[35]>[36]

Ceramics

First it should be mentioned that ceramics are defined as having a crystalline structure, unlike glass, which is not crystalline at all. For dental applications, pure glassy materials (i.e. fused-to-titanium "ceramics"); glassy materials with a certain amount of incorporated crystals, for instance, leucite or lithium disilicate (i.e. fused-to-metal "ceramics", e.g. Empress I, Empress II); and pure crystalline ceramics- real ceramics (i.e. aluminum oxide, zirconium oxide and glass-phase containing modifications thereof) (e.g. InCeram-Alumina, InCeram-Zircon) are used. However, all these types of glasses, glass ceramics and "real" ceramics are, in dentistry, covered by the general term "ceramic". Today different types of ceramics are available in orderto manufacture ceramic restorations (Fig 3-9).

All ceramics can be subdivided as follows:
- silicon oxide (Si02)-based ceramics
- aluminum oxide (A^C^-based ceramics
- aluminum oxide-based ceramics reinforced with zirconium oxide (Zr02)
- pure aluminum oxide ceramics
- pure zirconium oxide ceramics.

WWW.HIGHDENT.IR
همیار دندانسازان و دندانپزشکان

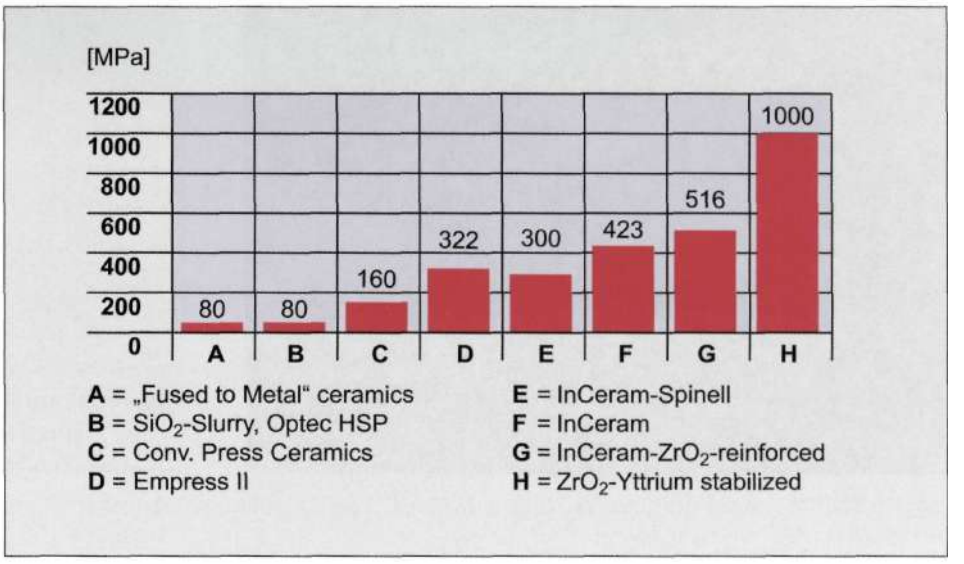

Fig 3-9 Strength of different ceramic types.

These ceramics not only differ in strength owing to their structure, but also in opacity. As a rule, silicon oxide-based ceramics are the most transparent, since they consist of a larger glass phase and only a small crystalline phase. Therefore they are able to create the best esthetics and are also able to pick up the color of their surroundings ("the chameleon effect"). To sum up, with an larger crystalline phase the strength of a ceramic material increases, but unfortunately so does its opacity. Forthis reason, Empress II, which provides the highest strength of all of today's silicon oxide-based ceramics, contains approximately 60% lithium disilicate crystals. However, its transparency is less compared with the conventional silicon oxide-based ceramics.

The strongest ceramics known for dental applications are aluminum oxide and zirconium oxide ceramics. They are 100% crystalline but also very opaque. Spinell, which is an aluminum oxide-based material, provides for its special crystalline structure (Spinell-structure) a significantly better transparency compared with pure aluminum oxide, but not as good as the silicon oxide-based ones. However, opacity might be a desired characteristic if severely discolored teeth must be masked with veneers. Forthis reason only silicon oxide-based ceramics will be considered in the following paragraphs.

A further differentiation is possible by considering the manufacturing method which depends on the respective ceramic (Table 3-1). Apart from those already mentioned, there are other techniques, such as sonoerosion, burnout and subsequent sintering, etc., which could be used to manufacture veneers.

Silicon oxide-based ceramics are characterized by a glass phase, which contains crystals (e.g. tetra silica mica, leucite, lithium disilicate). By etching away the glass phase it is possible to visualize the structure (Fig 3-10). They can be processed according to the slurry technique as well as to the press technique. However, the slurry technique is no longer used very often for this ceramic type. Optec HSP (Jeneric/Pentron Inc., USA) is, for instance, a ceramic processed on a refractory material.[37] The majority of silicon oxide ceramics is processed according to press techniques, which have several advantages, especially with regard to strength, homogeneity and fit.

Well-known ceramics of this type are:
Empress I (Ivoclar/Vivadent AG, Liechtenstein)
Empress II (Ivoclar/Vivadent AG, Liechtenstein)
Finesse All Ceramic (Dentsply/Ceramco, USA)
Carrara Press (Elephant, The Netherlands)
Cergo (Degussa-Dental, Germany)
Optec OPC (Jeneric/Pentron Inc., USA).

Silicon oxide ceramics are also machined, as is the case with the Cerec System (Sirona AG, Germany, Cerec-Blocks: Vita, Germany). However, other machining systems (e.g. Celay (Mikrona AG, Switzerland), DCS Precident System (DCS

WWW.HIGHDENT.IR
همیار دندانسازان و دندانپزشکان



Fig 3-10 Structure of a silicon dioxide based ceramic (Dicor). The glass phase is etched away, exposing the tetra mica silica crystals (SEM).

Table 3-1 Types of ceramics and processing techniques

Type of ceramic	Processing techniques			
	Slurry	Press	Machined	Casting
SiO_2	x	x	x	x
Al_2O_3			x	
Al_2O_3 glass modified			x	
Al_2O_3 glass infiltrated	x		x	
Al_2O_3 ZrO_2-reinforced	x		x	
$MgAl_2O_4$ Spinell	x			
ZrO_2 YTZP			x	

Dental AG, Switzerland) or DigiDent (Girrbach, Germany)) can be used. Table 3-1 lists casting as a processing technique, too. Between 1985 and 1995 this technique was very popular and successful. It is known under the trademark Dicor (Dentsply International Inc., USA). Dicor was the first really acceptable all-ceramic system which provided good esthetics as well.[38,39] However, production was stopped in the last years of the twentieth century because the product has been substituted by ceramics providing higher strengths and improved processing and esthetic properties. Today the strongest dental silicon oxide ceramic known is Empress II, with a flexural strength of more than 300 MPa.[40] High-strength, non silicon oxide-based ceramics are quite opaque and, therefore, not suitable for the manufacture of ceramic veneers. We will not discuss these materials as possible substrate for bonding within this chapter.

Adhesive Technique

Basic principles of adhesion

To achieve a good bond between two different materials, several prerequisites need to be fulfilled. To accomplish adhesion, the two substrates must come into very close contact. Only if the molecules are approached in a nanometer range intermolecular forces may be built up. For solid substrates this is almost impossible, because of

WWW.HIGHDENT.IR
همیار دندانسازان و دندانپزشکان

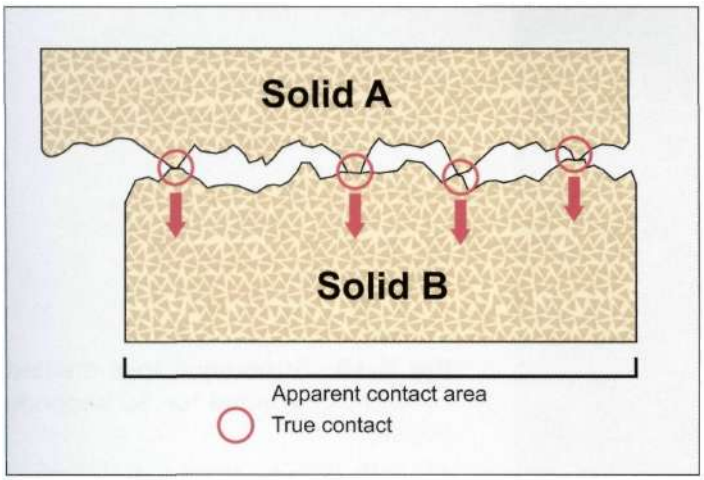

Fig 3-11 Intimate contact of two solids. Difference between true contact area and apparent contact area.

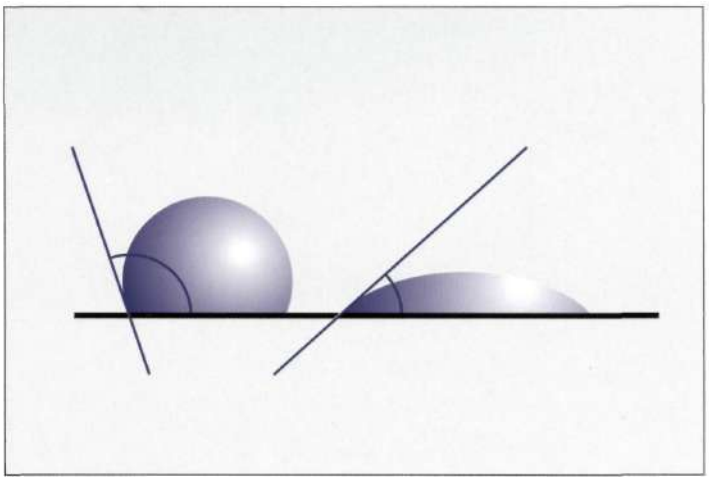

Fig 3-12 Contact angles of wetting (low contact angle, right) and non-wetting (high contact angle, left) liquids on a surface.

the surface morphology. Therefore, there is a large difference between the apparent contact area and the area of true contacts (Fig 3-11). This is the reason only small forces may be obtained with this mechanism - for example, two glass plates in close contact. This problem is solved by filling in the gaps left with an adhesive. The adhesive must be capable of getting into intimate contact with both surfaces - i.e. wetting them perfectly - which is only possible if the surface characteristics are compatible with the adhesive. For the mostly hydrophobic resins, which are used as enamel adhesives or restorative materials in dentistry, high surface energies and perfectly dry surfaces are required. This is shown with the contact angle. If the surface matches the wetting liquid, then the liquid tries to cover a surface as large as possible (low contact angle, Fig 3-12). If there is a mismatch, then the surface will try not to accept the liquid (high contact angle, see Fig 3-12).

Furthermore, the design of the adhesive configuration must be optimized to reduce interfacial stress. The larger the surface, the better. This rule is very favorable forthe bonding of veneers, where very large surfaces are available for bonding.

Bonding to enamel

Almost fifty years ago, *M. G. Buonocore* published an article in which he showed that it is possible to bond acrylic resins to enamel, if the enamel is etched with phosphoric acid and rinsed and dried priorto the application of the resin.[41] This opened the road for the first steps in adhesive dentistry: the reliable bond to enamel. Untreated enamel has a very low surface energy and is therefore not suitable for bonding. Furthermore it is covered by a biofilm consisting of glycopolysaccharidesfrom saliva. By removing this biofilm and etching the enamel with 37% phosphoric acid, two changes occur which are very favorable for bonding:[42] the surface energy of the enamel is increased considerably and, owing to selective dissolution, a microretentive surface is created that can be optimally penetrated by the hydrophobic diacrylate resins, which are the matrix of composite resins and which are used as enamel-bonding agents.

Therefore, enamel bonding is mainly a micromechanical interlocking of resin with the enamel surface. Resin may penetrate into undercuts or may shrink during polymerization on top of rod-like structures created by the etching process. This can only occur if all traces of humidity are eliminated, which is seen when the etched enamel becomes chalky in its appearance. All traces of water and other contamination (saliva, blood

WWW.HIGHDENT.IR
همیار دندانسازان و دندانپزشکان



Fig 3-13 Substance loss created by etching enamel for 30 seconds (SEM).
left side, bottom: enamal is etched;
top: unetched enamel, the height of the ledge (arrow) is indicating the substance loss;
right side: higher magnification of etched enamel.

sulcus fluid) would compete with the hydrophobic resins and of course win the race. With appropriate technique, approximately 30 MPa of bond strength may be obtained, if the enamel prisms are cut more or less perpendicularly before etching and bonding.

The 37 % phosphoric acid seems to be the best compromise between substance loss and histological changes of the surface morphology. Etching for 30 seconds creates approximately 10 |um of substance loss (Fig 3-13).

The classical enamel bonding technique consists of precisely etching the enamel with a phosphoric acid gel[43] for 30 seconds, then rinsing vigorously with a water-air spray to remove all precipitates and finally, carefully and completely drying the enamel surface with a blast of air before applying the hydrophobic enamel bonding agent.

Bonding to dentin

Bonding to dentin has proven to be more complex and difficult. Reliable materials and techniques were offered to dentists only after it was realized that a permanent bond to dentin is possible if a micromechanical bond is achieved[44] (Fig 3-14). Two important approaches were changed in the treatment philosophy.

1. Dentin must be etched, which does not harm the pulp.
2. Hydrophilic resins must be used which are able to penetrate into the etched dentin surface despite its moist condition.[45]

To accomplish an appropriate micromechanical bond to dentin, which yields approximately 30 MPa, the following fundamental steps are required.

1. Etch the dentin surface in order to decalcify the surface for a few microns depth. Bythis means the collagen fibers are denuded and ready to be used as retention forthe components of the adhesive system. In this phase it is important not to desiccate the dentin because then the collagen fibers would collapse and stick together, hindering the proper penetration of any components of the adhesive system.[46] On the other hand, if the dentin is kept too wet, then the so-called "over wet phenomenon" occurs, which meansthatthe components of the adhesive system are diluted too much, again hindering sufficient penetration of monomers.[47] The preferable acid is phosphoric acid, which should be applied for not more than 15 seconds. If the dentin is over etched, then the etching is too deep and, again, the monomers may not penetrate fully the demineralized zone, yielding poor bond and probably facilitate nanoleakage (microleakage within the hybrid

WWW.HIGHDENT.IR
همیار دندانسازان و دندانپزشکان

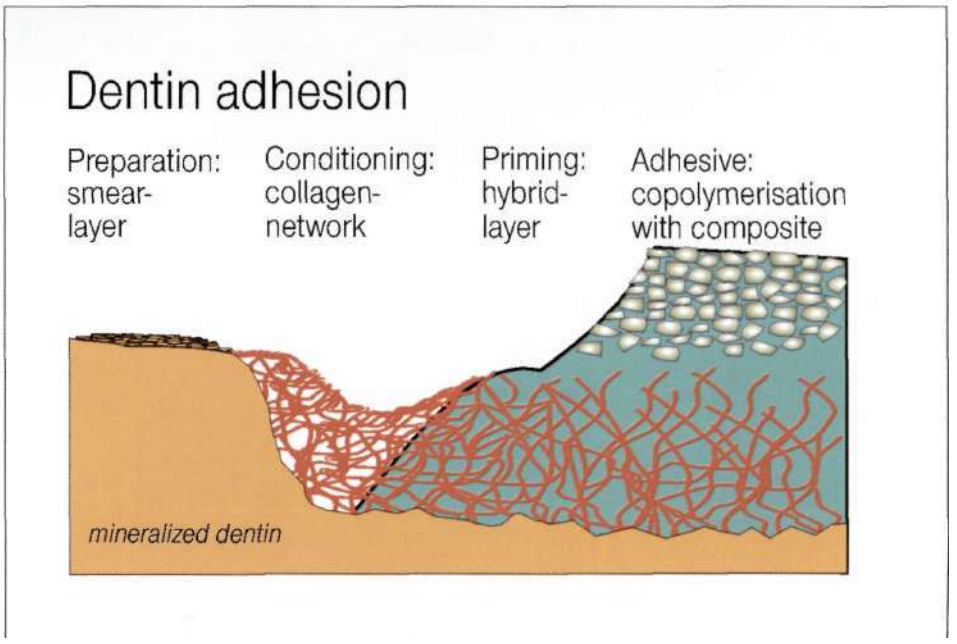

Fig 3-14 Principle of bonding to dentin.

layer). Sclerotic dentin should be etched for 30 seconds.

2. The etched dentin surface must be primed, i.e. penetrated with hydrophilic or amphiphilic monomers. These monomers are only able to penetrate into the wet collagen network. This penetration is possible either by the extreme hydrophilic character of the monomer (e.g. HEMA) and/or is supported by hydrophilic solvents such as acetone or alcohol. Penetration requires time, so it is very important to follow precisely the time indicated in the instructions issued by the manufacturer.[48] Usually, priming is finished by gently drying the surface with air, in order to evaporate the solvent excess.

3. The primed dentin surface is now ready to accept the adhesive, which is usually more hydrophobic and must be compatible with the composite resin of the reconstruction or the luting composite. At this stage the resin-infiltrated dentin is very fragile. It is therefore mandatory to polymerize this layer prior to applying the restoration.[46] If this is not done, the polymerization shrinkage of the overlaying composite will destroy the hybrid layer right away.

In order to facilitate the use of adhesive systems, manufacturers have tried to combine some steps. This has lead to different classes of adhesives, which are very different in their application (Fig 3-15). There are two separate approaches regarding the conditioning process of enamel and dentin—the "total-etch technique" and the use of "self-etching bonding" systems. Within the first group we find products like Optibond FL (Kerr) and Scotchbond MP (3M Espe), which include the separate application of primer and adhesive after etching enamel and dentin simultaneously. This group of products is also called "multi-step adhesive systems". In order to simplify the application, a group of one-bottle adhesives in combination with the total-etch technique can be identified, also described as "etch and prime-bond". With these products (e.g. One Coat (Coltene), Optibond Solo Plus (Kerr), Prime & Bond NT (Dentsply), Scotchbond Single Bond (3M Espe) and Excite (Vivadent)), the manufacturers use a primer-adhesive, i.e. a mixture of hydrophilic and hydrophobic monomers. The problem with this mixture is to combine the function of a primer (to facilitate the penetration of the bonding system into the etched dentin) with the function of the adhesive (to level the cavity surface for a perfect adaptation of the composite resin).

There is also the growing group of products acting as so-called "self-etching bondings". The idea is that by being acidic enough to condition enamel and dentin, these primers can penetrate into the demineralized surface during the condi-

WWW.HIGHDENT.IR
همیار دندانسازان و دندانپزشکان

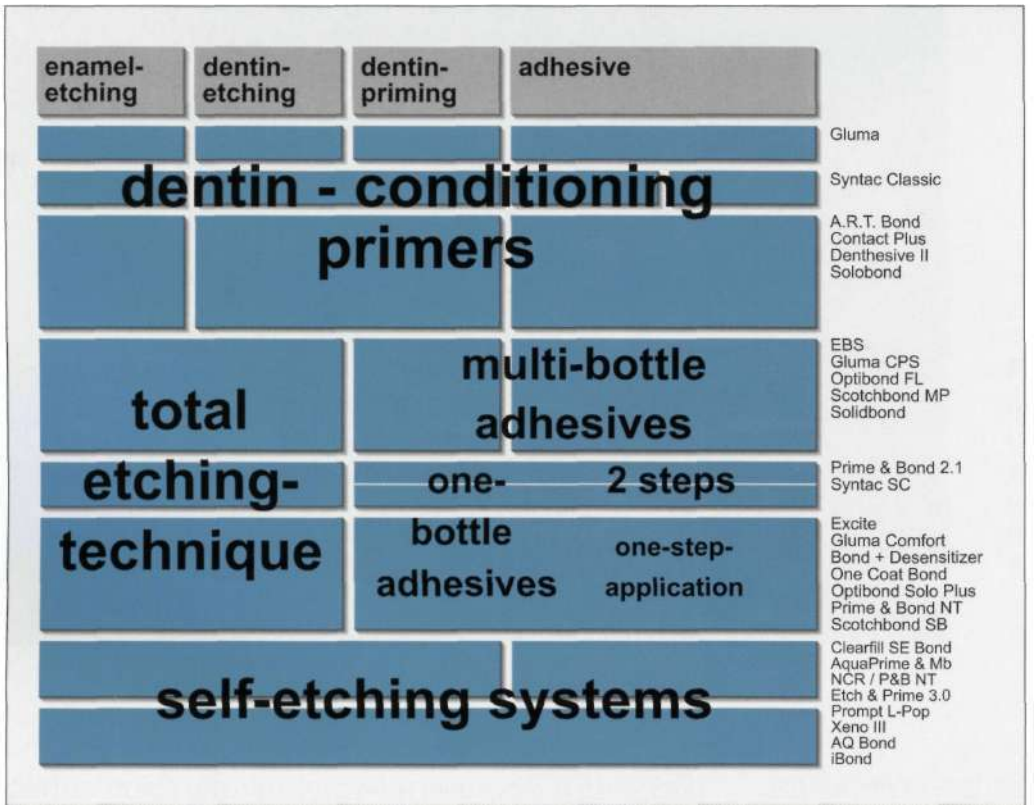

Fig 3-15 Simplification of adhesive systems.

tioning process. Therefore, because one has never to rinse away the acid, all the problems of desiccated or over wet dentin should be solved. However, there is some concern regarding the reliability of bonding to enamel with these products. Although the acidity of these systems is not sufficient to create pronounced etching patterns (Fig 3-16), the bond strength to cut enamel is not statistically different from enamel surfaces etched with phosphoric acid. However, bonding to uncut enamel is statistically lower by using self-etching adhesives than after acid-etching.[48,49]

One group of products within the self-etching bondings can be described as "etch-prime and bond" (e.g. AquaPrime & MonoBond (Merz), Clearfil Liner Bond 2V (Kuraray) and Clearfil SE Bond (Kuraray)) with separate application of the self-etching primer and the adhesive.

Another group, etch-prime-bond, can be called self-etching adhesives and should be the ultimate simplification regarding the application of adhesive. This group again can be divided into two subgroups. Because of the required high acidity there is a problem regarding shelf life of the adhesive resins. Therefore, in one subgroup the components must be stored separately, forcing the dentist to mix the solution directly prior to application (e.g. Etch & Prime 3.0 (Degussa), Futurabond (Voco), Prompt L-Pop (3M Espe), One Up Bond F (Tokuyama) and Xeno III (Dentsply). Some manufacturers have proposed a number of intelligent mixing devices (Fig 3-17) (e.g. Prompt L-Pop) to facilitate this mixing procedure. Despite their simplicity, they have not yet completely fulfilled expectations. The other subgroup of self-etching adhesives solved the shelf life problem by further developments of monomersystems which do not need to be mixed and can be applied directly from the bottle (e.g. AQ Bond, Sun Medical) and iBond (Heraeus Kulzer).

As we have mentioned, it is important that such resin-impregnated dentin layers are stabilized by polymerization before a composite resin is placed on top, so as to prevent debonding at the interface due to the polymerization shrinkage of the composite. For precise veneers, inlays and crowns this poses a problem, since pooling of the bonding agent may prevent a precise relocation of the ceramic piece into the cavity. There are two ways out of this situation.

WWW.HIGHDENT.IR
همیار دندانسازان و دندانپزشکان

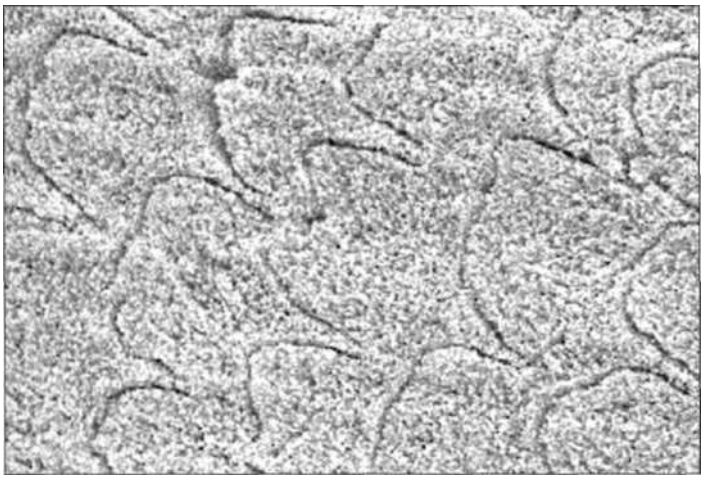

Fig 3-16 Etching pattern in enamel created by a self-etching primer (SEM).

Fig 3-17 Mixing device for self-etching adhesive (Prompt-L-Pop).

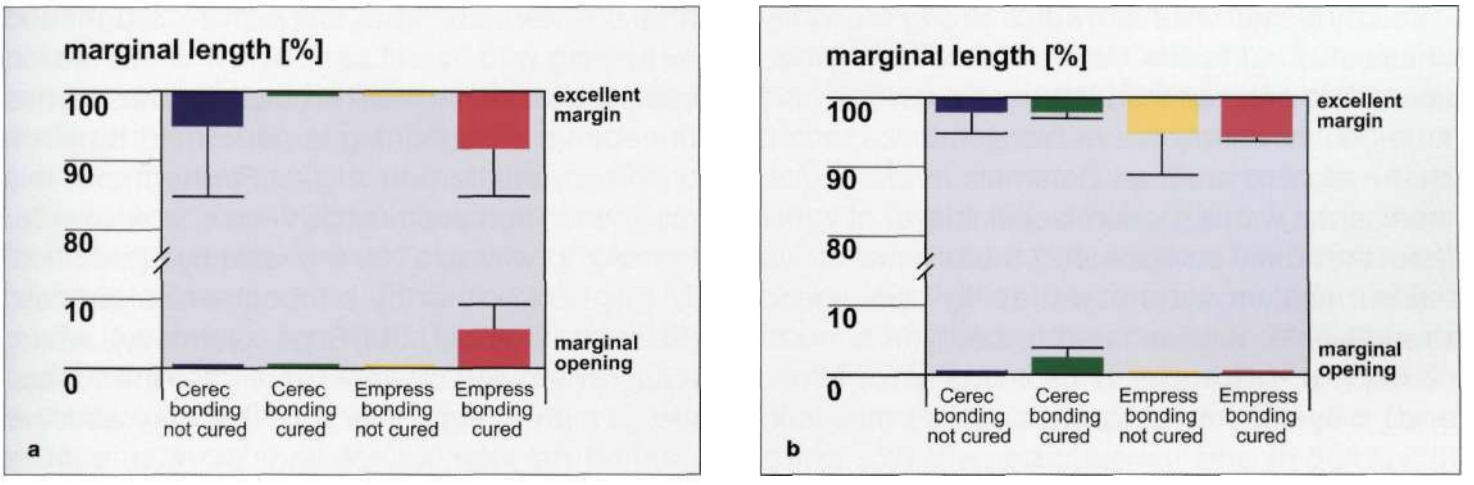

Fig 3-18a, b Margin quality of ceramic inlays bonded to teeth with Etch & Prime, (a) Box plots show the enamel composite interface, (b) Box plots show the dentin composite interface *{Clotten, Blunck, Roulet,* Influence of a simplified application technique).

1. The dentin is sealed right after the cavity preparation and then the enamel finishing line is cleaned again to make sure that it is resin free prior to the impression. At the next appointment the cavity is cleaned carefully with pumice before the veneer/inlay/crown is luted with an adhesive technique.[50]

2. The dentin must be sealed with an adhesive of very low viscosity which does not interfere with the restoration, even if it is polymerized prior to the insertion of the veneer/inlay/crown. *Clotten, Blunck* and *Roulet*[51] have demonstrated that with such a technique it is possible to obtain an excellent margin quality in vitro with ceramic inlays (Fig 3-18aand b).

Bonding to ceramics

A reliable bond of composites to ceramics is also achieved by micromechanical retention. Feldspathic (silicon oxide) ceramics and lithium silicate ceramics contain a glass phase[38,39,52] that can be etched with hydrofluoric acid[53-55] *or* similar compounds,[39] exposing the crystallites contained in the ceramic to create microretentions. Based on chemical knowledge, hydrofluoric acid etching is only possible with Si02-based ceramics or glasses according to the reaction equation:

$$6\ H_2F_2 + 2\ SiO_2 \qquad 2\ H_2SiF_6 + 4\ H_2O$$

WWW.HIGHDENT.IR
همیار دندانسازان و دندانپزشکان

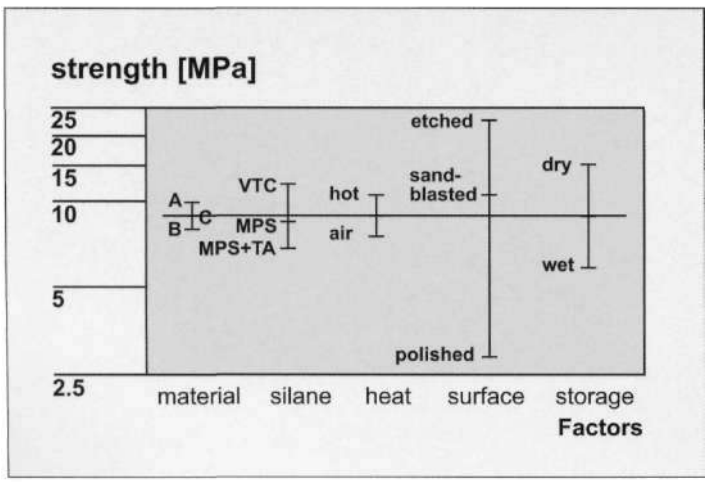

Fig 3-19 Factors influencing the ceramic-composite bond *{Roulet, Soderholm, Longmate,* Effects of treatment and storage conditions).

The etched surface can be wetted and penetrated by resins which provide a strong micromechanical bond to the ceramic. Sufficient bond strength is only reached if the resin used is able to penetrate deeply the microretentions created by the etching process. Ceramics tend to cover themselves with a monomolecular layer of water (from the humid environment), thus silanization of the surface increases "wettability" and bond strength.55,56 Silanes need to be hydrolyzed to be reactive.[56] However, once activated (by acetic acid), they become unstable, because they tend to build up dimers, trimers, tetramers, etc., which are not reactive any more.[57] The more active a silane, the shorter is the shelf life. The best way to handle this problem is to use a two-component silane, which is activated by mixing with acetic acid priorto application. Preactivated silanes have a limited shelf life, especially after the bottles are opened and give access to water. Since this surface treatment is crucial for the clinical behavior, it is highly recommended to dentists to perform the conditioning of the ceramic's inner surface immediately prior to the insertion of the restoration. Only with this approach can one exclude any surface contamination, which would jeopardize the bonding of the ceramic restoration to the tooth. *Roulet, Soderholm* and *Longmate*[58] have clearly demonstrated that the most important factor for bond strength is the roughening of the ceramic surface (Fig 3-19).

The aforementioned chemical reaction cannot occur with high-strength alumina or zirconia ceramics since they do not contain a silicon oxide phase. Therefore, they cannot be roughened by etching with hydrofluoric acid. For this reason special treatments are indicated for these types of ceramic. Roughening is performed by sandblasting, usually with Al2O3. Furthermore, this roughened surface must be silica coated in order to make it "wettable" for the resin by silanization. This is done either by a tribochemical process (Rocatec, Coe Jet, 3M/Espe, Germany), where silica-coated particles are blown onto the surface with a high energy.[59-62] /\ f_{ur}ther very effective method is flaming of the surface with a silane-enriched butane flame. There are two techniques: Silicoater[59,63-64] and PyroPen.[65] However, special glues (e.g. Panavia Ex) have also been successfully tested to bond zirconia ceramic.[62,66]

Product Recommendation for Bonding Veneers

Veneers are characterized by two specific features: they are usually very thin and transparent and they are bonded mostly (but not exclusively) to enamel. These two characteristics determine which bonding/luting systems should be selected. Since enamel is the prime target for bonding, reliable enamel bonding should be used. However, dentin may be involved too. Therefore, any

WWW.HIGHDENT.IR
همیار دندانسازان و دندانپزشکان

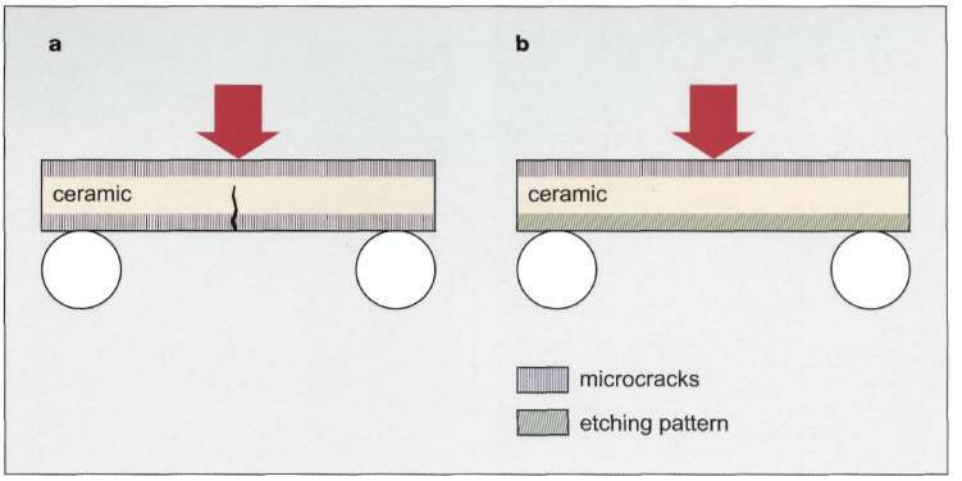

Fig 3-20a, b Crack propagation in a ceramic beam, (a) If the beam is under load, the lower side is under tensile stress, where cracks are initiated, (b) By etching the lower side of the beam the initial cracks are eliminated. Furthermore, the infiltrated composite, which is less brittle, decreases crack initiation.

total bonding system (i.e. any system where enamel and dentin are separately etched with phosphoric acid), such as etch, bond, prime systems or etch and prime-bond systems, are to be preferred. The ceramic must be etched and silanated immediately priorto insertion in orderto optimize the "wettability" of the ceramic surface for diacrylate resins. The use of a two-component silane is recommended. From the luting composite, low-viscous light-cured systems should be preferred, because veneers are usually very thin and translucent. Only if very opaque veneers are to be cemented should one consider a dual-cured luting resin, especially since it is well known that these materials tend to show a yellow-brownish discoloration over time, owing to their higher amine content.

As clinicians, we would prefer the single systems where the manufacturer provides the dentist with a water-soluble try-in paste (e.g. Nexus2, Sybron-Kerr;Calibra, Dentsply) which allows us to check the final result priorto bonding the veneers in place permanently.

The Need for Bonding Ceramics

An inlay or a crown is frequently stressed similarly to a beam in athree-point bending test. If loaded from the occlusal surface, the inner surface of the ceramic restoration is subjected to tensile stress. Such situations are also possible with veneers.[67] Ceramic is a brittle material, and always contains micro cracks at the surface because of the finishing procedures. These micro cracks can propagate under load, even a moderate load, after fatigue of the biomaterial, with subsequent catastrophic failure (Fig 3-20a). There are two ways out of this problem: (1) improve the mechanical characteristics of the ceramic material, which leads to high strength ceramics (not suitable for veneers owing to their high opacity), or (2) eliminate/prevent the crack propagation at the inner surface of the restorations. This is done with adhesive techniques.

The question is: why are bonded ceramics more resistant to fractures? One can hypothesize that etching diminishes micro cracks, and after penetration of the surface with a resin-based material (composite) that is less brittle than ceramic, more stress at the inner surface is required to induce fractures (Fig 3-20b). This hypothesis is supported by several publications based on laboratory data. Fracture strength of ceramic beams is improved if the lower surfaces are carefully polished to a high gloss,[68] or strengthened (e.g. by ion addition[69,70] or by adhesively coating with composite resin).[71] There has also been clinical evidence for this behavior. Analysis of the survival rate of 1,444 Dicor complete crowns was performed using *Kaplan Meier* statistics by *Malament* and *Socransky,*[72,73] and they reported significantly better results for acid-etched and bonded restorations after fourteen years (Fig 3-21).

WWW.HIGHDENT.IR
همیار دندانسازان و دندانپزشکان

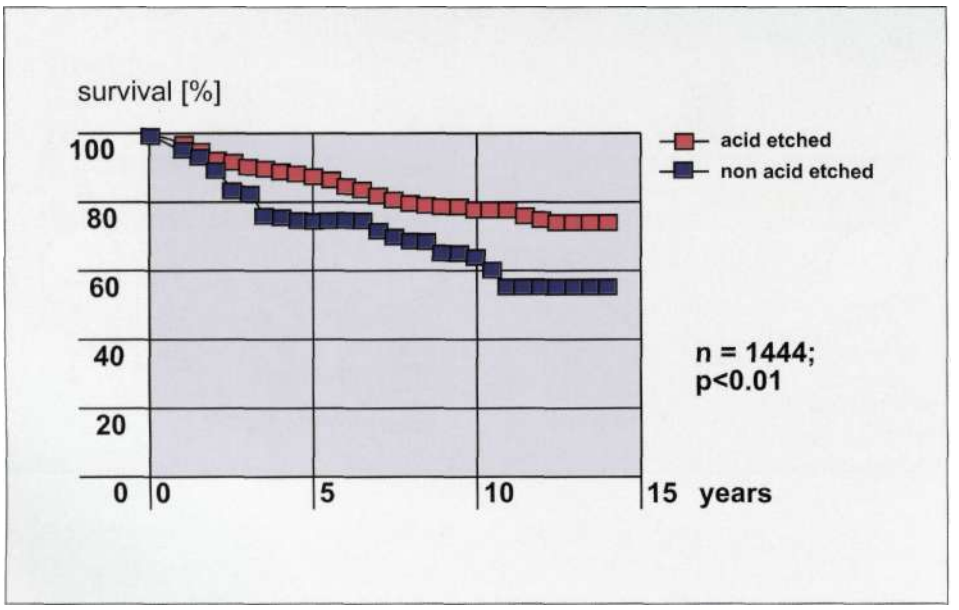

Fig 3-21 Longevity of Dicor crowns (Kaplan-Meier statistics). Note that the bonded crowns show a superior longevity *(Malament, Socransky,* Survival of Dicor glass-ceramic).

The Benefit of Bonding for Veneers

Owing to the combination of excellent materials' characteristics and reliable bonding techniques, veneers are the optimal way to restore anterior teeth following the principle of minimal invasiveness. Finite element studies have clearly demonstrated that it is possible fully to restore the original strength of teeth with veneers.[67,74] We have confirmed this in a study.[75-76] Veneers were bonded with Variolink II (Vivadent) into more and more extensive veneer/crown preparations (Fig 3-22a-g). Afterwards they were loaded up to fracture. As can be seen in Fig 3-23, there were no statistical differences between natural teeth, which fractured at around 1,100 N, and all veneers and crown with finishing lines in enamel. The fracture analysis revealed that no tooth fractured at the bonded interface. We found either cohesive fractures in the tooth (Fig 3-24a, b) or within the ceramic (Fig 3-24 c).

When veneers were placed on top of existing class III or class IV composite restorations,[7778] the fracture load was in a range between 800 N and 1,000 N (median, Fig 3-25), which was only slightly less than the values obtained for the teeth restored with different veneers with finishing lines in enamel, and definitely better than the values for the teeth restored with veneers/crowns with finishing lines in dentin (see Fig 3-23). The use of composite repair materials had no influence on the fracture resistance of the veneers. However, the margin quality at the composite-composite interface was superior if composite repair materials were used.

WWW.HIGHDENT.IR
همیار دندانسازان و دندانپزشکان

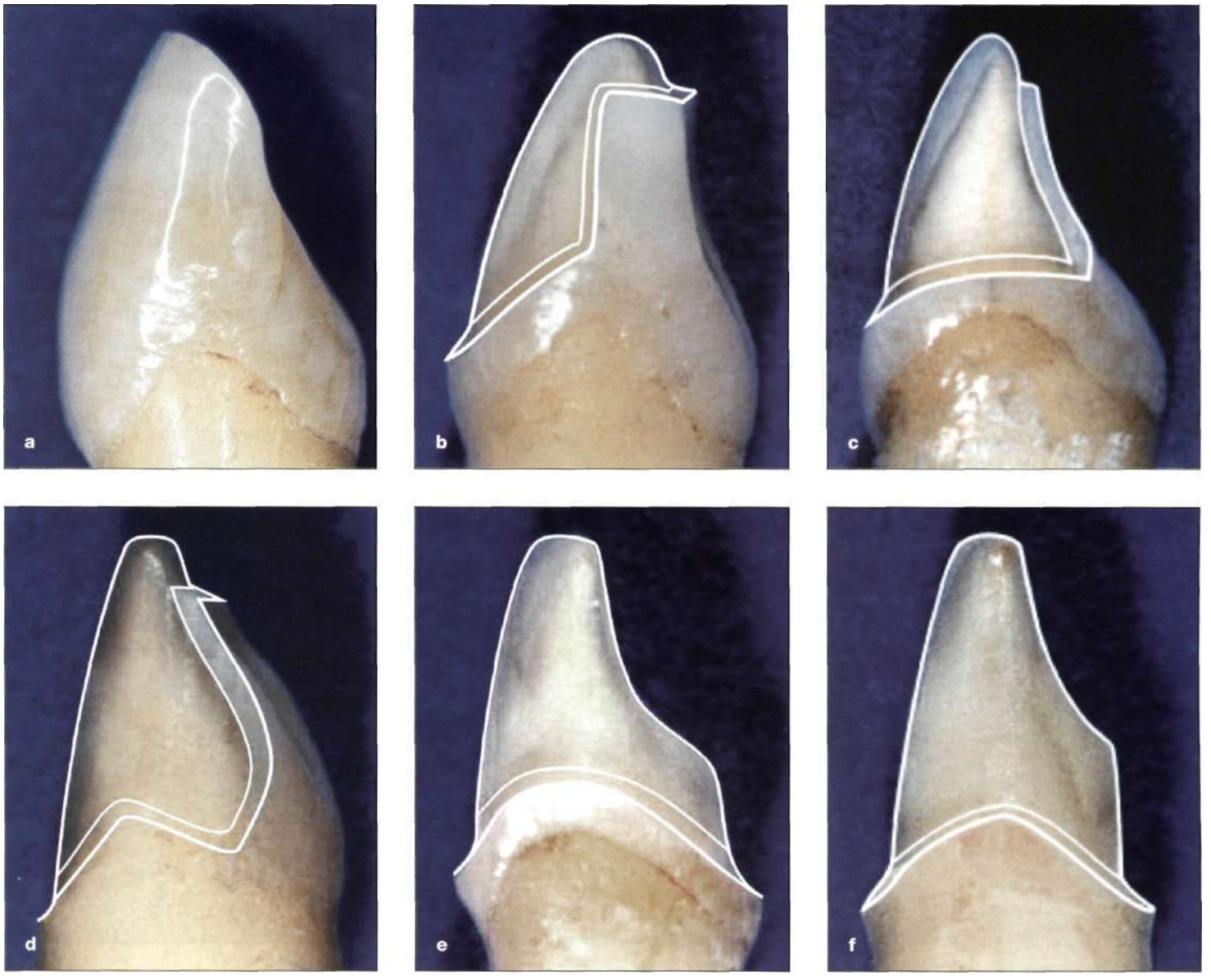

Fig 3-22a-g More and more extensive veneer/crown preparations on human central incisors seen proximally.

(a) Intact tooth.

(b) Preparation for veneer labial.

(c) Preparation for veneer proximal; finishing line cervical in enamel.

(d) Preparation for veneer proximal; finishing line cervical in dentin.

(e) Preparation for full crown, finishing line in enamel.

(f) Preparation for full crown, finishing line in dentin.

(g) Preparation for veneer on abraded tooth.

WWW.HIGHDENT.IR
همیار دندانسازان و دندانپزشکان

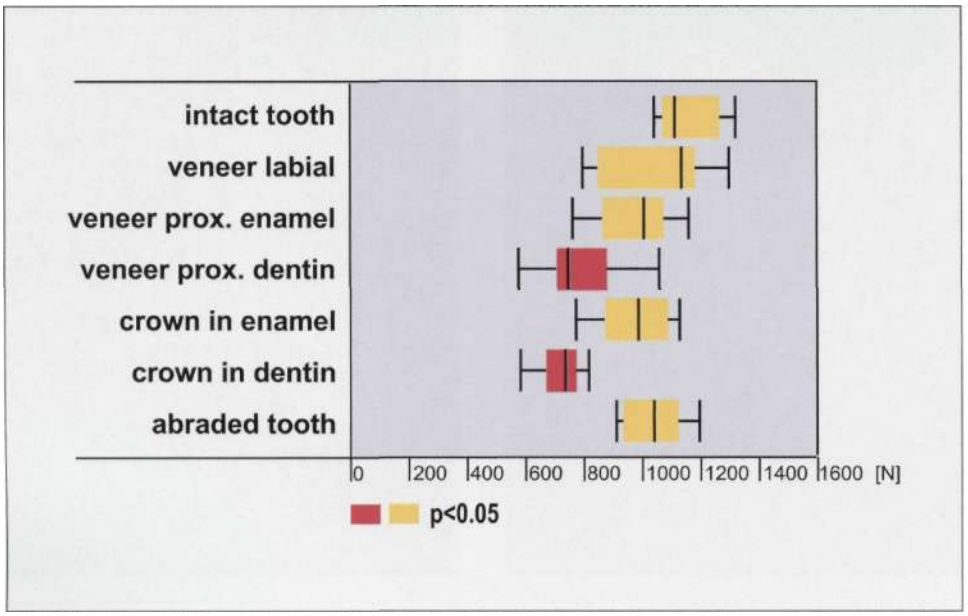

Fig 3-23 Fracture strength of human central incisors restored with veneers/ bonded ceramic crowns.

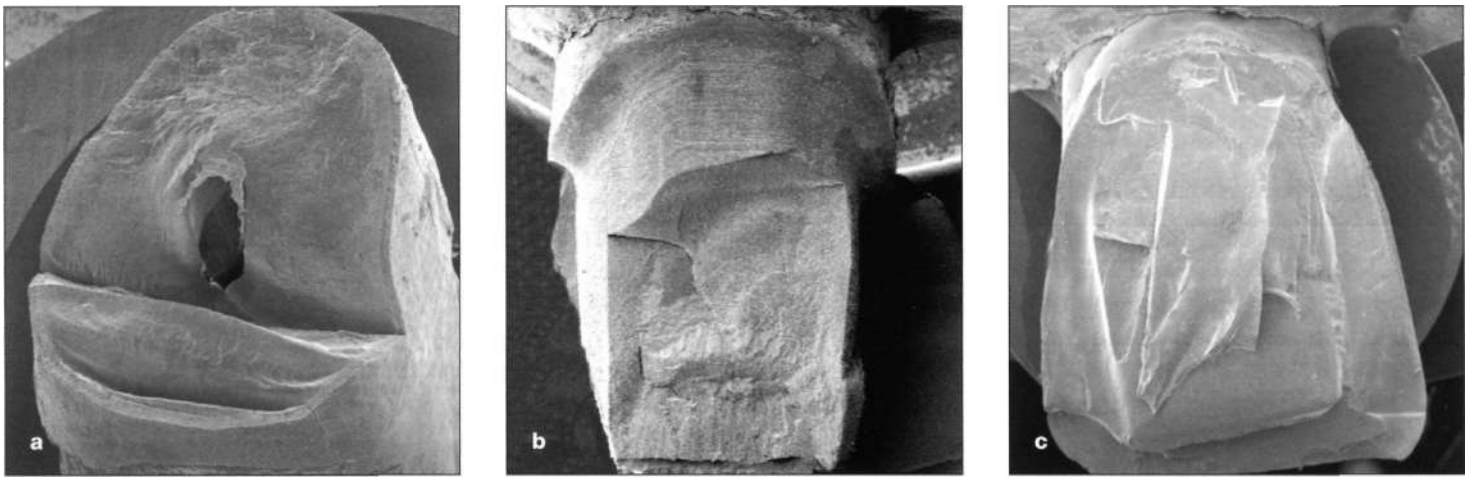

Fig 3-24a-c Tooth restored with veneer, fracture after loading up to failure, (a) Cohesive fracture at tooth neck, (b) Cohesive fracture in tooth, with small adhesive fracture portion, (c) Cohesive fracture in ceramic.

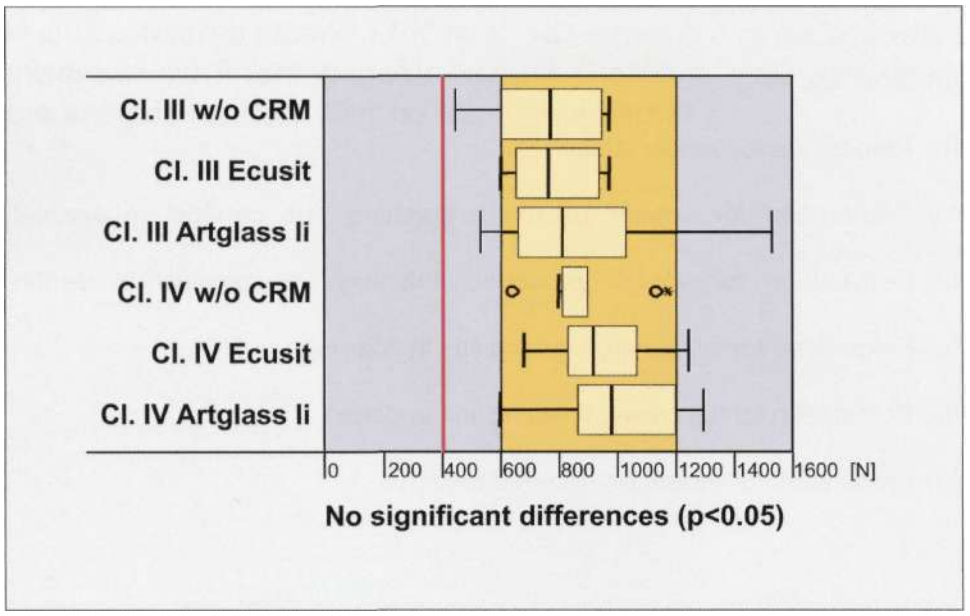

Fig 3-25 Fracture strength of human incisors restored with veneers placed on top of existing class III and class IV composite restorations.
w/o CRM = without composite repair material.
Artglass li and Ecusit = composite repair materials.

WWW.HIGHDENT.IR
همیار دندانسازان و دندانپزشکان

Conclusion

Veneers require reliable bonding mechanisms between ceramic and composite on one side and between tooth substance and composite on the other side to be feasible and successful. With the right selection of dental adhesive systems it is possible today permanently to bond veneers to anterior teeth and restore the original strength of the teeth. In the past, veneers were restricted to enamel as a substrate for bonding. Modern dental adhesives allow also bonding of veneers, if some portions of the preparation are in dentin. A meticulous adhesive technique with appropriate moisture control is a prerequisite for successful integration of veneers.

References

1. Roulet J-F, Degrange M. Adhesion. The Silent Revolution in Dentistry. Chicago: Quintessence, 1979.
2. Roulet J-F, Wilson NHF, Fuzzi M. Advances in Operartive Dentistry. Vol. 1. Chicago: Quintessence, 2001.
3. Wilson NHF, Roulet J-F, Fuzzi M. Advances in Operative Dentistry. Vol. 2. Chicago: Quintessence, 2001.
4. Brudevold F, Soremark R. Chemistry of the mineral phase of enamel. In: Miles AEW. ed. Structural and Chemical Organization of Teeth. Vol. 2. New York and London: Academic Press, 1967:247.
5. Angmar-Mansson B. Studies on the Distribution and Ultrastructure of the Main Components in Human Dental Enamel. Stockholm: Dr. Odont thesis, 1970.
6. Schroder HE. Orale Strukturbiologie. Stuttgart: Thieme, 1976:60-129.
7 Gwinnett AJ. The ultrastructure of the "prismless" enamel of deciduous teeth. Arch Oral Biol 1966;11:1109-1116.
8. Gwinnett AJ. The ultrastructure of the "prismless" enamel of permanent human teeth. Arch Oral Biol 1967;12:381-388.
9. Boyde A. The Structure of Developing Mammalian Dental Enamel. In: Stack MV, Fearnhead RW eds. Tooth Enamel. Bristol: John Wright and Sons Ltd., 1965:163-167.
10. Hdhling HJ. Die Bauelemente von Zahnschmelz und Dentin aus morphologischer, chemischer und struktureller Sicht. Munich: Hanser, 1966.
11. Rdnnholm E. An electron microscopic study of the amelogenesis in human teeth. II. The development of enamel chrystallites. J Ultrastruct Res 1962;6:249.
12. Frazier PD. Adult human enamel: An electron microscopic study of crystallite size and morphology. J Ultrastruct Res 1968;22:1-11.
13. Fosse G. The number of prism bases on the inner and outer surfaces of the enamel mantle of human teeth. J Dent Res 1964;43:57
14. Fosse G. A quantitative analysis of the numerical density and the distributional pattern of prisms and ameloblasts in dental enamel and tooth germs. IV. The number of prisms per unit area on the outer surface of human permanent canines. Acta Odont Scand 1968;26:409; V. Prism density and pattern of the outer and inner surface of the enamel mantle of canines. Acta Odontol Scand 1968;26:501; VII. The numbers of cross-sectioned ameloblasts and prisms per unit area in tooth germs. Acta Odontol Scand 1968;26:573.
15. Eisenmann DR, Glick PL. Ultrastructure of initial crystal formation in dentine. J Ultrastruct Res 1972;41:18-28.
16. Takuma S. Ultrastructure of Dentinogenesis. In: Miles AEW. ed. Structural and Chemical Organization of Teeth. Vol. 1. New York and London: Academic Press, 1967
17 Garberoglio R, Brannstrdm M. Scanning electron microscopic investigation of human dentinal tubules. Archs Oral Biol 1976;21:355-362.
18. Ketterl W. Studie uber das Dentin der permanenten Zahne des Menschen. Stoma 1961 ;17:148.

WWW.HIGHDENT.IR
همیار دندانسازان و دندانپزشکان

19. Frank RM. Ultrastructure of Human Dentine. In: Fleisch H, Blackwood JJJ, Owen M. eds. Calcified Tissues. Berlin: Springer, 1966.
20. Frank RM, Sauvage C, Frank P. Morphological basis of dental sensitivity. Int Dent J 1972;22:1-19.
21. Roane JB, Foreman DW, Melfi RC, Marshall FJ. An ultrastructural study of dentinal innervation in the adult human tooth. Oral Surg Oral Med Oral Pathol. 1973;35:94-104.
22. BrannstromM. Sensitivity of dentine. Oral Surg 1966;21:517.
23. Bergmann G, Engfeldt B. Studies on mineralized dental tissues. VI. The distribution of mineral salts in the dentine with special reference to the dentinal tubules. Acta Odontol Scand 1955;13:1.
24. Ericsson SG. Quantitative microradiography of cementum and abraded dentine. A methodological and biological study. Acta Radiol Diagn (Stockh).1965;(Suppl.)246.
25. Tronstad L. Optical and microradiographic appearance of intact and worn human coronal dentine. Arch Oral Biol 1972;17:847-858.
26. Tronstad L. Scanning electron microscopy of attrited dentinal surfaces and subjacent dentine in human teeth. Scand J Dent Res 1973;81:112-122.
27. Mjbr IA. Histologic studies of human coronal dentine following the insertion of various materials in experimentally prepared cavities. Arch Oral Biol 1967;12:441-452.
28. Mjbr IA. Human coronal dentine: Structure and reactions. Oral Surg Oral Med Oral Pathol 1972;33:810.
29. Douglas WH. Clinical status of dentine bonding agents. J Dent 1989;17:209-215.
30. Eick JD, Wilko RA, Anderson CH, Sorensen SE. Scanning electron microscopy of cut tooth surfaces and identification of debris by use of the electron microprobe. J Dent Res 1970;49:1359-1368.
31. Gwinnett AJ. Smear layer: morphological considerations. OperDentSuppl 1984;3:3-12.
32. Tronstad L. Ultrastructural observations on human coronal dentin. Scand J Dent Res 1973;81:101-111.
33. Suzuki T, Finger WJ. Dentin adhesives: site of dentin vs. bonding of composite resins. Dent Mater 1988;4:379-383.
34. Pashley DH. Smear layer: overview of structure and function. Proc Finn Dent Soc 1992;88(Suppl 1):215-224.
35. Pashley DH. Dentin permeability and dentin sensitivity. Proc Finn Dent Soc 1992;88(Suppl 1):31-37.
36. Erickson RL, Glasspoole EA, Pashley DH. Dentin permeability changes from acidic dentin conditioners. J Dent Res 1991 ;70:378 (Abstr 903).
37. Vaidyanathan TK, Vaidyanathan J, Prasad A. Properties of a new dental porcelain. Scanning Microsc 1989;4:1023-1033.
38. Adair PJ. Glass ceramic dental products. US Patent No 4, 431 420, 1984.
39. Adair PJ, Grossman DG. The castable ceramic crown. Int J Periodontics Restorative Dent 1984;4:32-46.
40. Ludwig K, Kubick S. Vergleichende Untersuchungen zur Bruchfestigkeit von vollkeramischen Frontzahnbrucken. Dtsch Zahnarztl Z 1999;54:711-714.
41. Buonocore MG. A simple method of increasing the adhesion of acrylic filling materials to enamel surfaces. J Dent Res 1955;34:849-853.
42. LutzF, LuscherB, Ochsenbein H, Muhlemann HR. Adhasive Zahnheilkunde. Zurich: Abteilung fur Kariologie und Parodontologie, Zahnarztliches Institut, Universitat Zurich (Selbstverlag);1976.
43. Noack MJ, Roulet J-F Rasterelektronenmikroskopische Beurteilung der Atzwirkung verschiedener Atzgele auf Schmelz. Dtsch Zahnarztl Z 1987;42:953-959.
44. Nakabayashi N, Kojima K, Masuhara E. The promotion of adhesion by infiltration of monomers into tooth substrates. J Biomed Mater Res 1982;16:265-273.
45. Perdigao J, Lopes M. Dentin bonding. Questions for the new millennium. J Adhesive Dent 1999;1(3):191-209.
46. Peschke A, Blunck U, Roulet J-F. Influence of incorrect application of a water-based adhesive system on the marginal adaptation of class V restorations. Am J Dent 2000;13:239-244.
47. Tay FR, Gwinnett AJ, Wei SH. Micromorphological spectrum from overdrying to over wetting acid-conditioned dentin in water-free, acetone-based, single-bottle primer/adhesives. Dent Mater 1996;12:236-244.
48. Pashley DH, Tay FR. Aggressiveness of contemporary self-etching adhesives. Part II: Etching on unground enamel. Dent Mater 2001; 17:430-444.
49. Hannig M, Reinhardt KJ, Bott B. Self-etching primer vs phosphoric acid: An alternative concept for composite-to-enamel bonding. Oper Dent 1999;24:172-180.
50. Bertschinger C, Paul SJ, Luthy H, Scharer P. Dual application of two dentin bonding agents. J Dent Res 1996;75:257 (Abstr 1919).
51. Clotten S, Blunck U, Roulet J-F. The influence of a simplified application technique for ceramic inlays on the margin quality. J Dent Res 1998;77:942 (Abstr 2483).
52. Craig RG. Restorative Dental Materials. 8th ed. St Louis, MO: Mosby, 1989,481-498.
53. Calamia JR. Etched porcelain facial veneers: A new treatment modality based on scientific and clinical evidence. NY J Dent 1983;53:255-259.
54. Calamia JR, Simonsen RJ. Effect of coupling agents on bond strength of etched porcelain. J Dent Res 1984;63:179.
55. Calamia JR, Vaidyanathan J, Vaidyanathan TK, Hirsch SM. Shear bond strength of etched porcelains. J Dent Res 1985;64:296 (Abstr 1086).
56. Plueddemann EP. Adhesion through silane-coupling agents. J Adhesion 1970;2:184-194.
57. Roulet J-F. Degradation of dental polymers. Basel: Karger, 1976.
58. Roulet J-F, Sbderholm KJM, Longmate J. Effects of treatment and storage conditions on ceramic/composite bond strength. J Dent Res 1995;74:381-387.
59. Edelhoff D, Abuzayeda M, Yildirim M, Spiekermann H, Marx R. Adhasion von Kompositen an hochfesten Strukturkeramiken nach unterschiedlicher Oberflachenbehand lung. Dtsch Zahnarztl Z 2000;55:617-623.

WWW.HIGHDENT.IR
همیار دندانسازان و دندانپزشکان

60. Gobel R, Luthardt R, Welker D. Experimented Untersuchungen zur Befestigung von Restaurationen aus Zirkonoxid und Titan. Dtsch Zahnarztl Z 1998;53:295-298.
61. Vogel K, Salz U. Factors influencing adhesion to Al2O3- and $Zr0_2$-ceramics. J Dent Res 1998;77:941 (Abstr 2475).
62. Wegner SM, Kern M. Long-term resin bond strength to zirconia ceramic. J Adhesive Dent 2000;2:139-147.
63. Musil R, Tiller H-J. Das Silicoater Verfahren nach funfjahriger klinischer Bewahrung. Zahnarztl Praxis 1989;4:124-128.
64. Musil R, Tiller H-J. Der Kunststoff-Metall-Verbund Silicoaterverfahren. Heidelberg: Huthig, 1989.
65. Janda R, Roulet J-F, Wulf M, Tiller H-J. A new adhesive technology for all-ceramics. Dent Mater 2002 (submitted).
66. KernM.WegnerSM.Bondingtozirconiaceramic:Adhesion methods and their durability. Dent Mater 1998;14:64-71.
67. Magne P, Belser U. Bonded Porcelain Restorations in the Anterior Dentition: A Biomimetic Approach. Chicago: Quintessence, 2002.
68. Fairhurst CW, Lockwood PE, Ringle RD, Thompson WO. The effect of glaze on porcelain strength. Dent Mater 1992;8(3):203-207.
69. Anusavice KJ, Shen C, Lee RB. Strengthening of feldspathic porcelain by ion exchange and tempering. J Dent Res 1992;71(5):1134-1138.
70. Anusavice KJ, Shen C, Vermost B, Chow B. Strengthening of porcelain by ion exchange subsequent to thermal tempering. Dent Mater 1992;8(3):149-152.
71. Rosenstiel SF, Gupta PK, Van der Sluys RA, Zimmerman MH. Strength of a dental glass-ceramic after surface coating. Dent Mater 1993;9(4):274-279.
72. Malament KA, Socransky SS. Survival of Dicor glass-ceramic dental restorations over 14 years. Part 1. Survival of Dicor complete coverage restorations and effect of internal surface acid etching, tooth position, gender, and age. J Prosthet Dent 1999;81:23-32.
73. Malament KA, Socransky SS. Survival of Dicor glass-ceramic dental restorations over 14 years. Part 2. Effect of thickness of Dicor material and design of tooth preparation. J Prosthet Dent 1999;81:662-667.
74. Magne P, Douglas WH. Additive contour of porcelain veneers: a key element in enamel preservation, adhesion, and esthetics for aging dentition. J Adhesive Dent 1999;1:81-92.
75. Raffelt C. Die Auswirkungen verschiedener Praparationsformen auf das Bruchverhalten menschlicher Frontzahne mit adhasiv befestigten IPS Empress Veneers und Kronen. Thesis, Berlin: HU, 2002.
76. Roulet J-F, Raffelt C, Pfeiffer H, Blunck U, Chun Y-H. The strength of anterior teeth with bonded porcelain veneers and crowns. J Dent Res 2002;81 (Spec Iss A):A415 (Abstr 3357).
77. Pfeiffer H. Applikation von Veneers auf mit Kompositfullungen versorgten Frontzahnen unter Berucksichtigung des Komposit- Komposit Verbundes. Thesis, Berlin: HU, 2002.
78. Chun Y-H, Pfeiffer H, Raffelt C, Blunck U, Roulet J-F. The quality of anterior veneers placed on composite restorations. J Dent Res 2002;81 (Spec Iss A):A250 (Abstr 1921).

WWW.HIGHDENT.IR
همیار دندانسازان و دندانپزشکان

4 Porcelain-Bonded Restoration and Function

Claude R. Rufenacht

Introduction

The field of function and occlusion has been widely investigated. We know today most of the parameters that contribute to good function. Unfortunately, in a modern general practice, where dentists concentrate their efforts mastering technically sensitive esthetic materials, little attention is paid to the application of these elements of knowledge. Emphasis is placed on the intrinsic beauty of a restoration, which all too often hides functional disturbances that insidiously develop in the oral cavity. Yet an appreciation of existing occlusal conditions and functional disturbances is critical when the restorative procedure involves porcelain-bonded restorations that neither wear nor show flexibility. In the constraining oral conditions, the esthetic finality of a restoration only makes sense when it is associated with its functional finality (Figs 4-1 and 4-2).

WWW.HIGHDENT.IR
همیار دندانسازان و دندانپزشکان

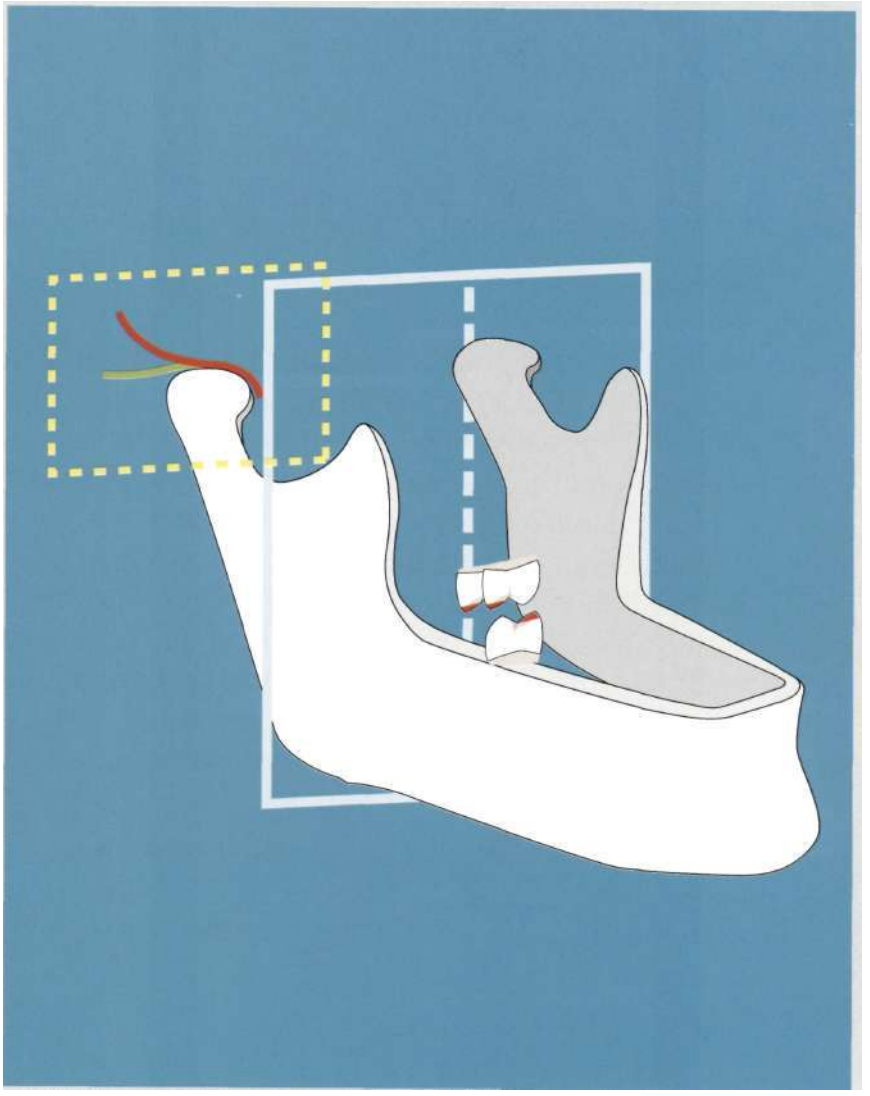

WWW.HIGHDENT.IR
همیار دندانسازان و دندانپزشکان

Fig 4-1a-d Migration of the whole anterior segment, (a) In occlusal relationships characterized by an anterior open-bite, (b) The restoration of this segment with porcelain-bonded restoration can certainly improve dental esthetic conditions but not tooth stability, (c) Long-term occlusal stability will require lifetime use of a removable acrylic night-guard, even if maxillary central incisors have been shortened to minimize tongue pressure.

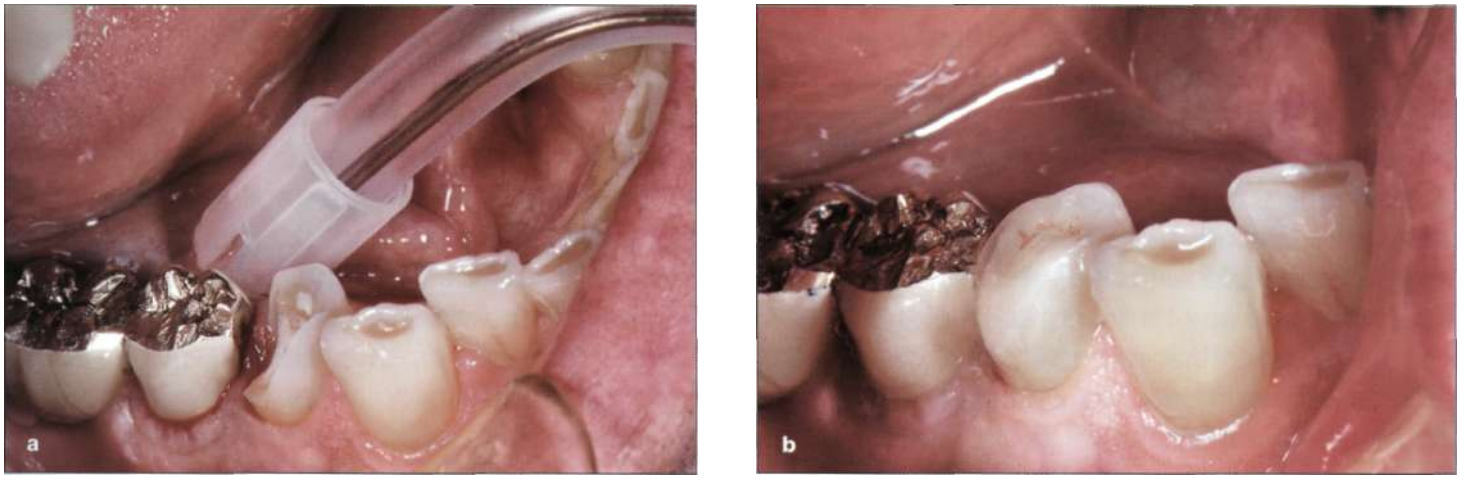

Fig 4-2a, b Such a porcelain-bonded restoration is designed to adapt or conform to antagonist or adjacent deformities. This design not only fools a basic principle of dental esthetics, which is the duplication of the morphologic reality, but its survival in such constraining occlusal conditions is limited. It broke seven years after insertion.

WWW.HIGHDENT.IR
همیار دندانسازان و دندانپزشکان

The Tooth-Porcelain-Bonded Restoration Complex

Enamel and dentin form a composite structure providing the natural tooth with unique characteristics which enable it to withstand for years the impact of masticatory forces and thermal variation. In this composite entity the hardness of the enamel seems to protect the soft underlying dentine, while the softness of the dentin and the presence of collagen fibers at the dentino-enamel junction provide the whole tooth with ideal biomechanical properties, and seem to compensate for the brittle nature of the enamel.[1] One can easily imagine that porcelain-adhesive material and remaining dental tissue could not only duplicate the original tooth structure but also reproduce the biomechanical properties of the original dentino-enamel complex.

Recent researches, however, have shown noticeable differences between these two entities. The strength of the tooth veneer complex was found to be greatly superior to that of the natural tooth in an in-vitro load-to-fracture test.[2,3] This has led to the hypothesis that the excess strength of the complex tooth porcelain-bonded restoration may lead to a stress transfer and failures at the level of the root, simulating the fractures affecting conventional restorations such as gold crowns or inlays, which are experienced in clinical practice.[4] To overcome these possibilities of fracture, attention has to be given to the proper design and adequate thickness of porcelain-bonded restorations[5-8] - elements that must be understood with the objectives of the most favorable load configuration or stress distribution,[9-11] or a search for a tooth porcelain-bonded restoration complex more compatible with the mechanical and biological properties of the original dental tissues.

Indeed, porcelain may well contribute to the recovery of crown biomechanical properties and compensate for structural tooth weakness following carious lesions, abrasion or erosion,[12] yet the advantages of increased strength remain questionable when flexibility is considered to be essential in the qualities of any structure to withstand the impact of a traumatic blow.[13] In this respect, the idea to modulate tooth resilience by the combination of composite resin and ceramics to reproduce the biomechanical characteristics of the original tooth deserves to be developed whenever such an approach is realistic.

We know that, whatever their design, all porcelain-bonded restorations increase tooth stiffness. Yetthe restoration of the original tooth compliance can best be obtained with a large build-up of composite material replacing the fractured part of an incisor and covered with a thin facial layer of ceramics slightly overlapping lingually.[11] Clinically one has to point out that this type of restoration is loaded with the unfavorable high thermal expansion of the composite and may lead to marginal adaptation failures.

Fortunately, clinicians' inclinations have always clearly favored restoring fractured incisors with full ceramic restorations, for reasons including enamel-like thermal expansion, color stability and refined esthetics, unconsciously choosing increased tooth stiffness and low stress distribution versus flexibility. Thanks to research, these can be easily optimized by increasing ceramic thickness at the incisal level and reducing its overcontour.

Clinically it can be stated that, despite marked differences in biomechanical properties with the natural tooth, porcelain-bonded restorations have demonstrated their predictability in terms of fracture rate, microleakage or debonding during more than a decade of clinical practice and clinical studies.[14-19]

This has encouraged clinicians and researchers to extend the field of indications of porcelain-bonded restoration to substantial morphological modifications, extensive hard tissue fractures and even worn-out dentitions.[2,20-23] This supposes a full confidence in the nature and qualities of the adhesive systems relating thetooth to constraining occlusal conditions and the porcelain restoration even when submitted to the adverse conditions of a reduced hard tissue support. This reduced hard tissue support surface must be considered with attention as it not only could affect the maintenance of tooth vitality but question the reliability of the adhesion of the porcelain-bonded restoration.

WWW.HIGHDENT.IR
همیار دندانسازان و دندانپزشکان

Porcelain-Bonded Restoration and Pulpal Health

The combination of tooth fracture and tooth preparation may lead to excess dentin reduction that will affect not only the vitality of the tooth substrate but the integrity of pulpal tissue. We know that the closer one approaches to the pulp, the higher content of organic material is found in the smear layer as a result of a widening of odontoblast-containing tubuli, while intratubular dentin lessen. This increase of organic material in the oral environment faces high possibilities of deterioration.

Indeed, as the organic portion of the smear layer is lost, microchannels usually occur, allowing bacteria and by-products to gain access to dentinal tubuli.[24-25] This invariably creates a situation that leads to pulp inflammation. Therefore, control of the biodegradable smear layer becomes imperative to ascertain dentinal vitality, pulpal health and postoperative sensitivity.

The protection of the dentin must be considered as a key clinical step in porcelain-bonded restoration preparation, which in most systems available today consists in the cleaning of the dentin, usually by way of a removal of the smear layer, and the seal of the tubuli. The removal of the smear layer is carried out by etching, either by the application of a 10-3 solution (10% citric acid with 3% of ferric chloride) or a phosphoric acid solution (which has the advantage of providing a lowertensile strength to dentin, probably because of an increased denaturing of the collagen fibers).[26]

It remains to ascertain the biologic seal of dentinal tubuli, which can be achieved clinically by hybridization, a procedure consisting in the formation of hybrid layers of demineralized dentin combined with an adhesive chemical agent. This hybridization is the most currently accepted mechanism for dentin bonding, as research has shown that the hybrid layer obtained acts as a protection for ground dentin[27-29] and apparently succeeds in providing the maintenance of pulpal health.

Clinically, it remainstoachieveachemical bond between the adhesive coating layer and the resin luting cement in an association whose quality and biocompatibility are aimed at providing adhesive strength to the tooth-porcelain-bonded restoration entity to resist the constraining forces of the occlusion.

Occlusion

Occlusion refers to the act of closure and the state of being closed. It involves at the same time dynamic and static components. Static components will be first considered.

In a good occlusion, all the teeth in the mouth make simultaneous contacts. It is, however, acknowledged that in the anterior segment teeth should have lighter contacts, which clinically may mean: "anterior teeth do just not contact". Indeed, the perception of a fremitus at interocclusal contact can be detrimental to tooth stability and lead to interproximal separation.

The total tooth contact area, which includes the anterior and posterior teeth, averages 4 mm^2. Considering the number of interocclusal contacts (64 to 100 for the whole mouth), taking into account varying opinion and the type of occlusion,[30-31] each single contact area is estimated to be extremely small. The multiplication of posterior interocclusal contacts is mandatory for improving stress distribution, as studies have shown that in the posterior segment, muscle contraction develops at 100%, whetheryou have single or multiple contacts[32] (Fig 4-3).

In nature, cusp to ridge contacts are the rule and characterize class I occlusions. Cusp to fossa contacts are usually found in class II occlusions, while the tripodization of interocclusal contacts remains a dream, born from the imagination of dentists anxious to provide tooth stability.

A coincidental location of tooth interocclusal contact and porcelain-bonded restoration margin should be avoided, as alterations of the marginal seal of porcelain-bonded restoration can be more often stated than when the opposing contact is located elsewhere.[33]

WWW.HIGHDENT.IR
همیار دندانسازان و دندانپزشکان

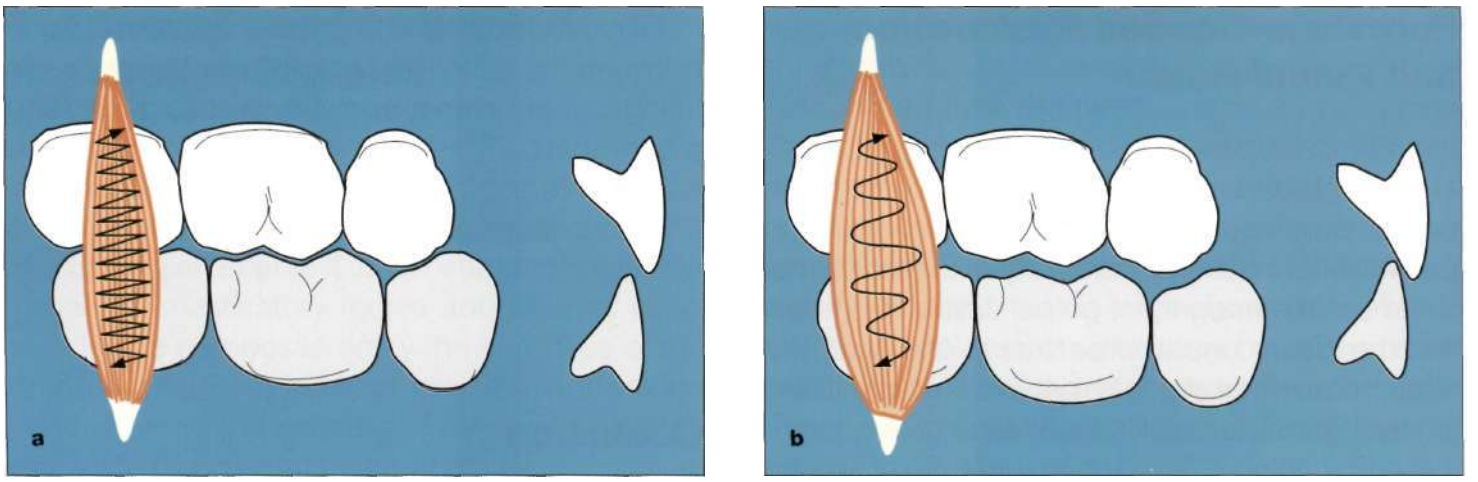

Fig 4-3a, b Research has shown (a) When only posterior teeth are allowed to contact, muscle contraction develops at 100%, whatever the number of interocclusal contacts, (b) When a single anterior tooth does contact in the absence of posterior contacts, muscle ability to contract is highly reduced but tends to increase proportionally with the number of anterior contacts.

Whenever this recommendation finds easy application in the anterior segment, clinical practice shows that the posterior segment appears as a privileged area where interocclusal contacts and PBR margins are coincidental by reason of posterior tooth morphology and the nature of interocclusal relationships. Observation shows also that it is in this area that the morphological design of the restoration is distorted to adapt to antagonist deformities, or inserted in a dental segment presenting various manifestations of abrasion (Fig 4-2). As a result, the possibilities of coincidental location of margin placement and enlarged interocclusal contacts increase. And with them the chances of altering the marginal seal resulting from porcelain microfractures under the load of occlusion. It can be assumed that further deteriorations of the marginal seal of porcelain-bonded restoration can take place under the impact of parafunctional habits such as clenching, when margin placement and interocclusal contacts are coincidental. This stresses the importance of tooth preparation for porcelain-bonded restorationsthat has not only to foresee interocclusal contact location but provide sufficient porcelain thickness to allow porcelain-bonded restoration to offer adequate resistance to constraining parafunctional conditions.

Function

Function takes place at the very moment teeth enter into action. This dynamic part of occlusion refers to the engagement of mandibular teeth towards centric, and to their disengagement. The spatial development of functional movements is dictated by condylar pathway, antagonist tooth morphology and tooth position. It displays at the registration athree-dimensional tracing delimiting an area defined as "the envelope of mandibular function" characterized by a droplet shape displaying, as a result of antagonist tooth morphology and position, infinite individual variations (Fig 4-4). This makes teeth the primary factors in tooth-closing patterns.[34-36] It has been established that tooth-closing patterns remain under neuro-muscular control - even if the exact nature of this phenomenon has always escaped scientific explanation.[37]

If we know most of the parameters that participate in function, the observation of unworn long-lasting dentitions clearly indicates the type of oral architecture that best integrates these parameters. These occlusions are characterized by similar parameters in the vertical and horizontal planes: that is to say in the overbite and overjet of incisors and canines. Frontal chewing patterns have an angle of about 70° from the horizontal for the canines and in eccentric occlusion we find a

WWW.HIGHDENT.IR
همیار دندانسازان و دندانپزشکان

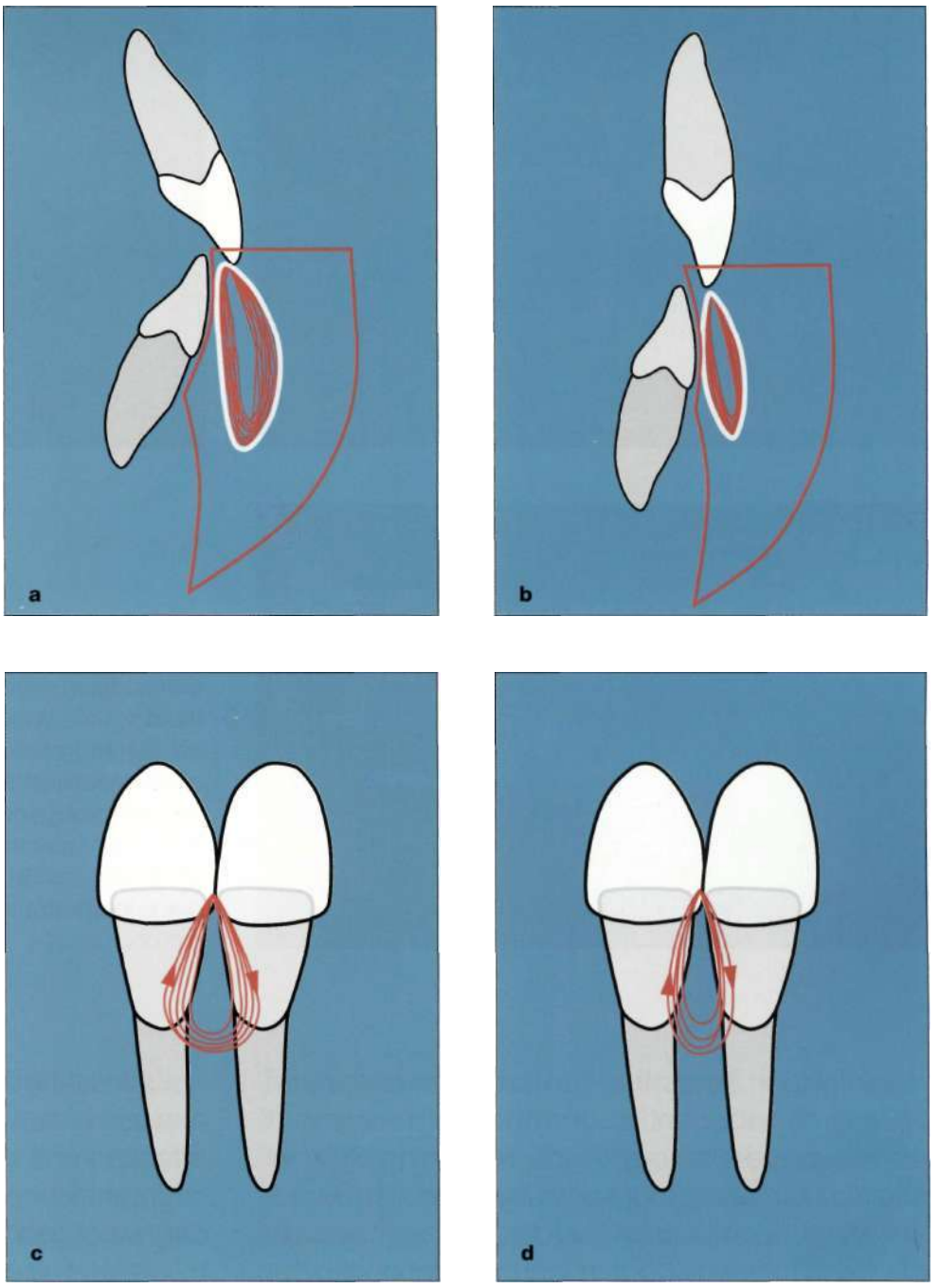

Fig 4-4a-d The "envelope of mandibular function" is, apparently, primarily dictated by antagonist tooth morphology and tooth position. It displays a characteristic droplet shape with noticeable individual differences in the sagittal (a, b) and frontal planes (c, d). Variations from those characteristic droplet shapes can be interpreted as the expression of a malocclusion.

tooth-to-tooth contact with a large posterior clearance (Fig 4-5). This tooth-to-tooth contact in eccentric occlusions can be considered as ideal, as it generates, according to research, a reduced muscular activity in comparison to group function and bi-balanced occlusion (Fig 4-3b).[38,39]

In these dentitions, morphologic integrity is the rule. The teeth can receive porcelain-bonded restorations without any specific restriction, but in respect of the environmental morphologic design: function follows forms. Functional integration will then be achieved by the control of simultaneous interocclusal contacts and the absence of interferences during tooth closure patterns.

In nature, however, oral architectural ideals are not the rule. Research has shown that in a selected population the occurrence rate of malocclusion, which includes open-bite, over-bite, class II and class III occlusions, averages 20%.[40] As a result, one in every five patients does not present an incisal pathway reflecting usual stan-

WWW.HIGHDENT.IR
همیار دندانسازان و دندانپزشکان

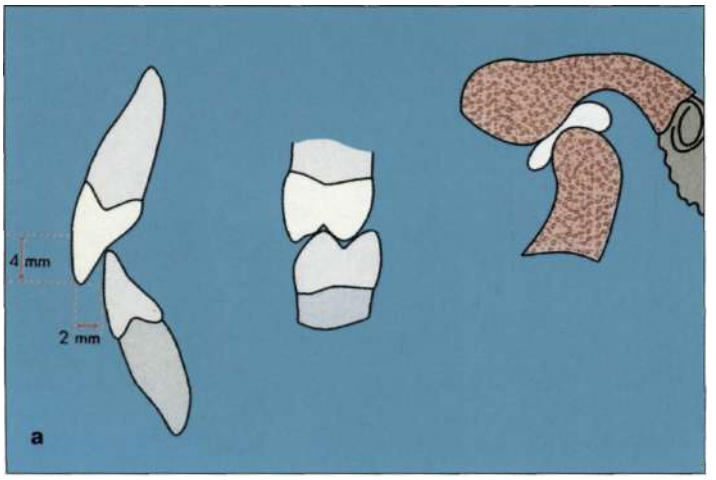

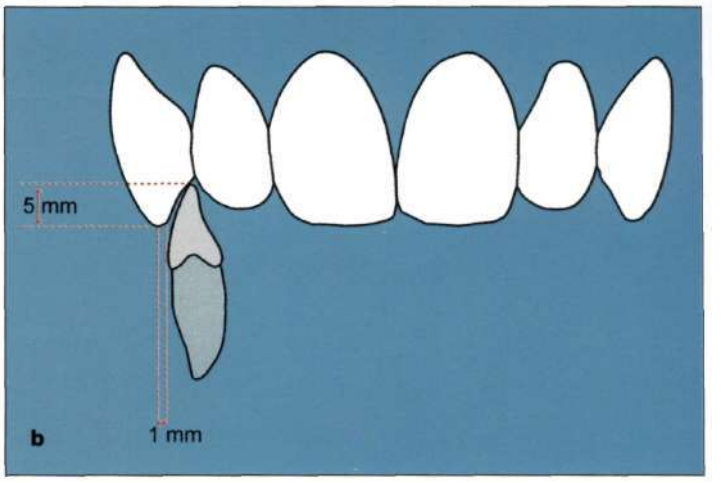

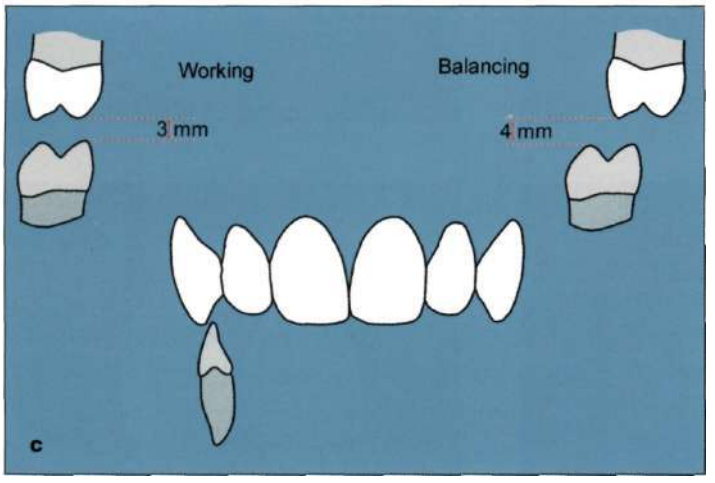

Fig 4-5a-c Long-lasting dentitions show similar characteristics: multiplication of interocclusal contacts for better stress distribution in centric occlusion and in eccentric occlusions, a tooth-to-tooth contact reducing muscle activity and preventing any possibility of posterior interference. A duplication of these parameters in reconstructions should ascertain long-term maintenance and occlusal stability, (a) Mean anterior relationships in the sagittal plane for the incisor, (b) Mean anterior relationships in the frontal planeforthe canine, (c) Frontal relationships in right eccentric occlusion.

dards, which leads them to consider correction by way of orthodontics or orthopedic surgery. It also appears that out of the remaining 80% of class I occlusions; most occlusal schemes do not show anterior relationships, duplicating those displayed in long-lasting dentitions. Variations in the depth of the overbite, width of the overjet, and related incisal and canine guidance are unlimited, which justifies or imposes corrective measures necessary to prevent posterior interferences during function.

By deduction, it can be advanced that one of the challenges faced by restorative dentists in restoring a physiological occlusion is the changing of poorly related anterior relationships. The restoration of an anterior segment should never be envisaged from the viewpoint of minimal tooth preparation for veneer seating but from that of occlusal maintenance and functional excellence.

Occlusal maintenance involves the evaluation and correction of localized manifestations of wear affecting one anterior tooth or the whole anterior segment, concomitant with an appreciation of the degree of incisal or canine guidance necessary to prevent posterior interferences in eccentric occlusions. The achievement of these objectives requires an increase of the steepness of the disclusive angle which, depending on oral conditions, can be achieved either with an increase of vertical interocclusal relationships by way of a tooth elongation or with a reduction of horizontal relationships. A combination of these therapeutic measures is not unusual. Clinically, a modification of the palatal morphology of maxillary incisors and canines appears best suited to improve tooth guidance without compromising esthetics (Fig 4-6). The nature of this modification remains to be defined as long as it leaves open the question of the ideal steepness of the interocclusal angle

WWW.HIGHDENT.IR
همیار دندانسازان و دندانپزشکان



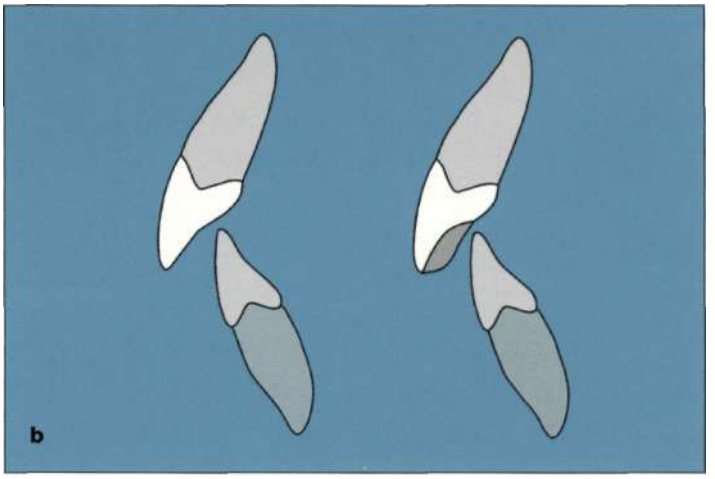



Fig 4-6a-c The improvement of anterior relationships for optimum guidance and occlusal maintenance may require a modification of maxillary anterior teeth morphology best achieved using porcelain-bonded restorations, (a) Palatal modification to correct insufficient horizontal parameters, (b) Incisal lengthening with palatal morphologic modification to correct insufficient vertical parameters following incisal wear, (c) Build-up of cingulum to prevent the eruption of antagonist mandibular incisors, correcting poor horizontal relationships.

(Fig 4-7). Mechanically, it appears that the deeper the angle the greater the likelihood of achieving tooth guidance and the greater the impossibility for posterior teeth contacting in eccentric occlusions. From a muscular point of view, the increase of the steepness of the disclusive angle may also produce a favorable result as it generates a proprioceptive inhibition that will shut down muscular activity thus reducing the load level in eccentric occlusions. This muscle inhibition has been explained by an increase of the torsional load affecting the teeth in their housing. This leads to a triggering effect on proprioceptive receptors[41]-[42] preventing muscles contacting harder through a feedback effect. However, careful attention must be paid, so that the increase in the disclusive angle does not cause the teeth, through their morphology or position, to interfere with neurological programmed tooth closure patterns. This will invariably lead to the abrasion of antagonist anterior tooth surfaces, mandibular buccal or maxillary lingual surfaces (Fig 4-8). Damage of this type affecting antagonist surfaces is mainly generated by overcontoured porcelain-bonded restorations but may also be found in orthodontic and orthognathic cases.

In the absence of available clinical possibilities of tracing three-dimensional, programmed tooth closure patterns for want of an articulator programmed to register this information, it is left to the dentist's sensibility to prevent restorations impinging on the area of function. Despite these restrictions, there is no better restorative material today than porcelain-bonded restoration to achieve functional and esthetic excellence or to duplicate the conditions found in long-lasting dentitions. All that remains is to apply the appropriate treatment at an appropriate time.

The maintenance of occlusal stability requires the detection and treatment of early manifesta-

WWW.HIGHDENT.IR
همیار دندانسازان و دندانپزشکان

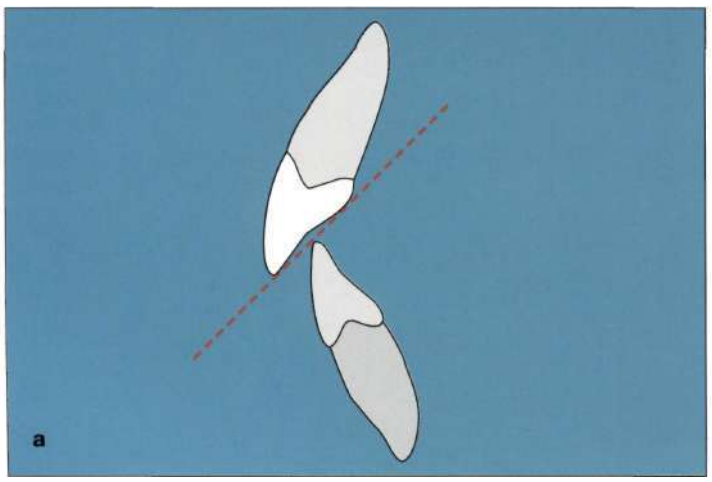

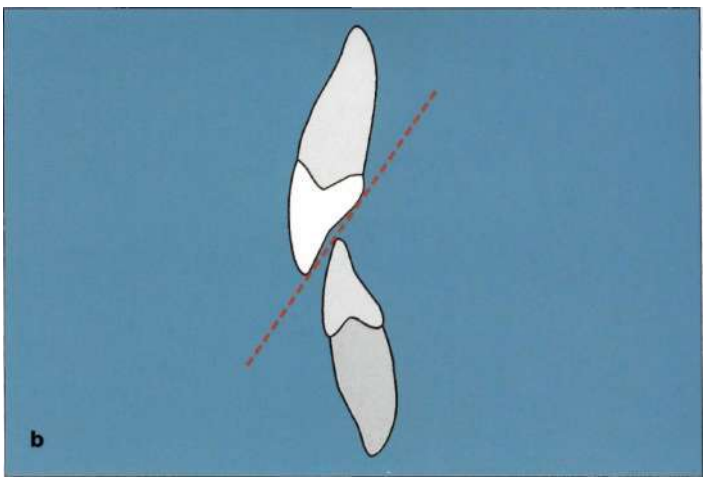

Fig 4-7a, b In the restorative process, the main remaining question is not the ideal interocclusal angle that should be given to anterior interocclusal relationships to ascertain tooth-to-tooth contact in eccentric occlusions but the individual limit allowed to the increase of the disclusive angle (a, b).

Fig 4-8 There is an individual limit to the increase of anterior interocclusal contact angle beyond which the tooth, through its morphology and position, may interfere with neurological programmed path of closure. The clinical consequences of this interference will abrade the facial surface of lower anterior teeth and/or lingual aspect of maxillary anterior teeth. An unfortunate design of the palatal aspect of maxillary porcelain-bonded restoration, including a probable increase of incisal width, is at the origin of antagonist hard-tissue destruction.

tions of wear affecting one anterior tooth or another (Fig 4-9). Given this opportunity of localized and restricted treatment, either the extension of occlusal degradation, labeled as occlusal disease, will invariably extend laterally to the lateral incisors and canines when affecting first the central incisors, or medially when canines have been first subjected to abrasion.

The period necessary forthe spread of occlusal disease along the whole anterior segment offers many opportunities to motivate patients to restore anterior esthetics and function at the same time (Fig 4-10). But once buccal inclines of premolars and molars have been erased, the mesially inclined slopes of lower molars distalized or their antagonist distally inclined slopes mesialized, when posterior tooth morphology has disappeared, nothing other than a full mouth restoration can be proposed to the negligent patient (Fig 4-11).

To satisfy a functional finality, this full mouth restoration involves the setting-up of anterior relationships generating the steepest possible anterior guidance capable of developing, overthe long term, atraumatic tooth closure patterns during the functions of speech, deglutition and mastication.

WWW.HIGHDENT.IR
همیار دندانسازان و دندانپزشکان

Fig 4-9a, b Initial manifestation of occlusal disease affecting the lower canine at a young age. (a) The porcelain-bonded restoration extending from lingual to incisal is expected to increase vertical relationships and disclusive angle (b) and prevent any possibility of interference in eccentric occlusions.

Fig 4-10a-c The extension of tooth wear patterns from canines to lateral and central incisors (a) offers a unique opportunity esthetically to restore the anterior segment and at the same time to ascertain long-term stability. Functional stability will then depend upon increasing anteriorguidance through increased anterior relationships (b) to prevent any possibility of posterior contact during tooth closer patterns (c).

WWW.HIGHDENT.IR
همیار دندانسازان و دندانپزشکان

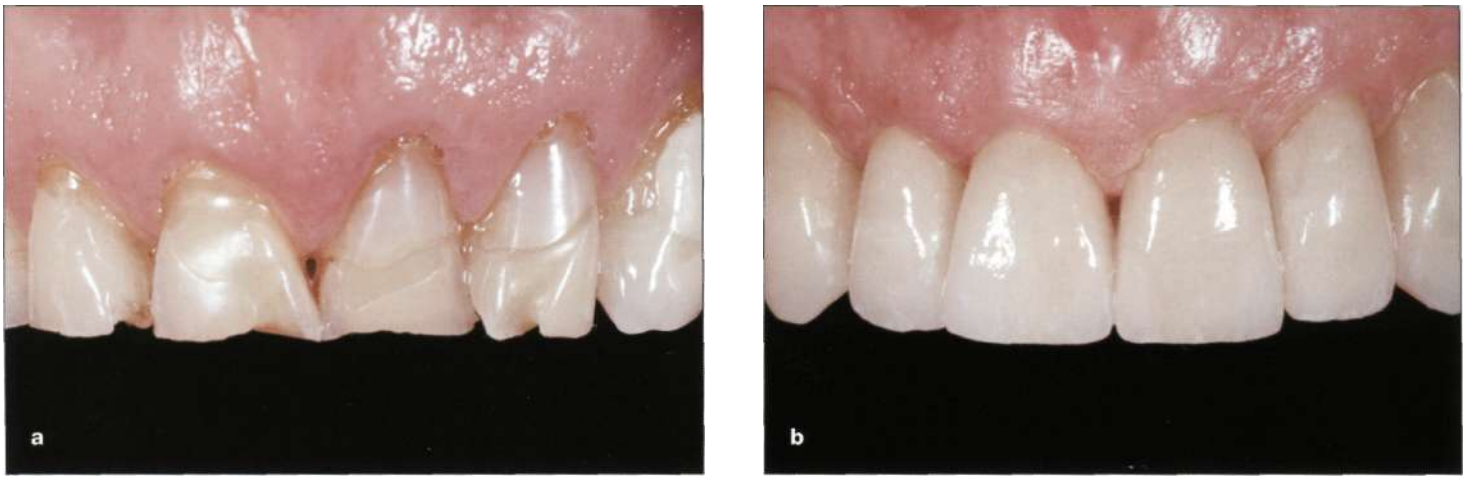

Fig 4-11 a, b Once anterior and posterior segments have been erased (a) there remains no alternative for the restorative dentist other than proposing a full mouth reconstruction to restore esthetics and function (b).

Incising

Mastication starts with the incision of food, which is followed by a lateral chewing phase. This lateral chewing phase can be divided in an early tooth-closing phase and a late tooth-closing phase. Incising requires an initial mouth-opening necessary to int rod uce food followed by a closing movement of the mandible, which develops in the sagittal plane and places upper and lower incisors in a tip-to-tip position. This movement seems to load incisors along their long axis and bring both condyles in a forward and downward translation. With unworn incisors there is no more than 1 mm of shearing load confined in the incisal edge of teeth. This shearing load will increase dramatically in the presence of worn-out incisal edges. As a result, the tip-to-tip incisal biting will gradually become a surface-to-surface biting, overloading incisors away from their long axis, allowing for the posterior confinement of condyles leading in turn to adverse neuro-muscular response. Finally, the incisal edges of the lower incisors will glide back along the lingual wall of maxillary incisors, a movement which develops atraumatically under neuromuscular control. Yet the presence of an increased incisal tip width affecting lower incisors will definitely overload the anterior teeth forcing lingually mandibular incisors (Fig 4-12).

It is therefore essential that porcelain-bonded restorations duplicate in their incisal design sharp unworn natural teeth and present in their whole configuration the most adequate compromise in terms of internal stress distribution and stress transfer following axial or horizontal loading.[6]

These mechanical requirements have to be considered when the presence of interproximal carious lesions, composite restorations, or tooth fractures impose a lingual extension of anterior maxillary porcelain-bonded restorations. In the same way, the palatal extension of porcelain-bonded restorations in the design of maxillary incisors and canines becomes unavoidable when functional finality demands:

- an improvement of anterior guidance to correct insufficient horizontal or vertical interocclusal relationships (Fig 4-6a)
- the design of cingulum and lateral palatal ridges to create punctiform centric interocclusal contacts and to prevent the eruption of lingually positioned antagonist lower incisors (Fig 4-6b).

To optimize the configuration of porcelain-bonded restorations one has to know that the area of the cingulum presents the lowest tensile strength of the whole palatal side at a tangential blow of 50 N directed against the incisal edge.[7] It can therefore be considered as an ideal location of porcelain-bonded restoration margin. Above all, a marginal location of porcelain-bonded restoration in this area of low tensile strength

WWW.HIGHDENT.IR
همیار دندانسازان و دندانپزشکان

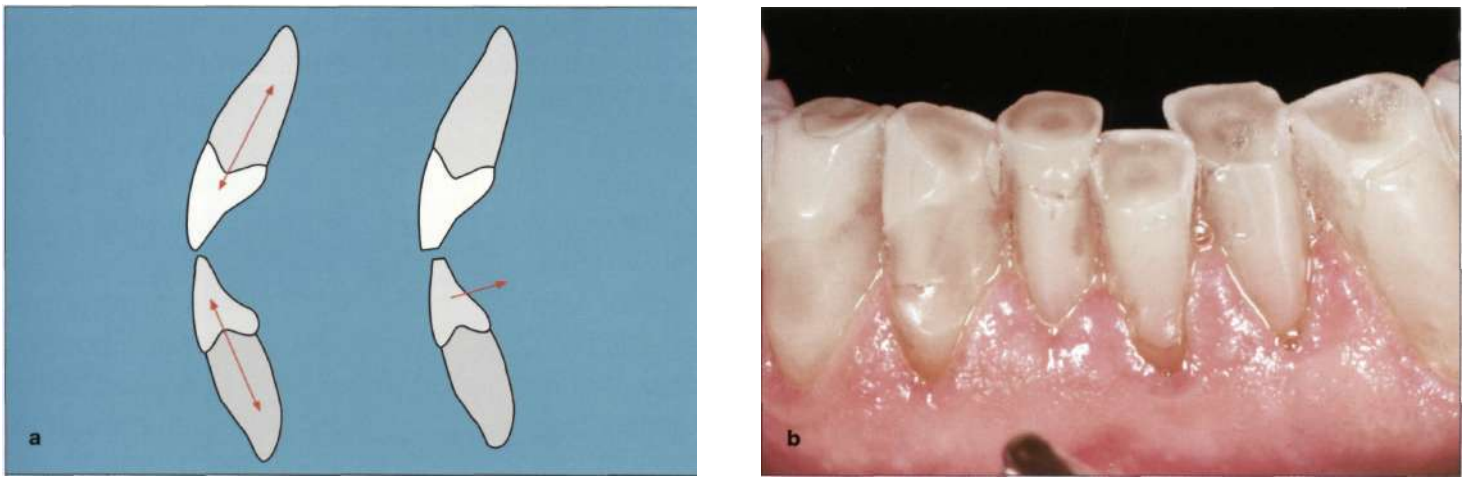

Fig 4-12a, b It is acknowledged that the incising function loads the teeth along their long axis (a). The evidence of an overload following the wear of the incisor edges can be clinically stated with the lingual migration of antagonist mandibular incisors (b).

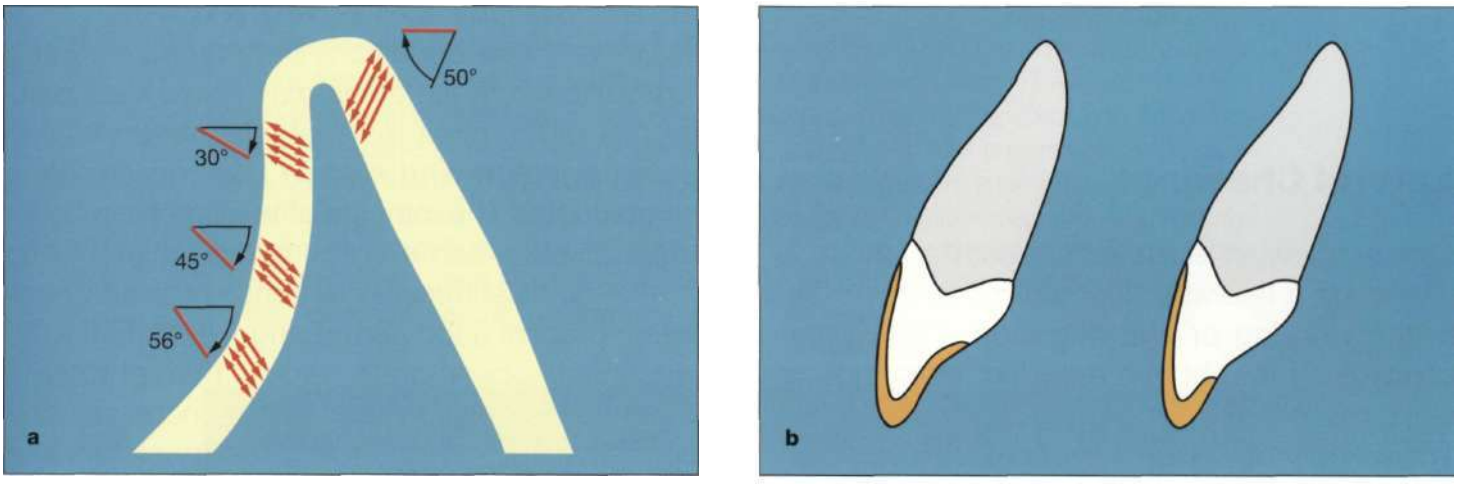

Fig 4-13a, b The direction of enamel rods varies from the incisal third to the palatal concavity and the cingulum. It presents an increasing angle to the horizontal from 30° to more than 50° *{Magne P, Douglas WH).*[6] (a) This imposes a specific design of porcelain-bonded restoration finish line according to its location. In the cingulum area a long chamfer cutting enamel rods at 90° is ideal for optimum adhesion, while a butt margin design remains perfectly valid. In the incisal third, the direction of the rods showing an angle at 30° from the horizontal, a mini-chamfer remains the best margin configuration, (b) The placement of the finish line at the lingual concavity should be avoided by reason of the extreme tensile stress experienced in this area following an incisal tangential blow.

reduces the importance of the design of the finish line: a butt margin cutting the enamel rods at an angle superior to 50° is perfectly acceptable while a long chamfer will reveal particularly resistant inasmuch it will cut the rods at 90°, allowing for an improved adhesion to enamel[43] (Fig 4-13).

Even if studies have shown that this type of porcelain-bonded restoration configuration presents the lowest relative compliance,[11] knowing that resilience is a key factor in fracture resistance,[13] fracture rate remains extremely low in clinical practice, maybe thanks to dentin bonds that have been proven to be a main determinant in the fracture mechanic.[44] As previously mentioned, the palatal extension of porcelain-bonded restoration is the rule each time functional conditions advocate an increase of anterior guidance to allow for sufficient posterior interocclusal clearance in eccentric occlusions.

The functional indication for palatal extension varnishes in functionally good occlusions where tissue preservation predominates. A limited in-

WWW.HIGHDENT.IR
همیار دندانسازان و دندانپزشکان

cisal palatal overlap remains the most valuable configuration as long as it is located in an area displaying low tensile strength, allowing for a finish line design that can be either a butt joint or chamfer.

These porcelain-bonded restoration configurations, palatal overlap or palatal coverage present the qualities to perfectly resist the incising function orthe tearing apart of food. Only a palatal extension of the porcelain-bonded restoration with a finish line ending up in the palatal concavity has to be avoided, as this thin extension of ceramic is precisely located in an area of high tensile strength.

Normal function not only implies the incision of food but the chewing of food.

Lateral Chewing

Lateral chewing starts with mouth opening, followed by a lateral movement of the mandible to the working or chewing side. The working condyle is brought in a retruded lateral position while the nonworking condyles move medially. The amount of this lateral shift varies, depending upon bone configuration of condyle and fossa, shape and conditions of disc and ligaments.

The shifting of the working condyle or *Bennet* shift[45] affects the mediolateral incline of the posterior cusps and conditions the direction of the buccal groove of lower molars whenever the occlusal scheme presents in eccentric occlusions a group function or a balanced occlusion (Fig 4-14).

In functionally good occlusal schemes, however, the importance of the *Bennet* shift is irrelevant. In the early closing phase of mastication, which sees both working canines starting to proprioceptively engage the closing movement, the importance of the mediolateral inclination of posterior cusps is irrelevant.

In the final closing phase, however, the approach to centric of opposing molar cusps can lead to interferences because the vertical guidance of the canine does not totally negate the path of the shifting condyle. As a result, interferences can occur in the mediolateral inclines of the second and first molars, especially when the condyle-fossa complex generates in the horizontal plane a shifting in lateroprotrusion (Fig 4-14) or a shifting in laterosurtrusion in the frontal plane (Fig 4-15).

The wear resulting from these interferences affects the mediolateral inclines of mandibular or maxillary molars predominantly in areas characterized by a cusp to fossa relationship such as the central groove of maxillary and mandibular molars. This is best visualized in natural unworn dentitions (Fig 4-16). In good occlusal schemes this occlusal wear is irrelevant but it may reach a pathological level with a decrease of the anterior interocclusal angle.

Under these conditions the introduction of a restoration in these areas may reveal itself detrimental to marginal material integrity as interocclusal contacts and margin location are often coincidental. The integrity of the porcelain-bonded restoration can even be compromised when mesial or distal transitional zones of tooth preparation present a too-abrupt angulation (Fig 4-17).

Clinical observation shows that porcelain-bonded restoration fracture rate increases precisely in the mesial part of maxillary molars and in the distal part of mandibular molars in occlusal schemes showing poor canine guidance. These elements need a configuration of posterior porcelain-bonded restoration with sufficient material thickness and suggest coverage of mediolateral cusps designed with a reduction of the inclination of the mediolateral slopes and a reduction of the MO or OD transitional angle.

WWW.HIGHDENT.IR
همیار دندانسازان و دندانپزشکان

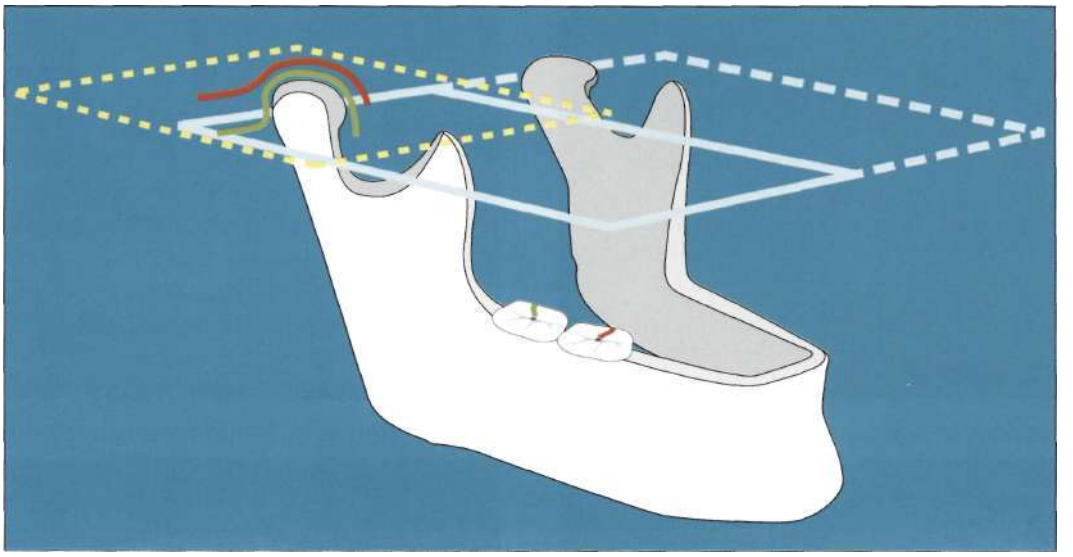

Fig 4-14 Pantographic tracing has demonstrated that in an occlusion provided with poor anterior relationships, the Bennet shift influences, in its horizontal tracing, the direction of the lingual groove of mandibular molars on the working side. However, in the late phase of closing patterns and in areas where cusp to fossa relationships can be found, a latero-protrusive Bennet pathway (green line) may generate the abrasion of the buccal incline of the lingual cusp of mandibular molar or lingual incline of maxillary buccal cusp due to the action of antagonist cusp. This suggests that porcelain-bonded restoration marginal integrity could be affected when placed in these locations and underthese conditions. When good anterior relationships do exist, the influence of the Bennet shift on the horizontal plane is irrelevant.

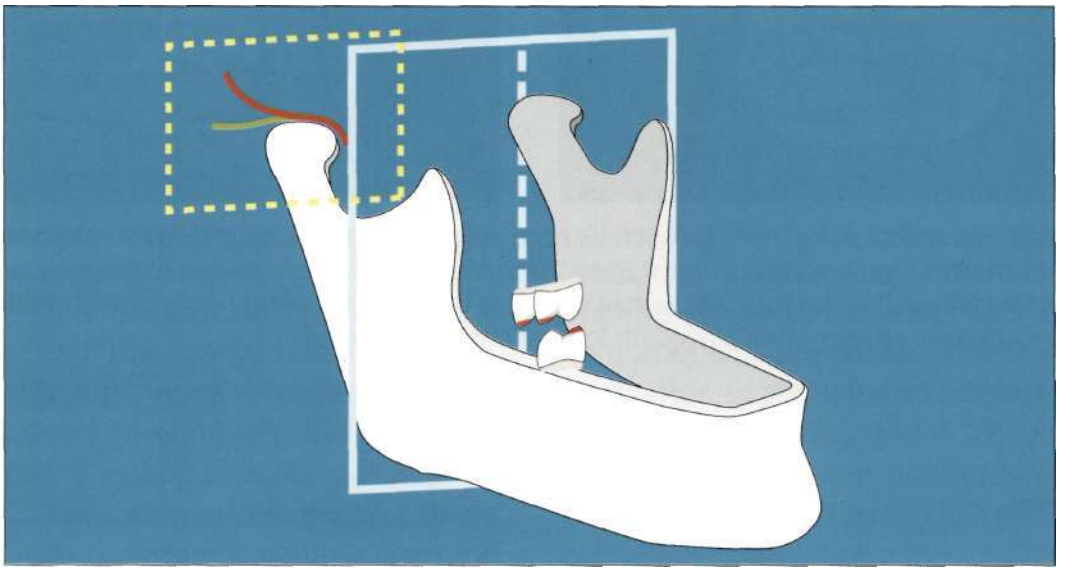

Fig 4-15 In the late phase of lateral chewing, to avoid the combined detrimental impacts of a Bennet shift showing not only a lateroprotrusion in the horizontal plane but also a laterosurtrusion in the frontal plane (red line), it could be helpful systematically to design the restoration with a more open mediolateral incline of maxillary buccal cusps or conversely mandibular lingual cusps, whatever the degree of guidance steepness. When applied to the maxillary posterior buccal cusps, this measure will highly improve the perception of the front-back progression.

WWW.HIGHDENT.IR
همیار دندانسازان و دندانپزشکان

Fig 4-16 In functionally good occlusal schemes and in areas where cusp to fossa relationships do exist, wear-faceting affecting the mediolateral incline of maxillary buccal cusps, conversely mandibular lingual cusp, can be observed. It states that a steep vertical guidance cannot totally negate the path of the shifting condyle in the late phase of lateral chewing especially when it presents both a horizontal lateroprotrusion and a frontal laterosurtrusion.

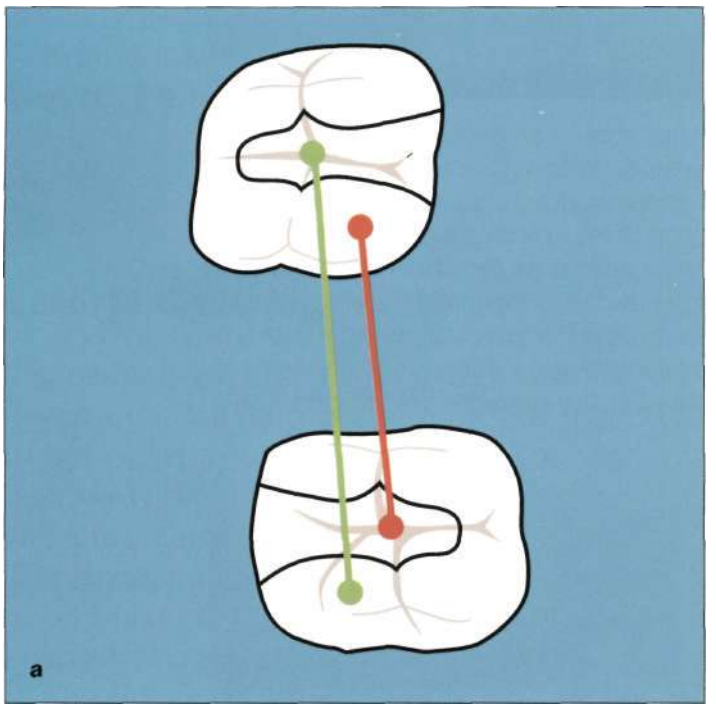

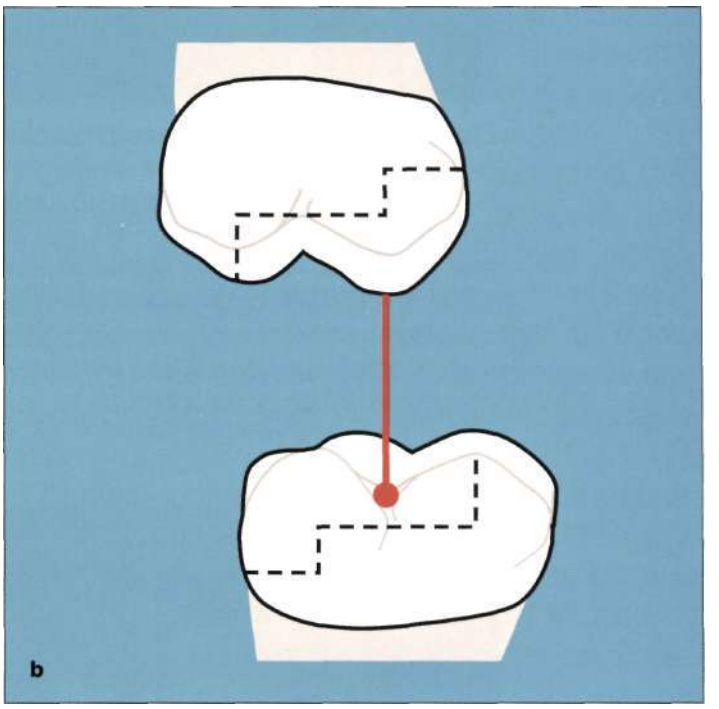

Fig 4-17a, b Constraining occlusal conditions such as poor anterior guidance cusp to fossa relationships, (a) Specific and individual TMJ morphology may affect the integrity porcelain-bonded inlays placed in strategic areas when weakened by too abrupt transitional zones, (b) Fracture rate seems to take place predominantly at the transitional zone of OD mandibular and MO maxillary inlays when placed on the first or second molar.

Dysfunction

The observation of unworn long-lasting dentitions has put in evidence harmonious relationships between skeletal and dental morphology and integrated function. It has long been speculated that abnormal function is mainly caused by abnormal tooth guidance. In turn, abnormal tooth guidance results from abnormal occlusal contact relationships.

We know that one out patient out of five does not have an incisal pathway reflecting an appropriate standard. Yet we can observe daily that out of the remaining patients reflecting appropriate standards in anterior pathways, few show or will show over the years an occlusal scheme free of wearing manifestations.

It can therefore be deduced from these observations that even appropriate standards in anterior pathways can display abnormal occlusal guid-

WWW.HIGHDENT.IR
همیار دندانسازان و دندانپزشکان

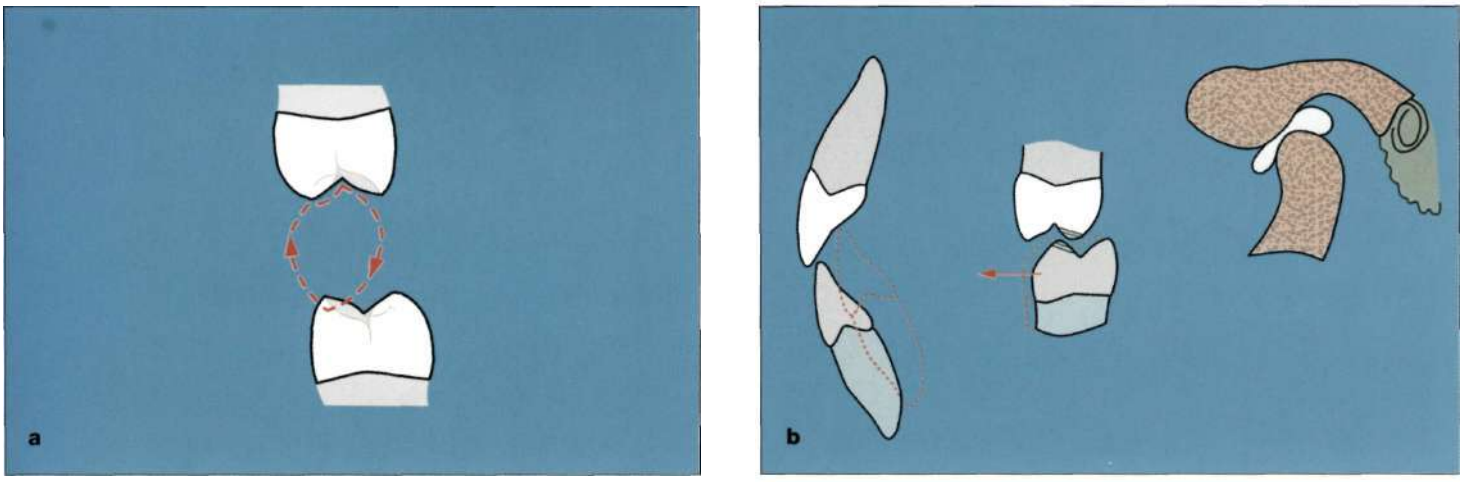

Fig 4-18a, b Frontal representation of a centric interference located in the mediolateral incline of a molar with lateral slide to centric, (a) Sagittal representation of interference leading to protrusive sliding during tooth closing patterns. (b) These types of interference can be easily eliminated by grinding.

ance. Submitted to registration these elements of abnormal guidance have been classified in a recent study in lack of guidance, poor guidance, overguidance, abnormal guidance, and interference.[46]

The presence of interferences in the development of tooth closure patterns has long been identified as the prime element of dysfunction. It has been even assumed that it could be at the origin of bruxism. There are two basic types of interferences:

- centric relation : anterior slide, lateral slide, protrusive-retrusive
- lateral border: non working and working side.

The elimination of centric interferences in the treatment of bruxism has always been controversial. In 1928, *Tischter* recommended occlusal adjustment in order to eliminate the so called "trigger contacts".[47] A large number of authors stress also the importance of eliminating these interferences in the treatment of bruxism,[48-50] while others deny any relationship between interferences and bruxism.[51] It appears, however, that clinically experienced practitioners never hesitate to proceed to occlusal correction before restorative procedure[52-60] by reason of the good results they obtained.

Dawson (1998) has written: "It is my experience that, when all occlusal interferences in centric relation and excursions have been eliminated on the posterior teeth, parafunctional movements resulting in anterior wear are eliminated or reduced to a point where they are of no clinical concern." His statement gives the restorative dentist the best reasons to proceed to occlusal controls, not only before restorative procedures but also following porcelain-bonded restoration placement, to eliminate the interferences that were either present or could have been introduced with new restorations.

This post bonding control is made necessary because of the great difficulty in appreciating before bonding porcelain-bonded restorations, the occlusal parameters because of the risks of fracture. Aside from interocclusal overcontacts in centric occlusion, centric interferences - lateral or anterior - can be found on posterior porcelain-bonded restorations (Fig 4-18), while protrusive-retrusive interferences are systematically present on anterior porcelain-bonded restorations, especially those showing a configuration with a palatal extension (Figs 4-7 and 4-8).

Clinical observation shows, however, that contrary to *Dawson's* statement, parafunctional habits can then be reduced to a point where they are of no clinical concern when both centric interferences have been eliminated and anterior guidance steepness has been concomitantly increased.

WWW.HIGHDENT.IR
همیار دندانسازان و دندانپزشکان

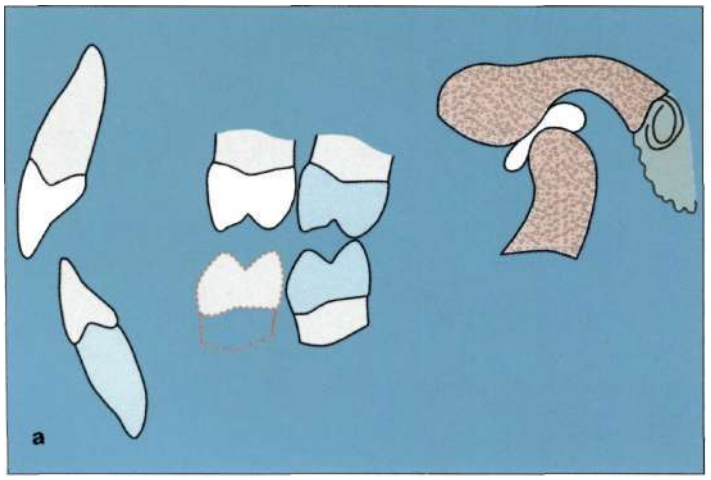

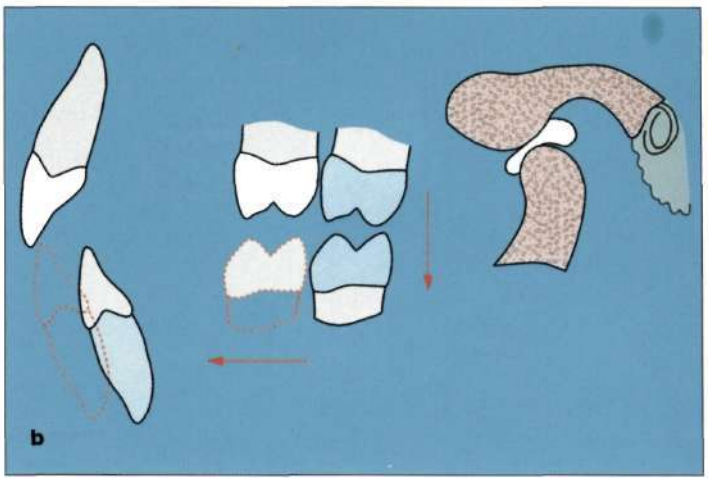

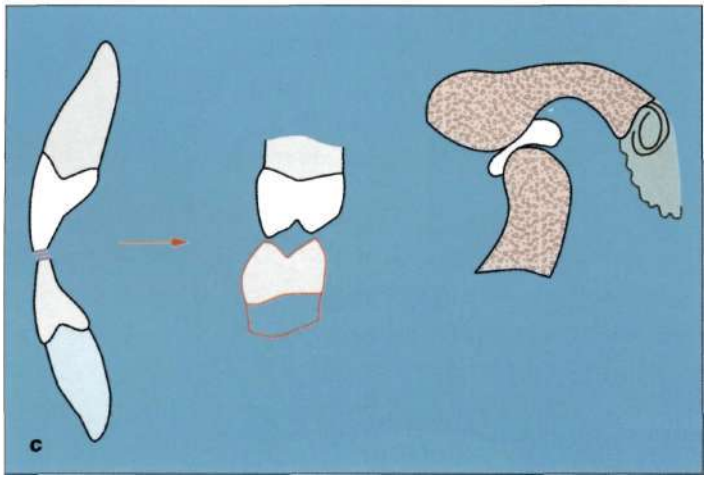

Fig 4-19a-c When an eccentric interference takes place in unusual mandibular positions (a). It generates a neuromuscular reflex action causing the mandible to avoid the prematurity with a pivoting movement, followed by a projection of the mandible against maxillary incisors (b). This back-and-forth movement progressively erases incisors or canines, reducing the posterior clearance in eccentric occlusion until wear progressively starts affecting posterior tooth morphology (c).

Indeed, nothing else but this increase of anterior guidance steepness can prevent possibilities of posterior eccentric interferences that may take place in the area of mandibular motion, clinically undetectable but made possible by increased muscle and ligament laxness, pillow or hang pressure. These interferences also can be the initiator of parafunctional movements.

Occlusal schemes showing moderate but apparently sufficient posterior clearance in eccentric occlusions must be looked at with suspicious eyes, especially those presenting deficiencies in tooth alignment. They open the possibility of unexpected eccentric contacts generator of avoidance patterns leading in an initial phase to the erosion of the elements of the anterior segment.

The rotation of the mandible around a posterior obstacle followed by a mandibular projection against the maxillary incisors has been observed in clinical tests, and the follow-up of muscles participation clearly described[61,62] (Fig 4-18). It has even been demonstrated that parafunctional avoidance patterns could not only project the mandible against maxillary incisors but be moved outside the confine of the maxilla[63-66] - that is to say in a cross-over position. This uncontrolled back and forth movement will progressively erase antagonist anterior teeth whose progressive morphological reduction will finally permit posterior contact, and posterior wear faceting (Fig 4-19).

As a consequence, the set-up of veneers, that is to say porcelain-bonded restoration, covering the facial part of the tooth and provided with a reduced palatal overlap, is restricted to occlusal schemes showing a total absence of faceting (Fig 4-20). The presence of wear faceting in the occlusal scheme (it could be a simple chipping, a localized or generalized chevron-shape anterior wear), requires a modification of veneer configuration with the design of either an elongated

WWW.HIGHDENT.IR
همیار دندانسازان و دندانپزشکان

Fig 4-20a, b When porcelain-bonded restoration is only used to improve anterior esthetics, careful attention must be paid that the newly designed prosthesis does not interfere with neurologically programmed tooth-closure patterns. Initial situation (a) and following the restoration of maxillary incisors (b).

Fig 4-21 a, b A full mouth restoration of a worn-out dentition should duplicate the parameters found in long-lasting unworn dentitions to ascertain occlusal maintenance and function, (a) Initial situation in centric occlusion, (b) Interocclusal relationships following restoration with porcelain-bonded restoration.

porcelain-bonded restoration or a porcelain-bonded restoration with a palatal extension, provided an increase of anterior guidance can be achieved to prevent any possibility of posterior interference in eccentric occlusions (Fig 4-21).

Conclusion

The predictability of any restorative process rests on the precise evaluation of oral and occlusal conditions. Porcelain veneer restorations can be considered as ideal restorations for the corrections of poor anterior relationships and anterio-guidance. Conversely, they can also be destructive for the dentition when occlusal conditions have been neglected or wrongly appraised.

WWW.HIGHDENT.IR
همیار دندانسازان و دندانپزشکان

References

1. Kreulen CM, Creugers NH, Meijring AC. Meta-analysis of anterior veneer restorations in clinical studies. J Dent 1998;26:345-353.
2. Andreasen FM, Flugger E. Daugaard-Jensen J, Munksgaard EC. Treatment of crown fractured incisors with laminate veneer restorations. An experimental study. Endod DentTraumatol 1992;8:30-35.
3. Munksgaard EC, Hojtved L, Jorgensen EH, Andreasen JO, Andreasen FM. Enamel-dentin crown fractures bonded with various bonding agents Endod Den Traumatol 1991; 7:73-77.
4. Stokes AAN, Hood JAA. Impact fracture characteristics of intact and crowned human central incisors. J Oral Rehabil 1993;20:89-95.
5. Andreasen FM, Daugard-Jensen J, Munksgaard EC. Reinforcement of bonded crown fractured incisors with porcelain veneers. Endod DentTraumatol 1991;7:78-83.
6. Magne P, Anthennis Versluis, Douglas WH. Rationalization of incisor shape: Experimental-numerical analysis. J Prosthetic Dent 1999;81:345-354.
7. Magne P, Douglas WH. Design opimization and evolution of bonded ceramics for the anterior dentition: A finite-element analysis. Quintessence Int. 1999;30:661-672.
8. Magne P. Douglas WH. Rationalization of esthetic restorative dentistry based on biomimetics. J Esthet Dent 1999;11:5-15.
9. Reek ES, Ross K. Tooth stiffness with composite veneer: A strain gauge and finite element evaluation. Dent Mater 1994;10:247-252.
10. Highton RM, Caputo AA, Matyas J. A protoelastic study of stress on porcelain laminate preparations. J Prosthetic Dent 1987;58:157-161.
11. Magne P, Douglas WH. Optimization and stress distribution in porcelain veneers for the treatment of crown-fractured incisors. Int J Periodontics Restorative Dent 1999;19: 543-553.
12. Magne P. Douglas WH. Additive contour of porcelain veneers: A key element in enamel preservation, adhesion and esthetics. J Adhesive Dent 1999;1:81-92.
13. Gordon JE. Strain energy and modern fracture mechanics. In: Gordon JE (Ed.). Structures or Why Things Don't Fall Down. New-York: Da Capo, 1978:70-89.
14. Fradeani M. Six years follow-up with Empress veneers. Int J Periodontics Restorative Dent 1998;18:216-225.
15. Peumans M, Van Meerbeek B, Lambrechts P, Vuylsteke-Wauters M, Vanherle G. Five-year clinical performance of porcelain veneers. Quintessence Int 1998;29:211-221.
16. Van Gogswaart DC, Van Thoor W, Lampert W. Clinical assessment of adhesively placed ceramic veneers after 9 years. (Abstract 1, 1978) J Dent Rest 1998;77:779.
17. CalamiaJR. Clinical evaluation of etched porcelain veneers. Am J Dent 1989;2:9-15.
18. Calamia JR. The current states of etched porcelain veneers. J Ind Dent Assoc 1993;72:10-15.
19. Rucker ML, Richter W, Macentee M, Richardson A. Porcelain and resin veneers clinically evaluated: 2-years result. J Am Dent Assoc 1990;121:594-596.
20. Walls AW. The use of adhesively retained all porcelain veneers during the management of fractured and worn out anterior teeth. Part 1. Clinical technique. Br Dent J 1995;178:333-336.
21. Walls AW. The use of adhesively retained all porcelain veneers during the management of fractured and worn out anterior teeth. Part 2. Clinical results after 5 years of follow-up. Br. Dent J 1995;178:337-340.
22. Belser U, Magne P, Magne M. Ceramic laminate veneers: Continuous evolution of indications. J Esth Dent. 1997; 9:209-219.
23. Magne P, Magne M, Belser U. Natural and restorative oral esthetics. Part 2. Esthetic treatment modalities. J Esth Dent 1993;5:239-246.
24. Pashley DH, Pashley EL. Dentin permeability and restorative dentistry: A status report for the American Journal of Dentistry. Am J Dent 1991 ;4:5-9.
25. Pashley DH. Smear layer: Physiological considerations. Op. DentSuppl 1984;3:13-29.
26. Britton GL, Moon PC, Barnes RF, Gunsolley JC. Effect of preparation cleaning procedures on crown retention. J Prosthetic. Dent 1988;59:145-148.
27. Mizusma T Relationship between bond strength of resin to dentin and structural change of dentin collagen during etching. Influence of ferric chloride to structure of the collagen J Jpn Soc Dent Mater 1992;5:54-64.
28. Wang T, Nakabayashi N, Takarada, K. Effect of HEMA on bonding to dentin. Dent Mater 1992;8:125-130.
29. Nakabayashi N. Adhesive bonding with 4-META. Oper Dent 1992;Suppl. 5:125-130.
30. Lee R. Esthetics and its relationship to function. In: Rufenacht CR. Fundamentals of Esthetics. Chicago: Quintessence, 1990:137-210.
31. Castellani O. Elements of Occlusion. Bologna: Ed Martina, 2000.
32. MacDonald JWC, Hannan A. Relationships between occlusal contacts and jaw-closing muscle activity during tooth clenching. Part 1. J. Prosthetic Dent 1984;52:718-728.
33. Magne P, Perroud R, Hodges JS, Belser U. Clinical performance of Novel Design porcelain veneers for the recovery of coronal volume and length. Int J Periodontics Restorative Dent. 2000;20:441-457.
34. Graf H, Lander HA, Tooth contact patterns in mastication. J Prosthet Dent 1963;13:1055-1066.
35. Scharer P, Stalland RE. The use of multiple radio-transmitters in studies of tooth contact patterns. Periodontics 1965;3:5-9.
36. Parmejier JHN, Glickman I, Roeber FU. Intraoral occlusal telemetry. Part 2. Registration of tooth contacts in chewing and allowing. J Prosthetic Dent 1978;39:569-573.
37. Ramfjord S, Ash M. Occlusion. 2nd ed. Philadelphia: WB Saunders, 1971.

WWW.HIGHDENT.IR
همیار دندانسازان و دندانپزشکان

38. Manns A, Chan C, Miralles R. Interference of group function and canine guidance on electromyographic activity of elevators muscles. J Prosthetic Dent 1987;57:494-500.
39. Williamson EH, Lundquist DO. Anterior guidance: Its effects on electromyographic activity of the temporal and masseter muscles. J. Prosthet Dent 1983;47:816-823.
40. Kelly JE, Sanchez M, Van Kirk LE. An assessment of the occlusion of teeth of children. (Data from the National Health Survey: DHEW Publication No (HRA) 74-1612) National Centerfor Health Statistics: US Public Health Service, 1973.
41. Weinberg LA, Kruger BA. A comparison of implant/prosthesis loading with four clinical variables Int. J. Prosthodontic 1995;8:421-433.
42. Williams WN, Low SB, Cooper WR, et al. The effect of periodontal bone loss on bite force discrimination. J Periodontal 1987;58:236-239.
43. Munechika T, Suzuki K, Nishiyama M, Ohashi M, Horie A. A comparison of the tensile bond strenghts of composite resins to longitudinal and transverse sections of enamel prisms in human teeth. J Dent Res 1984;63:1079-1082.
44. Verluis A, Tantbirojn D, Douglas WH. Why do shear bond tests pull dentin. J Dent Rest 1997;76:1298-1307
45. Bennet NG. A contribution to the study of the movements ofthemandibule. Proc Roy Soc Med. 1908;1:79-95.
46. Mayurama T. Esthetics: Occlusion and function. J Esth. Dent 1994;6:296-299.
47 Tieshler B. Occlusal habit neuroses. The importance of eliminating these interferences in the treatment of bruxism. Dental Cosmos 1928;70:690.
48. Ramfjord SP. Bruxism. A clinical and electromyographic study. J. Am Dent Assoc 1961 ;62:21.
49. Jenkelson, B. Physiology of human dental occlusion. J am Dent Assoc 1955;50:664.
50. Dawson PE. Evaluation, diagnosis and treatment of occlusal problems. St Louis, MO: Mosby, 1974:103.
51. Robinson JE, Reding G. Zeplin H, Smith UH, Zimmerman SO. Noctural teeth grinding: A reassesment for dentistry. J Am Dent Assoc 1969;78:1308.
52. Krough-Poulson WG, Olson A. Management of the occlusion of the teeth. In: Schwartz L, Chayes CM (Eds.) Facial Pain and Mandibular Dysfunction. Philadelphia: WB Saunders, 1968.
53. Schuylen, CH. Correction of occlusal disharmony, natural and artificial. J Am Dent Assoc 1935;22:1193.
54. Sorin S. Traumatic occlusion. Its detection and correction. Dent Digest 1934:170.
55. Sorin S. Traumatic occlusal and occlusal equilibration. J Am Dent Assoc 1958;57:477.
56. McHorris, WH. Occlusal adjustment via selective cutting of natural teeth. Part 1. Int J Periodontics Rest Dent 1985; 5:9.
57 McHorris WH. Occlusal adjustment via selective cutting of nature teeth. Part 2. Int J Periodontics Rest. Dent 1985; 5:9.
58. Ross IF. Coronal Reshaping. Alpha Omega 1985;73:35.
59. Arnold NR, FrumkerSC. Occlusal Treatment. Philadelphia, PA: Lea and Febiger, 1976:37-134.
60. Lauritzen AG. Function, prime object of restorative dentistry. A definite procedure to obtain it. J Am Dent Assoc 1951;42:523.
61. Assal J. Basculement mandibulaire provoque par une surelevation des dents posterieures: Etude anatomique et electromyographique. Rev mens Suisse odonto-stomatol 1998;98:459-464.
62. Assal J. Modification de la position de la mandibule chez l'adulte suite a une surelevation des dents posterieures. Rev mens Suisse odonto-stomatol 1986;9:1022-1037
63. Tanner. Personal communication 28 January 1999.
64. Wilson R. Harmonious anterior guidance in the crossover position. Presented at the Academy of Restorative Dentistry, Chicago, 25 February 1996.
65. Lytle JD. Occlusal disease revisited. Part 1. Function and parafunction Int J Periodontics Restorative Dent 2001; 21:265-271.
66. Lytle JD. Occlusal disease revisited : Part 2. Int J Periodontics Restorative Dent 2001 ;21:272-279.

WWW.HIGHDENT.IR
همیار دندانسازان و دندانپزشکان

5 Color

Stephen J. Chu

Introduction

Color is a language. Understanding color requires learning the language of color. It is frequently spoken, but often miscommunicated. Effectively to overcome the challenges associated with shade selection in esthetic restorative dentistry, it is essential to learn the science and art of color. It is a difficult task, because color is an abstract subject matter, intertwined with visual and scientific components. Compounding the dilemma is the inability of the human eye to perceive color in a clear, concise, and consistent manner. Individual differences in color perception may vary, since the eye is not the most reliable means for color analysis.

The inconsistent results in shade tab fabrication from a color control perspective were identified in the early 1900s, and the efforts of the clinicians are adequately presented in the literature.[1–10] Attention to this challenge was intensified in the 1980s[11–18] and has continued to the present time.[19–39] The emphasis has also been on close cooperation between the clinician and the laboratory technician and the development of new restorative materials[40–61] and dental adhesives.[62–68] Innovative restorative materials have enabled the clinician to enhance the vitality and translucency of dental restorations. Adhesive dentistry has maximized the strength of all-ceramic restorations while maintaining optimal color and translucency. A beautiful smile is no longer considered as a luxury but rather as an essential component in the current lifestyle.

WWW.HIGHDENT.IR
همیار دندانسازان و دندانپزشکان

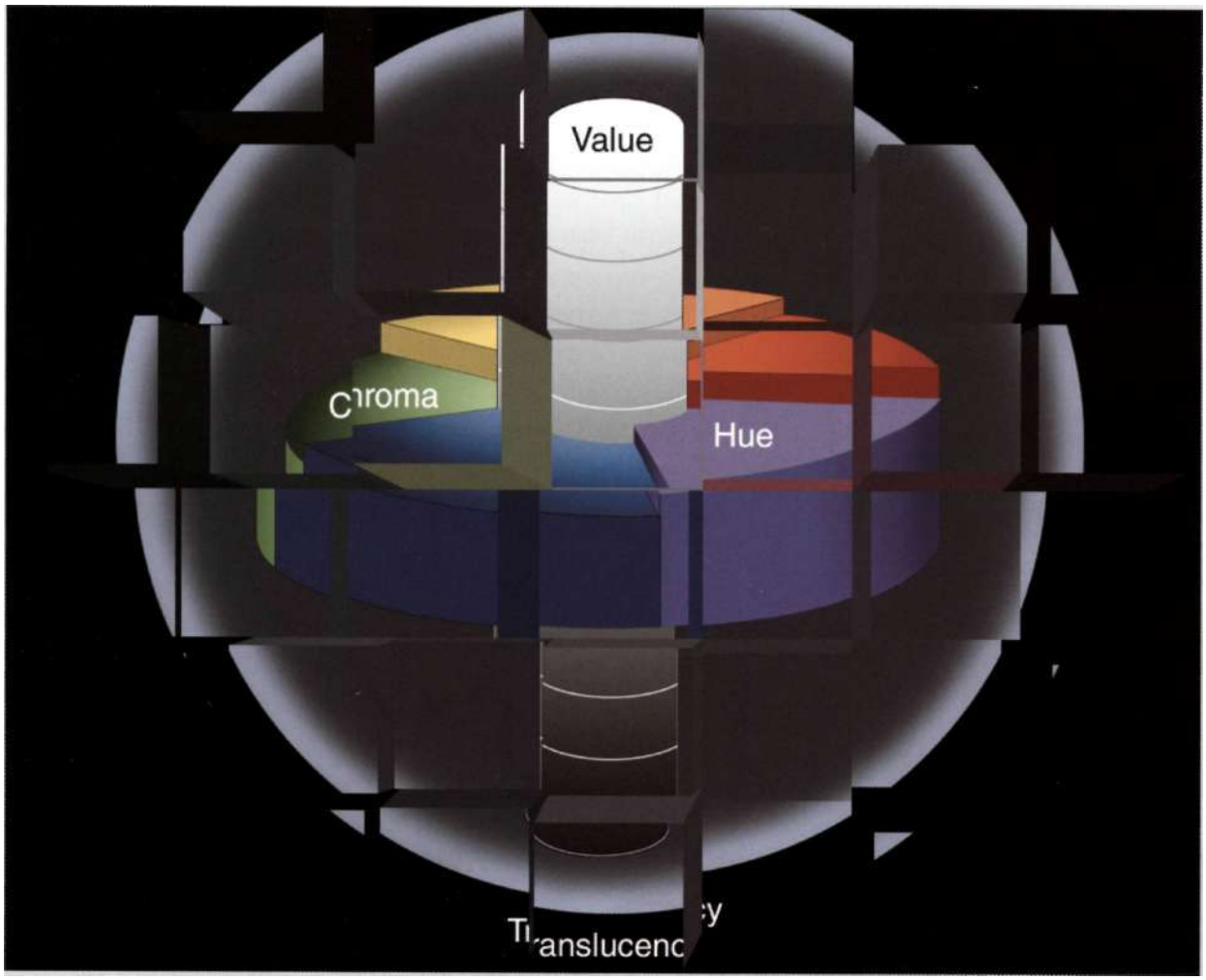

WWW.HIGHDENT.IR
همیار دندانسازان و دندانپزشکان

The ultimate test of an esthetically pleasing anterior restoration is the achievement of a natural visual appearance and function. The final results must satisfy the expectations of the clinician and the patient. Such results can be achieved only when the following prerequisites have been met:

1. The clinician has mastered the art and science of color treatment planning, including the correct color and shade selection for each patient.
2. The clinician has correctly communicated his treatment plan and shadeselectionstothe dental laboratory.
3. The laboratory technician has correctly interpreted the received information and successfully combined materials in the fabrication process to produce an unobtrusive restoration with natural appearance.

The shade selection process, however, has become more complex, owing to the variations and differences in optical properties of the new generation of cosmetic restorative materials. The shade determination comprises five distinct parameters, which must be satisfied in order to achieve a predictable esthetic outcome:

1. analysis
2. communication
3. interpretation
4. fabrication
5. verification.

The challenges associated with shade selection in dentistry were first identified in 1931 by *Clark,* who described them in the literature.[1-3] *Preston* and *Bergen*^ demonstrated the importance of selecting the appropriate quality and quantity of lighting for unbiased shade selection. They also identified the deficiencies in accuracy and consistency of shade tab fabrication. Subsequently, these efforts were further reinforced through the work of *Sproull*[4-7] and *Miller,*^[5] who proved that discrepancies existed between the shades of natural dentition and the popular shade guide systems. Numerous other authors, including *Bergen,*^[0] *Munsell,*[8] *Sorensen,*[58] *Yamamoto,*^[4] and *Ubassy*[16] contributed to the literature on inadequacy of conventional shade selection systems owing to their subjectivity.

The latest innovative effort in the achievement of optimal shade selection has been the development of technology-based shade guide systems; several effective shade selection systems are currently available. A subjective or an objective approach to color treatment planning is now available to the clinician. The subjective approach - the use of shade tabs - is the most common practice and contains uncertainties owing to the human factors surrounding the perception of color. The objective approach - technology-based computer imaging and analysis - overcomes many of the human factors. It requires levels of skill and familiarity with the equipment that are not widespread in either prosthodontics or general dentistry. Additional challenges may arise if the practitioner has limited knowledge of materials and their properties or if the laboratory technician lacks experience in working directly with the patients.

The clinical importance of correct shade selection in esthetic dentistry cannot be overemphasized. Unless an appropriate shade is selected, the most careful attention to the material, structure, and other aspects of the restoration will not produce an optimal final result. The purpose of this chapter is to provide an overview of the key issues involved in achieving optimal results in color determination and shade matching for all types of restorations requiring color analysis.

Color

Dimensions of Color

Understanding color requires comprehension of the dimensions of color, i.e. its hue, chroma, value, and translucency. Translucency is not addressed in *Munsell's* color analysis (Fig 5-1),[8] but it may be the single most important factor in the ultimate result of an esthetic restoration. When restorations are labeled as too opaque, marble-like, or dead in appearance, the esthetic limitation is generally the result of inadequate reproduction of translucency. Translucency, in effect, is the three-dimensional spatial relationship or representation of value.

WWW.HIGHDENT.IR
همیار دندانسازان و دندانپزشکان

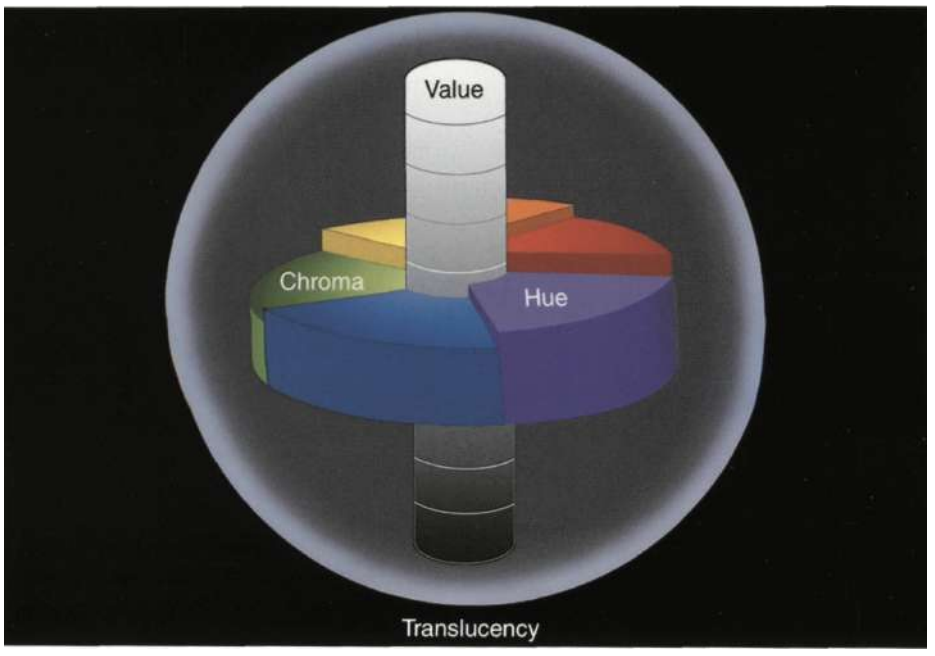

Fig 5-1 *Munsell's* color analysis modified (A Grammar of Color), identifying the four parameters: hue, chroma, value, and translucency.

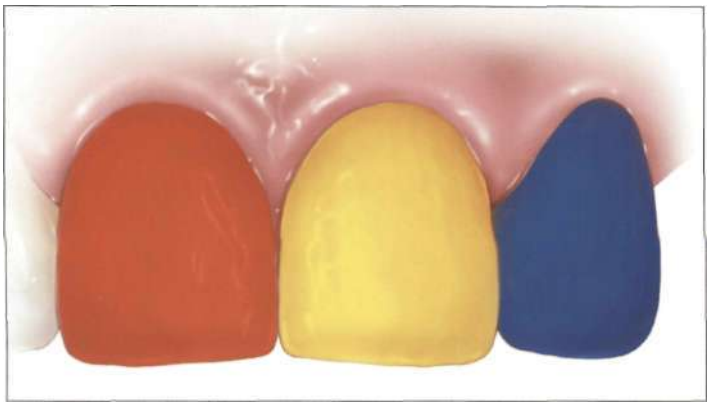

Fig 5-2 Hue is simply color tone, i.e. red, blue, yellow, etc.

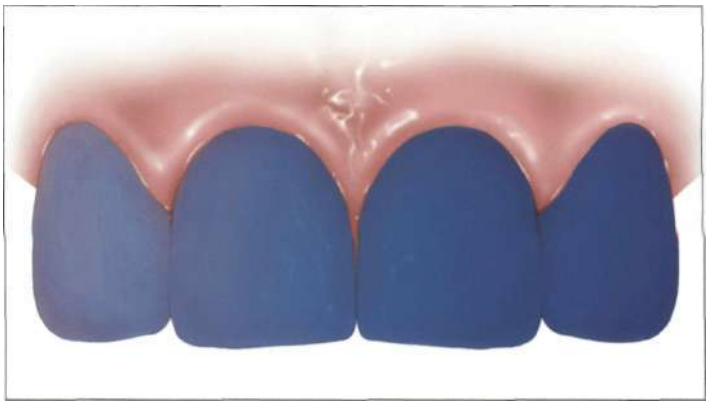

Fig 5-3 Chroma is the intensity or saturation of the color tone (hue), i.e. light blue, dark blue, etc. Chroma increases from tooth #7 (less chromatic) to tooth #10 (more chromatic).

Fig 5-4 Value is the relative lightness (brightness) or darkness of the hue. Tooth #7 is higher in value (lighter); tooth #10 is lower in value (darker).

Fig 5-5 Translucency is the three-dimensional representation of value.

WWW.HIGHDENT.IR
همیار دندانسازان و دندانپزشکان

Fig 5-6 Highly translucent teeth tend to be lower in value, since they allow lighttotransmitthrough the tooth and pick up the shadows and darkness of the oral cavity and the surrounding environment.

Fig 5-7 More opaque teeth allow less light transmittance; they are more reflective in nature and, therefore, appear brighter.

Fig 5-8 The opaque, dead appearance of a restoration should be avoided. Metal-ceramic crowns #8 and 9.

Fig 5-9 The goal of an optimal restoration is to achieve the natural appearance of the tooth. Metal ceramic crowns #8 and 9.

Hue is simply the color tone, i.e. red, blue, yellow, etc. (Fig 5-2). The term "hue" is synonymous with the term "color", and it is used to describe the color of a tooth or dental restoration. Chroma isthe intensity or saturation of the colortone (hue), i.e. light blue or dark blue (Fig 5-3). It is used to describe, for instance, the orange or yellow hue of a tooth or a restoration. Value is the relative lightness (brightness) or darkness of the hue (Fig 5-4). Translucency is the three-dimensional representation of value (Fig 5-5). Translucency is abstract and intangible, and it is difficult to measure and standardize at the present time. Translucency is best represented by value differences. Highly translucent teeth tend to be lower in value, since they allow light to transmit through the tooth (greater light absorption) and absorb the shadows and darkness of the oral cavity and surrounding environment (Fig 5-6). More opaque teeth allow less light transmittance; they are more reflective in nature and, therefore, appear brighter (Fig *5-7).* The characteristic of translucency must also be present in the restorative materials in order to achieve a natural appearance and avoid the opaque, dead-in-appearance restorations (Figs 5-8 and 5-9). Translucency and value are the

WWW.HIGHDENT.IR
همیار دندانسازان و دندانپزشکان

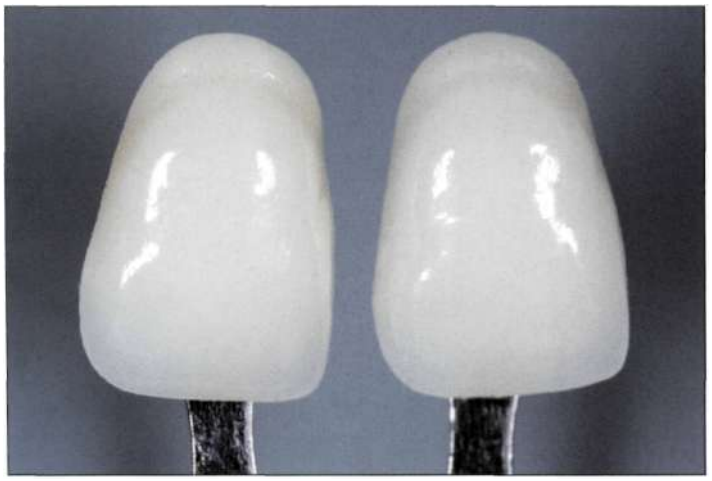

Fig 5-10 Translucency/value are the most important parameters in shade selection, since hue is not easily detectable and there is a lack of chroma in the lighter shades (A1 tab is on the left, B1 tab on the right).

most important characteristics in shade selection, since hue is not easily detectable, and since there is a lack of chroma in the lighter shades (e.g. A1, B1, Fig 5-10).

Value differences are easier to identify, since there are more rods than cones in the anatomy of the human eye. There is an inverse relationship between chroma and value. With increasing chroma (greater intensity) there is decreasing value (increasing darkness, Table 5-1). For instance, A4 has a high chroma and low value shade; A1 has a low chroma and a high value shade.

Spectral Colors

Spectral colors are the colors of light in the visible light spectrum. Even though white light appears colorless and intangible, it is formed by distinct electromagnetic energy. When light passes through a prism (Sir *Isaac Newton,* 1676), it is refracted, and the light energy is dispersed intothe various wavelengths of white light -hence the acronym ROY G BIV, i.e. red, orange, yellow, green, blue, indigo, violet (Fig 5-11). After a rain shower, we often see a rainbow, since the water droplets in the sky act as miniature natural prisms. The color of the sky also appears different at various times of the day (Fig 5-12). The cones of

Table 5-1 Dimension of Color

Dimension of Color	Terminology
Hue	Color Tone
Chroma	Intensity of Saturation
Value	Relative Lightness/Darkness

Table 5-2 Wavelengths of Light

White Light	Wavelength (0.000001 mm)
Red	800-650
Orange	640-590
Yellow	580-550
Green	530-490
Blue	480-460
Indigo	450-440
Violet	430-390

the human eye can perceive only these wavelengths of light, hence the term "visible light spectrum". In physical terms, the wavelengths of visible light range from 390 to 800 microns (Table 5-2). Each hue is accurately defined by its wavelength or frequency (Fig 5-13).

Pigment Colors

In dentistry, we must understand pigment colors, since the restorative media (ceramics, composites, and acrylic resins) possess color. The interaction of colors has a role of critical importance in the esthetic continuum. A discussion of primary, secondary, and complementary colors is necessary in order to control and alter shades for a predictable esthetic restorative outcome (Table 5-3).

WWW.HIGHDENT.IR
همیار دندانسازان و دندانپزشکان



Fig 5-11 Light passing through a prism is refracted (Sir *Isaac Newton),* and the light energy is dispersed into various wavelengths of white light.

Fig 5-12 The color of the sky appears different at various times of the day.

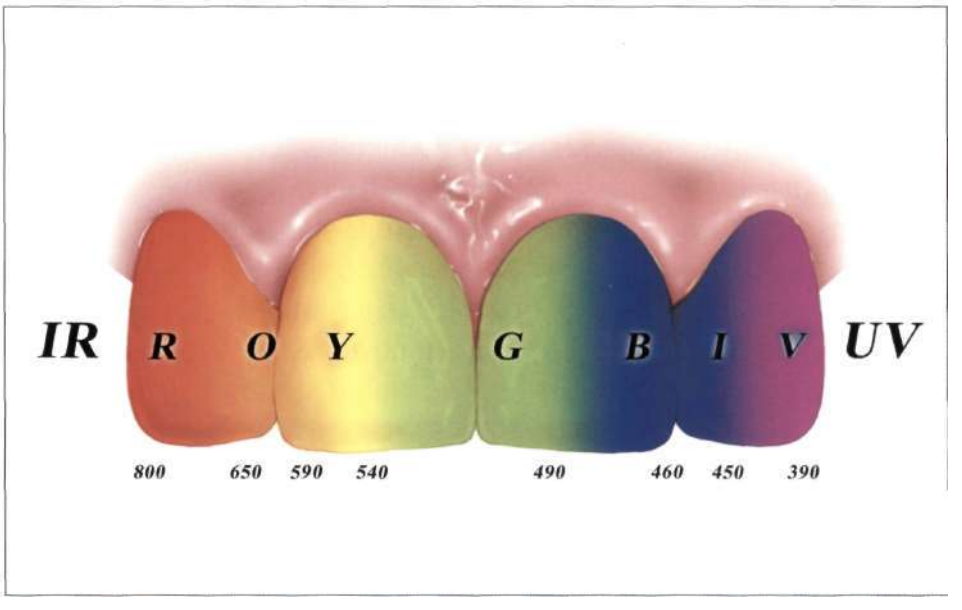

Fig 5-13 The wavelengths of visible light range from 390 to 800 microns. Each hue is accurately defined by its wavelength or frequency.

Key:

IR = infrared light
UV = ultraviolet light
R =red
0 = orange
Y = yellow
G = green
B = blue
1 = indigo
V = violet

WWW.HIGHDENT.IR
همیار دندانسازان و دندانپزشکان

Table 5-3 Complementary Colors

Primary Color	Secondary Color	Complementary Color
Red	Orange	Red-Green
Yellow	Green	Yellow-Violet
Blue	Violet	Blue-Orange



Fig 5-14 Primary colors: red, yellow, blue, occur naturally; they cannot be formed by mixing of other colors. Key: R=red; Y=yellow; B=blue.

Primary Colors

Primary colors - red, yellow, blue - are those that cannot be formed by mixing other colors; they occur naturally by themselves (Fig 5-14).

Secondary Colors

Secondary colors are formed by mixing primary colors: i.e. red + yellow = orange; yellow + blue = green; blue + red = violet (Fig 5-15).



Fig 5-15 Secondary colors: orange, green, violet, are formed by mixing primary colors; for example, red + yellow = orange.

Complementary Colors

Complementary colors look well together; they enhance the appearance of one another (Fig 5-16). When complementary colors are mixed together, they form the achromatic color gray (Fig 5-17).

The additive principle of complementary colors may be used to alter the value of restorations. For instance, if we want to lower the value (increase gray or darkness) of a restoration, the complementary color can be added to that hue (i.e. A3 shade contains: orange hue + blue stain = lower value). Adding gray stain to lowerthe value will only make the restoration look dull and unclean. Adding violet (purple) stain to a B shade (yellow hue) restoration will also appropriately lower the value. Therefore, adding the complementary color to a restoration will effectively alter the value. Conversely, raising the value of a restoration (increasing the brightness) cannot be managed with this modality.

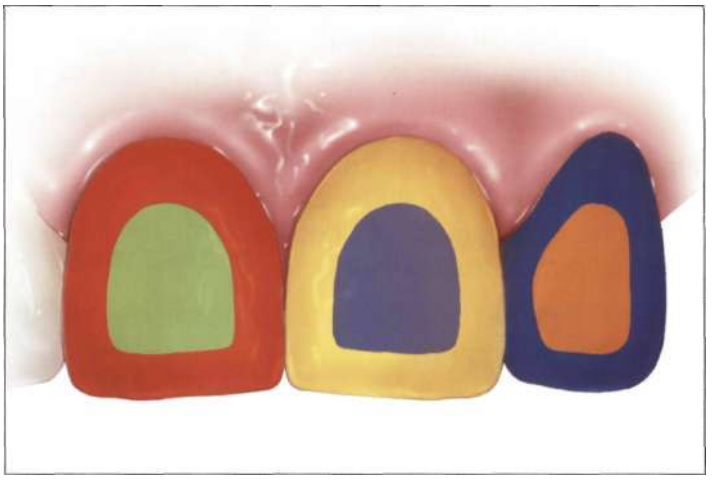

Fig 5-16 Complementary colors enhance the appearance of one another.

WWW.HIGHDENT.IR
همیار دندانسازان و دندانپزشکان



Fig 5-17 When complementary colors are mixed together, they neutralize one another, i.e. they form the achromatic color gray.

Color Perception

All objects exhibit color, such as white, black, red, purple, blue, yellow, etc. Color is perceived through absorption and reflection of the various wavelengths of visible light. For instance, a black object absorbs all the wavelengths of visible light completely (Fig 5-18), while a white object reflects all the wavelengths completely (Fig 5-19) A yellow object absorbs red, green, blue, indigo, and violet wavelengths of light and reflects orange (590-640 microns, Fig 5-20).

The light waves in themselves are not colored. Color arises in the human brain, with the cones in the eyes as the color receptors. Colors arise from qualitative differences in photosensitivity. The eye and the mind achieve distinct perception through comparison and contrast - a chromatic color (red, blue, green, etc.) may be determined by its relationship to an achromatic color (white, gray, and black, Figs 5-21 and 5-22). Color perception is the psychophysiological reality of color (Table 5-4).

Individual Differences in Color Perception

Even though an object may irradiate light with a consistent distribution spectrum, the perception of color may vary markedly between individuals. Table 5-5 presents the results of a study by *Nakagawa, Maruyama,* and *Shimofusa* (1975)[9,10] on individual color perception. Three dentists were asked to select a shade for a prosthesis and the adjacent natural teeth, using the conventional shade guide tabs. No dentists were in agreement 34% of the time; two dentists were in agreement 52% of the time, and only 14% of the time were all three dentists in agreement. Therefore, in 86% of the cases, all three dentists could not agree on the same shade. These figures clearly demonstrate a great divergence in visual shade selection with negative clinical predictability. Sources of error commonly originate from disparities in the shade selection environment, which influences color perception considerably. Shade determination under the same light source and positional relationship can eliminate such errors in individual color perception.

WWW.HIGHDENT.IR
همیار دندانسازان و دندانپزشکان

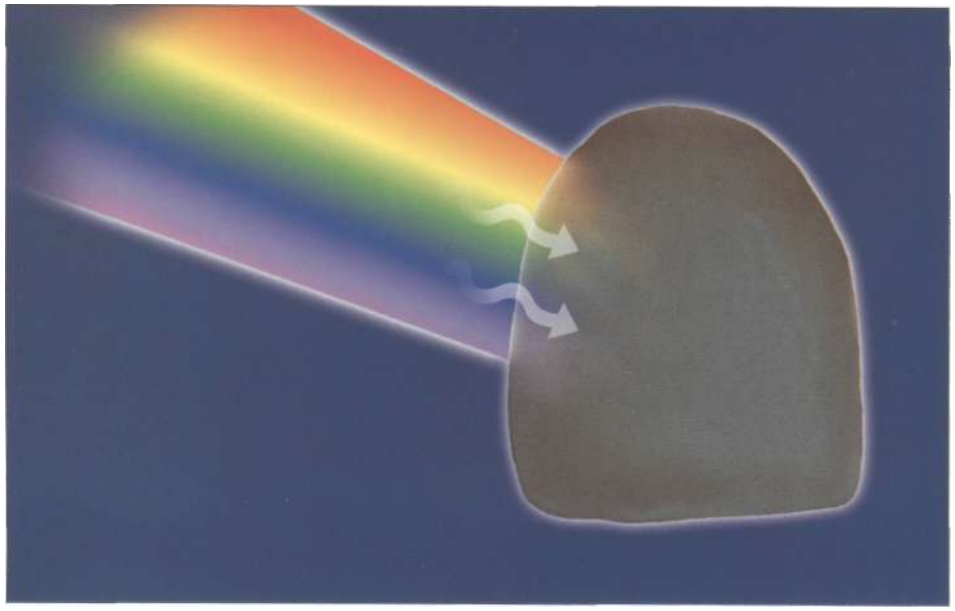

Fig 5-18 A black object or surface completely absorbs all the wavelengths of visible light.



Fig 5-19 A white object or surface completely reflects all the wavelengths.

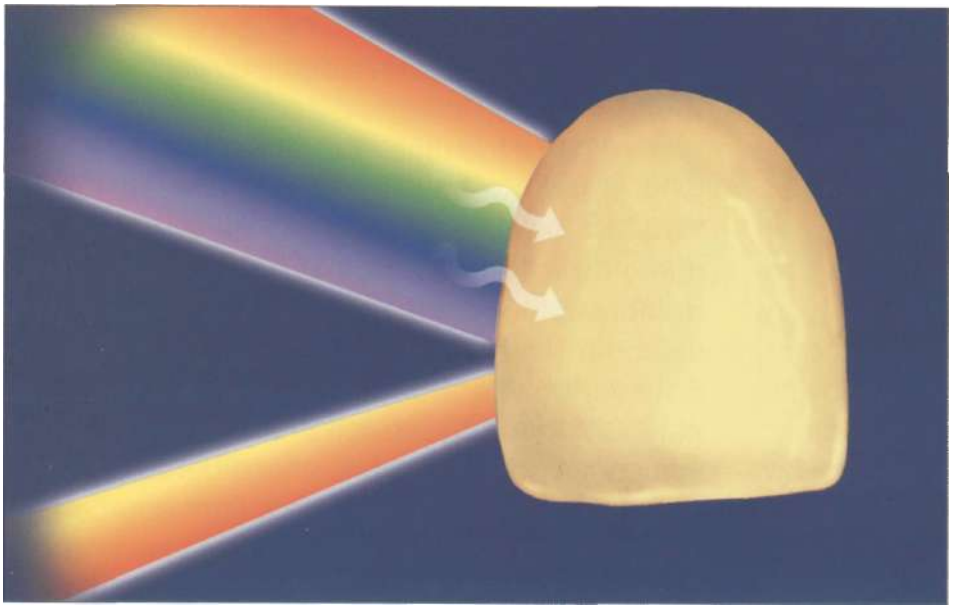

Fig 5-20 An orange object absorbs red, green, blue, indigo, and violet wavelengths of light, and reflects orange (590 to 640 microns).

WWW.HIGHDENT.IR
همیار دندانسازان و دندانپزشکان

Fig 5-21 The perception of chromatic color by the eye and the brain.

Fig 5-22 The perception of chromatic color by the eye and the brain, i.e. variations of green, based upon reflections of colorgreen.

Table 5-4 Color Perception

Color Perception	Psychophysiological Reality
Physical	Wavelength of light
Psychophysical	Reception of wavelength of light by the eye
Psychological	Interpretation of wavelength of light by brain

Table 5-5 Individual Shade Selection Differences

Number of Dentists	Number of Prostheses	Number of Natural Teeth	Total
Same shade selected by 3 dentists	18 teeth (14%)	10 teeth (14.3%)	28 teeth (14%)
Same shade selected by 2 dentists	72 teeth (59.2%)	30 teeth (42.9%)	102 teeth (51.5%)
Same shade selected by 0 dentists	38 teeth (26.7%)	30 teeth (42.9%)	68 teeth (34.3%)

WWW.HIGHDENT.IR
همیار دندانسازان و دندانپزشکان

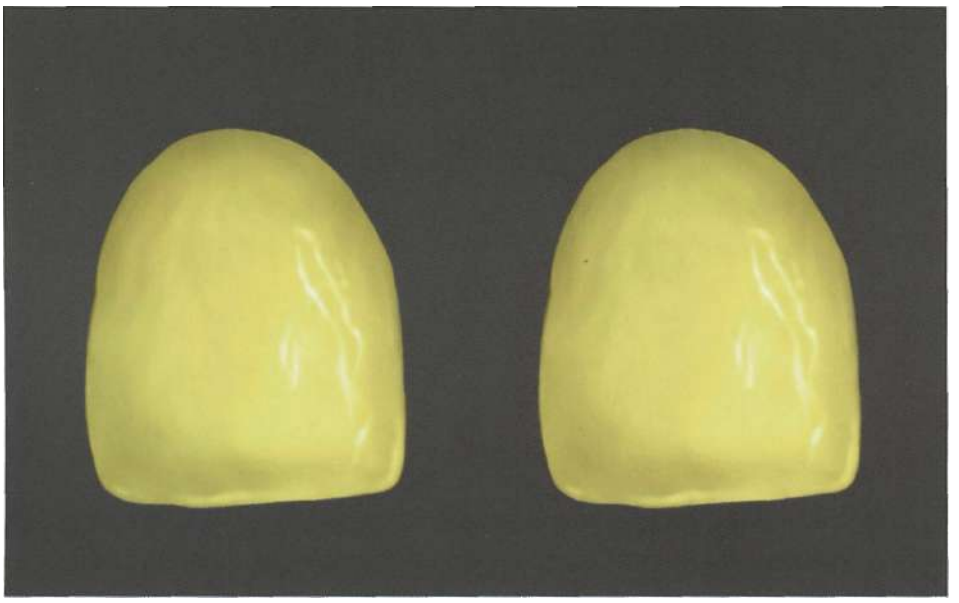

Fig 5-23 A diagrammatic presentation of an optic anomaly. When two objects of the same shape and color are arranged side by side, they may appear to be different, i.e. one seems slightly lighter than the other. It is a phenomenon where each eye perceives color slightly differently.

Fig 5-24 If the same two objects (as described in Fig 5-23) are placed on the same side, the effect is no longer evident.

Fig 5-25 Binocular color differences may cause disharmony in shade selection. Placing shade tabs on the same side of the tooth to be matched will compensate for this effect and eliminate errors.

WWW.HIGHDENT.IR
همیار دندانسازان و دندانپزشکان

Fig 5-26 Owing to the increase in secondary dentine formation with age, teeth themselves become darker (increasing chroma and decreasing value).

Binocular Difference in Color Perception

Color perception differences between individuals are considerable as we have discussed. However, even in the same individual a color perception difference may be present. This phenomenon is known as binocular color perception - it is a perception variance between the right eye and the left eye. Such color perception disparity between the eyes of an individual is small; however, when it is present, there must be a compensation for it. When two objects of the same shape and color are juxtaposed (arranged side by side), they may appear to be different, i.e. one seems to be slightly lighter than the other. This effect holds true if the objects are reversed in order from left to right. A diagrammatic presentation of this anomaly is given (Fig 5-23).

There also seems to be a phenomenon where each eye perceives color slightly differently. Interestingly, if the two objects are placed on the same side, the effect is not evident (Fig 5-24). Binocular color differences cause disharmony in shade selection and color matching. Placing shade tabs on the same side of the tooth to be matched will help to eliminate error and compensate for this effect (Fig 5-25).

Chronological Age and Color Perception

There are two distinct effects that occur with increasing age. First, the teeth themselves become darker (increasing chroma), owing to the increase in secondary dentine formation (Fig 5-26). Second, the lens of the human eye becomes more yellowish-brown, thereby imparting a yellow-brown bias. Differentiation between white and yellow becomes increasingly more difficult. This process begins at age 30, becomes more noticeable after age 50, and has clinical significance after 60 years of age. This phenomenon may present a clinical problem for a clinician and color work should, therefore, be delegated to younger auxiliary personnel, between the ages of 20 to 30 years.

Fatigue and Color Perception

Adverse visual perception is the consequence of systemic, local, and/or mental fatigue. The inability accurately to distinguish hue and chroma is most noticeable at times of fatigue, and the color may be perceived as faded or bedazzled. Successive shade observations and improper lighting (too bright or dark) are the most common causes of fatigue.

WWW.HIGHDENT.IR
همیار دندانسازان و دندانپزشکان

Table 5-6 Effect of Chemicals on Color Perception

Drug	Effect
Alcohol/morphine	Long wavelengths = brighter (red, orange, yellow) Short wavelengths = darker (blue, green, purple)
Caffeine	Long wavelengths = darker Short wavelengths = brighter

Drugs and Color Perception

The abuse of drugs, alcohol, and caffeine may affect the ability to perceive color correctly. The effects are presented in Table 5-6.

Illumination

Color can be neither perceived nor correctly evaluated without correct lighting and illumination (Fig 5-27). The studies by *Nakagawa,* et al.[9-10] and *Preston*[11] clearly showed the importance of lighting in the treatment room. They also demonstrated the dramatic influence of inadequate quality and quantity on optimal shade perception. Shade tabs, viewed under different lighting conditions, look completely different in hue, chroma, and value (Figs 5-28 to 5-30).

Metamerism

Metamerism is a phenomenon where the color of an object appears different, depending upon the light source. When viewed together under the same light source, two objects may appear to have the same color; however, each appears to have a different color when viewed under different light sources. For instance, a crown may be matched under incandescent light; however, when the crown is viewed under color-corrected or fluorescent light, the crown will appear different in color. In dentistry, this phenomenon occurs predictably and frequently if the shade selection environment is not controlled and neutral. To avoid or minimize metamerism, it is of utmost importance to control the lighting conditions when shade is being determined.

Clinical Lighting Tips

1. If the clinician or the laboratory technician has access to a natural light source, it is best to take shades at 10 am or 2 pm on a clear, bright day, when the ideal color temperature of 5500 degrees K is present.
2. Color-corrected lighting tubes that burn at 5500 K should be installed when only artificial lighting is available (without natural light).
3. A lighting intensity of 175 + or - 25 foot-candles must be maintained (verified by colortemperature meter).
4. A color temperature meter should be used periodically to verify that 5500 K is achieved in the shade taking area (treatment room or surgery).
5. Dust and dirt should be cleaned from lighting tubes and diffusers routinely, since the presence of dust may alter the quantity and quality of emitted light.

WWW.HIGHDENT.IR
همیار دندانسازان و دندانپزشکان

Fig 5-27 Optimal quantity and quality of lighting is required for accurate evaluation of the tooth color.

Fig 5-28 Shade under varied lighting conditions looks completely different in hue, chroma, and value. Here, the restoration is viewed under color-corrected light.

Fig 5-29 The same restoration as in Fig 5-28, now viewed under fluorescent light, looks completely different in hue, chroma, and value.

Fig 5-30 The same restoration tabs, viewed under incandescent light, looks completely different in hue, chroma, and value.

WWW.HIGHDENT.IR
همیار دندانسازان و دندانپزشکان

Contrast Effects

Optical Illusions

The phenomenon of contrast effect can alter the perception of color considerably, as well as the ability to evaluate color in a clear, concise, and objective way. The phenomenon is dramatically demonstrated in Fig 5-31. The purple-colored figures are all of equal length and size; however, owing to the optic illusion of converging lines, as our eyes move to the right side of the diagram, it appears that the far right figure is considerably larger than the far left figure.

Yamamoto described the various contrast effects in detail in his textbook on metal-ceramic restorations; it is a worthy reference.[19] In order to use colors effectively, it is essential to understand that value, chroma, and hue contrasts between an object and its background may severely influence color perception. There are four categories of contrast effects:

Simultaneous Contrast
When at least two objects are viewed at the same time

Area! Contrast
When the same colors are observed, appearing in different size areas

Spatial Contrast
When the same colors are observed in different positional relationships

Successive Contrast
When one color is observed after viewing another

The clinical significance of contrast effects is presented in Table 5-7.

Simultaneous Contrast

Simultaneous contrast is discerned when two objects are observed simultaneously. It may be further subcategorized as light/dark contrast and color contrast (hue and chroma).

Light/Dark Contrast

Visual judgement of brightness may not be dependable, since the relative brightness of an object is affected by the brightness of the contrasting background or surroundings. For example, if the surrounding background is dark, an object appears brighter; if the surrounding background is light, the object is perceived as less bright (Figs 5-32 to 5-34). The perceived brightness is inaccurate, even though the reflectivity of the object is constant. The retina is very sensitive to changes in light, and the phenomenon is the result of the interpretation of these changes by the brain.

A practical example of this phenomenon is inflamed gingival tissues. The redness of the gums - and consequently the background - act to distort our color perception abilities. The restoration invariably appears too bright when it actually is too dark. When the tissues heal, the crown is too low in value, since the perception indicated that the crown was of the correct shade (Figs 5-35 and 5-36).

Hue Contrast

When two chromatic colors are combined, the perceived hue varies closer to the complementary color than to that of the background (Figs 5-37). The perceived hue of the mock tooth against a red background takes on a green color tone (Fig 5-38 and 5-39); against a green background it takes on a red hue (Figs 5-40 and 5-41); against a yellow background its hue is purple (Figs 5-42 and 5-43); and against a purple background it appears to be yellow (Figs 5-44 and 5-45). Note how the same A3 Vitapan shade tab appears to be quite different in hue when imaged against a red versus a blue background (Figs 5-46 and 5-47). We use this phenomenon to our advantage when taking shades by preconditioning our eyes to see tooth shades more effectively. For instance, tooth shades fall predominantly into the orange hue family, and if we want to be able to see the orange tones more discriminately, we can precondition our eyes by first looking at a light blue background, i.e. immediately prior to the shade selection process. The closerthe colors-to-be-combined are to the complementary colors, the more vibrant they appear, owing to mutual repulsion (Fig 5-48).

WWW.HIGHDENT.IR
همیار دندانسازان و دندانپزشکان

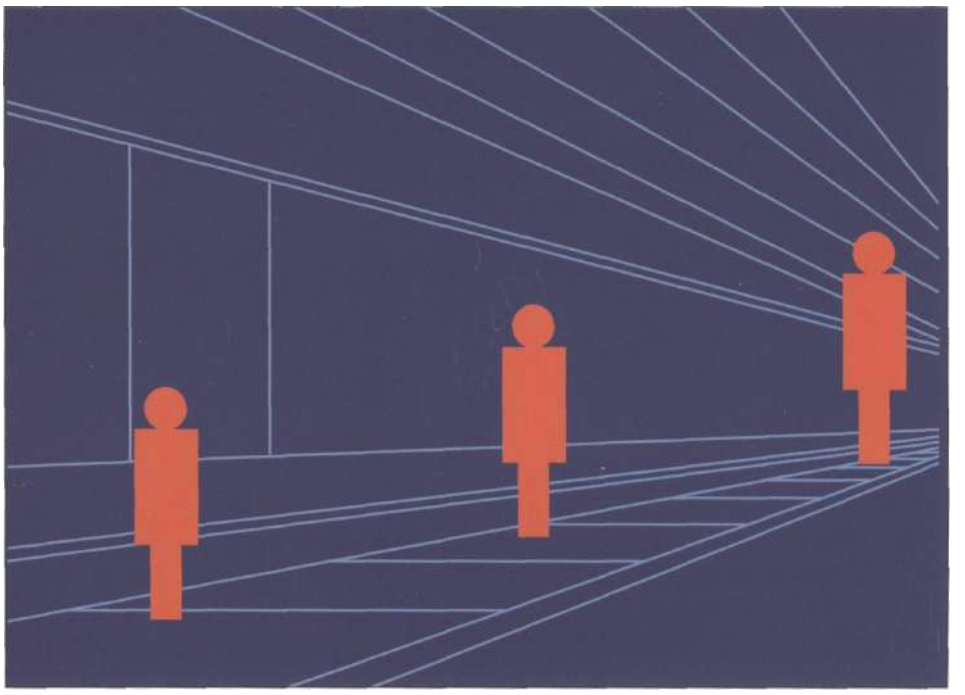

Fig 5-31 Perspective. The figures are all of equal length and size; however, owing to the optical illusion of converging lines, as our eyes move to the right side of the diagram, it appears that the far right figure is considerably larger.

Table 5-7 Clinical Significance of Contrast Effects

Contrast Effect	Clinical Effect	Clinical Application
Light/Dark	Can be correlated to surrounding environment, such as skin tone, hair and eye color, and the brightness of the adjacent (intra-arch) teeth. A darker environment tends to make an object brighter, as well as light.	Select brighter shades for light-toned patients and darker shades for pigment-toned patients, since the tendency is for the opposite contrast to occur - teeth will appear darker for lighter patients and lighter for darker patients. Error in value tendency of adjacent teeth (i.e., low value if dentition is dark; high value if teeth are the converse).
Hue	The complementary color of background or surrounding environment is more apparent.	Use a light blue or neutral gray background when selecting shades to precondition the eye for an improved perception of (complementary) color tones.
Areal	Large teeth tend to look brighter; bright teeth tend to look larger; dark teeth tend to look smaller.	Consider decreasing the value or increasing chroma by one-half the shade and lightening the shade of dark teeth by the application of bleaching/whitening procedures or ceramic laminate veneers.
Spatial	Tooth position may affect the perception of brightness.	Recessed teeth can be made brighter; protruding teeth can be made darker. Consider orthodontic therapeutic correction or ceramic laminate veneers.

WWW.HIGHDENT.IR
همیار دندانسازان و دندانپزشکان

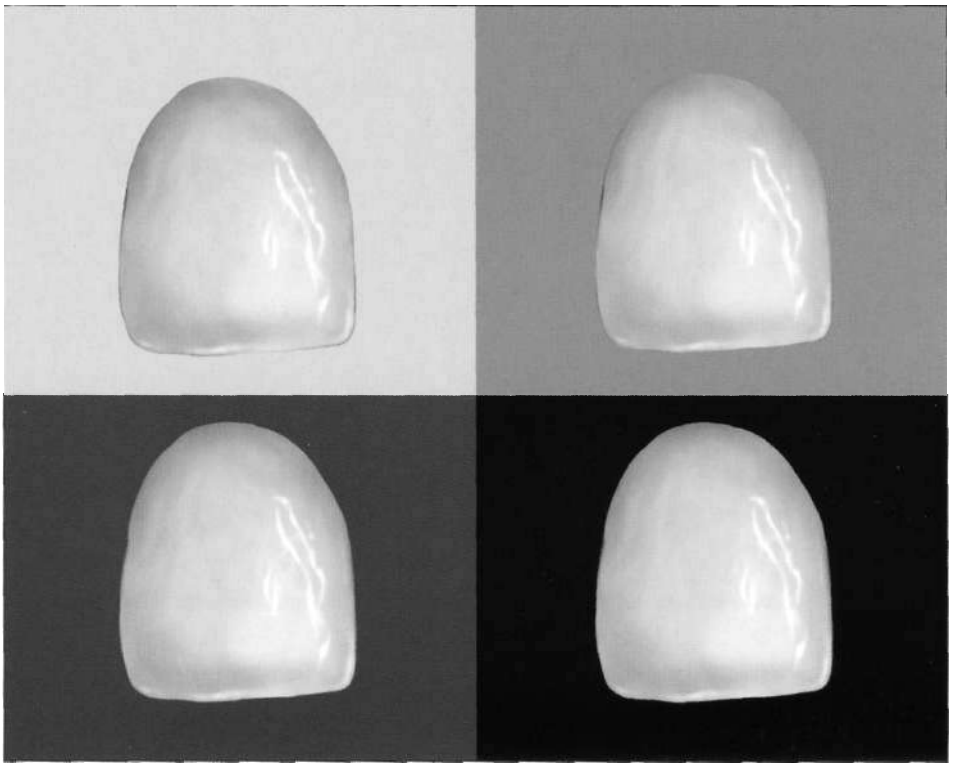

Fig 5-32 The relative brightness is affected by the contrasting background, owing to the light and dark contrasts. Even though the teeth represented are in the same light/darkness, the background influences the appearance (upper left is lighter; lower right is darker).

Fig 5-33 A ceramic crown against a dark background appears considerably lighter than against a light background.

Fig 5-34 The same ceramic crown against a light background appears considerably darker.

WWW.HIGHDENT.IR
همیار دندانسازان و دندانپزشکان

Fig 5-35 The redness of inflamed gingival tissue, for example, distorts our color perception. This phenomenon has a significant clinical importance: if the shade is taken while the gingival tissues are inflamed, the tooth will appear to be lighter, and the color selected will be too dark.

Fig 5-36 When the inflamed tissues heal, and the color returns to normal, the selected crown value may be too low (dark).

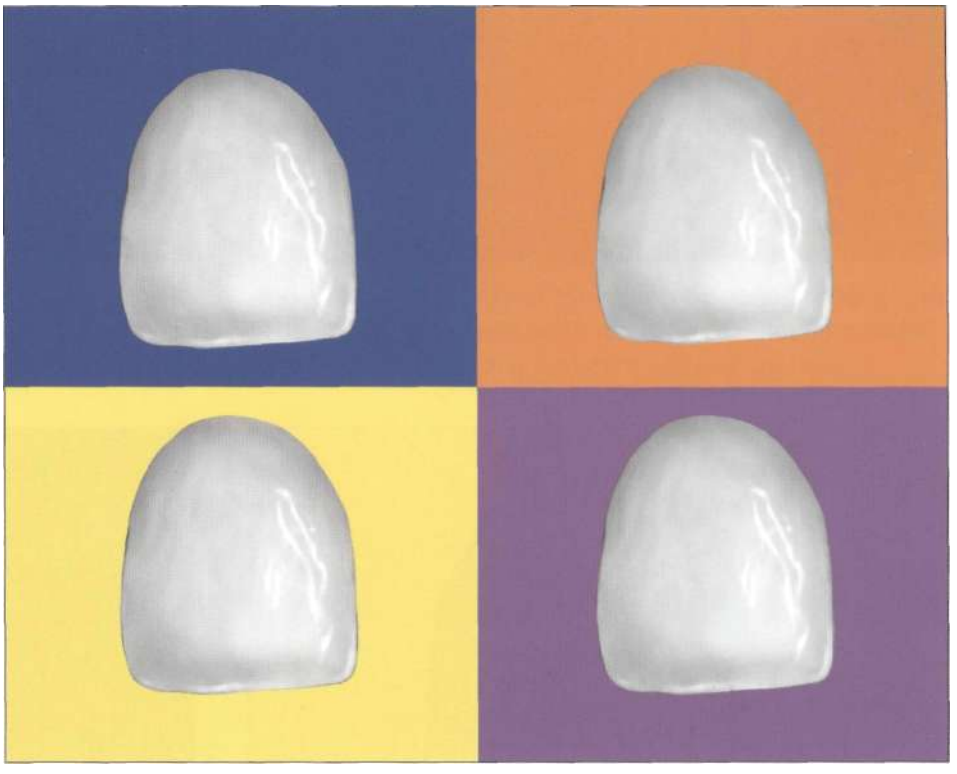

Fig 5-37 When two chromatic colors are combined, the perceived hue varies closer to the complementary color than to that of the background.

WWW.HIGHDENT.IR
همیار دندانسازان و دندانپزشکان

Fig 5-38 The perceived hue of a tooth against a blue background appears to be orange.

Fig 5-39 A metal-ceramic crown against a blue background appears to be orange in hue.

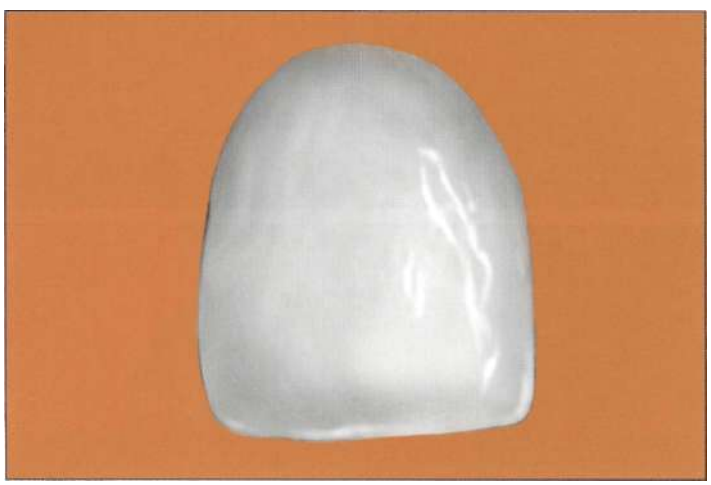

Fig 5-40 Placed against an orange background, a metal-ceramic tooth appears to be blue.

Fig 5-41 Placed against an orange background, a metal-ceramic tooth appears to be blue in hue.

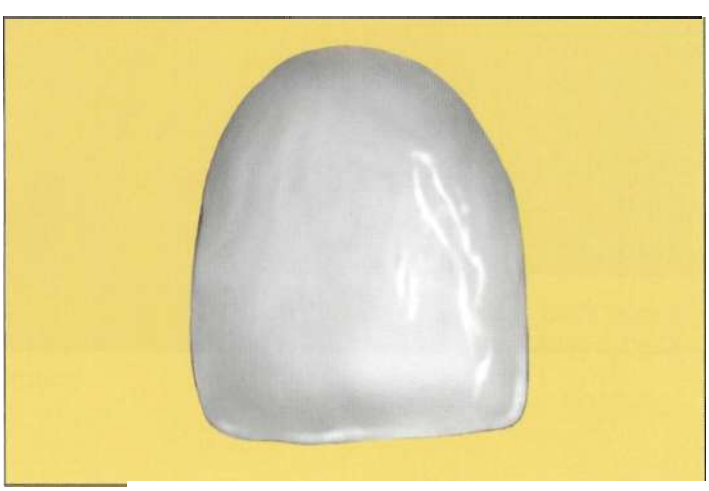

Fig 5-42 Placed against a yellow background, the tooth appears to be purple.

Fig 5-43 Placed against a yellow background, a metal-ceramic tooth appears to be purple.

WWW.HIGHDENT.IR
همیار دندانسازان و دندانپزشکان

Fig 5-44 Placed against a purple background, the tooth appears to be yellow.

Fig 5-45 Placed against a purple background, a metal-ceramic crown appears to be yellow.

Fig 5-46 The hue of an A3 Vitapan shade tab against a black background takes on a brighter appearance.

Fig 5-47 The same A3 Vitapan shade tab as in Fig 5-46 appears quite different when placed against a blue background - it takes on a darker, more orange hue.

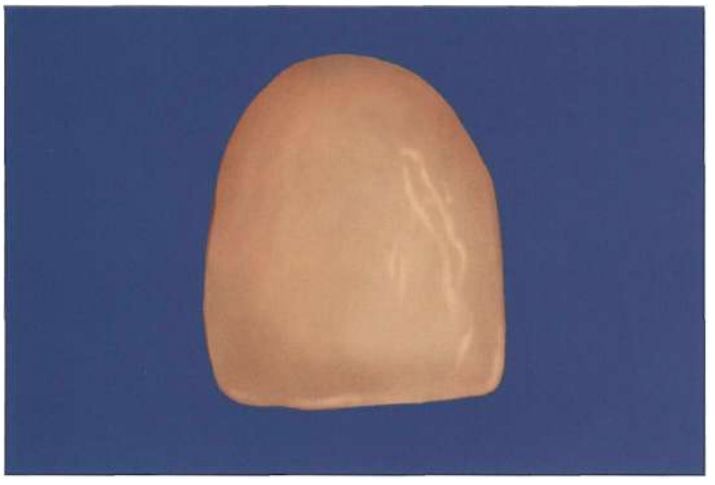

Fig 5-48 Mutual repulsion. The closer the colors to be combined are to the complementary colors, the more vibrant they appear.

WWW.HIGHDENT.IR
همیار دندانسازان و دندانپزشکان

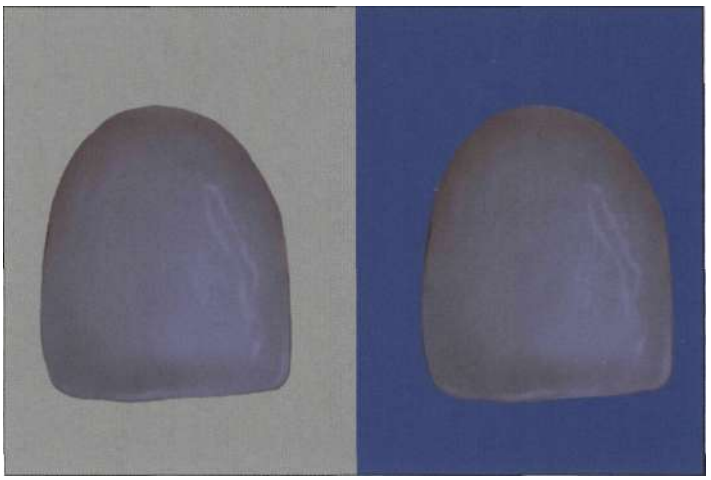

Fig 5-49 Chroma contrast. Clinical example: the color of the background is close to the color of the tooth, rendering the tooth color muted.

Fig 5-50 Chroma contrast. The closer the color of the orange tooth is to the orange background, the more muted it becomes. The effects are influenced by light/dark contrast and by hue contrast.

Chroma Contrast

This phenomenon follows the effects generated by light/dark contrast as well as hue. The image against the gray background appears brighter (light/dark contrast) since it is low in chroma. The image againstthesame hue background appears dull (light/dark contrast), owing to the increase in chroma of the background, as well as the slightly blue presence in tone (hue contrast) (Figs 5-49 and 5-50).

Areal Contrast

Visual color perception is also influenced by the size of the object. Optical illusion is present even though the object reflects the same wavelength of light in the visible spectrum. For instance, a large object will appear brighter, while one of asmallersizewillappeardarker, even though they both are of the same color (Figs 5-51 and 5-52).

Conversely, a brighter object will appear to be larger, while a darker object will appear smaller (Figs 5-53 and 5-54). Fig *5-55* shows a crown made for tooth #9, which is considerably lower in value than the natural tooth #8. Even though they are both of equal size and dimension, tooth #9 appears smaller because it is darker. (The fashion industry employs the illusion of color perception as well. Dark clothes have a tendency to make an individual appear smaller and thinner, while white clothes tend to make the individual appear larger and heavier.)

Spatial Contrast

Spatial contrast can be equated to brightness and size as well. An object that is more recessed will appear to be smaller in size and not as bright; an object closer to the observer will appear larger and brighter (Fig 5-56). This phenomenon is frequently seen with rotated and overlapped teeth. The teeth that are recessed appear to be darker, and they tend to be more difficult to clean. However, once the stain is removed, the teeth will still appear darker, owing to the spatial contrast (Fig 5-57). Posterior teeth appear to be darker, since they are more recessed in the oral cavity. The shadows in the mouth further contribute to the darker appearance (Fig 5-58).

Successive Contrast

Successive contrast is a phenomenon that presents itself when one color is observed following the observation of another color. An afterimage

WWW.HIGHDENT.IR
همیار دندانسازان و دندانپزشکان

Fig 5-51 Area contrast. Visual color perception is also influenced by the size of the object: a large-size object will appear lighter, a small-size darker.

Fig 5-52 Example of area contrast as perceived in maxillary central (larger, brighter) and lateral (smaller, darker) incisors. Even though the crowns are the same (A2) shade, they appear much brighter since they are physically much larger.

Fig 5-53 With objects of an equal size, a brighter object will appear larger.

Fig 5-54 With objects of an equal size, a darker object will appear smaller.

Fig 5-55 View of a crown for maxillary left central incisor that is considerably lower in value than the natural tooth #8 (right central incisor). They are of the same size and color, but the crown appears to be smaller because it is darker.

Fig 5-56 Spatial contrast. An object that is more recessed will appear to be smaller.

WWW.HIGHDENT.IR
همیار دندانسازان و دندانپزشکان

Fig 5-57 Spatial contrast. Teeth that are more recessed appear to be darker.

Fig 5-58 Posterior teeth appear to be darker because they are more recessed in the oral cavity.



Fig 5-59 Afterimages. Positive after images occur after a short visual interaction and have the same color as the original perception. Negative after images occur after a long visual contact with an object and have the opposite or complementary color.

Fig 5-60 Preoperative view of a full maxillary arch to be restored with ceramic veneers.

(visual experience) is an example of successive contrast when the visual perception remains after the eye has left the object. Afterimages are categorized as positive (similar) or negative (different). Positive afterimages have the same color as the original perception; negative afterimages have the opposite or complementary color to the original perception. Positive afterimages occur following a short visual interaction, while negative afterimages occur after a long visual contact with an object (Fig 5-59). Figs 5-60 to 5-70 present the preoperative and postoperative views of a case of full maxillary arch ceramic restorations. Note how - by changing the background paper - the phenomenon of value, chroma, and hue contrast affects the appearance of the veneers of teeth #8 and #9 (Figs 5-63 to 5-70).

WWW.HIGHDENT.IR
همیار دندانسازان و دندانپزشکان

Fig 5-61 Postoperative facial view at a conversation distance.

Fig 5-62 Postoperative close-up view of the maxillary central incisors, restored with ceramic veneers.

Fig 5-63 Placed against a gray background, the object will appear lighter in color.

Fig 5-64 Clinical representation of the light/dark contrast. Postoperative view ofthe maxillary central incisors restored with ceramic veneers. Note the translucency of the incisal edges against dark background.

Fig 5-65 Placed against a white background, the maxillary central incisors restored with ceramic veneers. Note the difference of the incisal edges and the darker appearance of the teeth.

Fig 5-66 Placed against a blue background, the ceramic veneers take on orange appearance.

WWW.HIGHDENT.IR
همیار دندانسازان و دندانپزشکان

Fig **5-67** Placed against a yellow background, the ceramic veneers take on a purple appearance.

Fig **5-68** Placed against a purple background, the ceramic veneers take on a yellow appearance.

Fig 5-69 Placed against a red background, the ceramic veneers take on a green appearance.

Fig 5-70 Placed against a green background, the ceramic veneers take on a red appearance.

Shade Guide Systems

Shade selection is a process of converting shade perception into shade communication - conversion of color into a terminology and language of the ceramic system and then communicating it to the laboratory technician for fabrication of the restoration. A technician with high color analysis acuity can look at a tooth and see the colors as they correlate to a porcelain system. Determining an accurate shade match is one of the most critically important procedures in esthetic restorative dentistry and has always been one of the greatest challenges in dentistry and a source of frustration. The dilemma lies in achieving accuracy, predictability, and consistency in shade selection.2.26 our dental schools do not provide adequate training of dental students in color education,[4]^ and most laboratory technicians have never had the opportunity to work directly with patients.

Shade guide systems may be divided into two categories: conventional, using shade tabs, and technology-based, using digital computer imaging and analysis.

WWW.HIGHDENT.IR
همیار دندانسازان و دندانپزشکان

Conventional Shade Guide Systems

Shade Tabs

Shade tabs are used as visual guides; they are only guides, not definitive answers. A neutral environment, maintenance of correct quantity and quality of light, and absence of eye fatigue are important prerequisites for achieving accurate shade selection. *Miller*[15,20,21] demonstrated that the Vita Classic shade guide was too low in chroma and too high in value when compared to the extracted natural tooth samples. Inherent inconsistencies in the fabrication of present conventional shade guide systems have also been described. For example, shade A3 Vita Laminate tabs may vary within and among several guides by the same manufacturer.

The Vitapan Classical, Ivoclar Chromascop, and Vitapan ED Shade Master are currently the most common and popular shade guides. In the Vitapan Classical shade guide, hue is categorized according to groups or families with letter notations:

A - Orange
B - Yellow
C-Yellow/Gray
D - Orange/Gray (Brown)

The Chromascop System uses numbers instead of letter to identify the shade:

100-White
200 - Yellow
300 - Orange
400 - Gray
500 - Brown

The Vitapan 3D ShadeMaster is a unique departure from the conventional lettering/numbering categorization. It is based upon the pioneer work of *Miller*[15] and further developed by *McLaren.*[39]

L - denotes a tendency toward a yellow hue
R - denotes a tendency toward a red hue.

The Vitapan Classical and Ivoclar Chromascop Systems communicate chroma by a system of increasing numbers.

Vitapan Classical: 1 to 4 - 1 is the least chromatic, 4 is the most chromatic.

Chromascop: 10 to 40 - 10 is the last chromatic, 40 is the most chromatic.

3D ShadeMaster: 1 to 3 - 1 is the least chromatic, 3 is the most chromatic.

The Vitapan Classical and Ivoclar Chromascop Systems address value through chroma: 1 to 4 and 10 to 40 are not only increasing in chroma but also decreasing in value.

The 3D ShadeMaster addresses value first: 1 to 5-1 is the brightest (high value), 5 is the darkest (low value).

Value-based versus Hue-based Shade Guides

Value-based shade guides are a more accurate means of shade selection, as previously discussed, since our eyes are more sensitive to changes in lightness/darkness and chroma than subtle changes in hue. This is especially true for lighter shades (which are the current trend in cosmetic restorative dentistry). With lighter shades, there is very little saturation of hue (low chroma); therefore, hue is not apparent, nor is it a factor in the shade selection process. Value becomes the dominant parameter. Examining a B1 versus A1 shade tab, it would be difficult to assess which tab contains more yellow or orange; however, it is relatively easy to determine which tab is brighter (value). If value and chroma are correct, the restoration will be clinically acceptable, even if the hue is slightly off the optimal.

Clinical Need for Improved Systems of Shade Determination

In the conventional shade tab system, selection of the appropriate shade had always been left up to the subjective knowledge and skill of each practitioner. In such a system, great variability is inherent. The standard visual shade selection protocol has several inherent difficulties, already mentioned in the foregoing text. Metamerism, proper lighting, measured in foot-candles, illumination type (color-corrected versus fluorescent bulbs,

WWW.HIGHDENT.IR
همیار دندانسازان و دندانپزشکان

Fig 5-71 The Shofu ShadeEye-EX Chroma Meter (Shofu, Menlo Park, CA) uses a single point source spectrophotometer as the basis of shade analysis.

color illusion, and color perception differences are merely some of the variables that contribute to the inconsistencies in shade selection).

Clinically, the development of new restorative materials with improved physical and optical properties became a major factor in highlighting the need for improved methods of shade selection. The improved characteristics of dental ceramic materials were primarily in material density with a direct influence on light transmission, i.e. opacity and translucency. Owing to the differences in molecular and crystalline structure of the new materials, changes took place in light reflection, absorption, refraction, and dispersion. The material science itself had become sophisticated and intrinsically involved in the optical aspects of the dental restorative processes.

As these clinical inadequacies in the conventional shade selection became identified, research was generated for the development of more accurate methods. A need for objective standards of shade selection became evident in the dental profession, which could virtually eliminate the wasted chair time consumed in repeated appointments and loss of productivity.

Technology-based Shade Guide Systems

The development of the Shofu ShadeEye-EX Chroma Meter (Shofu, Menlo Park, CA) in 1998, which uses a single point source spectrophotometer as the basis of shade analysis, marks the emergence of technology-based systems for determination of shade for fabrication of dental materials (Fig 5-71).

Goldstein first reported the Shofu chroma meter in the literature[69] followed by *Yamamoto.*[23] The system employs point source references of information to extrapolate color determination. The potential disadvantage of such a system is that it employs single point sources of information and subsequent extrapolation of that information. Teeth are polychromatic entities and, therefore, require multiple point sources of reference when using this system in order to achieve a more representative analysis of shade distribution. Correct interpretation of the information is of critical importance for a predictable and accurate result. An additional drawback of the Shofu chroma meter is its limitation of compatibility to the Shofu porcelain system. However, if the technology is employed properly, it provides sufficient and reliable information to fabricate well-matching restorations.

In 2000, *Robert*[37] reported the application of another technology-based system - ShadeScan (Cynovad, formerly Cortex Machina, Montreal, Canada) that used "artificial vision", i.e. computer-aided digital and video camera vision technology, to see and analyze tooth images and objectively infer their appearance properties based on color and translucency (Fig 5-72). The digital image is then cross-referenced with a database of shade tabs and guides from known manufacturers (e.g. Vita Lumin, Vita 3D Master, and Ivoclar Chromascop). Additional shade guides can be readily incorporated into the system by scanning them into the database. The advantage of such a system is the objective analysis of shade selection, mapped out in a clear concise manner. The report includes a translucency distribution map that identifies contrasting areas of translucency and opacity. Information concerning value, chroma, and hue differences between the original

WWW.HIGHDENT.IR
همیار دندانسازان و دندانپزشکان

Fig 5-72 The ShadeScan System (Cynovad, formerly Cortex Machina, Montreal, Canada) uses computer-aided digital camera vision technology to analyze dental images and infer color and translucency.

tooth and the shade map is also presented in detail (Figs 5-73 to 5-79).

The optical device is easy to use. To capture an image, the device is held perpendicular to the tooth surface, and it can compensate for an angle deviation of up to 20 degrees. The halogen fiber optic light illuminates the tooth surface at a 45-degree angle to minimize surface reflectance that would cause image distortion. Image capture set-up takes approximately 5 seconds, and the actual capture takes less than 1 second. During the image capture, the patient should hold their breath so as not to fog the lens of the optical camera. Capture of the image is effortless for the anterior teeth; however, the head of the equipment may be too large to capture images of the posterior teeth in patients with smaller mouths. The key to the system is the consistent and constant level of light illumination, which standardizes the image capture and analysis. The output is internally calibrated to ensure constant intensity of illumination.

The SpectroShade System (MHT International, Newton, PA) is another technology-based shade matching system (Fig 5-80); it was described by *Cherkas* in 2001.[26] It differs from the Shade Scan system in that it employs spectrophotometric data (wavelengths of reflected light) for the analysis of shade, although it uses 300,000 points of reference, which are then computer reformatted. This process differs markedly from the ShadeEye-EX Chroma Meter, which measures only single-point sources of reference. Calibration is sensitive and requires 2 images for an exact match. Several reference images may be required before calibration is achieved. However, when calibrated, it provides atremendous source of invaluable objective information to aid the dental technician in restoration fabrication (Fig 5-81).

The ShadeScan System differs from the other systems in that it uses RGB digital camera technology to infer color properties versus a spectrophotometer measuring wavelengths of reflected light and reformats the images based upon that information. Using a spectrophotometer in his study to measure the color of extracted teeth, *Miller*[15] identified the following provisions: reproducibility of the spectrophotometer was accurate to 1 %; the spectrophotometer was sensitive to small shifts in location on a natural tooth; the high reflectance and translucency of natural teeth and porcelain restorations required making average measurements in the center areas of the tooth restoration; minor errors were created in translating spectrophotometer data into *Munsell's*[8] equivalents, since the ShadeScan technology is not governed by these conditions.

Using technology that responds to light in a similar manner to that of the human eye, the X-Rite ShadeVision System uses colorimetric data

WWW.HIGHDENT.IR
همیار دندانسازان و دندانپزشکان

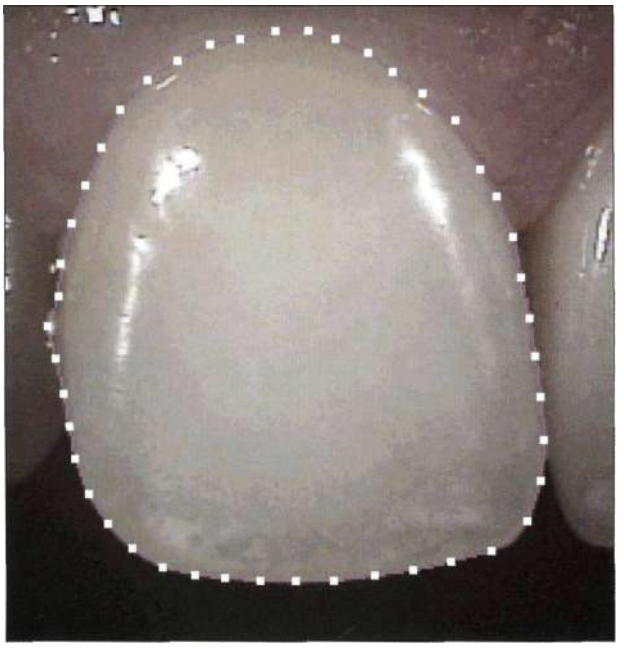

Fig 5-73 Clinical example of tooth #8. The ShadeScan system technology demonstrates the differences between the original tooth and the shade map. Tooth #9 to be restored with a PFG restoration.

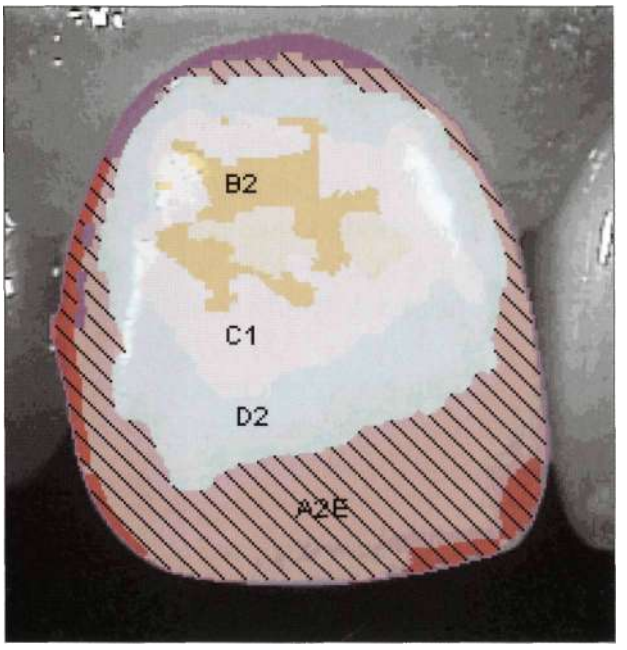

Fig 5-74 The fine shade map of tooth #8, correlated with Vita Classic shade guide tabs.

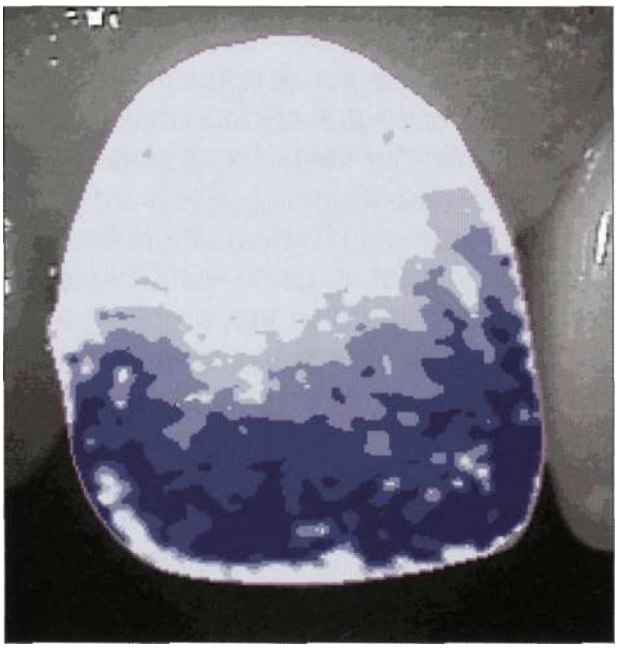

Fig 5-75 Inferred translucency map of tooth #8. The darker areas of blue imply greater translucency.

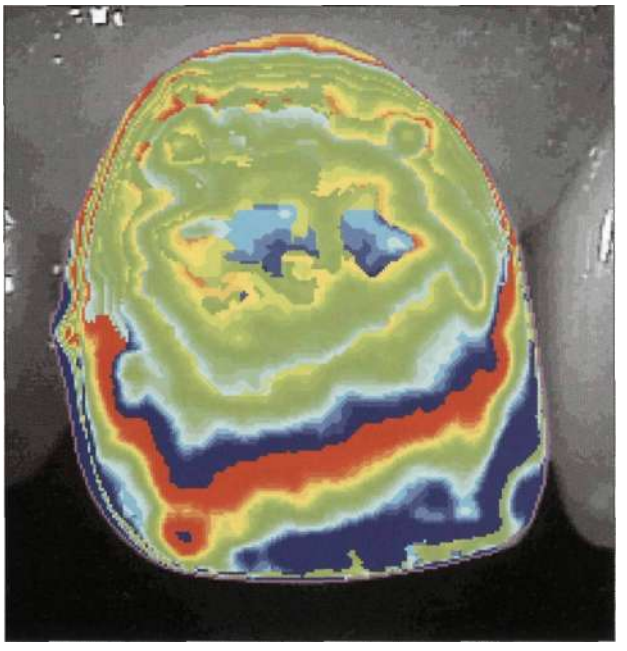

Fig 5-76 Value difference map of tooth #8. Note the change in low (blue), neutral (green), and high (red) value.

WWW.HIGHDENT.IR
همیار دندانسازان و دندانپزشکان

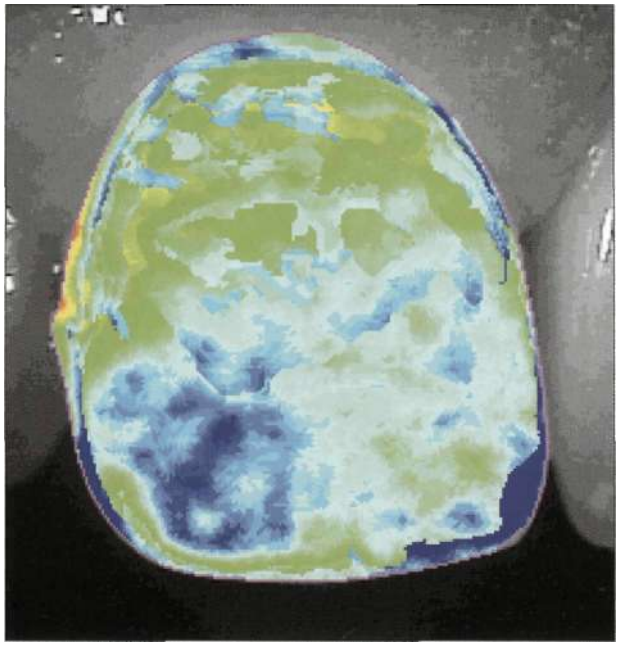

Fig 5-77 Chroma difference map of tooth #8. Note the color change: green is neutral.

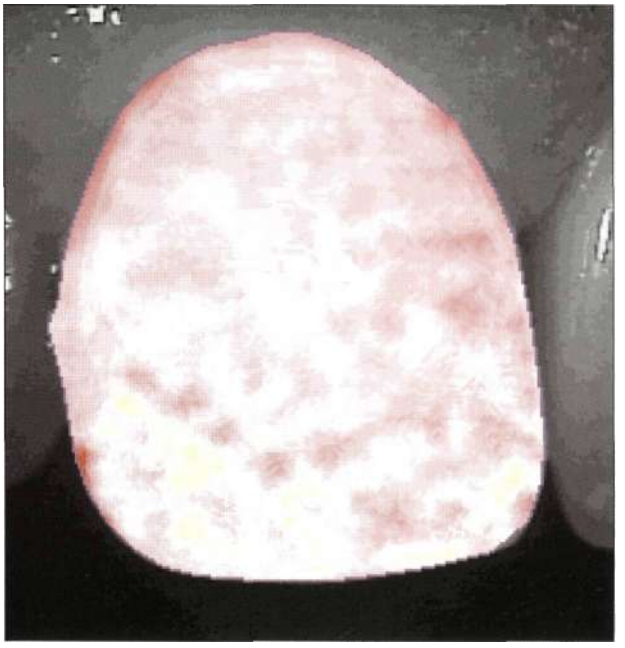

Fig 5-78 Hue difference map of tooth #8. Hue difference tendency is toward red or yellow.

Fig 5-79 Final clinical photograph of tooth #8 and crown restoration #9. Note the imperceptible difference between tooth #8 (natural tooth) and tooth #9 (fabricated crown).

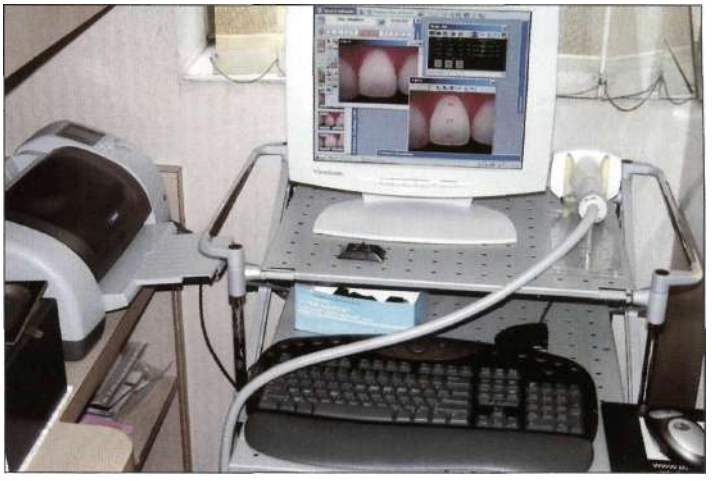

Fig 5-80 The SpectroShade System (MHT International, Newton, PA) uses spectrophotometric data for the analysis of shade with 300,000 points of reference, which is then formatted using computer imaging.

to provide consistent and accurate shade measurement technology (Fig 5-82). The cordless handheld instrument is an electronic shade-taking device that captures images of natural dentition and determines up to 22,000 individual measurements of hue, value, and chroma; these images are then uploaded into the computer via the docking station for analysis, processing and documenting. The information can be sent to the laboratory via an email, saved to media or printed (Fig 5-83). The lab uses the data for an accurate fabrication of the restoration using detailed color analysis of the tooth. The laboratory can also use the system to measure the restoration and compare with the original information supplied by the dentist without the presence of the patient. This is called the "virtual try-in" appointment where shade verification can be established.

WWW.HIGHDENT.IR
همیار دندانسازان و دندانپزشکان

CMHT

Dentist Name:	Stephen J Chu, DMD,MSD
Address:	
Patient Name:	Chu, Stephen
Age:	43
Sex:	Male
Tooth #:	
Tooth Label:	CS--1
Notes:	
Time:	3/16/02 12:06:06
Shade Guide:	Vita Classical
Find-Best Formula:	|ΔL|

All

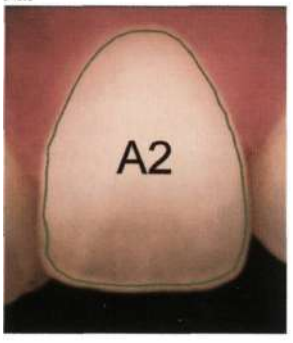

Three Areas

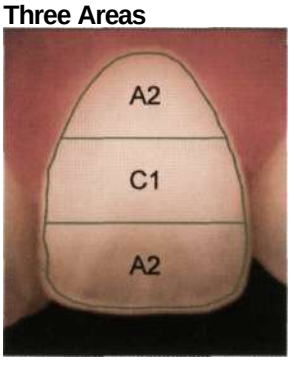

Coarse Map

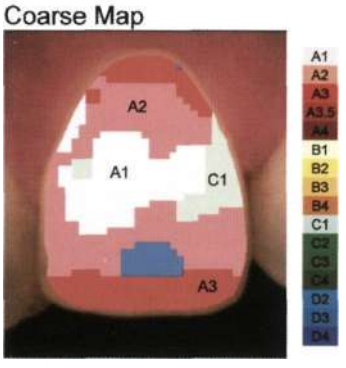

Translucency



All:	Tooth:	A2:	Diff.:
L:	71.04	71.16	-0.12
C:	16.17	16.99	-0.81
h:	77.85	84.52	-1.93
		ΔE:	2.10

Shade A2:

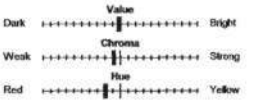

Cervical:	Tooth:	C1:	Diff.:
L:	70.93	70.10	0.83
C:	19.72	16.75	2.98
h:	71.35	79.60	-2.61
		ΔE:	4.05

Shade C1:

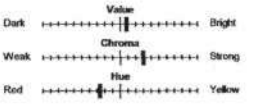

|ΔL|: 0.83

Middle:	Tooth:	B2:	Diff.:
L:	74.48	74.40	0.09
C:	16.03	18.66	-2.63
h:	78.63	88.07	-2.85
		ΔE:	3.88

Shade B2:

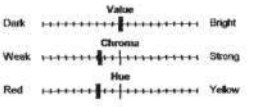

|ΔL|: 0.09

Incisal:	Tooth:	A2:	Diff.:
L:	67.40	67.17	0.23
C:	14.42	13.06	1.36
h:	81.97	88.22	-1.50
		ΔE:	2.04

Shade A2:



|ΔL|: 0.23

12/20/02 6:38:51 PM Page 1 of 1

Fig 5-81 The MHT SpectroShade report identifies the shade broken into the gingival, body, and incisal areas, respectively. Information of shade is correlated to comparative AE values.

WWW.HIGHDENT.IR
همیار دندانسازان و دندانپزشکان

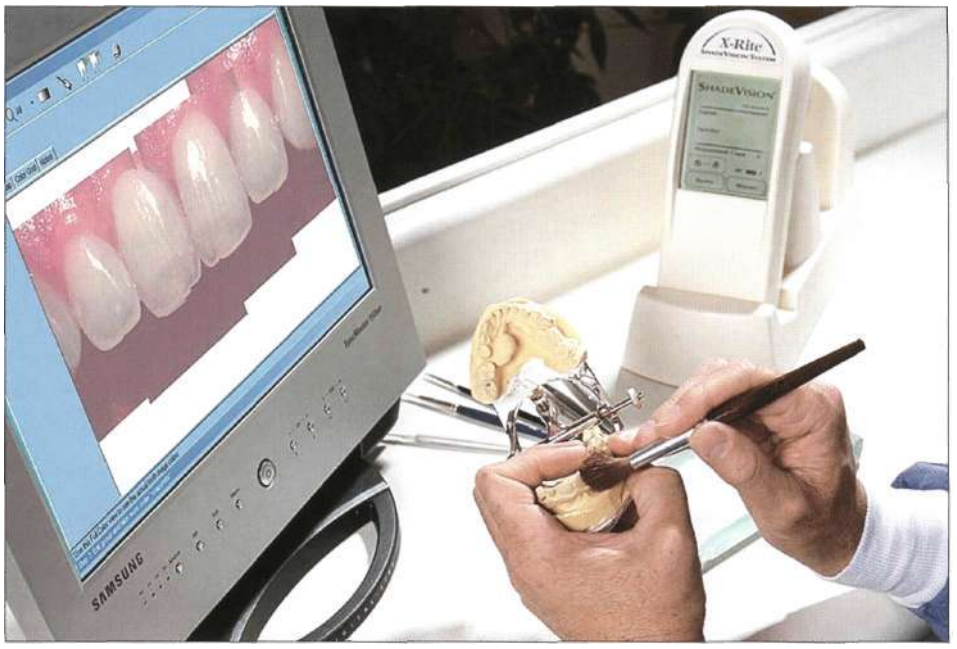

Fig 5-82 The Shade Vision System (X-Rite, Grand Rapids, MI). It uses colorimeter-based data for the analysis of shade with 22,000 measurement reference points. The image capture unit is cordless and portable allowing freedom between treatment rooms.

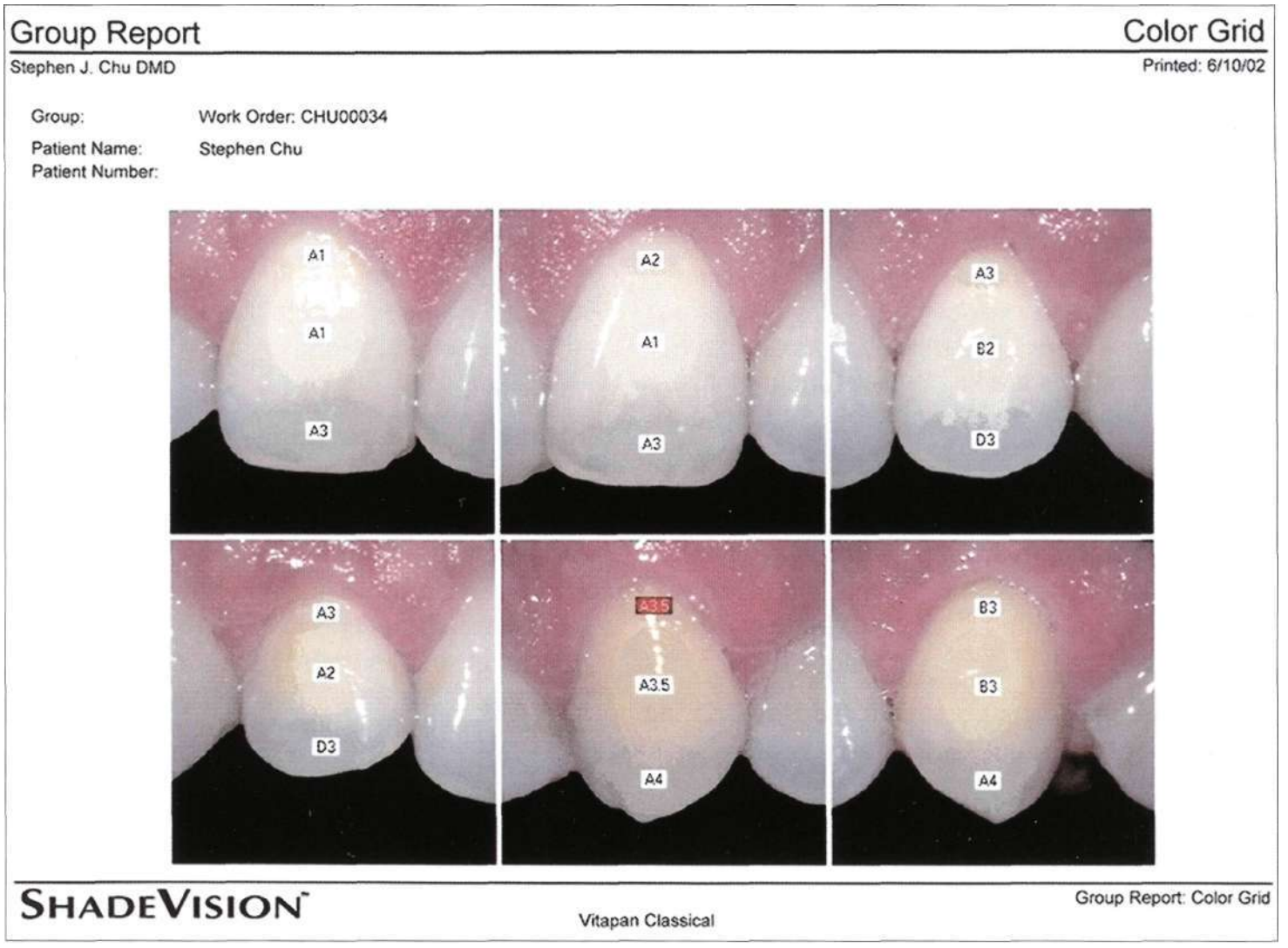

Fig 5-83 The X-Rite Shade Vision report provides an exceptionally clear image of the recorded teeth as well as identifying the respective gingival, body, and incisal shades. Up to eight images can be captured at a time.

WWW.HIGHDENT.IR
همیار دندانسازان و دندانپزشکان

Advantages and Disadvantages of the Technology-Based Systems

The technology-based shade guide systems have a distinct advantage over the conventional methodology. The reports are less subjective; the capture of an image takes less time, rendering the dehydration of a tooth a non-issue; and the shade of a restoration can be verified prior to the intraoral placement (Fig 5-84). In 2001, *Chu* and *Tarnow*[31] used a clinical case report to describe the subjective deficiencies in the conventional shade selection process and compared the method to computer-aided information with "artificial vision" technology. Shade determination is rapidly evolving towards a more objective standard.

The predominant current disadvantage of the technology-based systems is cost, owing to the expenditures incurred in research and development of these systems. Interpretation of the reports is still subjective, i.e. dependent upon the skill and knowledge of the technician fabricating the restoration. If shade determination can be divided into four critical areas - analysis, communication (of information to the laboratory), interpretation, and fabrication - technology-based systems address the issues of analysis and communication very well. Interpretation and fabrication of restorations are still inherently subjective. The advantages and disadvantages of the conventional and technology-based shade selection systems are summarized and compared in Table 5-8. As the efforts are proceeding in the direction of objective evaluation through unbiased technology-based information systems, the future in shade selection in the dental profession looks promising.

Impact of Materials and Material Science on Color

The importance of restorative materials and their effect on color shade cannot be overemphasized. With the esthetic dental industry driven by innovative materials, impressive strides in improvement have been made in material science and adhesive technology, offering improved physical and optical properties (Table 5-9). The major participants include Procera, Nobel Biocare, Yorba Linda; Creation AV, Jensen Industries; Empress I and II, Ivoclar-Vivadent; Cerpress SL, Leach and Dillon; In-Ceram; Omega 900, Vita Zahnfabrik; HeraCeram.

England's *McLean*[47,48,55] - one of the leaders and innovators in dental ceramic materials - developed a variety of present-day commercially available ceramics. The improved characteristics are primarily in material density, which correlates directly to light transmission (opacity and translucency). There are five categories of materials that have direct application as materials for fabrication of ceramic laminate veneers:

Sintered aluminum oxide ceramics
(Procera)
Lithium-disilicate ceramics
(IPS Empress 2 Eris)
Leucite-reinforced ceramics
(Empress I, Cerpress SL)
Feldspathic ceramics
(Creation, Ceramco 3, Finesse)
Synthetic low-fusing quartz glass ceramics
(HeraCeram).

Sintered Aluminum Oxide

Full-coverage restorations using sintered aluminum oxide have achieved a new status in fixed prosthodontics. The excellent marginal adaptation that can be achieved, high resistance to fracture under compressive loading (690 MPa), and the ability to receive a variety of cosmetic veneering porcelains render these materials highly desirable. Their application in veneer restorations is just emerging. Preparation of the tooth is of critical importance in the fabrication process, since computer scanning is difficult and limited, owing to the inherent topography and irregularities in tooth preparation designs. The preparation must be able to resist distortion when the sprayed aluminum oxide powder is sintered onto the refractory die cast. If accurate copings can be made,

WWW.HIGHDENT.IR
همیار دندانسازان و دندانپزشکان

Fig 5-84 When using some technology-based systems (X-Rite, MHT International), the shade of a restoration can be verified prior to the intraoral placement. The Shade Vision system allows shade verification using a computer software program called the "Virtual Try-In Appointment". Laboratory images can be directly compared to clinical images on the same screen for visual approval without the presence of the patient.

Table 5-8 Advantages versus Disadvantages of Shade Selection Systems

System	Advantages	Disadvantages
Conventional	Cost	Subjectivity
	Ease of use	Inconsistency in fabrication by manufacturers
	Visual tool	Selection easily affected by surrounding environment and lighting conditions
	Transportable	
Technology-based	More objective	Increased cost
	Verification of restoration shade in the laboratory	Interpretation of the report is technician dependent
	Not influenced by surrounding environment and lighting conditions	Not easily transportable (Cynovad Shade Scan and MHT Spectro Shade Units)
	Increased productivity - less chairside time and fewer remakes	
	Tooth dehydration is a non-issue	

WWW.HIGHDENT.IR
همیار دندانسازان و دندانپزشکان

Table 5-9 Current Materials for Ceramic Laminate Veneer Restorations: Fracture Toughness and Relative Optical Properties

Material	Flexural Strength (MPa)	Opacity/ Translucency
Slip-Cast Alumina Ceramics		
(In-Ceram, Vita Zahnfabrik, Germany)	630	high/low
High-Alumina Reinforced (Sintered) Ceramics (Procera-Sandvik, Stockholm, Sweden)	600	high/low
Leucite-Reinforced Ceramics		
(Empress 1, Ivoclar-Vivadent, Lichtenstein)	180	moderate/moderate
(Cerpress SL, Leach and Dillon, Cranston, Rl)	180	variable (high/low)
Feldspathic Ceramics		
(Creation, Jensen Industries, New Haven, CT)	**90**	low/high
Synthetic Low-Fusing Quartz Glass Ceramics (HeraCeram, Heraeus-Kulzer-Jelenko, Armonk, NY)	120	very low/very high

cosmetic ceramic veneering can be applied predictably and confidently. Only the traditional facial/incisal preparation is indicated at this time. Interproximal preparation - which would be required if proximal caries and/or existing restorations were present - is not amenable to Procera scanning and fabrication.

Lithium-disilicate Ceramics

Lithium-disilicate material was developed in 1998 (IPS Empress 2).[61] It has 340 MPa fracture toughness, and it can be etched with hydrofluoric acid. It is pressed accurately, achieves excellent marginal adaptation, and is strong enough to provide superior marginal integrity. It is not as opaque in appearance as sintered aluminum oxide, yet it is more opaque than the conventional leucite-reinforced (Empress I) and feldspathic ceramics. This characteristic is esthetically beneficial for masking moderately advanced discoloration of dentition. Figs 5-85 to 5-94 present a clinical case of feldspathic ceramic veneer restorations, replaced with lithium disilicate pressed veneers. The difference in optical properties is quite evident between the two materials.

Leucite-reinforced Ceramics

Ivoclar developed leucite-reinforced ceramics in 1990 under the trade name IPS Empress 1, with clinical applications in full-coverage restorations. They have evolved to encompass veneer restorations, since they can be etched, possess ade-

WWW.HIGHDENT.IR
همیار دندانسازان و دندانپزشکان

Fig 5-85 Case 1. Preoperative view of a clinical case, where the previous restorations of teeth #8 and #9 with feldspathic ceramic veneers are to be replaced with lithium disilicate pressed veneers.

Fig 5-86 Preoperative clinical close-up view of teeth #6, #7, and #8.

Fig 5-87 Preoperative close-up view of teeth #8 and #9 with existing feldspathic ceramic veneer restorations.

WWW.HIGHDENT.IR
همیار دندانسازان و دندانپزشکان

Fig 5-88 Preoperative close-up view of teeth #9, #10, and #11.

Fig 5-89 Intraoperative view of the prepared maxillary incisors. The existing veneers have been removed. Note the darkness of the stump shade. The dentition had previously been aggressively prepared.

Fig 5-90 Laboratoryview of the definitive lithium disilicate veneers for the 6 anterior maxillary teeth (#6 to #11)

Fig 5-91 Postoperative view of the lithium disilicate veneer restorations, placed and cemented.

Fig 5-92 Right lateral postoperative view of the maxillary lithium disilicate veneer restorations, placed and cemented.

Fig 5-93 Anterior postoperative view of the maxillary lithi urn disilicate veneer restorations, placed and cemented.

WWW.HIGHDENT.IR
همیار دندانسازان و دندانپزشکان

Fig 5-94 Left lateral postoperative view of the maxillary lithium disilicate veneer restorations, placed and cemented.

quate strength (180 MPa), and can be fabricated with varying forms of opacity, depending upon the manufacturer. Leach and Dillon manufactured pressed ceramic ingots in three types of opacity - high, medium, and translucent - depending upon the needs of the clinical circumstances. Excellent marginal fit and variable translucency render this material attractive.

Feldspathic Ceramics

Weinstein first described the use of feldspathic ceramics for metal ceramic restorations in the early 1960s.[43] The work of *Bowen,*[44] *Buonocore,*[65] *Calamia,*[62] *Calamia* and *Simonsen,*[63] and *Kanca*[66,67] dramatically changed the complexion of current dentistry and introduced a new generation of dental adhesives. Ceramic veneers - the thin fragile pieces of ceramics - can now be predictably adhered to the prepared tooth structure. The adhesive interface is no longerthe weak link in the system. Feldspathic ceramics are the most commonly used material for veneer restorations at present. In their fabrication, they are highly versatile and can be produced using the platinum foil or refractory die techniques. They possess beautiful esthetic qualities, most importantly translucency, and have remained steady in clinical application - longer than any other ceramic laminate restorative material to date.[52]

Synthetic Low-fusing Quartz Glass Ceramics

In 1982, *Karino*[56] first described the use of low-fusing ceramics with metal ceramic restorations. In 1998, *McLaren*[57] discussed the development of a new low-fusing ceramic, also used with ceramometal restorations that fired at 100 degrees centigrade lower than feldspathic ceramics. In 2001, *Chu*[60] described the development of a completely synthetic glass ceramic material for metal ceramic restorations. This synthetic material is also applicable in laminate veneer restorations. The greatest benefit provided by these materials is kindness to the natural dentition, with less wear to the opposing natural teeth. Figs 5-95 to 5-104 present a case utilizing the same shade but two different restorative materials (feldspathic ceramic and synthetic low-fusing quartz glass ceramic) for the veneer restoration of teeth #8 and #9 and the color response to those materials. Note the differences in opacity/translucency of the restorations.

The above groups of ceramic materials present various and unique physical and optical properties, owing to the differences in molecular and crystalline structure. For instance, sintered aluminum oxide coping materials possess high strength yet greater opacity, while - on the other end of the spectrum - feldspathic ceramics have

WWW.HIGHDENT.IR
همیار دندانسازان و دندانپزشکان

Fig 5-95 Case 2. Preoperative view of a clinical case, where both maxillary incisors are to be restored using the same shade but two different restorative materials (feldspathic ceramic and synthetic low-fusing quartz glass ceramic). Note the differences in opacity/translucency of the restorations (Figs 5-101 and 5-103).

Fig 5-96 Preoperative view of the same case. An error in chroma and value is intolerable, while an error in hue is less noticeable.

Fig 5-97 Intraoperative anterior view of both maxillary central incisors (teeth #8 and #9), prepared for restoration.

Fig 5-98 Laboratory view of synthetic low-fusing quartz glass ceramic veneer restorations for both maxillary incisors. Fired directly on to the refractory dies.

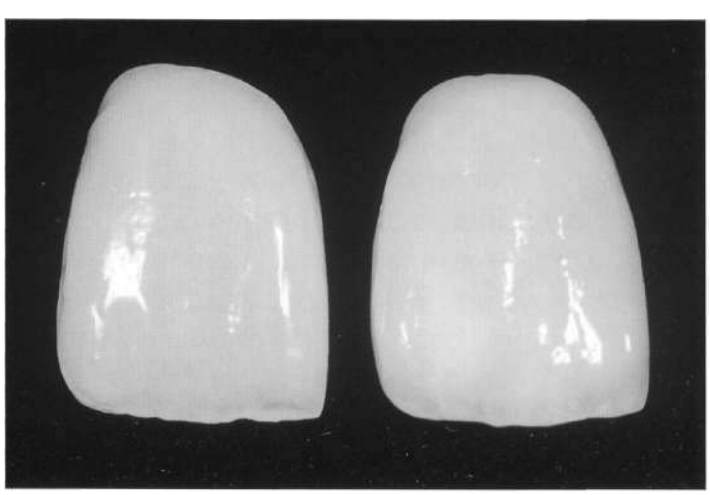

Fig 5-99 Laboratory refractory cast technique for tooth #8: feldspathic (left) and synthetic low-fusing quartz glass (right) ceramic veneer restorations. Note the difference in optical properties.

WWW.HIGHDENT.IR
همیار دندانسازان و دندانپزشکان

Fig 5-100 Laboratory refractory cast technique for tooth #9: feldspathic (left) and synthetic low-fusing quartz glass (right) ceramic veneer restorations. Note the difference in optical properties.

Fig 5-101 Clinical try-in: synthetic low-fusing quartz glass ceramic veneer restorations in place.

Fig **5-102** Clinical try-in: feldspathic ceramic veneer restorations in place.

Fig 5-103 Definitive postoperative clinical anterior view: the feldspathic ceramic veneer restorations were selected, placed, and cemented. The feldspathic material better matched the adjacent lithium disilicate full coverage crowns.

Fig **5-104** Postoperative natural view of the restorations at close conversational distance.

the lowest physical properties (690 MPa versus 90 MPa fracture toughness) but high translucency. Changes and differences in light reflection, absorption, refraction, and dispersion translate in the variations in optical effects perceived. There is a correlation between strength and opacity: high strength = high opacity; lowerstrength = high translucency.

WWW.HIGHDENT.IR
همیار دندانسازان و دندانپزشکان

Fig 5-105 Example of a mild color variation often present in the natural dentition. The maxillary central incisors are the most esthetically dominant of the 6 maxillary teeth, the canines are usually the most dominant in hue and chroma.

Fig 5-106 The hue of the canines is usually different from that of the central and lateral incisors, and their chroma is of greater intensity.

Clinical Applications - Ceramic Laminate Veneer Color Matching

The principles of translucency, value, chroma, and hue can be applied to either single or multiple unit ceramic veneer restorations. There is a considerable variability in shade within a given dental arch in the same patient. Slight variations are noticeable between the maxillary central incisors, lateral incisors, and the canines. Even though the central incisors are the most esthetically dominant of the six maxillary teeth, the canines are usually the most dominant in hue and chroma (Fig 5-105). The central incisors tend to be the brightest in the arch; the cuspids are the darkest. There may be slight variation of chroma and value between the central and the lateral incisors; the lateral ones are smaller and slightly lower in value. However, the hue is often the same. The hue of the canines is usually different from that of the central and lateral incisors, and their chroma is of greater intensity (Fig 5-106). The same holds true of the mandibular canines, yet the mandibular central and lateral incisors are equal in hue, chroma, and value when compared to the maxillary teeth. The posterior teeth - molars and premolars - match the central incisors more closely.

There is a stratification of color within each tooth. The enamel layer acts like a window, refracting and reflecting light waves. The enamel layer is linked more directly to value. True color (hue and chroma) arises from the dentine layer (Figs 5-107 to 5-112). This phenomenon is clearly evident when tetracycline-discolored teeth are prepared. As the enamel layer is stripped (made thinner), the tooth appears to be more chromatized (darker) (Figs 5-111 and 5-112), presenting a "Catch 22" situation. As we prepare the tooth structure to receive the veneer restoration, the discoloration increases - higher in chromaand lower in value (darker) - thereby making it more difficult to mask the discoloration.

Sulikowski and *Yoshida*[35] proposed that the depth of tooth preparation be based on the presentation level of discoloration. Greater depth of reduction is required to allow greater thickness of cosmetic restorative materials to mask the underlying tooth shade, even though this procedure is somewhat contradictory to nature, as previously mentioned. However, it is logical from a fabrication standpoint, since the technician has more layering options available to mask the discolored dentine.

Unlike metal ceramic restorations, where the shade can be controlled more predictably through the application of opaque porcelain over the metal framework, ceramic veneers rarely have that option - if they did, they would appear too bright and opaque. Often there is not enough

WWW.HIGHDENT.IR
همیار دندانسازان و دندانپزشکان

Fig 5-107 Preoperative view of unprepared anterior teeth for synthetic low-fusing quartz glass ceramic veneer restorations. True color (hue and chroma) arises from the dentine layer.

Fig 5-108 Preparation of tooth #8 (note moderate discoloration of dentine layer),

Fig 5-109 Preoperative right lateral view of moderate to advanced discoloration.

Fig 5-110 As the enamel layer is stripped (made thinner) the tooth appears to be more chromatized (darker) As the tooth is prepared to receive the restoration, the discoloration increases, making it more difficult to mask the discoloration.

Fig 5-111 Preoperative right maxillary view of severe tetracycline discoloration.

Fig 5-112 The underlying prepared tooth structure, or "stump", influences (affects) the background shade of the final cemented restoration. This is commonly known as the stump shade.

WWW.HIGHDENT.IR
همیار دندانسازان و دندانپزشکان

Fig 5-113 Postoperative view of the ceramic veneer restorations.

facial reduction to allow the opaque, dentine, and enamel porcelains to be layered while still maintaining vitality and translucency. Invariably, the underlying prepared tooth structure or "stump" acts as the background shade of the final cemented restoration. This is commonly known as the stump shade (Fig 5-113).

Ceramic veneers are a truly laminated structure: prepared tooth + cement + ceramic veneer. Hue, chroma, and value can be greatly influenced by the stump shade: color of the stump + color of the cement + color of the veneer = color of the final restoration. Value in the final restoration is the most notable dimension of color that the stump shade can influence. Hue and chroma are not often apparent in the lighter shades, since the saturation of hue is so low; therefore, value becomes the major variable in the esthetic effect. For example, patients cannot tell the difference in hue between A1 and B1 (orange versus yellow) because there is so little saturation of color in these shades. However, they can distinguish the difference in the brightness of the shade (value difference) more easily.

Alteration of hue is probably the most difficult characteristic to manage, since most composite luting agents are value based - clear, light, dark, or white cements are frequently the only shades offered in the luting kits. Hue-based composite stain can be added to enhance color tone. An error in hue is less noticeable; however, error in chroma and value is intolerable (Fig 5-96). Fortunately, value of the final restoration is more easily altered and controlled by the luting agent.

Controlling value for a severely discolored dentition is best addressed using a lithium disilicate restorative material. The pressed core possesses adequate capacity to more effectively mask very dark, low value areas. Figs 5-114 to 5-123 present a laboratory case that demonstrates how black areas can be effectively masked using a lithium disilicate restorative material.

Shade selection and matching a single veneer restoration are best accomplished using a pressed ceramic restorative material (Figs 5-124 to 5-126). Base color is then controlled more easily, especially with variable opacity ingots (Cerpress SL, Leach and Dillon), and cosmetic veneer layering is accomplished in accordance with the conventional pressed ceramic build-up techniques.[33]

WWW.HIGHDENT.IR
همیار دندانسازان و دندانپزشکان

Fig 5-114 Case 3. A laboratory case that demonstrates how black areas can be effectively masked using a lithium disilicate restorative material.

Fig 5-115 Cast after sectioning and trimming of the dyes. Dyes are trimmed and prepared. The cervical areas are marked black to identify areas of severe discoloration for masking.

Fig 5-116 Wax-up of the pressed maxillary anterior teeth.

Fig 5-117 Pressed veneers. Note the effectiveness of the material in blocking out the discolorations.

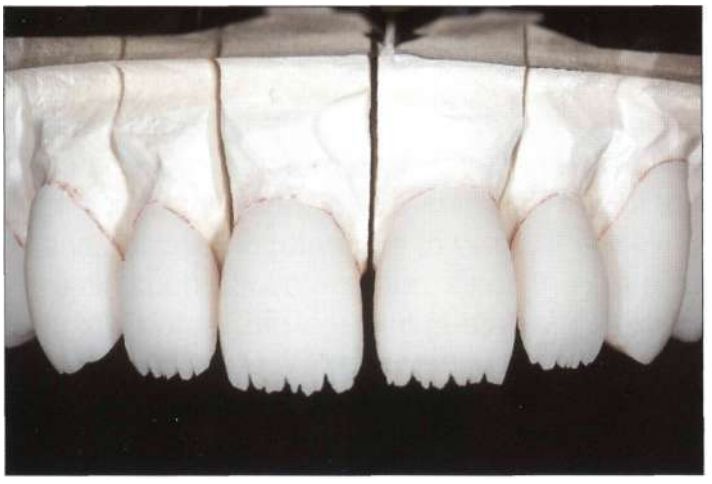

Fig 5-118 Cut-back of the pressed core material to receive veneering porcelain.

Fig 5-119 Veneer porcelain has been applied to the pressed cores.

WWW.HIGHDENT.IR
همیار دندانسازان و دندانپزشکان

Fig 5-120 Veneers (teeth #5 to #12) are glazed and polished.

Fig 5-121 Right lateral laboratory view of the veneers for teeth #5, #6, and #7.

Fig 5-122 Anterior laboratory view of the veneers for teeth #8 and #9 - both maxillary incisors.

Fig 5-123 Left lateral laboratory view of the veneers for teeth #10, #11, and #12.

Fig 5-124 Case 4. Preoperative view of the maxillary left lateral incisor (tooth #10). Shade selection and matching a single veneer restoration was best accomplished using a pressed ceramic restorative material.

WWW.HIGHDENT.IR
همیار دندانسازان و دندانپزشکان

Fig 5-125 Intraoperative view of the prepared tooth. Base color is controlled with variable opacity ingots.

Fig 5-126 Postoperative view of the veneer on tooth #10 in place. Cosmetic veneer layering is accomplished in accordance with the conventional pressed ceramic buildup techniques by Aoshima and Mieleszko.

Clinical Tips for Ceramic Laminate Veneer Shade Selection

Multiple Units

1. Establish a properly lighted environment for shade selection.
2. Select the final shade of the veneers, based upon the patient's preference as well as the tone of hair, eyes, and skin.
3. Take a photograph of the selected shade tab adjacent to the unprepared tooth structure (Fig 5-25) as a reference shade for the technician (calibration interpretation of the color transference from slides or polaroids to clinical reality.
4. Select the original shade of the hydrated unprepared tooth structure as a reference point. The clinical significance is to identify the role of the enamel layer in reference to value. It is well to retain such documentation, since the patients quickly forget and lose perspective of the extent of discoloration of the preoperative dentition.
5. Select the stump shade after the final tooth preparation. Note that the stump shade can vary within each tooth as well as interproximally (between the teeth). This importance and clinical significance of this step cannot be overemphasized.
6. Take a reference stump shade photograph for the technician. (All these photographs will give the technician information and, therefore, an advantage in fabrication of the restorations, keeping in mind the influence the stump shade affords. In essence, the restorations must compensate for the darker, greater chroma stump shade and are frequently fabricated higher in value and lower in chroma in the correct hue.)
7. Always use a try-in or trial cement prior to the definitive luting in order to verify the final shade and acquire patient approval.
   Note that dual cure cements are prone to slight changes in value owing to degradation of benzoamines in the luting agent. The final color effect will be slightly lower in value (darker).
   The final shade is indicative of a laminate of materials as well as underlying tooth structure.

Single Units

Except for the deletion of Step 2, clinical shade selection tips for single units are the same as for multiple units.

WWW.HIGHDENT.IR
همیار دندانسازان و دندانپزشکان

Conclusion

This chapter has provided an overview of the current issues in achieving optimal results in color analysis and shade selection. Some aspects, however, are discussed in considerable detail for the dental practitioner and laboratory technician. The discussions of differences in color in color perception and the measures to recognize and compensate for these differences are extensive and include practical clinical advice on how to achieve optimal lighting in the surgery for shade selection. The recognition of contrast effects includes discussion of their impact in clinical practice and the measures for correction. Extensive illustrations, slides, charts and graphs are included to exemplify the concepts.

A historical review of the conventional shade guide system identifies the inadequacies that generated the current efforts in research and development of technology-based systems of color analysis and shade selection. The advantages and disadvantages of the conventional and the technology-based systems are juxtaposed and compared. The improvements in physical and optical characteristics of dental ceramics are outlined, along with the advantages of the new dental adhesives.

In a society where optimal achievement in esthetic restorations is expected from the clinician, the arrival of these new systems and materials is welcome. It is hoped that this chapter will contribute to the general efforts in providing improved dentistry for the patient.

WWW.HIGHDENT.IR
همیار دندانسازان و دندانپزشکان

References

1. Clark EB. Analysis of tooth color. J Am Dent Assoc 1931;18:2093-2103.
2. Clark EB. The color problems in dentistry. Dent Dig 1931;37:499-509.
3. Clark EB. Seventy-fourth annual session of the ADA. Buffalo, NY, 15 Sept 1932.
4. Sproull RC. A Survey of Color Education in the Dental Schools of the World. El Paso, TX: US Army Research Report, 1967.
5. Sproull RC. Color matching in dentistry. Part 1. J Prosthet Dent 1973;29:416-424.
6. Sproull RC. Color matching in dentistry. Part 2. J Prosthet Dent 1973;29:556-566.
7. Sproull RC. Color matching in dentistry. Part 3. J Prosthet Dent 1974;31:146-154.
8. Munsell AH. A Grammar of Color. New York: Van Nostrand Reinhold Company, 1969.
9. Nagakawa Y Color analysis of shade guides. Shikai Tenbo 1976;48:1-9.
10. Nagakawa Y Analysis of natural tooth color. Shikai Tenbo 1975;46:527-537.
11. Preston JD, Bergen SF. Color Science and Dental Art: A Self-Teaching Program. St Louis, MO: Mosby, 1980:42.
12. Bergen SF. Color in esthetics. NY State Dent J 1985;51: 470-471.
13. Preston JD. Current status of shade selection and color matching. Quintessence Int 1985;16:47-58.
14. Yamamoto M. Variations in color perception. In: Proceedings from Osaka Dental Technology Meeting (1980). Osaka, Japan.
15. Miller LL. A Scientific Approach to Shade Matching. Chicago: Quintessence, 1988.
16. Ubassy G. Shape and Color. Chicago: Quintessence, 1988.
17. Seghi RR. Spectrophotometric analysis of color differences between porcelain systems. J Prosthet Dent 1986;56: 35-40.
18. Seghi RR. Performance assessment of colorimetric devices on dental porcelains. J Restor Dent 1989;68:1755-1759.
19. Ishikawa-Nagai S. Using a computer color matching system in color reproduction of porcelain restorations. Part 1. Application of the CCM to the opaque layer. Int J Prosthodont 1992;5:495-502.
20. Miller LL. Shade matching. J Esthet Dent 1993;5:143-153.
21. Miller LL. Shade selection. J Esthet Dent 1994;6:47-60.
22. Pensler AV What you were not taught about shade selection. Dent Econ 1995;85:80-81.
23. Yamamoto M. Development of the vintage halo computer color search system. QDT 1998;21:9-26.
24. Miyoshi Y, Sasaki J. Glinical application of the computer color search system and digital recording method of the buildup recipe: Use of the "Shade Eye File" database. QDT 1999;22:69-77.
25. Lichter JA. Shade selection: Communicating with the laboratory technician. NY State Dent J 2000;66:42-46.
26. Cherkas LA. Communicating precise color matching and cosmetic excellence. Dent Today 2001 ;4:52-57.
27. Ahmad I. Three-dimensional shade analysis: Perspectives of color. Part 1. Pract Periodont Aesthet Dent 1999;11: 789-796.
28. Ahmad II. Three-dimensional shade analysis: Perspectives of color. Part 2. Pract Periodont Aesthet Dent 2000;12: 557-564.
29. Priest G, Lindke L. Tooth color selection and characterization accomplished with optical mapping. Pract Periodont Aesthet Dent 2000;12:497-504.
30. Vanini L. Light and color in anterior composite restorations. Pract Periodont Aesthet Dent 1996;8:673-682.
31. Chu SJ, Tarnow DP. Digital shade analysis and verification: A case report and discussion. Pract Periodont Aesthet Dent 2001;13:129-136.
32. Chiazzari S. The Complete Book of Color. Boston: Element Books, 1999.
33. Aoshima H. Aesthetic all-ceramic restorations: The internal live stain technique. Pract Periodont Aesthet Dent 1997; 9:861-870.
34. Mieleszko AJ. The art of color mapping, i Magazine (Ivoclar Vivadent Inc.) 2001;5:6-7.
35. Sulikowski AV, Yoshida A. Clinical and laboratory protocol for porcelain laminate restorations on anterior teeth. QDT 2001; 24:8-22.
36. Heydecke G. In vitro color stability of double-layer veneers after accelerated aging. J Prosthet Dent 2001 ;85: 551-556.
37. Robert D. First contacts with the ShadeScan System. Canadian J Dent Technol 2000;4:52-60.
38. Preston JD. Digital tools for clinical dentistry. J Calif Dent Assoc. 1998;26:915-922.
39. McLaren EA. Provisionalization and the 3-D communication of shade and shape. Contemp Esthet Rest Pract 2000;5:48-60.
40. Bowen RL. Properties of silica-reinforced polymer for dental restorations. J Am Dent Assoc 1963;66:57-64.
41. Bertil H. Procera All-Ceram laminates: A clinical report. J Prosthet Dent 2001 ;85:231-232.
42. Seymour KG. Stresses within porcelain veneers and the composite lute using different preparation designs. J Prosthodont 2001;10:16-21.
43. Weinstein M, Katz S, Weinstein AB. Fused porcelain-to-metal teeth. US patent 3052,982 (1962).
44. Yamamoto N. Metal-Ceramics: Principles and Methods of Makoto Yamamoto. Chicago: Quintessence, 1985:219-305.
45. Preston JD. Perspectives in Dental Ceramics: Proceedings of the Fourth International Symposium on Ceramics (1985). Chicago: Quintessence, 1988.
46. Castelnuovo J, Tjan AH, Phillips K, Nicholls JI, Kois JO Fracture load and mode of failure of ceramic veneers with different preparations. J Prosthet Dent 2000;83:171-180.
47. McLean JW. The science and art of dental ceramics. Bridge design and laboratory procedures in dental ceramics. Chicago: Quintessence, 1980:2.

WWW.HIGHDENT.IR
همیار دندانسازان و دندانپزشکان

48. McLean JW. Evolution of dental ceramics in the twentieth century. J Prosthet Dent 2001 ;85:61-66.
49. Spear FM. The metal-free practice: Myth? reality? desirable goal? J Esthet Rest Dent 2001; 13:59-67.
50. Shoher I, Whiteman A. Captek h A new capillary casting technology for ceramometal restorations. QDT 1995; 18: 9-20.
51. Shoher I. Vital tooth esthetics in Captek restorations. Dent Clin North Am 1998;42:713-718.
52. Garber D. Porcelain laminate veneers: Ten years later. Part 1. Tooth preparation. J Esthet Dent 1993;5:56-62.
53. Stewart RM. Electroforming as an alternative to full ceramic restorations and cast substructures. Trends Tech Contemp Dent Lab 1994; 11:42-47.
54. McLean JW. The science and art of dental ceramics. Bridge design and laboratory procedures in dental ceramics. Chicago: Quintessence, 1980;2:189-209.
55. McLean JW, Seed IR. The gold/alloy porcelain bond. Trans Brit Ceram Soc 1973;5:235.
56. Karino S. A study of the development of low fusing porcelains for fusing to metals. D.Sc. thesis, 1982. Gifu University, Japan.
57. McLaren EA. Utilization of advanced metal-ceramic technology: Clinical and laboratory procedures for a lower-fusing porcelain. Pract Periodont Aesthet Dent 1998; 10; 835-842.
58. Sorensen JA, Choi C, Fanuscu MI, Mito WT. IPS Empress crown system: Three-year clinical trial results. J Calif Dent Assoc 1998;26:130-136.
59. Jones W. Low-fusing porcelains. In: Preston JD. Perspectives in Dental Ceramics: Proceedings of the Fourth International Symposium on Ceramics (1985). Chicago: Quintessence, 1988:29-46.
60. Chu SJ. Use of a synthetic low-fusing quartz glass-ceramic material for the fabrication of metal-ceramic restorations. Pract Proced Aesthet Dent 2001; 13:375-380.
61. Sorensen J, Cruz M, Mito W: Research evaluations of a lithium disilicate restorative system: IPS Empress 2. Signature 1998;5:4-10.
62. Calamia JR. Etched porcelain veneers: The current state of the art. Quintessence Int 1985;16:5-12.
63. Calamia JR, Simonsen RJ. Effect of coupling agents on bond strength of etched porcelain. J Dent Res. 1984;63: 162-362.
64. Kanca J 3rd, Gwinnett AJ. Successful marginal adaptation of a dentine-enamel bonding system in vitro and in vivo. J Esthet Dent 1994;6:286-294.
65. Buonocore MG. A simple method of increasing the adhesion of acrylic filling materials to enamel surfaces. J Dent Res 1955;34:849-853.
66. Kanca J 3rd. Effect of resin primer solvents and surface wetness on resin composite bond strength to dentin. Am J Dent 1992;5:213-215.
67 Kanca J 3rd. Improving bond strength through acid etching of dentin and bonding to wet dentin surfaces. J Am Dent Assoc 1992;123:35-43.
68. Roulet J-F, Degrange M. Prosthodontics of the future: Cementing or bonding? In: Adhesion: The Silent Revolution in Dentistry. Chicago: Quintessence, 2000.
69. Goldstein, GR, Schmitt, GW. Repeatability of a specially designed intraoral colorimeter. J Prosthet Dent 1993;69: 616-619.

WWW.HIGHDENT.IR
همیار دندانسازان و دندانپزشکان

6 Periodontal Considerations in Esthetic Treatment Planning

Korkud Demirel, Galip Gurel

Introduction

Esthetic dental treatment should not be limited to the technical skills and esthetic perspectives of the dentist and the dental technician; the patient's perceptions and her or his understanding of the problems and solutions are also important. Patients should be instructed that esthetic dental rehabilitation is a complex and complicated form of treatment and that she or he is a party to that treatment not merely a recipient of it. The patient needs to see treatment as a collaborative effort in particular because oral hygiene habits and periodontal status dictate the outcome and longevity of the esthetic result. The rehabilitation of a smile relies not only on restorative dental procedures, but also on a healthy and esthetic gingival appearance. Esthetic periodontal problems can only be tackled after efficient plaque control and proper initial periodontal therapy have been addressed. Soft tissue defects may become more apparent as gingival shrinkage occurs after the resolution of the inflammation.

The esthetic outcome of a case is determined by the relationship of the crown with the soft tissues, whether it is a natural tooth, a pontic, or an implant. A sound knowledge of the normal anatomy of the dentogingival unit may initially prevent violation of the basic principles and then one can understand the point where physiological tolerance may shift to inflammatory reaction.

WWW.HIGHDENT.IR
همیار دندانسازان و دندانپزشکان

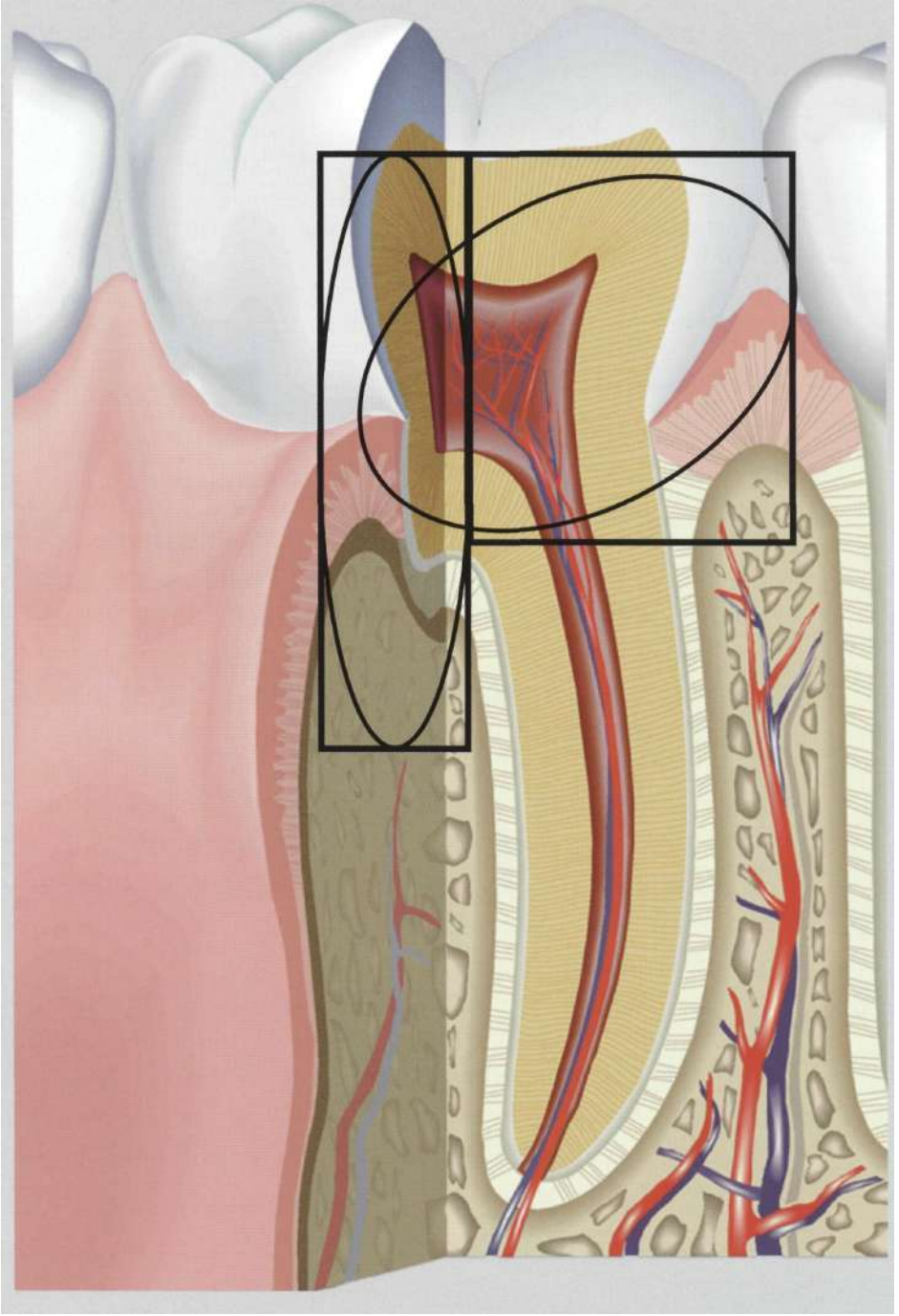

WWW.HIGHDENT.IR
همیار دندانسازان و دندانپزشکان

Periodontal Tissues in Health

The Dentogingival Unit and Biological Width

The dentogingival unit represents a unique anatomical feature concerned with attachment of gingiva to the tooth (Fig 6-1 a). It is composed of epithelial and connective tissue compartments. Three types of anatomically distinct epithelia are associated with the dentogingival unit. The first, gingival epithelium, consists of stratified squamous keratinized epithelium which is continuous at the gingival crest with the second type, stratified nonkeratinized or parakeratinized epithelium. Sulcular epithelium relines the soft tissue wall of the gingival sulcus facing the tooth but not attaching to it and is continuous at the base of the sulcus with the junctional epithelium, or the epithelial attachment. The lack of keratinization of the sulcular epithelium is the result of inflammation in its supporting connective tissue. Junctional epithelium forms a collar around the tooth and the surface cells provide the actual attachment of gingiva to the tooth surface. In a study of autopsy material by *Gargiulo* et al.[1] it was determined that the average sulcus depth was 0.69 mm, and the average length of the junctional epithelium was 0.97 mm. A significant finding in that study was that the average depth of gingival sulcus was highly variable from tooth to tooth and around the same tooth.

Connective tissue compartment of the dentogingival unit presents fibrous attachment of the gingiva to the hard tissue wall and support to the epithelium of the dentogingival junction. Fibrous connective tissue attachment to the root surface is provided by a gingival collagen fiber system that also maintains the functional integrity of the teeth and its gingival collar. *Gargiulo* et al.[1] reported that the average length of the supracrestal periodontal fiber group was 1.07 mm and was constant at all locations around the teeth. The most important groups of fiber bundles that compose this gingival unit are dentogingival, alveologingival, dentoperiosteal, transseptal, circular/semicircular, and interpapillary fiber bundles[2]-[3] (Fig 6-1 b).

The autopsy material reported by *Gargiulo* et al.[1] showed that the average length of the junctional epithelium was 0.97 mm, supracrestal collagen fiber group was 1.07 mm, and the average sulcus depth was 0.69 mm. Of these three tissue components the supracrestal connective fibrous attachment seems to exhibit the least variability, followed by the junctional epithelium and sulcus depth. In 1962, *Cohen*[4] defined the "biologic width" of supracrestal gingival tissue as those junctional epithelium and connective tissue elements of the dentogingival unit that occupy the space between the base of the gingival crevice and the alveolar crest, that the total dimension would be in the vicinity of 2.04 mm (Fig 6-2).

For practical reasons, as suggested by *Nevins* and *Skurow,*[5] the "biologic width" can be expressed as the sum of the supracrestal fibers, the junctional epithelium and the gingival sulcus. A better name that would prevent confusion could be "biologic zone" as used by *Kois*[6] (Fig 6-2). The minimum dimension of this space between the most coronal level of the alveolar bone to the most coronal level of gingival margin would be in the vicinity of 3 mm in a healthy and normal gingiva. This is the minimum space required for the tissues to maintain their continuity in a healthy status.

WWW.HIGHDENT.IR
همیار دندانسازان و دندانپزشکان

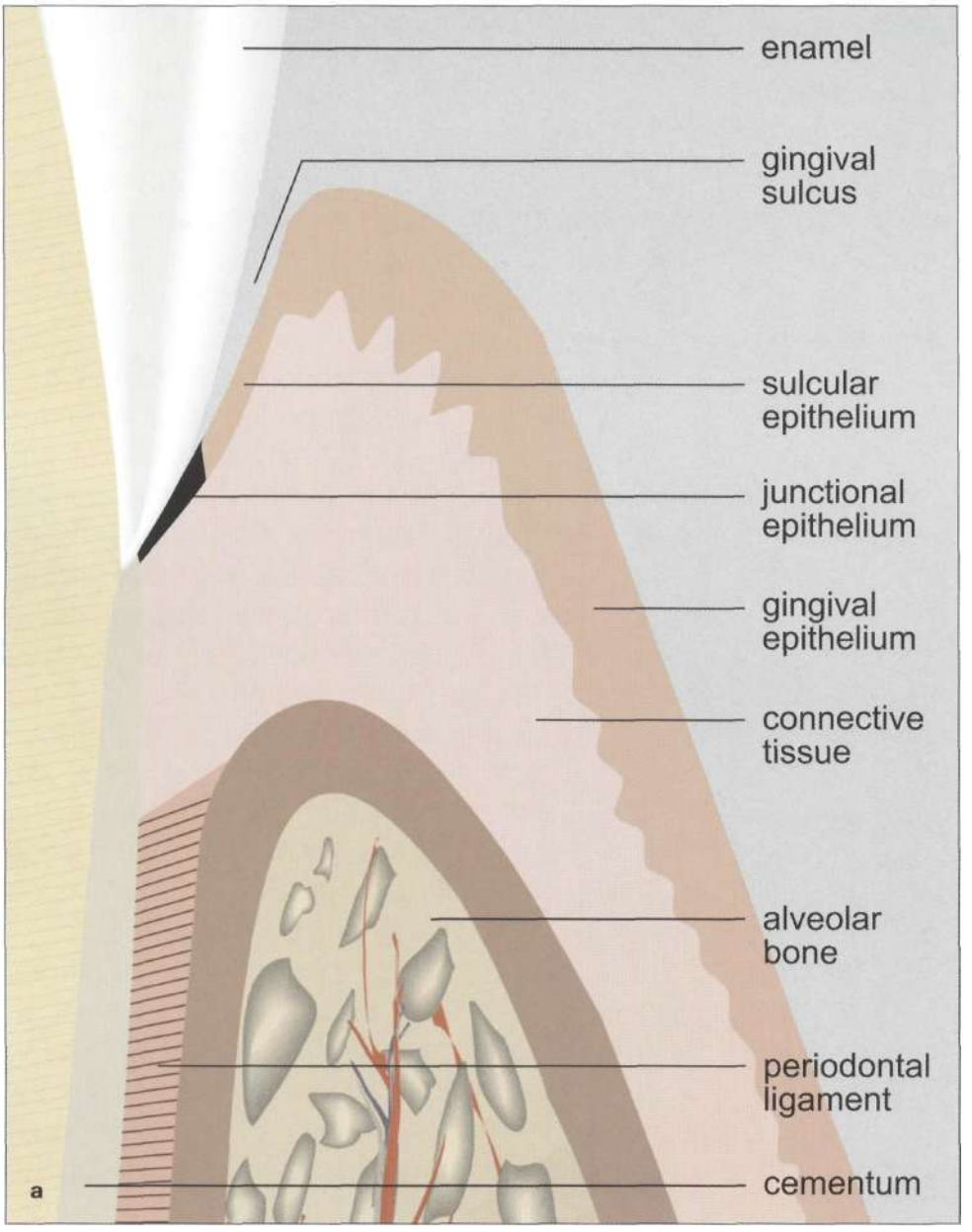

Fig 6-1 a, b (a) Anatomical landmarks of the tooth-soft tissue interface, (b) Fibers of the gingival connective tissue. Dentogingival group: these are the most numerous fibers, extending from cementum to free and attached gingiva and they provide support to gingiva. Alveologingival group: these fibers radiate from the bone of the alveolar crest and splay into the attached gingiva. These fibers provide the attachment of gingiva to the underlying bone. Dentoperiostal group: running apically from the cementum over the periosteum of the outer cortical plates of the alveolar process. These fibers anchor tooth to bone and provide protection to periodontal ligament. Transseptal fiber system: these fibers run interdentally from the cementum just apical to the base of the junctional epithelium of one tooth overthe alveolar crest and insert into a comparable region of the cementum of the adjacent tooth. These fibers maintain relationship of the adjacent teeth and protect interproximal bone. Circular and semicircular group: these are a small group of fibers that form a band around the neck of the tooth, interlacing with other groups of fibers in the free gingiva. They maintain the contour and position of free marginal gingiva. Interpupillary fibers: these are also a small group of fibers within interdental gingiva in an orofacial course. These fibers fix the vestibular papilla to the oral papilla and provide support for the interdental gingiva.

WWW.HIGHDENT.IR
همیار دندانسازان و دندانپزشکان

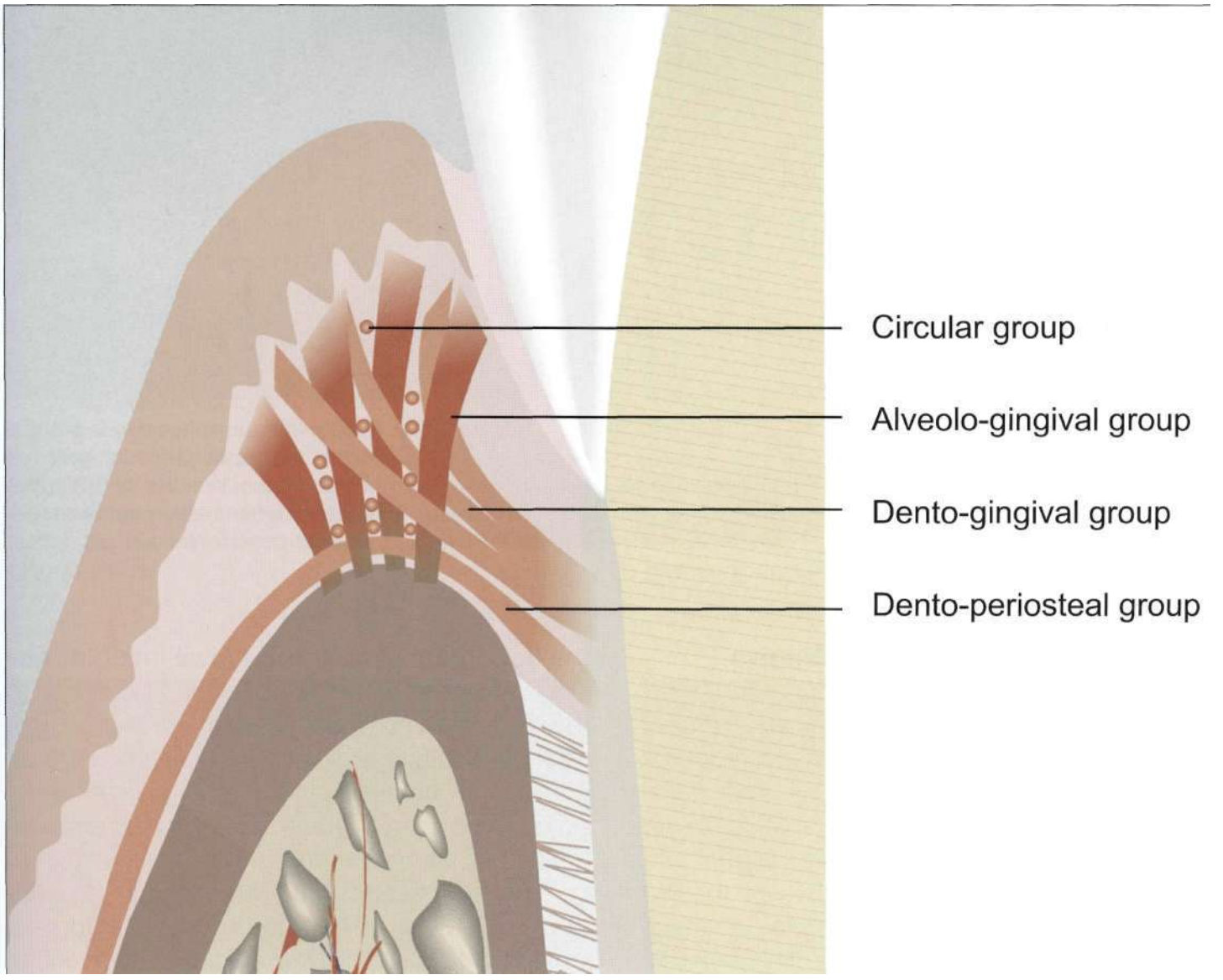

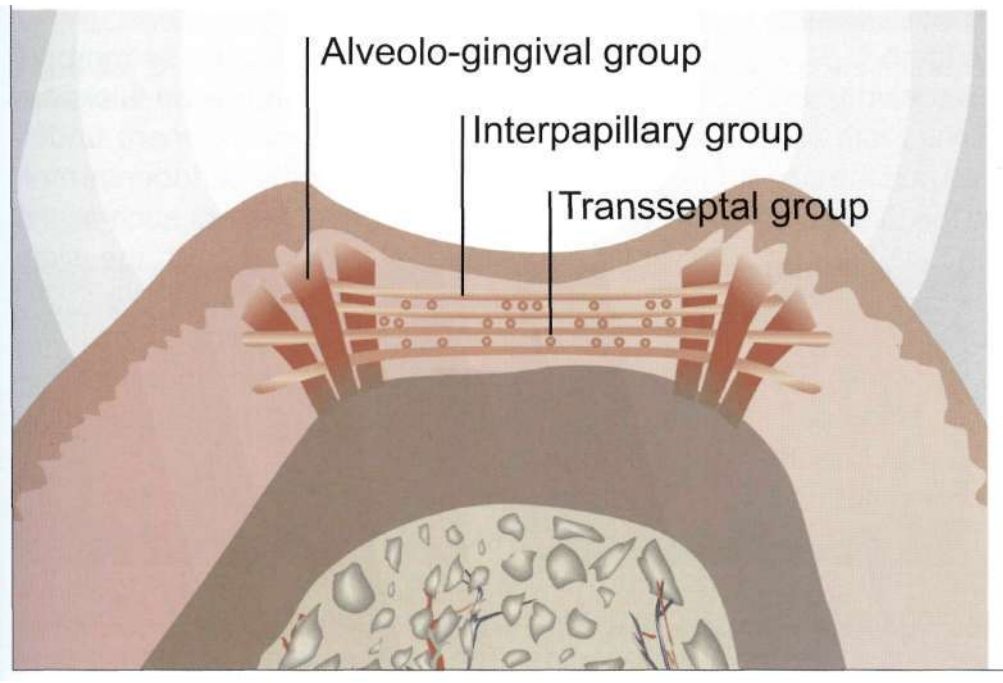

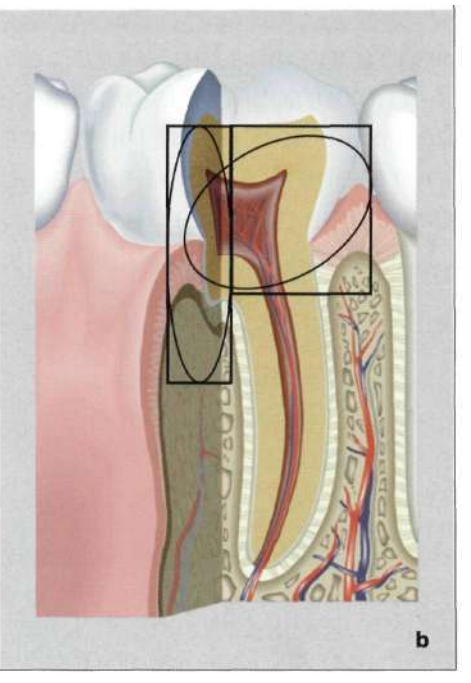

WWW.HIGHDENT.IR
همیار دندانسازان و دندانپزشکان

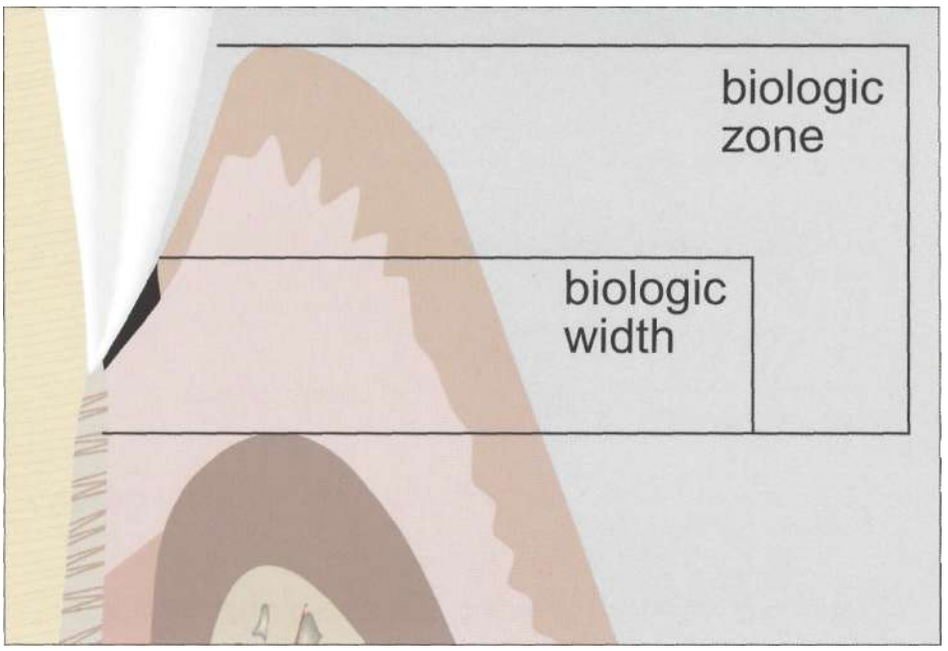

Fig 6-2 Biologic width and biologic zone refer to the minimum dimensions of the space between the most coronal level of the alveolar bone and the bottom of the gingival sulcus and the marginal gingiva respectively. This is the minimum space needed for the tissues to maintain their integrity in a healthy status. Violation of this space results in inflammation and eventually loss of periodontal support.

Clinical Features of Marginal Gingiva

Healthy gingiva could be characterized as the tissue having a coral pink color with varying degrees of pigmentation that embrace teeth in a collar-like fashion (Fig 6-3). The marginal gingiva follows a scalloped outline on the facial and lingual surfaces in a firm and resilient consistency that do not bleed on gentle probing. The clinical sulcus depth and bleeding on probing is clinically influenced by the status of gingival health, inflammation at the base of the sulcus, the diameter of the probe tip, the amount of probing force, probe angulation, and the location on the tooth.[7]

The contour of the gingiva varies considerably and is influenced by the shape of the teeth and their alignment in the arc, the location and the size of the area of proximal contact, and the thickness of the underlying alveolar bone (Fig 6-4). It forms a straight line along teeth with relatively flat surfaces. On teeth with pronounced mesio-distal convexity, or teeth in labial version, the scalloped contour is increased and the margin is thinned, and the gingiva is located farther apically. On teeth in lingual version, the gingiva is horizontal and thickened.

The level of gingival tissue normally mimics or follows the architecture of the underlying osseous crest (Fig 6-5). *Smukler* and *Chaibi*[8] report that the topography of the gingival margin was observed to relate to the underlying bone and to the surface anatomy of the teeth. In a healthy periodontium, the gingival margin was reported to be consistently parallel to the alveolar crest of bone, both labially and lingually. This parallel arrangement was also constant in the interdental concavities of tooth surfaces, where the tissues were seen to rise coronally, and on convex surfaces, where the tissues fell away apically. The accentuation of surface topography of teeth is reflected in the peaks and valleys of the osseous gingival continuum.

Thick, normal, and thin periodontal morphotypes can be defined according to the thickness of the gingiva and its bony component underneath (Fig 6-6). Thickness in the periodontal morphotype is a combination of factors such as the alveolar bone, gingival thickness, and the width of the tooth in the facial lingual plane. Subgingival margin placement should be avoided if possible in thin periodontal morphotypes since they are likely to recede even under minor chronic irritation or trauma.

Under ideal conditions at full smile the Vermillion border of the upper lip is expected to correspond with the tangential line drawn between the facial gingival margin of maxillary central incisors and cuspids. The gingival margin of the lateral

WWW.HIGHDENT.IR
همیار دندانسازان و دندانپزشکان

Fig 6-3 Surface texture, color, form and consistency of the gingiva correspond to the health status of the tissues. Stippling on the surface, coral pink color with varying degrees of pigmentation, scalloped outline that envelope teeth in a collar-like fashion are basic properties of healthy gingival tissues.

Fig 6-4 The contour of the gingiva is influenced by the shape of the teeth, their alignment in the arch and the thickness of the alveolar bone. The gingiva with scalloped contour is usually thinner and prone to recession with minor trauma. Thick gingival tissues display straight gingival contour, and are more resistant to trauma.

Fig 6-5a, b In healthy periodontium the gingival margin follows the architecture of the alveolar crest and the cementoenamel junction (CEJ).

Fig 6-6a-c (a) Thick, (b) normal and (c) thin periodontal morphotypes. Thickness of the periodontal morphotype is a combination of factors such as the alveolar bone, gingival thickness and alignment of the teeth in the dental arch. Thickness of the gingiva can be modified by appropriate surgical techniques to achieve an ultimate esthetic result.

WWW.HIGHDENT.IR
همیار دندانسازان و دندانپزشکان

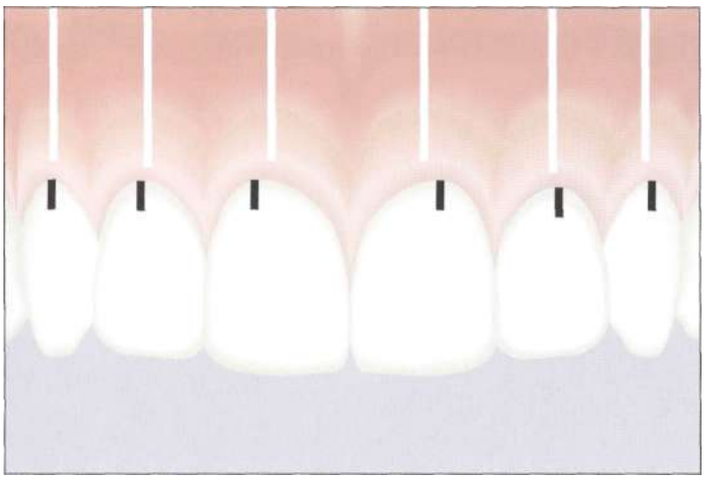

Fig 6-7 The most apical point of the marginal gingiva does not correspond with the midpoint at upper central and canines. The "zenith" is located at the distal line angles of those teeth. Lateral incisors have the zenith at the mid-facial. The "zenith" should be relocated by periodontal surgery in cases where diastema will be closed by restorative means.

incisors is usually located 1-2 mm more incisally, or at the same height of central incisor and cuspids. The height of the contour, or, as often called, the gingival zenith, is located at the distal line angle of the central incisors and cuspids (Fig 6-7). The maxillary lateral incisors have a symmetrical gingival height of contour with the gingival zenith at the midfacial tooth surface[9] (for detailed discussion of the ideal full smile see Chapter 2).

Clinical Features of Interdental Gingiva

The interdental gingiva occupies the space delineated within the area of tooth contact, interdental tip of the alveolar bone and tooth surfaces (Fig 6-8). The interdental gingiva can be pyramidal or have a "col" shape in the facial lingual direction. Increase in the facial-lingual diameters of teeth results in shift from pyramidial shape to col shape as observed in anteriorto posterior regions. Where the shape of the interdental gingiva is pyramidal there is only one tip of the tissue which is immediately under the contact point. *Cohen*[10] wasthefirstto describethe interdental papilla with two peaks, vestibularly and lingually, within a concave crest shaping the so-called col. The vestibular peak of the interdental papilla extends more coronally than the lingual one and the distance between those peaks increases from anterior to posterior (Fig 6-9).

The morphology of interdental gingiva is governed by the size, shape, and position of contact area between adjacent teeth and the level of underlying bone crest[11] (Fig 6-10). The interdental embrasure and the gingiva filling the space are narrow, mesiodistally, when the proximal surfaces of the teeth are relatively flat; buccolingually, the roots are close together, and the interdental bone is thin mesiodistally. Conversely, with proximal surfaces that flare away from the area of contact, the mesiodistal diameter of the interdental gingiva is broad. The location of the contact point is the result of the emergence profile and the line angle form of the maxillary incisors and cuspids.[12] Contact point between the maxillary central incisors is located in the incisal third of the labial aspect, between the central and lateral incisor in the middle, and between the lateral incisor and the canine in the apical third. The presence and the space occupied by the soft tissue is observed to be relevant to the distance from the contact to the crest of the alveolar bone. *Tarnow,* et al.[13] report that the papilla was present in all cases when the distance from the contact point to the crest of bone was 5 mm or less. A 1 mm increase in the distance from the contact point to the bone reduces the possibility of an intact papilla almost by half, in which papilla was present in 56% of the cases where the distance was 6 mm, and only 27% or less of the cases when this distance was 7 mm or more. Root angulation is another factor that affects interdental gingiva. Divergent angulation of the roots of two adjacent teeth creates a wider embrasure space and a contact point located incisally.

WWW.HIGHDENT.IR
همیار دندانسازان و دندانپزشکان

Fig 6-8 The base of the papilla corresponds to the line tangential to the gingival margins of adjacent teeth, while a healthy papilla reaches about half-way to the incisal edge, and shows a high degree of stippling. The papilla located between the central incisors is being the most challenging one by its location and volume.

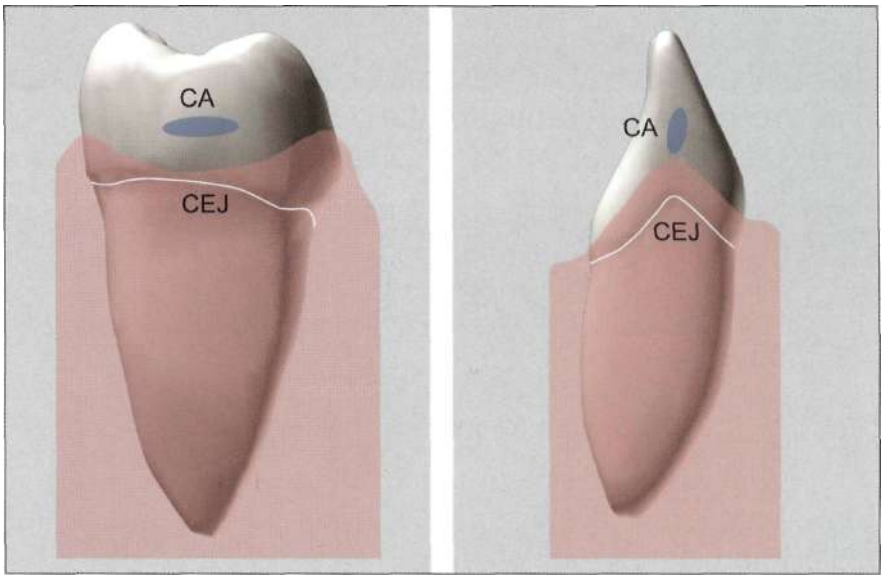

Fig 6-9 The interdental papilla has only one peak at the anterior teeth. The peak is located just apical to the contact area between two teeth. At the posterior teeth the papilla has two peaks and the concavity between two peaks is called the "col". The col is located just apical to the contact area and is not resistant to microbial irritation.

Fig 6-10 The interdental space is not filled with papilla in cases of diastemas. In such cases the interproximal gingival tissue shows a higher degree of keratinization.

WWW.HIGHDENT.IR
همیار دندانسازان و دندانپزشکان

Esthetic Periodontal Problems

Gingival Inflammation and Tissue Loss Owing to Periodontal Disease

Periodontal disease is the result of the accumulation of dental plaque at the gingival margin leading to inflammation of the periodontal tissues. Traditionally, periodontal disease has been divided into gingivitis and periodontitis, depending on whether destruction of the tooth-supporting tissues has occurred (Fig 6-11). Diagnosis and treatment of periodontal problems are based on clinical findings such as probing pocket depths, attachment loss, gingival bleeding, and radiographic evaluation of the alveolar crest. The objective of periodontal treatment can be summarized as the prevention of tooth loss, maintenance of periodontal support, repair, and regeneration of damaged tissues and theirfunction. But when the etiology of the periodontal disease is considered, the main task seems to be the modification of patient habits in order to constitute an oral hygiene level that would prevent inflammation of periodontal tissues owing to plaque accumulation.

Gingival inflammation and associated periodontal destruction are leading factors that can reverse the esthetic outcome in the long term. Establishing definitive restorations when inflammatory periodontal problems are present not only restrains esthetic success, but also accelerates the rate of periodontal destruction. Elimination of gingival inflammation is mandatory before initiation of any restorative treatment. Initial periodontal therapy that consists of oral hygiene instruction, elimination of retentive factors, scaling and root planing will result in the resolution of inflammation. Patients with moderate to severe periodontitis may require advanced periodontal treatment that could consist of surgical procedures to eliminate residual periodontal pockets and regeneration of the lost periodontal tissues. Pocket elimination surgery usually results in long clinical crowns that may be esthetically unacceptable. In deep isolated angular periodontal defects, guided tissue regeneration offers good results to maintain the tooth and avoid an esthetic disaster. Alveolar ridge deformities are inevitable after the extraction of hopeless teeth when special attention was not paid to preserving the height and width of the ridge at the time of extraction.

Restorative Margins and Violation of Biological Principles

Preservation of the healthy status of periodontal tissues is the most significant factor in the long-term prognosis of a restored tooth. There are five major causes of plaque-related inflammatory periodontal disease associated with restorative procedures:

1. severe damage to the periodontal tissues during tooth preparation and impression making
2. failure to maintain emergence profile
3. inability to adequately finish and/or seal subgingival margins
4. placement of subgingival margins at sites with minimum to no attached gingiva
5. violation of the biologic width.

Teeth prepared without retraction cord which subsequently receive either retraction cord, electrosurgery, or rotary gingival curettage sustain various degrees of soft tissue damage, as reported by *Dragoo* and *Williams.*[14,15] Tooth preparations for restorative procedures should be accomplished atraumatically to avoid irreversible damage to the supracrestal connective tissue fibers and tissue loss.

The cervical one-third of the clinical crown is also referred to as the emergence profile of the tooth. This is the region where the crown emerges from the periodontium and its supra-subgingival contours should have a flat emergence profile, with the guidance of anatomic information in order to maintain an area that is cleanable with oral hygiene instruments and which has a good marginal seal of the restoration (Fig 6-12). There is a very strict relationship between marginal seal and emergence profile.[16] Poor adaptation and roughness of the restoration margin results in mechanical irritation of the sulcular epithelium and can harbor microbial flora.[17] Overhanging margins not only accumulate more plaque than

WWW.HIGHDENT.IR
همیار دندانسازان و دندانپزشکان

Fig 6-11 Chronic gingivitis is the inflammation of the marginal gingival tissue owing to plaque accumulation and is characterized clinically by redness, swelling and bleeding of the tissues. There is no destruction of the alveolar bone. Periodontitis, on the other hand, is the plaque-induced inflammation of the periodontal tissues that has resulted in destruction of the periodontal ligament and alveolar bone with apical migration of junctional epithelium.

WWW.HIGHDENT.IR
همیار دندانسازان و دندانپزشکان

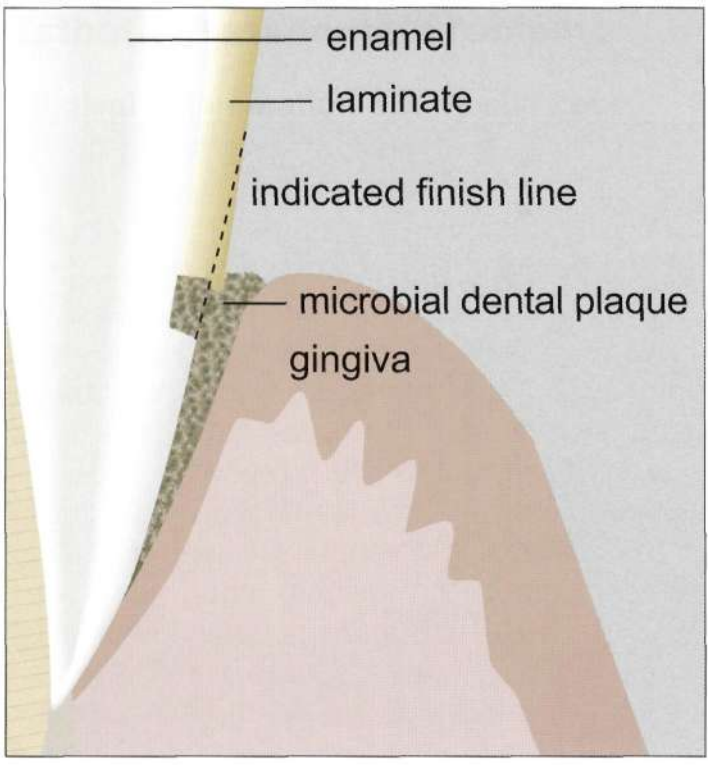

Fig 6-12 The interface between the laminate and the tooth should not facilitate plaque retention and should always be cleanable with oral hygiene instruments. The restoration surface should be flush with the surface of the remaining tooth structure.

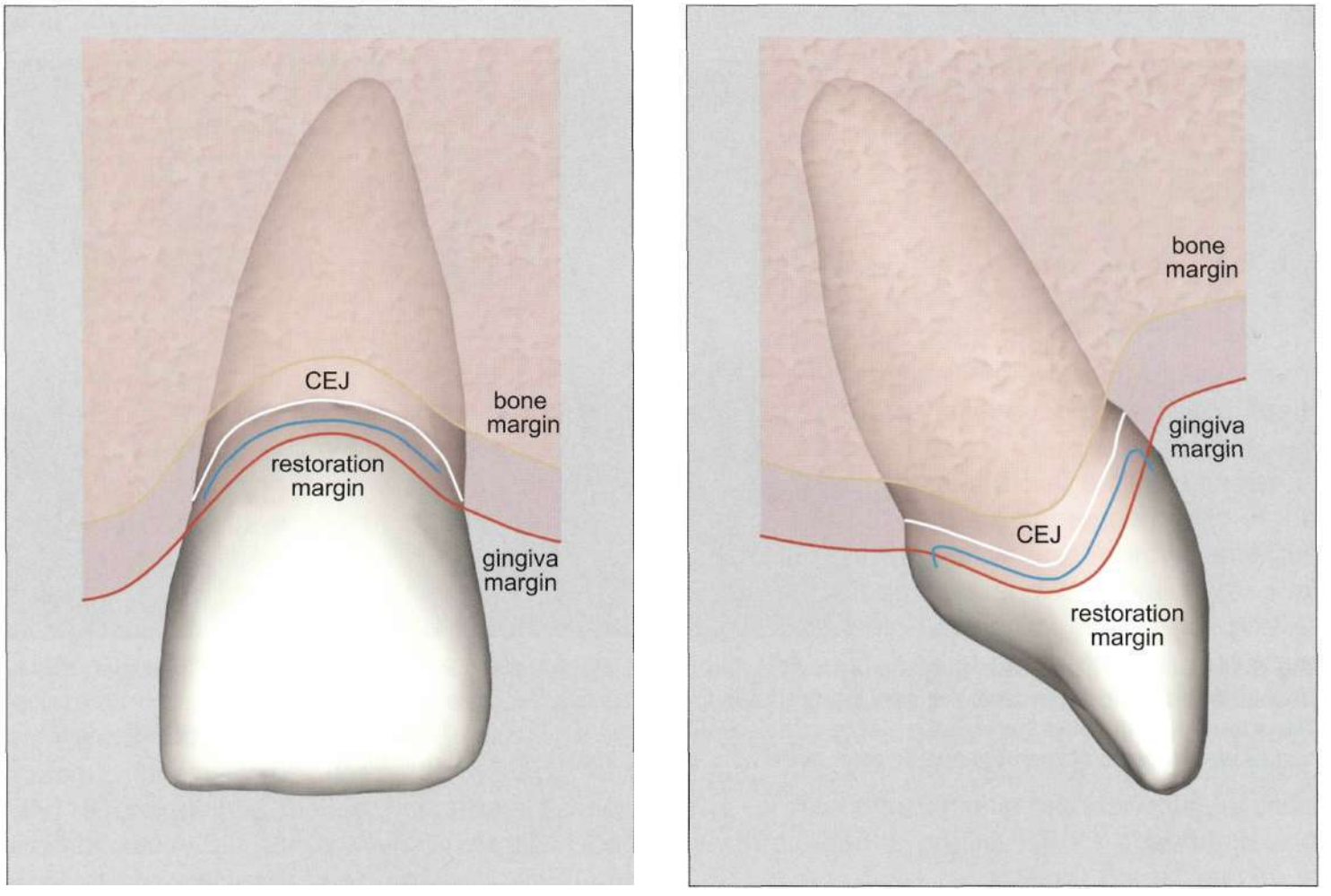

Fig 6-13 The margin of the restoration should follow the accentuation of the CEJ. The minimum distance required to maintain periodontal health is 2.5 mm from the restoration margin. Violation of this principle results in inflammation of the junctional epithelium and connective tissue attachment, and eventually marginal bone loss.

WWW.HIGHDENT.IR
همیار دندانسازان و دندانپزشکان

Fig 6-14 Maxillary central incisors require special attention since two teeth are adjacent and asymmetries could easily be detected. Lateral incisors, cuspids and bicuspids are also important but the distance between two identical teeth conceals minor asymmetries in most cases.

properly finished margins, but the plaque undergoes a shift in composition to that seen in association with destructive periodontitis.[18]

An adequate band of keratinized tissue is fundamental to successful restorative dentistry if the margins of the restorations are extended under free gingival margin.[17] Approximately 5 mm of keratinized tissue, composed of 2 mm of free gingiva and 3 mm of attached gingiva, is considered necessary to meet restorative objectives even in cases with ideal finishing and margin placement at the subgingival area.[17] Although no solid investigation is present to confirm this observation, augmentation of keratinized gingiva provides stability of the free gingival margin and surrounding gingival tissues so that the gingival health around the restoration can be maintained. Besides vertical dimension of the keratinized gingiva, the thickness of the tissue should be enough to tolerate intracrevicular restorations.

The gingival sulcus extends from the free gingival margin to the epithelial attachment. In health, its depth is in the vicinity of 0-3 mm,[1] and it is lined with thin sulcular epithelium. The depth of this sulcus may vary from tooth to tooth and from surface to surface on the same tooth. Compromising the apico-coronal width of the connective tissue attachment by placement of crown margins deep in to the sulcus initiates persistent and irreversible gingival inflammation owing to violation of the biologic width. Such violations sever the junctional epithelium and the supragingival connective tissue fibers. Apical migration of thejunctional epithelium encourages development of periodontal pockets and alveolar bone loss. The finish line of restorations should follow the contour ofthecementoenamel junction and be always kept at least 2.5 mm away from the bone crest (Fig 6-13). A 2.5-mm difference means that although the biologic width is being respected, the finish line is located near the base of the crevice. A greater distance between the bone crest and finish line of the restoration is needed to ensure that margin of the restoration could be well reached by the plaque control instruments. The golden standard today is to prepare the finish lines of the restorations 0.5 mm below the marginal gingiva if the sulcus depth is 1 mm, 0.5 to 1 mm if the sulcus depth is exceeding 1.5 mm. This leaves enough distance for the junctional epithelium and supracrestal fibers, and is also close enough to the gingival margin to be reached by oral hygiene procedures. When the healthy sulcus depth is less than 1 mm, placement of the margin 0.5 mm subgingival could result in impinging upon the junctional epithelium. The margin in such cases should be terminated just at or above the gingival margin.

Gingival asymmetries and discrepancies

The esthetic appearance is considerably affected by the symmetry created by dental and facial midline (Fig 6-14). In the etiology of gingival asymmetries, altered passive eruption, different patterns of tooth wear, traumas that modify tooth

WWW.HIGHDENT.IR
همیار دندانسازان و دندانپزشکان

Fig 6-15 High, medium and low lip lines. Gingival margins of upper teeth and the vermilion border of the upper lip are the important landmarks in determining the level of the lip line. Esthetic treatment planning is complicated in patients with a high lip line.

eruption, tooth positioning in the dental arch, parafunctional habits and overzealous tooth brushing should be considered. The selection of an adequate method of treatment depends on adequacy of attached gingiva, tooth structure, vestibular depth, the distance from the gingival margin to the crest of the bone, root angulation and tooth positioning and interproximal level of the alveolar bone when recession is present. Correction of this disharmony requires surgical elongation or root coverage, orthodontic treatment and restorative procedures.

Excessive Gingival Display

"Gummy smile" can be considered as a significant esthetic problem by many patients. Ideally, the smile should expose minimal gingiva around the lateral incisors. The gingival margins of maxillary central incisors and cuspidsshould coincide with the vermillion border of the upper lip. The lip line, assessed when the patient is in full smile, is classified as high (gummy smile), medium (ideal), and low (maxillary lip covering a portion of maxillary teeth) (Fig 6-15). Aging leads to a decrease in the amount of anterior tooth display when smiling.[19] Maxillary overgrowth, insufficient upper lip, tooth malpositioning, and delayed apical migration of the gingival margin or a combination of more than one are among the most common reasons of "gummy smile".

Skeletal deformities that involve maxillary overgrowth can be diagnosed by evaluation of the proportions of the face and cephalometric analysis. In such cases the teeth's length-to-width ration usually remains constant - the ideal being approximately 10:8.[20] The ideally proportioned face is divided into three equal parts from the hairline to the eyebrow, from the eyebrow to the base of nasal process, and from the base of the nose to the chin. When the middle one-third of the face is longer than other two, "gummy smile" is diagnosed owing to maxillary overgrowth. In combined cases that maxillary overgrowth is superimposed with delayed passive eruption and the latter should be treated first. Treatment limited to periodontal surgery will be insufficient, since the level of the incisal edge to lip at rest position cannot be rebuilt. Minor maxillary overgrowth cases can be successfully treated with periodontics-orthodontics or periodontics-restorative combinations. Increase in the gingival and mucosal display necessitates complex treatment options that combine orthognathic-orthodontic procedures and perio-prostho treatment.

The normal length of the upper lip is between 18 and 21 mm, vertically. A shorter lip over a moderate dental arch could result in excessive gingival display. When the "gummy smile" is solely dependent on insufficient lip dimensions, a perio-restorative solution composed of surgical crown lengthening and restoring the teeth with laminates could be the choice of treatment.

A less frequent reason of excessive gingival display is the tooth malpositioning. Orthodontic repositioning and surgical correction are the treatment options in those cases.

WWW.HIGHDENT.IR
همیار دندانسازان و دندانپزشکان

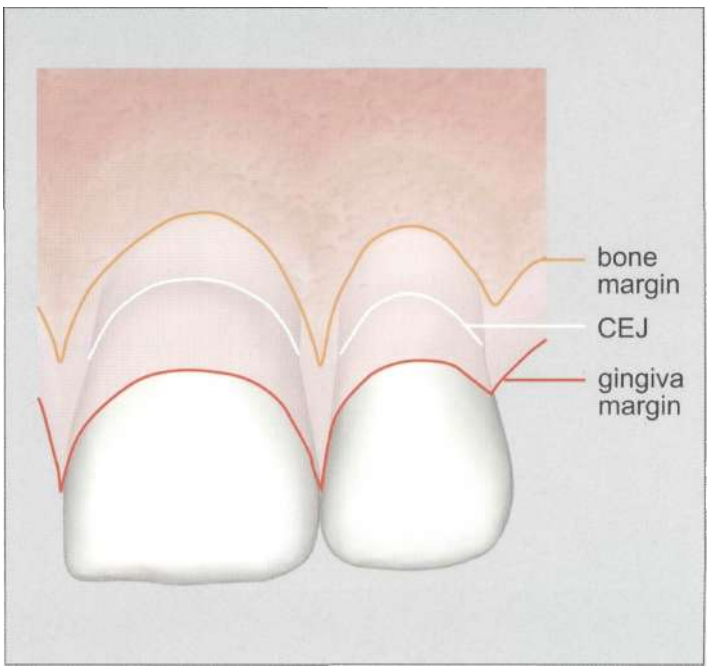

Fig 6-16 Square tooth form with thick and fibrotic gingival tissues indicates delayed passive eruption. Probing pocket depth measurements exceed 3 mm and the CEJ is at its base or underneath the bottom of the sulcus in such cases. The distance from the gingival margin to the crest of the bone is increased.

The last but not least reason for the excessive gingival display is the delayed passive eruption, or what some authors call "altered passive eruption". Passive eruption isthe exposure of teeth by apical migration of the gingiva, whereas active eruption is the movement of teeth in the occlusal direction. When the teeth reach their functional antagonists, the gingival sulcus and junctional epithelium are still on the enamel, and the clinical crown is approximately two-thirds of the anatomic crown.[21] Delay in the apical migration of the marginal gingiva and the junctional epithelium results in a condition in adulthood in which the gingival margin is positioned incisallyorocclusally on the anatomic crown and does not approximate the CEJ.

When the gingiva is not inflamed but thick and fibrotic, and displays a nominal degree of scallop to the free gingival margin resulting in a square tooth form, delayed passive eruption should be suspected (Fig 6-16). Diagnosis is made by probing the sulcus and sounding the alveolar bone margin to determine their relationship with CEJ. Clinical and anatomic crown length, width of the attached gingiva, tooth positioning and involvement of frenum are additional factors in diagnosis and treatment planning.

There are two types of delayed passive eruption, as proposed by *Coslet,* et al.[22] (see Table 6-1). In this classification, gingival/anatomic crown relationship is divided into two major groups. In type 1 cases, the gingival margin is located incisal or occlusal to the CEJ, with a wide zone of attached gingiva, and the mucogingival junction is usually apical to the alveolar crest (Fig 6-17). There is typically an excessive amount of gingiva as measured from the free gingival margin to the mucogingival junction. In type 2 cases the mucogingival junction is located at the level or near CEJ where the band of attached gingiva is in the normal range as measured from the free gingival margin to the mucogingival junction (Fig 6-18). The major distinction between two types is the location of the mucogingival junction, which also serves as a useful guideline in the treatment planning. A further subdivision evaluates the alveolar crest and CEJ relationships (Fig 6-19).

Treatment options of delayed passive eruption should be based on diagnosis of the type. A typical case of type IA delayed passive eruption

WWW.HIGHDENT.IR
همیار دندانسازان و دندانپزشکان

Fig 6-17 Delayed passive eruption type 1. Wide zone of attached gingiva. The case is treated with gingivectomy procedure since there is a wide band of attached gingiva.

Fig 6-18 Delayed passive eruption type 2. Normal width of the attached gingiva. Normal width of the attached gingiva excludes the treatment choice of a gingivectomy procedure. An apically located flap procedure is needed to maintain the width of the attached gingiva.

Table 6-1 Classification of Delayed Passive Migration of the Gingival Margin

Type	A	B
1. Short clinical crowns with mucogingival junction being apical to the alveolar crest. Wide band of attached gingiva.	Alveolar crest to CEJ > 2 mm	Alveolar crest to CEJ < 2 mm
2. Short clinical crowns with mucogingival junction being at the level or near CEJ. Normal band of attached gingiva.	Alveolar crest to CEJ>2 mm	Alveolar crest to CEJ < 2 mm

WWW.HIGHDENT.IR
همیار دندانسازان و دندانپزشکان

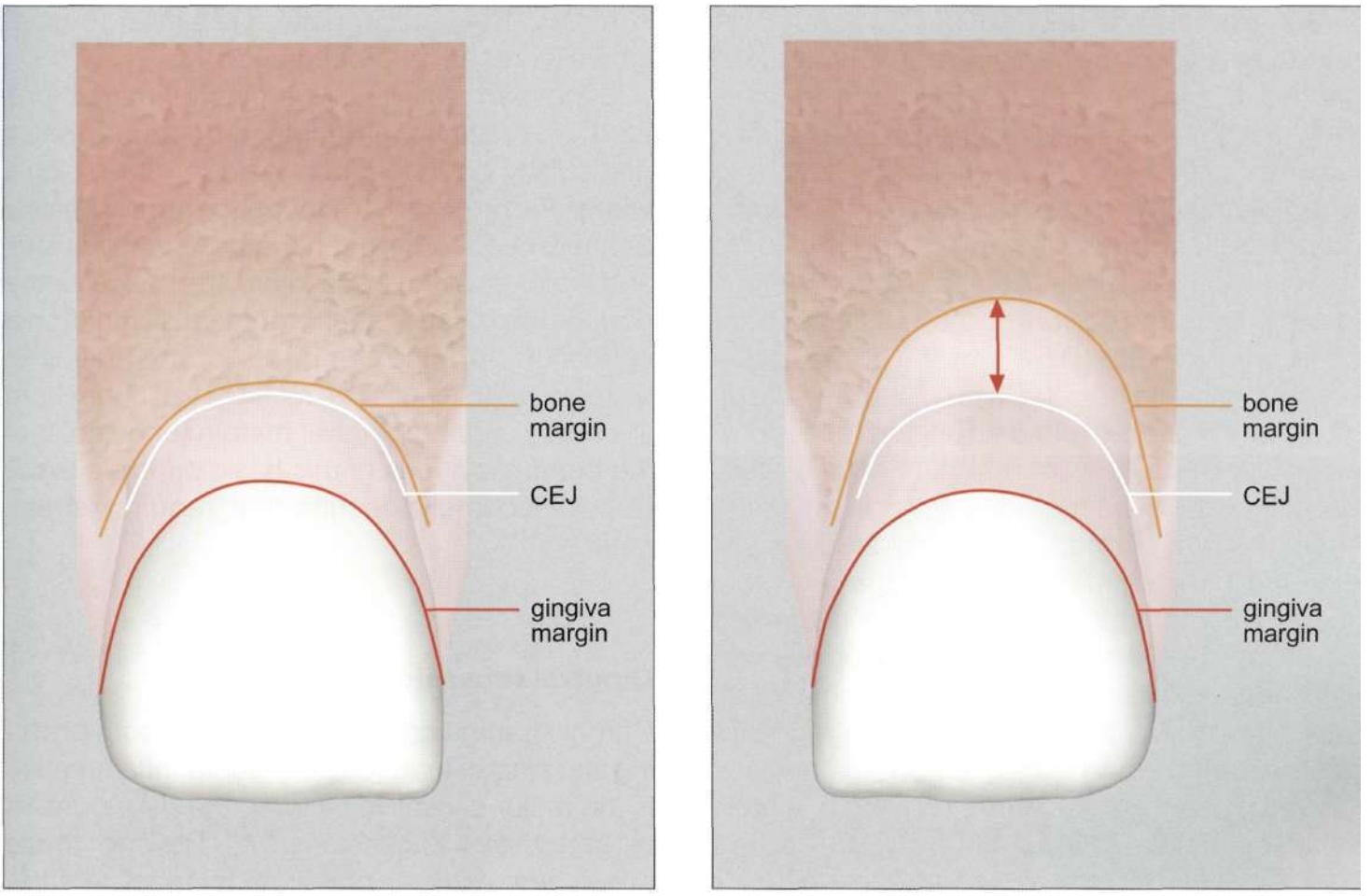

Fig 6-19 Alveolar crest-CEJ relationship in delayed passive eruption cases. In subgroup A, the distance from CEJ to the crest of the alveolar bone corresponds to the 2 mm distance, which is accepted as normal. In cases of subgroup B, the alveolar crest is almost at the level of CEJ.

exhibits short, square-looking teeth with a wide zone of attached gingiva and confirms the presence of sufficient space (biologic width) to maintain supracrestal fiber attachment on transgingival probing. A gingivectomy procedure performed by a scalpel, electrosurgery or CO2 laser can remove the excess tissue (Fig 6-17). Tissue removal should be performed very carefully in order not to compromise interdental papilla and end up with some loss at the gingival tissue filling the embrasures. Removal of the tissue will result in more elliptical tooth form that restores the 10:8 length to width ratio. Initial wound healing takes place in the first couple of weeks where remodeling of the soft tissue continues for as long as 4 to 6 months.

Treatment options of type IB delayed passive eruption cases should create sufficient space for supracrestal fiber attachment to maintain the proper biologic width while eliminating the excess gingiva. In type IB cases there is an added dimension buccolingually to the osseous form.[23] This extra thickness of osseous structure allows for an apical angulation of the bone crest from the gingival aspect of the periodontal ligament side allowing for insertion of the connective tissue fibers just apical to the CEJ. Surgical correction of this reverse anatomy requires relocation of the alveolar crest, thinning of the alveolar margin, and securing enough space for development of proper biologic width (Fig 6-18). Since the level of gingival tissue normally followsthe architecture of the underlying osseous crest, alveolar reduction should meticulously be performed in order to dictate the final gingival level and contour at the time of bony recontouring. The height of the inter-

WWW.HIGHDENT.IR
همیار دندانسازان و دندانپزشکان

proximal bone should always be 3 to 4 mm coronal to the height of the newly created alveolar crest on the facial aspect in order to support the interproximal papilla. Surgical crown lengthening requires reflection of full thickness flaps and recontouring of the alveolar bone with chisels and burs. Surgical trauma owing to full thickness reflection of the access flap and bone recontouring results in resorption of the crestal alveolar bone approximately 0.63 mm.[24] This inevitable bone loss should be calculated at the time of surgical planning to prevent unexpected recessions, especially in cases with thin gingiva and facial alveolar plate where more bone loss is expected.

On the other hand, in a clinical study it was reported that a 3 mm biological zone was not routinely achieved after surgical crown lengthening procedure, and the amount of root surface was still short of the initially planned biologic width after healing.[25] A histometric study in monkeys demonstrated that healing following osseous crown lengthening procedure resulted in a junctional epithelium that extended to the apical level of root planing, reestablishing a reduced biologic width.[26] Scaling and rootplaning during crown lengthening was recommended to enable the surgeon accurately to determine the superior termination of thesupracrestal connective tissue, since space forthesupracrestal connective tissue fiber groups is created by crestal resorption of alveolar bone.[26] Initial wound healing takes around 10 days after surgery, and final remodeling usually continues for as long as 6 months, but the tissue reaches a stable position after 6 weeks. Gentle handling of the tissues and strict adherence to plastic surgery principles shortens healing and remodeling periods.

Treatment of type II cases requires relocation of the entire dentogingival complex to a more apical position without rendering loss of attached gingiva with or without removal of the bony margin. Loss of attached gingiva results in alveolar mucosa located at the gingival margin that jeopardizes maintenance of the marginal health, and unacceptable esthetics. Attached gingiva must be preserved at crown-lengthening procedures in such cases by reflection of full to split thickness flap and apical positioning of the mucogingival complex. The healing pattern is similar to other crown-lengthening procedures.

Long-term stability of the gingival margin created by crown-lengthening procedures relies particularly on the respect paid for the biologic width. As previously mentioned, approximately 2 mm is needed between the base of the sulcus and the crest of the bone to provide space for the connective tissue attachment and junctional epithelium. Adding the depth of the sulcus to biologic width results in a minimum of 3 mm from the newly created gingival margin to the crest of the bone. Violations of this basic principle result in poor cosmetic results that require retreatment.

Gingival recessions

Chronic trauma caused by vigorous tooth brushing and plaque-induced periodontal inflammation is the major causative factor in the development of soft tissue recessions.[27,28] Beyond those two major causes, malpositioning of teeth,[29] dehiscence in vestibular alveolar plate,[30] high frenum,[31] and iatrogenic factors[32] contribute significantly in the etiology of recessions. Elimination of those factors is crucial in both prevention and treatment of recessions in a predictable long-term outcome. *Sullivan* and *Atkins*[33] made initial classification of the marginal tissue loss in two major vertical categories of shallow and deep recessions with horizontal subgroups as "narrow" and "wide". This classification was used until 1985 when *Miller*[34] presented an expanded classification (Fig 6-20). Based on this classification, the amount of root coverage can be determined presurgically. Total root coverage is expected in class I and II cases. In class III cases, the amount of root coverage can be estimated presurgically by placing a periodontal probe horizontally on an imaginary line connecting the tissue level on the mid-facial of the two teeth on either side of the tooth exhibiting recession. This is a very practical and important classification for the clinical decision-making process, because it allows the practitioner and the patient to have realistic expectations regarding the outcome of the case.

WWW.HIGHDENT.IR
همیار دندانسازان و دندانپزشکان

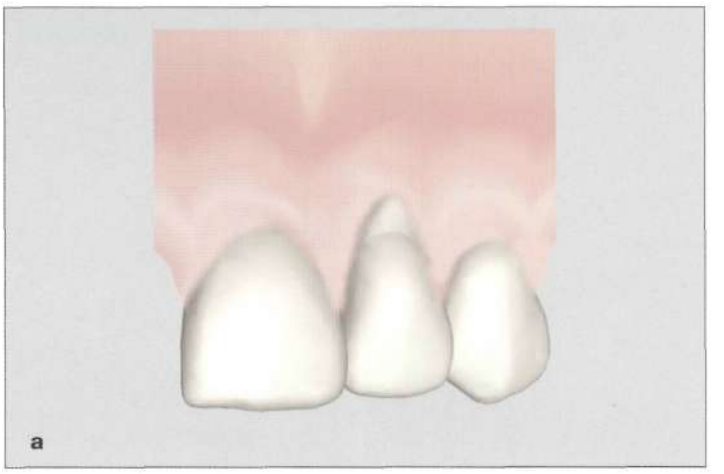

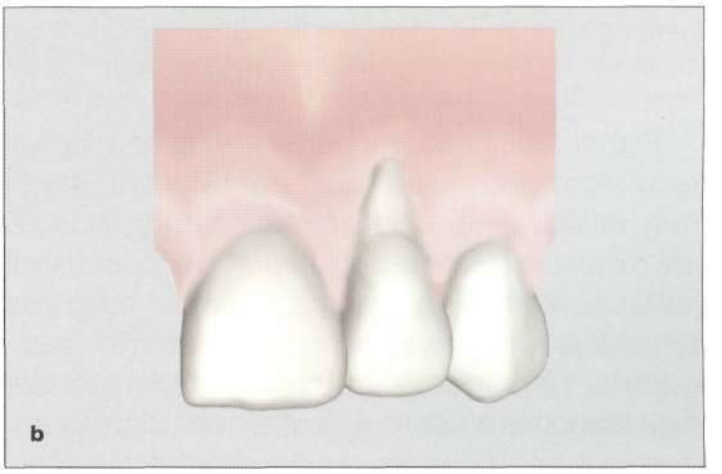

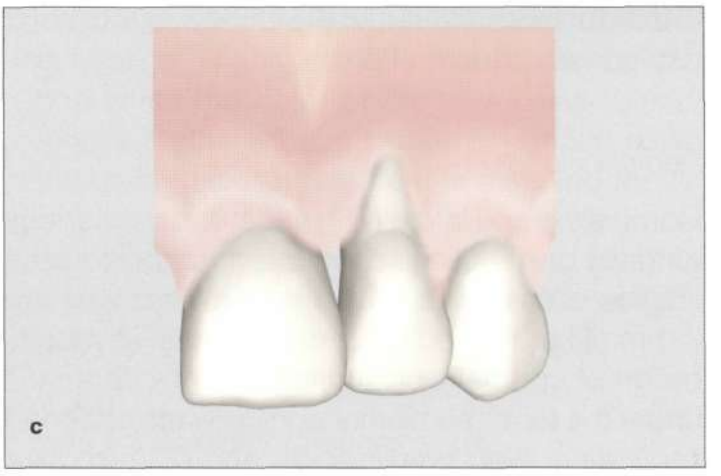

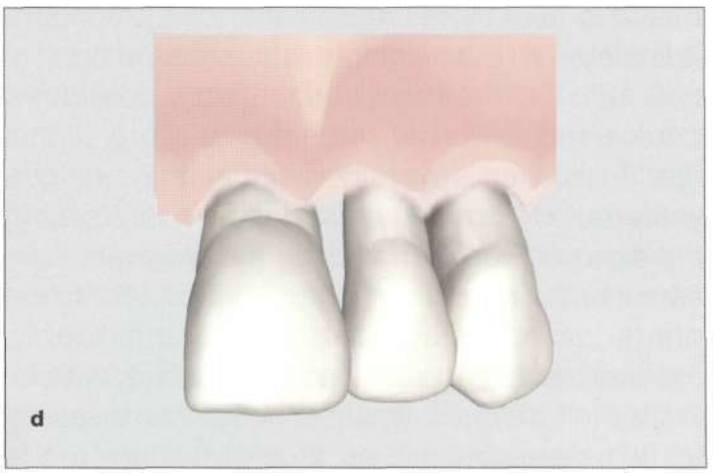

Fig 6-20a-d Classification of gingival recessions, (a) Class I: Marginal tissue recession that does not extend to the mucogingival junction. There is no periodontal loss (bone or soft tissue) in the interdental area, and 100% root coverage can be anticipated, (b) Class II: Marginal tissue recession that extends to or beyond the mucogingival junction. There is no periodontal loss (bone or soft tissue) in the interdental area, and 100% root coverage can be anticipated, (c) Class III: Marginal tissue recession that extends to or beyond the mucogingival junction. Bone or soft tissue loss in the interdental area is present, or there is malpositioning of the teeth that prevents the attempting of 100% root coverage. Partial root coverage can be anticipated, (d) Class IV: Marginal tissue recession that extends to or beyond the mucogingival junction. The bone or soft tissue loss in the interdental area and/or the malpositioning of the teeth is so severe that root coverage cannot be attempted.

WWW.HIGHDENT.IR
همیار دندانسازان و دندانپزشکان

Fig 6-21 Laterally positioned pedicle flap procedure offers the advantage of single surgical site and a good supply of blood with an excellent color match. Good blood supply shortens the healing phase and minimizes the risk of complications. The major limitation is the lack of sufficient donor tissue lateral to the defect. Three weeks after surgery, as seen in the case, tissue has matured to a great extent despite the debris and poor plaque control.

Besides esthetic concerns owing to gingival recessions, increased root sensitivity and sensitivity related gingival inflammation and/or decay are major problems associated with exposed root surfaces. With the growing concern for cosmetic dentistry, and the subsequent need for periodontal procedures that would meet patient expectations, numerous techniques have been developed to cover the exposed root surfaces. Those techniques fall into the following four major categories.

Pedicle Flaps

Coronally[35] and laterally[36] positioned contiguous gingival grafts. The technique is used to treat shallow areas of recession *(Miller* class I) where 3 mm of keratinized tissue is present.[37] A modification of coronally positioned flaps by *Tarnow*[38] under the term "semilunar coronally repositioned flap" offers high predictability and superb color match to treat class I recessions. This procedure is limited with the height and thickness of the gingiva apical to the recession. Laterally positioned pedicle flap (called by some clinicians "rotational flap") received several modifications over the years but the fundamental principle is covering the exposed root surfaces by the gingival tissue lateral to the recession (Fig 6-21). This technique offers the advantages of good blood supply, excellent match of color, and a single surgical site. On the other hand, limitations like the necessity for adequate dimensions of gingiva lateral to the site of recession, as well as its inability to treat multiple recessions and its requirement of deep vestibule, confines its application to cases of single recession with an adequate amount of neighboring attached gingiva.

Free Autogenous Soft Tissue Grafts

Free gingival[39] and subepithelial connective tissue[40] grafts have been reported to be predictable and successful ways of root coverage. Free gingival grafts are utilized to increase the zone of attached gingiva around teeth and implants, and to cover the exposed root surfaces. Having the palatal mucosa on the surface 1.5-2 mm thick, free gingival grafts heal in a lighter and more opaque color than the gingiva at the recipient site, and it increases the gingival thickness. Meta-analytic review of success rate of the free gingival grafts revealed a high predictability in classes I and II recessions with mean root coverage around 75%, and complete root coverage incidence 50%.[41] Subepithelial connective tissue graft is also used in root coverage surgery. The procedure takes advantage of a double blood supply from the recipient bed and the gingival flap that covers the graft. It generally results in a better color match, but increased thickness can compromise esthetics in the healing period until the remodeling process is completed within a year (Fig 6-22a and b). The major contraindication to this approach is the inability to harvest adequate thickness of donor material from the palate. Mean root

WWW.HIGHDENT.IR
همیار دندانسازان و دندانپزشکان

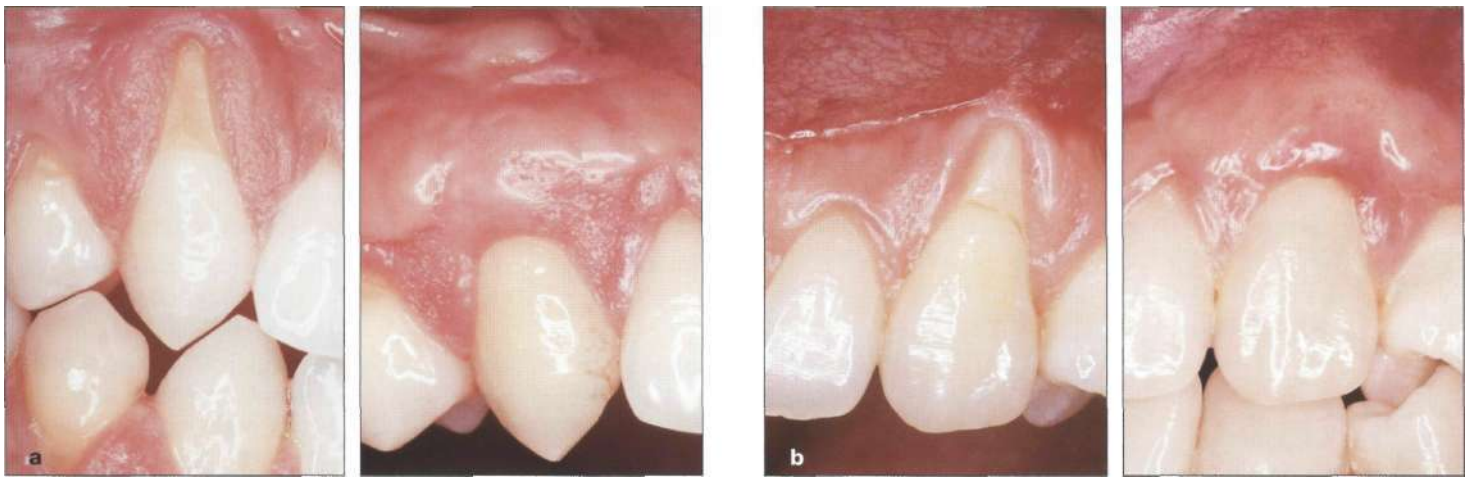

Fig 6-22a, b (a) Although full maturation of the thick subepithelial connective tissue grafts takes a long time, a thick and well-matched color can be obtained within a year. Thick gingival tissue is more important in cases where root prominence is evident, (b) The surface characteristics of thin grafted tissue mature in a shorter period of time. Color match is acceptable and the band of attached gingiva is increased.

coverage and total root coverage incidence is very high in classes I and II cases and reported to be 91% and 68% respectively.[41]

Combined Techniques

These are surgical proceduresthat combine more than one technique either in the same stage or at a second stage of surgery. Free gingival graft with a coronally positioned flap is a common example of this approach. Either a gingival graft is placed simultaneously with the coronally positioned flap, orfollowing placement of a gingival graftthe entire complex is moved coronally at a second surgical procedure. Another common combination is the root surface coverage with a subepithelial connective tissue graft and sliding the lateral two papillae over the grafted tissue. Other clinicians have suggested several more combinations to furnish the requirements of specific cases, but none has become popular and widely used.

Guided Tissue Regeneration

The technique is based on the principle to provide and maintain an adequate space to allow formation of a blood clot that is expected to transform into new cementum, new connective tissue attachment, and new bone. Results obtained by resorbable and non-resorbable membranes to cover exposed root surfaces are comparable with subepithelial connective tissue grafts,[42] and can be used in the treatment of deep and wide (larger than 5 mm) facial recessions. No requirement for a donor site reduces patient discomfort during healing. Highly esthetic results can be provided since the color of the new tissue blends evenly with the adjacent sites. The main disadvantage is that the treatment is reserved for single tooth application. The specific use is limited to the cases that lacks donor tissue and attached gingiva until improved GTR devices and surgical methods are developed.

Open Interproximal Spaces

Reconstruction of the lost interdental papilla is one of the most challenging and least predictable problems in periodontal plastic surgery. Besides creating a black triangle at the maxillary anterior region, missing interdental papilla results in food impaction and phonetic problems. The presence and morphology of the interdental papilla is strictly dependent on the size and shape of interproximal contact, crest of alveolar bone, and shape of lateral tooth surfaces, as stated earlier.[11] Reconstruction of the lost interproximal tissues therefore requires techniques that reestablish

WWW.HIGHDENT.IR
همیار دندانسازان و دندانپزشکان

Fig 6-23 Subepithelial connective tissue grafts (especially thick ones) are a good alternative in creating papillae where interproximal bone loss is minimum. Primary good blood supply must be accomplished by choosing an atraumatic technique with the periosteum left intact.

the prerequisites of the presence of the papilla. Nonsurgical and prosthetic approaches may alter the contact point, lateral tooth structure and tooth angulation resulting in restoration of the lost interdental tissue. Surgical techniques that aim to increase the gingival soft tissue and bone content of the interproximal spaces are complicated with the anatomic limitations and the blood supply problem. Several surgical techniques have been suggested in case reports for reconstruction,[43,,45] but none of them seems to be sufficient and predictable to restore the lost tissue. Limited success has been attained by soft tissue grafts (Fig 6-23). Regeneration of the interproximal alveolar bone seems to be the ultimate treatment method to achieve papilla reconstruction keeping in mind that the gingival contour follows the crestal alveolar bone and that the distance from the bone crest to the contact area dictates the interdental soft tissue level.

WWW.HIGHDENT.IR
همیار دندانسازان و دندانپزشکان

References

1. GargiuloAW, WentzFM, Orban B. Dimensions and relations of the dentogingival junction in humans. J Periodontol 1961;32:261-267.
2. Hassell TM. Tissues and cells of the periodontium. Periodontology 2000 1993;3:9-38.
3. Freeman E. Periodontium. In: Oral Histology: Development, Structure, and Function. 4th ed. Ten Cate, AR ed. St Louis, MO: Mosby, 1994:276-313.
4. Cohen DW. Periodontal preparation of the mouth for restorative dentistry. Presented at the Walter Reed Army Medical Center, Washington, DC, 1962. Cited from note 8.
5. Nevins M, Skurow H. The intracrevicular restorative margin, the biologic width, and the maintenance of the gingival margin. Int J Periodont Rest Dent 1984;4:30-49.
6. Kois JO New paradigms for anterior tooth preparation: Rationale and technique. Contemp Esth Dent 1996;2:1-8.
7 Periodontal literature reviews: A su mmary of current knowledge. Chicago: American Academy of Periodontology, 1996:36-39.
8. Smukler H, Chaibi M. Periodontal and dental considerations in clinical crown extension: A rational basis for treatment. Int J Periodont Rest Dent 1997;17:465-477.
9. Allen EP. Surgical crown lengthening for function and esthetics. Dent Clin North Am. 1993;37:163-179.
10. Cohen B. Pathology of the interdental tissues. Dent Pract 1959;9:167-173.
11. Kohl JT, Zander HA. Morphology of interdental gingival tissues. Oral Surg Oral Med Oral Pathol 1961;60:287-295.
12. Miller PD, Allen EP. The development of periodontal plastic surgery. Periodontology 2000 1996;11:7-17.
13. Tarnow DP, Magner AW, Fletcher P. The effect of the distance from the contact point to the crest of bone on the presence *or* absence of the interproximal dental papilla. J Periodontol 1992;63:995-996.
14. Dragoo MR, Williams GB. Periodontal tissue reactions to restorative procedures. Part 1. Int J Periodont Rest Dent 1982;2:8-29.
15. Dragoo MR, Williams GB. Periodontal tissue reactions to restorative procedures. Part 2. Int J Periodont Rest Dent 1982;2:34-42.
16. Martignoni M, Schbnenberger A. Precision fixed prosthodontics: Clinical and laboratory aspects. Chicago: Quintessence, 1990:255-258.
17. Maynard JG, Wilson RD. Physiologic dimensions of the periodontium significant to the restorative dentist. J Periodontol 1979;50:170-174.
18. Lang NP, Kiel RA, Anderhalden K. Clinical and microbiological effects of subgingival restorations with overhanging or clinically perfect margins. J Clin Periodont 1983; 10: 563-578.
19. Vig RG, Brundo GO The kinetics of anterior tooth display. J Prosthet Dent 1978;39:502-504.
20. Borissavlievitch M. The Golden Number. London: Alec Tiranti, 1964.
21. Itoiz ME, Carranza FA. The gingiva. In: Carranza FA, Newman MG. Clinical Periodontology. 8th ed. Philadelphia: WB Saunders, 1996:12-29.
22. Coslet JG, Vanarsdall RL, Weisgold A. Diagnosis and classification of delayed passive eruption of the dentogingival junction in the adult. Alpha Omegan 1977;70:24-28.
23. Garber DA, Salama MA. The aesthetic smile: Diagnosis and treatment. Periodontol 2000 1996;11:18-28.
24. Pennel B, King K, Wilderman M, Barron J. Repair of the alveolar process following osseous surgery. J Periodontol 1967;38:426-431.
25. Herrero F, Scott JB, Maropis PS, Yukna RA. Clinical comparison of desired versus actual amount of surgical crown lengthening. J Periodontol 1995;66:568-571.
26. Oakley E, Rhyu IC, Karatzas S, Gandini-Santiago L, Nevins M, Caton J. Formation of the biological width following crown lengthening in nonhuman primates. Int J Periodont Rest Dent 1999;19:529-541.
27 Loe H, Anerud A, Boysen H. The natural history of periodontal disease in man: Prevalance, severity, and extent of gingival recession. J Periodontol 1992;63:489-495.
28. Khocht A, Simon G, Person P, Denepitiya JL. Gingival recession in relation to history of hard toothbrush use. J Periodontol 1993; 64: 900-905.
29. Kallestal C, Uhlin S. Buccal attachment loss in Swedish adolescents. J Clin Periodont 1992; 19: 485-491.
30. Lost C. Depth of alveolar bone dehiscences in relation to gingival recessions. J Clin Periodont 1984;11:583-589.
31. Mirko P, Miroslav S, Lubor M. Significance of the labial frenum attachment in periodontal disease in man. Part 1. Classification and epidemiology of the labial frenum attachment. J Periodontol 1974;45:891-894.
32. Stetler KJ, Bissada NF Significance of the width of keratinized gingiva on the periodontal status of teeth with submarginal restorations. J Periodontol 1987;58:696-700.
33. Sullivan HC, Atkins JH. Free autogenous gingival grafts. 3. Utilization of grafts in the treatment of gingival recession. Periodontics 1968;6:152-160.
34. Miller PD. A classification of marginal tissue recession. Int J Periodont Rest Dent 1985;5:8-13.
35. Harland AW. Discussion of paper: Restoration of the gum tissue. Dent Cosmos 1907;49:591-598.
36. Grupe HE, Warren RF Jr. Repair of gingival defects by a sliding flap operation. J Periodontol 1956;27:290-295.
37 Allen EP, Miller PD Jr. Coronal positioning of existing gingiva: Short term results in the treatment of shallow marginal tissue recession. J Periodontol 1989; 60: 316-319.
38. Tarnow DP. Semilunar coronally repositioned flap. J Clin Periodontol 1986;13:182-185.
39. Miller PD Jr. Root coverage using a free soft tissue autograft following citric acid application. Part 1. Technique. Int J Periodont Rest Dent 1982; 2: 65-70.
40. Langer B, Langer L. Subepithelial connective tissue graft technique for root coverage. J Periodontol 1985;56:715-720.

WWW.HIGHDENT.IR
همیار دندانسازان و دندانپزشکان

41. Efeoglu A, Demirel K, Okan E. Diseti gekilmelerinin tedavisinde kullanilan cerrahi ydntemelerin degerlendirilmesi. Academic Dental 2001;3:20-26.
42. Ricci G, Silvestri M, Tinti C, Rasperini G. A clinical/statistical comparison between the subpedicle connective tissue graft method and the guided tissue regeneration technique in root coverage. Int J Periodont Rest Dent 1996; 16: 539-545.
43. Han TJ, Takei HH. Progress in gingival papilla reconstruction. Periodontol 2000. 1996;11:65-68.
44. Blatz MB, Hurzeler MB, Strub JR. Reconstruction of the lost interproximal papilla. Presentation of surgical and nonsurgical approaches. Int J Periodont Rest Dent 1999;19:395-406.
45. Azzi R, Takei HH, Etienne D, Carranza FA. Root coverage and papilla reconstruction using autogenous and connective tissue grafts. Int J Periodont Rest Dent 2001 ;21:141-147.

WWW.HIGHDENT.IR
همیار دندانسازان و دندانپزشکان

7 Atlas of Porcelain Laminate Veneers

Galip Gurel

Determining the Essentials

In order to determine the optimal method of patient care, the patient's existing clinical condition must be accurately diagnosed and treatment objectives (biocompatibility, esthetics and long-term function) established accordingly. Once an analysis of the condition has been completed, the correct restorative procedure can be selected in order to address the complications presented by that particular patient. Comprehensive radiographic and clinical examinations (occlusal, muscular, joint) are integral components in the process of determining the preoperative status of the patient and, consequently, the evaluation of the possibility of achieving a successful rehabilitation.[1]

Dentistry continues to advance and present-day esthetic dentistry has evolved into effective functional biocompatible procedures that are appearance enhancing as well. However, esthetic dentistry can be a complex and demanding process. The dental profession has experienced a proliferation in the number of available choices in dental materials, prosthetic designs and laboratory techniques, especially in the last 10 years. The numerous choices now available increase the dentist's responsibilities, as it is not only diagnosis and treatment planning that are important but communication and performance as well.[2]

Various predetermining factors play important roles in the evaluation and decision-making process of the treatment planning of each case. In cases where PLVs are planned, many factors should be thoroughly determined before the actual treatment begins. These details must be carefully analyzed to minimize difficult situations that may arise during the actual treatment process and to avoid possible postoperative complications.[3]

WWW.HIGHDENT.IR
همیار دندانسازان و دندانپزشکان

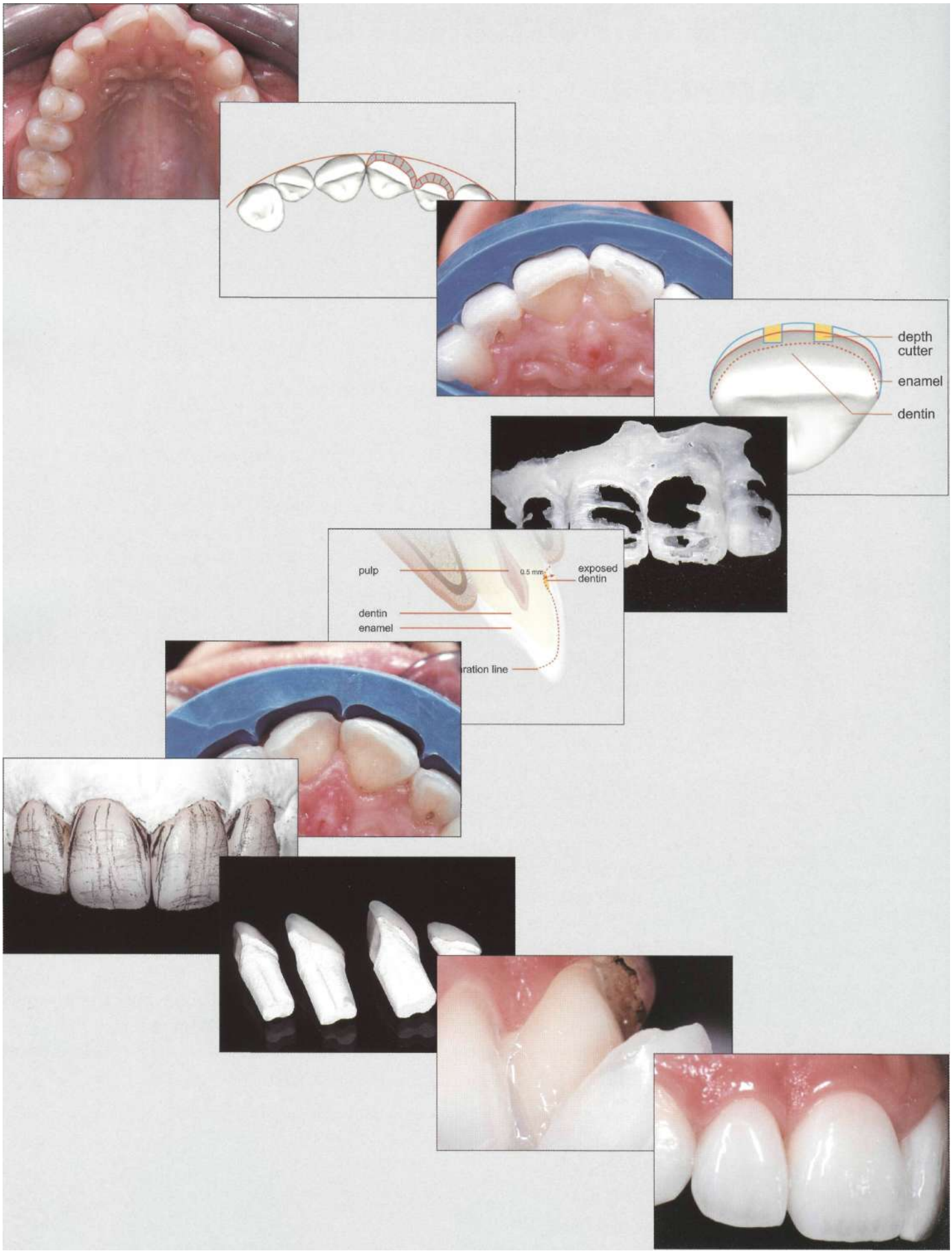

WWW.HIGHDENT.IR
همیار دندانسازان و دندانپزشکان

Fig 7-1 Protruded central #21(9) with irregular gingival architecture. Palatinally rotated mesial side of the lateral #22(10) results in a smaller mesial embrasure, whereas the distal torsion creates a larger embrasure than normal. Both the centrals and laterals are displaying shorter crown length and larger width.

Tooth Position

In-depth knowledge of the hard tissues of the mouth and the teeth is essential to the development of restorative procedures. Biomimetics, one of the new terms introduced to the dental glossary by *Magne,* et al.,[4] refers to the reproduction of the original performance of the intact tooth that is about to be restored. This is vitally important when restoring fractured, worn-out or aged teeth. In most cases, even if the teeth are intact, their improperalignment, rotation, lingual orlabial position will play an important role in treatment planning (see aesthetic pre-recontouring), as the amount of sound tooth reduction is often related to the position of the teeth. For example, the extreme labial position of the tooth must be more aggressively prepared than the facial in order to keep the finished PLV level with the rest of the arch. Pulp status (forexample, pulpsizeinayoung patient) should be evaluated and, in lingually aligned teeth, care must be taken not to reduce unnecessarily the facial structure of the tooth (Fig 7-1).

Gingiva

The soft tissues and bone height in relation to adjacent teeth should always be taken into account to avoid gingival asymmetry and to maintain the height of the interdental papillae. If this is not carefully evaluated, the formation of black holes at the gingival embrasures will be unavoidable, and in some cases may even be the cause of a variety of problems. This is especially true if it has not been discussed with the patient before the treatment begins. Poor dental hygiene, gingival inflammation and one or more gingival recession sites should all be treated. It is even more crucial that patients are observed for a period of time in order to determine the extent of the cooperation exhibited.

Gingival Margins

The cervical placement of the PLV margins is also an important issue to betaken into consideration. Although the laminate veneer's ideal margins are preferably located on the enamel and away from the gingiva, the condition of the teeth must always be apprised before deciding on any form of treatment. The extent of previous restorations and carious lesions, defective enamel or gingival recession and root exposure, especially in the case of a high lip-line, may necessitate the overextension of the preparation margins, and special care should be exercised in doing so.

The incisal edge position sets the starting point of the esthetic treatment planning, as discussed before. Therefore, to avoid unesthetic or unpredictable results, the crown length, incisal wear, and the extent of the lengthening of the incisal aspect should be carefully evaluated and only then should the extent of gingival alterations be decided.

WWW.HIGHDENT.IR
همیار دندانسازان و دندانپزشکان

Occlusion

Occlusal relations, heavy function orparafunction play vital roles in PLV applications. In some cases where the patient exhibits severe parafunctional habits *or* unfavorable occlusal relations, full ceramic or porcelain-fused-to-metal crowns may be considered the preferred choice for restoring these teeth.[3]

It is a well-known fact that cervical abfractions, specifically at the premolars, are due to tooth flexing under heavy occlusal forces. These are some of the clues to heavy occlusion that have to be very carefully evaluated before any definitive restorative treatment is undertaken. The relative fragility of PLV restorations requires an accurate analysis of the patient's occlusion, to ensure that the restorations do not extend into areas of occlusal stress. The results of this analysis may limit the opportunities for remodeling.[5]

PLVscan be widely used in incisally worn teeth if attention is paid to occlusion and anterior guidance. In other words, establishment of the correct protrusive anterior guidance, together with the canine-guided lateral excursions, are of vital importance. Occlusal relations such as horizontal and vertical overlap, or crowding of the mandibular dentition which may distort the protrusive relations, play important roles in setting the anterior guidance, and, if properly handled, should not affect the incisal lengthening of the incisor teeth.

Age

Aged or worn-out teeth exhibit different thicknesses of enamel and surface texture that are directly related to the extent and distribution of the occlusal interferences or external stimuli. While treating such cases with PLVsthe most important issue is not the strength of the ceramic material, which has been proven to be three times stronger than the enamel in tensile strength, but the preservation of sufficient enamel and controlling the occlusal forces.[6] In the aged tooth, the enamel may be so thin that any extra preparation for PLV may lead to a loss of this existing precious enamel, while the loss of the surface area of etchable enamel may directly affect bonding. An even more critical issue, perhaps, is the loss of the thickness of this enamel that is so vitally related to the flexibility of the tooth. The thinnerthe enamel gets, the more flexible the teeth become. In order to avoid this and to maintain the natural strength of the tooth, preserving the already existing enamel is of prime importance, especially while working with the aged tooth. The strength of the bonded veneer, together with the preserved existing enamel, will minimize the tooth flex and thus create a strong bond between the PLV and the enamel.

The correct choice of treatment, and the sequence that is to be followed, must be thoroughly planned prior to the commencement of treatment. Each case should be carefully evaluated in advance, as there are numerous alternatives to the color, size, shape and position of a single tooth or a group of teeth within the arch. Attractive, predictable esthetic results can be obtained through the creative initiative of the dentist and coordinated with the ceramic skills of the laboratory technician.[7]

Pre-operative Evaluation (Analyzing the Smile)

To select the most appropriate option for each patient, the dentist must carefully evaluate each case, review all available options, and clearly define how that goal will be reached, along with what necessary steps must be followed in order to achievethe desired result. The dentist must first examine and evaluate each tooth and its surrounding tissues to ensure that they are functionally sufficient. Once this is established, careful attention to a functional diagnosis should be made, leading to the definition of reconstructive goals for both the dentist and his/her technical staff. Clear goals are essential to avoid any misunderstanding that could compromise the esthetic results, and when fully understood by all parties involved, the chances for success are greatly increased.[8]

WWW.HIGHDENT.IR
همیار دندانسازان و دندانپزشکان

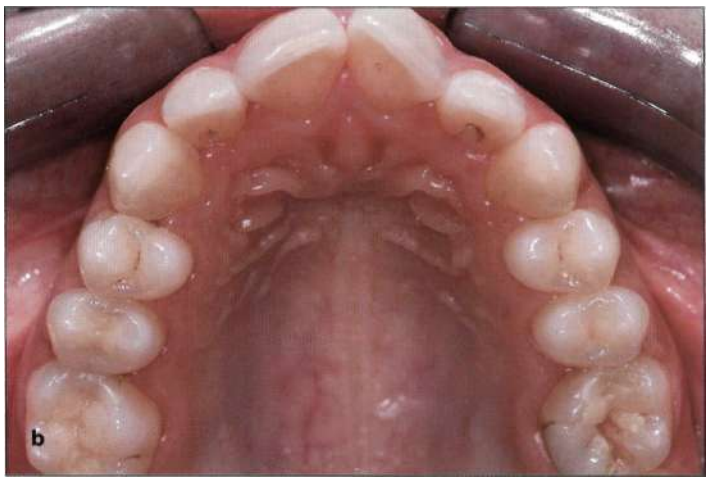

Fig 7-2a, b (a) The teeth, lips and smile should be observed and evaluated from different angles. Note the protruded left central and rotated right central and lateral, (b) These rotations can be best visualized from an occlusal view.

The Face

The initial impression when we first meet a person is not formed from focusing on a single tooth, but rather from taking in the person's face as a whole. In smile analysis, the dentist must consider and decide on what affects that person's appearance, directly or indirectly. Details such as the shape and color of the teeth, their harmony with other features, and perhaps even the character of that person, are what make up the whole appearance of that individual. Therefore, any variations in color and size will affect the way we perceive the finished product.[5]

Even though the shape of the individual tooth alone is important, the shape of an element becomes secondary to the shape of a series of these elements. The second important factor is the presence of a border, which binds the elements within into a separate, organized entity. In dentistry, the face and lips are provided for us by nature to serve that very purpose.[9]

The Lips

Being the frame of the smile, the lips and their size are also important factors. Full thick lips enable the dentist to use larger centrals and provides the dentist with a wider range of choice in relation to the proportion of the teeth.

While designing the smile, the extent of lip movement during function, and the visibility of the coronal portions of teeth, both natural and PLV, must be taken into account. Careful evaluation of the smile in a three-dimensional aspect is important and it must be observed from the front, both sides, and diagonally from different angles (Fig 7-2) 5

The level of the upper lip-line must be evaluated while at rest, when talking and when smiling (see Chapter 2), as the level of gingival display and visible tooth surface are affected by these various positions. The incisal edge and lip-line must be in harmony. It is generally accepted that high lip-lines are less favorable because they display more gingival tissue. The cervical gingival line is also important in the case of a high lip-line and the resulting asymmetric problems need to be dealt with accordingly.

The Color

While these parameters play an important role in the spatial arrangement of the teeth, the importance of color should never be underestimated. The hue, value, chroma, translucency and texture should be carefully evaluated, as they directly affect the appearance of the teeth (see Chapter 5).

A thorough evaluation of the teeth, including all aspects of their color, shape, position and

WWW.HIGHDENT.IR
همیار دندانسازان و دندانپزشکان

general condition should be completed before preparation, and this evaluation will be essential to the ultimate success. All characteristics of the teeth should be documented, taking special care to note any changes in colorand value within each tooth from the gingival to the incisal. Any characteristic deemed undesirable by the patient should also be noted so that they can be neutralized by the final veneer.[10]

Photography and Videotaping

High-quality photographs, in addition to a full examination, are a must for the esthetic evaluation process. These photographs are not only important for communication with the laboratory, but also to help the dentist clearly to evaluate some of the details that might have been missed during the naked eye visual examination. However, these tools may not be sufficient for the in-depth evaluation of a smile. If the dentist wishes to go one step further, then the use of a video camera will enable him/herto record the patient's teeth and their relationship to the lips and face while smiling, talking, etc. To catch a natural smile in a photograph may be difficult or even forced, whereas, through the use of the video, the patient will eventually relax and allow these relations, and the range of facial expressions, to be observed in a more natural setting. With the introduction of digital video cameras, one can freeze any frame and easily print out the picture. This is a great communication tool, not only for the dentist and patient, but for the technician as well.

As mentioned in the first chapter of this book, understanding what you and the patient would like to accomplish will dictate the type of smile design and the veneer preparation to be used.

Treatment Planning

Defining our goals is as essential as the steps necessary to reach them.[11] In esthetic cases, the patient may help by clearly defining exactly what they would like to see at the end, which is a crucial part of the treatment planning process. The worst scenario is when the patient does not know what they want and therefore constantly changes his/her mind. Once the esthetic needs are confirmed, the dentist should identify the potential difficulties. The patient's present clinical condition should be carefully evaluated and, in addition to esthetics, the biocompatibility and long-term function should be considered.[12] Only after a very thorough examination can a proper treatment plan for that particular patient be decided upon.

Checking Teeth Individually

Each patient's occlusal scheme will affect their smile design and the amount of compromise necessary for that particular individual to achieve an esthetic appearance while maintaining proper engineering.[13] Thorough radiographic and clinical examinations will helpthedentistto determine the state of the patient's oral health and increase the chances for a successful treatment. For each site, the sulcus probing depths should be recorded, and, using a facebow transfer for the maxillary casts, the stone casts should be mounted in a semi-adjustable articulator. A diagnostic wax-up must be made, and the mandibular casts mounted in centric relation. In order to evaluate the patterns of occlusion, a mounting cast on the articulator should be used before defining an esthetic treatment plan. Careful evaluation provides clues to what the esthetic and functional results will be.[14]

This is especially true in the case of abfraction lesions that are commonly caused by grinding or bruxing, and which should be detected as they can be the cause of tooth flexure, necessitating an occlusal analysis of those teeth in question and a restorative treatment accordingly planned.[15] In order to be able to provide successful treatment, all factors relating to the final outcome must be carefully diagnosed prior to the commencement of treatment.[16]

WWW.HIGHDENT.IR
همیار دندانسازان و دندانپزشکان

Esthetic Integration

In the past, color matching was the main concern of both patient and dentist in esthetic restorations. However, in esthetic dentistry today, especially in the case of anterior restorations, color is only one of many factors to be considered in achieving a pleasant smile. It is not only a single tooth, or its adequate display, that are important, but also the gingiva in harmony with the tooth arrangement, as well as the lips and their integration into the facial characteristics (see Chapter 2). As the popularity of esthetic dentistry increases, the patient's expectations of a successful restoration increase as well and therefore nothing should be lacking in the quality of the color, contour, texture or shape. Good communication between the dentist, technician and patient, that begins before the actual treatment commences, is vital to the ultimate success.

Durability

In multiple-unit cases, the accuracy and durability of the final restorations are especially important, and a carefully planned occlusal scheme as well as an appropriate smile design should be well thought out.[17] The length and position of the anterior teeth are critical in the result and in the occlusal scheme for any dentition.[18,19] Perhaps an even more important factor to consider is the anterior guidance. When lengthening the incisor with PLV, a frequent mistake made is to shorten the anterior incisor's length instead of establishing proper anterior guidance.

Facial Analysis

The dentist should also evaluate the facial shape and categorize any irregularities. When evaluating the face, its symmetry and shape should be taken into consideration. The shape may vary from long to wide or average. As far as form, function and their relationship to the lips are concerned, the proportions between the anterior teeth will dictate the length of the central incisors as well as the lateral incisors in respect to the central incisors. Sometimes the lips may exhibit unusual characteristics such as an irregular upper lip-line, a high or low smile-line, or overly thick or thin lips. These characteristics must be evaluated and explained to the patient in accordance to the treatment plan that is to be undertaken.

Lip movements during function, and the amount of visible coronal portions of theteeth and the PLV, are very important in the planning stages for the PLV. Ideally, only a small portion of the incisal maxillary teeth should be seen when the lips are in rest position. As the mouth and therefore the lips move when in the process of function, the teeth will be more visible towards the apical direction depending on the maxillary incisor's incisal edge position. Accordingly, each esthetic plan should start with determining the position of the incisal edge. Once the incisal edge position of the incisor and the central incisor's facial curvature are determined, then it is possible to predict a successful result.[3]

Gingival Concerns

The length of theteeth and the incisal edge's position will determine the levels of the gingiva.[3] At times the gingival plane may not be parallel to the interpupillary line and therefore natural asymmetry is often exhibited or at times[3] asymmetry of the gingival tissues may exist. This is especially true if there is a case of high or medium lip-line, and so their alignment must be incorporated into the treatment planning. If the gingiva is visible when in full smile or during speech, the incisal and gingival planes must be harmonized with the face.[3]

Smile Architecture

An analysis of the shape of the teeth in relation to the patient's mouth, age and sex should be made.[9] Dominance is usually obtained by using a large central incisor that is capable of dominating the composition. The amount of this dominance or prominence in a smile depends on just how much of a youthful smile is desired.[20] Uniformity is achieved when the teeth harmonize with the age and sex of the patient. A natural variety of shading can be used to create an organic

WWW.HIGHDENT.IR
همیار دندانسازان و دندانپزشکان

composition and gradation principles should be followed accordingly. When the PLV meets these requirements, and unity and harmony exist, then that individual's personality will be reflected in the final result.[9] The process of treating a patient and working it through to the final esthetic result is referred to as the process of "smile architecture".[21]

Smile architecture is directly related to the treatment plan. One of the most important elements in deciding on the new smile design is the individual patient. Their perceptions, expectations and feelings should never be underestimated. The parameters explained above and esthetic treatment planning will have no value unless they are discussed and shared with the patient. Although dentists are experts on defining the incisal edge position, tooth volume and altering the gingiva levels, problems can arise when the esthetic perceptions of the patient, the dentist and the dental technician differ. Sometimesthe patient wants replication of an appearance they have become accustomed to, despite it not being esthetically ideal.[22]

Composite Mock-up

Additive wax-ups, silicon guides and corresponding diagnostic templates are very helpful in increasing the survival rate of restorations and patient satisfaction.[23] To get a better idea instantly of what the eventual outcome will be, utilization of the composite mock-up is wonderful as an aid.[24]

The neighboring tissues or teeth provide three-dimensional information that is necessary to give the restoration the correct volume and shape. A diagnostic "composite mock-up" which is the direct application of composite without surface preparation that perches itself on the teeth, is indicated when such elements are missing, or when an alteration of tooth forms is necessary.[25] A silicone key makes the final fix of the situation once it is programmed.[26] From the preparation to the PLV build-up and restoration finishing, the clinician is guided by these spatial references. The restorative steps will be facilitated by the visual inspection of the frontal, lateral and incisal planes.[27]

Determining the Incisal Edge Position

The composite mock-up is both diagnostic and informative. Especially in the case of diastemas, fractures, misshapen or malpositioned teeth, mock-ups can be extremely useful. It gives the patient an inexpensive preview of what the veneer will look like. Without these visual aids, it is difficult for even the most experienced dentist to predict the final outcome. It enables the dentist to establish the incisal length of the centrals as well as the buccal-lingual position of the incisal edge and the incisal edge plane. It is also helpful in establishing the lateral, central incisor relationship and their axial inclinations.

In addition, it will be a great visual aid for both the dentist and the patient to establish a favorable buccal corridor. On the functional side, it will give an indicative preview of the desired guidance schemes. In the more complex cases, where restoration with PLVs appears to be impossible, the use of these mock-ups often offers a chance for a good prognosis.[24]

Technique

Depending on the difficulty of the case, it takes from 5 to 20 minutes to prepare the new smile design with composite mock-ups for the whole upper arch. The easiest way of doing the mock-up is with the freehand carving method.[25] The composite is rolled between the fingers and applied overthe dried tooth structure. It is shaped with the help of the fingers and special hand carving instruments and then light cured. The teeth can be lengthened or protruded, or the color can be altered for the patient to visualize. After placing the composite mock-up on the tooth, if any part is over exaggerated (in other words, if too much composite is applied and polymerized), it can be corrected with the help of a fissure diamond bur. However, careful attention should be given not to touch the intact tooth structure while

WWW.HIGHDENT.IR
همیار دندانسازان و دندانپزشکان

doing so. Leaving a scratched enamel surface will be unfortunate if the patient does not accept the treatment.

Determining the Gingival Line

Atrial that can be referred to as a "reverse mock-up" is also possible to make (see Chapters 12 and 13). If the dentist decides that the incisal edge positions of the teeth are in their correct place, but that the teeth still appear short, this may be an indication for alteration of the gingival levels. In such a case, instead of adding the composite material over the incisal edge, the material is added overthe gingiva after it has been dried. This will appear a little overcontoured since the composite is being added overthe original volume of the gingiva. However, it offers the patient a great chance to visualize and to formulate an idea about the appearance of the newsmileand of the longer teeth that have been lengthened towards the apical direction. Once the patient is satisfied with the new appearance, an alginate impression can be made from this mock-up and sent to the lab together with Polaroid photo-graphs. After this, a transparent template can be built which can be used as a surgical stand, to dictate where the new gingiva should be located. This will serve as an indispensable communicative tool to the periodontologist who will be responsible for altering the gingival levels (see Chapter 13).

Interactive Patient Communication

These composite mock-ups can also be used to open a discussion with the patient as to how their smile can be modified. Here the finer details of the restoration, such as the nuances of color and all pertinent parameters - position, contour and proper communication - can be tested and given approval by the patient. For those who need complicated corrections, but who do not wish to experience a lengthy treatment or interdisciplinary procedures, such as orthodontic treatment, these mock-ups are indispensible.[28]

Short-term Provisionals

When the teeth need to be lengthened and/or protruded, some patients may complain that the pressure on the upper lip causes phonetic disturbances.[3] In such cases the mock-ups can be held in place for a longer period of time. Light retention can be provided by extending the composite over the gingival embrasures, or by other undercuts that can be incorporated into the composite build-up. The patient may then be dismissed with the mock-ups in their mouth for up to a period of a few hours in order better to evaluate the esthetic outcome. It is common for the patient's lips to adjust to the uncomfortable pressure from the mock-ups and it also enables the patient to get feedback from the people they trust the most, in terms of their opinion of the esthetic outcome. This is all done for the benefit of the patient and in respect to their desires for a functional esthetic goal.[29] The dentist should use the mock-up, if not for any other reason, just for the wonderful educational and enlightening experience it offers the patient.[30]

Laboratory Communication 1

It often happens that in some esthetic cases the laboratory results do not meet the expectations of the dentist or the patient. Discrepancies in tooth length, position, size proportion, color, function, phonetics and occlusion may cause disappointments. This negative impact on the outcome of an esthetic case can be eliminated when an efficient, well-informed and respectful relationship exists between the dentist and the technician and when both are capable of comprehending the desires of the patient.[2]

After the composite mock-up trial, a prosthetic solution should be prepared in the dental laboratory so that unrealistic patient expectations do not jeopardize a successful result. Solutions that are not prepared in this way are compromised, even though some acceptable results may develop in the course of ordinary prdsthetic treatment. The harmonious integration of the new smile design,

WWW.HIGHDENT.IR
همیار دندانسازان و دندانپزشکان

material selection and interdisciplinary communication must be implemented in order to deliver optimal treatment with PLV restorations.

In esthetic dentistry one of the main concerns and first priorities is the actual tooth preparation. Errors can be avoided through the diligent recording of any and all information useful to the patient, dentist and technician prior to the commencement of treatment.[5] All of the previous diagnostic studies should be carefully analyzed, thoroughly understood, and any changes necessary in tooth shape, size or color accepted by the patient. The question of whether or not a new smile design necessitates new esthetic conditions should be clarified.

Diagnostic Study Models

Study casts as a reference for use in the laboratory are a necessary requirement, whether for provisional or permanent prostheses. No matter if the patient wishes to preserve their original smile, to improve their tooth color or desires a new smile design, study casts are indispensable for conveying the pertinent information to the laboratory.[5] After a careful analysis of the existing problems and a consultation with the patient, these study models help to illustrate what must be changed and what can remain unchanged in their present state.

The use of mounted diagnostic casts and a diagnostic wax-up allows the dentist and laboratory technician to visualize the expected result. Although the esthetic outcome can be observed in the patient's mouth during the composite mock-up stage, it may be difficult completely to analyze the details and functional outcome while in the mouth. Therefore, diagnostic study casts have a very valuable place in determining these essential details and the problems that may arise during function. While preparing the mouth for an esthetic case, careful analysis of the ceramist's ability to create occlusal harmony may be affected by certain discrepancies. Effective use of study casts and double-checking will helpto ensure that the desired occlusal plane is ultimately achieved even though there were irregularities in tooth position.[12]

Through the use of aids such as composite mock-ups, and after the dentist has clearly defined the desired esthetic appearance he/she is striving for they can now progress to the use of properly mounted diagnostic models. Before any preparation begins, an alginate impression of the arch should be made. Additional diagnostic cast alterations with white wax carving may be used to create any desired changes. Pink base plate wax can be used to simulate anticipated modifications in the soft tissues. The wax-ups made for both the hard and soft tissues can be used as a guide for treatment planning by both the periodontist and the dentist.[31]

Reference Points

Objective reference points are very important in the esthetic process and will be referred to throughout the treatment procedure, providing the dentist with a sense of security and a better chance of achieving success. It is also useful in their relationships with the patients and laboratory technicians. Dental technicians cannot make these decisions alone and must have input from the dentist. For example, the length of the teeth in relation to the upper lip, and other important parameters, cannot be verified by the dental technician alone. The reasonable way to transfer this information to the lab is via written explanations. The dentist can write down the patient's expectations in conjunction with his or her own personal ideas on improving the smile. In contrast, verbal communication concerning the length of theteeth or other details is subjective and not useful to the technician and hinders the chances of a successful restoration.

Transferring the Mock-ups

The author suggests that the best way to transfer this information to the lab is with an alginate or silicon impression made from the composite mock-up, which is simpler and self-explanatory. It is the ideal way of transferring the incisal edge's position and its inclination to the lab. As discussed before, the rest of the build-up will depend on this parameter. A model made from the composite

WWW.HIGHDENT.IR
همیار دندانسازان و دندانپزشکان

Fig 7-3 The pretreatment pictures are very useful guides to the dental technician in terms of reference points, color, shape and the texture of teeth.

mock-up of the newsmile, that has been approved by the patient, and followed by an impression or the silicon index reflecting these changes in three dimensions, should be delivered for wax-up production together with the intra and extra oral pictures of the patient.

Photography

To isolate an object that is being scrutinized is impossiblewithout also taking in its surroundings. It is not only the specific object we wish to observe but also the surrounding objects and how they relate to each other that create an image for the observer. For successful dental surgery, photographic equipment is vitally important, and very often pre-treatment slides can be a source of motivation for the patient.[5] Pre-operative photographs are useful in the evaluation of contour, texture, enamel cracks and amalgam restorations which can affect the color of the neighboring teeth. Variations in chroma and value that may be due to excessive attrition can easily be documented by photography.

Laboratorytechnicians who do not have much or any contact with the patient can benefit from full-face photos from different angles as well as intraoral close-up pictures, and each item is characterized in accordance to the other objects that are in the field of view (Fig 7-3).[9] Now that the technician has more solid information, at least about the esthetic outlines, he/she can check the functional compatibility of this mock-up on the articulator. For example, overlap on the original study cast or from the cast of provisional restorations determines the horizontal overlap in the laboratory.

Different casts that are commonly used are the reference, opposing and master casts. The master cast that is taken is of the original tooth shape and acts as a reference while also providing the dentist with pertinent information that is useful for the final restorations. The reference model that is the cast of the mock-ups remains the esthetic reference point, while the opposing cast is used for evaluating the functional relationship of the upcoming restorations with the opposing arch.

Silicone Index

The waxing-up of the veneers is aided by the use of a silicone index of the composite mock-up. The outline of the incisal edge is captured in the cast and enables freer esthetic design while maintaining sufficient porcelain thickness.[32] In order to achieve the proper esthetic orientation the cast of reference made from the mock-ups must be brought out with the opposing cast. The reference cast and the master cast are in fact interchangeable and share the same indexing. The wax-up's

WWW.HIGHDENT.IR
همیار دندانسازان و دندانپزشکان

given dimensions can be precisely indicated with the silicone index that ensures the support of the porcelain and is vitally important for the thickness of the porcelain veneers. Proximal contact position can be created and optimal embrasures allowed.[3]

Esthetic Evaluation

The patient should be evaluated as an individual before any decisions about the size, color, shape or form are made. This lessens the chance of the laboratory making any esthetic errors, as the dentist is the one who actually sees the patient and should be the one to make all the final decisions. If it is necessary for the technician to make the wax-ups then he/she must first be provided with pictures, models, sketches and very detailed instructions indicating the desired tooth position.[33] In addition to all the communication tools explained above, the lab can also be provided with radiographs to enhance their understanding of the crown-root ratios and the support of the alveolar bone and help guide the lab technician in building up his/her occlusion. In PLV cases, the existing and desired tooth shape should be noted, and both intraoral and full-face photographs should be sent.

Realizing the Limitations

In this first stage, for each case the communication between the patient and dentist is as important as that between the dentist and the technician. There is no golden rule for effective communication. If it is excellence that the dentist strives for, precisely fitting restorations are a necessity. Attention to the details of color, shading and harmony with the surrounding teeth is of the utmost importance and only effective communication can assure this.[10] This will help to relate the esthetic needs to function.

After the first stage of laboratory communication, the dentist should be provided with preliminary wax-ups, silicon indexes and transparent templates that will play a crucial role in the esthetic pre-evaluation as well as in the actual tooth preparation.

Educating patients on the benefits and limitations of the veneer technique will save everyone involved time and money. After listening carefully to a patient's desires, an honest evaluation with feedback from the dentist and the dental technician must take place. At this point it must be determined whether the patient's needs and expectations can be satisfied with veneers, or if another type of restoration is more appropriate.[10]

After the initial communication with the laboratory, the esthetic and functional possibilities should be defined. Protrusive and lateral jaw movements should be controlled by the dentist and laboratory technician to determine if the space is sufficient for the restorations. This is especially true when the lengthening of the mandibular and maxillary teeth is in question. The cause of 75% of unsuccessful restorations is due to occlusal interference in the lateral or protrusive movements.[15] Requests for adjustments arising from such misunderstandings are familiar occurrences to dentists and technicians alike. When the dental technician is supplied with all pertinent information, he/she can start producing the wax-ups.

The diagnostic wax-up should be produced over the mounted casts. The study casts, which are the references for the preoperative condition, will be the foundation for the planned design of the wax-up. The technician at this stage should try to create a wax replica of the intended restoration.[2] The design and the production of the wax-ups are vitally important since the conservative preparation limits will be primarily based on these criteria. The provisionals will also be fabricated from the template that is an exact duplicate of the wax-ups. Therefore, the technician should very carefully design the wax-up. Some technicians even build up their wax-ups from different colored waxes in order to simulate the final look of the PLVs they will be producing They should not only be esthetically pleasing but functional as well (see Chapter 10).

Wax-up for Tooth Preparation

One of the very crucial issues in the production of PLVs is to keep the maximum existing enamel of

WWW.HIGHDENT.IR
همیار دندانسازان و دندانپزشکان

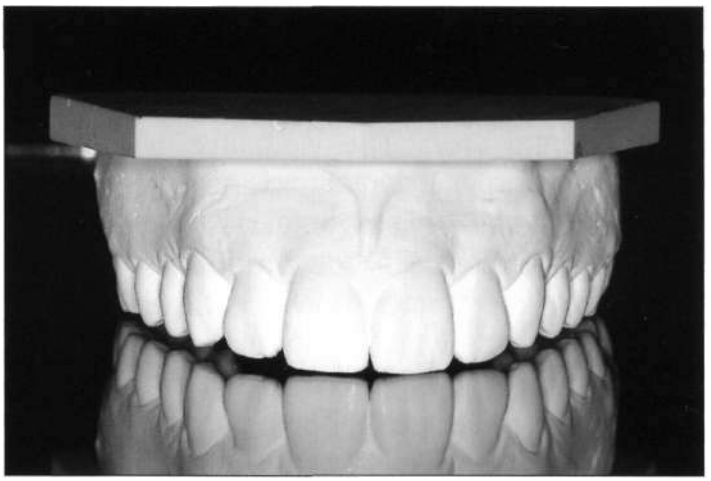

Fig 7-4 The models have to be waxed-up in order to visualize the final outcome in terms of both esthetics and function. Then a stone model is duplicated from this wax-up in order to prepare the silicon index, transparent template, etc.

the tooth structure. Before the dentist even starts thetreatment planning, and especially when treating the aged tooth with PLV, the amount of remaining enamel and the final volume of the PLV should be very carefully analyzed.

The amount of tooth reduction should never be made according to the existing tooth surface but rather to the final volume of the restoration. The spatial orientation and architectural dimensions of the wax-up will be used to predesign and validate the intended preparations for the teeth involved. This illustrates the importance of using correct wax-up techniques in creating the exact tooth shape desired. In PLV treatment the most important element in the process is the wax-up (Fig 7-4).[34] In order to transfer these data to the clinic, the dentist should be supplied with transparent templates and silicon indexes by the laboratory technician (see Chapter 10).

Aesthetic Pre-recontouring (APR)

The final esthetic and functional form determines the actual tooth preparation and entire PLV build-up we seek to achieve. In the restoration process, factors like occlusion, function, interproximal position of the adjacent teeth and their contact zone, the size of the pulp and the hard and soft tissues, along with the age of the patient, are all very important. Smile design and the artistic arrangement of the teeth can only be dealt with in relation to these various factors. When necessary, these parameters can be manipulated into the desired position in orderto achievethefinest esthetic results. Tooth preparation that has been done without prior evaluation and planning is doomed negatively to affect the final result.[35]

Chairside Evaluation

It is important to identify the primary anatomic structures before the preparation phase begins. There are numerous components that make up the linguoincisal anatomic form and incisal edge survey form that interact with each other to create physiologic and bioesthetic harmony in the natural dentition. These components are: the cementoenamel junction, the cervical ridge contour, points of concavity, longitudinal developmental lobes, proximal concave lines and the mesial and distal line angles.[36]

The varying components of the normal human body are proportionally related to each other,[37] each contributing towards the body esthetics as a whole. The proportions of theteeth are an important factor in the beauty of a smile. The beauty of any smile depends on the proportion between the length and width of the teeth, their distribution in the arch, the shape of the arch and the smile configuration. When two teeth are the same width but different lengths, the longer tooth seems narrower. Consequently, the width length relationship of each tooth to the adjacent teeth has a significant

WWW.HIGHDENT.IR
همیار دندانسازان و دندانپزشکان

effect on the visual appearance of the ensemble.[37]

Teeth are single objects that are part of a whole - the dental arch. The visibility of the teeth decreases from the dental mid-line to the posterior area of the arch. The frontal view only allows a certain amount of visibility, butthe important issue here is the interchange between the visible and invisible aspects which determines the invisible aspect of morphology.[38] When a lateral incisor is viewed from the front, the tooth can be seen near the mesial margin. However, the mesial line angle is in the middle of the line in view.[38]

Position of Teeth

The position and alignment of teeth in the arch can significantly affect the appearance and balance of a smile. Rotated lingually or facially positioned or aligned tooth orteeth will disrupt the total harmony and balance (see Fig 7-2). A smile is more pleasant when the teeth are adequately positioned and aligned. Poorly positioned or rotated teeth not only distort the shape of the arch but they also interfere with their apparent relative proportion. Anterior esthetics necessitates the contouring and shaping of the teeth in order to create an illusion that gives the perception of pretty teeth and an attractive smile. The ability of the dentist to reshape the tooth to conform to or enhance nature's given contours is truly an art form that is essential to esthetics.[39] One of the most important avenues that requires this artistic procedure is (a)esthetic pre-recontouring (APR). In order to dictate the final outcome of a pleasant smile and to obtain an adequately equal tooth reduction for the technician for his/her PLV build-up, an APR should be considered before the actual material preparation.

APR

When the individual tooth position or their alignment need to be altered, the basic principle of APR is to put the partially protruding axially misaligned or rotated teeth into proper alignment on the arch, having the imaginary finished PLV designs in the dentist's mind before starting the actual material preparation. Therefore the dentist should first have a solid understanding of that particular individual's tooth form and the alignment of their teeth in order to improve their APR technique. This is especially important in morphological correction and in the related preparation for PLV. The ability to trim and shape the tooth is as important as being able correctly to perceive and to interpret the teeth and their alignment and to fabricate the individual PLVs.

Teeth that are to be treated with PLVs may exhibit positions on the dental arch different from what is considered to be pleasing. For example, when the distal of the lateral is too bulky or in labial version (protruded), the view of the mesial aspect of the canine may be blocked. Teeth may have mesially or distally tilted positions; exaggerated lingual orfacial inclinations; rotations around themselves and malformations—or the mid-line may be canted.

In the actual material preparation (AMP) the required amount of enamel, and sometimes dentin, must be removed to provide enough space for PLV build-up. However, before doing so, any minor or major problems must be evaluated and misalignments corrected. In other words, an APR has to be made in order to put these things into order and to obtain a pleasing symmetry and balance in the arch. This will depend on how many teeth are to be restored for the new smile design and should definitely be decided before the actual material preparation starts. Unfortunately, this field of pre-recontouring tends to get far less attention than is necessary.

Incisal Edge Position and the Mid-line

To start preparing the teeth for the esthetic improvement of the arch, the dentist must first decide on the position of the incisal edge and the mid-line. These two parameters will set the starting point of the whole treatment. APR should start by adjusting the incisal edge position, and then should be followed by redirecting the angle of the mid-line perpendicularto the incisal edge and the infraorbital line, if necessary. The angulation of the

WWW.HIGHDENT.IR
همیار دندانسازان و دندانپزشکان

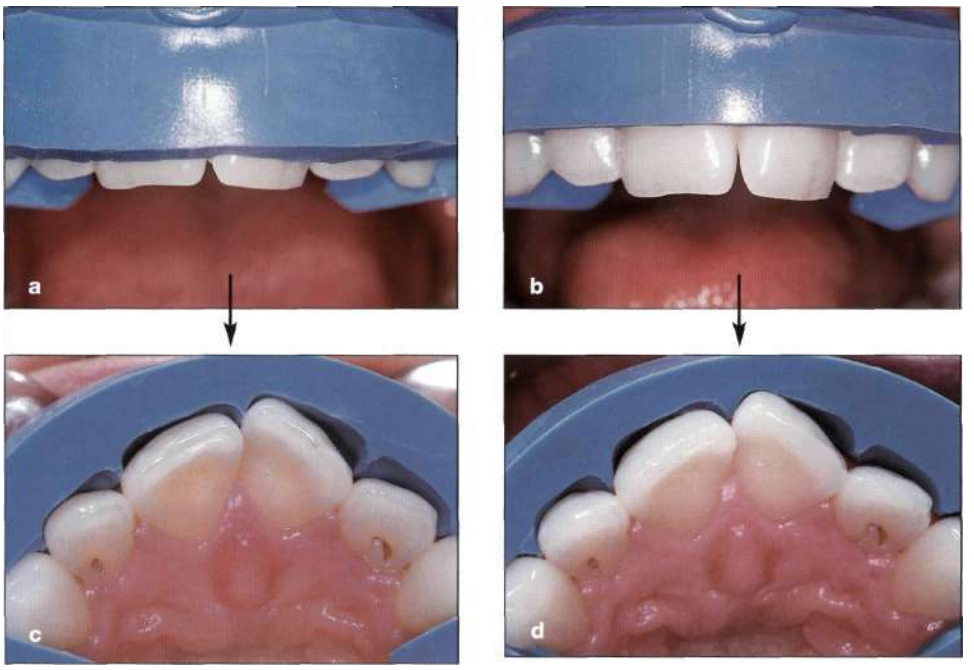

Fig 7-5a-d (a, b) If the dentist has hesitations on exacting the facial contour during the APR phase, the most accurate way to analyze this is via a silicone index. It is better to prepare the silicone index in slices to observe different depths. However, two indexes can also be prepared instead of a sliced index, (c and d) Once the silicone index is produced on the duplicate model of the wax-up it is seated over the arch, and the facially protruding portions will come in contact with it, sometimes creating problems with its proper seating. Note tooth #21 (9)touchingthe silicone index and the distance between the centrals and the silicone index. Comparing slides c and d it is possible to observe that the middle 1/3rd of the tooth #21(9) (d) is protruding more than its incisal 1/3rd (c).

mid-line is extremely important when focusing on the symmetry and balance of the max arch. A misalignment of the angle of the mid-line, or, in other words, if the mid-line is not perpendicular to the horizon or the pupillary line, all symmetry will be distorted. It will be very difficult for the dental technician to correct the mid-line with the PLVs if the mid-line is not aligned properly and teeth are not prepared enough to supply the space to adjust to it. Correcting such a problem during the APR stage will make life easier for both the dentist and the dental technician. It will not only ease the technician's problems, but also help the dentist better to visualize what he/she will be preparing afterwards.

Facial Contours

The dentist should also be careful to relate the teeth to each other as well as to their original existing positions. In cases where it is not possible to use homologous teeth as a reference, teeth from other groups, such as the canines or incisors that are on the opposite side of the same arch and which are properly placed, can supply information as to tooth shape and position.

If, for example, the facial inclination and/or rotation are not corrected before treatment, and the prep is done according to the existing position, the final preparation will also result in a facial inclination or rotation that will be very difficult to correct with PLV that has a maximum thickness of 0.3-0.5 mm.

Exacting the Contours

However, if a dentist has difficulties in trying to perceive where and how the teeth should be aligned from the start, the simplest method to overcome this problem is to use a simple silicon index that is prepared from the diagnostic wax-up. By placing this customized index over the teeth, the dentist can visualize the teeth or a portion of a tooth that creates the disharmony, either by a facial protrusion or unnatural axial inclination (Fig 7-5). The dentist can now trim down the protruding incisal edges, marginal ridges or axial inclinations until they can easily fit into the silicon index. By doing so, overextended teeth towards the facial, orthose that tend to stay out of the expected arch line, will be brought into their esthetically pleasing positions both vertically and horizontally (see Chapters 9 and 10). In this way, the facial limits of the PLVs will be well defined even before beginning the actual preparation stage (Fig 7-6).

WWW.HIGHDENT.IR
همیار دندانسازان و دندانپزشکان

Fig 7-6a, b In order to achieve a natural-looking smile, with teeth proportionally aligned on the maxillary arch, the teeth exhibiting different positions can be brought back to where they should actually appear. This has to be done before the actuel material preparation, (a) The facially protruded central is trimmed down with a fissure diamond bur. (b) The new position is achieved before the actual material preparation. Once the protruding areas are trimmed down (white arrow), the silicone index can passively sit on the unprepared teeth.

APR of Gingiva

The APR in some cases is not limited to the hard teeth tissue. It can also be applied to minor gingival alterations. Biologic parameters permitting (see Chapter 6), gingival contouring to achieve proper height can be accomplished with a diode laser (see Chapter 13). While doing that, the zenith points can also be changed, especially in the diastema cases. When minor gingival tissue remodelling is done with the diode laser surgery, no post-op apical migration of the tissue is witnessed. For the post-op comfort of the patient, gels including Oxyfresh can be prescribed to be applied to the gingival tissue 3-4 times a day.[40]

Aesthetic Pre-evaluative Temporaries (APTs)

Lingually Positioned Teeth

Aesthetic pre-recontouring (APR) refers to the necessary mean reduction of the tooth surface that protrudes out before the actual material preparation. However, in some certain cases, the tooth or teeth may be lingually positioned in the arch. For those teeth that are extremely lingually inclined, orthodontic intervention is a must. On the other hand, for the patients who do not want to receive orthodontic treatment with teeth that are only slightly inclined to the lingual, PLV treatment is possible. On such occasions the most important issue is to be able to visualize the final outcome (see Fig 7-7).

Preserving the Sound Enamel

In orderto preserve the maximum amount of tooth enamel, the final tooth reduction should be designed according to the expected final outcome. If not, the reduction of dental structures will not be the same within the space requirements for porcelain veneers, which vary from 0.3-0.9 mm. One example of this is the misalignment caused by the lingually misplaced tooth in the arch.[41]

Composite Mock-ups

In order to fill the esthetically missing volume, materials such as composite mock-ups can be addedtothefacial surfaces of these lingually positioned teeth. This will help to create the correct esthetic placement of the tooth surface on the dental arch. This is a very simple way of visualiz-

WWW.HIGHDENT.IR
همیار دندانسازان و دندانپزشکان

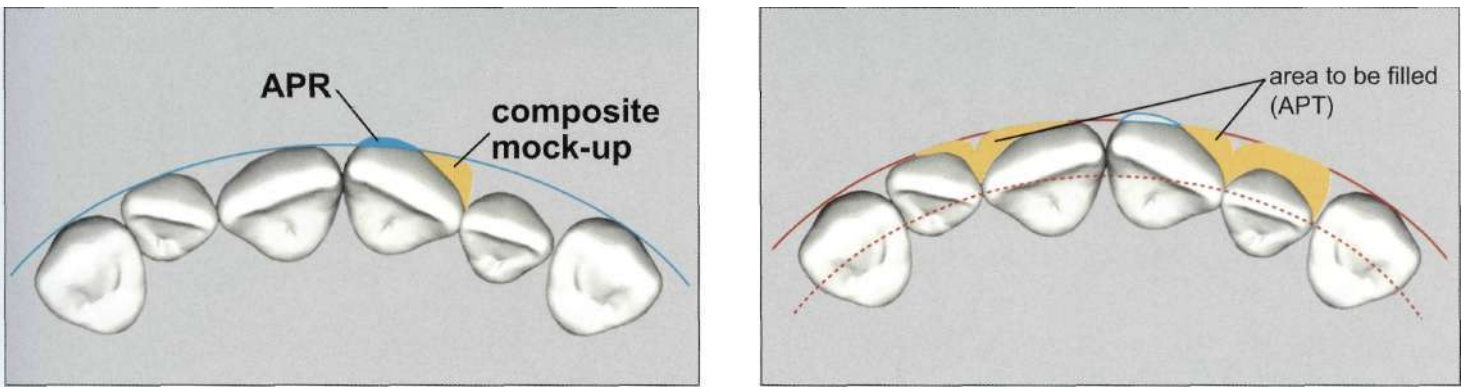

Fig 7-7a, b (a) The buccaly produced portions of the teeth are trimmed down to achive a better esthetic layout (APR). If the preparation is limited to one or two teeth, then the lingualy positioned teeth can be buccaly contoured with composite mock-up. (b) However when multiple teeth are involved a flowable composite can be placed on the teeth with the help of a transparent template or silicon impression, thus creating the APT.

ing their positions in the new smile design. This is done not only to perceive how the new smile will look, but also to evaluate its occlusal compatibility.[42] When the position of the tooth is corrected with the composite mock-up, before the actual material preparation, excessive healthy tooth reduction can be avoided and a thicker layer of porcelain built up over the unnecessarily overprepared tooth (which can compromise the natural value and chroma) that will result in a restoration with an artificial appearance is prevented.[42]

Depth Cutters

As we all know, the first step for the actual material prep is to obtain a sufficient depth with the help of depth cutters. However, the depth cutters always reduce the same amount of tooth that their grid depth indicates. In other words, no matter what the position of the tooth is, or whether they are lingually or buccally inclined, the depth cutter will always remove the same amount of tooth structure that will not necessarily dictate the true depth of the restoration. For the inexperienced dentist, who religiously follows systematic preparation techniques for PLVs, the improper application of these depth cutters can be extremely destructive.

Technique (Gurel Technique)

A simple technique, which has great value for controlling the depth of the preparation in such special cases, can be easily used. This technique using a composite resin can simply be added to the facial surfaces of lingually positioned teeth with spot etching and bonding up to where the tooth needs to be buccally reoriented or filled by volume (Fig 7-7). This is especially very efficient when dealing with a single tooth or up to 2 to 4 teeth. It mimics the final outcome that we aim to restore with the PLVs. When the composite mock-up is still on the tooth, it is logical to use the depth cutter over that composite build-up, so that the true depth will be reached when the depth cutter is used and thus preserve the maximum enamel on the tooth surface. By doing this, we limit our depth cutter to go only as deep as our smile design dictates, resulting in an even more conservative tooth reduction.

For example, let us assume that the tooth is tilted 0.2 mm lingually. If we do not use the technique explained above, then when we use the depth cutter of 0.3 mm we will end up with a 0.5 mm space that the PLV must fill. However, if we add the composite mock-up, and use the depth cutter over that volume, we will end up with the necessary reduction of only 0.1 mm, which will still provide the 0.3 mm of thickness for the final PLV. This way the enamel is being preserved

WWW.HIGHDENT.IR
همیار دندانسازان و دندانپزشکان

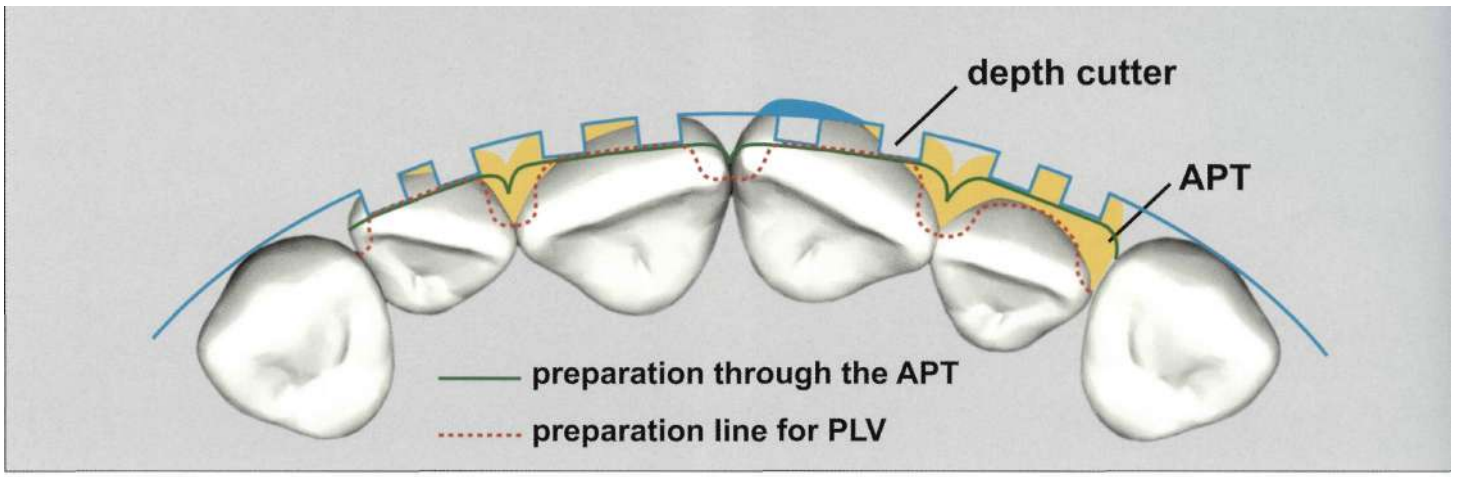

Fig 7-8 After the APR, the composite mock-up or the APT is placed over the teeth. The APT is a duplicate of the exact final out come, In order to save maximum sound tooth structure, thus to be minimaly invasive; the depth cutter is used through the APT This way the depth cutter can only go as deep as the APT allows (green line). It will be surprising to see that in most of the cases the necessary material removal will not even reach the enamel surface. In such instances, the APT should be removed and the surface of the untouched enamel be roughened, to remove the surface luster for improved bonding (red dots).

whenever possible and the geometric principles of tooth preparation for porcelain veneers are followed to maximize their strength.[43]

Sometimes the lingual inclination of the tooth can be more than the depth of our depth cutter. Therefore, the amount of mock-up composite added to that surface properly to align its position over the dental arch might be thicker than our intended reduction (e.g. more than 0.5 mm). In such cases, after we prep the tooth with our pre-decided depth cutter, we will still see some composite over the tooth. In this situation, the area that was prepped with the depth cutter relative to where the facial surface of the PLV will be is actually in a position deeper than the grid depth of the bur. This is why we should still see the composite from underneath the prepped area of the depth cutter (Fig 7-8). If this is the case, and the dentist wants the finished PLV to have maximum contact with the enamel surface, he/she should go ahead and remove the remaining composite mock-up from the surface and slightly roughen the enamel surface to remove the surface luster for improved bonding,[44-46] even though the result will be a veneer displaying greater thickness. This should be discussed with the lab, informing them that the thickness of the veneer will be thicker in that area.

New Smile Design

Proper tooth form should be developed and evaluated throughout the restorative process. In order to facilitate this analysis, and especially when designing the new smile, diagnostic information, impressions and wax-ups are all essential. More specifically, this has to be precisely applied and transferred to the mouth before any unnecessary reduction is made.

Even though the final outcome can be predicted with the provisionals that are prepared after the actual tooth prep is finished, the question is, what if the expectations of both the patient and the dentist are not met after all the teeth have been prepped? Or what if the dentist realizes that they have already removed far too much sound tooth tissue than was necessary?[47]

(A)esthetic Pre-evaluative Temporaries for Visualizing the Final Outcome

The author, after years of experience, has discovered that the best way to overcome this unpleasant surprise is to prepare what he terms "aesthetic pre-evaluative temporaries" (APTs) even be- fore preparing the teeth.

To further explain this technique: a wax-up and a transparent template should be provided by the

WWW.HIGHDENT.IR
همیار دندانسازان و دندانپزشکان

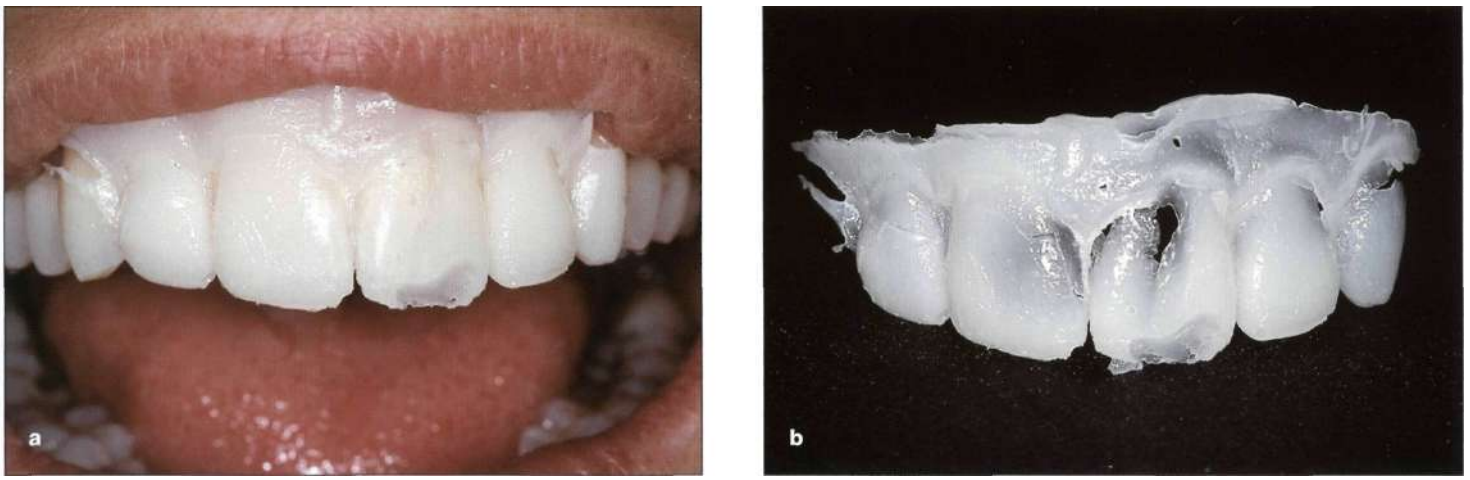

Fig 7-9a, b APT can be produced over the teeth to be prepared for a veneer construction. A transparent template or a translucent silicone impression is made from the wax-up. It is filled with a flowable composite (Luxatemp), seated on the unprepared teeth and light cured, (a) Note the show-through spots especially at the middle 1/3rd due to the position of the tooth and the thin wax-up for that area, (b) The APT removed from the mouth and showing the different depths of the existing tooth structure, in relation to the final outcome.

technician before the actual tooth prep appointment (see Chapter 9). If the dentist is not provided with a template, a translucent silicon impression of the waxed-up model can also serve the same purpose. The dentist should first finalize the APR, and eliminate all the protruding parts of the existing natural teeth that are about to be veneered, so that this template can be easily placed over the unprepared teeth (see Fig 7-6). Once the template is easily seated over the teeth, it will be filled with a flowable resin and placed over the teeth again and followed by light curing, just as if the provisionals are being made. After the composite is polymerized, the template is removed. With the help of the APTs, which duplicate the neatly prepared wax-ups exactly, the final outcome can now be easily visualized by both the patient and the dentist in terms of form, shape, length and even color (Fig 7-9). It is at this stage that phonetics, lip support, smile-line and function can be partially determined to decide what proper form and esthetic result will be achieved through the procedure. As this will be done prior to anesthesia, since the lips are not numb, the above parameters can easily be evaluated by both the patient and the dentist, using the lips as references to the new teeth position and thus smile design.

Esthetic Adjustment on APT

If for some reason the new smile design has to be modified, then minor corrections can be made over the APT. When the shape of a tooth is altered, the direction of light striking that tooth also changes. Flatter, smoother surfaces reflect a greater amount of light directly towards the observer, so that they tend to look wider, enlarged and closer to the observer. On the other hand, rounded and irregular surfaces reflect light sideward, reducing the amount of light directly reflected towards the observer. They appear to be narrower, smaller and further away. This can also be adjusted during the APR together with the application of APT, if necessary. If the tooth needs to appear narrower at the f i nal stage, the exact space for that can be provided by rounding the mesial or distal line angles of the APT before the actual prep is made. An evenly executed reduction over this preliminary preparation will give the technician the exact space needed to build up the PLV, which will look narrower. The opposite can also be done by flattening the middle portion of the tooth in advance in order eventually to achieve a wider-looking, flatter PLV surface.

However, if major alterations are to be done on the APT, in order to ensure accuracy on the

WWW.HIGHDENT.IR
همیار دندانسازان و دندانپزشکان

Fig 7-10 The exact facial thickness of the APT, and so of **the** final outcome, can be double checked with the help of the silicone index. Note that there is no gap between the silicone index and APT.

actual material preparation a quick impression should be made from the new design. A new silicon index should be prepared chairside with a heavy body silicone to be used for the final preparation, together with a new template which will be the foundation of the provisionals.

APT For Exact Facial Reduction

The major advantage of using the APT is to ensure the final outcome is accepted by both the dentist and patient. The exact facial thickness can be double checked with the help of a silicone index (Fig 7-10). As the APT now mimics the final outcome, the teeth can be prepared very precisely through the use of APT being that they represent the final contours of the actual PLVs. The APT's facial thickness and the use of depth cutters through them will dictate the necessary facial reduction. In doing so, the dentist will avoid the unnecessary loss of enamel associated with excessive tooth preparation and be able to supply the ideal preparation depth and volume forthe PLV production (Fig 7-9b). When talking about the ultimate esthetic dental approach, one should never forget that the most important factor concerning the nature of the PLV is that it cannot be thinned down or shortened without seriously affecting the outer surface, incisal edge or the general esthetics of the restoration.[5]

APR and APT for Rotated Tooth

The rotated tooth may need both APR and APT in advance. When discussing such a condition, it is possiblethatthe mesial portion of thetooth may be buccally rotated whereas the distal portion is lingually positioned. If a combination of the rules mentioned earlier is applied, it will be very easy to visualize the tilt that will transform the tooth into its normal position as it should be in a pleasant smile (see Fig *7-7).* It is obviously necessary to make a thorough, deeper preparation of the protruding prominent area so that the restoration can be made with the proper physiologic contour.[48] This can be accomplished by first contouring any of the surfaces that extend buccally.[49] The buccally positioned mesial part must be ground down enabling the dentist to visualize whether the necessary preliminary reduction has been achieved or not, by using a silicone index made from the wax-up model. Once the silicone index is properly seated over the facially reduced teeth, it confirms that the APR is successfully finished. Once this is established, the transparent template, which has actually been prepared to build up our provisionals, can easily be seated into its original position without touching the reduced, facial surface of the tooth, which was protruding before. When this is achieved, the teeth are spot etched and an adhesive is applied to the surface area and light cured.

Then the template is loaded with a small portion of the flowable composite or acrylic resin and

WWW.HIGHDENT.IR
همیار دندانسازان و دندانپزشکان

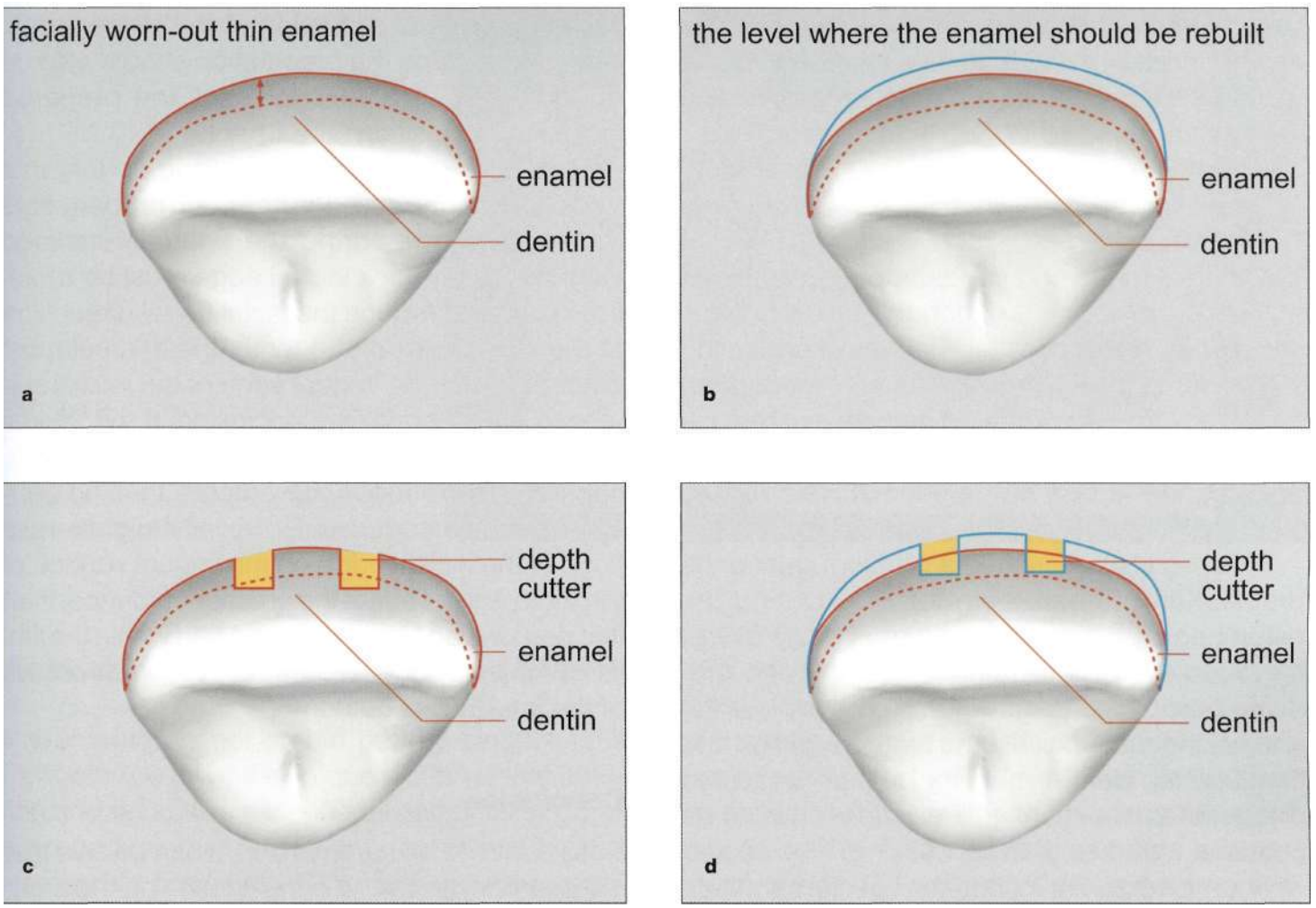

Fig 7-11a-d (a) Aged or facially worn-out central, (b) The level of where the enamel should be. That can easily be seen after a composite mock-up, or APT which is duplicating the wax-up. (c) The preparation without the APT. Note the invasion to dentin, (d) The preparation with and through APT. Note that the maximum amount of enamel is preserved, without entering the dentin.

seated over the teeth, and light cured. This way the APT is firmly seated on the teeth that are about to be prepared. This now resembles the finished surface and volume of the PLV. The two advantages of this application are that the patient will immediately see the final outcome even before we start treating the case, and because the preparation will be executed through the partially bonded temporaries it will be a very conservative preparation with no removal of unnecessary enamel with the depth cutter (see Facial Prep).

APT on Aged Teeth

This has been an aspect of veneer preparation often ignored or overlooked until now, but it becomes an important issue when this application is performed over facially eroded or aged teeth. These teeth, owing to the thinning of the existing enamel surface, have already lost their original facial volume and have become weakened. If this is not taken into account, the ignorant application of the depth cutter will be extremely destructive, resulting in the total loss of the existing thin enamel surface (Fig 7-11).[42]

It is vitally important to respect the thickness of enamel that remains during the tooth's preparation as well as the biomimetic recovery of the

WWW.HIGHDENT.IR
همیار دندانسازان و دندانپزشکان

crown and the original enamel thickness.[29] The pre-diagnosis and the material preparation of the tooth have been covered in recent research and have been found to be vitally important. When these principles are followed, the healthy tooth structure is preserved while the flex factor of the tooth is decreased.[29]

The final forms and contours of the teeth can also be accomplished during the provisionalization phase. This is possible in terms of evaluating the outcome, however, in the case of tooth prep; if the teeth are over prepared nothing can replace the unnecessarily lost healthy tooth structure resulting in the loss of the enamel which is the source of the strength of the teeth.[24]

This has always created a problem during the preparation of aged teeth for PLV. During the natural aging process, the enamel thickness of the aged teeth gets thinner and thinner, gradually losing its original volume. The thinner the enamel the more flexible the tooth becomes and therefore the dentist must try his/her hardest to preserve as much of the existing enamel as possible. However, if the tooth prep is executed without correctly estimating the special condition of the aged or worn-out teeth, almost all the existing enamel surface and thus its support will be lost. This is one of the most important situations where the APT must definitely be utilized. If the APT is not used, at least a silicon index prepared over the wax-up should be utilized (see Fig 7-5c, d). It will dictate the final volume and hence inform the dentist about the depth already lost to facial erosion. In this way, the maximum conservation of the enamel will be achieved which in turn will enhance the strength of the final outcome helping to minimize crack propagation.

On the other hand, if a solid reference such as a silicone index is not used, the extreme preservation of enamel thickness during tooth preparation often leads to overcontouring of the final restorations.[23-50]

APT For Incisal Preparation

The use of APT is not limited to preserving and exacting the final facial volume but is also used to determine the exact incisal length and the necessary amount of reduction of the incisal edge. Reduction during the preparation should also be done through the APT to exact the prepared incisal edge position (see Chapter 9).

In the restoration process, it is important that the functional incisal edge has been properly contoured. When restoring the lingually inclined tooth, an overly thick incisal edge must be avoided. In order to reduce the faciolingual dimension of the incisal part of the tooth, the enamel must be prepared to the lingual edge of the incisal surface, if permitted by the occlusion. If the lingual areas take part in the functional contacts while engaging in protrusive movements, then no alteration can be introduced. However, if slight reductions of the incisal edge on the lingual surface of the tooth will not affect the anterior guidance, then this portion can be slightly modified within the limits of the enamel to prevent excessive thickness of the final incisal outcome.

Conclusion

If this needs to be summarized, it can be said that it will be beneficial to bring these "off-the-arch" positioned teeth into a favorable position on the arch. This can be accomplished with a combination of the APR followed by filling the negative spaces, as in the case of lingually positioned worn out teeth or teeth that need to be incisally lengthened with the APT. Then one can proceed with the actual material preparation in order to finish the PLV with its proper physiological contour by establishing the teeth's new facial volume and creating the required amount of thickness all over instead of trying to duplicate the existing morphology.

Even though utilizing the APR and APT sounds like a long and time-consuming procedure, it is not—and it is extremely beneficial to the final outcome. By utilizing these procedures, nothing is left to chance. Everything is controlled and the dentist very accurately dictates the result.

WWW.HIGHDENT.IR
همیار دندانسازان و دندانپزشکان

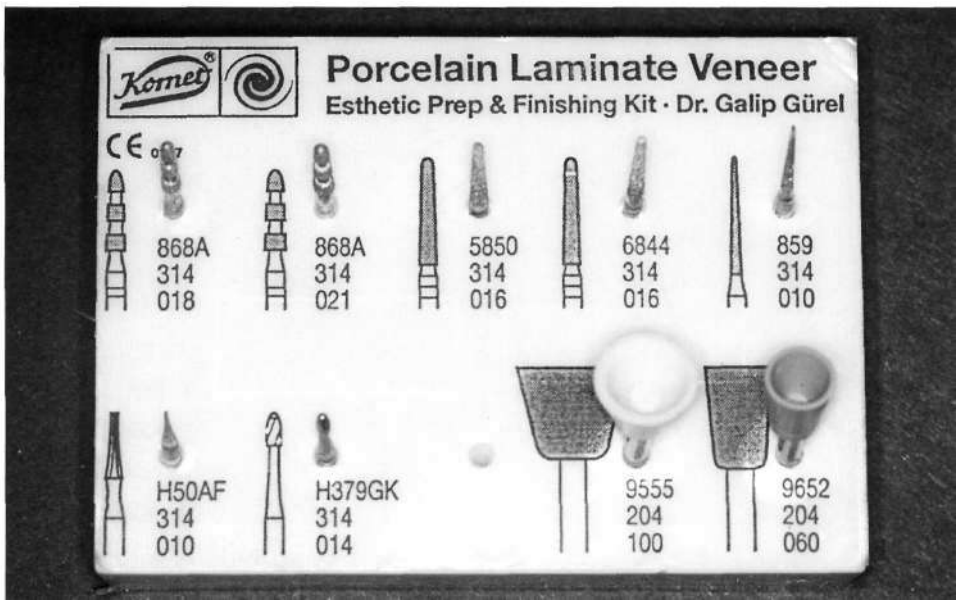

Fig 7-12 Specifically designed PLV preparation and finishing kits ease the whole procedure, since the chosen burs can be used in step-by-step techniques

Actual Material Preparation (AMP)

Instruments do not create beauty, people do.[7] PLVs provide us with a unique tool to restore function and recapture exceptional esthetics through a procedure that is not only conservative but also highly predictable. Dentists, however, may still experience problems and complications which are often related to post-bonding cracks that are mostly due to bad preparation design, insufficient spaceforthe ceramic, and inadequate bonding techniques.[34]

When PLVs were first being utilized, there was little or no tooth preparation recommended[51,53] and therefore there was a considerable increase in tooth thickness and also gingival and proximal overcontouring. The actual tooth preparation for laminate veneers has experienced many advancements and changes, especially in the last 10-15 years,[52,54,57] and all techniques believe in some form of removal of varying amounts of tooth structure.[54-58,63] Most dentists accept the importance of tooth preparation in increasing the longevity of a procedure. The enamel should be reduced by 0.3-0.5 mm in a conservative intraenamel preparation with the finish line as close to the gingiva as possible. However, no matter what the condition is, cervical preparation is essential to display the laminate's normal emergence and to prevent overcontouring.

In orderto maximize esthetics, improve fracture resistance, optimize laboratory artistry and maintain soft tissue health, meticulous tooth preparation is required forthe PLVs.[64] Although PLVs can be applied with very little tooth preparation, this should not be misinterpreted as being a simple procedure and, in fact, actually requires great skill. Various kinds of PLV preparation and finishing kits have been designed which can help the dentist to achieve success through systematic procedures (Fig 7-12).

Enamel Removal

To ensure the bond strength of the resin composite to the tooth surface it is necessaryto reduce the enamel.[44,46] Due to its poor retention capacity, the aprismatic top surface of mature teeth that have not been prepared must be removed. Careful attention is of the utmost importance in orderto obtain successful results and solid bonding.[65] As the anatomy and the shade of the restoration are directly affected by the preparation design, very precise planning is necessary.[66] The ceramic material allows for the reproduction of natural light transmission (i.e. refraction, reflection, translucency) and an esthetic result can be hindered by insufficient tooth preparation in relation to the soft tissue parameters and the restoration.[67] The shape of the preparations also influ-

WWW.HIGHDENT.IR
همیار دندانسازان و دندانپزشکان



Fig 7-13 The loops widen the working area. It is one of the indispensable armamentariums for delicate esthetic preparations.

ences the appearance and longevity of a restoration. In order to manipulate light and to establish a depth of translucency and space for the incisal effects, a minimum ceramic thickness of 0.3 to 0.9 mm is desired.[67]

Delicate Preparation

When this proves impossible, it can cause misunderstandings between the dentist and technician. In such cases, to avoid frustration, the use of available materials, space and the methods at hand will be the best solution.[66] Preparations for laminate veneers do, in fact, require great stringency and a great deal of training, as no rectification can be made once the procedure is completed.[5] Experience is required for mastery of 0.3-0.5 mm reductions.

Tooth preparation for the PLVs is exacting (Fig 7-13). Using magnification loupes to facilitate careful preparation is tremendously helpful for accomplishing this step. It also helps to preserve as much enamel as possible[15] as the bond strength of porcelain bonded to enamel is still superior when compared with the bond strength of porcelain bonded to dentin.[68]-[69] Some studies have demonstrated that porcelain veneers restore the mechanical behavior and microstructure of the intact tooth in vitro even when they are bonded to an extensive dentin surface, using an optimized application mode of dentine adhesives.[70] Recent research showed that if the periphery of the preparation can be kept on intact enamel, larger areas of dentin can be incorporated in the PLV restoration, such as is the case in traumatized or broken teeth.[41]

Relieving the Stress

A facial reduction of 0.5 mm with chamfered margins and 1.0 mm of incisal reduction are preferable considering the conservative nature of PLV preparation.[62]-[71] It is not difficultto ensurethe adequate uniform thickness that is necessary for structural integrity when under stress, when there is emphasis on conservative tooth reduction in this preparation phase.[72] A ceramic and luting composite thickness ratio of above three for crack propensity will providethe restoration with a pleasant form when an adequate even thickness of ceramic and a minimum thickness of luting composite exist.[73] Stress distribution in the porcelain laminates appears to be influenced by this ratio. Higher stress at the surface and interface of the restoration may occur when a restoration is too thin or has a poor internal fit (Fig 7-14).[74]

Precision

The tooth that is about to be prepared may be intact or damaged (broken, endodontically treated, etc.). In the case of preparing the intact tooth structure, many variables affect the preparation form and depth. The position of the tooth on the dental arch needs a different approach and different preparation depths so that an adequate amount of tooth reduction is provided for an evenly distributed PLV thickness. Protruding teeth or facially slanted teeth, even without color alter-

WWW.HIGHDENT.IR
همیار دندانسازان و دندانپزشکان

Fig 7-14a, b The thickness of the luting cement should be at least three times less than the thickness of porcelain, (a) The veneer and the tooth before bonding, (b) The cross section of the PLV bonded tooth. Note the minimal thickness of the luting resin at the tooth-porcelain bonding interface.

Fig 7-15 All the line angles should be rounded to minimize microcracksand prevent crack propagation

ations, must be reduced more to allow adequate space, so that the finished PLV will not be overbulked. Occasionally with the tooth in linguo-version, very little preparation is necessary. Most of the time, preparation of the lingually tilted tooth may be limited to creating a finish line on the proximal and the gingival regions and/or the removal of surface luster on the facial enamel. This strategy is especially indicated to improve the appearance of cone-shaped lateral incisors.

The previously explained APR and APT techniques enable these treatments to be accomplished with very little effort and the utmost precision. The slanted position of these teeth, no matter if they are lingual or facial, affects the dimensions on the location of the proximal contours. The size and shape of the facial embrasures can also affect this area. Interproximal preparation should be extended as far as the facial aspect of the contact area to ensure that the margin between the veneer and the tooth is not visible.[75]

Rounded Transitions

In order to obtain successful results, clear logic and precision are of vital importance. The most demanding of all anterior preparations is that of the PLV. In order to minimize the microcracksthat sometimes occur during the firing of porcelain on the refractory die, a uniform thickness of porcelain is needed (Fig 7-15).

Fractures along these microcracks can grow when static fatigue occurs due to the moist environment,[76] which will result in an ultimately unsuccessful restoration. The formation of microcracks will increase during the firing procedures if there are no smooth, rounded line angles between preparation surfaces produced and, instead, acute line angles between the proximal, occlusal and lingual (palatal) preparation surfaces created. To prevent crack propagation related to time-dependent stress or so-called station fatigue, rounded transitions between preparation surfaces is suggested.[77]

Dynamics of Color

The etiology and dynamics of color are important in the proper estimation of the depth of tooth reduction. The tooth enamel tends to be thicker in the incisal region and thinner in the cervical region, with a mean thickness of 1.0 mm on the incisal 2/3rds regions. Shallow, well-defined limits with chamfered finishing lines are used to prepare teeth that do not need color alteration.

Preparation depth fortheseteeth with slight discoloration must be approximately 0.3 mm in the cervical area and 0.5 mm at the middle third and

WWW.HIGHDENT.IR
همیار دندانسازان و دندانپزشکان

incisal areas The aim should be to preserve as much enamel as possible—however, it should not jeopardize the restoration planned by minimizing the preparation. In other words, the dentist should keep in mind that the exaggerated preservation of enamel thickness during tooth preparation often leads to the overcontouring of the final restoration.[50] In general, the preparation should provide a reduction of approximately 0.5 mm.[54,78,79]

In order to produce veneers with minimal overcontouring and overextension, we must use preparations with distinct margins that offer bulk as well as clear boundaries to work from. To provide the space for a thickness capable of masking a dark background color without making an excessively thick restoration should be the main aim of any restoration's preparation (see Chapter 10). There is no need for an exaggerated contour if necessary facial reduction is used and therefore there should not be any problems with the care of the teeth at the margins.[49]

The same general principles are followed with the preparations for the PLVs of discolored teeth and of those with little or no alteration. In the case of severely discolored teeth, the important difference is the extent of the preparation, as it is not only the severely discolored teeth's facial surface, but also the gingival and interproximal as well that requires a deeper preparation. To form the finish line, a slight chamfer should be placed in the enamel slightly subgingival or at the level of the gingival crest.[70]

Intrinsic shading of the porcelain is demanding, time-consuming and requires experience, but it gives the best esthetic rendition with the proper depth of color and adequate tooth reduction. Although it is time-consuming and is a skill that requires a great deal of expertise, interior shading is vital to achieve the best esthetic result that will include adequate tooth reduction as well as proper depth of color.[80] Approximately 0.5 mm of enamel removal for the majority of PLV restorations allows for the minimal thickness of porcelain. Some believe that the best enamel removal is 0.75 mm,[81] but, no matter what the depth is, the required uniform reduction can be achieved by following an orderly progression of steps.

Patient Communication

Besides the physiological conditions of the tooth, understanding what you and the patient would like to accomplish will often dictate the type of veneer preparation to be used. This is particularly true in patients who wish to have their esthetic appearances changed or improved. On the surface of the anterior teeth the enamel on the gingival half of the labial surface is quite thin. Especially in the cases of discolored teeth, where the gingival margin needs to be hidden by means of extendingthe preparation linesubgingivally, the dentist should evaluate the smile-line and the position of the cementoenamel junction.

Although it may be necessary to hide the discoloration at the gingival margin, in the cases of patients with a low lip-line, it should be discussed with the patient. The positive and negative aspects of placing the PLVs subgingivally must be explained, and in such cases the patient's esthetic concerns and desires will be definitive. If it is decided that the margin will be extended apically, then the cementoenamel junction should be properly identified. Usually in the case of gingival recession, this junction may be level or supragingival with the soft tissue level that means the preparation should be placed overthe cementum or dentin.[49] The results of the newest generation of dentin adhesive systems are very promising.[68,69] However, when cervical margins are bonded to dentin or cementum, the longevity of the restoration is questionable due to the leakage atthe margins. Ideally, cervical margins should be located in the enamel.[50,70] If this is not possible, the patient should be informed that this is not an ideal indication for the procedure.[82]

Deeper Preparations

Preparation of crowded teeth also needs a preplanned, delicate approach, especially if the mandibular incisors are of concern. Since some special cases need more aggressive preparation depths, such as in the case of the discolored or facially misaligned teeth, reduction of the facial surface on the teeth that suffer from severe discoloration must not be limited to the enamel (see

WWW.HIGHDENT.IR
همیار دندانسازان و دندانپزشکان

Chapter 10). The preparation will have to be deeper, even if it exposes the dentin. Whenever it is feasible, increasing the depth of reduction to 0.5 mm in the cervical region and 0.7 mm in the middle third and incisal areas is recommended.

Proper Preparation

Lengthening the tooth requires special attention during the preparation stage. The occlusion, especially the anterior guidance, should be very carefully evaluated. If the anterior guidance needs to be altered with the help of the PLVs, then palatally finishing preparation lines can be applied and in doing so the facial-palatal thickness of the incisors should be taken into consideration.

Rigidity in the tooth is due to the amount of enamel thickness and thus the more enamel that is removed the more the tooth flexes. Throughout our lifetime the teeth change in color, volume and flexibility. Sometimes teeth that are facially eroded or deficient in enamel should therefore be minimally prepped with very little or no reduction other than the definition of the margins. Preservation of this valuable existing enamel can only be sufficiently achieved when APT and/or silicon index are used during the preparation (see Chapter 9).[83] In the actual tooth preparation thereshould be control of the contour, emergence angle, margin, facial profile and the color. Influence over the margin placements, veneer seating, placement and bonding are also important for both the dentist and the technician. Some of the advantages of proper tooth preparation include careful management of porcelain bulk for occlusal loading, preservation of the glaze in the finishing procedures, tooth recontouring for misalignment and enamel etch by removing the fluoride-rich layer.[61]

Surface Roughness

Dental literature has often argued about the final surface roughness of the preparation. Some studies have shown thatthere is greater retention when the tooth is prepared with diamond stones.[84,85] In contrast, other studies have found little difference between rough and smooth preparations as far as retention is concerned.[84,86,87] A recent study reports that the level of efficiency in cutting does not increase when coarser grits are used as opposedto medium (100 micrometer) grits.[88] The author believes in using a medium coarse diamond to create a more retentive surface for better bonding. The bur selected for the "esthetic preparation and finish kit" (Komet #5850 314 016) number perfectly fulfills this purpose. In addition, the extra-fine round-end tip provides a very smooth champher margin at both the gingival and interproximal margins.

Acquiring a smooth surface requires light pressure of the hand piece during preparation as excessive force can result in pulpal damage. There is little improvement in the cutting efficiency if the hand piece load is increased beyond the clinical range of 50 to 150g. Degradation and debris accumulation of the bur are more important and both have an affect on efficiency.[89]

Hand Pieces

Magnification, illumination and other technical improvements (e.g. electric hand pieces) are of the utmost importance in producing precise natural restorations. Certain hand pieces differ from the traditional air-turbine, and operate more concentrically, allowing enhanced speed control, such as in the use of a high-torque low-speed electric hand piece. These tools enable the dentist to develop their tactile sense, which is reflected in their work. Caution must be observed when the high-speed tooth preparation is done with ultra-coarse diamonds that can induce thermal damage in the pulp tissues.[90] Plenteous irrigation with the low-speed electric hand piece may helpto prevent thermal damage to the pulp and deserves further enquiry. Oscillating hand pieces (KaVo) can also be used, while preparing an incisor, adjacent to another unprepared teeth.

WWW.HIGHDENT.IR
همیار دندانسازان و دندانپزشکان

Facial Preparation

Facial Convexity

Today restorative dentistry means the production of biocompatible restorations that exhibit a very natural appearance. If tooth preparation is not properly preformed it is difficult, if not impossible, to copy the natural dentition with the manipulation of light that today's ceramics are capable of.[35]

During the preparation of the buccal plane the facial of the incisors, which are convex, should be addressed in the incisal, middle 1/3rd and cervical aspects.[3] Different characteristics are apparent when viewed from the mesial and distal aspects.[91] The maxillary central incisor's vertical mesial line angle profiles are basically the same, and the cervical, middle and incisal portions of the central display proportions of 1 to 2 to 3 respectively, when viewed from the mesial prospective. However, individual variations of the vertical distal line angle of the maxillary centrals exist. The variations in length (according to each developmental lobe) of the cervical, middle and incisal aspects of the buccal plane add diversity and character to the anterior teeth.[91] Preparation according to the length of these three aspects of the buccal surface enables the dentist to preserve character in the veneer restoration.

Depth Cutters

Accurate judgement of size, depth and angle is required in the practice of restorative dentistry. Most assessments are made simply by visual examination, and are therefore often subjective. The limitation of visual perception renders such judgements inaccurate and subject to variation. Ceramic laminate veneers have become synonymous with controlled enamel preparation. It is a substitute enamel that closely resembles the natural tooth enamel with its optical, mechanical and biological properties.[5]

The use of standardized objects to allow size or angle judgement by direct comparison improves accuracy, and their routine use may improve the quality of the restorative treatment. Two different-sized depth cutters (Komet # 868A.314.018 and # 868A.314.021) control the depth of the facial tooth preparation. They enable the dentist to guide, visualize and quantify enamel reduction. Due to the rounded tip, margins can be plotted if deemed necessary. When the color changes are two shades or less,[61] as in more than 90% of the cases, 0.3 mm and 0.5 mm depth cutters are used. Without a depth guide, it can be dangerous to gauge reduction in enamel depth between 0.3 mm and 0.5 mm.[5] However, if the pre-operative evaluation is not done properly, these depth cutters can be very destructive in terms of unnecessary sound tooth structure loss, and thus weaken the intact tooth structure (see APR and APT).

Necessary Depth

PLV restorations can at times fail to meet the expectations of the dentist and patient owing to dissatisfaction with the tooth color. This is often due to the relative thinness of the PLV and the light that they allow to pass through making the background color of the tooth and mouth somewhat visible. To overcome this, the dentist must increase the PLV thickness by deepening the preparation to minimize the effect on the restoration.[48] In other words, greater reduction is required to provide the necessary thickness for the proper optical properties inthe veneer in order to block or change tooth color.[15] The color and position of the existing teeth will determine the technique to be used in order to achieve a desirable result. The facial preparation should reduce an adequate amount of tooth structure to facilitate the placement of the PLV. Depending on the severity of the tooth discoloration, additional reduction of the facial enamel may be required at the expense of dentin exposure to generate adequate space for the PLV to hide the discoloration. When preparing an individual treatment plan, three different preparation depths, "minimal", "medium" and "deep", should be considered.[16-92]

In the "minimal" preparation, the teeth that are about to be restored are no more than one shade different from the proposed final PLV restoration

WWW.HIGHDENT.IR
همیار دندانسازان و دندانپزشکان

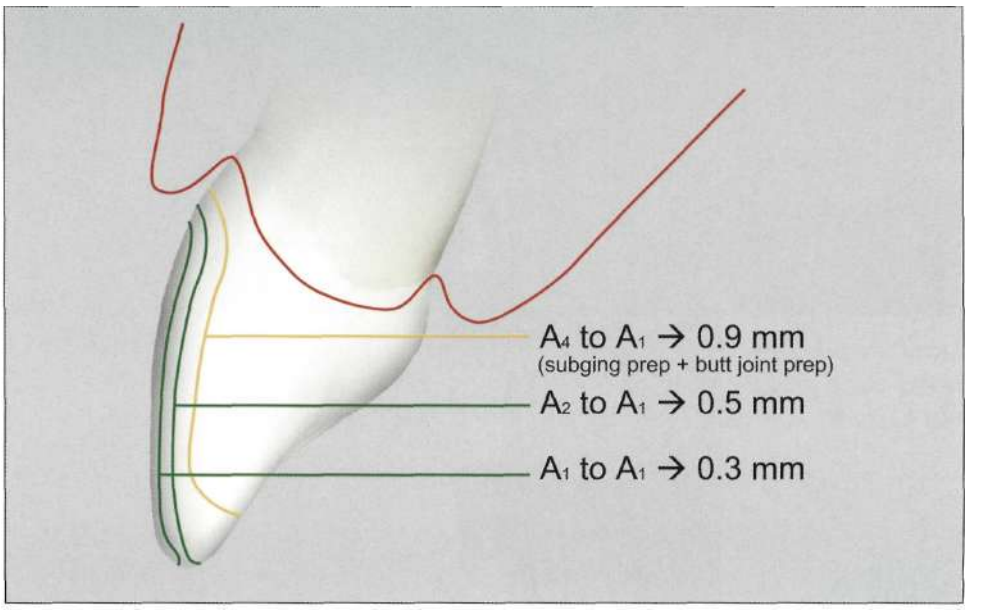

Fig 7-16 Generally speaking, a depth of 0.2 mm is needed to change the hue of the tooth by one shade.

color, and therefore only a 0.3 mm reduction is required from the proposed contours. The background color will provide a natural look and the margin location will be supragingival.

In the "medium" preparation, the shade variation with the original tooth color is up to two or three shades in comparison with the proposed PLV color. More attention to the modification of the background shades will be necessary in these cases in order to acquire the desired level. Approximately 0.6 mm space from the proposed contours is required fortooth preparation, with the margin location at the gingival crest. When the tooth is dark and a shallow preparation must be done, a differenttechnique can be used to achieve the final desired color with a relatively thin PLV. The resulting shade can then be a combination of the existing tooth shade and a thin PLV lighter than the shade that it is expected will be achieved through the restoration. To create an A2 shade when the background is A3.5, the technician will use A1 shade in order to achieve the desired effect.

In the "deep" preparation we are dealing with three *or* more shade differences between the desired shade and the original teeth. When a considerable difference in color exists, masking is required. Masking provides the desired color by hiding the unwanted discoloration. Subgingival margin location will frequently be necessary.[16] In general, the underlying hue can be modified by one shade for every 0.2mm of tooth reduction (Fig 7-16).[93]

Enamel Thickness

Enamel has different thicknesses at the gingival, middle and incisal 1/3rds of the facial surface of the tooth. They can be 0.3-0.5 mm at the facial gingival third, upto 0.6-1.0 mm at the middle third and 1.0-2.1 mm at the incisal third.[94]

This indicates that having these variables both on the surface texture (i.e. convexity) and using a special diamond instrument at different angles, designed specifically for the task, can better facilitate enamel thickness tooth preparation. Diamond depth cutters (originaly designed by Dr. *Tuoti)* (models 868 A.314.018 and 868A.314.021 Brasseler, Germany) have different cutting depths within themselves, relative to the enamel thicknesses of the facial surface of the incisors. The self-limiting depth cutter is designed so that it can cut to a depth limited to the radius of the wheel (Fig 7-17). The wheels are limited to penetrating the enamel until the shaft is flush with the tooth surface. Course diamond wheels with different diameters mounted on a 1 mm-diameter noncutting shaft create the correct depth - orientation grooves on the facial surface of the incisors. Once again, the wheels cutthrough the enamel until the

WWW.HIGHDENT.IR
همیار دندانسازان و دندانپزشکان



Fig 7-17 The depth cutter can only penetrate until the noncutting shaft is flush with the tooth surface.

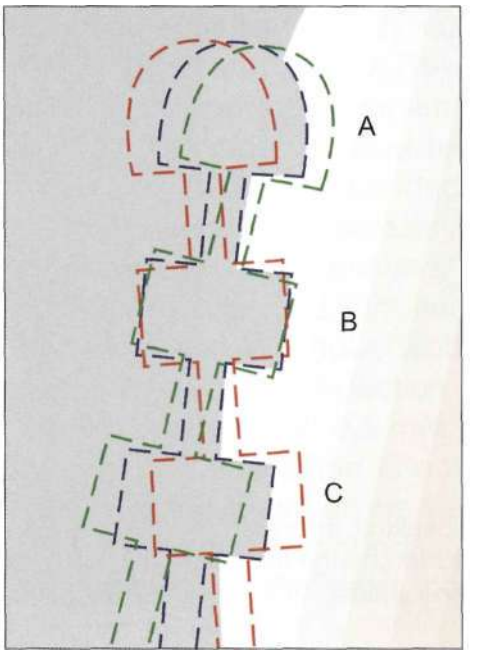

Fig 7-18 The surface after the depth cutter is used in only one angle. Note that the only true depth is gained in the area of B (middle 1/3rd, black dots). To reach the necessary depth on points A (gingival 1/3rd, green dots) and C (incisal 1/3rd, red dots), the bur should be used in three different angulations.

shaft is flush with the surface, and 0.3 to 0.5 mm deep grooves are created. The most important issue here is to hold the depth cutter at three different angles so that all the diamond wheels will be able to reach the necessary depths.

Technique

At the beginning of each preparation horizontal grooves are traced. Labial surface striations are apart from the margin. Especially in the case of the lower premolars and the canines, the three striations are very rarely allowed on the natural curve of the facial surface.[5] When the bur is held parallel to the surface of the tooth, only the middle (Fig 7-18) section of the three-tiered deep-cutting bur penetrates into its entire depth, which is due to the convex labial surface of the tooth.[95] Under-preparation of the cervical or incisal area can be avoided by positioning the bur at three different angulations to ensure its penetration.[96] However, if an APT is not used, extreme care should be taken to prevent over-preparation of the tooth, especially in cases of malpositioning or loss of enamel volume due to aging. As the tooth preparation is developed from calibrated depth cuts, the incisal 1/3rd of the preparation will assume a correct position as the facial convexity of the tooth about to be prepared serves as a reference.[3]

Painting the Surface

Once the desired depths are achieved and horizontal groves are prepared, the remaining part of the APT can be removed (Fig 7-19). To further remove the remaining tooth structure found between the depth-orientation grooves, and to acquire the desired depths, a tapered round-ended fissure diamond bur (originaly designed by Dr. *Goldstein* (model 5850.314.016 Brasseler, Germany) is used. Painting of the facial surface of the tooth with waterproof paint enhances the contrast between the prepared and unprepared teeth, and is a useful method for inexperienced eyes (Fig 7-20). The horizontal grooves will remain painted until the desired depth is acquired through the use of the round-ended fissure diamond bur (Fig

WWW.HIGHDENT.IR
همیار دندانسازان و دندانپزشکان

Fig 7-19a-c (a) The depth cutters are used through the APT. This will provide the dentist with the minimal invasive preparation, (b) The APT after the depth cutter is used. Note that remaining parts would have been uselessly prepared if the APT was not used, (c) The horizontal grooves produced through APT. Note how shallow the grooves are.

Fig 7-20 Coating the surface of the tooth with a water insoluble tint allows the depths of the horizontal grooves to be more easily perceived. Note the horizontal grooves hardly reach to the distal of the central and mesial of the lateral. Any unnecessary entry is prevented by the preparation done through the APT.

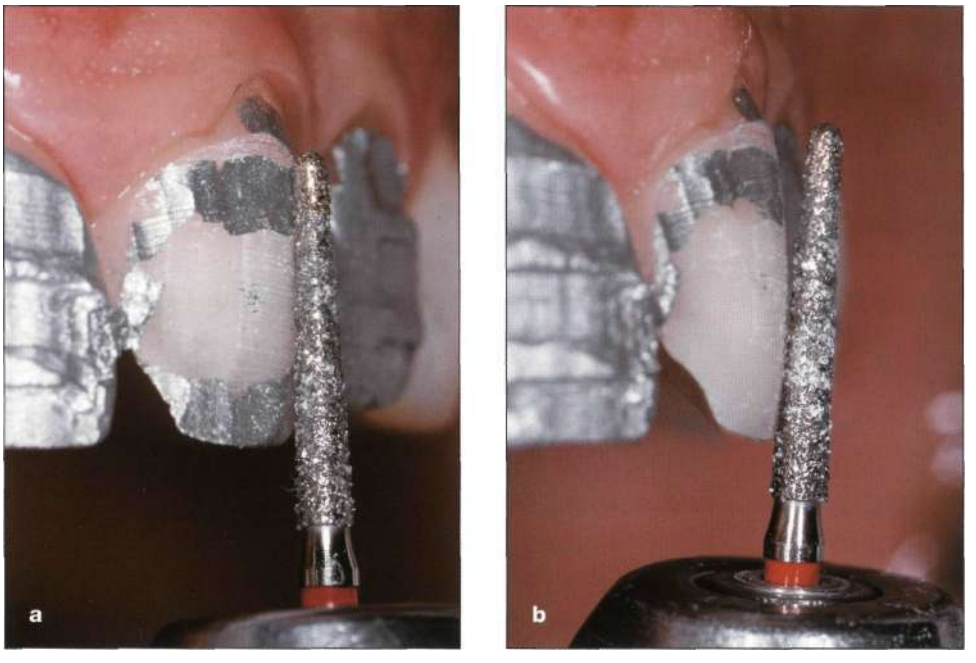

Fig 7-21 a, b (a, b) The round ended fissure diamond bur is used in three different planes until all the color at the surfaces of the bottom of the grooves disappears. This will indicate that the true actual material preparation depth is fully achieved.

WWW.HIGHDENT.IR
همیار دندانسازان و دندانپزشکان

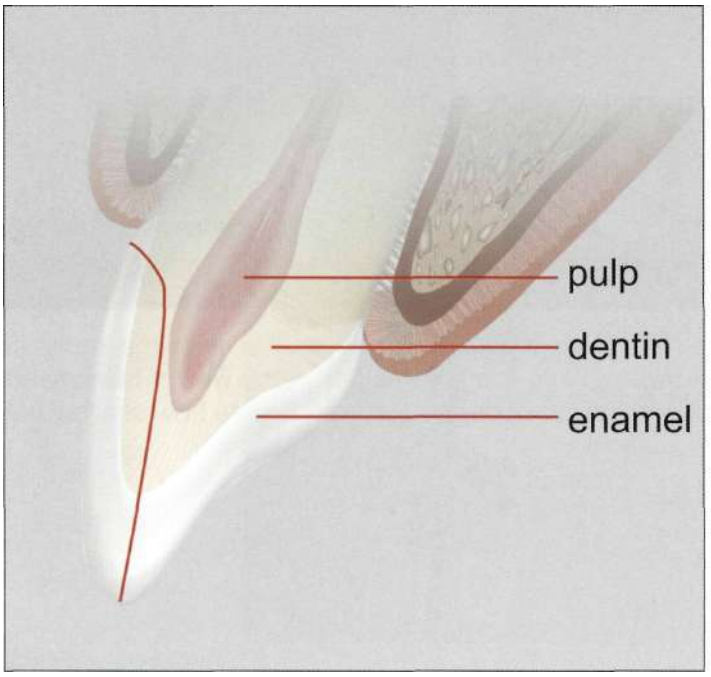

Fig 7-22 Tooth preparation without respecting the facial convexity. Such straight preparations can result in irreversible pulp damage.

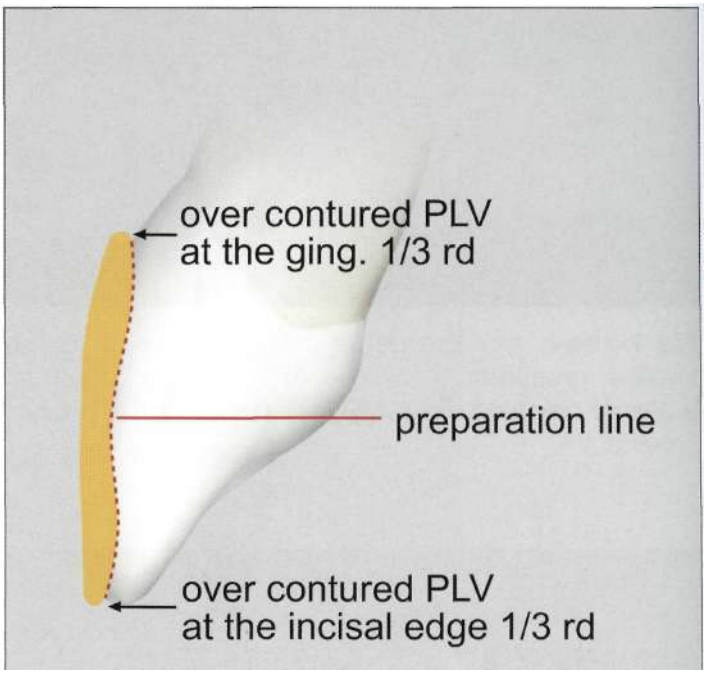

Fig 7-23 If the incisal or cervical 1/3rd is not prepared deeply enough, the final PLV may be overcontoured in this area.

7-21).[91] To provide a natural healthy look for the incisor that mimics its true convex nature, a uniform removal of substrate is essential and can be achieved through the use of the bur, keeping it at three different angles. Otherwise, one plane facial reduction may come too close to the pulp (Fig 7-22).[97] When thediamond is swept in the mesiodistal direction, a gentle convex surface in the gingival and incisal 1/3rds is obtained.[15] The facial reduction is complete once the paint becomes invisible on the facial side, and to complete the final reduction, the horizontal labial depth grooves are connected.[91]

Preparing the Incisal 1/3rd

A common error is to place the incisal 1/3rd too far labially in the final restoration.[98] This is frequently due to insufficient tooth reduction (Fig 7-23). The preparation must reproduce the natural convexity of a maxillary central incisor and provide for a minimum reduction thickness of 0.7 at the junction of the middle and incisal thirds of the tooth.[99-100] Insufficient tooth reduction, in terms of leaving a sharp line angle and not rounding off the incisal labial area, is the leading cause of an overtapered preparation, or produces opaque show through, or overcontouring of the incisal third of the restoration. This will not only influence the external facial form of the tooth, but the light reflection as well. Light reflects off the tooth and travels through it at the incisal. If the edge has a rounded surface at the incisal-labial, that reflected light is being diffused and yields an ideal transition of the shade from incisal color to body color (see Fig 7-38).

Silicone Index

Using a silicone index is a controlled way of prepping the remaining portion of this side and can frequently determine sufficient tissue reduction during the preparation of the tooth.[5] This can be prepared by the dental technician from the initial wax-up model. When viewed from the incisal preparation depths, cutting the silicone index into horizontal slides can follow different vertical levels of the facial surface.[101] The middle or gingival 1/3rd can be visualized when the slides are moved once the incisal 1/3rd has been checked. The desired homogenous depth can be completed in this accurate way (see Fig 7-5).

WWW.HIGHDENT.IR
همیار دندانسازان و دندانپزشکان

Gingival Preparation

The fabrication of the PLV is directly affected by the placement of the finishing line. Smooth margins that are fully exposed and readily cleansable generally provide the best results.[102] Consequently, the essential key here is for the dentist to place the finishing line where the margins of the restoration can be kept clean by the patient and properly finished by the dentist. In addition, finish lines must be placed so that they can be duplicated by the impression, without tearing or deforming the impression when it is removed past them.

Unlike circumferential preparations, and like the metal ceramic crowns that have their margins buried into the sulcus, the thin porcelain and the resulting chameleon effect on the cervical margin enables the dentist to place the gingival margins of the PLV supragingivally. With no cement line or metal margin visible, the porcelain blends in with the underlying composite resin in a harmonious finish. Whenever possible, the finish lines should be placed in the enamel following the contour of the soft tissue from mesioproximal to distoproximal.

Kourkouta, et al.[103] demonstrated that afterthe placement of the PLVs there was noticeable plaque index reduction and plaque bacteria vitality. Forthose patients who have problems with oral hygiene, PLVs are the restorations that cause the least problems.[29] In comparison to gold, resin or hard tooth structures, dental porcelain is less likely to accumulate bacterial plaque and therefore the periodontal response is favorable.[104-105]

Supragingival Margins

Placement of the gingival margin supragingivally or coronally frees the gingival margin. This has many advantages such as: eliminating the chances of injury to the gingival tissue, cutting down on the risks of undue exposure of the dentin in the cervical region and obtaining crisp clear margins, as impressions are easier to make with supragingival preparations compared to subgingival preparations. It also increases the likelihood that the restoration will end on enamel and this increased area of enamel is extremely important for stronger adhesion and less microleakage in the future.[48]

Microleakage

Finishing the gingival margins supragingivally also has other positive aspects. During the try-in and bonding stages, proper isolation of the operative field is easier, so moisture control and the chances of contamination during adhesive procedures are reduced. It also offers easier access for the finishing and polishing stages with easily accessible margins. Postoperatively it eliminates the possibility of impingement on biological widths by an inadvertent overextension of the preparation, making it possible for the patient to perform meticulous hygiene in this critical region and allowing the dentist to evaluate marginal integrity during the follow-up and maintenance visits.[48] Restrictions to enamel[106,107] are a necessity for marginal tooth preparations and bonded restorations, including ceramic veneers, as exposure of the dentin margins may reduce bond strengths and increase the chance of microleakage.[94,108] When the preparation margins are completely located in the enamel, microleakage is minimal or none at the tooth/luting composite interface[50,70-82,109,110] and negligible in the luting composite/porcelain interface.[50,70,82]

Enamel in the cervical region has a prismatic configuration.[111,112] The poor marginal sealing that is often reported in the porcelain veneers in vitro at the cervical margins may be due to the fact that aprismatic enamel is generally located in this region where the veneer preparations end.[50,82,110] In spite of this, it is always better to finish the cervical margin on enamel since more microleakage has been found at the luting composite/tooth interface when the cervical preparation margin was located in the dentin.[280]

Subgingival Margin

The reaction of the gingival tissues largely depends on the cervical extension of the restoration in regard to the location to the gingival mar-

WWW.HIGHDENT.IR
همیار دندانسازان و دندانپزشکان

gin.[113] Generally speaking, the major etiological factor in periodontitis is the subgingival placement of a restoration.[114,115]

On the other hand, it is reported that PLVs typically show less gingival reaction than metal ceramic restorations as the extension comes closer to or below the gingival margin. In a majority of the cases, the subgingival margin preparation of the intracrevicular margins should be placed at about half the width of the crevice depth. To create a buffer zone between the epithelial attachment and the bur, it is best to place the margins half way in the crevice to leave enough space for the gingival cord placement.

Sometimes the preparation may be deeper than the desired depth. If the objective is to place the margin at half the depth of the sulcus, there will be some leeway preventing encroaching of the epithelial attachment of the biologic width. The deeper the restoration margin resides in the gingival sulcus, the greater the chance of inflammatory response[116,117] and that such tissues can bleed upon probing.[118,119]

Although some studies reported that no differences between subgingival and supragingival margins were seen, it is still recommended that the placement be supragingival whenever possible.[102,120]

Another aspect is the difficulty of visually following the cervical margins so that even the experienced restorative dentist can miss marginal defects as great as 120 micrometer when the margins are subgingival.[121] On the other hand, placing the veneer preparations slightly subgingival^ allows the technician to preserve the existing height of the papilla as well as to make certain that all interproximal spaces and/or diastemas will be closed while permitting control over the emergence profiles.[122]

In non or minor tooth color changes (such as one ortwo shades lighter), there is no need to prep the tooth subgingivally. In other words, once the teeth are free from discoloration or presenting "discreet color alteration", the gingival margin must not be placed in the gingival sulcus.

It is not only the color but the nature of the lip-line as well that determines whether the PLV marginal placement will be supragingival, equigingival orsubgingival. Supra or equigingival placement is preferred for the patient with a high lip-line. If there is gingival exposure while smiling, subgingival placement may be necessary in order to achieve desirable esthetic results, but to a certain extent it depends on the esthetic expectations of the patient.[123]

Chamfer Preparation

It is almost impossible to finish an accurately fitting PLV without being overcontoured over a knife-edge preparation at the cervical area (Fig 7-23). Therefore, irrespective of its placement (sub or supragingivally), a chamfer is preferred for all the gingival margins. A study was conducted using finite element analysis to gauge the total strain on porcelain stresses on 90- and 120-degree shoulders and chamfer preparations, with the chamfer showing the most resilience.[124] In comparison with the 90-degree shoulder, the chamfer finish preserves more natural tooth. Owing to the gradual color transition between restoration and tooth substrate, thereby avoiding the sudden delineation between tooth and crown, it is also a better option esthetically.

In order to obtain a very distinct and visible finish line, removal of the serrated, overhanging enamel prisms is essential.[123] To avoid periodontal inflammatory responses and future gingival recession, improving gingival architecture, survey lines and points of concavity with a chamfered margin while carefully controlling the anatomical contours in the cervical third, is of the utmost importance.[124] The rounded tip of the fissure diamond bur will enable the cervical margin to be initiated slightly above the gingival level.

Enamel Thickness

One of the major concerns the dentist should be aware of is that the thickness of the enamel decreases in this area, especially when moved apically. This becomes more obvious towards the cementoenamel junction. Consequently, the preparation of this area should be kept to a minimum and ideally should not exceed the depth of

WWW.HIGHDENT.IR
همیار دندانسازان و دندانپزشکان

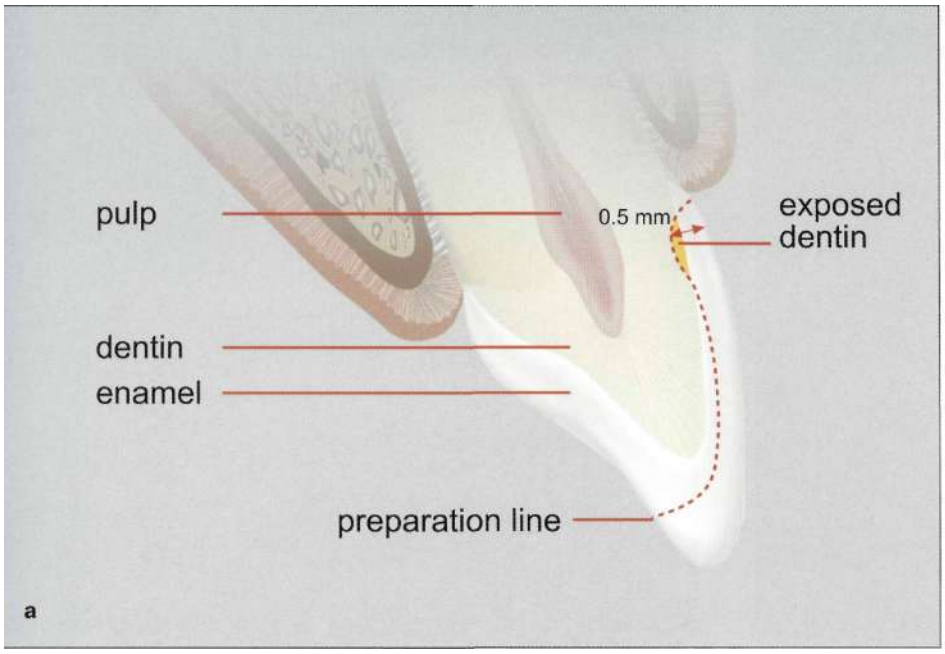

Fig 7-24a, b The round-ended fissure diamond bur is held almost parallel to the facial inclination of the cervical **1/3rd** to prepare the cervical margin. In most of the cases a preparation depth of 0.3-0.5 mm ends up in exposing the dentin in the cervical area.

0.3 mm labio-lingually, which is the minimum recommended thickness for the PLV during fabrication.

However, primarily due to the extent and thickness of the enamel, a reduction of 0.3-0.5 mm in the gingival area of the anterior teeth is not possible without interfering with the dentine.[94] The mean thickness of enamel at the gingival third is 0.4 mm on the maxillary central incisors and only 0.3 mm on the maxillary lateral incisor.[94] In actual daily practice in the majority of cases where the dentist has used a freehand preparation technique, not only is the dentine exposed but the proximal and cervical enamel is reduced to more than 0.5 mm (Fig 7-24).[125]

Gingival Displacement

Supragingival preparations do not need special attention. However, if the preparation is subgingival, it necessitates the displacement of the gingiva, to avoid injury. During preparation, gingival displacement is achieved by delicately inserting the braided retraction cords into the sulcus so as to avoid any bleeding. It may also be beneficial to use non-medicated deflection cords instead of the medicated ones as they may be the cause of secondary gingival recession. While doing this, the coronal preparation limit of the gingival contour of the tooth can be recorded, before the gingival displacement. If the dentist wants to be certain of the exact placement of the cervical margin in order notto make a deeper preparation than is necessary, he/she should draw a line at the present location of the gingival cavo surface margin with a sharpened pencil or a water insoluble pen before placing the tissue displacement cords into the sulcus (see Chapter 10).

Dentin Exposure on the Margin

In the majority of cases, the placement of the gingival margins for the PLV is open to subjective criteria. However, there will be some situations where subgingival margins are unavoidable, such as in the case of caries or old fillings that extend under the gingiva (Fig 7-25).[126~130]

Patches of dentin exposure are no longer a problem during the preparation as long as the margins are kept on the enamel. However, in most of the abnormal situations, such as extensive caries lesions in the gingival areas, placement of the subgingival margin can go as deep as to be placed on the dentin. Therefore, in order to stop,

WWW.HIGHDENT.IR
همیار دندانسازان و دندانپزشکان

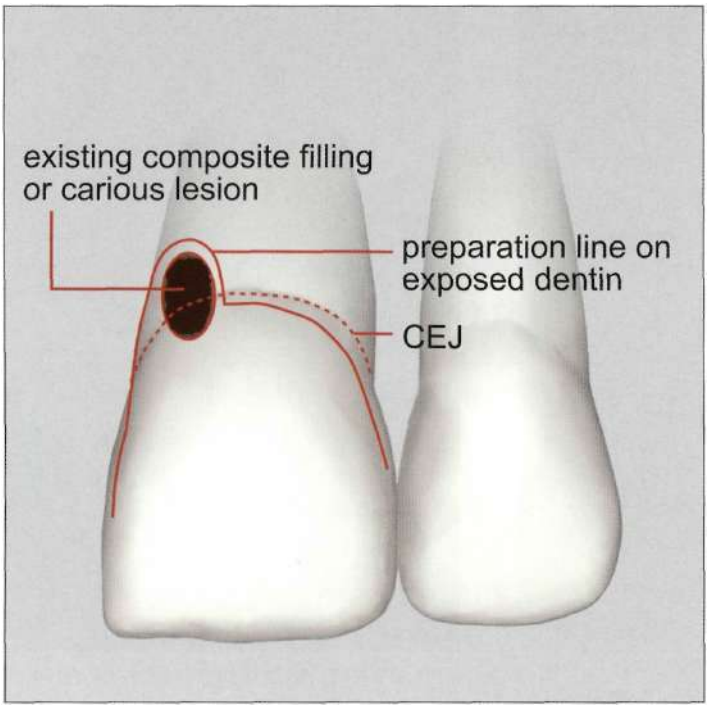

Fig 7-25 Cavities that extend over the cementum may be the reason for an extended marginal preparation line towards the apex, leaving the margins with exposed dentin or cementum.

Fig 7-26 It is important to control the depth of the preparation in relation to the radius of the round-ended diamond bur to avoid the formation of a reverse margin.

or minimize, the possible marginal leakage, the dentist should very carefully identify the condition of the existing dentin. Thus, obtaining a successful bond to dentin with a perfect marginal seal that will not exhibit discoloration[131-133] has became a much larger problem that has occupied many researchers over the past four decades.[134]

When dealing with the depth of the preparation, the dentist must be aware that the dentin has a mean thickness of 2.3-3.0 mm[135] In all age groups, the most critical area of bonding at the level of the cementoenamel junction is the superficial and middle-deep dentin, which consists primarily of intertubular dentin. It is not the tag formation into the tubuli, but the interlocking of the bonding agent to the collagen network of the intertubular dentin that seems to be responsible for the adhesion of composites to the dentin.[136] The age of the dentin has only a minor influence on the bond strengths and sealing capacity of the dentin bonding agents.

Sclerotic Dentin

Bonding to and preparing the sclerotic dentin is slightly different from normal dentin preparation and may necessitatefurtherattention. When there is a sclerotic area in the cervically exposed dentin in the gingival margin, there is a morphologic differentiation to the unaffected normal dentin. Numerous tubules obstructed by highly mineralized peritubular dentin are characteristic of this.[137] The sclerotic surface zone is removed during preparation and/or decalcified by extending the application time of the etching gels, so that adhesion to this altered dental material can be achieved.[137-141]

Abfractions

Abfraction is another interesting feature of the condition of the cervical area, due to occlusal disturbances especially in the premolar areas. If the problem is not solved, however, this PLV system will eventually result in failure, as it appears not to be capable of preventing occlusal load from causing accumulated fatigue damage in vital dentin and enamel.[142] Interfacial debonding of the enamel and dentin may be due to highly stressed regions of the dentoenamel junction and the gingival third of the crowns.[143-145] Unsuccessful retention of the restoration may cause gap formation at the cervical margin.[146-147] Therefore, in

WWW.HIGHDENT.IR
همیار دندانسازان و دندانپزشکان

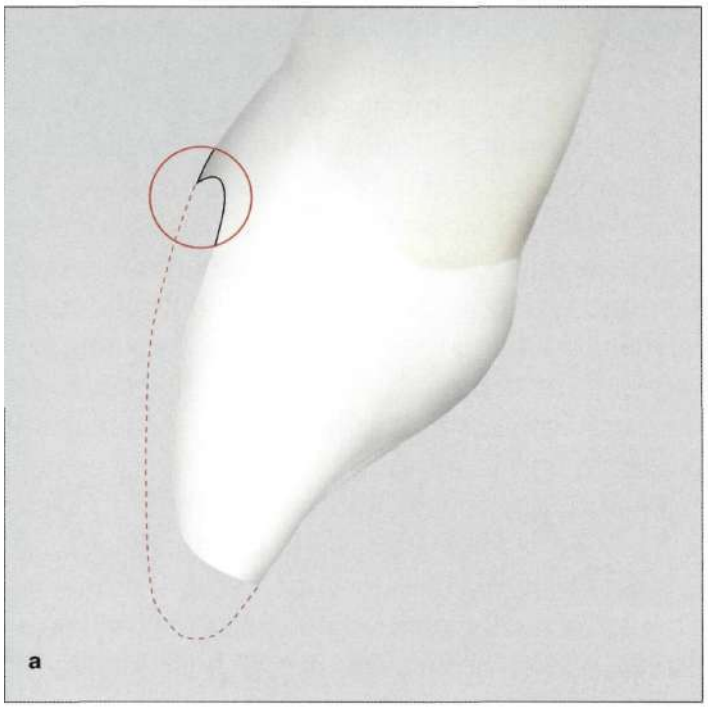

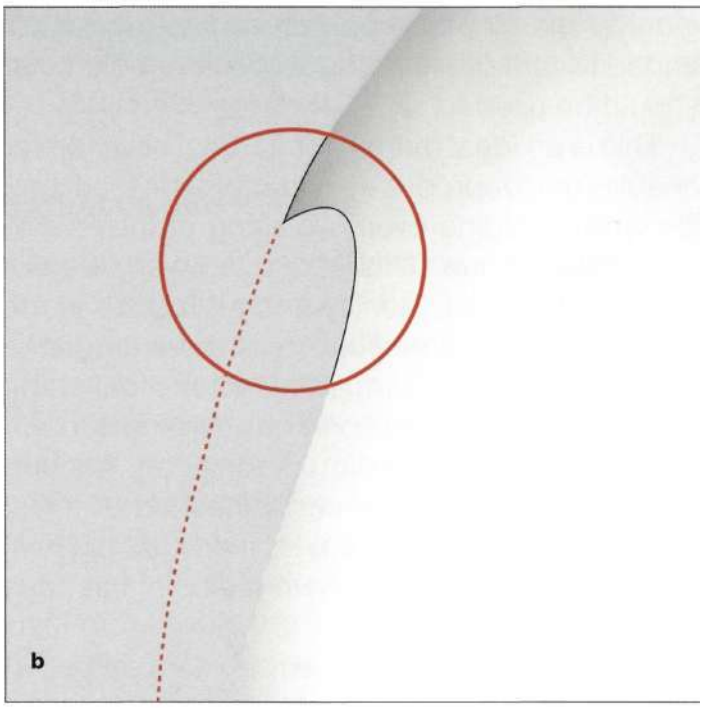

order to achieve success in such cases, occlusal disturbances have to be corrected before starting the preparation.

Technique

Afterfinishing the preparation of the labial surface, the round end of the fissure diamond bur (model 5850.314.016 Brasseler, Germany) is held almost parallel to the inclination of the cervical 1/3rd of the labial preparation surface and moved from the apical end of the distal proximal surface towards the apical end of the mesial interproximal surface, delicately following the gingival contour. This gingival contour should already have been esthetically shaped and the gingiva must be in optimum condition. To improve the health of the tissue or for esthetic recontouring, if any periodontal surgery need be performed, a minimum of 6-8 weeks should be given for the tissue to heal completely and settle into place, thereby eliminating the chances of tissue displacement.

The physical properties of the fine diamond particles located at the tip of a two-grit diamond bur give us the chance of removing and finishing the cervical margin, while at the same time refining it to a very smooth finishing edge. Coarser diamonds should be used sparingly as they may cause cracks at the preparation margins that can reduce enamel toughness. In time, this will lessen the resistance to crack propagation within the enamel. Diamond tips with progressively finer grits and reciprocating handpieces[148] remove the median-type cracks and microcracks between and within the enamel rods, and result in the smoothest of finish lines. Resultant preparation margins become stronger with fewer cracks through the use of this method.[149]

The final cervical margin will take on the profile of a mini chamfer, measuring an average of 0.3 mm, and matching the tip of the diamond instrument. It is also important to pay attention and not to exceed the cementoenamel junction, which if violated during the preparation may be a reason for microleakage at this junction in the future.[150]

When the chamfer margin preparation is deeper than one-half of the width of the bur, a thin shell of reverse margin is occasionally left (Fig 7-26).[151] This reverse margin is difficult to impress and is subject to fracture in the lab by distorting the marginal fit or on the tooth leaving a marginal gap between the PLV and the tooth. If deeper chamfer preparations need to be placed at the

WWW.HIGHDENT.IR
همیار دندانسازان و دندانپزشکان

gingival margin, the appropriate fine-grit round-ended fissure diamond burs of a larger diameter should be used.

This is an ideal margin for a PLV. This chamfer enables us to reproduce a natural visibletooth profile while avoiding overcontouring of the PLV in the cervical zone. This accurate finish line will be easy to record, identify and reproduce in the laboratory. Ideal continuation of the emergence profile, without any ledge at the junction of the veneer and enamel, can only be achieved through such a chamfer preparation. Additionally, it allows the veneers to be more easily inserted at try-in, and during the final placement it provides a higher fracture resistance and avoidance of fractures at the edges of the PLV.[5]

A natural transparent precise PLV restoration is dependent on the fabrication and delivery of this technique. Laboratory technicians maximize the use of their contemporary ceramic systems with the space and margins provided by the finishing process. The health of the tissues and the restoration itself may be in danger if this process decreases the potential by infringing on the biological width. If the restoration is to be harmoniously integrated with the natural teeth, this process is vital to the definitive restoration that it necessitates.[67]

Proximal Preparation

Prior to the facial preparation and the creation of the gingival margin, the preparation for the proximal surfaces must be thoroughly planned. The aim must be to place the margins beyond the visible area and to preserve the contact area.

Esthetics should be carefully considered when placing the proximal "stop-line", providing that the teeth are free of proximal restorations. It is very important to go beyond the visible area that can be viewed from the front or side, especially when tooth color is very different from that of the laminate veneers.

Destroying the contact areas in order to create the margins is unnecessary, but, in some cases, the preparation margin may be extended further in a lingual direction. The margin can be drawn back even more in the lingual direction if the natural contact area has already been lost due to a diastema, restoring a broken angle or to encompass a proximal composite.[5]

An ordinary viewer's attention usually focuses on the facial surface of the teeth, whereas the dentist tends to look straight at the central incisors while interpreting the depth and the proximal surfaces. The ordinary viewer actually sees the incisors without any contour.[38] In order to be accurate and to achieve the best results esthetically and functionally, the dentist should always be able to visualize the three-dimensional form. For PLVs' biologic integration into the area, one should have a better understanding of the placement and design of the proximal finishing line.

It is useful to study this surface in two regions: the gingivoproximal area, which extends gingivally from the interdental contact area, and the direct proximal contact area, which is located in the incisal 2/3rd of the proximal surface.[48]

Gingivoproximal Preparation

A segregate esthetic factor that assures harmony in the dental composition is the interdental embrasure that is formed from the cervical point of contact, the interdental papilla and the proximal wall of the adjacent teeth.[7] Interproximal embrasures and interdental papilla are vital areas in our PLV procedures and a solid understanding of their anatomy is essential.

The tooth form, related bone and gingival relation differ as we proceed from the centrals towards the molars. At the gingival margin, when viewing the gingiva from a mesial aspect, there is a concavity almost following the form of the enamel (Fig 7-27) that is deeper towards the incisal at the anterior and gets shallower towards the posterior of the mouth. This actually refers to the shape ofthecementoenamel junction that is related to the form of the tooth and the intercrestal bone morphology. The deeper the cementoenamel junction atthe proximal, the higherthe intercrestal bone should be so that the papilla will fill that space.

WWW.HIGHDENT.IR
همیار دندانسازان و دندانپزشکان

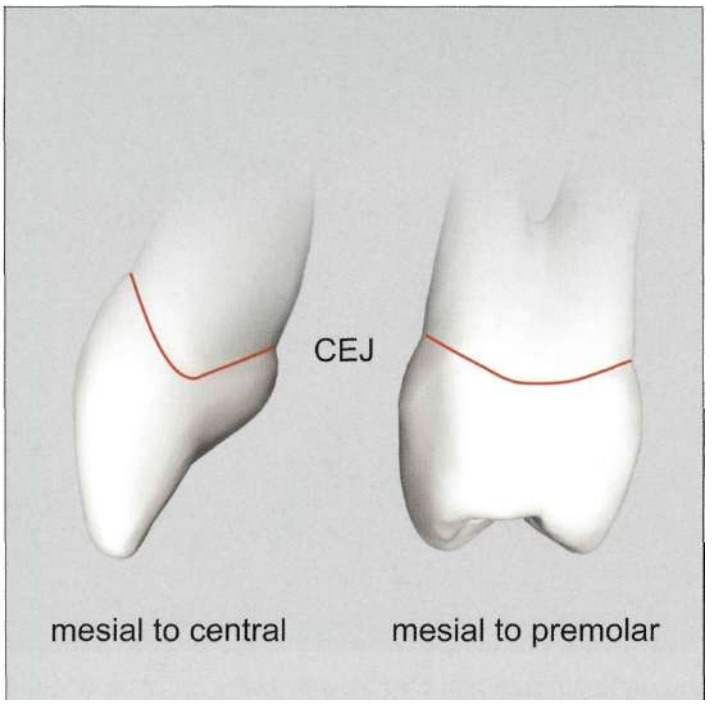

Fig 7-27 The cementoenamel junction gets flatter as one proceeds to posterior.

Papilla

It is acknowledged that bone is the foundation of the soft tissues. The shape of the bone is followed by the interdental gingiva and according to its location the shape varies. Although flatter in the posterior region, the anterior area appears convex, with a knife-shaped edge that is reduced in width. The general rule is that the interproximal tissues become higher and more convex as the roots get closer. If the roots are further apart, the interdental tissues will be that much flatter. In the anterior, where the roots are the closest, the length of the papilla is a solid 5.0 mm when measured from the crest of the interproximal bone (see Chapter 6).

This increases the importance of the delicacy of the gingivoproximal preparation, especially in the anterior region and more specifically between the centrals, laterals and canines. The dentist should be aware of the fact that he/she will be dealing with a delicate papilla, prone to change if not handled properly. When preparing the area for PLVs, the prognosis of the papilla, periodontal tissues and its marginal integrity is directly proportional to careful planning and delicate preparation, with atrue understanding of all the anatomical structures involved.

Esthetics and Hygiene

It has been mentioned that a decrease in esthetics increases the accessibility for oral hygiene. Oral hygiene is more easily accomplished when there are open embrasures in the posterior area that leave room for the gingiva.[152,158] However, phonetic and esthetic requirements are not compatible with the maintenance of wide-open embrasures in the anterior area. Furthermore, there is a very delicate balance in the anterior region. Hygiene should be properly maintained with naturally placed crisp triangular-shaped papilla without the formation of any black holes.

When normal tooth structure exists with an adequate interproximal root proximity and a sound periodontal state, the maintenance of the embrasure space depends directly on the delicacy of preparation and margin placement, the proper fit of the restoration, the emergence profile, the interproximal tooth design and the location and the width of the gingivoproximal area. Consequently, regardless of the patient's oral hygiene, maintenance of a healthy embrasure is entirely dependent on the ability and capability of the restorative dentist.

Maintenance of Gingival Embrasure

In PLV preparation, maintenance of the gingival embrasure space is only possible when sufficient tooth preparation has been done. Sometimes overpreparation of the tooth may be indicated to avoid any overcontouring. Tooth preparation and tissue protection are as important as the systematic, accurate approach they necessitate. Esthetics and oral hygiene will dictate the amount of enlargement of the embrasure space involved in the preparation and final stages of the restorations.[7]

Although it is generally underestimated, the interproximal tooth structure which is gingival to the contact area of the adjacent tooth, is very important. This area is not visible from a direct

WWW.HIGHDENT.IR
همیار دندانسازان و دندانپزشکان

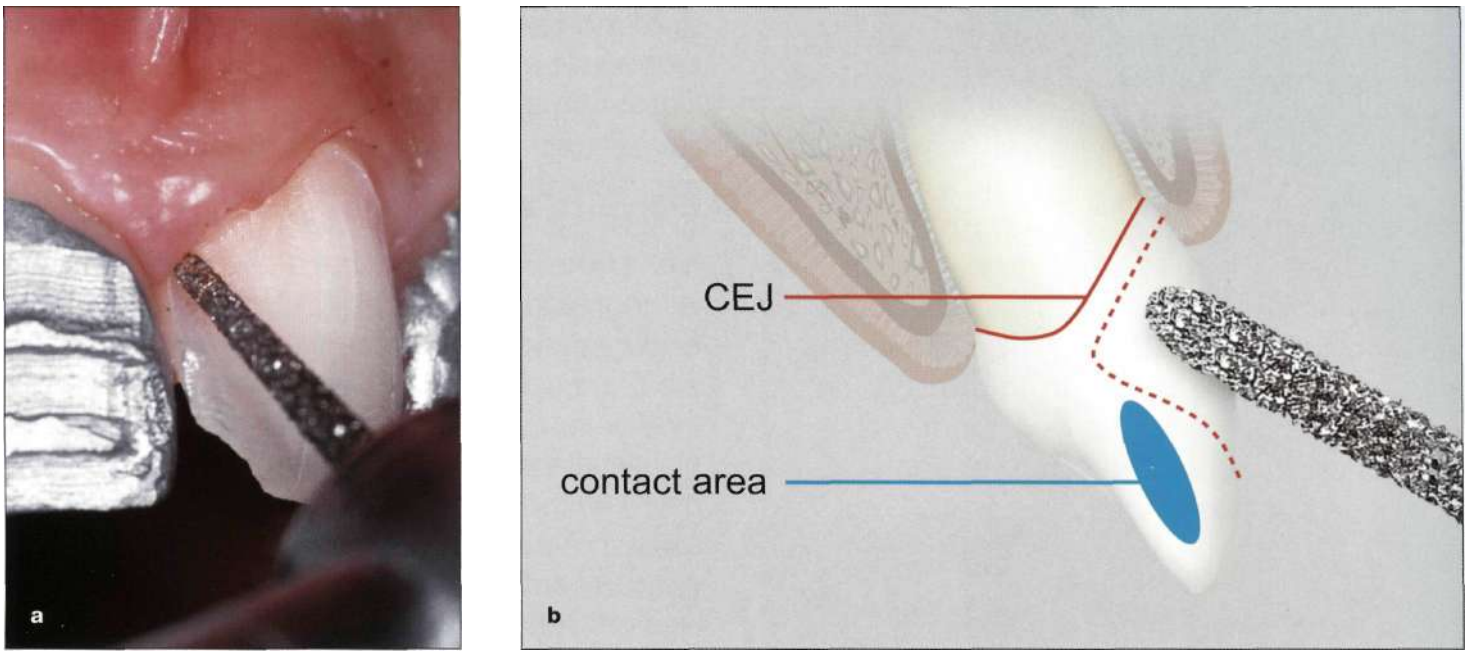

Fig 7-28a, b (a) Care must be taken to avoid penetration into the dentogingival complex as well as the cementoenamel junction, (b) The bur is held almost 60 degrees to the axial inclination and gently pushed towards the palate to create a dogleg gingivoproximal extension.

frontal view and so it is left either underprepared or totally unprepared. However, when observed from obliquely, it is visible and it is therefore essential that this area be meticulously prepared.[159] This is even more critical in cases where the unprepared tooth structure and the final restoration differ significantly in terms of color.[160]

Technique

Gingivoproximal margin preparation should begin after the gingival preparation is finished. The round-end tapered fissure diamond (Fig 7-28) (model 5850.314.016 Brasseler, Germany) is held at an almost 60-degree angle, and follows the gingival prep towards the palatinal, from both the mesial and then the distal. When viewed from the mesiofacial aspect, a concavity is created with the ultra-fine tip of the bur in the shape of an interproximal elbow or dogleg form.[15] Depending on the facial convexity of the incisors, their depth can alter. It is usually kept supragingival.

Depth of Chamfer

As mentioned previously, the type of margin is preferably a chamfer form in this particular area. The question can be, "what kind of chamfer should be used?" or, in other words, "what should be the depth of that margin?" (Fig 7-29). Adjusting the color of PLV with the help of different-colored composite luting resins, at the time of bonding, is not suggested. However, in real life, these problems may occur owing to a lack of proper color communication with the lab. If the chamfer is kept too deep then the replacing porcelain will be thicker than it should be and the thicker porcelain will allow less of a color change. Therefore, color-adjustment options will be limited when a heavy chamfer is used. Any attempt to alter the color with the help of a composite luting agent will be unsuccessful.

Although thin chamfer may produce improved color control, it is impractical because its thin porcelain margin makes it vulnerable in the dental laboratory or even in the dentist's chair. Light chamfer without internal line angles allows preservation of the enamel and thereby prevents marginal microleakage.[70] However, the author prefers medium chamfer that allows color adjust-

WWW.HIGHDENT.IR
همیار دندانسازان و دندانپزشکان

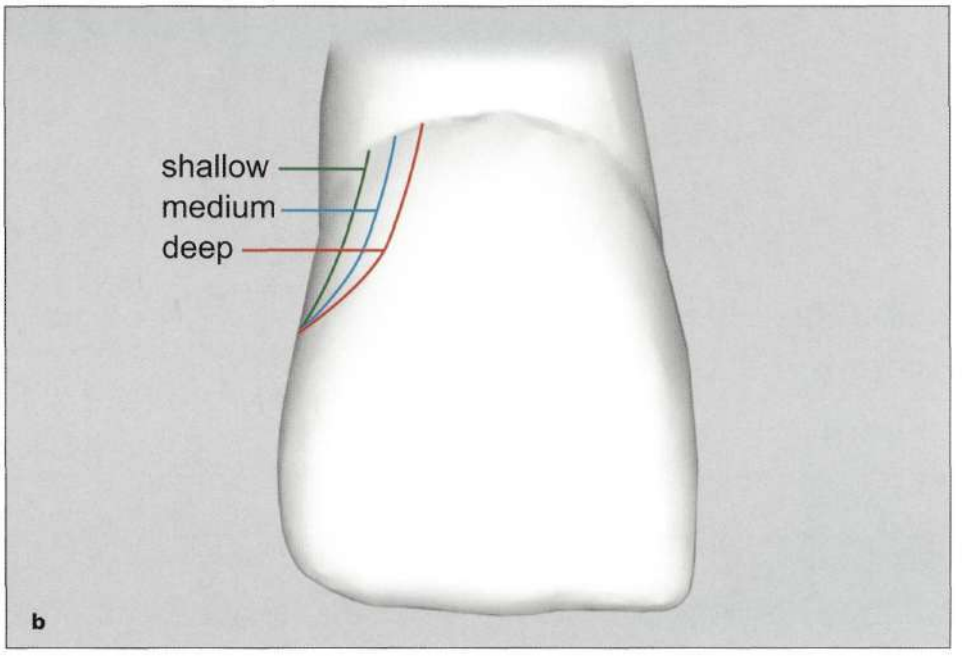

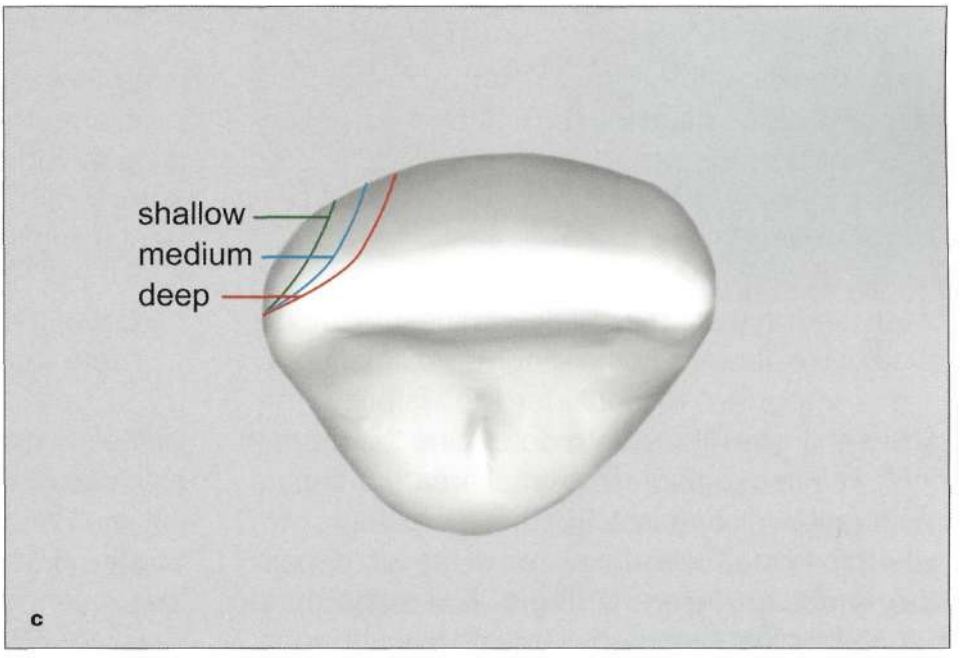

Fig 7-29a-c The horizontal depth of the gingivoproximal preparation will affect the thickness of the porcelain in that area.

ments and yet has a porcelain margin of adequate thickness. Especially in cases of dark discoloration and thick gingiva, the margins will still be placed on enamel.[7] They can be placed subgingival^ and more palatally in cases that display severe discoloration or diastema closure, or in cases where it is followed by a reduction of the gingival level, or when periodontal disease or perio surgery has taken place.

The visual area of the labial embrasure influences the viewer's perspective. Shadows that are cast from the surrounding structures are particularly influential as well as other important factors such as the lips, the adjacent teeth's contours, gingival architecture, contour, shade and the position of the teeth.[161]

Depth of Extension

When significant shading differences exist between the tooth and the restoration, and distinct color alteration is necessary, in order to prevent the margin from being visible, the proximal margin must be extended palatally and halfway

WWW.HIGHDENT.IR
همیار دندانسازان و دندانپزشکان

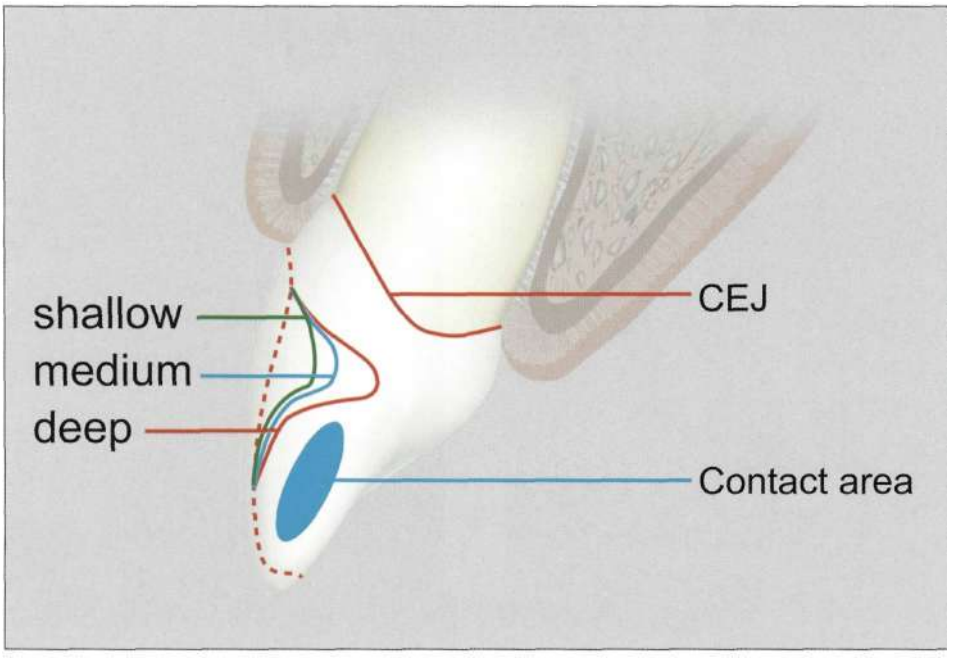

Fig 7-30 The palatinal extension of the gingivoproximal area is related to the required color change and the visibility of the area. Usually distinct color changes necessitate deeper preparations towards the palate. If the color does not need to be changed, the preparation margin can be kept shallow.

intothefaciolingual dimension of the contact area. It is possibleto extend the proximal margin palatally in the gingivoproximal area until the unprepared tooth surface is no longer visible (Fig 7-30). In this way the esthetics is not harmed by unsightly tooth angles that remain visible. The color and visibility of the teeth in that area will determine the amount of palatal extension in the gingivoproximal area.

It is important to consider the visibility from different angles in order to determine the margin finish line in the gingivoproximal area.[48] After the preparation is completed, esthetic problems may arise if the gingivoproximal area of the tooth structure is visible from any angle. For those teeth with slight coloralterationoreventhose with none, the preparation must be extended palatally to include 0.2 mm of the gingivoproximal area.[48] Throughout the placement of the proximal margin, the dentist must continually check for any portion of darkened tooth structure beyond the preparation that will still be visible afterthe restoration is complete, by frequently checking from different viewpoints.[48]

Gingival Response

In addition to its importance in improving the final esthetic result, this space is very important because it is a favorite location for microorganisms that cause caries and inflammatory tissue problems. Interdental tissue can be vulnerable, as is observed in daily practice. It is known that the spread of this inflammatory process to the interdental papilla through to the transeptal fibers can follow the blood vessels directly into the dental canals of the osseous septum (see Chapter 6).[7]

There are various studies being conducted to try to determine gingival reactions to bonded porcelain margins. Porcelain is the material closest to natural tooth enamel and it is also the most esthetic and biocompatible material available. Studies have shown that it also retains less plaque than even natural enamel,[29,117,162,163] and that the plaque is more easily removed with less bacterial plaque vitality.[164] Glazed porcelain's low surface roughness is the vital key to this phenomenon.[165] Short-term[166-167] and medium-term[113,168,169] clinical studies suggest a positive reaction of the marginal gingival tissues to porcelain veneers as well as a decrease in plaque accumulation on the restorations.[170] It has been found that, although both are porcelain materials, PLV shows much less gingival inflammation when compared to PFM restorations. While plaque index and plaque bacteria vitality decrease considerably, the volume of gingival crevicular fluid increases.[167171] However, one should never forget that all these studies are produced under

WWW.HIGHDENT.IR
همیار دندانسازان و دندانپزشکان

Fig 7-31 After the gingivoproximal preparation is finished, the fissure diamond bur is uprighted vertically to make the interproximal preparation

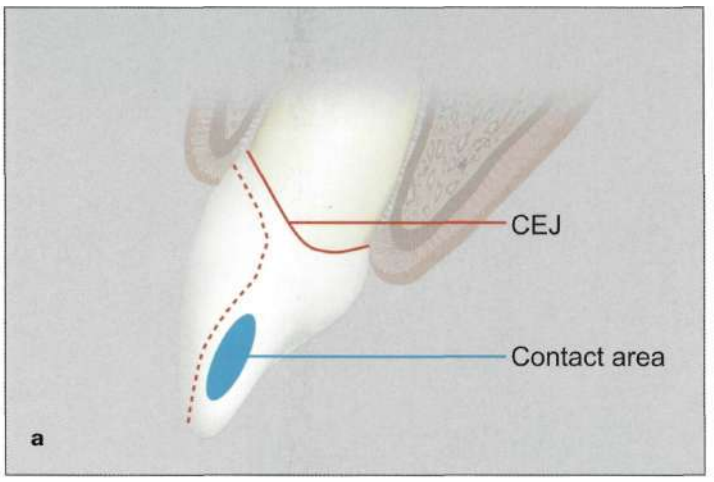

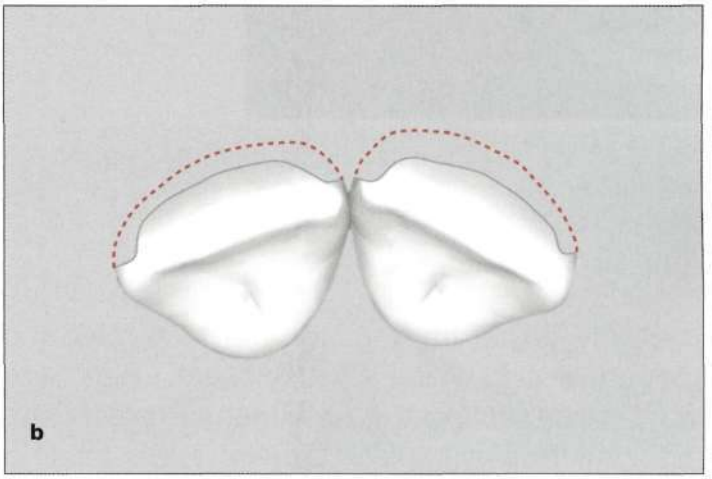

Fig 7-32a, b Preferably, the interproximal margin should stay short of the contact area.

circumstances where there were relatively excellent marginal fits. If the principles explained above for the gingivoproximal area preparation are not applied properly, and if marginal gaps or uncontrolled overbulked porcelain margins are created, these statements will have no value. Periodontal problems can be expected in the case of improperly placed gingivoproximal margins.

Interproximal Preparation

Technique

Proximal reduction is simply an extension of facial reduction. Using the same round-end tapered fissure diamond bur, the gingivoproximal reduction is continued by uprighting the angle of the bur vertically (Fig 7-31) into the proximal area, making sure to maintain adequate reduction, especially at the line angle. To correct an uneven finish line, ensure that the diamond is parallel with the long axis of the tooth and parallel to the mid-line. Even though this seems to be a minor detail, it is a vitally important one. It not only helps the dental technician to have enough space for PLV build-up, but guides him/her to the correct esthetic incisal line by mounting the cast into the articulator (see Chapter 13), perpendicularto the correctly placed mid-line.

Under normal circumstances this preparation should stop just short of breaking the contact (Fig 7-32).[172] The proximal margin on teeth that are free from color alteration or with "discreet discoloration" should be hidden by the preparation made far enough into the contact area so that the proximal wall will end 0.25 mm facial to the actual contact area.[48]

In some instances, the dentist may only be preparing a single tooth or two teeth and must

WWW.HIGHDENT.IR
همیار دندانسازان و دندانپزشکان

Fig 7-33 Oscillating instruments work the best on the interproximal areas that are being prepared next to an intact adjacent tooth.

therefore pay extra attention not to scratch the tooth next to it, which will stay intact. One of the ways of protecting the proximal surface of the adjacent tooth is to place a metal matrix band in between. However, sometimes, poor placement of this metal band may injure the papilla.

Oscillating Instruments

Rotary instrumentation with fine-grit diamond points most often leads to injury of the adjacent tooth if proper precautions are not taken.[173] In addition, they may produce uneven margins with enamel fractures next to areas that are untouched.[174,175] The safest way of preparing the interproximal area as an alternative preparation method, is to make use of oscillating instruments. They have differently shaped tips and the beauty of the system is that one side has a noncutting flat surface that cannot cut or scratch the adjacent tooth while the other side perfectly prepares the interproximal area.[173-174] Oscillating working tips that are diamond-coated on one side, allow very precise apposition of the instrument to the surface to be worked on, while the uncoated side can be exposed to the adjacent tooth surface without damaging it. It is reported that an overall 79% to 100% of the perfect margins without enamel defects are obtained with working tips of 40-micrometer grits.[176] During the interproximal preparation of the anterior teeth, the "half-torpedo" working end can be used to avoid scratching the adjacent tooth that will not be prepared (Fig 7-33).

Interproximal Contact Area

It is no longer necessary to split the models with the modern techniques available. There are numerous factors that determine how deep to prepare the contact area. Whenever possible, it is best to preserve the contact area, as it is an anatomical feature that is difficult to reproduce. When the actual treatment is in progress and the teeth are not periodontally stable, then it becomes a challenge to keep them intact and to prevent displacement of the teeth between the preparation and placement sessions. Consequently, the try-in procedures are simplified and save clinical adjustments of the contact areas where the fine ceramics are intricately placed. Bonding and finishing procedures are thereby simplified and easier toothbrushing and dental flossing is made possible.[15]

Breaking the Contact

Certain clinical circumstances, such as closing a diastema or changing the shape or position of a group of teeth, may require some specific preparation of the interproximal area[5] in order to allow the technician greater freedom in alteration of the form or position.[177] Another reason for designing specific preparations at the contact area is the existence of caries, defects or preexisting composite fillings. In such cases it is important that after thorough elimination of carious dentin, the weakened residual enamel thickness be evaluated. A compromise must be made between saving the tooth structure and mechanical principles that govern support and stability for an indirect restoration.[27]

At times it may be necessary to full-slice through the contactto open a diastema (Fig 7-34). The esthetic and functional demands of the

WWW.HIGHDENT.IR
همیار دندانسازان و دندانپزشکان

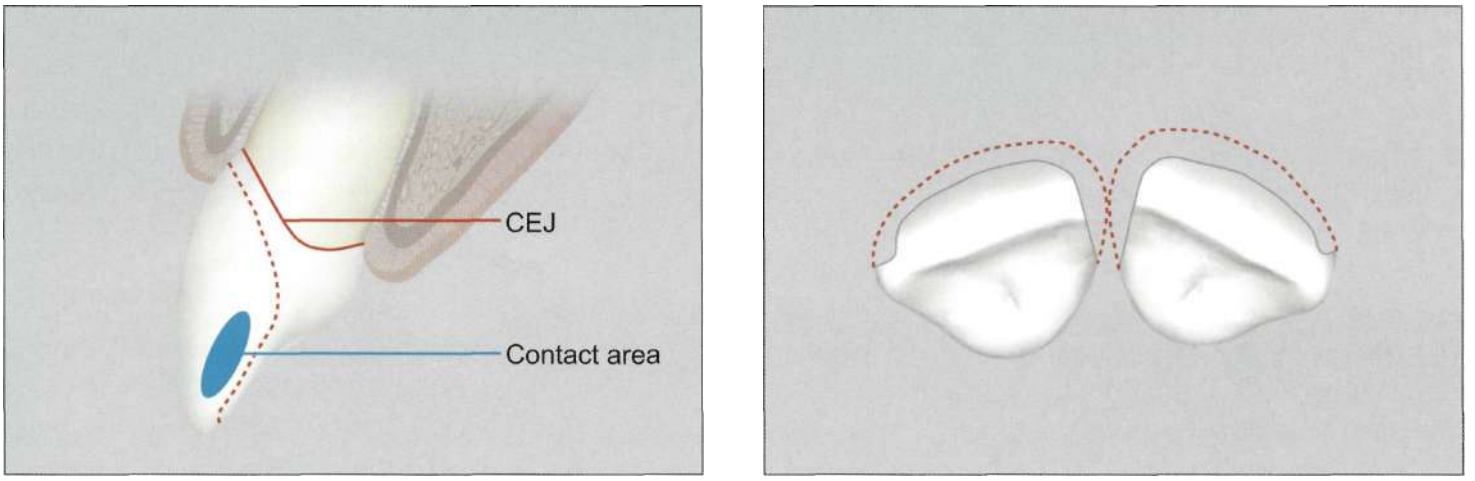

Fig 7-34 Sometimes the contact area can be sliced from the facial to palatinal, to open a diastema and to give freedom to the dental technician.

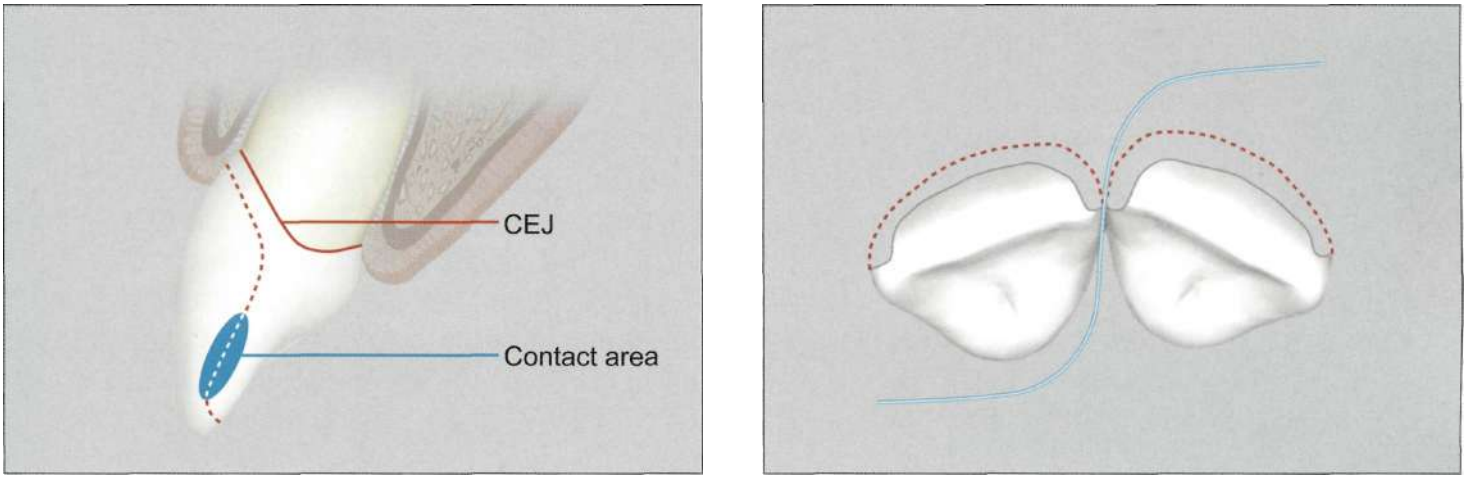

Fig 7-35 However, if the interproximal margin has to be placed on the interproximal contact area, a diamond strip should be used to create a definite, crisp marginal edge.

specific tooth involved will determine the design of the preparation of the proximal walls.[15] However, if for some reason the preparation must finish on the proximal contact area,[178] instead of extending the preparation more palatinally, which will cause the loss of intact enamel in the contact area, it can be stripped to achieve a clear interproximal margin (Fig 7-35).

Eliminating Existing Restorations

At the restoration dentin interface, the connection of resin cement to dentin may be the weakest link. Bonding PLVs onto a composite filling considerably increases the risk of failure.[179] When the preparation margin is located within an existing filling, numerous failures have been reported.[180,181] The author believes in the incorporation of all the existing composite fillings and caries cavities into the PLV preparation (Fig 7-36). However, in some instances, the removal of the composite, which may be too palatally located, can prevent the insertion of the PLV unless sound tooth structure is removed. These are the conditions where the dentist must use his/her common sense for removing the composite to the extent that the intact tooth structure allows, leaving the rest of the composite as it is and finishing the PLV line over the remaining composite filling. In doing so, the old composite filling should be thoroughly

WWW.HIGHDENT.IR
همیار دندانسازان و دندانپزشکان

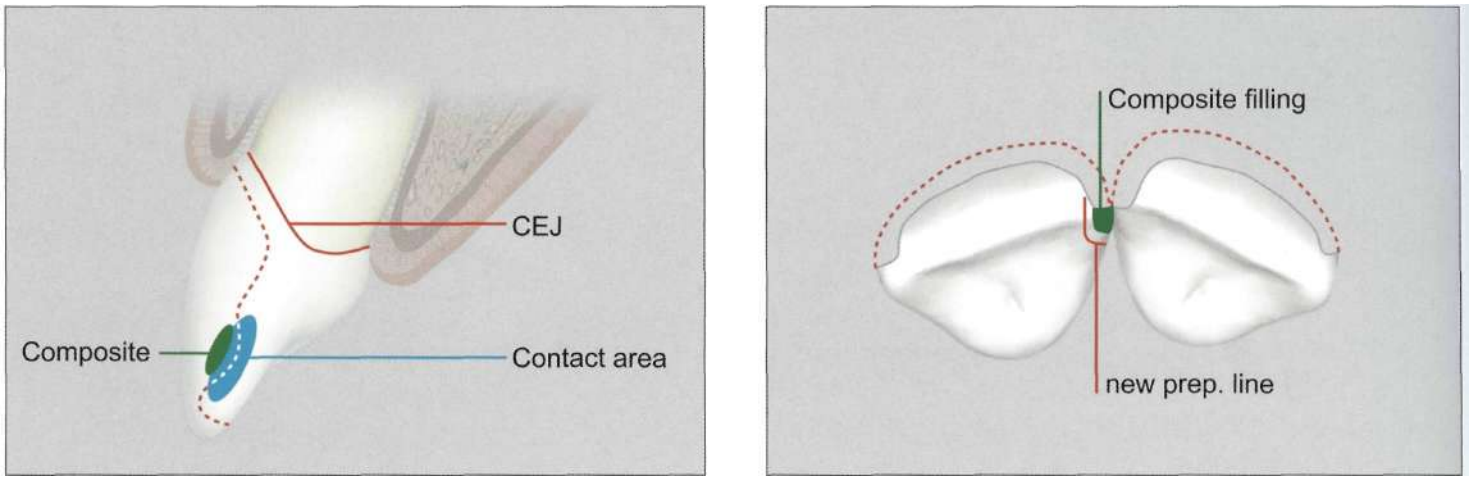

Fig 7-36 The already existing cavities or composite fillings are usually removed and incorporated into the PLV preparation.

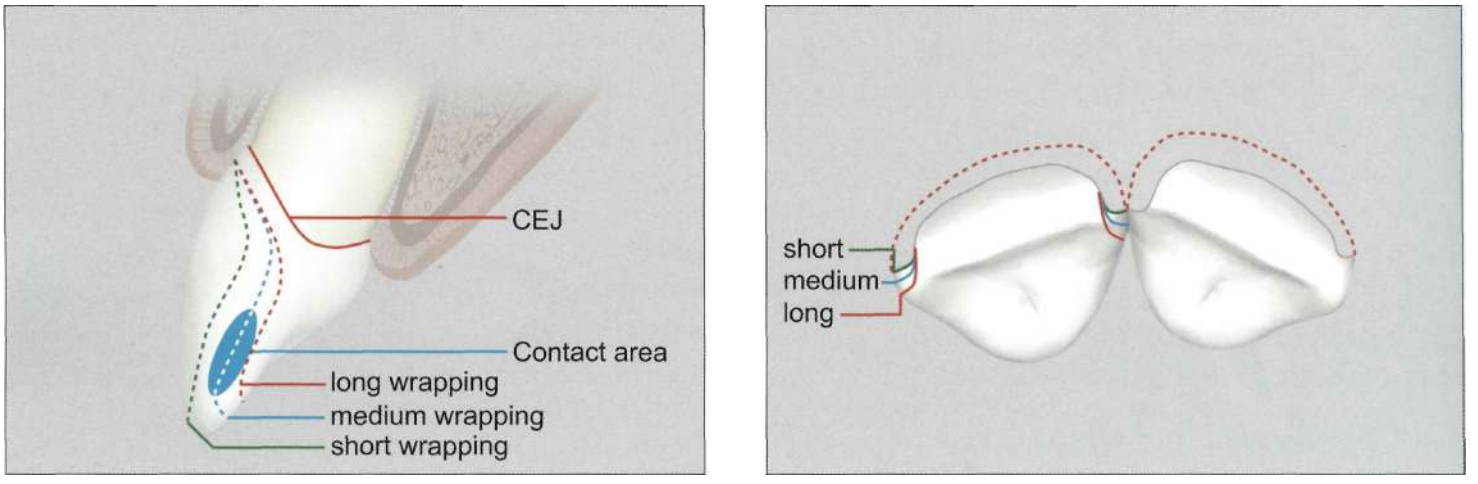

Fig 7-37 The depth of the interproximal preparation can be classified as short, medium and long wrapping *[Magne).*

checked, and if any secondary caries or defects are suspected, or if marginal discrepancies are seen, they should be redone before the actual PLV preparation takes place. Nevertheless, in order to initiate the shaping of the preparation, a definitive chamferfinish line must be clearly established.[67]

Palatinal Extensions

If needed, the preparation may go as deep as possible towards the palatinal, in order to break the interdental contacts. There are three different degrees of interdental preparation depending on how deep the preparation line extends towards the palatinal (Fig 7-37). *Magne* and *Douglas*[4]^ classified the penetration depths of the interproximal preparation as "short wrapping" (the veneer to extend only to the facial margin of the tooth), "medium wrapping" (the veneer that extends into the bulk of the mesial or distal marginal ridge by penetrating 50% of the interdental area) and "long wrapping" (the veneer which entails covering the entire interdental area).

In their studies, it appeared that "medium wrapping" was the preferred choice. In conclusion, this interesting study found that during an extension of the veneer to the interdental area the use of wraparound laminates can provide improved stress distribution within the restoration when it is

WWW.HIGHDENT.IR
همیار دندانسازان و دندانپزشکان

subjected to incisal loading[41] The safety and innocuousness of interdental wrapping can be supported by other investigators who indicatethat the most important mechanical events in incisors appear within the buccolingual plane.[182]

Thermal Changes

Extreme thermal changes, curing contraction of the luting composite and mechanical loading are all sources of stress. Cracks can be initiated in porcelain veneers through the harmful stress that thermal changes can create.[6,74] Short-wrap veneer, when compared to the other veneers, showed higher riskfailureduetothermal changes and shrinkage. This veneer technique is facial to the contact and conservative in nature.

On the other hand, owing to difficulties in their fabrication and application arising from the problems in handling both the extension of ceramic and the delicate margin definition and insertion axis, long-wrap veneers are also quite impracticable. Consequently, it should only be used in cases where major changes are necessary, as in the closure of diastemas (or interdental triangles), which necessitate adequate margins (marked chamfer) and ceramic thickness. Partial wrap (medium wrap) is asuitablecompromise between clinical practicality and stress distribution when restoring class III composites.[183] The margin can be hidden, and extending the preparations into the contact area can provide a better, more stable seat for cementation.[177]

Incisal Preparation

There are two basic techniques for the placement of the incisal finish line. The first terminates the prepared facial surface at the incisal edge. There is no incisal reduction or prep of the lingual surface and it can be in the form of a window or intra-enamel preparation or the feathered incisal preparation. In the second technique, the incisal edge is slightly reduced and the porcelain overlaps the incisal edge, terminating on the lingual surface. In a retrospective clinical evaluation the two techniques were used equally and both provided clinically acceptable results.[184]

After two and a half years of clinical functioning, porcelain veneers have shown no relation between survival rates due to incisal preparation design (no incisal overlap versus incisal overlap).[185] Many different techniques—such as the overlapped incisal edge tooth preparation, the feathered incisal edge tooth preparation, the incisal 0.5-1 mm bevel preparation and the intraenamel or "window" tooth preparation in which 1.0mm of incisal edge is preserved—are presently being used.[142,186]

Incisal Overlap

Whether or notthe incisal edge of thetooth should be included in the preparation of the PLV is still a matter of debate. Several authors favor the overlapped incisal preparation.60,61,81 Some authors believe[182,187188] that full coverage is vitally important in order to improve the mechanical resistance of the veneer, despite the fact that to accomplish this, 0.5-2 mm of intact incisal edge may have to be removed thereby placing the vulnerable cavosurface margin in an area of opposing tooth contact. It is better to incorporate an incisal overlap in the preparation as the porcelain is stronger and produces a positive seat during the cementation process. The proper seating of the veneer is made possible by the vertical stop that the slight incisal overlap provides.[54]

The esthetic characteristics of the porcelain veneer are more easily handled and controlled by the dental technician with this type of incisal preparation. To improve the translucency of the veneer, a 1 mm incisal reduction is suggested with rounded line angles (Fig 7-38),[60] even though a two-dimensional photo-elastic stress analysis confirms that such preparations increase the resilience to incisal fractures.[182] This preparation reduces stress concentration within the veneer by distributing the occlusal load over a widersurface.

It is also emphasized that only when occlusal or esthetic requirements necessitate should the incisal edge be incorporated into the preparati$_{oni}$62,184,189,190

WWW.HIGHDENT.IR
همیار دندانسازان و دندانپزشکان

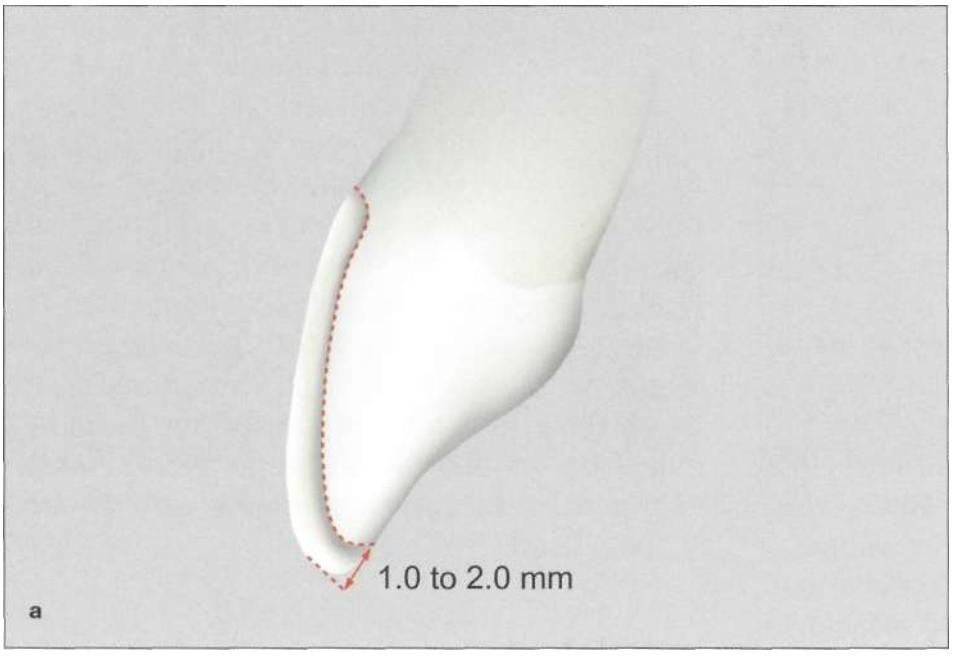

Fig 7-38a, b (a) It is better if the incisal overlap is incorporated into the preparation. It will not only improve the esthetic effects such as translucencies, but also improve the mechanical resistance of the veneer, (b) The bur is held 90 degrees to the incisal edge and the necessary preparation is done.

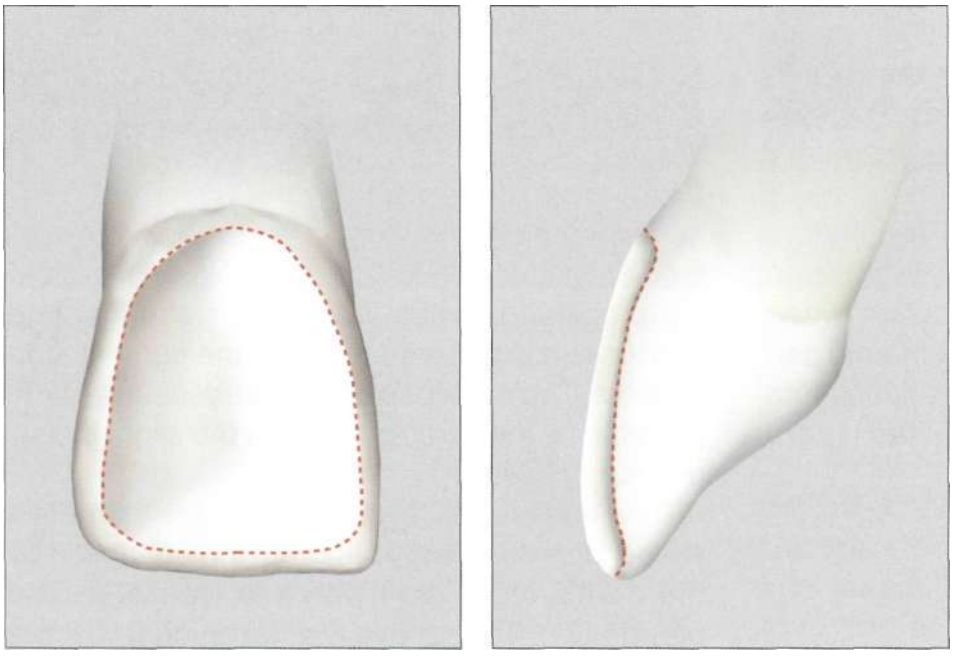

Fig 7-39 Window preparation is the most conservative preparation design.

Window Design

On the contrary, an in-vitro increased risk of cohesive fracture due to the maximum stress placed on the veneer caused by an overlap in the PLV design was demonstrated.[186,191] This study showed that a window design prepared entirely into the enamel was resistant to axial stress. It concluded that the most conservative type of veneer or window preparation was the treatment of choice when strength was the first priority (Fig 7-39).

WWW.HIGHDENT.IR
همیار دندانسازان و دندانپزشکان

Points of Reference

The incisal edge of the preparation assumes a precise position whether the aim of the treatment is occlusal, esthetic or for retention requirements. The dentist needs a reference forthe incisal edge and must therefore use the adjacent teeth. This is especially convenient if that tooth is not part of the preparation itself, as the tooth about to be prepared can simply be aligned to the adjacent tooth of reference. If the reference tooth is to be part of the preparation, it should be prepared last so that it can serve as a reference point during the earlier stages of treatment.[3] In cases where no reference point exists, the best way of estimating where the finished PLV margin will be is to use the APT in conjunction with the silicon index.

Cohesive Fractures

Due to the greater stress at the incisal edge of the veneer, clinical cohesive ceramic fractures can occur.[192] Chamfer was believed to be required to strengthen the veneers.[58] Photo-elastic studies have shown that by providing a wide vertical stop to resist loads by covering the incisal edge lessens the stress concentration in them.[182] The author prefers reducing the incisal edgefrom 1.5-2.0 mm shorter than the final incisal edge of the PLV. This will not only enhance the mechanical resistance but the esthetics as well. The gradation effect of translucency can only be obtained if the incisal edge is prepared like this and the esthetic outcome through the coverage of the incisal edge is usually the most desirable method for patients.

Butt Joint

Instead of a chamfer margin that may weaken the final restoration (see lingual preparation), a flat shoulder should be used at the incisal edge.[108] However, if the tooth exhibits the length desired forthe PLV, a 1.0-1.5 mm reduction will be required which will establish a thickness of 2.0 mm in the buccal palatinal direction of the incisal margin. Sub- sequently, a flat incisal surface that emerges perpendicular to the angle of the final emergence profile in the PLV restoration should create the delicate incisal edge configuration where the incisal edge grooves are connected.[91] This will place the margin finish line 2.00-2.5 mm down from the incisal on the lingual, away from the incisal edge while creating a pleasing length, form and incisal characterization, allowing the ceramist much more flexibility.

Another important aspect to be aware of is the condition of the palatal surface of the tooth that is about to be prepared. The finish line on the lingual aspect of the restoration should not end on a wear facet and it is also preferable not to place the finish line on the central contact points. In the caseofawornincisala2.0-2.5mmreductionfrom the desired length of the finished veneer is required.[10] If the already existing tooth length is 1.5 mm shorter than the expected final outcome, than in order to achieve a 2.0 mm incisal reduction, only 0.5 mm of preparation will be sufficient. In any of these cases, the fracture potential of the final restoration can be avoided by the rounding of the incisal line angles that reduce the internal stress.[182]

Adhesive Bonding

In adhesive dentistry, all ceramic restorations are dependent on the macro mechanical retention from geometric form that is not very important when it comes to bonded ceramics. The butt joint preparation is simpler and consumes less time than the tooth preparation with palatal chamfer, and the master cast can be used for a precise palatal finish line. However, the only true mechanical indications of a butt joint are the cases where the proximal preps are extended all the way to the palatinal. In these long-wrapping PLV preparations the path of insertion is from the facial. Therefore, only butt joint incisal preparations will allow such a buccal-palatal path of insertion.

Porcelain Support

As it is preformed on the facial surface with adequate support for ceramic veneers, it makes it easier for the dental technician to fabricate the PLV. Buccal, palatal and incisal cervical directions should be followed in the insertion of these

WWW.HIGHDENT.IR
همیار دندانسازان و دندانپزشکان

Fig 7-40 The sharp horizontal edge that is created at the incisal 1/3rd is rounded with a fine fissure diamond bur.

Fig 7-41 The incisal depth should be double checked to finalize the preparation.

restorations. This design makes it easier to control the risk of fracture for these thin unsupported palatal ledges. A favorable ceramic/luting composite ratio at the palatal surface, which reduces the risk of post-insertion palatal cracks caused by shrinkage of the composite cement during polymerization and by natural thermal changes in the oral environment, is also provided by a joint butt design. A peripheral enamel layer around all margins is preserved by this butt joint incisal configuration. Micro leakage at the palatal tooth reduction interface can be eliminated by the presence of enamel, which is also critical to counteract shear stress.[58,108]

Overcontouring

The pronounced facial curvature of the natural maxillary incisor with its various reflection patterns has a pleasing affect. In poorly countered crowns, convexity in a direct profile is commonly evident.[98] The greatest difficulty in correcting the incisal profile is to preserve a comfortable and unrestricted anterior guidance while pushing the incisal edge to its original esthetic appearance.

In order to detect the gross overcontouring of the incisal third, measurements of the buccolingual thickness of PLV with the tooth crown at the junction of the middle and incisal third should be made. The natural central incisor's thickness ranges from 2.5 mm for a rather thin tooth to 3.3 mm for a thick tooth. When the PLVs thickness together with thetooth exceeds 3.5 mm, over contouring may be suspected.[3]

Rounding the edges

To reduce the number of weak points in the ceramic, all angles and corners should be rounded off. In order not to detract from the bonding, red-banded diamond instruments are used for finishing (Fig 7-40).[5] The use of abrasive paper discs can help to achieve a finish line on the vertical flare without rest to polish.[193] Rounding this horizontal sharp line angle not only improves the strength of the PLV, but also reduces the internal restoration stresses, and the esthetic acceptance of it. If this line remainssharp, it will stand out when the PLV is inserted unless the technician built overbulked porcelain on the incisal 1/3rd, which will not appear esthetic as well.

WWW.HIGHDENT.IR
همیار دندانسازان و دندانپزشکان

Ideal Preparation

If the ideal preparation was accomplished when viewed from the labial, the incisal outline of the proposed final restoration should be identical to the incisal outline of the tooth except for the 1-2 mm incisal reduction. In this way, an even thickness of porcelain is achievable.[96]

Even if all the details explained above are considered to be ideal, in certain cases the size of a defect will dictate the extent of preparation. Numerous factors must also be taken into consideration as far as the anatomic and internal topographic structure of the anterior teeth. Relative size and extent of the pulp as compared to the position of the anteriorteeth in the dental arch are also important while making extensive preparations.[194]

Tensile Forces

If the ceramic is exposed to tensile loads it is more susceptible to failure.[192] In a study of veneers with 2 mm of unsupported incisal ceramic and butt joint configuration, it was found that the incidence of fractured ceramic veneers was reduced to zero.[108] This will also optimize the luting composite to veneer thickness ratio of which the ideal ceramic thickness should be three times greater than the luting composite.[6]

The strongest veneers that remain intact for the longest period of time are those with 2.0 mm of unsupported incisal ceramic and butt joint ceramic veneers. Placing a palatinal chamfer does not increase the PLV strength. Ease of tooth preparation, PLVfabrication, insertion and bonding are some of the clinical advantages of a butt joint preparation.[108] The final depth should be double checked with the help of a silicone index (Fig 7-41).

Lingual Preparation

The special nature of the palatinal side of the anteriorteeth plays an extremely important role. It is of prime importance to be careful during the preparation stage thus increasing the longevity of the porcelain veneer or the bonded ceramic restoration.

Although applied in practice by the majority of clinicians some researchers have only minimally explored the systematic creation of an incisal overlap scientifically in relation to the biomechanical integration of the veneers.[4] Excessive care should be applied to the concavities as well as the convexities since the impact of the stresses will change depending on the nature of the surface. Palatal concavity that provides the incisor with its sharp incisal edge and cutting ability, proved to be an area of stress concentration. This shortcoming can be compensated for by the cingulum and the marginal ridges that feature thick enamel (Fig 7-42).[6] In their research, *Magne* et al showed that when a horizontal force is applied to the tip of the anterior teeth from the palatinal aspect, the recorded strains were always higher in the concavity when compared with the cingulum whereas at the same time the entire facial surface was submitted to compressive forces. It became more dramatic in the absence of facial enamel and tensile stresses measured in the palatal concavity when they reached the elevated and potentially harmful level of 272 Mpa.[4] However, smooth and convex surfaces with local enamel bulk such as the cingulum, the marginal ridges, and the facial cervical third of the anatomic crown showed the lowest stress level. The modified natural tooth that exhibited thick palatal enamel and a mostly convex palatal surface gave the optimal configuration with regard to the stress pattern.[4]

Margin Placement

If a lingual preparation is to be done, this raises the important issue of where to finish the palatinal margins and how deep to prepare the lingual surface of the maxillary anteriors. Logically, the preparation should preferably not finish at the

WWW.HIGHDENT.IR
همیار دندانسازان و دندانپزشکان

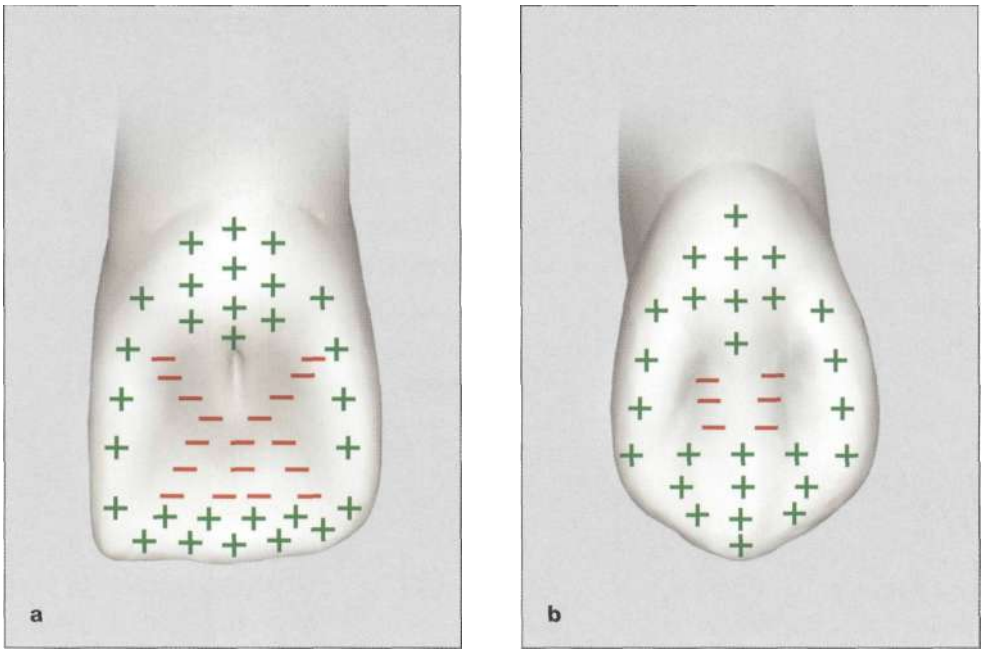

Fig 7-42a, b (a) Palatinal view of central areas. Red (-) markings correspond to concavities that are proven to be the area of stress concentration, (b) The palatinal view of a canine. Due to the thick nature of the enamel and the longer cingulum, there is less stress concentration on the canine. Green (+) markings correspond to the conuexities where the palatinal preparation margin can be located.

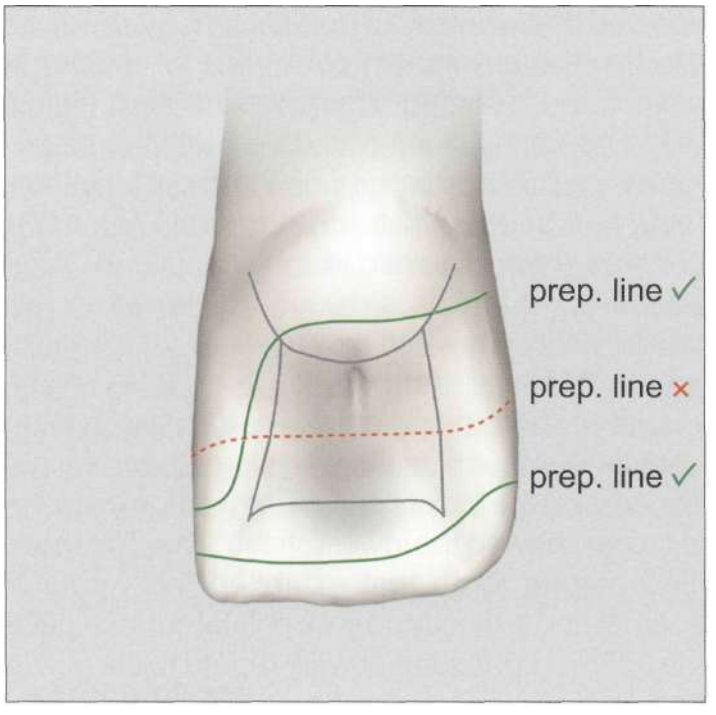

Fig 7-43 The preparation lines on the lingual should not be located on the palatinal concavity.

concavity but rather it should be placed either above the concavity or below on the smooth convex area of the cingulum so that they will be subject to low tensile forces (Fig 7-43). The vertical palatinal marginal ridges also support the strength of the anteriors and therefore care should be given to keep them intact.

Incisal Notch

Placement of the lingual finish line for a laminate veneer will also depend on the thickness of the tooth and the patient's occlusion. If the preparation needs to be extended palatinaly over the incisal edge, the remaining part towards the incisal should have enough thickness to prevent breakage. When the teeth are thinner than 1.5 mm labiolingually at the incisal 1/3rd; reducing the labial and the lingual incisally by 0.5 mm, the preparation leaves us with a thin sliver tooth structure that cannot be rounded off and is susceptible to breaking. These areas are sometimes kept so thin that they even break at the laboratory while the technician tries to take the refractory dies out of the impression, or at the time of the provisional's removal. This situation may cause another

WWW.HIGHDENT.IR
همیار دندانسازان و دندانپزشکان

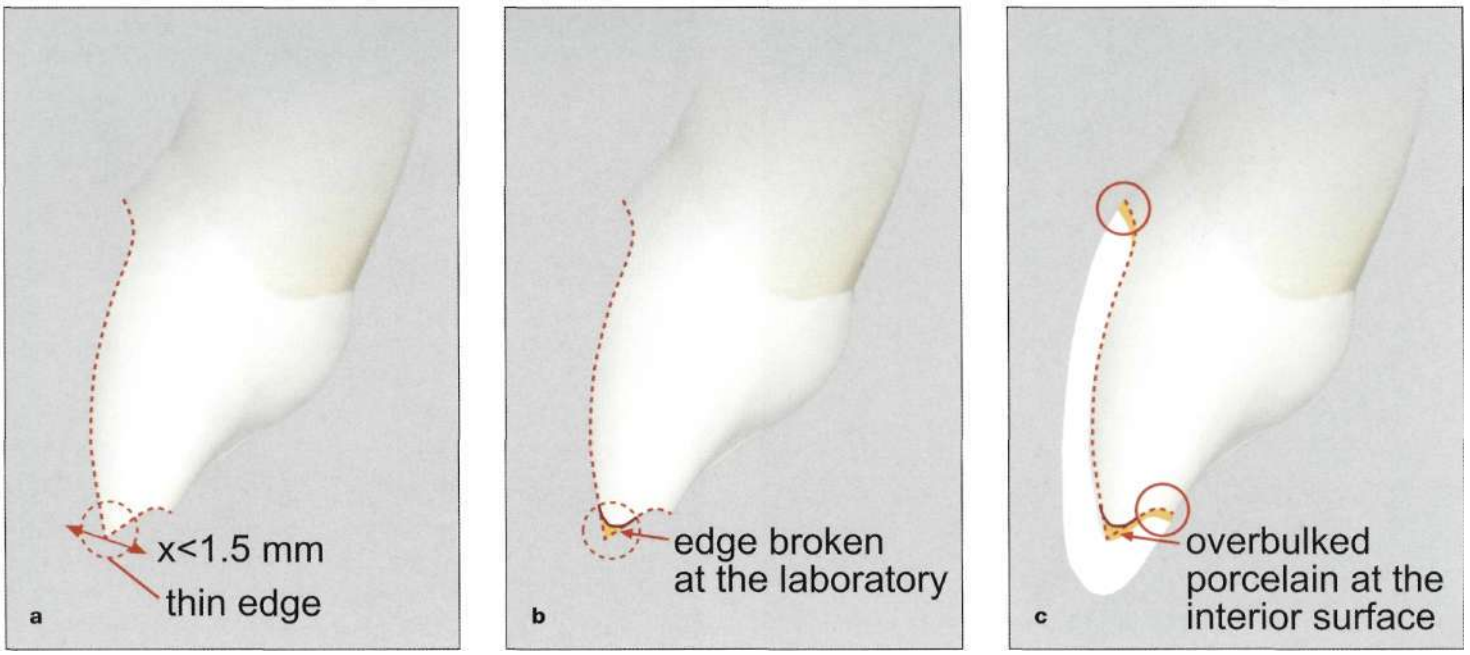

Fig 7-44a-c (a) If a very thin notch is left at the incisal edge (b) it may break at the lab. (c) The extra porcelain that is fired into that area will prohibit the natural seating of the final PLV.

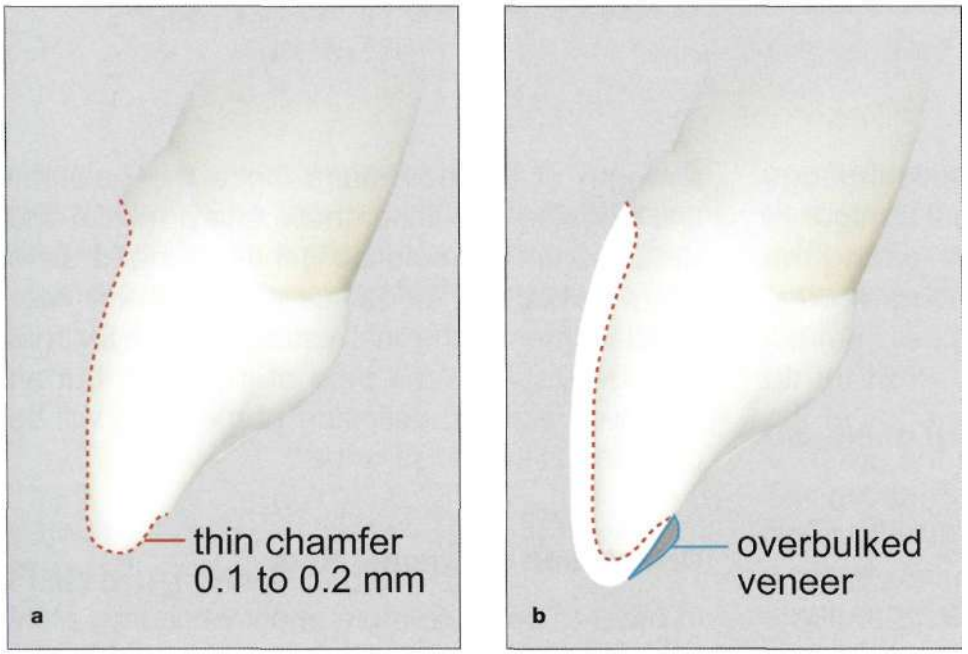

Fig 7-45a, b If the palatinal chamfer is prepared thinner than it should be, the result is an overbulked lingual extension. It will cause discomfort to the patient's tongue, and, if it is to be thinned, then the porcelain in this area will be prone to microcracks.

serious problem if the tip of the stone model coincides with the very thin portion and is broken during the lab procedures, resulting in a PLV with extra porcelain in that area. When that PLV is seated on the tooth, care must be taken to avoid mistakes due to the overbulked interior surface of the incisal edge which will make it impossible to seat the veneer properly and result in an inaccurate fit at the cervical margin (Fig 7-44).

Overbulked Porcelain

Accordingly, in a situation where a lingual chamfer is to be prepared without preplanning, the tendency is to under reduce the depth of the lingual chamfer to 0.1-0.2 mm instead of the minimum of 0.5 mm. As the porcelain can not be made as thin as 0.1 or 0.2 mm, the end result will be a joint with a ledge of porcelain beyond the normal contour of the tooth (Fig 7-45). After being bonded, the first feedback will be in the form of a complaint from the patient due to the uncomfortable feeling

WWW.HIGHDENT.IR
همیار دندانسازان و دندانپزشکان



Fig 7-46 The round-ended fissure diamond bur should be held parallel to the long axis of the tooth while preparing the lingual side.

Fig 7-47a, b (a) Sometimes a sharp notch is created on the proximal, (b) This should be rounded to facilitate impression-making, try-in, bonding, etc.

of their tongue. To comfort the patient this ledge must be thinned down to the lingual contour of the tooth with a rotary instrument, leaving the remaining 0.1 or 0.2 mm thick porcelain prone to cracks in the near future. Having this in mind, it is always better to keep the distance from the tip of the prepared incisal edge to the edge of the palatinal wrap around shorter than the distance between the prepared tip of the tooth to the expected incisal edge of the PLV.

A palatally extended preparation should make use of a round-end tapered diamond that will make it easier to create the lingual finish line. Its end should form a slight chamfer, 0.5 mm deep with the instrument held parallel to the lingual surface (Fig 7-46). The finish line should preferably be about one-fourth the way down the lingual surface about 1.0mm from the centric contacts while connecting two proximal finish lines. Care should be given not to locate this finishing line on the palatal concavity. The creation of the lingual finish line often produces a notch (Fig 7-47) at the mesial and distal incisal corners.[172] These corners are often not taken into consideration and left sharp. This kind of a preparation will cause a lot of problems during impression making, try-in and bonding, therefore weakening the bonding strength of the porcelain. Once the palatinal finishing line is placed, these sharp mesial and distal corners should be gently rounded as in interproximal and incisal overlap which will ease the placement of the final restoration. They will not only be stable at the time of insertion, but an improved esthetic definition of the PLVs will be obtained in the incisal zone.

Orientation of Enamel Rods

In order to produce more effective enamel etching the prismatic and interprismatic mineral crystals must be removed.[195] Therefore it is advisable to expose the cross sections of the palatal enamel rods versus their sides while developing a margin, which will enhance the etchant contact with the interprismatic enamel.[108] As they are placed at an angle of 30° to the tooth axis, the orientation of enamel prisms appears to be critical in the incisopalatinal area.[183] A minichamfer can be prepared to overcome this situation since it will section enamel rods at an angle close to 90° and yet still be distant from the concavity. The orientation of the enamel rods change towards greater angulations of approximately 50°, if the palatinal preparation line is to be placed away from the

WWW.HIGHDENT.IR
همیار دندانسازان و دندانپزشکان

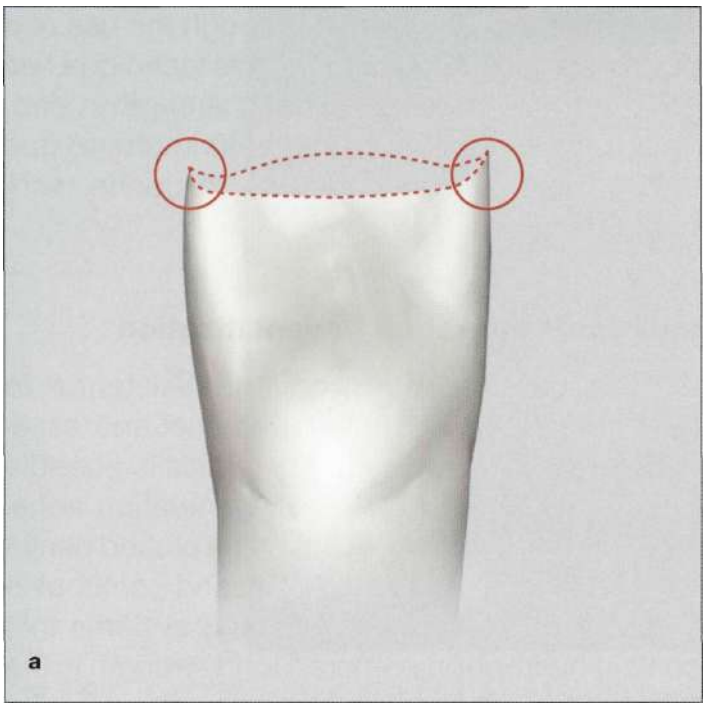

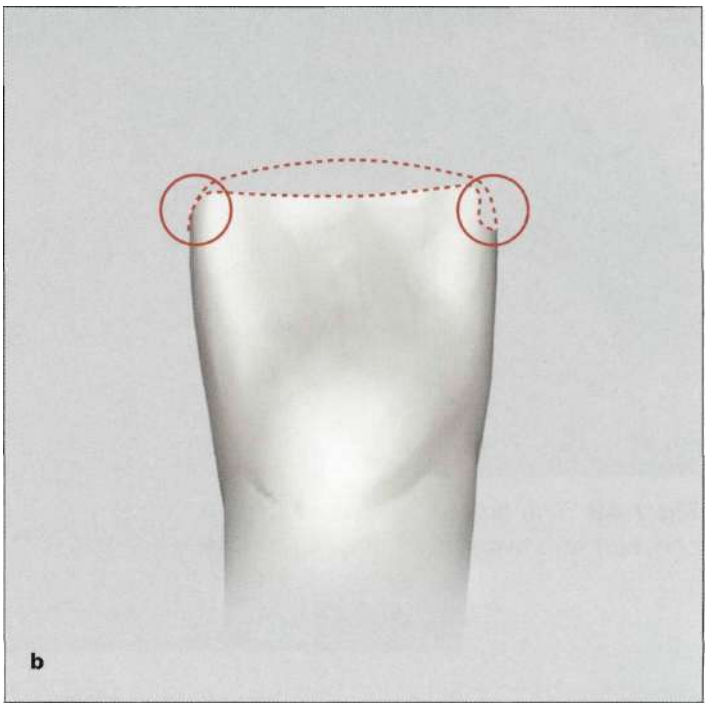

incisal, more towards the middle 1/3rd. A butt margin should be the choice of preparation as such a position is sufficient for strong bonding, when preparing a fractured tooth to receive a PLV (seeFig4-13).[183]

Finishing the Preparation

After all the steps that have been explained for tooth preparation have been finished, a thorough examination of the prepared teeth is necessary. Especially at the junction of the incisal angle and the lingual reduction, the dentist must be careful to remove any sharp angles that might serve as a focal point for stress concentration. At the point where the facial, proximal and lingual planes of reduction meet, other sharp features that may have formed in the final preparation should be avoided and there should not be any sharp angles.[172]

The dentist must always strive for the most natural pleasing effect and in order to do so, they must check to see if the incisal embrasures are opened, rounded and of varying depths. The dentist must also check if the embrassures are sufficiently deepened and if the gingival embrasures are carved to create a healthy gingival papilla.[31]

Checking the Prepared Surfaces

The author recommends that all the margins be checked with magnification systems in order to avoid any scratches on the under prepared areas. Another great way to visualize these defects is to take a picture of the prepped teeth. Looking through the lens with 1:1 magnification; will most often surprise the dentist as many minor defects that would otherwise never be seen with naked eye, will be observed.

If everything is under control up until that point, then one final check should be made with the previously prepared silicone index from both the occlusal view and from the lateral view. This will ensure that the necessary reduction of the facial surface is done properly (Fig 7-48). Once the final adjustments are made, dentin sealing, impression and the provisionals can now be prepared. If there is no dentin exposed, than the next step is to make the shade selection. However, if there is any dentin

WWW.HIGHDENT.IR
همیار دندانسازان و دندانپزشکان

Fig 7-48 The final facial and interproximal reduction is checked with two silicone indexes at different levels.

exposure, the author believes in sealing the freshly cut dentin, just after preparation and before impression making.

Pre-sealing the Exposed Dentin

An important aspect is the sealing of the dentin tubules of the freshly prepared dentin. To prevent post-operative sensitivity and bacterial invasion of the exposed dentin, protection for the period between preparation and final cementation is important.[196,197] It is only possible to partially seal the surface with the temporary materials (resin composite or acrylic resin) that are presently available.[198,199] It is recommended that right after the completion of the tooth preparation, etching and a dentin bonding agent should be applied immediately, before the final impression is taken as it's potential for superior bonding is best when applied to the freshly prepared dentin.[200,201]

After the dentin is etched for 15 seconds, a primer, which is a hydrophilic reactive monomer in an organic solvent, can be more effectively used to prime the exposed dentin.[202-203] If the exposed dentin surface area is adequately retreated at the appointment priorto the actual cementation, then the pri mers or desensitizers that are used after the preparation do not seem to deteriorate the adhesion to the dentin.[204]

The frequent problem of bacterial leakage and dentin sensitivity experienced during the temporary phase, can be avoided through the use of a bonding agent. Application of this technique has been found to improve the bond strength in vitro. The recovery of crown stiffness has improved due to the more efficient bonding to dentin techniques.[205]

Indirect Preparation Desensitization

On the dentin, waterproofing, resistance to debonding similar to natural enamel and especially in the field of bonded ceramics is possible to obtain with fourth and fifth generation adhesives.[206] The superficial layer of the etched dentin can be penetrated intertubularly and peritubularly by the modern dentin bonding systems that contain hydrophilic primers. Bond strength in the dental operatory has increased due to a better understanding of the results of etching dentin and the more recent developments in this field. A hybrid layer is important to the micromechanical retention of resin composite to dentin.[207] The dentin's surface must first be demineralized followed by penetration of adhesive hydrophilic monomers.[206]

Exposed Dentin

When the preparation is finished, the surface of the tooth is carefully examined in order to find the exposed dentin areas. Under normal circumstances they will usually appear on the gingival 1/3rd of the tooth. However in cases of facially protruded tooth, the dentin can even be exposed on the incisal area, due to the aggressive nature of the teeth preparation. It is better to immediately etch and seal these areas.

Etching

Many details have to be considered to be able to accurately assess the effect of acid etching on dentin[208] such as, the time of etching, the remaining dentinal thickness and the ability of the restorative materials to seal the etched dentin, along with the type of acid as well as its pKa an pH and the applied concentration (Fig 7-49).

WWW.HIGHDENT.IR
همیار دندانسازان و دندانپزشکان

Fig 7-49 The freshly exposed dentin is acid etched with 37% phosphoric acid.

Fig 7-50 Primer is applied only on the blot-dried dentin. Precaution should be taken to limit the application on the dentin avoiding too much spreading over the enamel.

In clinical practice, the most important factor with today's etching agents is that the dentist should not exceed the recommended time of application that is usually less than 15 seconds. Longer applications will cause the collagen to collapse and negatively affect the bonding.

If etching is properly done, the smear layer should be removed to permit bonding to the dentin matrix. It will also cause the demineralization of the matrix dentin, uncovering both the intertubular and peritubular dentin, to permit resin infiltration. It will also clean the dentinal surface free of any biofilms.[208]

Primer and Adhesive Application

Then the etch surface is washed thoroughly, but not dried. It should only be blot-dried with the help of a cotton pellet. The dentin itself has a wet character, which does not necessarily interfere with proper bonding. In fact, fourth generation bonding systems can be used effectively on wet dentin[150,209] and it is inadvisable to demineralize dentin on purpose as it may draw more fluid up from the pulp to the surface, resulting in collapse and shrinkage of the dentinal surface. This phenomena forms the basis for the so called wet-bonding technique advocated by *Kanca.*[210,211] There should be no misunderstanding about the term wetness, as it is not a technique that allows saliva, blood or gingival fluid to contaminate the etched dentin as they contain proteins that coat the surface of the conditioned dentin and the spaces between the collagen fibers through which the resin must diffuse. While the dentin is reasonably wet, the primer should be applied (Fig 7-50) and left there for a minimum of 30 seconds. It can then be gently warm-air dried from a distance, so that it's carrier weather alcohol, water or acetone will evaporate. At the end of this stage a shiny, stable surface should be visible.

Now the adhesive can be applied over the primer. The resin tags can penetrate into the intertubular dentin to a depth of 6 microns.[212] This micromechanical bond can be better achieved if the bonding agent is cured directly after application.[213] It should be kept in mind that an oxygen inhibited layer of 40 microns will exist over the polymerized adhesive. Therefore high filler content adhesives should be used and covered with a barrier (DeoX-Ultradent) to prevent this layer forming during light curing. It is better if a highly filled adhesive like Optibond FL. (Kerr) is used. It

WWW.HIGHDENT.IR
همیار دندانسازان و دندانپزشکان

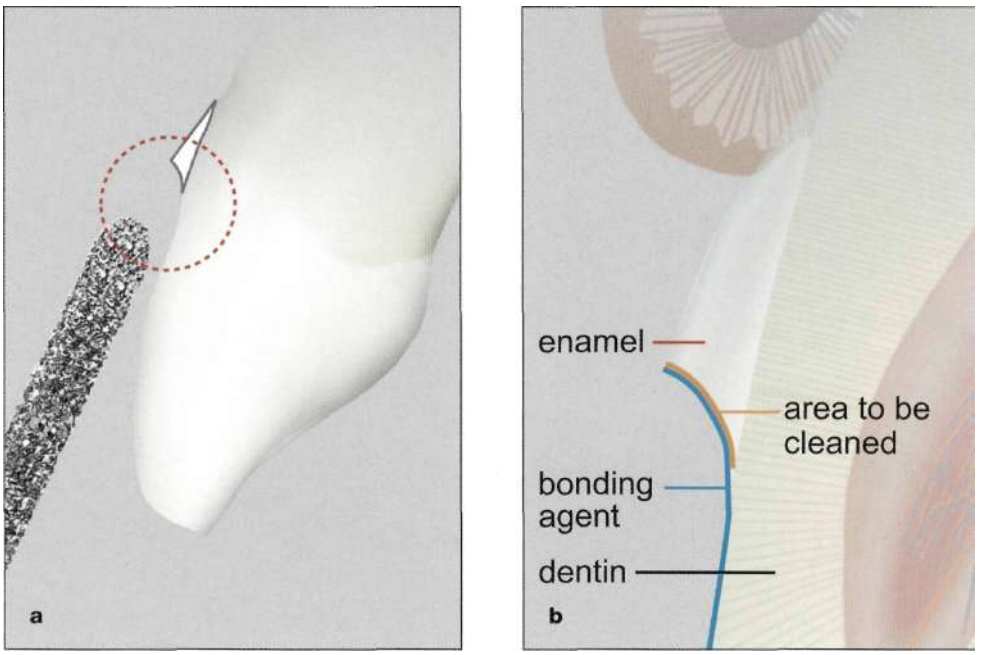

Fig 7-51 a, b The adhesive that may have covered the cervical margin should be cleaned with a round-ended, tapered, extra-fine diamond fissure bur.

has a thickness of 80 microns. This automatically resists the 40-micron oxygen inhibited layer and if sealed with oxygen barrier (Deox Ultradent) a true thickness of 80 microns can be obtained.

Cervical Marginal Check

A popular way to avoid the use of local anesthesia at the seating appointment and to keep people comfortable during the provisionalization period, is to seal the freshly cut dentin of the preparations at the preparation appointment prior to taking the impression, as explained above. However, the existence of this 80-micron thick adhesive may stay on the gingival-enamel margin. Therefore, the last thing to do in the tooth preparation is to delicately go over the gingival margin with an ultra fine, round-ended fissure bur, to create a crisp clear fine enamel margin for the impression (Fig 7-51).

Due to the use of a highly filled adhesive, a similar stress breaker effect may occur. This filler content of low viscosity acts as an intermediate resin and has exhibited improved strength.[214,215] and less leakage[216] than other systems.

As the dentin is hybridized at the preparation appointment, it is fully protected. To prevent the provisional from totally bonding to, or from damaging the area, the hybridized area must be scrubbed with Vaseline after taking the impression and prior to provisional cementation.[24]

Shade Selection

The dentist and the laboratory technician often have difficulties in communicating when it comes to the sensitive area of shade selection for the anterior indirect restorations. There has been a conscious effort to develop techniques to overcome this problem, including pictures, drawing diagrams, and the use of multiple porcelain shade guides (see Chapter 5). However, there are many dentists who have not kept up with the progress that has been made in this field and are only familiar with their already less contemporary techniques from dental school, and so remain unaware of the superior methods that are available to them and their patients.

WWW.HIGHDENT.IR
همیار دندانسازان و دندانپزشکان

Color Selection

To achieve a natural appearance details such as color, surface texture, luster, translucency and contour all play important roles in the creation of the ceramic restoration.[217] The range of tooth color that exists in nature is far more than the colors available on shade guides.[218"221] In comparison to the thin veneer ceramic restorations, the guides are made of a much thicker porcelain and therefore the porcelain used for the shade tab is quite different from the porcelain used for fabricating the restorations.[222] A commercial color guide with 16 selections cannot possibly cover the variations exhibited in natural teeth.[172] Subsequently, any treatment must begin with first determining the color. The entire process of reconstruction and its success is directly related to the correct shade selection. Therefore, the technician must have all the related details to be able to make the precise and necessary adjustments. The enamel and body shades are selected in the same way. To do this effectively, an experienced dentist and technician must evaluate a thorough understanding of the various shade combination possibilities. In order to select the base color, custom shade tabs and resin shade rings can be utilized.[8]

Color Vision Deficiency

Color vision deficiency may exist in the form of not being able to distinguish certain colors and although more common in men, it can also exist in women as well. One recent study found 9.3% of the men to be color deficient as opposed to 0.1 of the women.[223] Individuals with a red green deficiency showed lower colorvision scores inthe yellow region of the visible light spectrum.[224] This can be a serious concern for a dentist and therefore a dentist must be aware of any such condition, and if severe, they must use their assistant's or technician's trained eye to match the shades for them.[225]

Importance of Light Source

In any successful esthetic restoration the dentist must not only considerthe artistic side of the procedure but also the scientific side. Color is actually a phenomenon of light and a matter of visual perception that allows us to differentiate between similar objects. The perception of color depends on the object, the observer and the light source[226] and our perception of a particular color may change when any one of these factors is altered.

The light that falls on an object, reflecting, absorbing, transmitting and refracting part or all of the light energy will produce color. Even a single object can exhibit varying amounts of light or color variations. Scattered or reflected light from walls, furniture or other objects may influence our perception of an object.[225] Perception of color is primarily influenced by light and so environmental light is very important. Gray is an excellent color for the environment in order to accurately evaluate the shade of the restorations, as it is a combination of primary and secondary colors and does not have a contrasting complementary color.[227] An interior shade room should be a part of any good dental office or laboratory and should be painted in neutral gray and be well light with color corrected fluorescent bulbs. The patient should not be wearing lipstick and their clothes must be covered with a gray bib. Only after these conditions have been met can the shade selection process begin.

The ideal situation will exist if both the dental office and the lab have the same illumination sources as well as wall colors. This is especially important to minimize the metameric confusion (see Color Chapter).

Timing

The shade selection should be done even before the tooth preparation begins. This will avoid any value alteration during the preparation period (i.e. dehydration). In order to attempt to match the shade, the dentist must first be certain that the patient's teeth are perfectly clean and unstained. Accordingly, just before the shade is to be

WWW.HIGHDENT.IR
همیار دندانسازان و دندانپزشکان

Fig 7-52 Stump shade is very important since the technician prepares a very thin layer of porcelain according to the color of the prepared teeth.

matched, that area ofthe mouth must have a quick rubber cup and paste prophylaxis done, followed by a thorough rinsing of the paste in that area.

In any examination the patient's teeth suffer from dehydration, therefore shade taking should be done as the first step of the process. In fact, it can take uptotwo hoursforthe dehydrated tooth's shade to return to normal if white calcification occurs due to dehydration.[228] Consequently, it is very importantto take the necessary photographs as quickly as possible, as even the simple procedure of using a cheek retractor for more than a minute is a cause for dehydration.[16]

Stump Shade

One of the most important procedures in communication with the technician is the transfer of the stump shade, which refers to all the shades of the prepared teeth after the reduction. Since the PLV is a very thin piece of ceramic, the technician should definitely know the color of the underlying structure in order to compensate for this underlying discoloration and achieve the desired shade of the final PLV (Fig 7-52).

A common mistake during this procedure, that is made by most dentists, is to dry the prepared tooth surface before taking the stump shade. However, due to the phenomenon of dehydration, the color of the remaining tooth surface will appear lighter than when they are wet. Consequently, when it comes to the try-in and bonding stage, all of a sudden the tooth and therefore the PLV will appear darker than it is expected to be. This is a point that should be seriously considered so as not to face unpleasant surprises at the final stage.

Low Value versus High Value

Even though it is not recommended; while talking about a perfect color match, if a dentist cannot decide between two colors; it is beneficial to choose the lighter shade. It is always safer to go along with the lighter shade, as it is easier to darken PLV than to lighten it. (lower the value and increase the chroma) Therefore, whenever in doubt, opting for the lighter color alternative is more logical.[96] In such cases the dentist should also remind the technician to place a double or triple spacer, in order to open some space for the bonding composite that is effective in the color change. The average spacer has a thickness of 3 to 10 microns upon single coating. A composite that is squeezed into such a thin area, during bonding, may not suffice to change the color of the final PLV result.

Character of the Tooth

There are numerous factors to consider in the complicated issue of shade matching. The three most influential factors are illuminant, observer and object. Careful recognition of these factors which include metamerism, gloss, translucency and fluorescence, will help to improve the result

WWW.HIGHDENT.IR
همیار دندانسازان و دندانپزشکان

of the match. One of the keys to good matching is to recognize the tooth's original form, whether opaque, translucent, dull, or highly reflective. No matter if the porcelain restoration is brilliantly done or if the shade has been correctly chosen, if the surrounding teeth are dull, a high, glossy glaze will be incompatible.[31]

Ocular Fatigue

It can be difficult for the observer to distinguish between colors if ocular fatigue sets in.[229] In orderto prevent retinal fatigue (retinal adaptation) concentrated short 5 second intervals will be more useful in detecting the difference in shades.[31] The perception of color is determined by cone cells on the surface of the retina that send a signal to the brain.[230] If a color is viewed for an extended period of time, these cells become fatigued andthesignalstothebrainthusdecrease in accuracy of their perception of the object being observed. Since blue fatigue accentuates yellow sensitivity, the dentist should glance at a blue object (wall, drape, card, etc.).[172]

The cone cells correct the inaccurate shade perception by recharging the sensation of orange when observing the complimentary blue shade of the bib. The aged teeth need additional consideration, as their glossy surface tends to absorb any color close to them and thus distort the perception.

Impression Making

After the tooth preparation is completely finished and the exposed dentin areas are sealed with the bonding agent, it is now time to make the final impression. Each time, and even if it is only to be a single tooth veneer preparation, the impression of the whole arch should be made with a polyvinyl siloxane impression material. This will help the technician to accurately relate the two arches to each other and have more control on occlusion. The full impression of the opposing arch should also be made. However, a precise alginate impression will suffice for that.

In order to properly handle the impression materials, one should have some knowledge of the mechanical properties of the most frequently used impression materials for PLV cases in order to make a restoration that can fit precisely, an accurate undistorted impression of the prepared tooth must be made.[172]

Impressions need careful handling until poured into the gypsum product. Impression making is an area of restorative dentistry where much abuse of materials occurs, and improper handling or untoward delays between removal from the mouth and pouring have distorted many an impression.[172]

With a successful impression the dentist and the technician should be certain of the location and configuration of the finish line. In order to do so they should make an exact duplication of the prepared tooth that includes all the preparation and enough undercut tooth surface beyond the preparation to allow for this. Preserving the health of the gingiva is the key to successful impressions. The first priority is a healthy, stable, non-traumatized gingival sulcus.[7] After this, all considerations are secondary. To accomplish proper articulation of the cast and contouring of the restoration, the adjacent teeth and tissue must be accurately reproduced. The occlusal surfaces of the other teeth in the arch and especially in the area of the finish line must be free of bubbles.[172]

It is the operator's choice to choose from any number of the fine materials available. Today's impression materials are so stable and accurate, that under normal circumstances, all dentists should be able to easily obtain an excellent impression of the teeth they plan to prepare for the PLVs.

It has even been shown in a scanning electron microscopy study[231] that, the molecular structure of the material (usually gypsum or an epoxy resin) used for the master model determines the quality of the reproduction and not the impression material.[136]

WWW.HIGHDENT.IR
همیار دندانسازان و دندانپزشکان

Hydrophilic-Hydrophobic

When choosing an impression material it is important that the dentist and their team find the characteristics that they work best with, as each impression material has different handling techniques. Impression materials can be classified as hydrophilic and hydrophobic.

Hydrophilic materials are the easiest to pour, as in irreversible hydrocolloid (alliginate), reversible hydrocolloid and polyether. Polyvinyl siloxanes and condensation reaction silicones are the most hydrophobic, as can be observed in their high contact angle. Hemorrhage and moisture in the gingival sulcus may more easily repel them. However these findings certainly do not contraindicate the use of polyvinyl siloxanes.

Viscosity

According to the type of material, the viscosities for impression materials vary. The least viscous are the light bodied polysulfide and condensation silicones.232 Viscosity will also increase as time elapses after the start of mixing.[23]4 Cast restorations need accuracy and there are several types of impression material with the necessary adequacy. Many factors may affect the choice, from simply personal preference to the ability to manipulate, to economics. However, there is no clinical evidence to show any differences between these materials as far as accuracy is concerned.[172] The most frequently used impression materials today are polyvinyl-siloxanes and polyethers.

Pol i vinyl Siloxane

The author prefers the polyvinyl siloxane and irreversible hydrocolloid, to the other available materials, for PLV cases. Polyvinyl siloxane silicone is also commonly called addition silicone. Addition silicones represent advancements in accuracy over condensation silicones. This has been achieved by a change in polymerization reactions to an addition type, and the elimination of an alcohol by-product that evaporates, causing shrinkage. These materials are available as two-paste systems in four viscosities and a range of colors, allowing the dentist to monitor the degree of mixing.235 one paste contains silicone with terminal silane hydrogen groups and inert filler. The other paste is made up of a silicone with terminal vinyl groups, chloroplatinic acid catalyst and a filler.[233]

Packing

The two pastes usually come packaged in separate tubes, or for those that are used with a dispenser gun, a twin barreled cartridge. A mixing tip with multiple varies or baffles mix the materials together. As this method eliminates the spatula and mixing pad by mixing the material, these mixing guns have become the most popular method of dispensing. There are great advantages to this system as there is no air entrapment and contamination is prevented by ensuring a constant ratio of catalyst and base.[23]6

Chemistry

Upon mixing equal quantities of the two materials, there is an addition of silane hydrogen groups across vinyl double bonds with the formation of no by-products.237 As no volatile by-products are produced in the reaction, addition silicones have a much greater dimensional stability,[233-237,238] than condensation silicones. The pastes are available in light, medium, heavy and putty viscosities. Some manufacturers include a retarder for extending the working and setting times.[235] The result is an exceptionally stable material. The working time and setting times of addition silicones are faster than polysulfides and a retarder is often supplied to extend the working time.

Storage

They have excellent elasticity and show very low dimensional shrinkage upon storage.235,239 an(j it is still accurate, even when poured 1 week after removal from the mouth.[240] Therefore, addition silicones can be safely poured up later or sent to a dental laboratory.[235] it has been demonstrated that the storage of unpoured polyvinyl siloxane and polyether impressions in the temperature

WWW.HIGHDENT.IR
همیار دندانسازان و دندانپزشکان

range of 4°C to 40°C do not affect the accuracy of the master model.[241] It is easy to imagine, however, that the temperature in a car or airplane that the impression is being transported in from the office to the technician can easily surpass this range of temperatures. Studies of the effect of storage conditions in the range of -10°C to 66°C, revealed significant distortions in the materials following an extended period of storage at 66°C.[242] Therefore, the dentists working with advanced laboratories overseas should especially consider this interesting research when sending their impressions. Special boxes that are insolated and that are not affected by temperature changes should be used to prevent temperature related distortions.

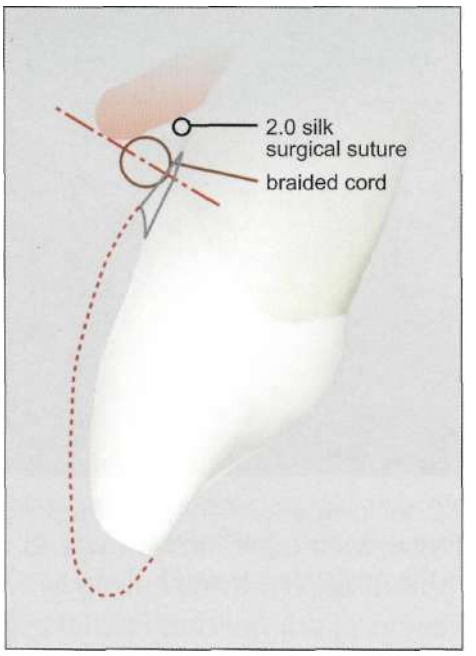

Fig 7-53 If the cervical margin is located subgingivally, a retraction cord can be use for better impressions. A 2.0 silk suture cord is placed into the sulcus in order to stop tissue fluids coming out. On top of that a braided retraction cord is placed in order to deflect the sulcus. It should not be buried into the sulcus. Its thickest part should be leveled with the sulcus tip.

Impression Making with Polyvinyl Siloxane

The casts should be made from articulated full arch impressions, as PLVs will play a role in providing protrusive or lateral guidance. High viscosity polyvinyl siloxane putty is the most rigid impression material and is therefore never used alone but with the low polyvinyl siloxane (wash), with low rigidity.[243]

Before the impression is made, the impression tray should be coated with its special adhesive at least 15 minutes in advance. Most of the time the gingival margins of the prepared teeth are left supragingival and in such cases, there will be no need to place a retraction cord into the sulcus.

Retraction Cords

However, if the margin is placed subgingivally, or the technician needs to be supplied with detailed information on the emergence profile for some reason, retraction cords can be used. If there is too much tissue fluid coming out of the sulcus, and if it is suspected that this may distort the impression, than a double cord technique can be used. A thin (2.0) silk surgical suture is gently placed intothesulcus.Careshouldbegiven when it is placed, so that the two ends do not overlap each other. In other words, they should come edge to edge. Then a braided retraction cord is placed over the silk cord. The dentist should not push the second cord excessively (Fig 7-53) and remember that, the aim of using the second cord is only for "displacement" and consequently it should be pushed only half way, to keep the largest part of its diameter level with the sulcus tip. The cord is left in the sulcus for a couple of minutes and then gently removed, keeping the first one in the sulcus, which will help to stop the tissue fluid flow. The impression should be made as soon as possible, before the deflected gingival margin collapses back to its original position. In addition, if there are big undercuts at the palatinal surface or if larger gingival embrasures exist, it may be beneficial to block these sites out before making the impression, as the material will most likely tear away from these areas and at times distort the impression.

Avoiding Cross Contamination

If a tube-dispensed material is used in a double-mix technique, the assistant and operator start

WWW.HIGHDENT.IR
همیار دندانسازان و دندانپزشکان

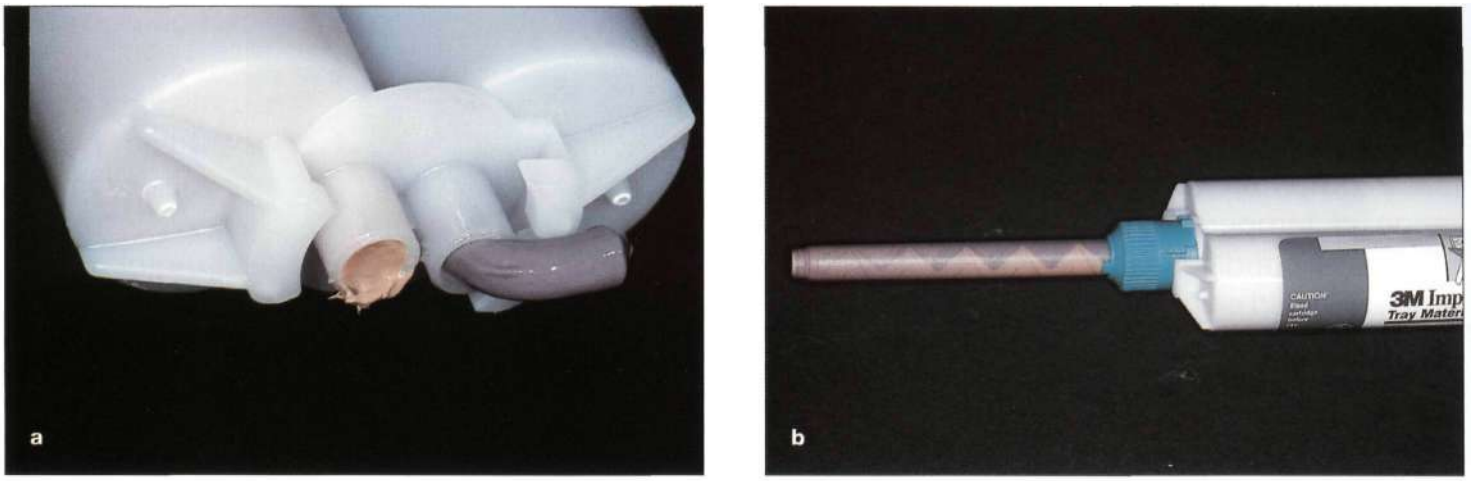

Fig 7-54a, b (a) If not properly managed, the end of the barrels can get cross-contaminated and become blocked through polymerization, (b) The best way to prevent this from happening is to keep the used mixing tip on the cartridge untill the next time it is used.

mixing material at about the same time. Removing the cap opens the cartridge and a small quantity of the material from the tip of both barrels is squeezed out. It is possible that the end of the barrels may have been cross-contaminated from the previous application, and thus, the reason for the polymerized plugs at the nozzle (Fig 7-54). If the nozzle is not carefully inspected before the impression is made, the dispenser may jam, causing an unexpected delay, as the dentist struggles to get the impression material out of the barrels by over powering the jammed dispenser. The easiest way to overcome this problem is to leave the used mixing tip on the cartridge as a cap. This way, the next time the dentist is ready to make a new impression, removing the already used mixing tip will provide a very clean area in the exit region of the barrels.

Fig 7-55 If the true gingival displacement is obtained with the retraction cords, the impression material should display all the details in the cervical area.

Technique

Once this is achieved, the dentist starts applying the light bodied material with the syringe, which should have a relatively thin mixing tip nozzle, right over the gingival margins of the preparation. However it should be kept in mind that if unmodified additional silicones are used, these hydrophobic materials cannot displace any moisture or hemorrhage that is not removed prior to placement of the impression material.[235] Therefore, even though they may be hydrophilic, the area should be kept clean of saliva, hemorrhage and sulcular fluids. The aim should be, to try to place the material in between the gingival margin and the sulcus (Fig 7-55). The most predictable way of achieving this istostartfrom one point and keep ongoing in the same direction, with a gentletouch of the nozzle over the area, without any interruption, to avoid the formation of any bubbles. At the

WWW.HIGHDENT.IR
همیار دندانسازان و دندانپزشکان

same time, the assistant loads the tray with the medium or heavy-bodied material.

Once the application of the light-bodied impression material is finished, than the medium body loaded tray is seated (over the light body material) firmly in the mouth and it is held in place for seven minutes from the start of mixing. As the material does not stain and has both pleasant scents and colors, they can be used with stock or custom trays while the patient is reclining.[235] The temperature can affect the working and setting time of the impression materials. The components of two different systems cannot be mixed together as they are not compatible and the material will not set if addition silicones are combined with condensation silicones. Caution must be exercised as temperature increases will decrease the working and setting times.[335] Once set impression must be removed as quickly and as straight as possible to prevent distortion. Addition silicones exhibit excellent recovery from deformation and they are very accurate and have high dimensional stability after setting. Then the impression is rinsed, blowed, dried, and then inspected. It should be placed in a disinfectant solution before pouring it.[235]

Disinfection of Impressions

Prior to disinfection it has been found that fewer microorganisms are retained on the surface of polyvinyl siloxane impressions than on any of the other materials.244 Polyvinyl siloxanes generally display excellent tolerance to immersion in sodium hypochlorite,245,246 giutaraldehyde[247,250] iodophor2[3]9,248,25i and phenols.[237]>[25]2,253

Reaction to Latex

No matter how precise the dentist makes the impression, in some cases, at the time of the inspection, there remains some still soft, unpolymerized spots or larger areas that can be detected. This is due to one of the points that is often ignored, the polymerization retardation of the polyvinyl siloxanes, which is due to their reaction to latex. The use of latex gloves while mixing or dispensing the putty will interfere with the setting process. The sulfur derivatives in the latex are probably responsible for the polymerization retardation.[254] If it is not automix putty and mixed putty,255 jt is more susceptible to contamination. However, only some brands of impression material, in combination with some brands of gloves, cause restarted setting.[25]6 other latex items such as a rubber dam that is used to seal the area may cause problems when they come in contact. The contact does not even have to be made directly. Even if the impression material comes in contact with a tooth that has been touched by a latex glove (not even directly the glove itself), it may cause polymerization retardation. To avoid this vinyl gloves can be used during impression making while handling the impression material.[257]

Pouring Time

Another important aspect is the pouring time of the impressions. Usually the impressions are sent to the labs and poured there. However, if the dentist wants to pour it himself or herself for some reason, he/she must be careful not to do it too quickly after making the impression, because as explained before, these materials may release hydrogen gas on setting. That will cause surface porosity and voids on the stone cast. Even though their formula has been improved by the addition of palladium to absorb the hydrogen that has minimized this problem, pouring should be delayed for a short time of 15 to 30 minutes.[225] Therefore careful study of the available materials and the ability to interpret the information is essential. The dentist must be fully aware of how long to wait before pouring the impression, since it will determine the dimensional stability (Fig 7-56).[235]

Irreversible Hydrocolloid

Irreversible hydrocolloid can be used to make the preliminary study cast impressions as well as the opposing arch impression however the most widely used impression materials in dentistry today are the alginates.[235]

Alginates are supplied as a powder containing sodium or potassium alginate (12% to 15%) and calcium sulfate dihydrate (8% to 12%) as reac-

WWW.HIGHDENT.IR
همیار دندانسازان و دندانپزشکان

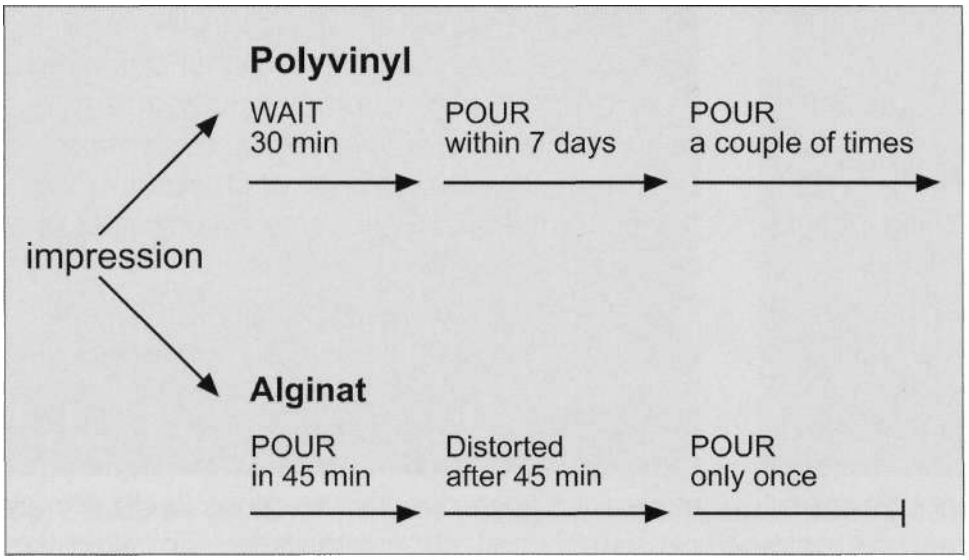

Fig 7-56 The dentist must be fully aware of how long to wait before pouring the impression

tants; sodium phosphate (2%) as a retarder; a reinforcing filler (70%),such as diatomaceous earth, to control the stiffness of the set gel; potassium sulfate or alkali zinc fluorides(10%) to provide good surfaces on gypsum dies; and coloring and flavoring agents (traces) for esthetics. The sodium phosphate content is adjusted by the manufacturer to produce either regular-or fast-set alginates.[235] A dustless version, where the powder is coated with glycol, has been introduced to avoid the inhalation of alginate dust. This powder is mixed to obtain a paste.

Advantages

Alginate impression materials are pleasant tasting, easy to manipulate, easily poured into stone, hydrophilic, inexpensive and capable of displacing blood and body fluids. As alginates have atendency to tear easily, they must be poured immediately after removal. They can be used with stock trays and also have limited detail reproduction, and as they are dimensionally unstable they can only be used for single casts. Therefore, they cannot be used, if the dentist does not have a pouring access in the clinic, and if the alginate impression has to be sent to a laboratory far away from where the dental office is located. In order to achieve proper disinfection, the manufacturers recommendations must be followed carefully. Immersion in iodphors or sodium hypochlorite can be used to disinfect the alginate hydrocolloids.

Facebow Transfer

A commonly overlooked aspect of communication between dentist and ceramist is the correct orientation of the master model. The ceramist must be able to visualize the patient, just as the dentist does from the frontal view, by utilizing the master model. The ceramist can only estimate horizontal and vertical alignment of the working cast from landmarks taken from the cast itself, unless precise information has been transferred to them from the laboratory. Especially in the case of multiple anterior preparations where there is always the potential for misalignment due to poor communication between dentist and ceramist, it is unwise to leave judgement to pure chance.

The best way to evaluate the inclination of the incisal plane is to face the patient directly to view their face as a whole. In order to make a final appraisal, it is necessary to examine the direction of the dental mid-line and gingival plane from one canine to the other. The incisal plane may be observed to be slightly to moderately canted or parallel to the pupillary line. Although not frequently seen, severe canting may exist. A canted incisal plane frequently exists with the dental midline perpendicular to it when there are deficient crowns. Incorrect orientation of the working cast can cause a different inclination of the incisal plane of the teeth in the mouth, in comparison to the articulator. A slightly canted incisal plane requires either no correction at all, or only minor

WWW.HIGHDENT.IR
همیار دندانسازان و دندانپزشکان

incisal reshaping of the incisal edge. Before any prosthetic reconstruction takes place, a partial or full correction of the incisal plane is required when there is a moderately canted incisal plane. The key to success in a partial correction of a moderate cant is to make certain that the gingival margins of the incisors are also parallel to the pupillary line. Even with misalignment of the canines, a moderately canted plane can be made esthetically pleasing as long as the gingival margins of the maxillary incisors are aligned on a horizontal plane and the incisors are restored and aligned with the interpupillary line. A unilateral surgical elongation of the incisor on the lower aspect is indicated if the orientation of the gingival plane follows the cant of the maxilla and appears oblique in relation to the interpupillary line.[258]

A divergence between the interpupillary line and the intercondylar axis may occur due to natural asymmetries of the head leading to unnatural canting of the maxillary cast due to the facebow record transfer converts and the asymmetrical axis locations to the horizontal symmetrical axis of the articulator (see Chapter 13).[259] The dental laboratory technician may not recognize this problem on the bench surface, and improperly canted incisal and occlusal planes of the crown restorations may ensue at try-in.259,260

Bite Registration

In most of anterior PLV cases (unless the occlusion has to be improved or changed, or if the patient is having some TMJ pain or discomfort) a simple "centric occlusion" registration will be sufficient. It is always preferable to have registration material that is as stiff as possible. It should be very soft when introduced into the mouth to prevent the patient from biting with force and forming different closing positions than normal. It is a common phenomenon that when biting on a harder material, a patient will apply some force and unconsciously their bite will be considerably different than it normally is.

It is also wise to use a minimum amount of material in order to prevent the material flow into the undercut areas beyond the equatorial limits of the posterior teeth since the technician will have difficulties when seating the stone models on the bite-registration material and relating the upper and the lower stone models to each other. In most cases, if only the maxillary anterior teeth are to be treated with the PLVs, due to the reduction limited to the facial surfaces of these teeth; almost all the teeth will be in contact when the 2 stone models are brought into contact.

However, if the mandibularteeth are also being prepared for PLVs it is easier to place an anterior jig after the centrals and laterals are prepared in order to stabilize the arches into position. The occlusal-registration can then be made more accurately after the jig is seated over the lower incisors.

Provisionals

In PLV cases, the ultimate goal of provisionals is to master the function and esthetics of the final restorations. This makes it an integral part of the treatment, providing proper communication with the patient and laboratory, which directly enhances and positively affects the smile design process.

Provisionalization is a practical means of obtaining feedback, on the esthetic parameters, from not only the patients, butthe dentist and technician as well, since the subjectivity of a smile design can never be overemphasized.[261] This will eliminate most of the guesswork which may be the cause of an imperfect esthetic and functional outcome.

The dentist is able to create and develop facial esthetics,[262] smile design.[7]>258 tooth form and contour or occlusion and function.263,264 as we|| as marginal integrity and emergence profiles[115] through the use of diagnostic wax-up and provisional restoration. With the aid of provisionalization, verification of esthetic modifications and biological compatibility of the proposed restoration is made possible for the restorative team.

As was previously explained, the APT is produced prior to tooth preparation, and gives a

WWW.HIGHDENT.IR
همیار دندانسازان و دندانپزشکان

better idea of what can be expected in the final outcome. This is especially important if the original position of the anteriorteeth has been lost through disease or trauma, or if significant changes are to be made for the sake of creating a new smile design. The new form, position and length of teeth can easily be visualized using the provisionals.

Patient Communication

Although it is ultimately the dentist's responsibility to decide on the type of treatment that will work best for each patient, the patient also has the opportunity to express what is esthetic, comfortable and functional for them. The closer the temporaries are to the desired result, the less surprises will be incurred on the day of delivery. Even though the APT can help most of the patients finalize their visual expectations, some patients are strongly influenced by comments made by colleagues, family and friends once they leave the dentist's office. This kind of patient can voice their final approval in a few days after the provisional is inserted and if any changes are to be made, final touch-ups can be done. Well-established communication between the dentist and the laboratory is necessary. Despite this communication, the technician can still occasionally misjudge the incisal edge position and length due to the absence of the lips on a stone model.

Incisal Edge Position

The position of the incisal edge and the length/width ratio of the central incisors are two of the important factors that the dentist must decide on. The position and width/length ratio of the incisors is dictated by the two central incisors, Therefore, it is not only the color of the tooth that must be precisely described to the ceramist, but the entire smile as a whole.[3]

The original incisal position should be tested with provisional restorations that have been fabricated from a diagnostic wax-up. However, a common error is to drastically alter the original position before doing so. If a significant alteration in the incisal edge position is planned with new PLVs, the patient should first demonstrate functional adaptation to the new position in the provisional restorations.[265] Functional disturbances such as mobility, pain, or discomfort, which prove difficult for the patient to adapt to, can occasionally be caused by retraction of the protruded incisal edge position toward the lingual. Thinning of the palatinal portion of incisal edges of the provisional restorations may be necessary to attain a comfortable guidance. However, this thinning of the incisal may result in the final incisal edge position being further labial than anticipated from the diagnostic waxing. Significant esthetic alterations necessitate very careful planning and simultaneous restoration of both esthetics and function.

Phonetics, Function and Esthetics

Functional and phonetic parameters are an intrinsic part of esthetic results. To truly test the function, phonation, position of the lips and vertical dimension, these prostheses must be used.

Real life tryouts must be done to avoid situations that may jeopardize the ceramic preparations. The length, protrusion and position must all be "tried out" in the patient's mouth. The dentist and the patient must work together to find the esthetic and functional components they can agree on. A precise adjustment is necessary once they are cemented. The patient must be asked to perform protrusive, lateral and excursive movements while checking the anterior and canine guidance, so that the occlusion and function can be verified. The new smile should not affect speech or lip closure[2] if the overbite and over-jet relationship are balanced.

The final position and appearance of the central incisors will be dictated by the dentist's knowledge of smile design and the patient's guidance through functional movements and speech. When the dentist and patient are satisfied with the function and esthetics of the provisional restorations, an impression of the approved provisional is taken and sent to the laboratory. This is one of the most important communication tools along with the photographs, study models, and the incisal index.

WWW.HIGHDENT.IR
همیار دندانسازان و دندانپزشکان

Blueprint for the Ceramist

The approved provisionals act as a blueprint of what the ceramist will create. A well-fabricated temporary will dictate a proper occlusal scheme and esthetic form. Carefully designed provisional restorations, which fulfill the esthetic, biologic and functional criteria, will provide a constructive foundation for the long-term restoration.[261] The time spent at the delivery or final visit will decrease when more time is spent during thetemporization phase. An approved point of reference gives the ceramist confidence to successfully complete the final product. The success of this visit is very important and the dentist's ability to gain the patient's confidence is reflected in the success of the final restoration.

Pulp Protection

Provisionals traditional indication, have been to protect the prepared tooth structure. Provisional restorations are essential for ensuring health and esthetics until the definitive restorations are fabricated, during the time between the preparation of the tooth and the placement of the final restoration.[172]

Minimal invasive techniques are used for the PLV cases. However, in cases of altering very dark discolorations or incorporating the existing cavities or the worn out composite filling into the PLV restoration, deeper preparation of the tooth may be necessary. Prolonged exposure of the dentin permits microbial penetration and increases the potential thermal and chemical trauma.[266] Due to tooth sensitivity, the patient will also practise inadequate oral hygiene, which will cause gingival inflammation. In such cases, the provisional will be protecting the pulp, as well as decreasing postoperative sensitivity. In order to achieve this, the provisional must be fabricated from a material that will prevent the conduction of temperature extremes.

In today's dentistry, all materials used for fabricating the provisionals for PLV cases fulfill these criteria. However, care should be given to the adaptation of the margins to prevent microleakage, and thus bacterial invasion, which is considered the most important cause of post-op sensitivity. The sensitivity will be minimal or non-existent if the exposed dentin surfaces are sealed with the bonding agent just after the preparation and before impression making and provisionals.

Provisionals should also help maintain the periodontal health and tooth position. In cases where there is mobility of the teeth due to periodontal problems, the provisionals will also supply positional stability. However, while trying to achieve this and by connecting the provisionals together, the contours and the gingival embrasures should be delicately designed so that the area can easily be cleaned throughout the provisionalization period.

Even though most of the PLV margins are prepared supragingivally, in special cases where the margins are placed subgingivally, it is of the utmost importance that the margins of the provisional restoration do not impinge on the gingival tissues.[267"270] The resulting inflammation may not only cause gingival proliferation or recession, but hemorrhaging duringthefinal bonding, which will severely affect the longevity of the PLVs.

Various techniques such as spot etching and luting with a composite,[271"273] eugenol-free temporary cement[274] or the use of dental adhesives[275] have been suggested for the bonding of provisional restorations.

Technique

The fabrication of the provisionals can be classified into two groups, as direct (intraorally) or indirect (extra oral) prefabricated provisionals.

The latter is prepared at the laboratory on a plaster, stone or epoxy model before or after the teeth are prepped. The technician approximately prepares the stone model and builds up the provisional mostly from acrylic. After preparing the teeth, the dentist tries to adjust the interior surface of the acrylic veneers for an easy fit over the teeth. Once the provisional can be easily placed, then the inside of it is filled with a flowable composite and temporarily bonded.

However, the author prefers the intraoral provisional fabricating techniques. There are various approaches for the different techniques.

WWW.HIGHDENT.IR
همیار دندانسازان و دندانپزشکان

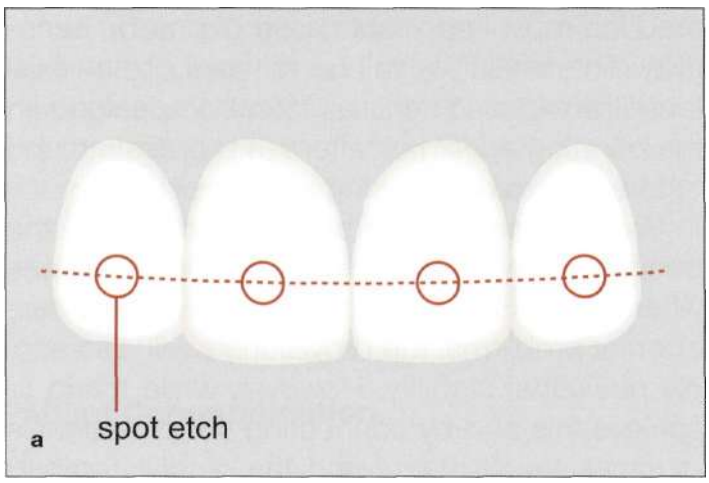

Fig 7-57a, b (a) Partially to bond the provisionals in place, teeth are spot etched. The important issue is to try to keep the spots on the same horizontal level. This will ease the cleansing of the bonded area just before actual PLV bonding. The tooth is then covered with adhesive, (b) A flowable composite (Luxatemp) is then loaded into the translucent silicone template and placed over the prepared teeth.

Free Hand Carving

Avery quick way to fabricate the provisional intraoral^ is by the freehand carving technique whether it is for a single veneer or two to four veneers.

When the restorative result is no longer dictated by the remaining tooth structure, manipulation of free hand composite resin enhances creative skills and familiarizes the clinician with different sensitive build-up techniques that are advocated in clinical practice for achieving predictable results.[25,276] The experience also develops spatial visualization, perception of forms and volumes, and the ability to discard rigid esthetic standards and discover creativity.[28] For improved clinical/laboratory communication, the use of free hand composite resins can familiarize the dentist with different dental designs, surface textures and anterior teeth positioning, learned through a unique craftsmanship process, to address the challenge of replicating natural esthetics.[28] The tooth can be spot etched and the bonding agent applied and light cured. Then the necessary amount of hybrid composite, with the desired color that matches the adjacent teeth is rolled between the fingers. The material is then placed and shaped on the tooth, with the help of the index finger. If the surface texture or extension of the provisional to the interproximal is required, then special instruments can be adjunctively used and light cured. In this technique, the dentists have the maximum control to themselves.

If it is to be placed on a single tooth, the adjacent teeth can be used as references in terms of length, tooth axis and color. However, iftwotofour teeth are being provisionalized, than the incisal length and position can be adjusted freely, paying the utmost attention to function and anterior guidance. Since these provisionals are being placed one by one, the interdental contacts can be left separated in order to leave space for easy cleaning practices.

Translucent Template or Silicone Impression

The second intraoral technique; is the fabrication of provisionals with the help of the transparent template which closely mimics the wax-upthat the lab technician produced at the very early stages of treatment planning. Instead of the template, the dentist may prefer to make a translucent silicon impression (Clinicians' Choice) of the stone models of which wax-ups have been made. To build the provisionals intraorallythe dentist can use that impression instead of the template.

Once the teeth are prepared, they can be spot etched and then the adhesive is applied and light

WWW.HIGHDENT.IR
همیار دندانسازان و دندانپزشکان

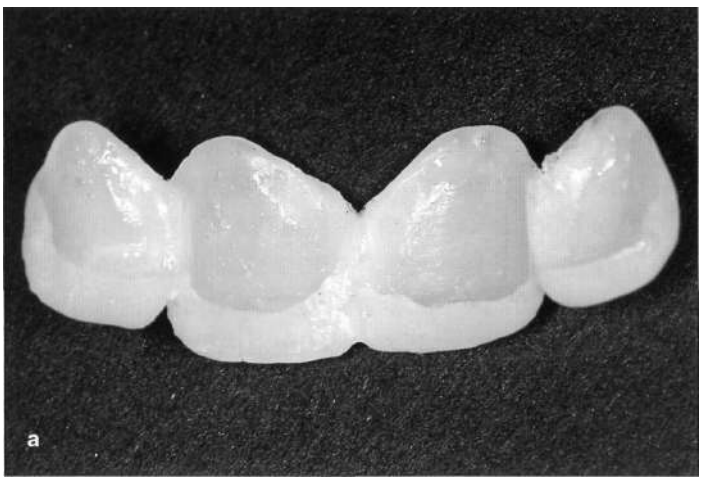

Fig 7-58a, b (a) The provisionals that come out with the template are trimmed down and polished, (b) The provisionals are in the mouth. They should be cemented with either a flowable luting resin or eugenol-free cement.

cured. Next, the template is loaded with a flowable resin, with the color of choice and gently placed overthe prepared teeth (Fig 7-57). The nice part of using the transparent template is that it allows the dentist to use light cured composites and they can visualize the voids that sometimes occur during the placement. If the voids are big, the template can be taken out of the mouth, filled with the same flowable composite, and re-inserted. However, if the voids are tolerable it is always possible to restore these areas after the provisional is completely polymerized and cemented.

After the composite is polymerized, two possibilities arise. The provisional either comes out with the template during removal or stays intact on the prepared teeth.

If it comes out, then the margins can be trimmed and polished extraorally and the provisional is then cemented over the teeth with non-eugenol cement or with a flowable composite (Fig 7-58).[277] A flowable luting resin is placed inside the temporary veneers and reseated onto the teeth. Each tooth is cured for 10 seconds with a plasmic arc or laser light, or 30 seconds with a conventional light.

However, if it remains on the teeth, then the provisional is totally polymerized in the mouth and gingival flesh is cleaned with the help of the finishing carbide burs without violating the dento-gingival complex. If voids exist, they can be restored and the final appearance is checked in terms of esthetics and function.

In case any alterations are necessary, they can easily be performed intraorally. Luxa Flow can also be used to repair or add onto the temporary. The areas must be micro etched or roughened with a bur, and a bonding agent should be applied. This represents the treatment phase that enables the dentist to put their artistic skills into practice.

If the provisional from the matrix, does not need to be altered, then the technician can use his/her wax-up for the final PLV build-up as a guide.

However, if any alterations were made, then the dentist should provide the technician with a new impression of the whole arch with the altered design of the provisionals cemented together with the pictures taken.

WWW.HIGHDENT.IR
همیار دندانسازان و دندانپزشکان

Laboratory Communication 2

While the availability of novel materials and application techniques in adhesive dentistry have expanded the esthetic armamentarium, it mandates that patient, clinician and technician remain in close communication in order to maintain a high level of performance, incorporating their combined knowledge and artistic ability.[278]

Understanding each other through shared experiences, successes and failures, and being in harmony enables the dentist and ceramist to communicate well. The more subjective side of the triad is the communication between the dentist and patient that relies on trust, dialogue, consensus and complicity.[5]

A solid collaboration between the dentist and laboratory is essential to achieve the desired esthetic result.[279] However, in orderto develop the highest level of communication, both the dentist and the technician should be knowledgeable in current trends while ensuring that they keep the communication line between them open at all times. This alone is not enough, as the restorative team must work together (dentist-technician) to develop common goals, interests, values, abilities and desires by improving the dentist's understanding of the laboratory phase, and the technician's cognizance of the clinical aspect of dentistry.[300]

Patient Expectations

Esthetic dentistry-although scientific in nature remains an art form that requires patient approval of the definitive outcome.[278] They are naturally more concerned with the final esthetic result than whether or not the fabrication was difficult. Consequently, there is no point in the dentist explaining the difficulty of the procedure to the patient if the patient is not satisfied with the result. This often leads to the technician feeling forced to make compromises in materials and technology.[283] Laboratory communication is of prime importance in achieving predictable and pleasing results in esthetic PLV cases. "A chain is as strong as its weaker link." No matter the amount of time spent with the patient or the knowledge of the dentist or the efforts of the technician, the result will only be as successful as the strength of the lab-dentist communication link that ensures that all the data is transferred properly. Consequently, the dentist should not expect miracles to happen in orderto obtain an esthetically successful result. Therefore, the process in the past that only sent the impression to the laboratory technician without very clear directives about the transfer's color is no longer a feasible communication tool. Beautiful smiles can only be created through sound communication.

Photography

In the case of anterior esthetics, a picture, and all that it is able to convey, is priceless. Using slides, prints or intraoral photographs enable the dentist to easily communicate invaluable information concerning the shape and texture of the teeth. The more sophisticated video imaging is also good at conveying information about the desired form.[96] Pictures make it easy forthe laboratory technician to actually see the tooth contours, the translucencies within the incisal edge, hypoplastic spots, enamel staining and the actual intensity of the characterization.

Polaroid photographic prints of the try-in stage or composite mock-ups can be used along with the necessary information written on them to be sent directly to the lab. Instant film development is possible with digital photography, allowing the dentist and technician to review images via email, no matter the distance, and in only a few seconds.

Color Communication

Perhaps the most sensitive and critical area of communication is that of color. It requires very close communication of concise information between the dentist and technician, in order to select the most accurate color (see shade selection). An unsuccessful result is often due to the incorrect choice of color that may be due to the unclear communication and poor correspondence between the parties.

Ideally, the technician should be involved in the selection process along with the dentist and

WWW.HIGHDENT.IR
همیار دندانسازان و دندانپزشکان

patient. When this personal contact is not possible, photographic images serve as the next best effective way to communicate information on color and esthetics. It is not very easy to convey the exact color by observing a slide, but if a shade tab is placed next to an image of the tooth, quite a lot of information is supplied to the technician about the translucency, texture and luster, along with the chroma, value, hue and the shape of the tooth.

Shade Tabs

The photograph should includetheshadetabthat has been chosen. A photograph and whatever information it conveys is dependent on the camera, the flash, the film etc. However, it is possible to correctly assess the color if the tab is included and the differences between the tab and the teeth are accurately recorded.[16] In order to correctly assess the color, the tab and the teeth should be on the same plane and placed edge to edge. If the tab is not observed from the same plane then the value may appear different than it actually is.[284] The tab levels must be placed so that they can clearly be seen and if possible, more than one tab should be included. The color is then adjusted according to the differences that have been recorded on the slide. In the comparison of different values, black and white photographs are most useful.

Translucency

With color, communication of the translucency and texture are important parameters that play an important role in the value of the teeth. Transforming the incisal details necessitates highly developed photography techniques. When photographing the mamelons there will be too much reflected light if the camera is held perpendicular to the labial surface. To avoid this, the camera must be held high at a 30-degree angle downwards. To record the translucency the teeth should be photographed clenched and opened. The thickness of the enamel layer and any crack lines can be seen in the photographs taken at a 30-degree side angle.

Full-face Pictures

The photographs should not only be limited to 1:1 intraoral pictures, as full face pictures are very useful and should always betaken and utilized. This is the best way to communicate with the lab in terms of teeth and lip relationships and the relation of them to the whole face. Pictures should be taken before, during and afterthe preparation and the provisionals. In addition to all the techniques explained for positioning the correct incisal line, photography will have a great input on the issue as well. Pictures of the provisionals should be taken, even if they may not be perfect. At least it helps the dentist, patient and technician by providing something to discuss in terms of reaching the desired esthetic goal that this triad is working towards.

Points of Reference

The technician may need to have one or several reference points in order to place the new incisal length and the new anterior position of the teeth. If intact teeth in the area exist, they will have no problems in using them as guides or references. However, in the case of a new smile design, with many worn or damaged teeth, it is best to use the provisionals as a master guide. The last photographs of the before and after (with provisionals) and stone models should be included.

The impressions should be delicately wrapped and sent to the laboratory in order to avoid any deformation (see impressions).

Facebow Transfer

Some of the other supportive tools of communication are the accurate bite registration and the face bow transfer. However, the face bow transfer does not always necessarily transfer the correct esthetic information. Care should be given to transfer the incisal line position (see Chapter 13).

WWW.HIGHDENT.IR
همیار دندانسازان و دندانپزشکان

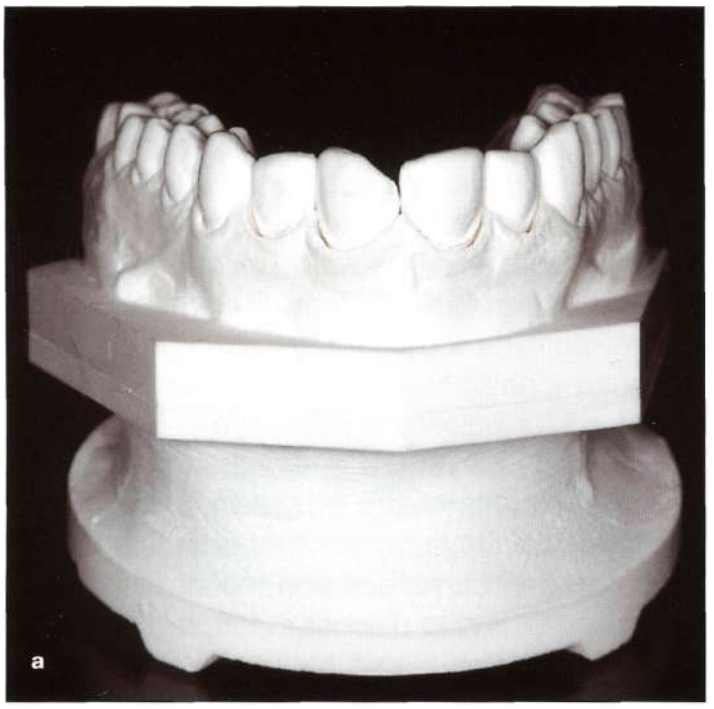

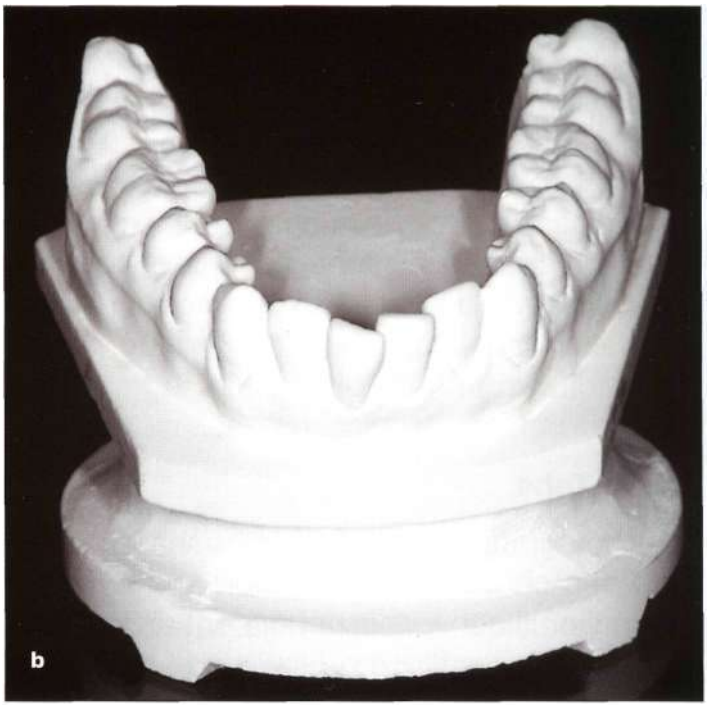

Fig 7-59a, b Model of intact gingival (Geller) with remova e refractory dies (front view).

Detailed Prescription

Although there are several ways of communicating information to the laboratory technician, the standard practice is to send a detailed prescription form with sufficient, objective information[285] so that it can easily be translated into a subjective result. A detailed written instruction sheet[286] should incorporate a comprehensive description of the patient and their expectations, as well as the dentist's comments. In this way, all pertinent information is communicated to the technician in a clear, concise manner.[5]

In addition, hand drawn diagrams, such as sketches of the hypocalcification spots, translucency patterns, crazing or even intrinsic shade mapping, will have great value in shade communication.

The details should be discussed, after the technician receives all the information together with the photos, models etc., in orderto avoid any conflicts.

Dentist-Technician Collaboration

Once, tooth preparation techniques, new materials, technical procedures, esthetic concepts, and smile design are mastered by the clinician and the ceramist, a higher standard of service can be provided to the patient[287] thereby producing restorations that are mechanically, biologically and esthetically sound.

Improving the dentist and technician's mutual understanding of each other's work and total awareness of the steps they each take as this procedure develops, can only enhance the details of this process of interdisciplinary communication.[288] If the dentist is well trained, or at least has solid knowledge of the technical aspects of the laboratory procedures, he/she should recognize the limits of the dental technician, especially in PLV cases wherethe maximum thickness of the porcelain will be as thin as 0.5-0.7 mm

On the other hand, the technician should also be dedicated to their profession, having adequate current knowledge of the materials, techniques and their own artistic abilities in orderto be able to produce the details that the esthetic dentist has transferred to them (Figs 7-59 to *7-77).*

WWW.HIGHDENT.IR
همیار دندانسازان و دندانپزشکان

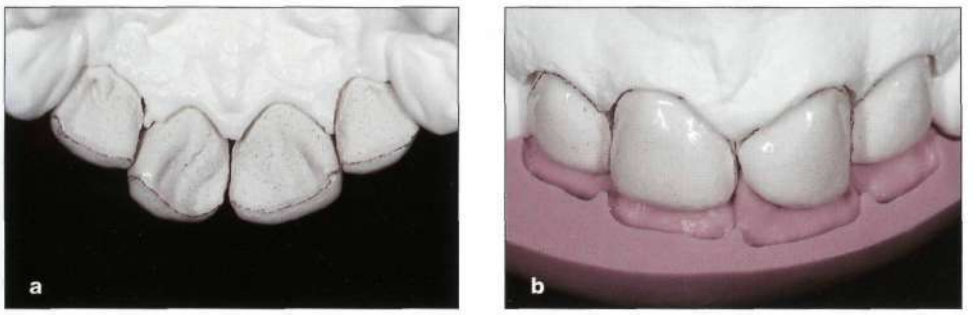

Fig 7-60a, b (a) Model of intact gingival with removable refractory dies (palatal view), (b) Model of intact gingival and silicone matrix on diagnostic volume of teeth.

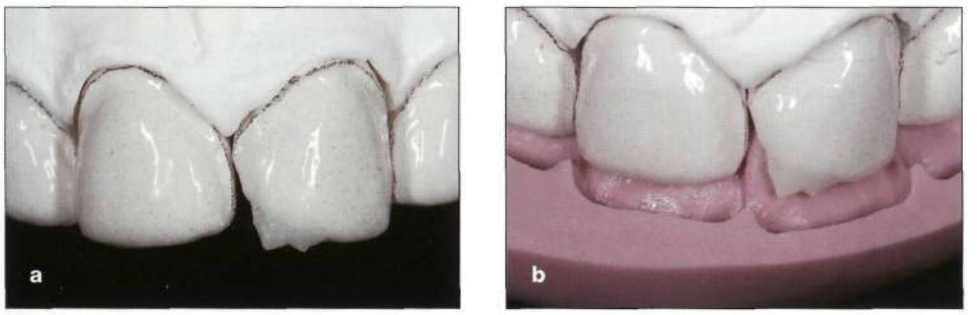

Fig 7-61 a, b (a) Material for rebuilding and to tie in with the volume of the preparations in between, (b) Check with silicone matrix. Note the mesioincisal addition on tooth #21(9).

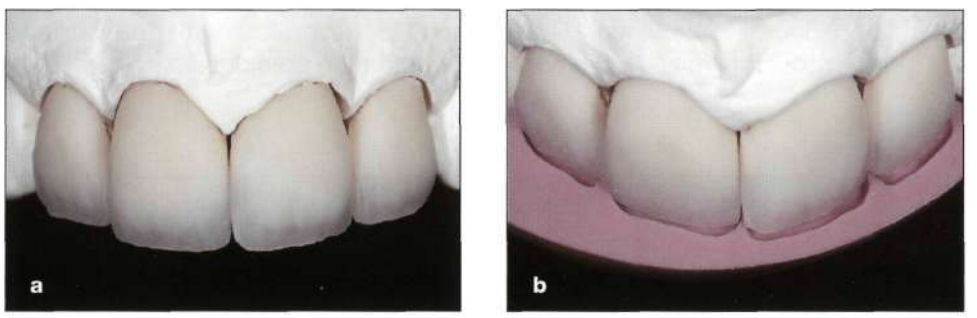

Fig 7-62a, b Principal bake, checked with silicone key.

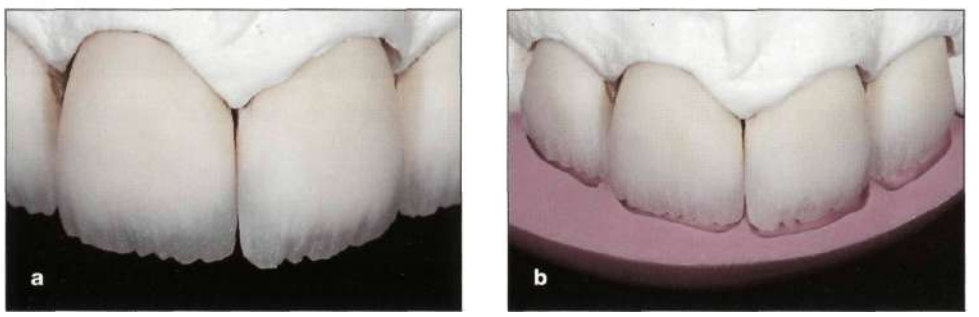

Fig 7-63a, b Cutback with drift. Checked with silicone matrix.

Fig 7-64 Deep characterization with internal stain and ceramic. This is very important in order to achieve a natural-looking PLV.

WWW.HIGHDENT.IR
همیار دندانسازان و دندانپزشکان

Fig 7-65a, b Opalescent and translucent enamel skin. The amount of translucency should be well controlled. If too much translucency is applied, the PLV will exhibit a grayish color.

Fig 7-66 Second bake correction.

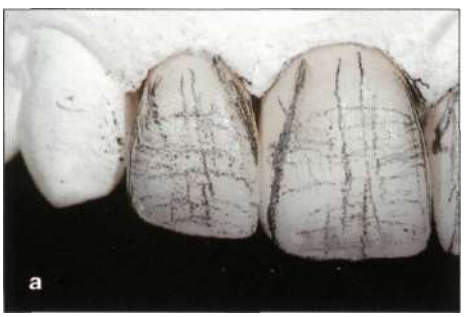

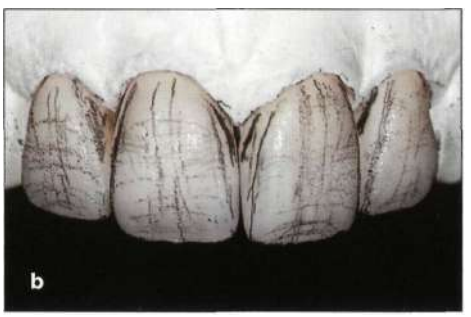

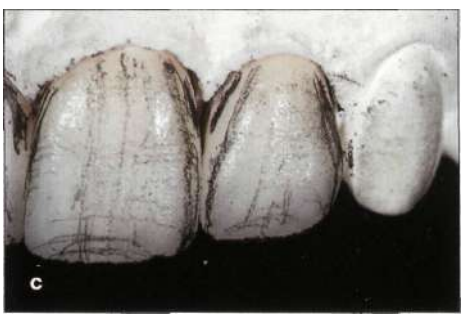

Fig 7-67a-c Adjustment shape with transition lines (front view). These lines, incorporated with the surface texture, are extremely important. The author believes that this may be more important than the color itself.

Fig 7-68a-c Visible adjustment on refractory dies (palatal view). The anatomy of the palatal surface plays an important role is establishing the anterior guidance.

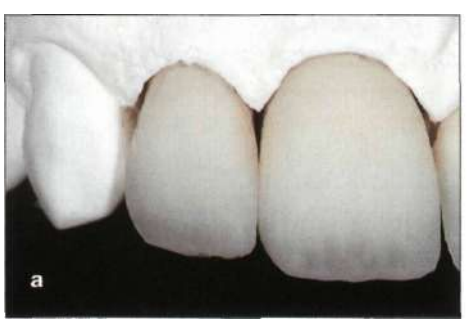

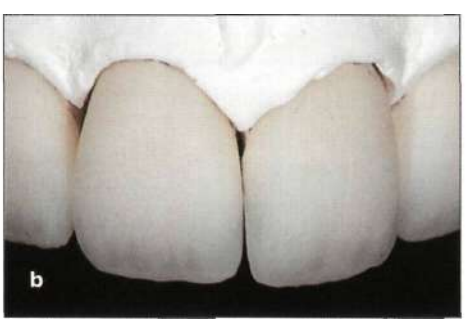

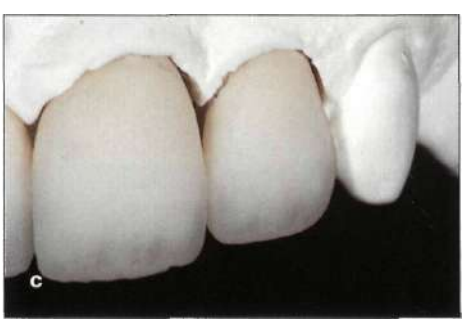

Fig 7-69a-c Surface before glazing. All the necessary texture and form adjustments must be finalized at this stage.

WWW.HIGHDENT.IR
همیار دندانسازان و دندانپزشکان

Fig 7-70a-d Surface before being baked with glazing liquid.

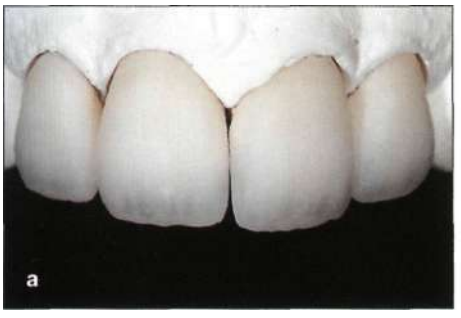

Fig 7-71 a-c After bake and mechanical polishing.

Fig 7-72 Finished crowns on the model before refractory separation.

Fig 7-73a, b Laminates on refractory dies. Note the refractory dies are prepared for the multiple-die technique.

WWW.HIGHDENT.IR
همیار دندانسازان و دندانپزشکان

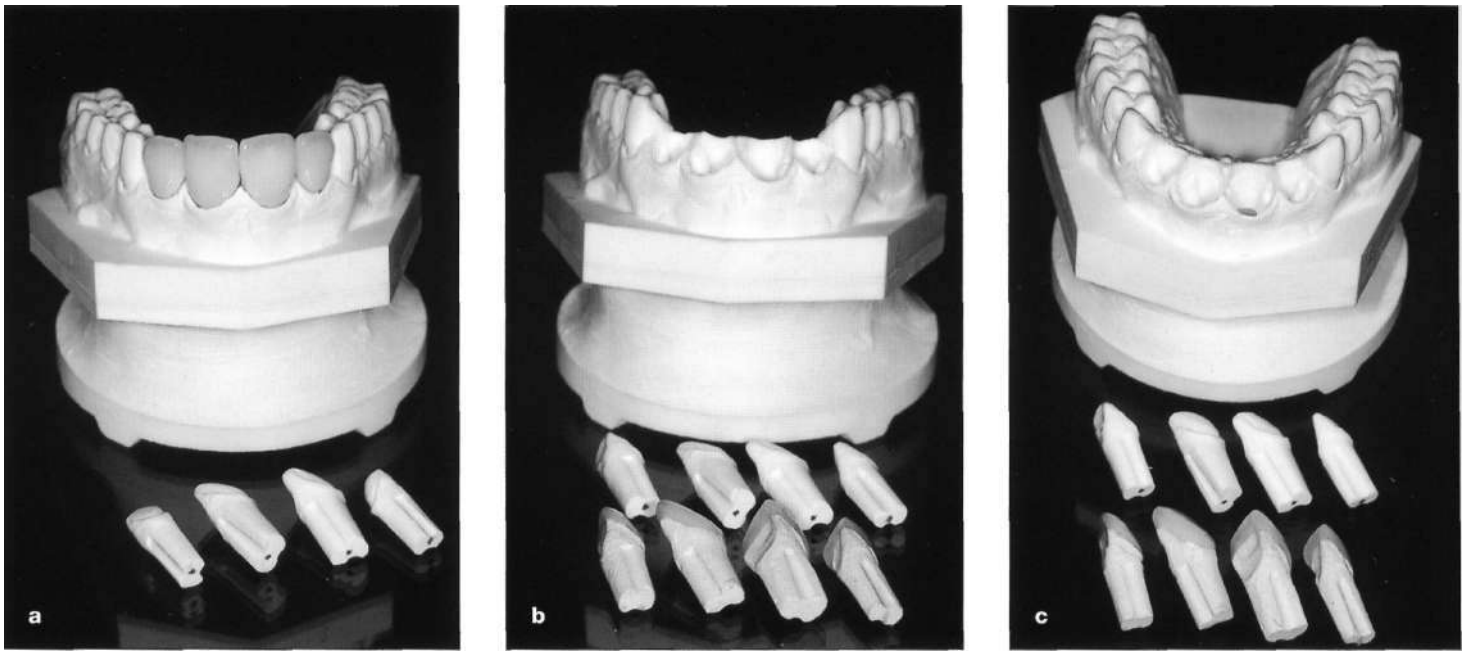

Fig 7-74a-c (a) Veneers on refractory dies for the model, (b) These dies are derived from a duplication of the master dies and they can be inserted into the model, (c) Detail of model *{Geller).*

Fig 7-75a-c Final work on the model (Ceramist *Michael Magne).*

WWW.HIGHDENT.IR
همیار دندانسازان و دندانپزشکان

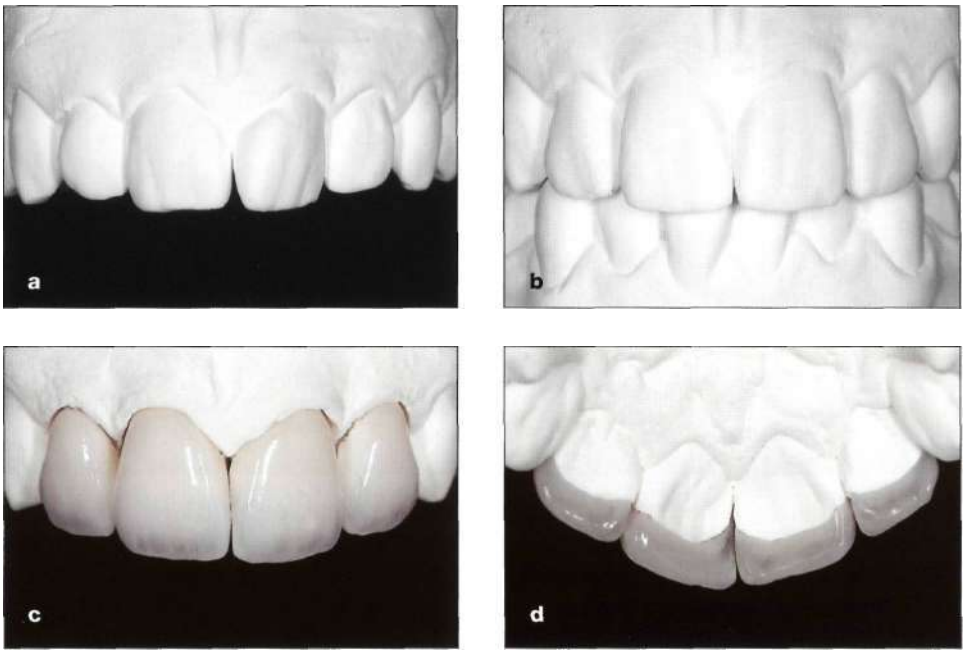

Fig 7-76a-d (a) Before wax-up. (b) After wax-up. Note the lengthening of the incisal edge that changes the individual tooth proportions, (c, d) Final work on the not-fragmented model in frontal and palatal views. Frontal adjustment of the contact.

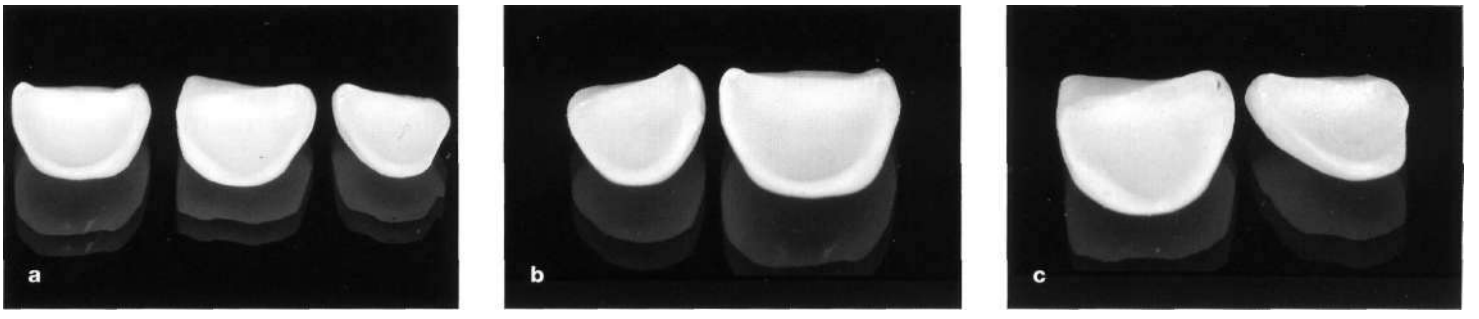

Fig 7-77a-c Finished veneers out from refractory and etched.

Try-in

The veneers should first be tried-in before they are bonded to eliminate unexpected surprises.

When the patient arrives for the final appointment the teeth are first anesthetized for the comfort of the patient. (This is especially true if the dentin is not hybridized at the first appointment) however, oneshouldnotforgetthatthetry-in stage will be the final decision making process before thefinal esthetic outcome. In other words, the dentist and the patient should strive to improve both the esthetic appearance and the new smile design, at the try-in stage (before the PLVs are bonded), while the possibility for improvement still exists.

Therefore, it is not a good idea to numbthe area together with the lips because, as it has been explained (see Chapter 2) before, the teeth position and the length and their relation to the lips have a great influence on the smile design and hence the overall appearance. In such cases, it is wise to use a palatinal injection, very sparingly, to numb the target area while being careful not to numbthe lips.

A vital component in achieving success for the holistic management of the esthetic patient is to conduct the entire treatment in a virtually painless environment. Despite the monumental advances in almost all the procedures related to esthetic case management, the one area that has potentially remained unchanged for as much as

WWW.HIGHDENT.IR
همیار دندانسازان و دندانپزشکان

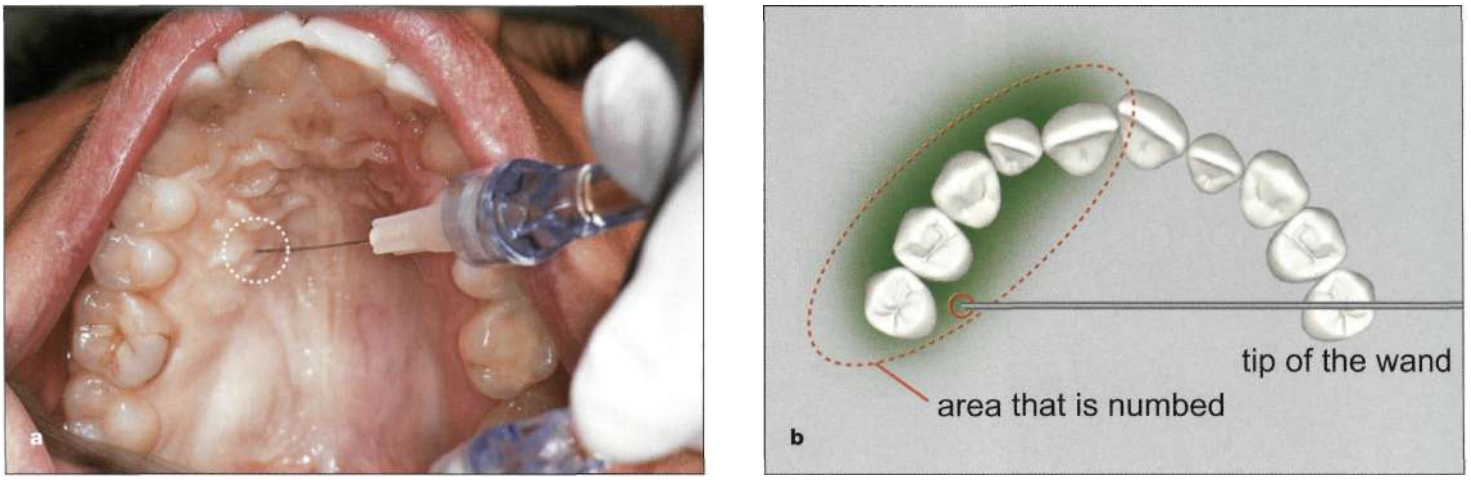

Fig 7-78a, b The tip of the needle is placed into an area (circled) midway between the first and second premolars. The handle should be held between the other premolar to achieve a 90° insertion path way. The whole anterior segment can be numbed without affecting the lips.

150 years *{Charles Pravaz,* Paris 1853) is that of the anesthetic delivery device. The traditional hand-held syringe systems are limited by their linear principles of application and as a result have largely determined the techniques we have chosen to use in the past.

The supra-periosteal buccal infiltration can result in an unwanted hamartoma (rich vascular supply), discomfort for the patient, inability to smile (motor effect), "swollen" lip (anesthetic volume) and resultant inaccuracy in the determination of the smile-line. Added to this, is the need to use more than one site of injection and larger quantities of anesthetic drug when treating the entire anterior arch for veneers in the anterior maxilla.

Aesthetic Anesthetics

Through the introduction of modern drug delivery devices such as the WAND (Milestone Scientific Inc.) 1997 and the CCS (Dentsply) 2001, computer controlled technology is now available to help us and our patients achieve successful "esthetic anesthesia". This term was introduced by *Williams*[289] and refers to the concept of achieving profound pulpal and soft-tissue anesthesia with the least possible unwanted side effects as part of the comprehensive management of the esthetic patient. By virtue of the associated anatomy and techniques defined in this concept, the major benefits contained therein are for procedures conducted from the first incisor to the second premolar on either side of the maxillary arch.

Technique

The AMSA block (anterior middle superior alveolar nerve), described by *Friedman* and *Hochman,*[290] is delivered palatally at a single-site and anesthetizes multiple teeth and related soft tissue. It can be administered to a single-site (unilateral) as well as two-sites (left and right) (bilateral). The exact location of the injection is an area approximately 1 cm in diameter, (i.e. not a point), with the tip of the needle bisecting the first and second premolars; and midway between the mid-palatine suture and free gingival margins. The approach angle for the needle and hand piece should be at a right-angle (90°) to a line drawn across the palatal cusps of the maxillary posterior teeth on the side, being injected (Fig 7-78). Alternatively, approaching the delivery site with the hand piece bisecting the premolars of the opposite quadrant will exact the delivery.

WWW.HIGHDENT.IR
همیار دندانسازان و دندانپزشکان

Mechanism of Action

Pain experienced during anesthetic solution delivery into the taught palatal mucosa is largely (if not completely) related to the high pressure that is built up when using the standard hand-held syringe. This pressure, in turn, relates directly to our inability to introduce very small volumes of liquid into these tissues in a consistent and predictable manner. Microchip technology allows for precision controlled flow rates and a resultant reduction in the associated pressure during delivery (current research). It is this marked reduction in pressure that allows for a virtually painless injection into the maxillary palate. The anatomy of the maxillary osseous tissue lends a further, logical explanation to this reduction in pressure and the palatal osseous tissue acts as a sponge when a solution is delivered (drop-by-drop) at controlled (slow) speed *(Hochman* and *Williams,* unpublished).

Structures Anesthetized

Pulps of the mesiobuccal root of the first molar, second and first premolars, canine, lateral and central incisor ipsilateral to injection site, as well as the attached gingiva and mucoperiosteum extending from mid-palatine suture to gingival margin (palatally) and attached gingiva (buccally) can be anesthetized. Although generally co-incidental to the teeth anaesthetized, the extent and direction of soft tissue anesthesia is related to the antero-posterior angulation of the needle/hand piece.

Dosage

Usually 0.6-0.9 ml. depending on the dosage, with a delivery time that varies from 1.5 to 4.0 minutes is enough. The use of a vasoconstrictor in concentrations exceeding 1:100000 may increase the risk of local tissue damage and are discouraged. Once correctly administered the area stays numb for 45 to 90 minutes.

Precautions/Guidelines

Case and drug selection is important in avoiding potential complications. Necroses, although extremely rare, have been reported in cases where patients with a very thin palatal mucosa have been injected. The inability of a thinner mucosa (reduced vascular supply) to rapidly remove a vasoconstrictive drug, the prolonged vasoconstrictive effect of excessive (quantity or concentration) or multiple delivery of vasoconstrictor containing drugs, or the use of inappropriate speed (and resultant high pressure) for delivery of the anesthetic solution to these tissues, may result in necrosis of the soft tissues.

The correct speed of delivery is also important to reduce pain (at commencement and during the injection), reduce the possibility of systemic reaction and to ensure maintenance of physiologically acceptable tissue pressures.

An "anesthetic pathway" should be created and maintained during the insertion procedure by using a controlled rotation-action of the needle. Pain during initial entry into the mucosa can be significantly reduced by correct placement of the needle bevel in relation to the tissue (flat part initially against mucosa—deposit a few-drops of LA then begin to rotate).

P-ASA Block

If only a few anterior PLVs are being tried in, the P-ASA block (palatal approach anterior superior alveolar nerve block) described by *Friedman* and *Hochman,*[290] is a simpler way to achieve anesthesia with a single injection (Fig 7-79). Although similar to the nasopalatine and incisive nerve blocks, the P-ASA differs in that it is described as a primary injection to achieve bilateral anesthesia of the six maxillary anterior teeth as well as the mucoperiosteum and gingiva in the region of the anterior palate innervated by the nasopalatine nerve. As a mucosal landmark the incisive papilla should be the delivery site. The combined advantage of the porosity of the osseous tissue at this site favoring the flow-dynamics of the anesthetic solution (toward the target neural tissue), and the introduction of the drug at slow speed

WWW.HIGHDENT.IR
همیار دندانسازان و دندانپزشکان

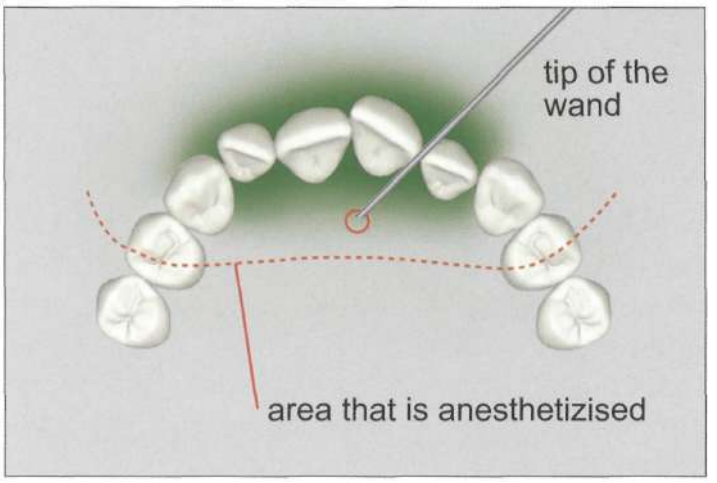

Fig 7-79 With the P-ASA block, only the anterior segment can be anesthetized.

Fig 7-80a, b (a) Usually the veneers can be easily removed with an excavator, (b) Note the microleakage that may occur due to weak bonding.

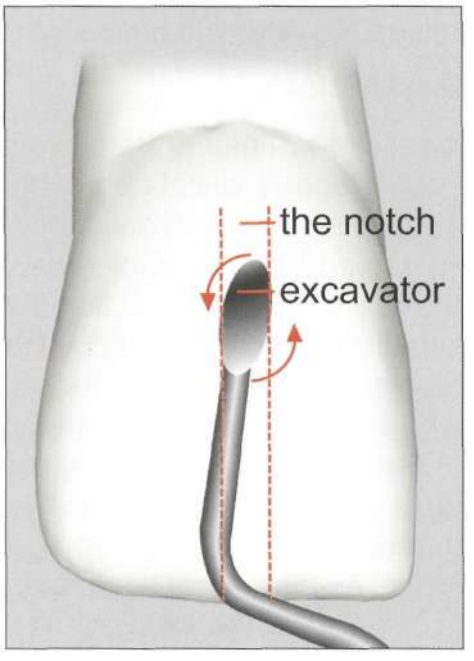

Fig 7-81 After a notch is created, an excavator is held 90° to the cut and twisted. In most cases the provisional veneer will easily pop up.

WWW.HIGHDENT.IR
همیار دندانسازان و دندانپزشکان

(again allowing favorable flow-dynamics with reduced pressure), result in this technique being virtually painless. With the administration to the maxillary central and lateral incisors, maxillary canines (bilateral), the palatal gingiva and mucoperiosteum extending from mid-palatine suture to gingival margin forthe anterior 1/3rd of the maxilla and the attached gingiva (buccally) extending from canine to canine is anesthetized.

Debonding The Provisionals

In order to start the try-in, the provisional veneers have to first be debonded. A spoon excavator can help, by levering the provisionals from the proximal wall, which will pop off the veneer at the proximal margin (Fig 7-80).

If the provisional resists dislodgment, then the facial surface can be vertically cut with a tapered fissure diamond bur. This should preferably be done without water spray, as it is easier to visualize the depth of the cut in order to prevent possible damage while entering the facial surface of the tooth. The cut should extend until the depth of the tooth surface is nearly exposed. The spot etched area can be slightly entered into with the diamond bur to enhance debonding. After that, the spoon excavator can be placed into the vertical notch with a torsion movement and the provisional can be broken into two fragments and easily removed (Fig 7-81).

Before the try-in, one of the most frequently ignored stages is the careful examination of the tooth surface itself. The facial and proximal surfaces of the prepared teeth should be carefully examined for any residual resin cement or provisional resin leftovers. If residue is found, it should be carefully removed. It is of vital importance to clarify this, in order to enhance the perfect fit of the PLVs. It is always better to check it with the help of magnifying loops.

If any doubt arises concerning the complete removal of the residual resin luting agent, the suspected area can be etched with 30% phosphoric acid, for 10 seconds as suggested by *Nixon.*[2m] The etch enamel surface will display a frosted appearance whereas the residual resin luting agent will not and so it will be easily detected and cleansed.

Fig 7-82 The facial surface is cleaned by sandblasting, pumice or with a very light application of a course diamond fissure bur. Care should be taken to use very gentle pressure.

Try-in

Now the PLVs can be tried in after the prepared tooth is first cleaned with fine pumice and water (Fig 7-82). A mixture of pumice and mercryl is suggested by some authors and is applied using a rubber Prophymatic cup.[5] This instrument avoids harming the gingiva by its alternating movements that reduce splashing and spilling. Fine metal strips moistened with mercryl are then used to clean the contact area. The tooth must then be thoroughly rinsed to free the tooth of any traces of pumice. Any substances that may cause bleeding should not be used, as bleeding can be detrimental to bonding and, therefore, all use of powder cleaners or brushes should be avoided.

Individual Evaluation

To start with, each veneer has to be tried in individually to evaluate their biologic integration relative to tooth and gingival harmony. Pressure should never be exerted at this stage since the

WWW.HIGHDENT.IR
همیار دندانسازان و دندانپزشکان

Fig 7-83 First, each PLV should be tried-in individually to check the marginal fit from every aspect, especially at the cervical 1/3rd.

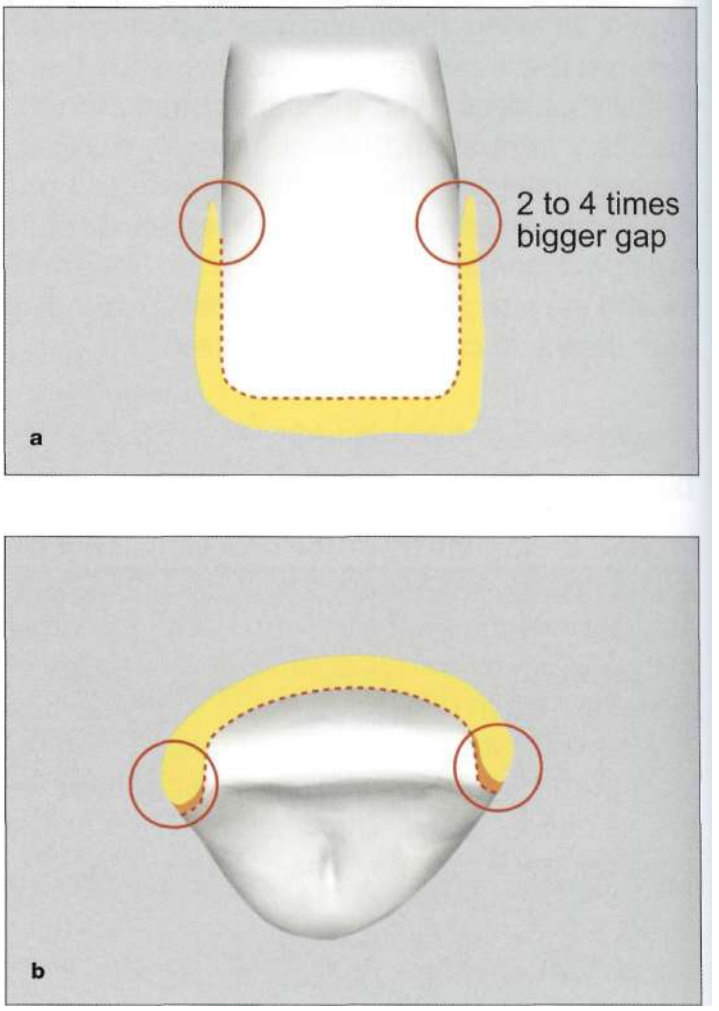

Fig 7-84a, b One of the most important sites to be carefully checked at the try-in stage is the gingivoproximal area, since the marginal openings in that area have been proven to be two to four times larger than midlabially.

porcelain is brittle before being bonded. Complete seating and marginal adaptation should be carefully checked (Fig 7-83). It must be kept in mind that large marginal discrepancies seen at thetry-in stage will result in an unesthetic outcome in cases of supragingival placement or cause periodontal problems in cases of subgingival placement. Shortly after they are bonded the organic matrix of the resin bonder (polymer-matrix composite) is subject to erosion and disintegration in the oral environment.[292] Poorthermal expansion, biocompatibility and plaque adhering properties are characteristic of polymer-matrix composites in comparison to enamel or porcelains. The bonding resin surfaces should be exposed to as little of the oral environment as possible. In order to achieve successful adhesive bonding, a reproducible precision of the marginal fit of complete porcelain is also required.

The delicate quality of porcelain tends to make it rather fragile and therefore it does not lend itself to finishing techniques. Consequently, after a proper margin design is produced by the dentist; the technician is responsible for the quality of the margin that requires their expertise, skill and dedication. Such technicians are able to realign margins and to produce margins very similar to metal or ceramometal restorations.

Checking the Margins

It is better to check the margins without using any kind of try-in gels to enable better, clearer access. Especially for PLVs, when the mesial and distal line angles are placed lingually, checking the gingivoproximal corners individually is of vital importance. Most studies show that the marginal openings at the gingivoproximal corners are two

WWW.HIGHDENT.IR
همیار دندانسازان و دندانپزشکان

Fig 7-85 After each PLV is tried-in separately all of the veneers can be tried-in together to see the esthetic integration.

Fig 7-86a, b If the seating problem is due to position shift of the teeth during provisionalization, then a gap will be seen on one side when overlapping of the PLV on the other. Finger pressure can be applied to realign the position of the tooth which has been mesially or distally moved.

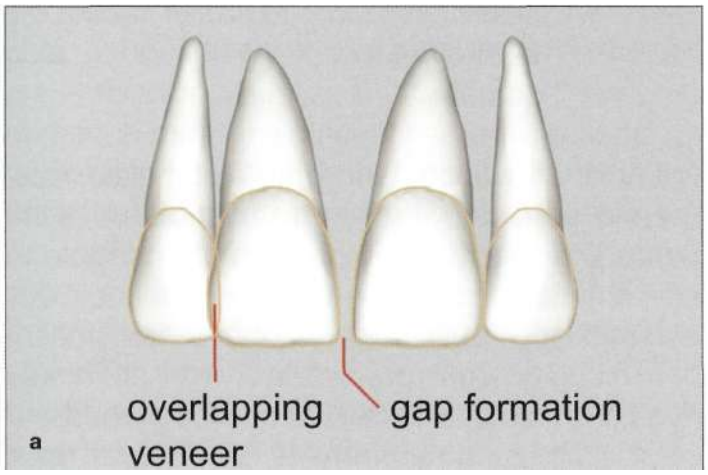

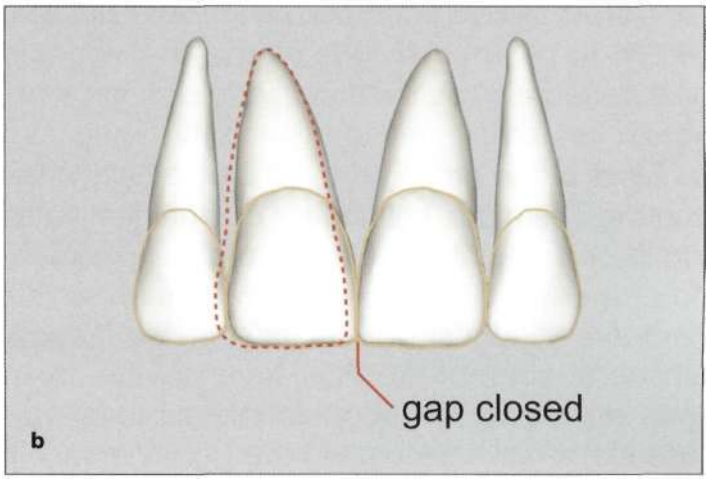

to four times larger than at the mid-labial portion (Fig 7-84).[50]>[281,293] This is related to the result of the shrinkage of porcelain towards the region of greatest bulk (the center) and the geometry of the margins. Clinically this poorer fit at the gingivo-proximal corners of the veneers would be further compounded by the difficulty in access for finishing of luted veneers in these regions.[111]

Collective Try-in

Once they are individually checked, all PLVs should be collectively tried-in to evaluate the proximal contacts and contours. This checking of the "esthetic-integration" of the PLVs will be the second stage of the try-in (Fig 7-85).

Under normal circumstances, the veneers should be passively seated on the teeth without any interproximal tightening. If any crowding due to tight contact exists, once it is attempted to place the adjacent veneer, it will move the other one to the side.

When such a problem arises, the lateral or protrusive shift of the prepared teeth during the provisionalization should first be evaluated. If the cause is that two PLVs are pushing each other sideways on their mesial and distal margins, a gap between the others will occur. The gap will close when a little finger-pressure is applied overthetwo veneers that resisted seating, shifting the teeth back into position and closing the gap between the adjacent veneers (Fig 7-86).

However, if this is not the case, all the other veneers will be in their natural contacts and the veneer(s) with overbuild interproximal contact areas will not be able passively to take its place. The mesial or distal marginal ridge must be adjusted to obtain that passive fit (Fig 7-87).

WWW.HIGHDENT.IR
همیار دندانسازان و دندانپزشکان

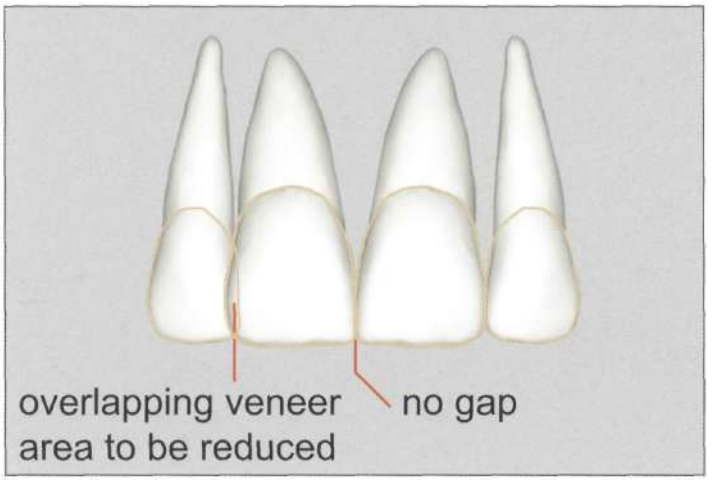

overlapping veneer \ no gap
area to be reduced

Fig 7-87 If there is no gap between the adjacent tooth exists, then the PLV should be adjusted for passive seating.

Fig 7-88 After all the veneers are seated, the color is checked. Note the color gradation effect towards the posterior. The canine has a higher chroma.

Most of the prepared teeth are actually unretentive. Therefore, holding six or eight laminates on these unretentive teeth may require a medium to provide stabilization. In order to improve this temporary adhesion and inspect the natural shade of color of the PLV, water-soluble try-in gels or transparent silicone can occasionally be used.[5]

Check the Color

After the veneers are comfortably seated, they should be checked with the shade evaluated under incandescent, fluorescent, and natural light. In order to minimize the effects of metamerism, when choosing a shade, it is best to avoid one that looks good in natural light but appears discolored in artificial light. It is better to opt for a shade that looks reasonably good in all lighting conditions. Before the actual cementation the dentist can allow the patients to moisten the ceramic and adjacent teeth with saliva and to observe themselves in a normal wall mirror for approval.[172]

The final color of the PLV will be affected by different formations and it depends on the laboratory build-up of the color of the ceramic and the color of the underlying tooth. The bonding medium that will be a luting composite may also affect the outcome, due to the thickness or color of its own.

With the advancements both in porcelain material and in the knowledge and artistic skills of the dental technicians, it is now almost possible to alter the dark color of a tooth, with a judicious ceramic build-up, using opaque or translucent dentin and enamel powders in a very natural way (Fig 7-88) (see Chapter 10). Even though the tooth color itself has a role in reflecting its own color and thus affecting the final outcome, the major role is on the delicately layered natural looking masking effect of the PLV itself.

Altering the Color

This shows the importance of reporting the stump shade guide to the lab. It is also very difficult to change the color of the veneer with a thin layer of luting composite. However, some authors[61] alternatively suggest, that a few coats of die spacing should be applied; in order to permit flexible chairside adjustment of value, chroma and to some extent the opacity, thus allowing the colorshift. On the other hand, research showsthat the thinner the distance between the tooth and the veneer, the better the adhesion and longevity of the PLV.

Additionally, in such instances, the greater the amount of luting resin that is incorporated into the bonding stage, the more polymerization shrinkage will occur that may also lead to marginal leakage.

WWW.HIGHDENT.IR
همیار دندانسازان و دندانپزشکان

If the dentist has hesitations about the final colorand prefers to use this technique,the choice should be low saturation and opacity. The higher these two factors, the more this layer will act as a barrier to reflect light transmission and hence affect the final color, with unacceptable results. In other words, it may be more advantageous to finish the PLV lighter in color (high value), so that its value can therefore be more easily lowered by the underlying composite. In contrast, it will always be more difficult to lighten a darker colored PLV.

The color of the polymerized luting resin may not always match the color seen when water-soluble, noncuring try-in paste other than transparent is used to visualize the outcome. This phenomenon may take place for several reasons.

The first possibility is that the shade of the try-in paste and the corresponding luting resin are not a precise match. It is also possible that the shade of the luting resin may change after curing or that the cured resin gradually changes over a period of time. One way to minimize this is to bench-cure samples of each luting resin, to place them in water and to note any changes.[96] These notes can help predict the eventual appearance of the final restoration at the time of try-in. It can be assumed that the restoration will be similarly affected if the chosen shade of uncured luting agent or try-in paste is lower in value than the corresponding cured sample and therefore the necessary compensation should be considered. However, to make a reasonable assessment, other factors such as the degree of opacity of the porcelain, the thickness of the luting agent layer and the metameric influence of the porcelain and dentin should be considered.

If the technician realizes that they cannot alter the color ofthedarktooth with the veneer that they will be producing, or if there are a few spots on a tooth differently colored than the rest of the teeth (see Chapter 13), then instead of trying to compensate for this at the bonding stage; it is always better to block the dark discoloration of the prepared tooth with the help of an opaque composite at the time of tooth preparation and before impression making. This will not only substantially minimize the shrinkage problem of the luting cement which will be encountered during the bonding stage, but it will also ease the fabrication of the PLV, in terms of color compensation.

However, the best results are obtained by careful tooth preparation, and good communication with the lab. Consequently, a skillful technician will always be able to obtain the right color match. In such cases, trying the veneers in with water or saliva, or in other words anything transparent, will enable us to predict the outcome in a more reliable way. When it comes to the bonding of these PLVs, in order to augment the light transmission at the interface, the most translucent composite available should be used. A much more natural appearance will be achieved as this transparent layer will transmit light in all directions.[5]

Bonding

Composite resin, acid etched porcelain and etched enamel have been proven in vitro studies to derive from a strong, durable complex (Fig 7–89).46,294

The porcelain veneer technique is used to change the color or form of the anterior teeth by bonding a thin porcelain laminate to the tooth surface using an adhesive and luting composite. Therefore, the strength and durability of the bond between the tooth, the veneer and the luting composite is what actually determines the success of the PLV treatment.

In this process of ceramic restoration, the calcified dental tissue, the ceramic and the bonding materials are the three main components, along with the interface between the bonding agent and the ceramics. This well structured ensemble is able to withstand the forces of mechanical stress (knock or mechanical fatigue), thermal stress (mechanical fatigue) or hydric stress (infiltration and sorption) existing in the oral environment.[295]

Chemically, tooth material, ceramic restorations, and composite luting resins are very different materials. A tooth consists of enamel (86% hydroxyapatite, 12% water);[296] dentin (45%

WWW.HIGHDENT.IR
همیار دندانسازان و دندانپزشکان

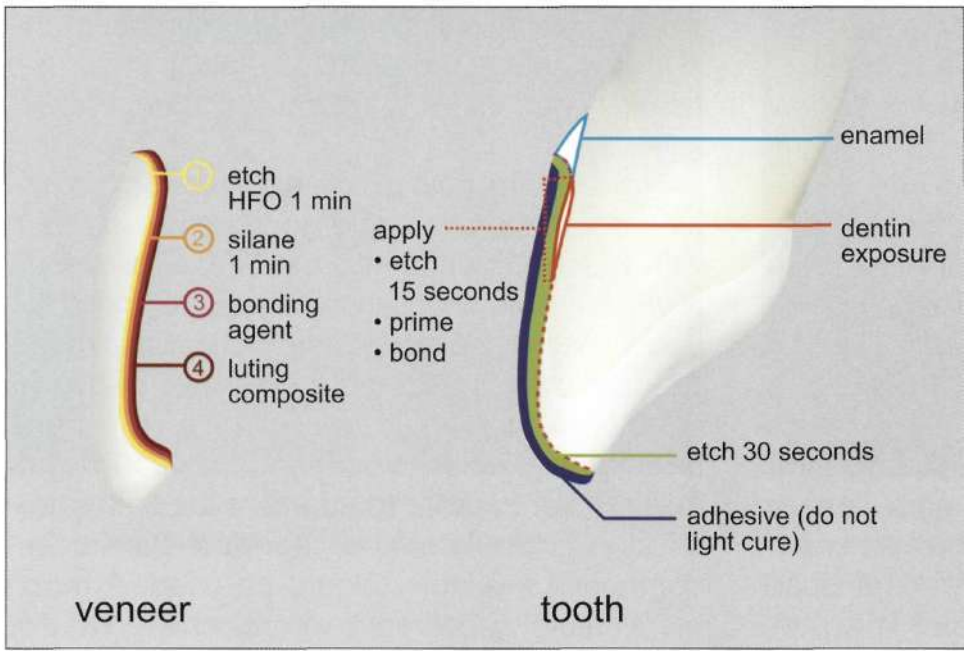

Fig 7-89 Steps for treating the inside of the PLV and the tooth surface just before bonding.

hydroxyapatite, 30% primarily collagen network, 25% water),[296] the pulp and other structures. Ceramic restorations are purely inorganic.[297] Composites have an organic matrix and inorganic fillers.[298] The composition of these materials explains why it is difficult or impossible to obtain a bond with a direct chemical reaction. *Buonocore's* idea of creating a micro etch pattern by using the acid-etch technique was completely new in 1955.[299] By means of a micro mechanic interlocking, a bond of 20 Mpa was obtained between composite luting resins and purely inorganic enamel.[300,301]The bond strength to etched and silanated ceramics is even as high as 45 Mpa.[302] These bond strength values are high enough to resist tensile and shear forces that are generated by thermal expansion or by shrinkage during the polymerization of composites.[303] To bond the PLV, on the chairside, the inside of the veneer and the tooth surface, have to be treated separately.

Treating the Interior PLV Surface

Acid Etching

Early research indicated that it was possible to chemically bond silica to acrylic or bis-GMA using a silane coupling agent.[304] It was discovered that no bond formed between the glazed porcelain and composite resin, even with silane[305,306] unless the surface was first roughened.[307] These studies done in the early 1980s proved that surface micropores similar to those found on etched tooth enamel are formed under the influence of hydrofluoric acid.[325] Aluminous ceramics apart, this phenomenon occurs because selective silicate compounds are dissolved from the surface.[307308] An additional property of the hydrofluoric compound is the surface activation of ceramic materials.

Once the PLV fabrication is finished at the lab, the inside of the veneers should be sand blasted and acid etched with a 10% hydrofluoric acid and then sent to the clinic. This preparation can also be made by the practitioner, just before bonding, after taking the necessary precautions for the use of hydrofluoric acid (Fig 7-90). The hydrofluoric acid on its own or together with the sand blasting will enhance the micro retention of the internal surface of the PLV. However, this technique can

WWW.HIGHDENT.IR
همیار دندانسازان و دندانپزشکان

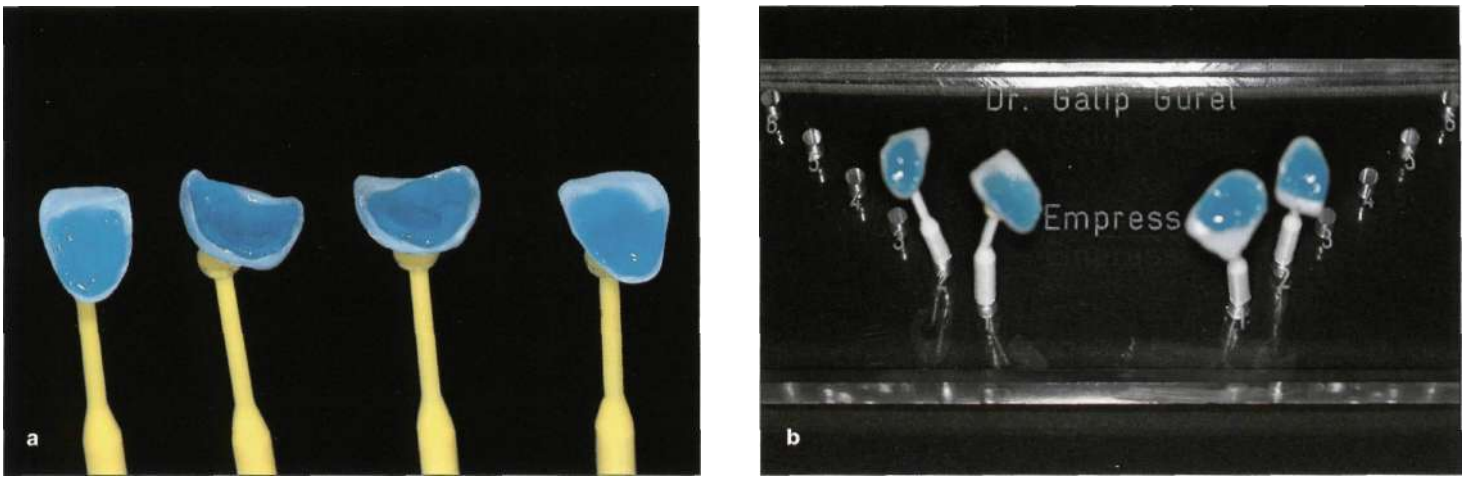

Fig 7-90a, b (a) The veneer should be acid etched with HFA either in the lab or at the chairside after the try-in. Seating veneers on the sticky poles will ease the application of etch, prime and bond, (b) APIexiglasstand designed by the author. It facilitates the positioning of the PLVsto prevent confusion, especially for the mandibular teeth.

cause abrasion of the ceramics during the silicoating process that uses airborne particles, and is therefore not recommended, despite its superior bonding strength.[310]

The cohesive strength of the porcelain itself, or that of the bond strength of a luting composite to etched enamel, has been surpassed by the bond strength of a luting composite to the etched porcelain surface which is prepared by etching the inner side of the porcelain veneer with hydrofluoric acid followed by silanizing the etched surface.[46,311-313] Some sort of anchoring is established when etching the inner side of the porcelain veneer with hydrofluoric acid, that creates a relief at the surface of the ceramic with a retentive etch pattern.[312,313] Micro-mechanical interlocking of the resin composite is made possible by the microporositesthat have been created on the internal surface area for bonding. The bond strength of the resin composite to the etched porcelain and the micro-morphology of each pattern is determined by the concentration of the etching liquid, the duration of etching, the fabrication method of the porcelain restoration[307,313] and the type of porcelain that is used.[314]

Checking the Etched Surface

After the inside of the PLVs has been etched and 1 to 4 minutes has passed (depending on the concentration of the etch liquid, fabrication of the porcelain restoration), the inside of PLV should be rinsed with a sufficient amount of water. The display of the inside of the PLV should be opaque over the entire surface. If there is, any place that displays a less opaque appearance, than that area should be etched again and the same check should be repeated in that area. A way to check the etched surface is to place a drop of water into the etched surface. If the surface is etched completely, the water will spread all over the internal surface. The cleaning process of the porcelain is aided by the increased wettability of the etched surface (Fig 7-91).[315]

There is no doubt that etching greatly increases the bond shear strength[316] of the porcelain, which is an advantage in that its strength does not diminish over extended periods of time and even surpasses the resin enamel bond strength.[317]

Preparing the Surface

The internal surface of the PLV should be thoroughly rinsed and cleansed after the try-in. To remove any salts from the etching process, the

WWW.HIGHDENT.IR
همیار دندانسازان و دندانپزشکان

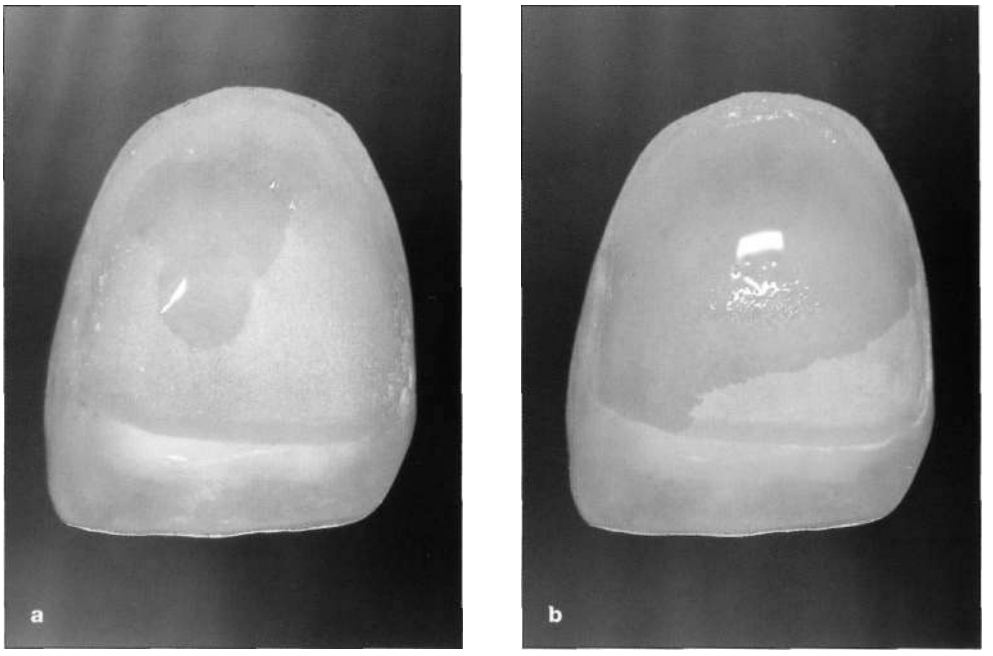

Fig 7-91a, b (a) If a drop of water is placed on the unetched interior surface of the PLV, it will not spread and stays localized, (b) However, when the same amount of water is dropped on the same PLV surface after it has been etched, it will spread over the whole surface.

etched area should be gently rubbed with a wet, cotton pellet and then cleaned with alcohol or acetone to remove any saliva or fingerprint contamination.

Water sorption,[314] fatique[318] and thermocyling,[319] are external factors that have a negative influence on the bond strength of resin composite to a pre-treated ceramic restoration after they are bonded. However, before the bonding process, contamination of the pre-treated surface with die stone,[320] latex gloves,[321] saliva[317,319] silicone-based fit checker paste[322] and try-in paste will also decrease the bond strength. In order to restore the original bond strength several cleaning methods are proposed.[320] Once the inside of the porcelain is contaminated with a try-in gel, cleaning the surfaces with acetone will not suffice. This can only be cleaned with re-acid-etching. However, a study reported that after chemical contamination bonding strength could not be restored.[322]

Re-etching the Surface After Try-In

If the etched surface of the PLV is contaminated with saliva, the surface should be restored with a 15 second application of 37% phosphoric acid.[52] However, it is betterto avoid, any other contamination after this stage.

The best result is achieved when the 10% hydrofluoric acid treatment with an etching time of 60 seconds, is done after the try-in. This will minimize the contamination of the acid etched surface, and hence increase the bond strengths. If this technique is used, there will be no need to furtheracid etch the surface with phosphoric acid. However, if the surface has already been HFA etched at the laboratory prior to try-in, then the interior surface of the PLV should now be covered with 30% phosphoric acid, rinsed and dried. The phosphoric acid will not enhance the micromechanical retentive areas, but rather alter the surface chemistry to make the silane more effective .

WWW.HIGHDENT.IR
همیار دندانسازان و دندانپزشکان

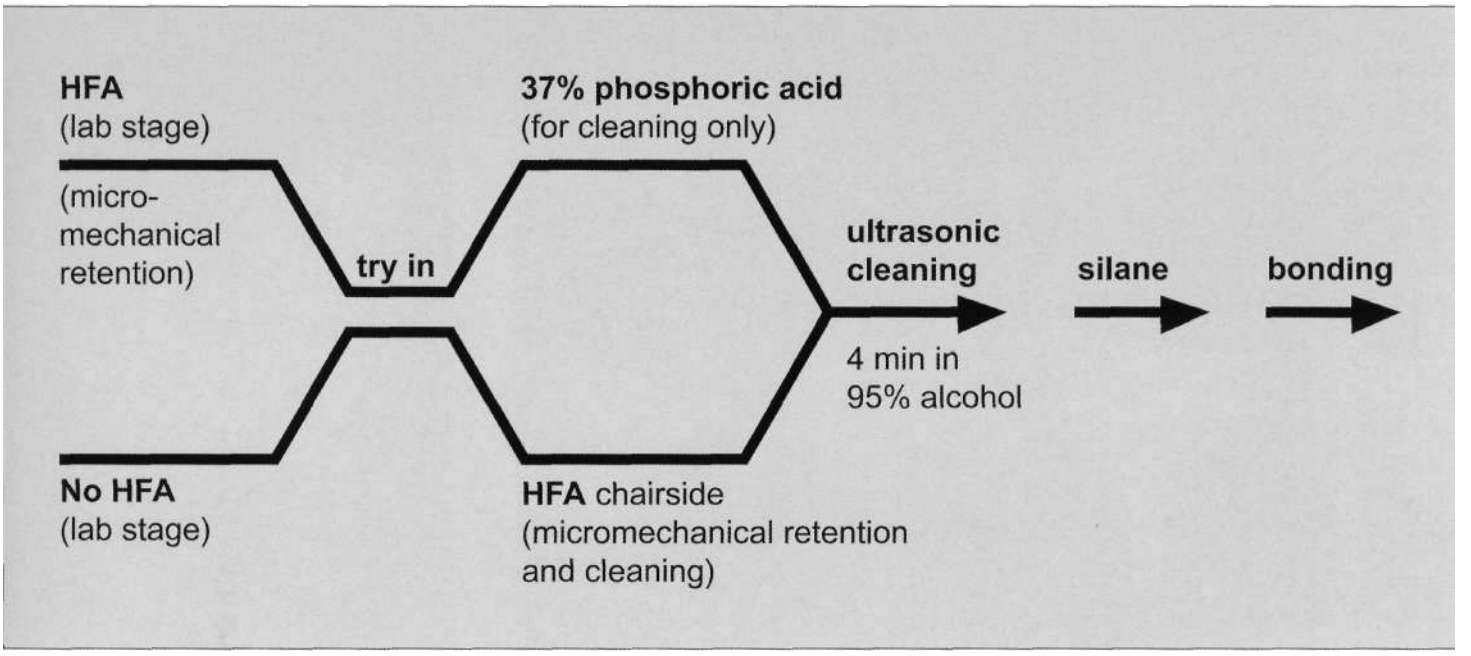

Fig 7-92 During the surface treatment of the inside of the porcelain laminate veneer, application of HFA (hydrofluoric acit) will create the micromechanical retentive surface which will enhance the bond strength. The chairside application of the 37% phosphoric acid, however, will only help to cleanse the contaminated interior surface of the porcelain laminate veneer.

Ultrasonic Cleaning

After acid etching the surface is rinsed and dried, however, SEM studies showed that, even after the etched surface is rinsed with copious amounts of water, a great number of acid crystals still stay deposited on the etched surface that may affect the bonding strength. In order to eliminate this, the veneers should be placed into the ultrasonic cleaner. All residual acid and dissolved debris can be removed from the surface of etched porcelain with an ultrasonic cleaning in 95% alcohol for 4 minutes, or acetone or distilled water. Remineralized salts seen as white residue or deposit[323] must not remain due to inadequate rinsing.[37] Many authors[111,324] agree that the immersion of the etched porcelain in an ultrasonic bath creates the best surface that allows penetrability. However, some have observed[326] no significant differences in surface morphology and bond strength between the hydrofluoric acid etched feldspathic porcelain and that without ultrasonic cleaning.

Silane Application

The bond sheer strength that has been improved from the average 600s to 3000 Mpa by acid etching can further be increased with the silane coupling agent application. The results of the following research best demonstrate the enhanced bond shear strengths when the internal surface of the porcelain is treated with both acid-etching and silane (Fig 7-92). The silane-coupling agent is the second component of the classic conditioning methods for ceramic restoration.[194] Silanizing etched ceramics and their major contribution to restoration techniques has been confirmed by many investigations. This coupling agent makes the retention of the bonded ceramic joints possible with its high wettability and its chemical contribution to adhesion.[295]

Technique

When the inside of the veneer is ready to receive the silane treatment to create a chemical link between the bonding composite and the ceramic, a fine layer of a silane coupling agent is painted over the internal surface of the laminate veneer

WWW.HIGHDENT.IR
همیار دندانسازان و دندانپزشکان

Figs 7-93a and b (a) Silane is applied overthe etched surface to increase the bond strength, (b) After a minute the silane is dried with a warm hair dryer to double the bonding effect. A salty-looking appearance should be observed. Once the silane is dried out, the choice of adhesive is applied overthe whole interior surface. However, it should not be light cured at this stage but kept in the dark. (Note the yellow color of the tip of the stick, showing through the very thin PLV.)

after it comes out of the ultrasonic cleaner. In the porcelain laminate veneer and the composite resin matrix, it is believed that silanization of the etched porcelain with a bi-functional agent provides chemically bonding to the silica. The silane group bonds to the hydrolyzed silicone dioxide copolymerising with the adhesive resin.[170]

The resin can better wet the surface , as scanning electron micrographs reveal. The silane eliminates the polymerization contraction gap, which forms in etched, nonsilanated and unetched-silanated restorations.[317] The silane is allowed to remain in contact with the etched porcelain for one minute (Fig 7-93). At the end of that time it is dried with an air syringe by blowing the air parallel to and slightly above the veneer and thus allowing the solvent to evaporate completely. At this stage, it has been reported that drying the inside of the veneer, with "warm air" (possibly with asmall hair dryer) will enhance the effect of the silane. When the silane-coated porcelain is heated to 100°C it results in bond strength double that of the porcelain where no heat was used.[314]

The numerous silane-coupling agents that exist increase the shear strength of the porcelain to composite resin bond. Single component systems that contain silane in alcohol or acetone are the simplest ways to silanate. However, with 2-component silane systems the two solutions that are mixed with an aqueous acid solution in order to hydrolyze the silane will polymerize to an unreactive polysiloxane and therefore it must be used within a few hours.[150]

Adhesive Application

Once a dry surface is obtained after silanization, the adhesive of choice is applied insidethe veneer with the help of a brush or a small cotton pellet. In principle, this could be done in a synchronized manner with the dental assistant while the dentist is applying the adhesive over the tooth surface. The adhesive should be compatible with the composite that is being used as a luting agent. At this stage, the adhesive should not be light cured.

As soon as the bonding is applied, the transparent composite luting agent is preferably placed inside the veneer. If color problems exist,

WWW.HIGHDENT.IR
همیار دندانسازان و دندانپزشکان

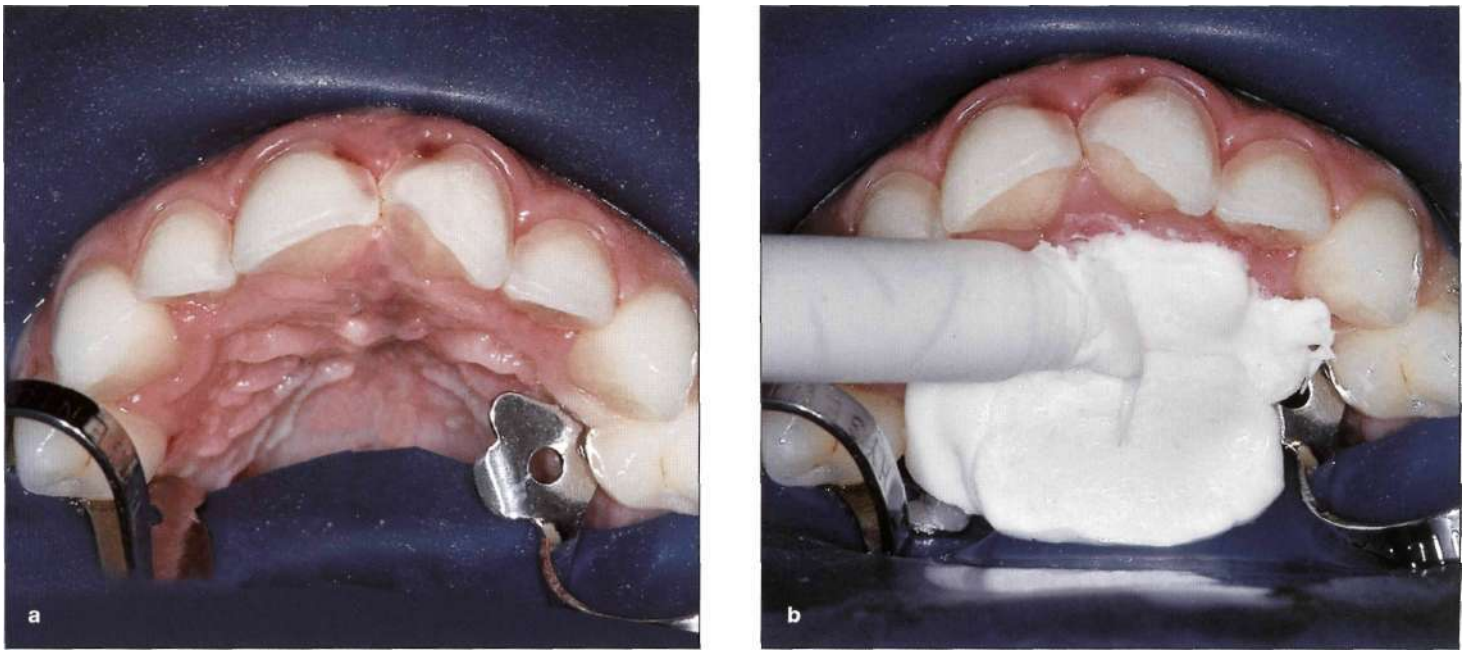

Fig 7-94a, b (a) The sectional rubber dam is applied, clamps are placed on the maxillary molars first, and the rubber dam is seated over them, (b) To provide a complete seal vanilla mousse is applied on the palatinal opening.

predetermined colored composites are used at the try-in stage, and actually, in most cases, light cured composites are used.

If the luting agent has been placed inside the veneer far before the adhesive application to the tooth surface for bonding, than the veneer and the applied luting cement should be kept in an absolutely dark place, to prevent premature light activated polymerization.

Treating the Tooth Surface

The other part of preparation in this process to achieve maximum bonding is the tooth surface. Luting procedures require meticulous attention to every detail. Even though different protocols have been proposed[326"328] if the basic steps are followed properly, the luting procedure becomes quite simple. Since the bonding will primarily depend on adhesion, great care must be taken to work under the cleanest conditions. The area should definitely be kept clean and purified of blood, saliva or oral contaminants (Fig 7-94).

Rubber Dam

A partially sectioned rubber dam application is preferred while bonding the veneers. It acts as a physical barrier to oral fluids, moisture, tongue and cheek movements so that we can manipulate easily in the oral cavity.

It has a good control of the ambient oral humidity thus increasing bonding strengths. Even though the hydrophilic primers like humidity, the hydrophobic adhesives don't. Besides, any kind of contamination of teeth distorts bonding strengths.

This contamination can be avoided with cotton rolls when dealing with a few teeth, but using the rubber dam is so practical and safer. It will prevent inhaling or swallowing dental chemicals.

Cleaning the Surface

The tooth has to be thoroughly cleansed before and after the try-in stage. The water-soluble try-in gels or the temporary cement over the prepared tooth surface should be totally removed. If the

WWW.HIGHDENT.IR
همیار دندانسازان و دندانپزشکان

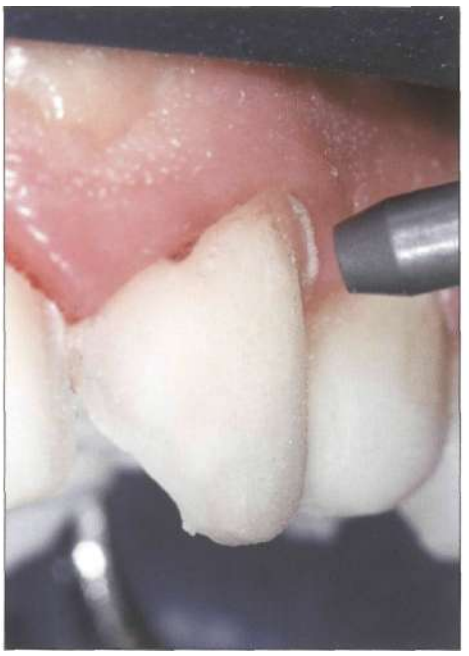

Fig 7-95 The surface is best cleaned with co-jet (Espe). The 30-micron thickness of the material will still let the 80-microns of the adhesive (Optibond) that has been applied at the preparation stage stay in place. Care should be taken not to cause any bleeding of the gingiva.

Fig 7-96a, b (a) The gingiva can easily be recontoured with a diode laser (Biolase), if needed. Note the mesiogingival tissue grown over the tooth due to a small marginal opening on the provisional, (b) The condition of the tissue seconds after laser application

dentin is not sealed at the time of preparation, the whole dentin bonding procedure should be carried out in this appointment. The use of pumice slurry in a prophy cup is to be the procedure for cleaning the teeth prior to etching or prior to conventional cementation of an indirect restoration.[24]

Preparing Hybridized Surface

However, the author prefers, hybridizing the exposed dentin area, just after the tooth preparation when the dentin is freshly cut. If this is the case, upon removal of the provisionals there should be no exposed dentin on the tooth surface, since it has already been sealed with the dentin-bonding agent. Priorto the actual bonding of the PLVs, this surface can either be gently cleansed and roughened with a diamond fissure bur, or even better, sand blasted with air abrasion (Fig 7-95). 30-micron thick particles will only be able to clean the surface of already bonded 80-micron adhesive (Optibond Kerr). If the provisional is bonded to the tooth with the spot etching method, the point or small area which has been spot etched, should be plotted. The remaining bonding agent on this spot of enamel should be very gently removed with the help of a diamond bur in order to obtain a clean surface for enamel etching.

The tooth surface can then be acid etched with 30%-40% of phosphoric acid, to further cleanse the dentin bonding agent and create micromechanical retention on the enamel surface (see Chapter 3).

Lazing the Tissue

Sometimes the tissue may bleed shortly after the sandblasting or the tissue might have grown over the prepared margin due to a small gap left on the provisional. At this stage, it is best to stop the bleeding with a diode laser (Biolaze). This will immediately stop the bleeding with a highly accurate control of the soft tissue contours (Fig 7-96).

WWW.HIGHDENT.IR
همیار دندانسازان و دندانپزشکان

Preparing the Exposed Dentin

However, some dentists may prefer hybridizing the dentin surface at the time of bonding. In other words, dentin etching, priming and application of the adhesive will all be conducted at this appointment, just before the PLV is bonded. In such a case the temporary cement and polluted dentin are best-removed aggressively with brushes and fluoride-free pumice or air-abrasion.329,330 Current thought suggests that reduced sensitivity by eliminating or minimizing bacterial growth under restorations can be achieved by combining the cleaning step with disinfecting the cavity. Bacteria reaching the pulp can cause sensitivity. Although many may disagree, and although it has not been proven, itisstillthoughttobebesttouse a disinfectant to clean the cavity prior to the restoration.

The recommended agent for disinfecting the teeth was benzalkonium chloride (BAC) mixed with EDTA, at the time when the concept of disinfecting teeth was originally proposed by *Brannstrom.* Its purpose was to disinfect and partially remove the smear layer. The current product contains the primary active ingredients of either BAC or 2% chlorhexidine gluconate.

Cleaning

Until the preparation is visibly clean, it should be scrubbed. Antibacterial solution (Tubulicid Red, Global Dental Products, Inc., Consepsis, Ultradent Products, Inc.) is then applied over the etched surface to act as a wetting agent and to decrease bacterial concentration, without having a negative effect to the bond strength.[331] Before placing an adhesive that bonds to the mist/wet tooth structure, these products have also been used to re moisten/re wet the cavity. A residual antibacterial effect can presumably help reduce bacterial ingress because of microleakage.

However, the dentin should not be cleaned with soaps. A study shows that low shear bond strength values of the tested dentin-bonding agents may be the result of cleansing the dentin with soaps after the application of provisional cements. Therefore, it is not recommended to use soaps as a clinical means to remove remnants of provisional cements before adhesive cementation.[136]

Acid Etching Enamel

After this step, the tooth can be acid etched with 30%-40% of phosphoric acid. Gels are favored over liquids due to our ability to exercise more control over the application of a gel than a liquid. An etchant gel should also have a smooth consistency and not be jelly-like.[24]

Acid etching of enamel, which is well known[331] and causes an interprismatic and demineralization, produces adhesive profiles that are more suited to bonding.295 *J^Q* creation of a micro etch pattern is the precondition for a successful bond between a composite resin and enamel. The quality of such an etching pattern depends on the morphologic and chemical characteristics of the crystalline structure of enamel. On the other hand, the etching pattern is dependent on the type and on the concentration of the acid used at the time of etching.[136] Different acids have been described for etching the enamel, 37% phosphoric acid as a standard procedure,299 lo%maleicacid and 1.6 % oxalic acid 2.6% aluminum nitrate,[332] 10% citric acid.[333] The bond strength values obtained with acids are reported to be 40% lower when compared to the 20 MP of bond strength that can be obtained with the standard procedure etching enamel of 60 seconds with 37% phosphoric acid. If the dentin was already sealed at the time of the preparation, this etching will be useful to clean the surface of the adhesive.

Acid Etching the Dentin

Most modern dentin bonding agents use low concentration acids for etching dentin.[334] The interlocking of the bonding agents with the dentin is due to a penetration of the resin into the collagen network of the dentinal surface. This appears to be no deeperthan 6 mikrometre.[333] The duration of this application can be up to 30-40 seconds on enamel. However, it should not exceed 15 seconds on the dentin in order to prevent collagen collapse, and thus decreasing the pen-

WWW.HIGHDENT.IR
همیار دندانسازان و دندانپزشکان

Fig 7-97 37% phosphoric acid is applied on the prepared area. Since the dentin is already sealed, the etch will clean the bonded area. It will also create micromechanical porosities on the enamel. Note the transparent strip, protecting the adjacent canine.

etration of the primer into the dentinal tubule (see Chapter 3).

Etchant should be applied to enamel, keeping it off the dentin, if possible. Etching times on enamel have a wide range; anywhere from 15-60 seconds is acceptable. Whatever the duration for enamel etching that is chosen, the etchant is spread over the dentin with a disposable brush, forthe last 15 seconds. Once the etchant is spread over the dentin, an immediate 15 seconds is timed. During this time, the etchant can be further pushed into the restricted areas of the preparation surface, such as the deeply prepared gingivoproximal areas just to make sure the entire preparation is properly coated with etchant. The air-water syringe and suction is kept ready to go. As soon as the 15 seconds is up, the surface is rinsed for as long as is recommended by the manufacturers (Fig 7-97).

Adhesive Application

While the bonding of composite to etched enamel has been clinically proven for many years, the bonding to dentin is the subject of ongoing development. The most current examples of dentin-bonding systems have demonstrated in vitro shear bond strengths that approach the tensile strength of human dentin. 179,335,336 Such a result would be desirable with use of PLVs when dentin is exposed during preparation, but there is clearly a lack of long-term clinical experience as to its success.

Then the teeth are thoroughly washed and dried. Dentin should only be blot dried with the help of a cotton pellet, in order to achieve "wet bonding".[337] The primer is applied over the exposed dentin area, left in place for 30 seconds and than very gently dried until the carrier of the primer evaporates. This time should be extended if the carrier of the primer is water based, or shortened if it is alcohol or acetone based. Preferably it should be executed with a hair-dryer, keeping in mind that, the air from the air syringe can always be contaminated with humidity or oil coming from the air compressor and thus affecting the bonding strength negatively.

Once the glossy appearance of the primer is achieved (Fig 7-98), than the adhesive can be applied on both the dentin and the enamel (Fig 7-99). The penetration of the resin into the etched enamel seems to be deeper. Enamel bondings can penetrate 15 to 50 micrometer deep into superficial enamel prisms that were etched tangentially to their longitudinal axis. If the prisms are etched perpendicularly to their longitudinal axes, the penetration will only be 5-10 mikrometre.[300] At this stage, it is important that the resin

WWW.HIGHDENT.IR
همیار دندانسازان و دندانپزشکان

Fig 7-98a, b It has been detected that there is still some dentin exposure on the cervical margin of the lateral, (a) Once the surface is etched, it is blot dried and (b) primer is painted on the exposed dentin area only.

Fig 7-99 After the carrier of the primer has evaporated, adhesive is placed over the whole prepared surface with a brush, giving it a shiny appearance. It is important that the adhesive is not light cured at this time.

should not be light cured until the veneer is seated over the tooth.

Bonding

After the tooth surface and the internal surface of the PLV are prepared, the PLV can be bonded to the tooth surface. A light-curing luting composite is preferred for cementation of porcelain veneers[37] A longer working time compared with dual cure or chemically curing materials is the major advantage of light curing.

In this way the dentist can remove excess composite priorto curing, considerably shortening the finishing time required for these restorations. In comparison to dual-cured or chemical-cured systems, their color stability is superior. The thickness and the opacity of the ceramic[338] affectsthe transmission of light and consequent micro hardness of the composite.[338,340,342] Although the usual ceramic thickness for the PLV of 0.5- 1.0 mm has no significant influence on the hardness of light-cured composite[343] the use of a dual-cure composite might be preferable in certain cases.[342] As mentioned before, if no color adjustments are needed, atransparent luting compositeshould be the choice. A light-curing agent should be chosen that is filled in orderto increase the resistance and optimizethe durability of the bonded joint. In order to obtain wettability of the two substrates, and more particularly of the ceramic, the bonding agent used must not be too viscous. The resin is applied with a brush to the inner part of the restoration. In case a highly filled composite luting agent that is slightly more viscous is being used (i.e. Herculite translucent), it is better to use a spatula to place it inside the restoration.

Technique

When bonding the veneers one by one or as pairs, it is always better to place the luting resin inside the veneer to ease the control. A brush can be used to evenly distribute the composite inside the veneer.

Theveneershould be positioned overthetooth very gently and slowly. The author prefers inserting the veneer starting from the incisal edge, and progressively pushing the veneer towards the gingivoapical direction (Fig 7-100). This is one of the best ways of avoiding the formation of voids

WWW.HIGHDENT.IR
همیار دندانسازان و دندانپزشکان

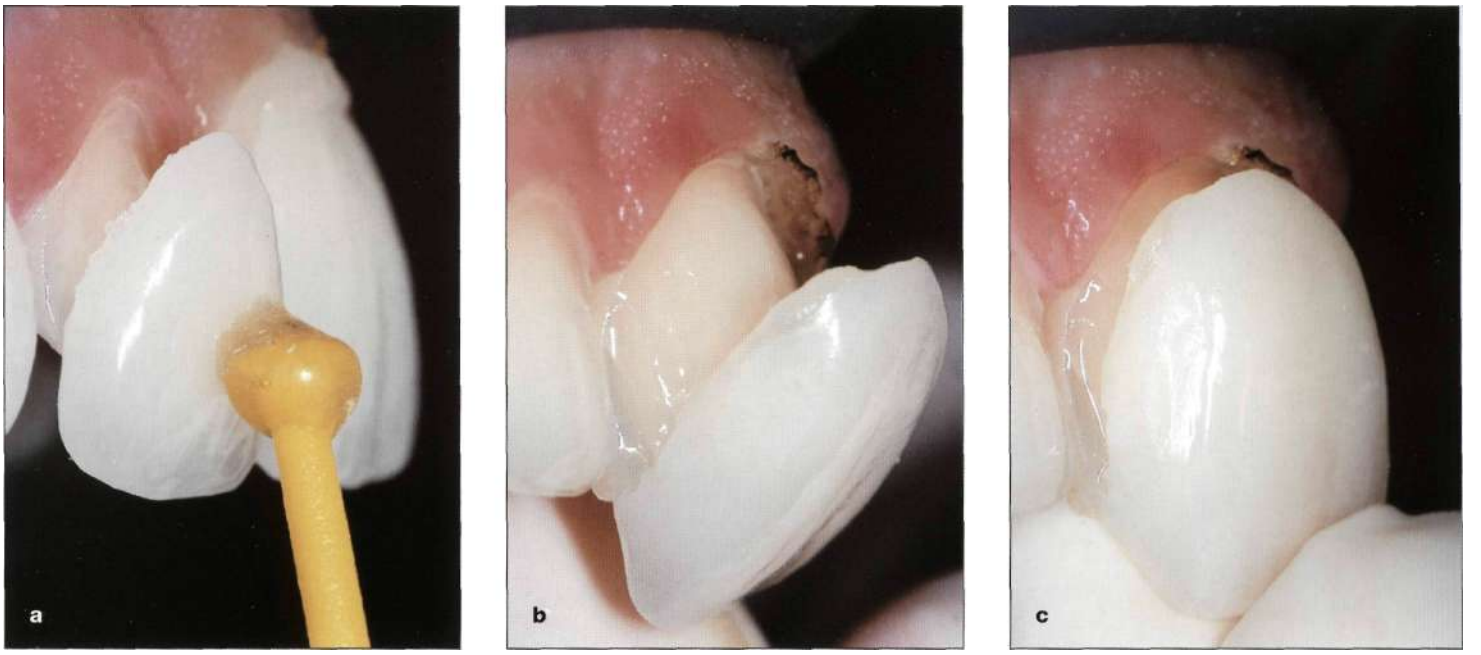

Fig 7-100a-c (a) After the inside of the veneer is loaded **with** the translucent luting resin (Herculite, Translucent, Kerr), it is brought next to the tooth with the sticky pole, (b) Once slightly seated from the incisal comer (c) it is then pushed apically and palatally with gentle finger pressure. The excess luting resin should be seen on all the margins, confirming that enough material is used.

between the tooth porcelain interfaces. It is also very critical that the dentist must observe the luting resin flash coming out from all the margins, indicating that enough luting material is applied precluding any air residue of air inclusions in the bonding agent.[344]-[345]

Several significant developments have been achieved in adhesive luting procedures. Of clinical relevance, is the use of ultrasonic energy to assist the placement of the restoration when highlyfilled luting cement is used.[346]The easy removal of the excess cement with the low viscosity luting resins can also be achieved with these highly filled resins. Even though they have a higher filler load, they have been successfully utilized for many years for the cementation of PLVs.[347] One of the advantages of these resins is their low wear rate. Once the translucent resin with medium viscosity is used, these materials appear to be particularly beneficial, since it provides extended working time and more precision and stability in positioning the restoration.[348] Due to the thixotrophic nature of such resins (Herculite, or Z 100), the veneer will not bounce off the tooth even if gentle finger pressure is released.

However, it is better to keep the veneer seated on the tooth with some sort of gentle pressure, either with the fingertips or with the help of instruments. The pressure should be spread evenly over the entire labial surface. The fingertip is more sensitive and therefore serves better than any instrument in judging the pressure level required.[213] It should be very carefully checked in terms of marginal fit, property seating and its relation with the adjacent PLV or intact tooth. Application of an apically directed pressure on the incisal edge with the help of a second finger will ensure that the PLV will have full contact with the tooth in the cervical area.

Even though the marginal fit was clarified during the try-in stage, sometimes the limited time due to the quick polymerization period of the luting resin may create mental pressure on the dentist. The desire to seat the veneers as quickly as possible may cause some problems in terms of not actually being able successfully to seat the veneers as they should have been and thus ending up with open margins. This is especially a problem for beginners.

WWW.HIGHDENT.IR
همیار دندانسازان و دندانپزشکان

Fig 7-101 When the veneers are completely seated they are spot tacked with a 2 mm turbo tip (Optilux 501, Kerr) centered at the middle 1/3rd. Note the still soft condition of the nonpolymerized luting agent around the margins.

Fig 7-102 After 1-2 seconds of light curing with the 13 mm-diameter curing tip. The excess luting resin that came out of the margins has a jelly consistency and can easily be cleaned with an explorer and brush dipped in a bonding agent.

Seating the Veneers

The author prefers bonding the veneers two by two. This technique does not only ease the control over bonding but ensures that the veneers are seated completely and correctly, without the possibility of inadvertent polymerization due to excess bonding or the chance of luting resin getting on the adjacent preparation priorto veneer placement which would result in an incomplete seating. This will minimize placement challenges and time expenditure while optimizing the results.[349] However, some practitioners prefer bonding them all at once. In doing so, the dentist and theirteam must be very experienced in using this technique.

Diverting the operatory light from the preparations will eliminate inadvertent polymerization of the adhesive before veneer placement. The veneers are tacked into place after the seating is completed usingthe2.0mmturbotip lightguides (Optilux501)(Fig 7-101).Thetipshould be placed centrally at the middle 1/3rd. of the veneer. To provide an inward/upward directed pressure and to ensure complete seating while eliminating hydraulic pressure from lifting the veneer off the preparation, finger pressure o blunt instruments are applied at the incisal edge and gingival margin. Spot tacking the veneer into place will act like an anchorthat will completely stabilize the veneer in its final seated position.

At this stage, the important aspect is that the composite flash that came out from the margins is still soft in nature.

The second stage will be applying the curing light with a 13.0 mm tip over the margins for only a few seconds. This is very important, since this makes the excess composite partially polymerize into a jelly consistency which can then be easily removed without injuring the soft tissues, while at the same time minimizing the post-bonding finishing and polishing procedures (Fig 7-102).

The further removal of the excess of nonpolymerized composite cement should be carried out with a brush moistened with bonding resin. This will reduce the tendency of the resin to drag out of the marginal gap and ensure a smoother margin that is polishable.[350] Meanwhile the interdental contact areas and the gingivoproximal

WWW.HIGHDENT.IR
همیار دندانسازان و دندانپزشکان

Fig 7-103 Before the luting resin is completely polymerized the interdental contact areas and gingival embrasures are cleaned with the help of dental floss. During this procedure the veneers should be held in place with the help of finger pressure.

Fig 7-104 The luting agent is completely polymerized with a 13 mm-diameter curing tip (Optilux 501, Kerr) from both palatinal and facial 60 seconds each. The light should be applied to different areas from different angles to avoid overheating of the tooth, thus preventing postoperative pulpal sensitivity.

corners should be gently cleaned with the help of dental floss. The rubbing motion should preferably be towards the palatinal in order to prevent dislodgement of the veneer from its tacked position (Fig 7-103).

Light Curing

The resin is photo polymerized intensely after any excess is removed (Fig 7-104). If the maximum light energy is applied,[172] the quality of polymerization will be superior. The porcelain veneer absorbs between 40-50% of the emitted light. There may be two reasons for prevention of light transmission through the porcelain. One may be the thickness of the material. However, the opacity of the porcelain veneer becomes more important during the photopolimerization. Whatever may be the cause, when PLV retards light transmission, the setting time of the luting resin composite must be increased.[339-343] Some authors even suggest to double the recommended exposure time.

Light cured resin composites do not reach their maximum hardness, in the case of porcelain with a thickness of more than *0.7* mm or when the surface is opaqued excessively.[342] In these situations it is advisable to use a dual-cured luting composite, which contains the initiation systems for both chemically and light-cured composites. A stronger bond can be obtained with the porcelain[351] using the latter luting agents. Due to their higher degree of polymerization, higher values of hardness were reported for the dual-cure resin cements than that for the light-cured luting cements.[342-366]

To avoid the development of an oxygen-inhibited layer at the margins, an oxygen inhibition material, such as deox (Ultradent) or glycerin, should be applied prior to the final polymerization (Fig 7-105). Then each tooth's veneer is light polymerized for 60 to 90 seconds on all surfaces.

Once all the veneers are completely bonded, the rubber dam is removed and now the occlusion and protrusive contacts can betruly checked. Interfering contacts during occlusal closure, as well as the anterior and canine guidance should clearly be adjusted, if necessary. Meanwhile; the silicon index that was used since the beginning of the treatment, is used again over the bonded veneers, to verify theirfacial/outcomes (thickness and volumes) (Fig 7-106). The patient is allowed to see the result in front of a big mirror, so that they are able to see the veneers as well as their integration with the lips and the face as a whole.

An instruction sheet should be given to the patient, explaining the do's and don'ts forthe next 48 hours, as well as for the future.

WWW.HIGHDENT.IR
همیار دندانسازان و دندانپزشکان

Fig 7-105 Deox (Ultradent) is applied over the margins to prevent an oxygen-inhibition layer and continued light curing.

Fig 7-106 The final outcome is double-checked with the silicone index. Notice the precision of the volumetric PLV fit.

Do's

- Use a soft toothbrush with rounded bristles, and floss as you do with natural teeth.
- Use a less abrasive toothpaste and one that is not highly fluoridated.
- Use a soft acrylic mouth guard when involved in any form of contact sport.
- Ensure routine cleaning.

Don'ts

- Avoid food or drinks that may contain coloring.
- Do not use alcohol and some medicated mouthwashes because they have the potential to affect the resin bonding material during the early phase (the first 48 hours).
- Avoid hard foods, chewing on ice, eating ribs and biting hard confectionaries and candy.
- Avoid extremes in temperature.

Finishing and Polishing

Finishing and polishing the bonded veneers is extremely important, especially if special care has not been taken during the bonding stage.

During luting, prime care should be taken in order to avoid marginal discrepancies. They should have been completely filled with the luting composite. This is crucial not only for the sake of preventing the marginal leakage, but also for the ability to polish the cement layer into a smooth margin. However, some authors reported that after finishing procedures, only a small portion of the margins of each porcelain were found to have ideal marginal adaptation microscopically[352] and a considerable amount of excess luting agent at the veneer margins.[293] This can be a problem especially in the cervical regions.[353]

The finishing process of the veneer margins results in removal of the glaze from the porcelain.[315] Glaze is 25-to 100-micron melted porcelain over the porcelain surface.[297] The removal of the glaze of the porcelain restoration during finishing, with microfine finishing diamonds, causes a slight increase in surface roughness at the cervical border. The wear of the antagonistic elements and increased plaque retention along with gingival reaction will occur unless the porcelain can be polished to a smoother surface.

Even though it is claimed that it is impossible to produce a polished surface, which is equal to a glazed porcelain surface with polishing procedures, the author strictly believes in not removing the porcelain glaze at the cervical margin area.[354-355]

Most of these polishing instruments are not well suited for finishing the crucial gingival or

WWW.HIGHDENT.IR
همیار دندانسازان و دندانپزشکان

interproximal regions of a bonded veneer, however they perform satisfactorily on flat accessible surfaces at high speeds. *Haywood,* et al.[356] evaluated finishing and polishing in these crucial areas in vitro. According to these authors, using finishing grit diamonds followed by a 30-fluted carbide bur and diamond polishing paste, a finish equal or superior in smoothness to glazed porcelain was achieved. Other finishing combinations were not as smooth as glazed porcelain and produced various textures. In contrast to dry polishing, polishing under water spray produced a smoother surface for a given sequence.[357] The effect of these finishing procedures must be evaluated in vitro to assess their effect on the cervical margin of the veneer with their difficult accessibility for polishing instruments.

All of the research above actually indicates the placement of the cervical margin supragingivally, to minimize the possible postoperative problems.

If the preparation's bonding and polishing are properly done, research shows a significant amount of lower bacterial plaque formation immediately after the placement of PLVs.[167]

Postoperative Longevity

When deciding on a type of treatment, the question of longevity is an important issue to consider. The tooth is at a greater risk when the potential treatment requires destructive preparation.[172] Being one of the most minimally invasive techniques, PLV has characteristically been less destructive to the tooth.

If properly prepared, tried-in and bonded, PLVs exhibit a long life span. The durability and survival rate for the PLV seems to range from one month to ten years according to clinical reports that have been published in the last ten years. [142,166,184,358-361] In vitro studies have indicated that when enough intact tooth tissue remains to bond the porcelain veneer, and when occlusion and articulation are not pathological, porcelain veneers are strong and durable restorations.

Clinical studies confirm that the maintenance of esthetics, with porcelain veneers was highly successful in retaining color stability and surface smoothness after years of clinical functioning. Over the years, the author has not witnessed a single patient who was not satisfied with the PLVs bonded and numerous studies confirm this fact. Patient satisfaction ranged from 80-100% while some studies even reported that patient satisfaction actually increased as time passed.[179,380] This increase was explained as a reflection of the patient's continually increasing comfort duetothe PLV restorations.

The cervical preparations are usually placed supragingivally. This is beneficial for post-operative longevity. However, even if they are placed subgingivally, providing that the preparation, fitting of the PLV and bonding technique is done properly, the studies reported no changes in the health of the gingival tissues of the restored teeth.[113,142,168,363] However, forthose patients with poor oral hygiene habits, some studies reported slight gingival inflammation.[179] Most in vivo studies reported excellent marginal adaptation in a high number of restorations after several years of clinical functioning (65-98%).[168>358-361>364] SEM examinations showed that it was the wearing out of the composite luting agent and the consequent loss of bonding[315] that caused these small marginal defects. In several in vivo studies of porcelain inlays[365] a similar phenomenon was reported as submargination. Replicas of inlays and porcelain laminate veneers in addition to clinical views clearly demonstrated that it was not the bonding agents that were responsible for failure in the restoration, but the fragile nature of the porcelain itself. It is cohesive and not adhesive fractures in the ceramic that show up in the scanning electron.

As mentioned before, the ideal preparation for the PLV should be confined within the enamel margins. However, sometimes due to gingival recession or extended class V caries, the cervical margin may be placed on the dentin or cementum. Afterthe cementation of PLVthere have been rare reports of postoperative sensitivity. This may be due to sensitivity in the cervical area where the margins end in dentin and where microleakage

WWW.HIGHDENT.IR
همیار دندانسازان و دندانپزشکان

may occur. A combination of marginal integrity, the use of a new-generation dental bonding agents and a meticulous execution of the cementation procedure can helpto minimize oreven prevent this postoperative sensitivity.[5]

The reduction of microleakage of the restoration margins in dentin and enamel is possible with the application of any of the new generation of bonding agents.[5]

If a very thin PLV is placed on a tooth without a masking effect, after some time there may be a color change of the PLV, due to the biologic color alteration of an aging tooth. The darkened color of the natural tooth will reflect, through the veneer, giving the perception that the PLV has changed its color.

After all, properly diagnosed, planned and executed PLV applications have always been satisfactory. When the aesthetic perception of the dentist is enhanced with his/her up-to-date knowledge, together with the artistic skill and devotion of the ceramist, creation of a very natural-looking smile is unavoidable. When details like anterior-posterior color gradation, translucent areas of the incisors, higher chroma of the gingival 1/3rd, surface texture, luster are meticulously applied; the final outcome of the PLVs will be undetectable other than the natural teeth (Figs 7-107 to 7-110).

Fig 7-107a, b (a) The protrusive nature of tooth # 21(9) as well as the rotations on teeth 12(7) and 11(8) before the treatment, (b) The final PLVs in the mouth. Note that all the esthetic discrepancies before the treatment have been esthetically and functionally corrected.

WWW.HIGHDENT.IR
همیار دندانسازان و دندانپزشکان

interproximal regions of a bonded veneer, however they perform satisfactorily on flat accessible surfaces at high speeds. *Haywood,* et al.[356] evaluated finishing and polishing in these crucial areas in vitro. According to these authors, using finishing grit diamonds followed by a 30-fluted carbide bur and diamond polishing paste, a finish equal or superior in smoothness to glazed porcelain was achieved. Other finishing combinations were not as smooth as glazed porcelain and produced various textures. In contrast to dry polishing, polishing under water spray produced a smoother surface for a given sequence.[357] The effect of these finishing procedures must be evaluated in vitro to assess their effect on the cervical margin of the veneer with their difficult accessibility for polishing instruments.

All of the research above actually indicates the placement of the cervical margin supragingivally, to minimize the possible postoperative problems.

If the preparation's bonding and polishing are properly done, research shows a significant amount of lower bacterial plaque formation immediately after the placement of PLVs.[167]

Postoperative Longevity

When deciding on a type of treatment, the question of longevity is an important issue to consider. The tooth is at a greater risk when the potential treatment requires destructive preparation.[172] Being one of the most minimally invasive techniques, PLV has characteristically been less destructive to the tooth.

If properly prepared, tried-in and bonded, PLVs exhibit a long life span. The durability and survival rate for the PLV seems to range from one month to ten years according to clinical reports that have been published in the last ten years. [142,166,184,358-361] In vitro studies have indicated that when enough intact tooth tissue remains to bond the porcelain veneer, and when occlusion and articulation are not pathological, porcelain veneers are strong and durable restorations.

Clinical studies confirm that the maintenance of esthetics, with porcelain veneers was highly successful in retaining color stability and surface smoothness after years of clinical functioning. Over the years, the author has not witnessed a single patient who was not satisfied with the PLVs bonded and numerous studies confirm this fact. Patient satisfaction ranged from 80-100% while some studies even reported that patient satisfaction actually increased as time passed.[179-380] This increase was explained as a reflection of the patient's continually increasing comfort duetothe PLV restorations.

The cervical preparations are usually placed supragingivally. This is beneficial for post-operative longevity. However, even if they are placed subgingivally, providing that the preparation, fitting of the PLV and bonding technique is done properly, the studies reported no changes in the health of the gingival tissues of the restored teeth.[113-142-168,363] However, forthose patients with poor oral hygiene habits, some studies reported slight gingival inflammation.[179] Most in vivo studies reported excellent marginal adaptation in a high number of restorations after several years of clinical functioning (65-98%).[168,358,361,364] SEM examinations showed that it was the wearing out of the composite luting agent and the consequent loss of bonding[315] that caused these small marginal defects. In several in vivo studies of porcelain inlays[365] a similar phenomenon was reported as submargination. Replicas of inlays and porcelain laminate veneers in addition to clinical views clearly demonstrated that it was not the bonding agents that were responsible for failure in the restoration, but the fragile nature of the porcelain itself. It is cohesive and not adhesive fractures in the ceramic that show up in the scanning electron.

As mentioned before, the ideal preparation for the PLV should be confined within the enamel margins. However, sometimes due to gingival recession or extended class V caries, the cervical margin may be placed on the dentin or cementum. Afterthe cementation of PLVthere have been rare reports of postoperative sensitivity. This may be due to sensitivity in the cervical area where the margins end in dentin and where microleakage

WWW.HIGHDENT.IR
همیار دندانسازان و دندانپزشکان

may occur. A combination of marginal integrity, the use of a new-generation dental bonding agents and a meticulous execution of the cementation procedure can helpto minimize or even prevent this postoperative sensitivity.[5]

The reduction of microleakage of the restoration margins in dentin and enamel is possible with the application of any of the new generation of bonding agents.[5]

If a very thin PLV is placed on a tooth without a masking effect, after some time there may be a color change of the PLV, due to the biologic color alteration of an aging tooth. The darkened color of the natural tooth will reflect, through the veneer, giving the perception that the PLV has changed its color.

After all, properly diagnosed, planned and executed PLV applications have always been satisfactory. When the aesthetic perception of the dentist is enhanced with his/her up-to-date knowledge, together with the artistic skill and devotion of the ceramist, creation of a very natural-looking smile is unavoidable. When details like anterior-posterior color gradation, translucent areas of the incisors, higher chroma of the gingival 1/3rd, surface texture, luster are meticulously applied; the final outcome of the PLVs will be undetectable other than the natural teeth (Figs 7-107 to 7-110).

Fig 7-107a, b (a) The protrusive nature of tooth # 21(9) as well as the rotations on teeth 12(7) and 11(8) before the treatment, (b) The final PLVs in the mouth. Note that all the esthetic discrepancies before the treatment have been esthetically and functionally corrected.

WWW.HIGHDENT.IR
همیار دندانسازان و دندانپزشکان

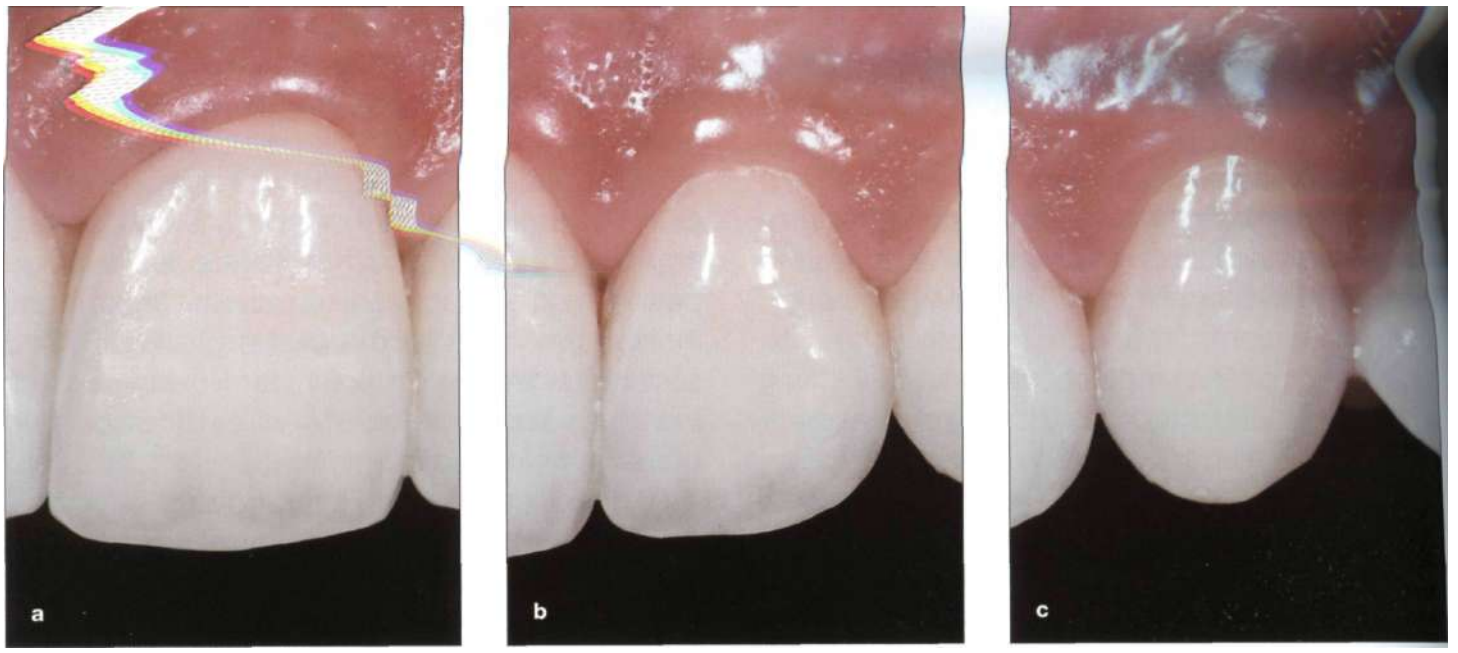

Fig 7-108a-c PLV in the mouth after a year. Note the excellent biologic integration at the cervical 1/3rd, as well as the esthetic integration of the PLVs and natural *teeth to* each other in terms *of form, texture* and color. Color gradation of every other tooth within themselves is achieved. The marginal 1/3rd, high in chroma, middle 1/3rd high in value and incisal 1/3rd with all the delicate characterizations. Also note the color gradation from anterior to posterior.

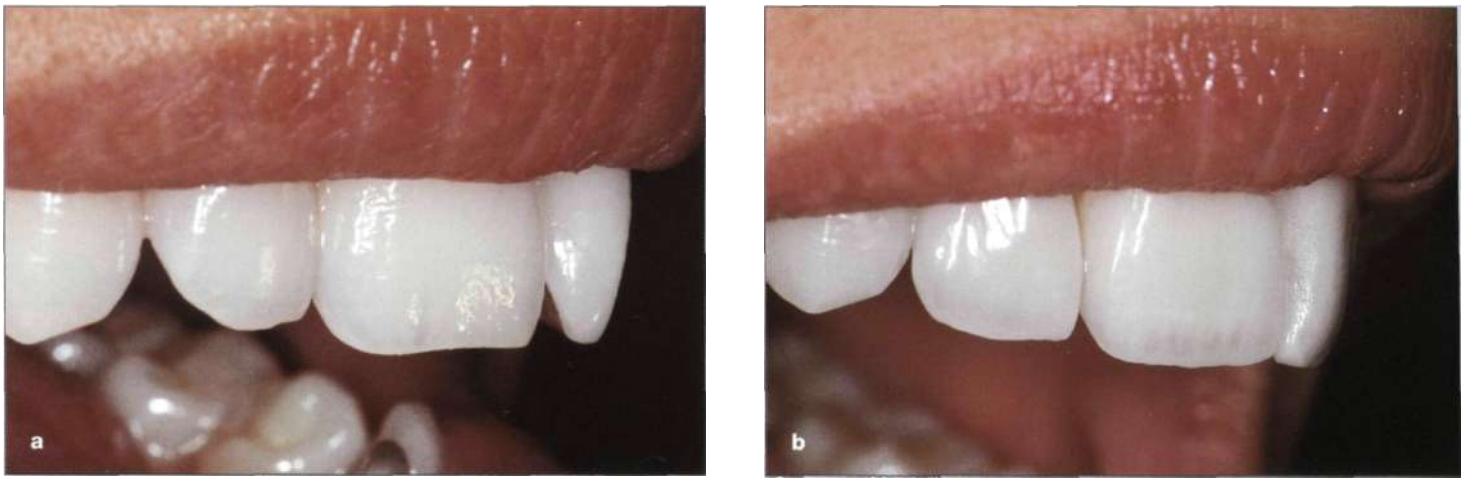

Fig 7-109a, b The harmony of the PLVs with the main frame. The PLVs should be integrated with the lips and the face. Close-up pictures (a) before (b) after. The success of such a natural-looking final restoration is due to careful diagnosis and treatment planning as well as delicate tooth preparation. Communication with the laboratory and the skilful hands of a technician complete the teamwork.

WWW.HIGHDENT.IR
همیار دندانسازان و دندانپزشکان

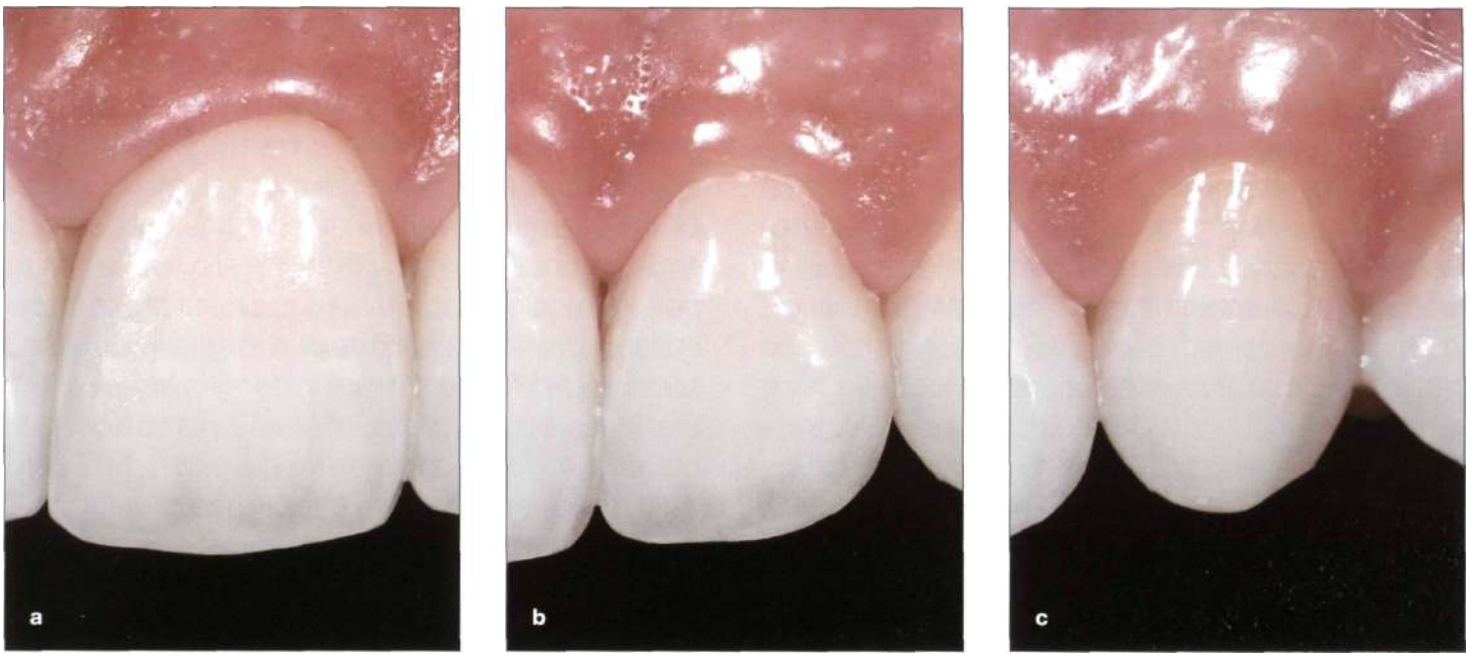

Fig 7-108a-c PLV in the mouth after a year. Note the excellent biologic integration at the cervical 1/3rd, as well as the esthetic integration of the PLVs and natural teeth to each other in terms of form, texture and color. Color gradation of every other tooth within themselves is achieved. The marginal 1/3rd, high in chroma, middle 1/3rd high in value and incisal 1/3rd with all the delicate characterizations. Also note the color gradation from anterior to posterior.

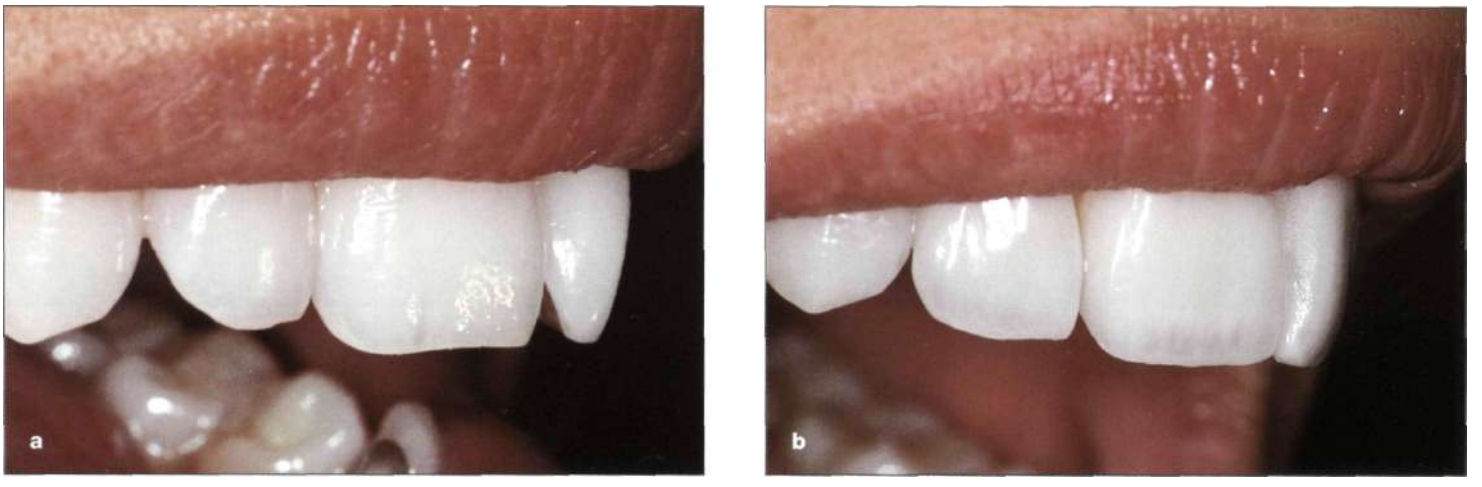

Fig 7-109a, b The harmony of the PLVs with the main frame. The PLVs should be integrated with the lips and the face. Close-up pictures (a) before (b) after. The success of such a natural-looking final restoration is due to careful diagnosis and treatment planning as well as delicate tooth preparation. Communication with the laboratory and the skilful hands of a technician complete the teamwork.

WWW.HIGHDENT.IR
همیار دندانسازان و دندانپزشکان



Fig 7-110 A beautiful smile, perfectly integrated with the lips and the face - the color of the veneers as well as the surface textures, form and delicate incisal embrasures adding youthful and beautiful effects to the face.

WWW.HIGHDENT.IR
همیار دندانسازان و دندانپزشکان

References

1. Trinkner TF, Roberts M. Aesthetic restoration with full-coverage porcelain veneers and a ceromer/fiber reinforced composite framework: A case report. Pract Periodont Aesthet Dent 1998;10:547-554.
2. Narcisi EM, Culp L. Diagnosis and treatment planning for ceramic restorations. Dent Clin North Am 2001 ;45:127-142.
3. Chiche GJ, Pinault A. Esthetics of Anterior Fixed Prosthodontics. Chicago: Quintessence, 1994.
4. Magne P, Versluis A, Douglas WH. Rationalization of incisor shape: Experimental-numerical analysis. J Prosthet Dent 1999;81:345-355.
5. Touati B, Miara P, Nathanson D. Esthetic Dentistry and Ceramic Restorations. New York: Martin Dunitz, 1999.
6. Magne P, Kwon KR, Belser UC, Hodges JS, Douglas WH. Crack propensity of porcelain laminate veneers: A simulated operatory evaluation. J Prosthet Dent 1999;81:327-334.
7. Rufenacht CR. Fundamentals of Esthetics. Chicago: Quintessence, 1990.
8. Schbnenberger AJ, Di Felice A, Cossu M, The Esthetic Potential of the Ceramic-Fused-to-Metal Technique. In: Fischer J. Esthetics and Prosthetics. Chicago: Quintessence, 1999:31-71.
9. Lombardi RE. The principles of visual perception and their clinical application to denture esthetics. J Prosthet Dent 1973;29:358-382.
10. Cornell DF. Ceramic veneers: Understanding their benefits and limitations. QDT 1998;21:121-132.
11. Frush JP, Fisher RD. Introduction to dentogenic restorations. J Prosthet Dent 1955;5:586-595.
12. Goldstein RE. Esthetics in Dentistry. 2nd ed. Hamilton, ON: BC Decker Inc, 1998:17-49.
13. Morley J. Smile design. Specific considerations. CDAJ 1997;25:633-637.
14. Morley J. The role of cosmetic dentistry in restoring a youthful appearance. J Am Dent Assoc 1999;130:1166-1172.
15. Morley J. Critical elements for the preparation and finishing of direct and indirect anterior restorations. Contemp Esthet Dent 1997;3:1-6.
16. Sulikowski AV, Yoshida A. Clinical and laboratory protocol for porcelain laminate restorations on anterior teeth. QDT 2001;24:8-22.
17. Morley J. Techniques for delivering multiple -unit veneer cases. Rest Quart 1998;7:7-10.
18. Spear F. The maxillary central incisal edge: A key to esthetic and functional treatment planning. Aurum Ceramic Dent Lab News 1998;2:1-5.
19. Kokich V. Esthetics and anterior tooth position: An orthodontic perspective. Part 2: Vertical position. J Esthet Dent 1993;5:174-178.
20. Miller LL. Porcelain crowns and porcelain laminates. Problems and solutions. Quintessence International Symposium (1991). New Orleans.
21. Rosental L. The art of building a high-profile celebrity practice. Dent Today 1995 May; 14:74,76-9.
22. Strub JR, T^rp JC. Esthetics in dental prosthetics. In: Fischer J, Esthetics and Prosthetics. Chicago: Quintessence, 1999: 11.
23. Magne P, Douglas WH. Additive contour of porcelain veneers: A key element in enamel preservation, adhesion and esthetics for aging dentition J. Adhesive Dent 1999; 1:81-92.
24. Miller M. Reality 2000. Houston: Reality Publishing, 2000.
25. Dietschi D. Free-hand composite resin restorations: A key to anterior aesthetics. Pract Periodont Aesthet Dent 1995; 7:15-25.
26. Vanini L. Light and color in anterior composite restorations. Pract Periodont Aesthet Dent 1996;8:673-682.
27. Roulet J-F, Degrange M. Adhesion. The Silent Revolution in Dentistry. Chicago: Quintessence, 2000.
28. Portalier L. Diagnostic use of composite in anterior aesthetics. Pract Periodont Aesthet Dent 1996;8:643-652.
29. Magne P, Perroud R, Hodges JS, Belser U. Clinical performance of Novel Design porcelain veneers for the recovery of coronal volume and length. Int J Periodontics Restorative Dent. 2000;20:441-459.
30. Bliss CH. A philosophy of patient education. Dent Clin North Am 1960;4:290.
31. Zinner ID, Panno FV, Miller RD, Parker HM, Pines MS. Ceramometal full coverage restorations. In: Dale BG, Aschheim KW. Esthetic Dentistry: A Clinical Approach to Techniques and Materials. Philadelphia, PA: Lea and Febiger, 1993:81-101.
32. Roach RR, Muia PJ. An esthetic checklist. In: Preston JD (ed). Perspectives in Dental Ceramics. Proceedings of the Fourth International Symposium on Ceramics. Chicago: Quintissence, 1988:445.
33. Gehl DH. Investment in the future. J. Prosthet. Dent 1967;18:190-201.
34. Magne P. Perspectives in Esthetic Dentistry. QDT 2000: 23;86-89.
35. Vence BS. Sequential tooth preparation for aesthetic porcelain full-coverage crown restorations. Pract Periodont Aesthet Dent 2000;12:77-85.
36. El Mostehy MR, Stallard RE. Intermediate cementum. J Periodontal Res 1968;3:24-29.
37. Albers HF. Tooth Colored Restoratives. Santa Rosa: Alto Books, 1985 and 1989.
38. Yamamoto M, Miyoshi M, Kataoka S. Special Discussion. Fundamentals of esthetics: Contouring techniques for metal ceramic restorations. QDT 1990/1991 ;14:10-81.
39. Rosental L. The art of tooth preparation and recontouring. Dent Today April 1997;16:1-4.
40. Rinaldi P. Clinical Topics in Dentistry. Continuing education video (n.d.).
41. Magne P, Douglas WH. Porcelain veneer: Dentin bonding optimization and biomimetic recovery of the crown. Int J Prosthodont 1999;12:111-121.
42. Heymann HO. The artistry of conservative esthetic dentistry. J Am Dent Assoc 1987; (special issue): 14E-23E.
43. Magne P, Douglas WH. Design optimization and evolution of bonded ceramics for the anterior dentition: A finite-element analysis. Quintessence Int 1999;30:661-672

WWW.HIGHDENT.IR
همیار دندانسازان و دندانپزشکان

44. Schneider PM, Messer LB, Douglas WH. The effect of enamel surface reduction in vitro on the bonding of composite resin to permanent human enamel. J Dent Res 1981;60:895-900.
45. Black JB. Esthetic restoration of tetracycline-stained teeth. J Am Dent Assoc 1982;104:846-851.
46. Stacey GD. A shear stress analysis of the bonding of porcelain veneers to enamel. J Prosthet Dent 1993;70:395-402.
47. Touati B. Defining form and position. Pract Periodont Aesthet Dent 1998;10:800-803.
48. Baratieri LN. Esthetics: Direct Adhesive Restoration on Fractured Anterior Teeth. Sao Paulo: Quintessence, 1998.
49. Crispin BJ. Contemporary Esthetic Dentistry: Practice Fundamentals. Tokyo: Quintessence, 1994.
50. Sorensen JA, Strutz JM, Avera SP, Materdomini D. Marginal fidelity and microleakage of porcelain veneers made by two techniques. J Prosthet Dent 1992;67:16-22.
51. Calamia JR. Etched porcelain facial veneers: A new treatment modality based on scientific and clinical evidence. NY J Dent 1983;53:255-259.
52. Horn HR. Porcelain laminate veneers bonded to etched enamel. Dent Clin North Am. 1983;27:671-684.
53. Christensen GJ. Veneering the teeth. State of the art. Dent Clin North Am 1985;29:373-391.
54. Calamia JR. Etched porcelain veneers: The current state of the art. Quintessence Int 1985;16:5-12.
55. Plant CG, Thomas GD. Porcelain facings: A simple clinical and laboratory method. British Dent Jour 1987;163: 231-234.
56. McLaughlin G, Morison JE. Porcelain fused to tooth: The state of the art. Rest Dent 1988;4:90-94.
57 Reid JS, Murray MC, Power SM. Porcelain veneers. A four-year follow-up. Rest Dent 1988;5:42-55.
58. Garber DA, Goldstein RE, Feinman RA. Porcelain Laminate Veneers. Chicago: Quintessence, 1988.
59. McComb D. Porcelain veneer technique. Ont Dent 1998; 65:25-27,29,31-32.
60. Weinberg LA. Tooth preparation for porcelain laminates. NY State Dent J 1989;55:25-28.
61. Nixon RL. Porcelain veneers. An esthetic therapeutic alternative. In: Rufenacht CR. Fundamentals of Esthetics. Chicago: Quintessence, 1990:329-68.
62. Garber DA. Porcelain laminate veneers: Ten years later. Part 1. Tooth preparation. J Esthet Dent 1993;5:56-62.
63. Friedman MJ. Augmenting restorative dentistry with porcelain veneers. J Am Dent Assoc 1991 ;122:29-34.
64. Chalifoux PR. Porcelain veneers. Curr Opin Cosmet Dent 1994:58-66.
65. Troedson M, Derand T. Shear stresses in adhesive layer under porcelain veneers. A finite element method study. Acta Odontologica Scandinavica 1998;56:257-262.
66. Deeks J. Full procedural build-up of a young maxillary left central incisor. QDT 1998:161-169.
67 Brian SV. Sequential tooth preparation for aesthetic porcelain full-coverage crown restorations. Pract Periodont Aesthet Dent 2000;12:77-84.
68. Van Meerbeek B, Peumans M, Gladys S, et al. Three-year clinical effectiveness of four total-etch dentinal adhesive systems in cervical lesions. Quint Int 1996;27:775-784.
69. Van Meerbeek B, Perdigao J, Lambrechts P, et al. The clinical performance of adhesives. J Dent 1998;26:1-20.
70. Lacy AM, Wada C, Weiming D, Watanabe L. In vitro microleakage at the gingival margin of porcelain and resin veneers. J Prosthet Dent 1992;67:7-10.
71. Chalifoux PR, Darvish M. Porcelain veneers: Concept, preparation, temporization, laboratory, and placement. Pract Periodont Aesthet Dent 1993;5:11-17
72. Kois JC. New paradigms for anterior tooth preparation. Rationale and technique.Oral Health 1998;88:19-22,25-27, 29-30.
73. Magne P, Kwon KR, Belser UC, Hodges JS, Douglas WH. Crack propensity of porcelain laminate veneers: A simulated operatory evaluation. J Prosthet Dent 1999;12:111-21.
74. Magne P, Versluis A, Douglas WH. Effects of luting composite shrinkage and thermal loads on the stress distribution in porcelain laminate veneers. J Prosthet Dent 1999; 81:335-344.
75. Dumfahrt H. Porcelain laminate veneers . A retrospective evaluation after 1 to 10 years of service: Part 1. Clinical procedure. Int J Prosthod 1999;12:505-513.
76. Jones DW. In: McLean JW (Ed.). Dental Ceramics: Proceedings of the First International Symposium on Ceramics. Chicago: Quintessence, 1983:135.
77 Pameijer JHN. Onlays: Is gold still the standard? In: Degrange M, Roulet J-F. Minimally Invasive Restorations with Bonding. Chicago: Quintessence, 1997:139-152.
78. Jordan RE. Esthetic Composite Bonding. Hamilton, ON: BC Decker Inc, 1987, Ch 3.
79. Quinn F, McConnell RJ, Byrne D. Porcelain laminates: A review. Br Dent J 1986; 161:62-65.
80. McLean JW, Jeansonne EE, Chiche GJ, Pinault A. All ceramic crowns and foil crowns. In: Chiche GJ, Pinault A. Esthetics of Anterior Fixed Prosthodontics. Chicago: Quintessence, 1994;97-114.
81. Christensen GJ. Have porcelain veneers arrived? J Am Dent Assoc 1991;122:81.
82. Tjan AHL, Dunn JR, Sanderson IR. Microleakage patterns of porcelain and castable ceramic laminate veneers. J Prosthet Dent 1989;61:276-282.
83. Crispin BJ, Jo YH, Hobo S. Esthetic ceramic restorative materials and techniques. In: Crispin BJ. Contemporary Esthetic Dentistry: Practice Fundamentals. Tokyo: Quintessence, 1994:155-299.
84. Symid ES. Dental engineering applied to inlay and fixed bridge fabrication. J Prosthet Dent 1952;2:536-542.
85. Tuntiprawon M. Effect of tooth surface roughness on marginal seating and retention of complete metal crowns. J Prosthet Dent 1999;81:142-147
86. Smith BG. The effect of the surface roughness of prepared dentine on the retention of castings. J Prosthet Dent 1970;23:187-197
87 Ayad MF, Rosentstiel SF, Salama M. Influence of tooth surface roughness and surface area on the retention of crowns luted with zinc phophate cement. Austr Dent J 1987;32:446-457

WWW.HIGHDENT.IR
همیار دندانسازان و دندانپزشکان

88. Siegel SC, von Frauhofer JA. Assessing the cutting efficiency of dental burs. J Am Dent Assoc 1996; 127:763-772.
89. Siegel SC, von Frauhofer JA. Dental cutting with diamond burs. Heavy-handed or light touch? J Prosthodont 1999;8: 3-9.
90. Ottl P, Lauer HC. Temperature response in the pulpal chamber during ultra-highspeed tooth preparation with diamond burs of different grit. J Prosthet Dent 1998;80: 12-19.
91. Schwartz JC. Vertical shoulder preparation design for porcelain laminated veneer restorations. Pract Periodont Aesthet Dent 2000;12:517-524.
92. Gurel G. PLV A to Z. American Academy of Cosmetic Dentistry. Annual Meeting, San Antonio (1999).
93. Rouse J, McGowan S. Restoration of the anterior maxilla with ultraconservative veneers. Clinical and laboratory consideration. Pract Periodont Aesthet Dent 1999;11: 333-339.
94. Ferrari M, Patroni S, Balleri P. Measurement of enamel thickness in relation to reduction for etched laminate veneers. Int J Periodont Rest Dent 1992; 23:407-413.
95. Liebenberg WH. Porcelain laminate veneers. Preparation and isolation innovations. Gen Dent 1995;43:50-58.
96. Dale BG, Aschheim KW. Esthetic Dentistry: A Clinical Approach to Techniques and Materials. Philadelphia, PA: Lea and Febiger, 1993:123-151.
97 Shillinburg HT, Hobo S, Fisher DW. Preparations for cast gold restorations. Chicago: Quintessence, 1974.
98. Dawson PE. Determining the determinants of occlusion. Int J Periodont Rest Dent 1983;3:17
99. Jorgenson MW, Goodkind RJ. Spectrophotometric study of five porcelain shades relative to the dimensions of color, porcelain thickness and repeated firings. J Prosthet Dent 1979;42:96.
100. Terada Y, Maeyama S, Hirayasu R. The influence of different thicknesses of dentin color reflected from thin opaque porcelain fused to metal. Int J Prosthodont 1989;2:352.
101. Magne P. Konturanpassung von Keramikveneers. Die Quintessenz 1999;50:1133-1143.
102. Eissmann HF, Radke RA, Noble WH. Physiologic design criteria for fixed dental restorations. Dent Clin North Am 1971;15:543-568.
103. Kourkouta S, Walsh TT, Davis LG. The effect of porcelain laminate veneers on gingival health and bacterial plaque characteristics. J Clin Periodontol 1994;21:638-640.
104. Chan C, Weber H. Plaque retention on teeth restored with full-ceramic crowns: A comparative study. J Prosthet Dent 1986;56:666-671.
105. Koidis PT, Schroeder K, Johnston W, Campagni W. Color consistency, plaque accumulation, and external marginal surface characteristics of the collarless metal-ceramic restoration. J Prosthet Dent 1991 ;65:391-400.
106. Sheets CG, Taniguchi T Advantages and limitations in the use of porcelain veneer restorations. J Prosthet Dent 1990;64:406-411.
107 Friedman MJ. Multiple potential of etched porcelain laminate veneers. J Am Dent Assoc 1987;115 (special issue):831-878.
108. Castelnuovo J, Tjan AH, Liu P. Microleakage of multi-step and simplified-step bonding systems. Am J Dent 1996; 9:245-248.
109. Zaimoglu A, Karaagaclyoglu L. Influence of porcelain material and composite luting resin on microleakage of porcelain laminate veneers. J Oral Rehab 1992;19:319-327
110. Sim C, Neo J, Kiam Chua EK, et al. The effect of dentin bonding agents on the microleakage of porcelain veneers. Dent Mater 1994;10:278-281 (Abstract 215).
111. Peumans M, Van Meerbeek B, Yoshida Y, et al. Porcelain veneers bonded to tooth structure: An ultra-morphological FE-SEM examination of the adhesive interface. Dent Mater 1999.
112. Gaspercic D. Micromorphometric analysis of the cervical enamel structure of human upper third molars. Arch Oral Biol 1995;40:453-457.
113. Pippin DJ, Mixon JM, Soldon-Els AP. Clinical evaluation of restored maxillary incisors: Veneers vs. PFM crowns J Am Dent Assoc 1995;126:1523-1529.
114. Waerhaug J. The location of the restoration margins in relation to the gingiva are governed by histologic conditions. Dent Clin North Am 1960; 4:161-176.
115. Reeves WG. Restorative margin placement and periodontal health. J Prosthet Dent 1991 ;66:733-736.
116. Silness J. Fixed prosthodontics and periodontal health. Dent Clin North Am 1980;24:317-329; Karlsen K. Gingival reactions to dental restorations. Acta Odontologica Scandinavica 1970;28:895-904.
117. Newcomb GM. The relationship between the location of sub gingival crown margins and gingival inflammation. J Periodont 1974;45:151-154; Jameson LM, Malone WFP. Crown contours and gingival response. J Prosthet Dent 1982;47:620-624.
118. Lang NP, Kaarup-Hansen D, Joss A, Siegrist BE, Weber HP, Gerber C, et al. The significance of overhanging filling margins for the health status of interdental periodontal tissues of young adults. Schweiz Monatsschr Zahnmed 1988;98:725-730.
119. Lang NP. Periodontal considerations in prosthetic dentistry. Periodontal 2000 1995;9:118-131.
120. Richter WA, Ueno H. Relationship of crown margin placement to gingival inflammation. J Prosthet Dent 1973;30: 156-161.
121. Christensen GJ. Marginal fit of gold inlay castings. J Prosthet Dent 1966;16:297-305.
122. Trinkner TF, Roberts M. Anterior restoration utilizing novel all ceramic materials. Pract Periodont Aesthet Dent 2000; 12:35-39. ^
123. Ahmad I. Predetermining factors governing calculated tooth preparation for anterior crowns QDT 2001 ;24:57-68.
124. Bichacho N. Cervical contouring concepts: Enhancing the dento-gingival complex. Pract Periodont Aesthet Dent 1996;8:241-254.
125. Nattress BR, Youngson CC, Patterson JW, et al. An in vitro assessment of tooth preparation for porcelain veneer restorations. J Dentistry f995;23:165-170.
126. Larato DC. Effect of cervical margins on gingiva. J Calif Dent Assoc 1969;45:19-22.

WWW.HIGHDENT.IR
همیار دندانسازان و دندانپزشکان

127. Berman MH. The complete coverage restoration and the gingival sulcus. J Prosthet Dent 1973;29:301-304.
128. Stein RS, Kuwata M. A dentist and a dental technologist analyze current ceramo-metal procedures. Dent Clin North Am 1977;21:729-749.
129. Behend DA. Ceramometal restorations with supragingival margins. J Prosthet Dent 1982;47:625-632.
130. Gardner FM. Margins of complete crowns: Literature review. J Prosthet Dent 1982;48:396-400.
131. Goldberg AJ. Deterioration of restorative materials and the risk for secondary caries. Adv Dent Res 1990; 4:14-18.
132. Ozer L, Thylstrup A. What is known about caries in relation to restorations as a reason for replacement? A review. Adv Dent Res 1995;9:394-402.
133. Kidd EAM, Beighton D. Prediction of secondary caries around tooth-colored restorations: A clinical and microbiological study. J Dent Res 1996;75:1942-1946.
134. Van Meerbeek B, Peumans M, Verschueren M, et al. Clinical status of ten dentin adhesive systems. J Dent Res 1994; 73:1960-1702.
135. Stambaugh RV, Wittrock JW. The relationship of the pulp chambertothe external surface of the tooth. J Prosthet Dent 1977;37:537-546.
136. Paul SJ. Adhesive Luting Procedures. Berlin: Quintessence, 1997:67-110.
137 Gwinnett AJ, Kanca J. Interfacial morphology of resin composite and shiny erosion lesions. Am J Dent 1992; 5:315-317.
138. Schi)pbach P, Guggenheim B, Lutz F. Human root caries: Histopathology of initial lesions in cementum and dentin. J Oral Pathol 1989;18:146-156.
139. Duke ES, Lindemuth J. Variability of clinical dentin substrates. Am J Dent 1991 ;4:241-246.
140. Schupbach P, Lutz F, Guggenheim B. Human root caries: Histopathology of arrested lesions. Caries Res 1992;26:153-164.
141. Van Meerbeek B, Braem M, Lambrechts P, Vanherle G. Morphological characterization of the interface between resin and sclerotic dentine. J Dent 1994;22:141-146.
142. Clyde JS, Gilmore A. Porcelain Veneers: A preliminary review. Br Dent 1988;164:9-14.
143. Levy JH. Ultrastructural deformations and proprioceptive function in human teeth, thesis, 1995. New York University College of Dentistry.
144. Lee WC, Eakle WS. Possible role of tensile stress in the etiology of cervical erosive, lesions of teeth. J Prosthet Dent 1984;52:374-380.
145. Paphangkorakit J, Osborn JW. The effect of pressure on a maximum incisal bite force in man. Arch Oral Biol 1997;42:11-17.
146. Heymann HO, Sturdevant JR, Bayne S, et al. Examining tooth flexure effects on cervical restorations: A two-year clinical study. J Am Dent Assoc 1991 ;122:41-47
147. Lambrechts P, Van Meerbeek B, Perdiago J, et al. Restorative therapy of erosive lesions. Eur J Oral Sci 1996; 104:229-240.
148. Kippax AJ, Shore RC, Basker RM. Preparation of guide planes using a reciprocating hand piece. Br Dent J 1996; 180:216-220.
149. Xu HHK, Kelly JR, Jahanmir S, et al, Enamel subsurface damage due to tooth preparation with diamonds. J Dent Res 1997;76:1698-1706.
150. Suh BI. All bond -fourth generation dentin bonding system. J Esthet Dent 1991;3:139-146.
151. Prestipino V, Ingber A, Kravitz J. Clinical and laboratory considerations in the use of a new all-ceramic restorative system. Pract Periodont Aesthet Dent 1998; 10:567-575.
152. Rateitschak KH, Rateitschak EM, Wolf HE Paradontologie. Stuttgart: Thieme, 1984.
153. Takei HH. The interdental space. Dent Clin North Am 1980;24:169.
154. Ramfjord S. Periodontal aspects of restorative dentistry. JOralRehabil 1974;1:107.
155. Hazen S, Osborne J. Relationship of operative dentistry to periodontal health. Dent Clin North Am 1967; 11:45.
156. Weinberg LA. Esthetic and the gingiva in full coverage. J Prosthet Dent 1960; 10:737
157 Hirshberg SM. The relationship of hygiene to embrasure and pontic design: A preliminary study. J. Prosthet Dent 1972;27:26.
158. Burch J. Ten rules for developing tooth contour in dental restorations. Dent Clin North Am 1971; 15:611.
159. Nixon RL. Tooth preparation for porcelain veneers. Forum Esthet Dent 4:5,1986.
160. Williams HA, Caughman WF, Pollard BL. The esthetic hybrid resin-bonded bridge. Quint Int 1989;29:623.
161. Celenza V. Cast Glass Ceramic - Full Coverage Restorations. In: Dale BG, Aschheim KW. Esthetic Dentistry: A Clinical Approach to Techniques and Materials. Philadelphia, PA: Lea and Febiger, 1993:117-122. The finish line must be a well-defined continuous chamfer.
162. Janenko C, Smales RJ. Anterior crowns and gingival health. Austr Dent J 1979;24:225-230.
163. Olsson J, van der Heijde Y, Holmberg K. Plaque formation in vivo and bacterial attachment in vitro on permanently hydrophobic and hydrophilic surface. Caries Res 1992; 26:428-433.
164. Hahn R, Weiger R, Netuschil L, Bruch M. Microbial accumulation and vitality on different restorative materials. Dent Mater 1993;9:312-316.
165. Quirynen M, Bollen CML. The influence of surface roughness and surface-free energy on supra- and subgingival plaque formation in man. A review of literature. J Clin Periodont 1995;22:1-14.
166. Calamia JR. Clinical evaluation of etched porcelain veneers. Am J Dent 1989;2:9-15.
167 Kourkata S, Walsh TF, Davis LG. The effect of porcelain laminate veneers on gingival health and bacterial plaque characteristics. J Clin Periodont 1994;21:638-640.
168. Kihn PW, Barnes DM. The clinical longevity of porcelain veneers at 48 months. J Am Dent Assoc 1998; 129:747-752.

WWW.HIGHDENT.IR
همیار دندانسازان و دندانپزشکان

169. Walls AW. The use of adhesively retained all porcelain veneers during the management of fractured and worn out anterior teeth. Part 2. Clinical results after 5 years of follow-up. Br Dent J 1995;178:337-339.

170. Peumans M, Van Meerbeek B, Lambrechts P, et al. Five-year clinical performance of porcelain veneers. Quintessence Int 1998;29:211-221.

171. Dumfhart H, Schaffer H. Porcelain Laminate Veneers. A retrospective evaluation after 1 to 10 years of service. Part 2. Clinical results. Int J Prosthodontics 2000;13:9-18.

172. Shillingburg Jr HT, Hobo S, Whitsett LD, et al. Fundamentals of Fixed Prosthodontics. 3rd ed. Chicago: Quintessence, 1997.

173. Hugo B, Stassinakis A, Hotz P. Die Randqualitat der Schmelzabschragung bei adhasiven Klasse-II-Minikavitaten in vivo. Deutsche Zahnartzliche Zeitschrift 1995; 50:832-835.

174. Hugo B, Lussi A, Hotz P. Die Preparation der Schmelzrandschragung bei approximalen Kavitaten. Schweiz Monatsschr Zahnmed 1992;102:1181-1188.

175. Lussi A, Hugo B, Hotz P. Einfluss zweier Finierungsmeden auf die Mikromorphologie des approximalen Kastenrandes. Schweiz Monatsschr Zahnmed 1992;102:1175-1180.

176. Hugo B. Preparation and restoration of small interproximal carious lesions. In: Roulet J-F, Degrange M. Adhesion. The Silent Revolution in Dentistry. Chicago: Quintessence, 2000:153-165.

177. Rouse JS. Full veneer versus traditional veneer preparation with a medium wrap: A discussion of interproximal extension. J Prosthet Dent 1997;78:545-549.

178. Chiche G, Aoshima H. Functional versus aesthetic articulation of maxillary anterior restorations. Pract Periodont Aesthet Dent 1997;9:335-342.

179. Christensen GJ, Christensen RP. Clinical observations of porcelain veneers. A three year report. J Esthet Dent 1991;3:174-179.

180. Dunne SM, Millar J. A longitudinal study of the clinical performance of porcelain veneers. Br Dent J 1993;175: 317-321.

181. Jager K, Stern M, Wirz J. Laminates - Reif fur die Praxis? Die Quintessenz 1995;46:1221-1230.

182. Highton R, Caputo AA, Matyas JA. A protoelastic study of stress on porcelain laminate preparations. J Prosthetic Dent 1987;58:157-161.

183. Magne P, Douglas WH. Interdental design of porcelain veneers in the presence of composite fillings. Finite element analysis of composite shrinkage and thermal stresses. Int J Prosthodontics 2000;13:117-124.

184. Karlsson S, Landahl I, Stegersjo G, Milleding P. A clinical evaluation of ceramic laminate veneers. Int J Prosthodont 1992;5:447-451.

185. Mormann WH, Link C, Lutz F. Color changes in veneer ceramics caused by bonding composite resins. Acta Med Dent Helv 1996;1:97-102.

186. Hui K, Williams B, Davis E, Holt R. A comparative assessment of the strengths of porcelain veneers for incisor teeth dependent on their design characteristics. Br Dent J 1991;171:51-55.

187. Chpindel P, Cristou M. Tooth preparation and fabrication of porcelain veneers using a double-layer technique. Pract Periodont Aesthet Dent 1994;6:19-30.

188. Meijering AC, Roeters FJM, Mulder J, Creugers NHJ. Recognition of veneer restorations by dentists and beautician students. J Oral Rehabil 1997;24:506-511.

189. Nordbo H, Rygh-Thoresen N, Henang T Clinical performance porcelain laminate veneers without incisal overlapping 3-year results. J Dent 1994;22:342-345.

190. Crispin BJ. Full veneers. The functional and esthetic application of bonded ceramics. Compend Contin Educ Dent 1994; 15:284,286-294.

191. Gilde H, Lenz P, Furst U. Untersuchungen zur Belastbarkeit von Keramikfacetten. Deutsche Zahnartzliche Zeitschrift 1989;44:869-71.

192. Friedman MJ. A fifteen-year review of porcelain veneer failure. A clinician's observations. Compend Contin Educ Dent 1998;19:625-636.

193. Tronstad L, Leidal Tl. Scanning electron microscopy of cavity margins finished with chisels or rotating instruments at low sped. J Dent Res 1974 53:1167-1174.

194. Fischer J, Kuntze C, Lampert F. Modified partial-coverage ceramics for anterior teeth: A new restorative method. Quintessence Int 1997;28:293-299.

195. Nabakayashi N, Pashley DH. Hybridization of Dental Hard Tissues. 1st ed. Tokyo: Quintessence, 1998:37-39.

196. Olgard L, Brannstrom M, Johnson G. Invasion of bacteria into dentinal tubules. Experiments in vivo and in vitro. Acta Odontologica Scandinavica 1974;32:61-70.

197. Brannstrom M. Etiology of dentin hypersensitivity. Proc Fin Dent Soc 1992;88:7-13, supplement.

198. Ellege DA, Schorr Bl. A provisional restoration technique for laminate veneer preparation. J Prosthed Dent 1989; 62:139-142.

199. Rada RE, Jankowski BJ. Provisional laminate veneer provisionalization using visible light-curing acrylic resin. Quintessence Int 1991;22:291-293.

200. Bertschinger C, Paul SJ, Luthy H, Scharer P. Dual application of dentin bonding agents. Its effect on the bond strength. Am J Dent 1996;9:115-119.

201. Paul SJ, Scharer P. The dual bonding technique: A modified method to improve adhesive luting. Int J Periodont Rest Dent 1997;17:536-545.

202. Nikaido T, Burrow MF, Tagami J, et al. Effect of pulpal pressure on adhesion of resin composite to dentin: Bovine serum versus saline. Quintessence Int. 1995; 26:221-226.

203. Cagidiaco MC, Ferrari M, Garberoglio R, et al. Dentin contamination protection after mechanical preparation of veneering. Am J Dent 1996;9:57-60.

204. Cobb DS, Reinhardt JW, Vargas MA. Effect of HEMA-containing dentin desensitizers on shear bond strength of resin cement. Am J Dent 1997;10:62-65.