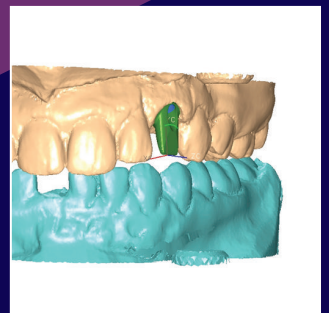
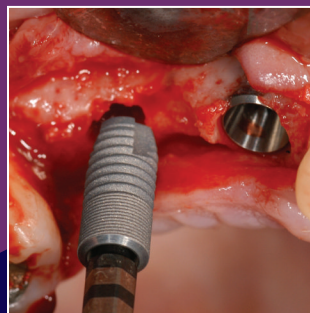
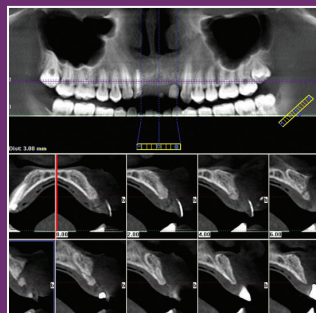


# Implants in Clinical Dentistry

## Second Edition



**informa**  
healthcare

Edited by  
Richard M. Palmer  
Leslie C. Howe  
Paul J. Palmer

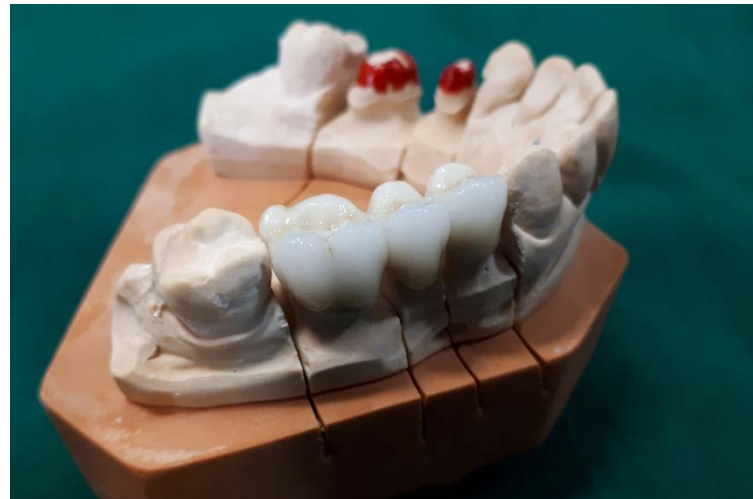
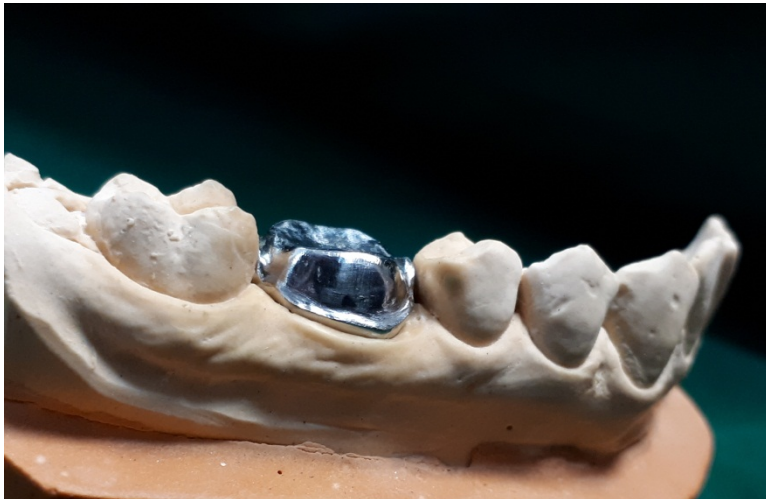
# مرکز تخصصی پروتزهای دندانی هایک دنت

طراحی و ساخت انواع پروتزهای دندانی بویژه ایمپلنت  
برگزار کننده دوره های آموزشی تخصصی و جامع دندانسازی و...

**با ما همراه باشید...**

**[WWW.HIGHDENTlab.com](http://WWW.HIGHDENTlab.com)**



# Implants in Clinical Dentistry

## Second Edition

**Richard M. Palmer, PhD, BDS, FDS RCS (Eng), FDS RCS (Ed)**

*Professor of Implant Dentistry and Periodontology, King's College London Dental Institute,  
London SE1 9RT, U.K.*

**Leslie C. Howe, BDS, FDS RCS (Eng)**

*Head of Conservative Dentistry, King's College London Dental Institute, London SE1 9RT, U.K.*

**Paul J. Palmer, BDS, MSc, MRD RCS (Eng)**

*Consultant in Periodontology, Guy's and St Thomas' NHS Foundation Trust, London, U.K.*

With Contributions From

**Kalpesh Bavisha, BDS, MSc, FDS RCPS (Glasg)**

*Consultant in Restorative Dentistry, Guy's and St Thomas' NHS Foundation Trust, London, U.K.*

**Mahmood Suleiman, PhD, BDS, MSc, MFGDP**

*Hon Specialist Clinical Teacher Implant Dentistry, Guy's and St Thomas' NHS Foundation Trust;  
Associate Specialist Maxillofacial Surgery, Ashford and St. Peter's Hospitals, London, U.K.*

**informa**  
healthcare

New York London

First edition published in 2002 by Martin Dunitz, Ltd., 7-9 Pratt Street, London, NW1 0AE, UK.  
This edition published in 2012 by Informa Healthcare, 37-41 Mortimer Street, London W1T 3JH, UK.

Simultaneously published in the USA by Informa Healthcare, 52 Vanderbilt Avenue, 7th Floor, New York, NY 10017, USA.

Informa Healthcare is a trading division of Informa UK Ltd. Registered Office: 37-41 Mortimer Street, London W1T 3JH, UK. Registered in England and Wales number 1072954.

© 2012 Informa Healthcare, except as otherwise indicated  
No claim to original U.S. Government works

Reprinted material is quoted with permission. Although every effort has been made to ensure that all owners of copyright material have been acknowledged in this publication, we would be glad to acknowledge in subsequent reprints or editions any omissions brought to our attention.

All rights reserved. No part of this publication may be reproduced, stored in a retrieval system, or transmitted, in any form or by any means, electronic, mechanical, photocopying, recording, or otherwise, unless with the prior written permission of the publisher or in accordance with the provisions of the Copyright, Designs and Patents Act 1988 or under the terms of any licence permitting limited copying issued by the Copyright Licensing Agency Saffron House, 6-10 Kirby Street, London EC1N 8TS UK, or the Copyright Clearance Center, Inc., 222 Rosewood Drive, Danvers, MA 01923, USA (<http://www.copyright.com/or> telephone 978-750-8400).

Product or corporate names may be trademarks or registered trademarks, and are used only for identification and explanation without intent to infringe.

This book contains information from reputable sources and although reasonable efforts have been made to publish accurate information, the publisher makes no warranties (either express or implied) as to the accuracy or fitness for a particular purpose of the information or advice contained herein. The publisher wishes to make it clear that any views or opinions expressed in this book by individual authors or contributors are their personal views and opinions and do not necessarily reflect the views/opinions of the publisher. Any information or guidance contained in this book is intended for use solely by medical professionals strictly as a supplement to the medical professional's own judgement, knowledge of the patient's medical history, relevant manufacturer's instructions and the appropriate best practice guidelines. Because of the rapid advances in medical science, any information or advice on dosages, procedures, or diagnoses should be independently verified. This book does not indicate whether a particular treatment is appropriate or suitable for a particular individual. Ultimately it is the sole responsibility of the medical professional to make his or her own professional judgements, so as appropriately to advise and treat patients. Save for death or personal injury caused by the publisher's negligence and to the fullest extent otherwise permitted by law, neither the publisher nor any person engaged or employed by the publisher shall be responsible or liable for any loss, injury or damage caused to any person or property arising in any way from the use of this book.

A CIP record for this book is available from the British Library.

ISBN-13: 978-1-84184-906-5

Orders may be sent to: Informa Healthcare, Sheepen Place, Colchester, Essex CO3 3LP, UK  
Telephone: +44 (0)20 7017 6682  
Email: [Books@Informa.com](mailto:Books@Informa.com)  
Website: <http://informahealthcarebooks.com>

---

#### Library of Congress Cataloging-in-Publication Data

---

Palmer, R.  
Implants in clinical dentistry / Richard M. Palmer, Leslie C. Howe, Paul J.  
Palmer. -- 2nd ed.  
p. : cm.  
Rev. ed. of: Implants in clinical dentistry / Richard M. Palmer ... [et al.].  
2002.  
Includes bibliographical references and index.  
ISBN 978-1-84184-906-5 (hb : alk. paper)  
I. Howe, Leslie C. II. Palmer, Paul J. III. Implants in clinical dentistry. IV.  
Title.  
[DNLM: 1. Dental Implants. 2. Dental Implantation--methods. WU 640]  
617.6'93--dc23

2011034760

---

For corporate sales please contact: [CorporateBooksIHC@informa.com](mailto:CorporateBooksIHC@informa.com)  
For foreign rights please contact: [RightsIHC@informa.com](mailto:RightsIHC@informa.com)  
For reprint permissions please contact: [PermissionsIHC@informa.com](mailto:PermissionsIHC@informa.com)

Typeset by MPS Limited, a Macmillan Company  
Printed and bound in the United Kingdom

## Preface to the Second Edition

Since the first edition of this book published in 2002, there has been a significant evolution of implant design where many of the major implant systems share common design features that facilitate treatment, improve success, and allow clinicians to more readily adapt to an alternative system. At the same time, there have been huge developments in CAD-CAM applications to implant dentistry and rapid treatment protocols. Despite these changes, the underlying basic principles of thorough diagnosis, meticulous treatment planning, and execution of treatment remain unchanged. This book is firmly based on promoting the acquisition and application of these basic principles in routine conventional treatment protocols before recommending that clinicians embark on more complex and sometimes higher risk treatments.

We are particularly grateful to two other clinicians in our implant dentistry team: Kalpesh Bavisha, who has revised the chapters on implant overdentures (chapters 6, 15, and 17), following the retirement of Brian Smith, and Mahmood Suleiman, who has revised the chapters on planning and surgery in fixed bridges (chapters 5 and 10). We also acknowledge the crucial importance of our highly skilled technicians as part of our team both within the institute and in private practice, in particular Geraldine Williams and her team at Guy's and St Thomas' Hospital; Mark Wade Dental Laboratory, Brentwood; and Brooker & Hamill, London W1.

The new text and format has been supplemented with a large number of new illustrations, and we sincerely hope that this book will continue to help many practitioners embarking upon this still exciting and innovative treatment modality.

### ACKNOWLEDGMENTS

We would like to thank the following people and publishers:

Dr. David Radford for producing the scanning electron microscopy images in Figures 1.7 and 1.10.

Dr. Paul Robinson for help with the maxillofacial aspects of treatment in the case illustrated in Figure 12.17.

Our postgraduate students who have supported our implant dentistry program and have contributed some of the figures included.

Astra Tech, Nobel Biocare, and Straumann for providing illustrations of implant components in chapter 1.

Original permission from Munksgaard International Publishers Ltd., Copenhagen, Denmark, to allow reproduction of Figure 1.18A from Cawood JJ and Howell RA, *International Journal of Oral and Maxillofacial Surgery* 1991; 20:75.

British Dental Journal Books for permission to reproduce figures in chapters 2, 13, and 14 from *A Clinical Guide to Implants in Dentistry* (2nd edition, 2008).

Dental Update to agree to reproduction of text and illustrations in chapter 11 from Palmer RM, et al. Immediate loading and restoration of implants. *Dental Update* 2006; 33:262.

Richard M. Palmer  
Leslie C. Howe  
Paul J. Palmer

## Contents

*Preface to the Second Edition* .....v

1. Overview of implant dentistry .....	1
2. Treatment planning for implant restorations: general considerations.....	15
3. Single tooth planning in the anterior region.....	21
4. Single tooth planning for molar replacements .....	30
5. Fixed bridge planning.....	35
6. Diagnosis and treatment planning for implant overdentures.....	46
7. Basic factors in implant surgery.....	57
8. Flap design for implant surgery.....	63
9. Surgical placement of the single tooth implant in the anterior maxilla.....	69
10. Implant placement for fixed bridgework .....	77
11. Immediate and early replacement implants .....	82
12. Grafting procedures for implant placement .....	91
13. Single tooth implant prosthodontics .....	121
14. Fixed bridge prosthodontics .....	149
15. Implant overdentures.....	181
16. Complications and maintenance.....	191
17. Prosthodontic complications of implant treatment and maintenance of implant overdentures.....	208

*Index* ....215

## Overview of implant dentistry

### INTRODUCTION

The development of endosseous osseointegrated dental implants has been very rapid over the last two decades. There are now many implant systems available that provide the clinician with

- a high degree of predictability in the attainment of osseointegration;
- versatile surgical and prosthodontic protocols;
- design features that facilitate ease of treatment and aesthetics;
- a low complication rate and ease of maintenance;
- published papers to support the manufacturer's claims;
- a reputable company with good customer support.

There is no perfect system and the choice may be bewildering. It is easy for a clinician to be seduced into believing that a new system is better or less expensive. All implant treatment depends on a high level of clinical training and experience. Much of the cost of treatment is not system dependent but relates to clinical time and laboratory expenses.

There are a number of published versions of what constitutes a successful implant or implant system. For example, Albrektsson et al. (IJOMI 1:11, 1986) proposed the following minimum success criteria:

1. An individual, unattached implant is immobile when tested clinically.
2. Radiographic examination does not reveal any peri-implant radiolucency.
3. After the first year in function, radiographic vertical bone loss is less than 0.2 mm per annum.
4. The individual implant performance is characterized by an absence of signs and symptoms such as pain, infections, neuropathies, paresthesia, or violation of the inferior dental canal.
5. As a minimum, the implant should fulfill the above criteria with a success rate of 85% at the end of a 5-year observation period and 80% at the end of a 10-year period.

The most definitive criterion is that the implant is not mobile (criterion 1). By definition, osseointegration produces a direct structural and functional union between the surrounding bone and the surface of the implant (Fig. 1.1). The implant is therefore held rigidly within bone without an intervening fibrous encapsulation (or periodontal ligament) and therefore should not exhibit any mobility or peri-implant radiolucency (criterion 2). However, to test the mobility of an implant supporting a fixed bridge reconstruction (fixed dental prosthesis), the bridge has to be removed. This fact has limited the use of this test in clinical practice and in many long-term studies, especially as many reconstructions are cement retained rather than screw retained. Radiographic bone levels are also difficult to assess as they depend on longitudinal measurements from a specified landmark (Fig. 1.2). The landmark may differ with various designs of implant and is more difficult to visualize in

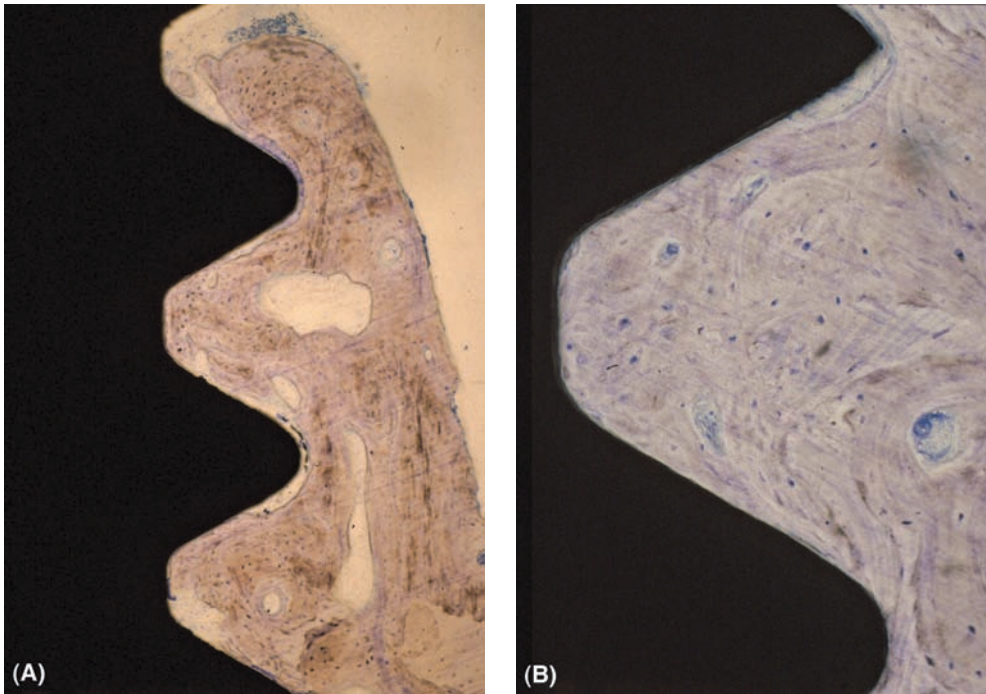
some than others. For example, the flat top of the implant in the Branemark system is easily defined on a well-aligned radiograph and is used as the landmark to measure bone changes. In many designs of implant, some bone remodeling is expected in the first year of function in response to occlusal forces and establishment of the normal dimensions of the peri-implant soft tissues. Subsequently, the bone levels are usually stable on the majority of implants over many years. A small proportion of implants may show some bone loss and account for the mean figures of bone loss, which are published in the literature. Progressive or continuous bone loss is a sign of potential implant failure. However, it is difficult or impossible to establish agreement between researchers/clinicians as to what level of bone destruction constitutes failure. Therefore, most implants described as failures are those that have been removed from the mouth. Implants that remain in function but do not match the success criteria are described as "surviving." Radiographic bone loss is also one of the criteria required within the definition of "peri-implantitis," in addition to the presence of soft tissue inflammation (see chap. 16). In most proposals this is defined as an absolute measurement of bone loss, for example, greater or equal to 1.8 mm, rather than a measure of progressive bone loss from a specific landmark. When reviewing the literature it is important to bear in mind that terms describing bone changes can be applied rather loosely, for example, "bone level" should describe the position of the bone in relationship to a fixed landmark at a point in time, whereas "bone loss" should indicate a deterioration in bone level over a period of time.

Implants placed in the mandible (particularly anterior to the mental foramina) have enjoyed a very high success rate, such that it would be difficult or impossible to show differences between rival systems. In contrast, the more demanding situation of the posterior maxilla where implants of shorter length placed in bone of softer quality may reveal differences between success rates. This remains to be substantiated in comparative clinical trials. Currently there is no comparative data to recommend one system over another, but certain design features may have theoretical advantages (see below).

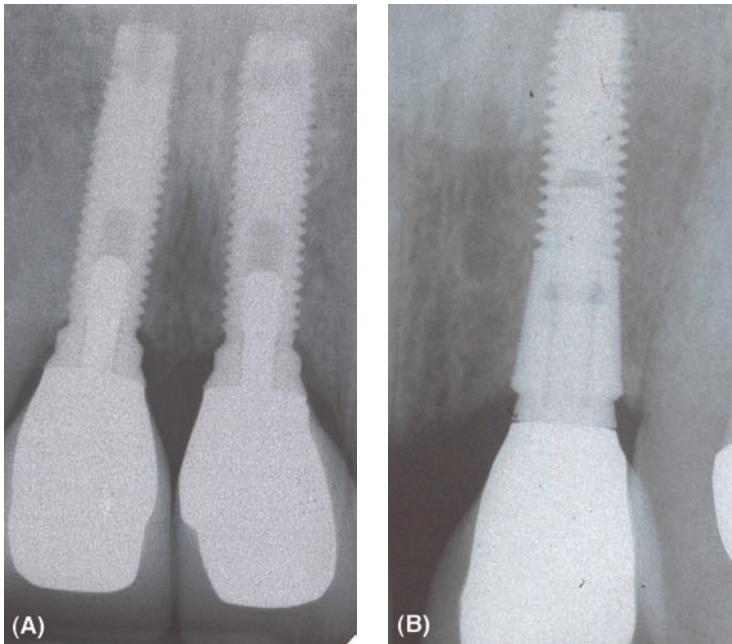
### PATIENT FACTORS

There are few contraindications to implant treatment. Following are the main potential problem areas to consider:

- Age
- Untreated dental disease
- Severe mucosal lesions
- Tobacco smoking, alcohol and drug abuse
- Poor bone quality
- Previous radiotherapy to the jaws
- Poorly controlled systemic disease such as diabetes
- Bleeding disorders



**Figure 1.1** Histological sections of osseointegration. **(A)** The titanium implant surface has a threaded profile and bone is in contact over a large proportion of the area. Small marrow spaces are visible, some of which are in contact with the implant surface. **(B)** A higher power view of bone in intimate contact with the titanium surface.



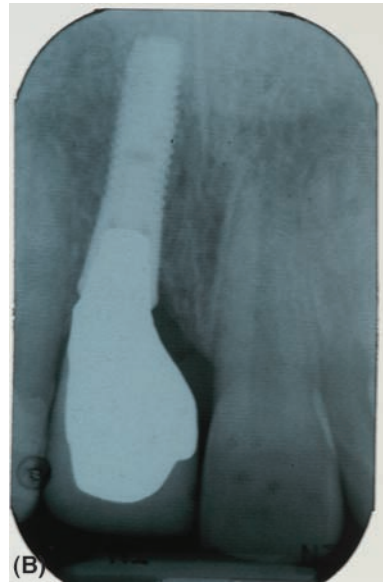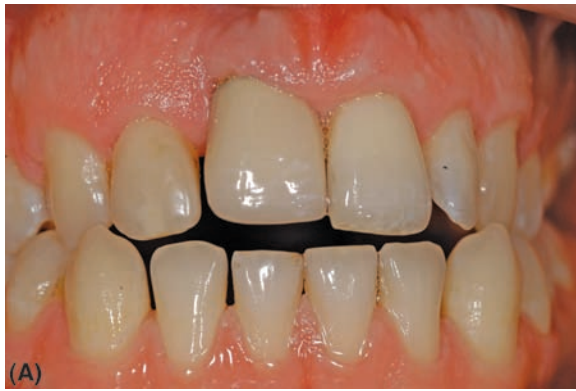**Figure 1.2** **(A)** Branemark implants used to replace upper central incisor teeth. The mesial and distal bone levels are level with the first thread of the implant body. The landmark usually chosen for measurement of bone levels is the head of the implant, which forms a flat plane at the junction with the titanium abutment. **(B)** An Astra Tech implant used to replace a central incisor tooth. The mesial and distal bone levels are level with the head of the implant. This is the normal landmark for measurement of bone changes with this implant system. The titanium abutment has a smaller diameter than the implant head, producing the appearance of a negative margin.

## Age

The fact that the implant behaves as an ankylosed unit restricts its use to individuals who have completed their jaw growth. Placement of an osseointegrated implant in a child will result in relative submergence of the implant restoration with growth of the surrounding alveolar process during normal development. It is therefore advisable to delay implant placement until growth is complete. This is generally earlier in females than males but considerable variation exists. At present there is no

reliable indication of when jaw growth is complete, and comparison with height measurement monitoring is not informative. It is usually acceptable to treat patients in the late teens. Although some jaw growth potential may remain in the early twenties, this is less likely to result in a significant aesthetic problem (Fig. 1.3).

There is no upper age limit to implant treatment, provided the patient is fit enough and willing to be treated. For example, elderly edentulous individuals can experience



**Figure 1.3** (A) A male patient in his mid-twenties who had the right central incisor replaced with a single tooth implant in his late teens. Further growth and eruption of the adjacent teeth has resulted in a relative infraocclusion of the right central incisor and a gingival margin, which is more apical. (B) The radiograph of the same case showing the relative apical positioning of the implant head, compared to the adjacent teeth.

considerable quality of life and health gain with implant treatment to stabilize complete dentures (see chap. 6).

### Untreated Dental Disease

The clinician should ensure that all patients are comprehensively examined, diagnosed, and treated to adequately deal with concurrent dental disease. Poor oral hygiene will result in inflammation of the peri-implant soft tissues—peri-implant mucositis. Inflammation of the soft tissues may subsequently lead to bone loss (peri-implantitis). Placement of implants in subjects susceptible to periodontitis may lead to higher implant failure rates and more marginal bone loss. Implants placed close to peri-apical lesions or residual peri-apical granulomas may be lost as a result of resultant infection.

### Severe Mucosal Lesions

Caution should be exercised before treating patients with severe mucosal/gingival lesions such as erosive lichen planus or mucous membrane pemphigoid. When these conditions affect the gingiva, they are often more problematical around the natural dentition and the discomfort compromises plaque control adding to the inflammation. Similar lesions can arise around implants penetrating the mucosa, giving rise to ulceration and discomfort.

### Tobacco Smoking and Drug Abuse

It is well established that tobacco smoking is a very important risk factor in periodontitis and that it affects healing. This has been extensively demonstrated in the dental, medical, and surgical literature. A few studies have shown that the overall mean failure rate of dental implants in smokers is approximately twice that in nonsmokers. Smokers should be warned of this association and encouraged to quit the habit. Protocols have been proposed that recommend smokers to give up for at least two weeks prior to implant placement and for several weeks afterward. Such recommendations have not been adequately tested in clinical trials and nor has the compliance of the patients. The chance of the quitter relapsing is disappointingly high and some patients will try to hide the fact that they are still smoking. It should also be noted that reported mean implant failure rates are not evenly distributed throughout the patient population.

Rather, implant failures are more likely to cluster in certain individuals. In our experience, this is more likely in heavy smokers who have a high intake of alcohol. In addition, failure is more likely in those who have poor bone quality and a possible association with tobacco smoking. It should also be noted that smokers followed in longitudinal studies have been shown to have more significant marginal bone loss around their implants than nonsmokers. Most of these findings have been reported from studies involving the Branemark system, probably because it is one of the best documented and widely used systems to date. More recent studies of modern implants with surface modifications have reported a reduced chance of early failure in both nonsmokers and smokers. However, differences may still be apparent especially if smoking is heavy.

Drug abuse may affect the general health of the individual and their compliance with treatment and may therefore be an important contraindication.

### Poor Bone Quality

This is a term often used to denote regions of bone in which there is low mineralization or poor trabeculation. It is often associated with a thin or absent cortex and is referred to as type 4 bone. It is a normal variant of bone quality and is more likely to occur in the posterior maxilla. In the mandible, a thick cortex may disguise poor quality medullary bone in plain radiographs. Three-dimensional radiographs will give a much clearer idea of bone density and in medical CT this can be measured in Hounsfield units. Osteoporosis is a condition that results in a reduction of the mineral bone density and commonly affects postmenopausal females, having its greatest effect in the spine and pelvis. The commonly used DEXA scans for osteoporosis assessment do not generally provide useful clinical measures of the jaws. The effect of osteoporosis on the maxilla and mandible may be of little significance in the majority of patients. Many patients can have type 4 bone quality, particularly in the posterior maxilla, in the absence of any osteoporotic changes. Osteoporotic patients who have been treated with oral bisphosphonates for osteoporosis probably do not present a significant risk of osteonecrosis. This is in contrast to patients treated with IV

bisphosphonates for tumors with bone metastases where the reported complication of osteonecrosis is significant.

### Previous Radiotherapy to the Jaws

Radiation for malignant disease of the jaws results in endarteritis, which compromises bone healing and in extreme cases can lead to osteoradionecrosis following trauma/infection. These patients requiring implant treatment should be managed in specialist centers. It can be helpful to optimize timing of implant placement in relationship to the radiotherapy and to provide a course of hyperbaric oxygen treatment. The latter may improve implant success particularly in the maxilla. Success rates in the mandible may be acceptable even without hyperbaric oxygen treatment, although more clinical trials are required to establish the effectiveness of the recommended protocols. Unfortunately, more recent clinical trials have not managed to provide clear evidence of the benefits of hyperbaric oxygen.

### Poorly Controlled Systemic Disease such as Diabetes

Diabetes has been a commonly quoted factor to consider in implant treatment. It does affect the vasculature, healing, and response to infection. Although there is limited evidence to suggest higher failure of implants in well-controlled diabetes, it would be unwise to ignore this factor in poorly controlled patients.

### Bleeding Disorders

Bleeding disorders are obviously relevant to the surgical delivery of treatment, and require advice from the patient's physician.

## OSSEOINTEGRATION

Osseointegration is basically a union between bone and the implant surface (Fig. 1.1). It is not an absolute phenomenon and can be measured as the proportion of the total implant surface that is in contact with bone. Greater levels of bone contact occur in cortical bone than in cancellous bone, where marrow spaces are often adjacent to the implant surface. Therefore, bone with well-formed cortices and dense trabeculation offer the greatest potential for high degrees of bone to implant contact. The degree of bone contact may increase with time. The precise nature of osseointegration at a molecular level is not fully understood. At the light microscopic level, there is a very close adaptation of the bone to the implant surface. At the higher magnifications possible with electron microscopy, there is a gap (approximately 100 nm in width) between the implant surface and bone. This is occupied by an intervening collagen-rich zone adjacent to the bone and a more amorphous zone adjacent to the implant surface. Bone proteoglycans may be important in the initial attachment of the tissues to the implant surface, which in the case of titanium implants consists of a titanium oxide layer, which is defined as a ceramic.

It has been proposed that the biological process leading to and maintaining osseointegration is dependent on the following factors, which will be considered in more detail in the subsequent sections.

- Biocompatibility
- Implant design
- Submerged or nonsubmerged protocols
- Bone factors
- Loading conditions
- Prosthetic considerations

## BIOCOMPATIBILITY

Most current dental implants are made of commercially pure titanium. It has established a benchmark in osseointegration, against which few other materials compare. Related materials such as niobium are able to produce a high degree of osseointegration, and in addition, successful clinical results were reported with titanium aluminum vanadium alloys. There has been a renewed interest in titanium alloys, for example, titanium/zirconium alloy by Straumann, because they have the potential of enhancing physical/mechanical properties of the implants. This is of greater significance in narrow diameter implants.

Hydroxyapatite-coated implants have the potential to allow more rapid bone growth on their surfaces. They have been recommended for use in situations of poorer bone quality. The reported disadvantages are the delamination of the coating and corrosion with time. Resorbable coatings have been developed, which aim to improve the initial rate of bone healing against the implant surface, followed by resorption within a short time frame to allow establishment of a bone to metal contact. Hydroxyapatite-coated implants are not considered within this book as the authors have no experience of them.

All the implant systems used by the authors and illustrated in this book are made from titanium and therefore highly comparable in this respect. The main differences in the systems are in the design, which is considered in the next section.

## IMPLANT DESIGN

Implant design usually refers to the design of the intraosseous "root form" component (the endosseous dental implant). However, the design of the implant-abutment junction and the abutments are extremely important in the prosthodontic management and maintenance and will be dealt with under a separate section.

The implant design has a great influence on initial stability and subsequent function in bone. Following are the main design parameters:


- Implant length
- Implant diameter
- Shape
- Surface characteristics

### Implant Length


Implants are generally available in lengths from about 6 mm to as much as 20 mm (Fig. 1.4). The most common lengths employed are between 8 and 15 mm, which correspond quite closely to normal root lengths. There has been a tendency to use longer implants in systems such as Branemark, compared to, for example, Straumann. The Branemark protocol advocated maximizing implant length where possible to engage bone cortices apically as well as marginally to gain high initial stability. In contrast, the concept with Straumann was to increase surface area of shorter implants by design features (e.g., hollow cylinders) or surface treatments (see below).

### Implant Diameter

Most implants are approximately 4 mm in diameter (Figs. 1.4B and 1.5). A diameter of at least 3.3 mm is normally recommended to ensure adequate implant strength. Implants of 3 mm diameter are now available and normally recommended for low load situations such as mandibular incisor teeth. Narrow implants may have to be designed as one piece (i.e., incorporating the abutment) as they are too narrow to allow connection



**Figure 1.4** (A) Branemark implants in a range of lengths from 7 to 20 mm. The implant surface is machined or turned and the implant head has a flat top and external hexagon connection. (B) A range of Astra Tech implants from 3.0 to 5.0 mm diameter. The large diameter implants have a longer conical collar, which is microthreaded.



**Figure 1.5** (A) A narrow diameter Straumann implant with a polished collar and external hexagonal abutment connection. (B) A standard diameter tissue level Straumann implant with a polished collar and internal abutment connection.

via an abutment screw of adequate diameter. Wider diameter implants (5 mm and over) are available, which are considerably stronger, have a much higher surface area, and are often indicated for molar replacement. They may also engage lateral bone cortices to enhance initial stability. However, they may not be so widely used because sufficient bone width is not commonly encountered in most patients' jaws.


### Implant Shape

Implants come in a very wide variety of shapes with many of the design features shared between systems and others limited to systems, especially where patents exist. The shape and screw design of the implant together with the recommended site preparation does have an effect on the surgical performance and stability of the implant that may guide operator preference. Most implants are parallel cylindrical or tapered

cylindrical threaded designs (Figs. 1.4–1.6). The tapered design will normally require more torque to insert as the wider part gradually engages the prepared site. The apical design may also be parallel or more commonly tapered to allow easier insertion, and may be smooth or have cutting faces to achieve self-tapping of the bone. The thread design and pitch vary considerably. A common thread pitch is 0.6 mm. The thread design may be more rounded or sharp and contribute to stability of the implant on insertion. The coronal end of the implant may be parallel sided or flared to provide a larger head or platform to connect to the abutment. The outer surface profile of the coronal end may have the same thread profile as the body of the implant, a finer microthread or a smooth profile (Figs. 1.4–1.6). The surface characteristics (see below) may be the same as the body of the implant or smoother. The abutment connection to the implant may be within the implant (internal connection) or sit on top of the implant (external connection).



**Figure 1.6** (A) An Astra Tech implant with a microthreaded conical top and a macrothreaded body. The entire surface has a dull appearance due to the surface treatment. (B) A Straumann implant with a conical design often used in immediate replacement protocols. There is a polished collar at the level where the soft tissue attaches.



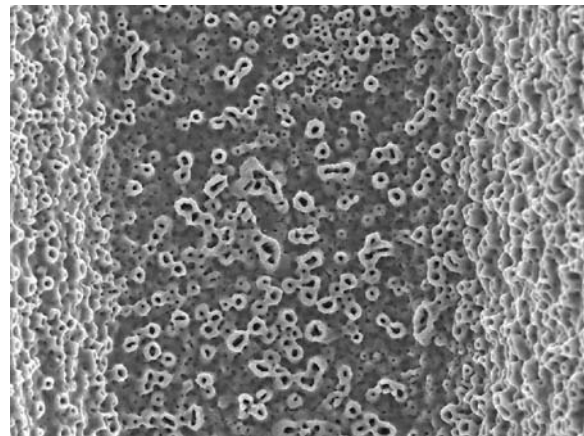
**Figure 1.7** An electron micrograph of a machined implant surface. The ridges and grooves on this Branemark implant are produced during the machining process.

### Surface Characteristics

The degree of surface roughness varies greatly between different systems. Surfaces that are machined, grit-blasted, etched, plasma sprayed, coated, and combination treated are available (Table 1.1).

The original Branemark implants have a machined surface as a result of the cutting of the screw thread. This has small ridges when viewed at high magnification (Fig. 1.7). This degree of surface irregularity was claimed to be close to ideal because smoother surfaces fail to osseointegrate and rougher surfaces are more prone to ion release and corrosion. However, most modern implants have a slightly rough surface that favors more rapid and higher levels of osseointegration (Fig. 1.8). Comparative tests in experimental animals have demonstrated a higher degree of bone to implant contact and higher torque removal forces than machined surfaces.

These surfaces can be produced in a number of ways. The earlier Astra Tech implants had a roughened surface produced by "grit blasting," in this case with titanium oxide particles. The resulting surface has approximately 5- $\mu$ m depressions over the entire intraosseous part of the implant. This surface treatment has more recently been modified to also incorporate fluoride ions (Fig. 1.9). The original Straumann



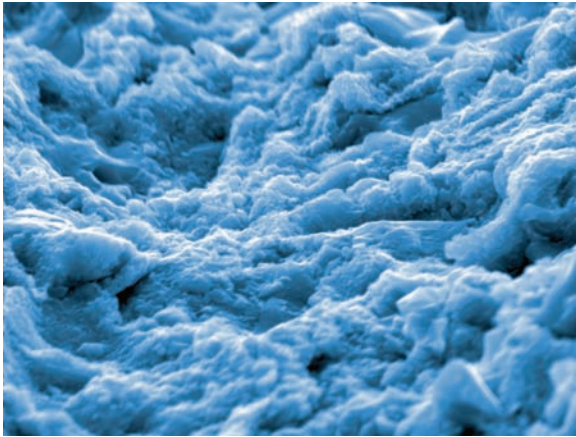
**Figure 1.8** An electron micrograph of the Nobel Biocare Ti-unite surface.

**Table 1.1** Implant Surface Sa Values


Smooth	<0.5 $\mu$ m	Polished
Minimally rough	0.5–1.0 $\mu$ m	Turned
Moderately rough	1.0–2.0 $\mu$ m	Modern surfaces
Rough	>2.0 $\mu$ m	TPS

*Abbreviations:* Sa, arithmetic mean of 3D roughness; TPS, titanium plasma sprayed.


surface was titanium plasma sprayed (TPS) (Fig. 1.10). Molten titanium is sprayed onto the surface of the implant to produce a very rough, almost porous surface. This type of surface is generally not used because of potential problems of peri-implantitis if it should become exposed to the oral environment. Straumann developed a newer surface called the SLA (sand blasted–large grit–acid etched) (Fig. 1.11). This technique produces a surface with large irregularities with smaller ones superimposed upon it. A newer version of SLA has been made more hydrophilic, which may further improve the speed of cell attachment and osseointegration.



**Figure 1.9** The Astra Tech osseospeed surface, which has fluoride ions incorporated.



**Figure 1.11** An electron micrograph of the Straumann SLA surface. *Abbreviation:* SLA, sand blasted–large grit–acid etched.




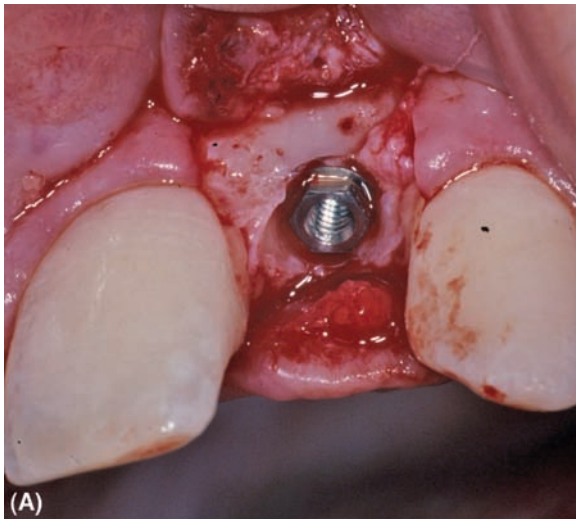
**Figure 1.10** An electron micrograph of the original titanium plasma-sprayed (TPS) surface used by Straumann.

The optimum surface morphology has yet to be defined, and some may perform better in certain circumstances. By increasing surface roughness there is the potential to increase the surface contact with bone, but this may be at the expense of more ionic exchange and surface corrosion. Bacterial contamination of the implant surface will also be affected by the surface roughness if it becomes exposed within the mouth. The current trend is therefore toward moderately roughened surfaces (Table 1.1).

### Implant-Abutment Design

Most implant systems have a wide range of abutments for various applications (e.g., single tooth, fixed dental prosthesis, overdenture) and techniques (e.g., standard manufactured abutments, preable abutments, cast design abutments, and various materials from titanium and gold to zirconium; see chaps. 13 and 14). However, the design of the implant-abutment junction varies considerably. The original Branemark implant-abutment junction is described as a flat top external hexagon (Fig. 1.12). The hexagon was designed to allow rotation (i.e., screwing in) of the implant during placement. It is an essential design feature in single tooth replacement as an anti-rotational device. The design proved to be very useful in the development of direct recording of impressions of the implant head rather than the abutment, thus allowing evaluation and abutment selection in the laboratory (see chap. 13). The abutment is secured to the implant with an abutment screw. The joint between implant and abutment is precise but does not produce a seal, a feature that does not appear to result in any clinical disadvantage. The hexagon is only 0.6 mm in height and it may be difficult for the inexperienced clinician to determine whether the abutment is precisely located on the implant. The fit is therefore normally checked radiographically, which also requires a good paralleling technique to adequately visualize the joint. Similar designs of external hexagon implants have increased the height of the hexagon, making abutment connection easier. The original design concept was that the weakest component of the system was the small gold screw (prosthetic screw) that secured the prosthesis framework to the abutment, followed by the abutment screw and then the implant (Fig. 1.12B). Thus, overloads leading to component/mechanical failure should be more readily dealt with (see chap. 16).

The Astra Tech implant system was one of the first bone level implant designs to incorporate a conical abutment fitting into the conical head of the implant, described by the manufacturers as a “conical seal” (Fig. 1.13). The taper of the cone is  $11^\circ$ , which is greater than a Morse taper ( $6^\circ$ ). The abutments self-guide into position and are easily placed even in very difficult locations. It is not usually necessary to check the localization with radiographs. This design produces a very secure, strong union. The standard abutments are either a solid one-piece




**Figure 1.12** (A) A Branemark implant placed in the lateral incisor region, showing the external hexagonal head. (B) A cross-section through an original Branemark implant stack. At the top of the stack a gold bridge screw connects a gold cylinder to a titanium abutment screw and the titanium cylinder that is in turn connected to the titanium implant.



**Figure 1.13** Section through a single tooth Astra Tech implant with a zirconium abutment, connected via an internal connection and titanium abutment screw.

component or two-piece components with an abutment screw to utilize the internal hexagon anti-rotation design.



**Figure 1.14** A cutaway section of a tissue level Straumann implant showing the internal abutment connection.

The tissue level Straumann implant has a smooth polished transmucosal collar to allow soft tissue adaptation, a feature that many of the other systems incorporate in the abutment design. The abutment-implant junction is therefore either supramucosal or just submucosal and therefore connection and checking of the fit of the components is easier than some systems. The implant-abutment junction also has an internal tapered conical design with an angle of  $8^\circ$  (Fig. 1.14).



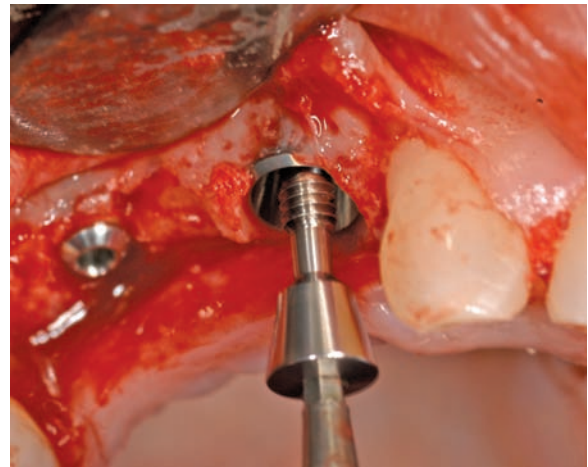
**Figure 1.15** The Nobel Replace internal abutment connection.

Many of the currently available implant systems have some of the features described above. They tend to have an internal connection between abutment and implant that is either parallel sided with a small area of flat surface at the top or a conical design (Fig. 1.15). Most feature an internal hexagonal/octagonal anti-rotational system with an abutment screw but some rely on the frictional fit of a Morse taper cone. With internal connection designs there has also been a trend to make the abutment diameter smaller than the implant head resulting in a “negative” margin. This so-called platform switching allows a greater volume of soft tissue in this region and may contribute to maintenance of implant bone levels by increasing the available surface distance in establishing the soft tissue biological width. The improved seal of internal connections may also reduce or eliminate bacterial ingress and subsequent inflammation that could affect bone levels.

### SUBMERGED AND NONSUBMERGED PROTOCOLS

The terms submerged and nonsubmerged implant protocols were at one time clearly applicable to different implant systems. The classic submerged system was the original protocol as described by Branemark. Implants are installed with the head of the implant and cover screw level with the crestal bone and the mucoperiosteal flaps closed over the implants and left to heal for several months (Fig. 1.16). This had several theoretical advantages:

1. Bone healing to the implant surface occurs in an environment free of potential bacterial colonization and inflammation.
2. Epithelialization of the implant-bone interface is prevented.
3. The implants are protected from loading and micromovement that could lead to failure of osseointegration and fibrous tissue encapsulation.



**Figure 1.16** A cover screw being placed into an Astra Tech implant before suturing of the flaps to bury the implants in a submerged two-staged technique.

The submerged system requires a second surgical procedure after a period of bone healing to expose the implant and attach a transmucosal abutment. The initial soft tissue healing phase would then take a further period of approximately two to four weeks. Abutment selection would take into account the thickness of the mucosa and the type of restoration.

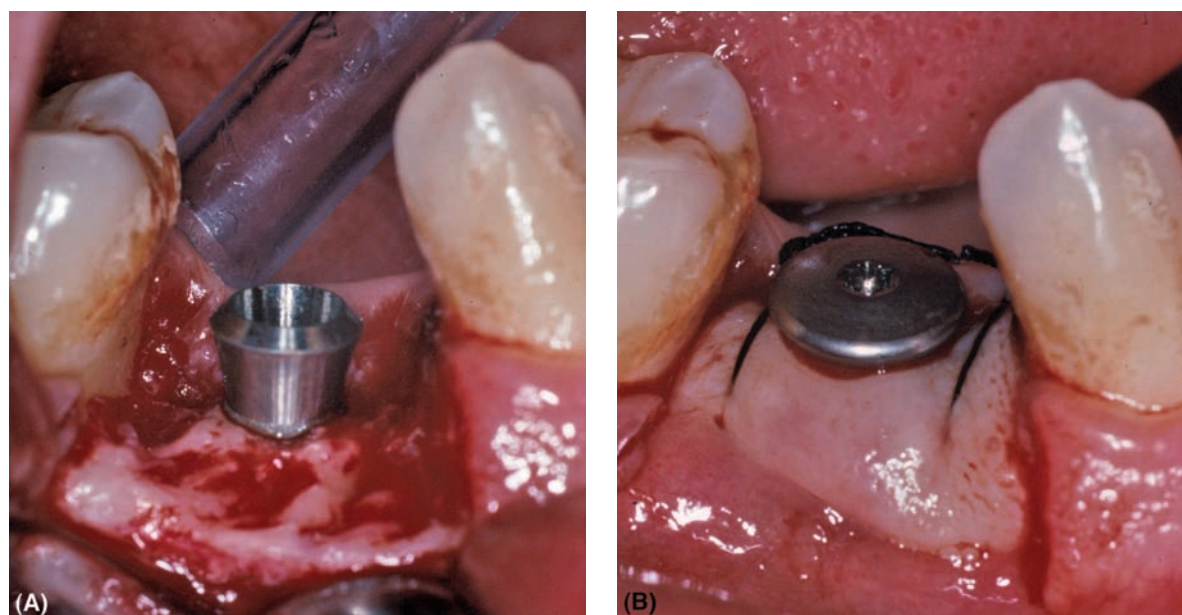
The best and first example of a nonsubmerged system is tissue level implant of Straumann. In this case, the implant is designed with an integral smooth collar that protrudes through the mucosa, and this allows the implant to remain exposed from the time of insertion (Fig. 1.17). The most obvious advantage is the avoidance of a second surgical procedure and more time for maturation of the soft tissue collar at the same time as the bone healing is occurring. Although this protocol does not comply with the three theoretical advantages enumerated above, the results are equally successful.

However, clinical development and commercial competition lead to many systems being used in either a submerged or a nonsubmerged fashion even though they were primarily designed for one or the other. The additional development of rapid treatment protocols involving immediate extraction/implant placement and early and immediate loading of prostheses has led to further development of single-stage non-submerged protocols (see chap. 11).

Another difference between systems designed for these protocols is the level of the implant-abutment junction in relationship to the bone. Many systems including Branemark/Nobel Biocare, Astra Tech, and Ankylos, and the newer Straumann bone level implant are designed such that the implant head is usually placed at the level of the bone or countersunk below the bone crest. At the time of abutment connection the interface with the implant is at the same level.

In the original Branemark system, it was observed that during the first year of loading the bone level receded to the level of the first thread and in following years most were relatively stable at this level (Fig. 1.2). The possible reasons for this initial bone change in the first year of loading have been proposed as

1. The threads of the implant provide a better distribution of forces to the surrounding bone than the parallel-sided head of the implant.



**Figure 1.17** (A) A 4.1-mm-diameter tissue level Straumann implant has been placed so that the polished collar is above the crest of the bone. (B) A closure screw has been placed on top of the implant and the flaps are sutured around the collar to leave the head of the implant exposed in a nonsubmerged fashion.

2. The establishment of a biological width for the investing soft tissues. The junctional epithelium is relocated on the implant and not on the abutment.
3. The interface between the abutment and implant is the apposition of two flat surfaces (flat top implant) that are held together by an abutment screw. This arrangement does not form a perfect seal and may allow leakage of bacteria or bacterial products from within the abutment/restoration, thereby promoting a small inflammatory lesion that may affect the apical location of the epithelial attachment.

However, in modern implants with a moderately rough surface and a good abutment-implant seal the bone often remains at the level of the implant head (Fig. 1.2B). The biological implication of this is that the junctional epithelium must be superficial to this and, therefore, located on the abutment/restoration. The possible reasons for this arrangement in contrast to the explanations given above for the loss of marginal bone are as follows:

1. The surface of the implant maintains bone height more effectively in the collar region. This may be due to the moderately rough surface or other design features such as the presence of microthreading.
2. The implant-abutment junction is a conical junction—a cone fitting within a cone—which provides a tighter seal, thereby eliminating microbial contamination/leakage at the interface and also producing a more mechanically sound union with less chance of micromovement. The ensuing stability of the junction may facilitate positional stability of the junctional epithelium.

The original Straumann implant-abutment interface is conceptually different to those described above. The integral smooth transmucosal collar of the implant is either 2.8 mm (with the

standard implant) or 1.8 mm long. The implant-abutment junction may be submucosal or supramucosal depending on the length of the transmucosal collar, the thickness of the mucosa, and the depth to which the implant has been placed. The end of the smooth collar coincides with the start of the roughened endosseous surface, which is designed to be located at the level of the bone at implant placement. There is, therefore, potential space for location of the junctional epithelium and connective tissue zone on the collar or neck of the implant at a level apical to the implant-abutment junction. Moreover, the implant-abutment junction is an effective conical seal. This would prevent any movement between the components and an interface that would prevent bacterial ingress.

The preceding considerations of the different implant systems reveal a number of basic differences:

1. The designed level of the implant-abutment interface.
2. The design characteristics at the implant-abutment interface in terms of mechanical stability and seal.
3. The macroscopic features of the implant and its surface characteristics.
4. The level of the transition of the surface characteristics on the implant surface.

This multitude of features has an impact on the level of the bone crest and the position of the junctional epithelium/connective tissue zone. Despite what appears to be a large and fundamental difference, the bone level comparison between the systems is clinically and radiographically very small (less than 1 mm at baseline values) and the maintenance of bone levels thereafter is very similar with all systems reporting highly effective long-term maintenance of bone levels. The differences reported in longitudinal trials are not sufficient to recommend one system over another.

## BONE FACTORS

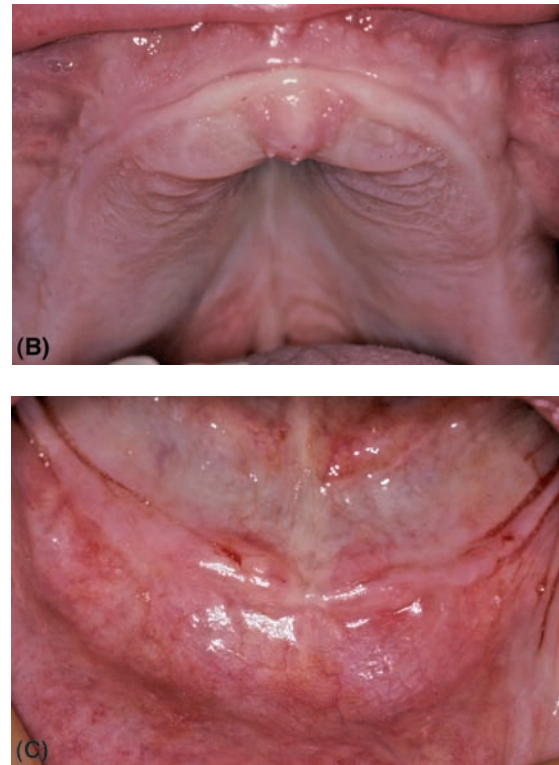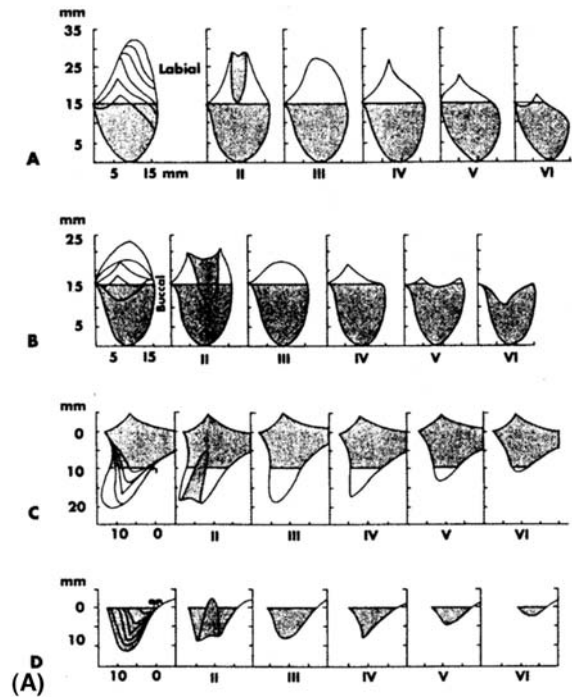
When an implant is first placed in the bone, there should be a close fit to ensure primary stability. The space between implant and bone is initially filled with blood clot and serum/bone proteins. Although great care is taken to avoid damaging the bone, the initial response to the surgical trauma is resorption, which is then followed by bone deposition. There is a critical period in the healing process at approximately two to three weeks post implant insertion when bone resorption will result in a lower degree of implant stability than that achieved initially. Subsequent bone formation will result in an increase in the level of bone contact and secondary stability. The stability of the implant at the time of placement is very important and is dependent on bone quantity and quality as well as implant design features considered above. The edentulous ridge can be classified in terms of shape (bone quantity) and bone quality. Following loss of a tooth, the alveolar bone resorbs in width and height (Fig. 1.18). In extreme cases, bone resorption proceeds to a level that is beyond the normal extent of the alveolar process and well within the basal bone of the jaws. Determination of bone quantity is considered in the clinical and radiographic sections of the treatment planning chapters. Assessing bone quality is rather more difficult. Plain radiographs can be misleading and sectional tomograms provide a better indication of medullary bone density (see chap. 2). In many cases the bone quality can only be confirmed at surgical preparation of the site. Bone quality can be assessed by measuring the cutting torque during preparation of the implant site. The primary stability (and subsequent secondary stability) of the implant can be quantified using resonance frequency analysis, which has proved to be useful in experimental trials and rapid treatment protocols.

The simplest categorization of bone quality is that described by Lekholm as types 1 to 4. Type 1 bone is predominantly cortical and may offer good primary stability at implant placement but is more easily damaged by overheating during the drilling process, especially with sites over 10 mm in depth. Types 2 and 3 are the most favorable quality of jaw bone for implant treatment. These types have a well-formed cortex and densely trabeculated medullary spaces with a good blood supply (type 2 has more cortex/dense trabeculation than type 3). Type 4 bone has a thin or absent cortical layer and sparse trabeculation. It offers poor primary implant stability and fewer cells with a good osteogenic potential to promote osseointegration, and has therefore been associated with higher rates of implant failure.

Healing resulting in osseointegration is highly dependent on a surgical technique that avoids heating the bone. Slow drilling speeds, the use of successive incrementally larger sharp drills, and copious saline irrigation aim to keep the temperature below that at which bone tissue damage occurs (approximately 47°C for 1 minute). Further refinements include cooling the irrigant and using internally irrigated drills. Methods by which these factors are controlled are considered in more detail in the surgical sections (see chaps. 7–11). Factors that compromise bone quality are infection, irradiation, and heavy smoking, which were dealt with earlier in this chapter.

## LOADING CONDITIONS

Osseointegrated implants lack the viscoelastic damping system and proprioceptive mechanisms of the periodontal ligament, which effectively dissipate and control forces. However, proprioceptive mechanisms may operate within bone and associated oral structures. Forces distributed directly to the



**Figure 1.18** (A) Classification of jaw resorption as described by Cawood and Howell (1991) showing cross-sectional profiles through different regions, 1 = anterior mandible, 2 = posterior mandible, 3 = anterior maxilla, 4 = posterior maxilla. (B) An example of an edentulous maxilla that would be clinically classified as class 3 in both the anterior and posterior regions. Although the ridges appear broad, there may be little bone in the posterior regions, due to the extension of the maxillary air sinuses. (C) An example of a severely resorbed edentulous mandible would be classified as class 5 or 6. Confirmation would require radiographic examination.

bone are usually concentrated in certain areas, particularly around the neck of the implant. Excessive forces applied to the implant may result in remodeling of the marginal bone, that is, apical movement of the bone margin with loss of osseointegration. The exact mechanism of how this occurs is not entirely clear, but it has been suggested that microfractures may propagate within the adjacent bone. Bone loss caused by excessive loading may be slowly progressive. In rare cases it may reach a point where there is catastrophic failure of the remaining osseointegration or fracture of the implant. Excessive forces may be detected prior to this stage through radiographic marginal bone loss or mechanical failure of the prosthodontic superstructure and/or abutments (see chap. 16).

It has been shown that normal/well-controlled forces may result in increases in the degree of bone to implant contact. Adaptation is limited, and osseointegration does not permit movement of the implant in the way that a tooth may be orthodontically repositioned. Therefore, the osseointegrated implant has proved itself to be a very effective anchorage system for difficult orthodontic cases.

### Loading Protocols

Loading protocols, that is the duration of time between implant insertion and functional loading, have been largely empirical. The time allowed for adequate bone healing should be based on clinical trials that test the effects of factors such as bone quality, loading factors, implant type, etc. However, there is very limited data on the effects of these complex variables and currently there is no accurate measure that precisely determines the optimum period of healing before loading can commence. This has not limited the variety of protocols advocated, including the following:

- Delayed loading (for 3–6 months)
- Early loading (e.g., at 6 weeks)
- Immediate loading

#### *Delayed Loading*

This has been the traditional approach and has much to commend it as it is tried, tested, and predictable. Following installation of an implant, all loading is avoided during the early healing phase. Movement of the implant within the bone at this stage may result in fibrous tissue encapsulation rather than osseointegration. In partially dentate subjects, it may be desirable to provide temporary/provisional prostheses that are tooth supported. However, in patients who wear mucosally supported dentures, it has been recommended that they should not be worn over the implant area for one to two weeks. In the edentulous maxilla, we would normally advise that a denture is not worn for one week and in the mandible for two weeks because of the poorer stability of the soft tissue wound and smaller denture-bearing surface. Patients can normally wear removable partial prostheses directly after surgery, provided they are adequately relieved. The original Branemark protocol then advised leaving implants unloaded and buried beneath the mucosa for approximately six months in the maxilla and three months in the mandible, due mainly to differences in bone quality. Nowadays the majority of delayed loading protocols recommend a maximum three-month healing period for both jaws.

#### *Early Loading*

Many modern systems with moderately rough implant surfaces now advocate a healing period of just six weeks before

loading. Some caution is recommended in that the implants should be placed in good quality bone in situations that are not subjected to high loads.

#### *Immediate Loading*

It has also been demonstrated that immediate loading is compatible with subsequent successful osseointegration, provided the bone quality is good and the functional forces can be adequately controlled. In studies on single tooth restorations, the crowns are usually kept out of contact in intercusp and lateral excursions, thereby almost eliminating functional loading until a definitive crown is provided. In contrast, fixed bridgework allows connection of multiple implants providing good splinting and stabilization and therefore has been tested in immediate loading protocols with good success. However, the clinician should have a good reason to adopt the early/immediate loading protocols particularly as they are likely to be less predictable.

The early and immediate loading protocols are dealt with in more detail in chapter 11. The long-term functional loading of the implant-supported prosthesis is a further important consideration that is dealt with in the following section.

## PROSTHETIC LOADING CONSIDERATIONS

Carefully planned functional occlusal loading will result in maintenance of osseointegration. In contrast, excessive loading may lead to bone loss and/or component failure. Clinical loading conditions are largely dependent on the following factors.

### The Type of Prosthetic Reconstruction

This can vary from a single tooth replacement in the partially dentate case to a full arch reconstruction in the edentulous individual. Implants that support overdentures may present particular problems with control of loading as they may be largely mucosal supported, entirely implant supported, or a combination of the two.

### The Occlusal Scheme

The lack of mobility in implant-supported fixed prostheses requires provision of shallow cuspal inclines and careful distribution of loads in lateral excursions. With single tooth implant restorations, it is important to develop initial tooth contacts on the natural dentition and to avoid guidance in lateral excursions on the implant restoration. Loading will also depend on the opposing dentition, which could be natural teeth, another implant-supported prosthesis, or a conventional removable prosthesis. Surprisingly high forces can be generated through removable prostheses.

### The Number, Distribution, Orientation, and Design of Implants

The distribution of load to the supporting bone can be spread by increasing the number and dimensions (diameter, surface topography, length) of the implants. The spacing and three-dimensional arrangement of the individual implants will also be very important, and is dealt with in detail in chapter 5.

### The Design and Properties of Implant Connectors

Multiple implants are usually joined by a rigid framework. This provides good splinting and distribution of loads between implants. It is equally important that the framework has a passive fit on the implant abutments so that loads are not set

up within the prosthetic construction. However, some clinicians advocate restoring multiple implants as single unsplinted units—this requires sufficient space for an implant per tooth unit and consequently a higher number of implants.

### Dimensions and Location of Cantilever Extensions

Some implant reconstructions are designed with cantilever extensions to provide function (and appearance) in areas where provision of additional implants is difficult. This may be due to practical or financial considerations. Cantilever extensions have the potential to create high loads, particularly on the implant adjacent to the cantilever. The extent of the leverage of any cantilever should be considered in relation to the anteroposterior distance between implants at the extreme ends of the reconstruction. This topic is dealt with in more detail in chapters 5 and 14.

### Patient Parafunctional Activities

Great caution should be exercised in treating patients with known parafunctional activities.

### CHOICE OF AN IMPLANT SYSTEM

In routine cases it may not matter which system is chosen, this is particularly the case with treatment in the anterior mandible. However, in our experience, choice of a system in any particular case depends on the following:

- The aesthetic requirements
- The available bone height, width, and quality (including whether the site has been grafted)
- Perceived restorative difficulties
- Desired surgical protocol

Therefore, we would suggest the following:

- In the aesthetic zone, choose an implant where the crown contour can achieve good emergence from the soft tissue with a readily maintainable healthy submucosal margin.
- Choose an implant of the appropriate length and width for the existing crestal morphology. Ensure that choice of a reduced width implant does not compromise strength in the particular situation.
- If the site will only accommodate a short implant or if the bone quality is poor or grafted, then splinting of implant units is more important.
- If there are likely to be difficulties with prosthodontic construction due to difficult angulation of the implants, choose a system that is versatile enough to cope with these difficulties, that is, has a good range solutions/components.
- If you wish to use a rapid treatment protocol, then choose a system that has a proven published record with that particular protocol.

### BIBLIOGRAPHY

Abrahamsson I, Berglundh T. Effects of different implant surfaces and designs on marginal bone-level alterations: a review. *Clin Oral Implants Res* 2009; 20(suppl 4):207–215.

Adell R, Eriksson B, Lekholm U, et al. A 15 year study of osseointegrated implants in the treatment of the edentulous jaw. *Int J Oral Surgery* 1981; 10:387–416.

Adell R, Eriksson B, Lekholm U, et al. A long-term follow-up study of osseointegrated implants in the treatment of totally edentulous jaws. *Int J Oral Maxillofac Implants* 1990; 5:347–359.

Aglietta M, Siciliano VI, Rasperini G, et al. A 10-year retrospective analysis of marginal bone-level changes around implants in periodontally healthy and periodontally compromised tobacco smokers. *Clin Oral Implants Res* 2011; 22(1):47–53.

Albrektsson T, Zarb GA, Worthing DP, et al. The long-term efficacy of currently used dental implants. A review and proposed criteria of success. *Int J Oral Maxillofac Implants* 1986; 1:11–25.

Alsaadi G, Quirynen M, Komárek A, et al. Impact of local and systemic factors on the incidence of late oral implant loss. *Clin Oral Implants Res* 2008; 19:670–676.

Astrand P, Engquist B, Dahlgren S, et al. Astra Tech and Branemark system implants: a 5-year prospective study of marginal bone reactions. *Clin Oral Implants Res* 2004; 15:413–420.

Bain CA, Moy PK. The association between the failure of dental implants and cigarette smoking. *Int J Oral Maxillofac Implants* 1993; 8:609–615.

Berglundh T, Lindhe J, Ericsson I, et al. The soft tissue barrier at implants and teeth. *Clin Oral Implants Res* 1991; 2:81–90.

Buser D, Mericske-Stern R, Bernard JP, et al. Long-term evaluation of non-submerged ITI implants. Part 1: 8-year life table analysis of a prospective multi-center study with 2359 implants. *Clin Oral Implants Res* 1997; 8:161–172.

Canullo L, Fedele GR, Iannello G, et al. Platform switching and marginal bone-level alterations: the results of a randomized-controlled trial. *Clin Oral Implants Res* 2010; 21:115–121.

Cawood JJ, Howell RA. A classification of the edentulous jaws. *Int J Oral Maxillofac Surg* 1988; 17:232–236.

Cawood JJ, Howell RA. Reconstructive preprosthetic surgery. I. Anatomical considerations. *Int J Oral Maxillofac Surg* 1991; 20:75–82.

Esposito M, Coulthard P, Thomsen P, et al. Interventions for replacing missing teeth: different types of dental implants. *Cochrane Database Syst Rev* 2007; (4):CD003815.

Fransson C, Lekholm U, Jemt T, et al. Prevalence of subjects with progressive bone loss at implants. *Clin Oral Implants Res* 2005; 16:440–446.

Friberg B, Grondahl K, Lekholm U, et al. Long-term follow-up of severely atrophic edentulous mandibles reconstructed with short Branemark implants. *Clin Implant Dent Relat Res* 2000; 2:184–189.

Friberg B, Jemt T, Lekholm U. Early failures in 4,641 consecutively placed Branemark dental implants: a study from stage 1 surgery to the connection of completed prostheses. *Int J Oral Maxillofac Implants* 1991; 6:142–146.

Gunne J, Astrand P, Lindh T, et al. Tooth-implant and implant supported fixed partial dentures: a 10-year report. *Int J Prosthodont* 1999; 12:216–221.

Hammerle CH, Wagner D, Bragger U, et al. Threshold of tactile sensitivity perceived with dental endosseous implants and natural teeth. *Clin Oral Implants Res* 1995; 6:83–90.

Hansson S. The implant neck: smooth or provided with retention elements. A biomechanical approach. *Clin Oral Implants Res* 1999; 10:394–405.

Hansson S. A conical implant-abutment interface at the level of the marginal bone improves the distribution of stresses in the supporting bone. An axisymmetric finite element analysis. *Clin Oral Implants Res* 2003; 14:286–293.

Hardt CR, Grondahl K, Lekholm U, et al. Outcome of implant therapy in relation to experienced loss of periodontal bone support: a retrospective 5-year study. *Clin Oral Implants Res* 2002; 13:488–494.

Hermann JS, Buser D, Schenk RK, et al. Biologic Width around one- and two-piece titanium implants. *Clin Oral Implants Res* 2001; 12:559–571.

Hinode D, Tanabe S, Yokoyama M, et al. Influence of smoking on osseointegrated implant failure: a meta-analysis. *Clin Oral Implants Res* 2006; 17:473–478.

Isidor F. Histological evaluation of peri-implant bone at implants subjected to occlusal overload or plaque accumulation. *Clin Oral Implants Res* 1997; 8:1–9.

Isidor F. Influence of forces on peri-implant bone. *Clin Oral Implants Res* 2006; 17(suppl 2):8–18.

- Jacobs R, Manders E, Van LC, et al. Evaluation of speech in patients rehabilitated with various oral implant-supported prostheses. *Clin Oral Implants Res* 2001; 12:167-173.
- Jaffin RA, Berman CL. The excessive loss of Branemark fixtures in type IV bone: a 5-year analysis. *J Periodontol* 1991; 62:2-4.
- Karoussis IK, Salvi GE, Heitz-Mayfield LJ, et al. Long-term implant prognosis in patients with and without a history of chronic periodontitis: a 10-year prospective cohort study of the ITI Dental Implant System. *Clin Oral Implants Res* 2003; 14:329-339.
- Lekholm U, Grondahl K, Jemt T. Outcome of oral implant treatment in partially edentulous jaws followed 20 years in clinical function. *Clin Implant Dent Relat Res* 2006; 8:178-186.
- Lindquist LW, Carlsson GE, Jemt T. A prospective 15-year follow-up study of mandibular fixed prostheses supported by osseointegrated implants. *Clinical results and marginal bone loss. Clin Oral Implants Res* 1996; 7:329-336.
- Lindquist LW, Carlsson GE, Jemt T. Association between marginal bone loss around osseointegrated mandibular implants and smoking habits: a 10-year follow-up study. *J Dent Res* 1997; 76:1667-1674.
- Listgarten MA, Lang NP, Schroeder HE, et al. Periodontal tissues and their counterparts around endosseous implants. *Clin Oral Implants Res* 1991; 2:1-19.
- Mombelli A, Cionca N. Systemic diseases affecting osseointegration therapy. *Clin Oral Implants Res* 2006; 17(suppl 2):97-103.
- Neukam FW, Flemmig TF. Local and systemic conditions potentially compromising osseointegration. *Clin Oral Implants Res* 2006; 17(suppl 2):160-162.
- Palmer RM, Howe LC, Palmer PJ. A prospective 3-year study of fixed bridges linking Astra Tech ST implants to natural teeth. *Clin Oral Implants Res* 2005; 16:302-307.
- Pikner SS, Gröndahl K, Jemt T, et al. Marginal bone loss at implants: a retrospective, long-term follow-up of turned Branemark System implants. *Clin Implant Dent Relat Res* 2009; 11:11-23.
- Quirynen M, Vogels R, Alsaadi G, et al. Predisposing conditions for retrograde peri-implantitis, and treatment suggestions. *Clin Oral Implants Res* 2005; 16:599-608.
- Renouard F, Nisand D. Impact of implant length and diameter on survival rates. *Clin Oral Implants Res* 2006; 17(suppl 2):35-51.
- Rompen E, Domken O, Degidi M, et al. The effect of material characteristics, of surface topography and of implant components and connections on soft tissue integration: a literature review. *Clin Oral Implants Res* 2006; 17(suppl 2):55-67.
- Safii SH, Palmer RM, Wilson RF. Risk of implant failure and marginal bone loss in subjects with a history of periodontitis: a systematic review and meta-analysis. *Clin Implant Dent Relat Res* 2010; 12:165-174.
- Schnitman P, Wohrle PS, Rubenstein JE, et al. Ten year results for Brånemark implants immediately loaded with fixed bridge prostheses at implant placement. *Int J Oral Maxillofac Implants* 1997; 12:495-503.
- Sennerby L, Ericson LE, Thomsen P, et al. Structure of the bone-titanium interface in retrieved clinical oral implants. *Clin Oral Implants Res* 1991; 2:103-111.
- Smith DE, Zarb GA. Criteria for success of osseointegrated endosseous implants. *J Prosthet Dent* 1989; 62:567-572.
- Ulm C, Kneissel M, Schedle A, et al. Characteristic features of trabecular bone in edentulous maxillae. *Clin Oral Implants Res* 1999; 10:459-467.
- van Steenberghe SD, Jacobs R, Desnyder M, et al. The relative impact of local and endogenous patient-related factors on implant failure up to the abutment stage. *Clin Oral Implants Res* 2002; 13:617-622.
- von Wowern N. Variations in bone mass within the cortices of the mandible. *Scand J Dent Res* 1977; 85:444-455.
- Wennerberg A, Albrektsson T, Andersson B, et al. A histomorphometric and removal torque study of screw-shaped titanium implants with three different surface topographies. *Clin Oral Implants Res* 1995; 6:24-30.
- Westwood RM, Duncan JM. Implants in adolescents: a review and case reports. *Int J Oral Maxillofac Implants* 1996; 11:750-755.
- Yerit KC, Posch M, Seemann M, et al. Implant survival in mandibles of irradiated oral cancer patients. *Clin Oral Implants Res* 2006; 17:337-344.

## Treatment planning for implant restorations: general considerations

### INTRODUCTION

This chapter provides an overall view of treatment planning. The reader should consult the chapters on planning for single tooth restorations, fixed bridges, and overdentures for more detailed considerations. The treatment plan should begin with a clear idea of the desired end result of treatment, which should fulfill the functional and aesthetic requirements of the patient. It is important that these treatment goals are realistic, predictable, and readily maintainable. Realistic means that the end result can be readily achieved and is not unduly optimistic. Predictable means that there is a very high chance of success of achieving the end result and that the prosthesis will function satisfactorily in the long term. The prosthesis should withstand normal wear and tear and not be subject to undue mechanical and technical complications (see chap. 16). Readily maintainable means that the prosthesis does not compromise the patient's oral hygiene and increases the patient's susceptibility to inflammation of the peri-implant tissues (see chap. 16 on peri-implant mucositis and peri-implantitis) and that the "servicing" implications for the patient and the dentist are acceptable.

In this chapter, it will be assumed that treatment options other than implant-retained restorations have been considered and there are no relevant contraindications (see chap. 1). Evaluation begins with a patient consultation and assessment of the aesthetic and functional requirements, and proceeds to more detailed planning with intraoral examination, diagnostic setups, and appropriate radiographic examination. At all stages in this process it is important to establish and maintain good communication (verbal and written) with the patient to ensure that they understand the proposed treatment plan and the alternatives.

Aesthetic considerations assume great importance in most patients with missing anterior teeth. This is an increasing challenge for the clinician and is related to

1. the degree of coverage of the anterior teeth (and gingivae) by the lips during normal function and smiling (Figs. 2.1A–C and 2.2A–C);
2. the degree of ridge resorption, both vertically and horizontally (Fig. 2.3A–C);
3. provision of adequate lip support (Fig. 2.4A,B).

The appearance of the planned restoration can be judged by producing a diagnostic setup on study casts or providing a provisional diagnostic prosthesis (Fig. 2.5A–C). The latter usually proves to be more informative for the patients as they can judge the appearance in their own mouth and even wear it for extended periods to adequately assess it. Both diagnostic casts and provisional prostheses can serve as a model for the fabrication of

1. a radiographic stent to assess tooth position in relation to the underlying ridge profile (Fig. 2.5D);
2. a surgical stent (or guide) to assist the surgeon in the optimal placement of the implants (Fig. 2.5E–H);
3. a transitional restoration during the treatment program (Fig. 2.5C).

Ideally, patients should be examined with and without their current or diagnostic prosthesis to assess

- facial contours;
- lip support;
- tooth position;
- how much of the prosthesis is revealed during function;
- occlusal relationships.

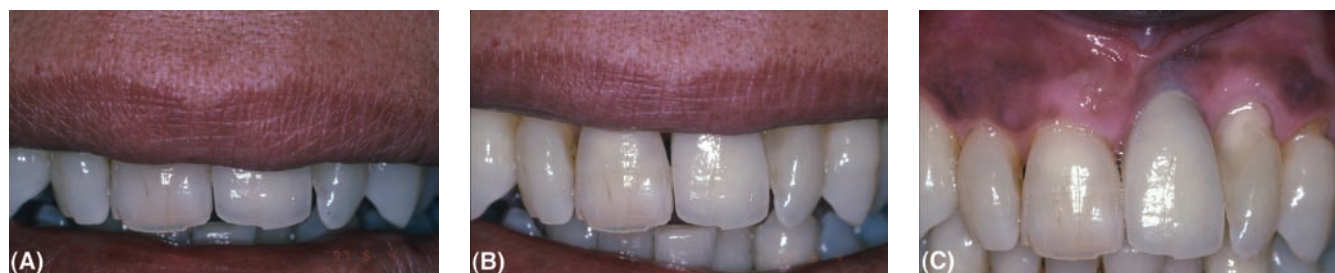The diagnostic setup should then be adjusted if necessary to fulfill the requirements of the desired end result before proceeding with treatment.

Reduced or insufficient function is a common complaint for patients who have removable dentures or who have lost many molar teeth. Functional inadequacy is often a perceived problem of the patient and is assessed by interview rather than any specific clinical measure. The variation between individuals in how they perceive this problem is large. In patients who are accustomed to an intact arch of teeth from second molar to second molar, the loss of a single molar can be completely unacceptable, and replacement with a conventional fixed prosthesis or implant restoration becomes necessary. In contrast, a shortened dental arch extending to the first molar or second premolar may provide adequate function and appearance for some patients. However, missing maxillary premolars (and occasionally first molars) often present an aesthetic problem.

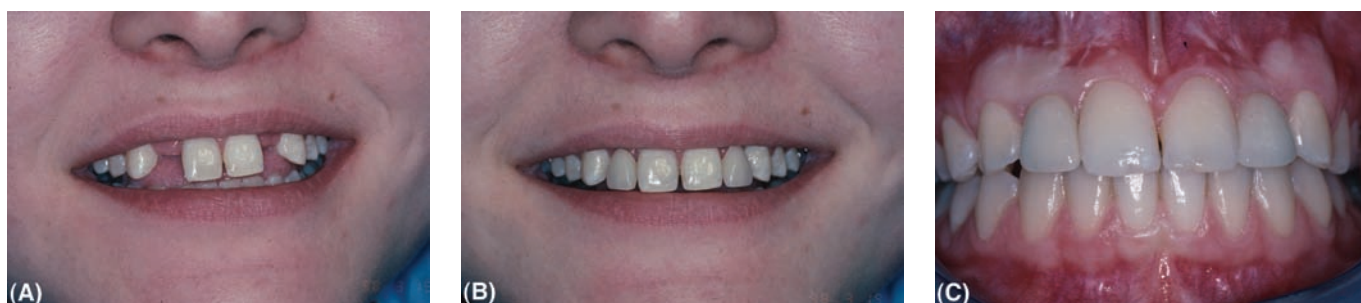Provisional dentures can be used to clarify these needs, for example how many posterior units are required to satisfy both appearance and function.

### INITIAL CLINICAL EXAMINATION

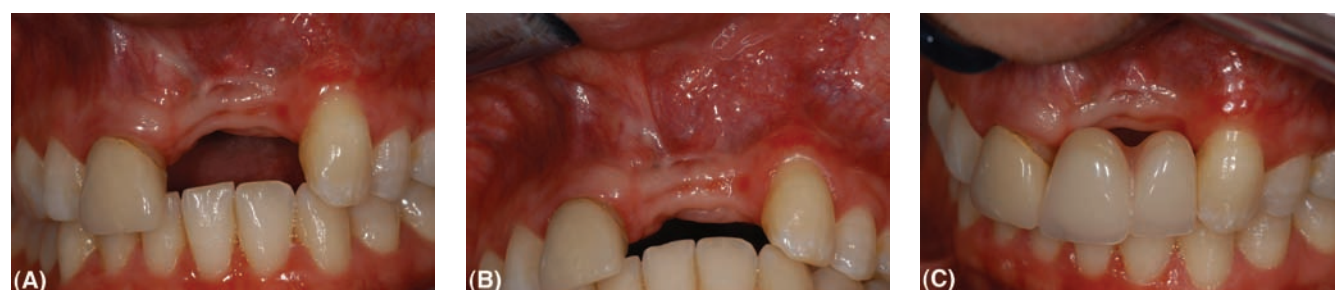A thorough extraoral and intraoral clinical examination should be carried out on all patients to ensure diagnosis of all existing dental and oral disease. The diagnosis and management of caries, periodontal disease, and endodontic problems is not the remit of this book and the reader is referred to other more relevant texts. However, it is very important to remember that susceptibility to periodontitis is associated with more implant loss and peri-implantitis, and implants placed close to apical endodontic lesions may fail. Factors of more specific relevance to implant treatment are dealt with here and in the related more detailed sections on single teeth, fixed bridges, and overdentures.



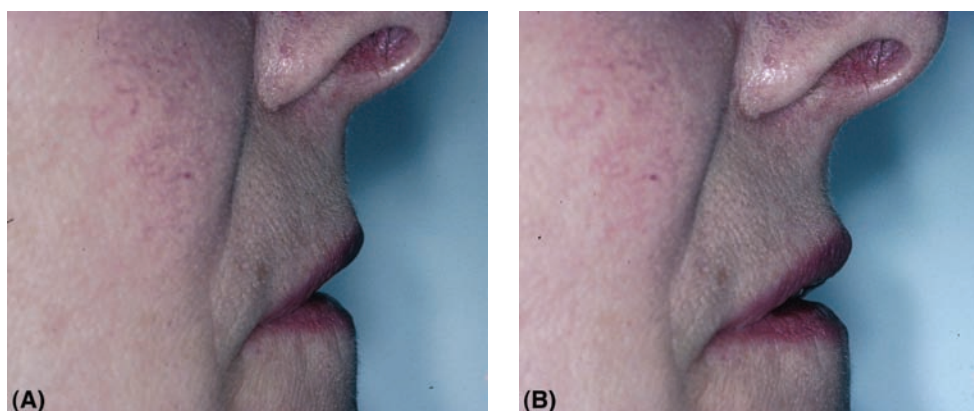
**Figure 2.1** (A) In normal function this patient reveals the incisal half of the anterior teeth. (B) The same patient smiling reveals most of the crowns of the teeth, but not the gingival margins. (C) The patient with the lips retracted showing a gross discrepancy of the gingival margins that is not visible in normal function and smiling.



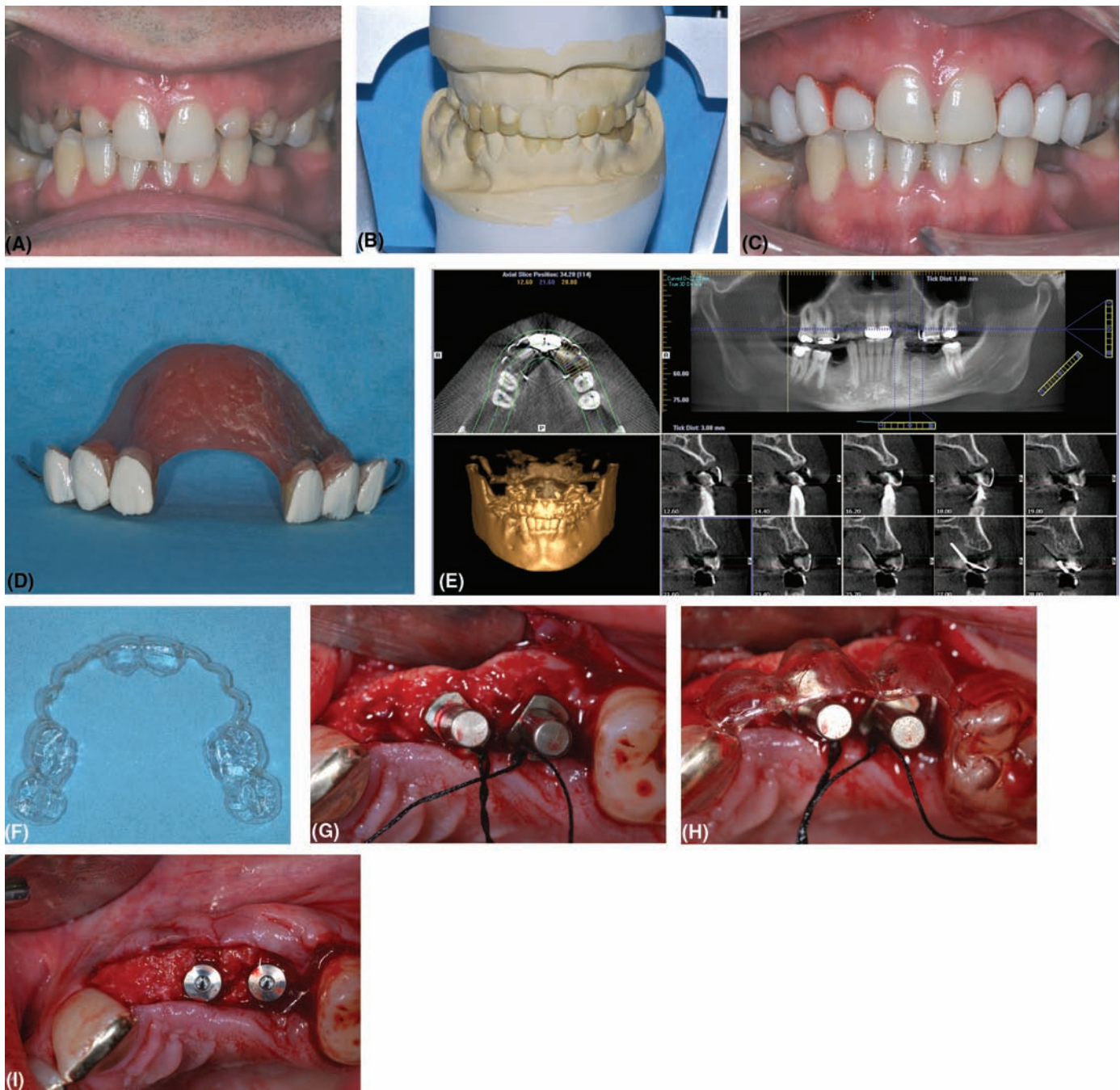
**Figure 2.2** (A) A young patient with missing maxillary lateral incisors. (B) The same patient wearing an existing partial denture allows assessment of the aesthetics and tooth position. (C) The completed result with two single tooth implants replacing the lateral incisors.



**Figure 2.3** (A) A patient with missing maxillary central and lateral incisor, showing loss of vertical ridge height. (B) The occlusal view shows some loss of ridge width. (C) The patient wearing a removable prosthesis showing the discrepancy between the tooth height and the underlying ridge form.



**Figure 2.4** (A) Profile of a patient wearing a removable denture with a labial flange to provide lip support. (B) Profile of the same patient showing poorer lip support, following removal of the labial flange.

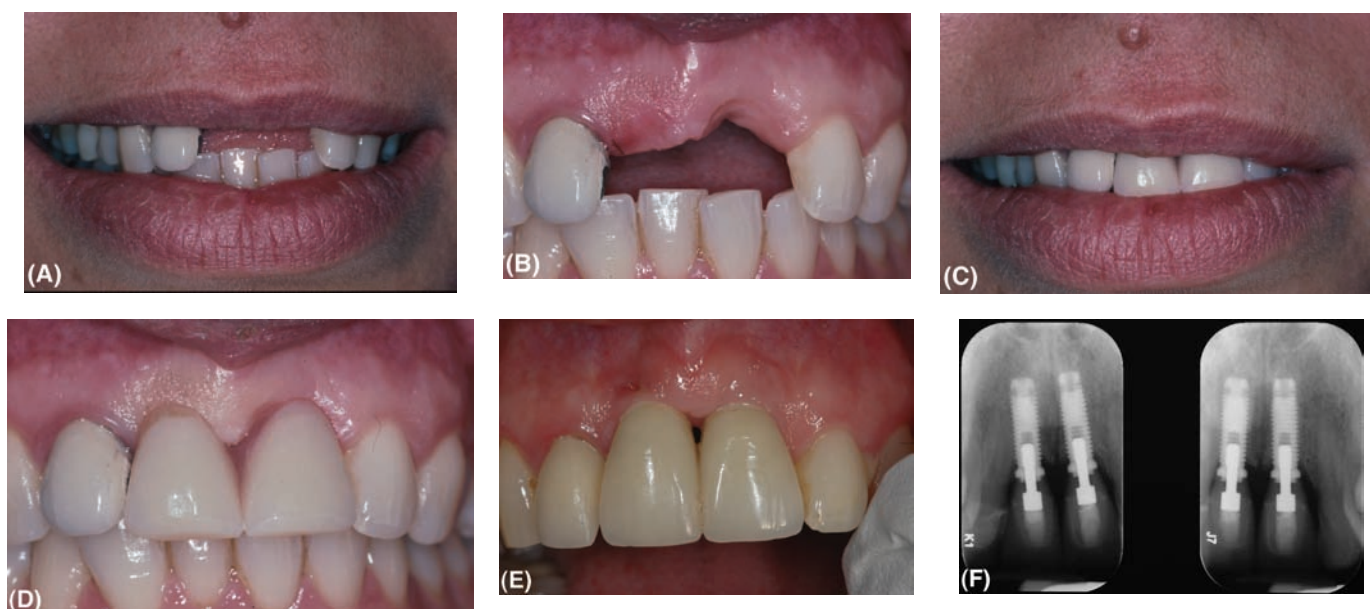


**Figure 2.5** (A) A patient with severe hypodontia and retained deciduous teeth in the maxillary lateral incisor, canine, and premolar areas. (B) Articulated study casts with a diagnostic wax-up. (C) The patient has been fitted with an immediate replacement partial denture based on information from the diagnostic wax-up. (D) The partial denture has been coated on the labial surfaces with a radiopaque medium (TempBond). (E) A cone-beam CT of the same patient wearing the denture with radiopaque medium. The outline of the teeth can be seen in relationship to the underlying ridge form. (F) A blowdown plastic surgical stent constructed based on the diagnostic denture. (G) Direction indicator placed in the implant site preparations at surgery. (H) The surgical stent in place showing a good relationship between the indicator post and the planned tooth position. (I) The implants inserted and cover screws placed.

### Evaluation of the Edentulous Space or Ridge

The height, width, and contour of the edentulous ridge can be visually assessed and carefully palpated (Fig. 2.6A–F). The presence of concavities/depressions (especially on the labial aspects) is usually readily detected. However, accurate assessment of the underlying bone width is difficult especially where

the overlying tissue is thick and fibrous. This occurs particularly on the palate where the tissue may be very thick/dense and can result in a very false impression of the bone profile. The thickness of the soft tissue can be measured by puncturing the soft tissue with a calibrated probe after administering local anesthetic or carrying out a more detailed ridge mapping.

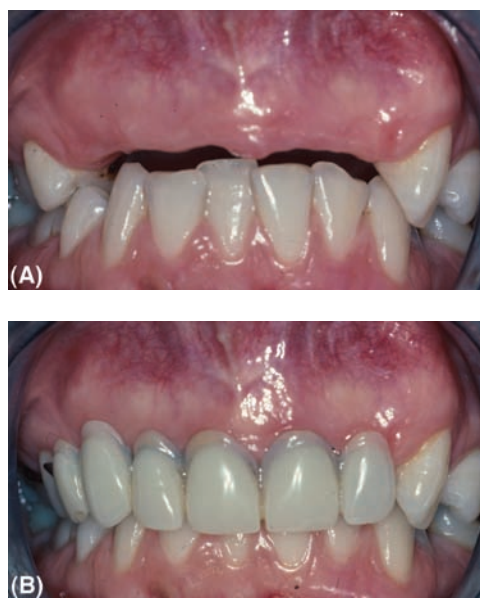


**Figure 2.6** (A) A patient with missing maxillary central incisors following loss of a fixed prosthesis. (B) The intraoral view showing good ridge height at tooth 11 but loss of vertical height at tooth 21. (C) The patient with a diagnostic denture in place with lips at rest. (D) The intraoral appearance of the diagnostic denture. There is no labial flange and the discrepancy in ridge height between teeth 11 and 21 is less obvious. This patient was treated without the ridge augmentation. (E) The same patient treated with single tooth implants after a period of eight years. The clinical crown heights of the central incisors are symmetrical but longer than the adjacent natural teeth. (F) The radiographs eight years following treatment showing ideal bone levels at the first thread of the Branemark implants. The abutments and crowns are ceramic.

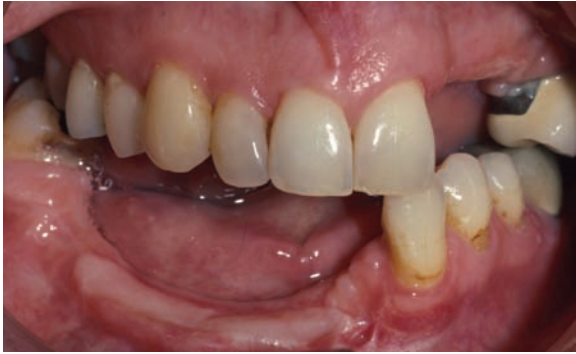However, 3D tomography to examine the bone profile is more commonly used (Fig. 2.5E).

The profile/angulation of the ridge and its relationship to the opposing dentition is also important. The distance between the edentulous ridge and the opposing dentition should be measured to ensure that there is adequate room for the prosthodontic components (Fig. 2.7). This will vary with the implant system being used and whether the prosthesis is to be cemented or screw retained. Retention of a cemented prosthesis is dependent on the abutment height and parallelism (which is more readily achieved with CAD-CAM technology), whereas a screw-retained prosthesis has to have sufficient height to accommodate the abutment/abutment screw and prosthesis-retaining screw (ideally with sufficient place to place a protective restoration over it). These factors are dealt with in more detail in chapters 13 and 14. Proclined ridge forms will tend to lead to proclined placement of the implants that could affect loading and aesthetics, especially if a screw-retained prosthesis requires angulated abutments. Increased vertical space between opposing jaws (Fig. 2.8) will result in a prosthesis with an increased vertical height that will be subject to higher leverage forces. Large horizontal discrepancies between the jaws, for example, the pseudo class 3 jaw relationship following extensive maxillary resorption must be recognized, and management appropriately planned. This may be solved by prescription of an overdenture treatment (see chaps. 6 and 15) or extensive grafting/orthognathic surgery (see chap. 12).

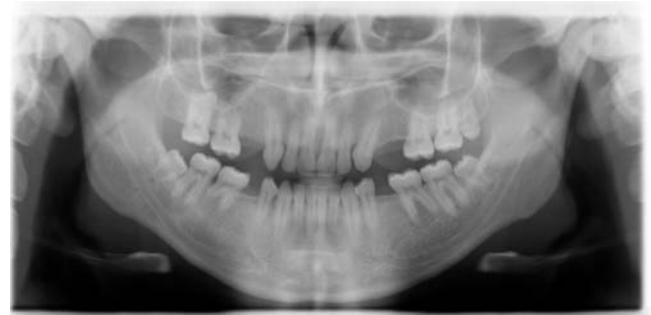The clinical examination of the ridge also allows assessment of the soft tissue thickness, which is important for the attainment of good aesthetics. Keratinized tissue, which is attached to the edentulous ridge, will also generally provide



**Figure 2.7** (A) A patient with missing maxillary anterior teeth in whom the lower incisors nearly touch the soft tissue ridge in centric occlusion. The space available for implant components will depend on the level of placement of the implant heads in the underlying bone. (B) The same patient with the existing partial denture. The prosthetic teeth have been ridge-lapped and no labial flange has been provided. The denture teeth produce a considerable overlap of the existing ridge. Implants would have to be placed in a submerged position to allow an emergence of the implant crowns at the cervical level of these teeth.



**Figure 2.8** This patient has suffered extensive loss of mandibular bone following a road traffic accident that resulted in a fractured mandible and osteomyelitis. There is now a marked vertical and horizontal discrepancy between the jaws.



**Figure 2.9** A dental panoramic tomogram provides a very good radiograph to show the major anatomical features of the jaws in relation to the existing teeth. This patient has good bone height in the premolar regions of the upper and lower jaw. The maxillary sinuses do not encroach upon the maxillary premolar sites and the mental nerve and inferior dental nerve are located well apically.

a better peri-implant soft tissue than nonkeratinized mobile mucosa. The mesiodistal length of the edentulous ridge can be measured to give an indication of the possible number of implants that could be accommodated (see chap. 1). This is best done with calipers and a millimeter rule. The space should be measured between the tips of the crowns, the maximum contour of the crowns, and at the level of the edentulous ridge. However, this also requires reference to

1. radiographs to allow a correlation with available bone volume;
2. the diagnostic setup for the proposed tooth location;
3. the edentulous ridges bound by teeth; the available space will also be affected by angulation of adjacent tooth roots, which may be palpated and assessed radiographically.

### INITIAL RADIOGRAPHIC SCREENING

A screening radiograph should give the clinician an indication of

1. overall anatomy of the maxilla and mandible and potential vertical height of available bone;
2. anatomical anomalies or pathological lesions;
3. sites where it may be possible to place implants without grafting and sites that would require grafting;
4. restorative and periodontal status of remaining teeth;
5. length, shape, angulation, and proximity of adjacent tooth roots.

In many instances the dental panoramic tomograph (DPT) is the radiograph of choice (Fig. 2.9). It provides an image within a predefined focal trough of both upper and lower jaws that gives a reasonable approximation of bone height, the position of the inferior dental neurovascular bundle, the size and position of the maxillary antra, and any pathological conditions that may be present. It is therefore an ideal view for initial treatment planning and for providing patient information as it presents the image in a way that many patients are able to understand. Some areas may not be imaged particularly well, but this can be minimized by ensuring that the patient is positioned correctly in the machine and that the appropriate program is selected. It provides more information about associated anatomical structures than periapical radio-

graphs but with less fine detail of the teeth. It should be remembered that all DPTs are magnified images (at approximately  $\times 1.3$ ). Distortion also occurs in the anteroposterior dimension reducing their usefulness when planning implant spacing/numbers. The initial screening radiograph allows selection of the most appropriate radiographic examination for definitive planning (see sections on single teeth, fixed bridgework, and overdentures) and together with the clinical examination indicates whether 3D scanning is needed.

### STUDY CASTS AND DIAGNOSTIC SETUPS

Articulated study casts allow measurements of many of the factors considered in the previous section. The proposed replacement teeth can be positioned on the casts using either denture teeth or teeth carved in wax (Fig. 2.5B, C). The former have the advantage that they can be converted into a temporary restoration that can be evaluated in the mouth by clinician and patient. The diagnostic setup therefore determines the number and position of the teeth to be replaced and their occlusal relationship with the opposing dentition.

Once the diagnostic setup has been agreed by the patient and clinician, it can be used to construct a stent (or guide) for radiographic imaging and surgical placement of the implants (Fig. 2.5D–F). The stent/guide can be positioned on the original cast, and with reference to the radiographs the clinician can decide upon the optimum location, number, and type of implants (see chap. 5).

### BASIC TREATMENT ORDER

Deciding on the treatment order may be very straightforward in some circumstances and in others extremely difficult, particularly for those cases involving transitional restorations.

A traditional plan may include the following:

1. Examination—clinical and initial radiographic
2. Diagnostic setup, provisional restoration, and specialized radiographs if required
3. Discussion of treatment options with the patient and decision on final restoration
4. Completion of any necessary dental treatment including
  - Extraction of hopeless teeth
  - Periodontal treatment

- Restorative treatment, new restorations and/or endodontics as required
- 5. Construction of provisional or transitional restorations if required
- 6. Construction of surgical guide or stent
- 7. Surgical placement of implants
- 8. Allow adequate time for healing/osseointegration according to protocol, bone quality, and functional demands
- 9. Prosthodontic phase

## CONCLUSION

It is imperative to consider all treatment options with the patient, and during detailed planning it may become apparent that an alternative solution is preferred. In all cases the implant treatment should be part of an overall plan to ensure health of any remaining teeth and soft tissues. Once the goal or end point has been agreed it should be possible to work back to formulate the treatment sequence. The cost of the proposed treatment plan is also of great relevance. The greater the number of implants placed, the higher will be the cost, and this may therefore place limits on treatment options. In difficult cases it is better to place additional implants to the minimum number required to take account of possible failure and improved predictability and biomechanics.

## BIBLIOGRAPHY

- Blanes RJ. To what extent does the crown-implant ratio affect the survival and complications of implant-supported reconstructions? A systematic review. *Clin Oral Implants Res* 2009; 20(suppl 4):67–72.
- Budtz-Jorgensen E. Restoration of the partially edentulous mouth—a comparison of overdentures, removable partial dentures, fixed partial dentures and implant treatment. *J Dent* 1996; 24:237–244.
- Cardaropoli G, Wennstrom JL, Lekholm U. Peri-implant bone alterations in relation to inter-unit distances. A 3-year retrospective study. *Clin Oral Implants Res* 2003; 14:430–436.
- Duyck J, Van OH, Vander SJ, et al. Magnitude and distribution of occlusal forces on oral implants supporting fixed prostheses: an in vivo study. *Clin Oral Implants Res* 2000; 11:465–475.

- Frei C, Buser D, Dula K. Study on the necessity for cross-section imaging of the posterior mandible for treatment planning of standard cases in implant dentistry. *Clin Oral Implants Res* 2004; 15:490–497.
- Halg GA, Schmid J, Hammerle CH. Bone level changes at implants supporting crowns or fixed partial dentures with or without cantilevers. *Clin Oral Implants Res* 2008; 19:983–990.
- Jemt T, Lekholm U. Implant treatment in edentulous maxillae: a 5-year follow-up report on patients with different degrees of jaw resorption. *Int J Oral Maxillofac Implants* 1995; 10:303–311.
- Lang NP, Pjetursson BE, Tan K, et al. A systematic review of the survival and complication rates of fixed partial dentures (FPDs) after an observation period of at least 5 years. II. Combined tooth—implant-supported FPDs. *Clin Oral Implants Res* 2004; 15:643–653.
- Naert IE, Duyck JA, Hosny MM, et al. Freestanding and tooth-implant connected prostheses in the treatment of partially edentulous patients. Part I: An up to 15-years clinical evaluation. *Clin Oral Implants Res* 2001; 12:237–244.
- Palmer RM, Howe LC, Palmer PJ, et al. A prospective clinical trial of single Astra Tech 4.0 or 5.0 diameter implants used to support two-unit cantilever bridges: results after 3 years. *Clin Oral Implants Res* 2011 (in press).
- Quirynen M, Mraiwa N, van Steenberghe D, et al. Morphology and dimensions of the mandibular jaw bone in the interforaminal region in patients requiring implants in the distal areas. *Clin Oral Implants Res* 2003; 14:280–285.
- Serhal CB, van Steenberghe D, Quirynen M, et al. Localisation of the mandibular canal using conventional spiral tomography: a human cadaver study. *Clin Oral Implants Res* 2001; 12:230–236.
- Weber HP, Kim DM, Ng MW, et al. Peri-implant soft-tissue health surrounding cement- and screw-retained implant restorations: a multi-center, 3-year prospective study. *Clin Oral Implants Res* 2006; 17:375–379.
- Wennstrom JL, Bengazi F, Lekholm U. The influence of the masticatory mucosa on the peri-implant soft tissue condition. *Clin Oral Implants Res* 1994; 5:1–8.
- Wennstrom J, Zurdo J, Karlsson S, et al. Bone level change at implant-supported fixed partial dentures with and without cantilever extension after 5 years in function. *J Clin Periodontol* 2004; 31:1077–1083.

## Single tooth planning in the anterior region

### INTRODUCTION

Single tooth restorations are often thought to be the most demanding implant restorations, particularly from the aesthetic viewpoint. Achievement of an ideal result is dependent on

1. the status of the adjacent teeth;
2. the ridge and soft tissue profile;
3. planning and precise implant placement;
4. sympathetic surgical handling of the soft tissue;
5. a high standard of prosthetic restoration.

The assessment and planning are dealt with in this chapter and surgical and prosthodontic factors in subsequent chapters.

### CLINICAL EXAMINATION

Examination should start with an extraoral assessment of the lips and the amount of tooth or gingiva that is exposed when the patient smiles (Fig. 3.1). A high smile line exposing a lot of gingiva is the most demanding aesthetically with both conventional and implant prosthodontics. The appearance of the soft tissue and particularly the height and quality of the gingival papillae on the proximal surfaces of the teeth adjacent to the missing tooth are important in these cases (Fig. 3.2). If there has been gingival recession, this should be noted. Exposure of root surface on the adjacent teeth labial surfaces may be correctable with periodontal mucogingival plastic surgery procedures, but recession on proximal surfaces is not usually correctable. The patient needs to be made aware of the limitations (which are the same as those that apply to tooth supported fixed bridgework). It is always easier to judge the aesthetic problems if the patient has an existing replacement, preferably one without prosthetic replacement of soft tissue. A simple "gum-fitted" removable partial denture, which has a satisfactory appearance, is very helpful (Fig. 3.3). The height of the edentulous ridge and its width and profile should be assessed by careful palpation. Large ridge concavities are usually readily detected. Ridge mapping is advocated by some clinicians. In this technique, the area under investigation is given local anesthesia and the thickness of the soft tissue measured by puncturing it to the bone using either a graduated periodontal probe or specially designed calipers. The information is transferred to a cast of the jaw, which is sectioned through the ridge. This method gives a better indication of bone profile than simple palpation but is still prone to error. Whenever the clinician is in doubt about the bone width and contour, it is advisable to request a radiographic examination that will achieve this (see section on sectional tomography).

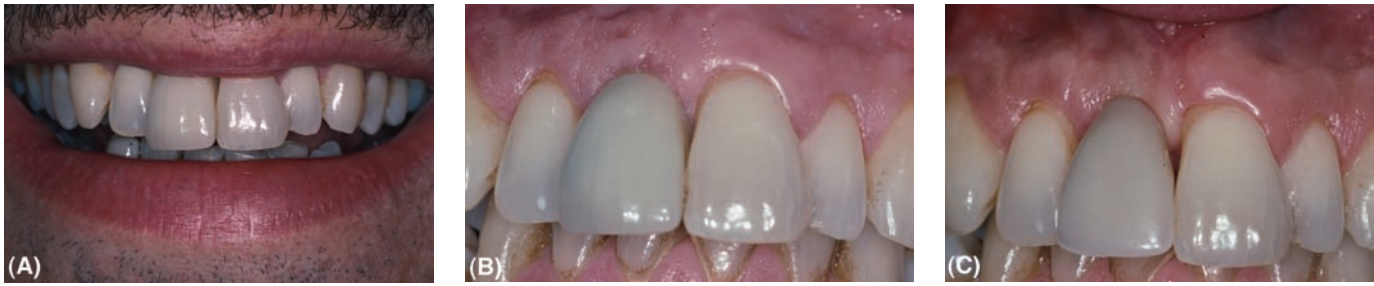One of the most important assessments is measurement of the tooth space at the level of the crown, at the soft tissue margin (narrowest point between natural teeth at gingival level), and between the roots (Fig. 3.4). The first is important

for the aesthetics and is best judged by measuring the width of the crown in comparison to the contralateral natural tooth if present. The available width at the root level determines whether an implant and abutment can be accommodated without compromising the adjacent tooth roots and soft tissue. A commonly quoted minimal dimension is 6 mm, both in the mesiodistal and buccolingual plane. This allows for an average implant of 4 mm diameter to have a margin of 1 mm of bone surrounding it. It is of equal importance to have sufficient space around the abutment and implant crown for a healthy soft tissue cuff and soft tissue attachment to the adjacent natural teeth. The mesiodistal dimension is commonly compromised in the maxillary lateral incisor region and the lower incisor region where the natural teeth are small (Figs. 3.2 and 3.5). In the case of young patients with developmentally missing maxillary incisors, it is advisable to liaise with the treating orthodontists to agree space requirements and to check that adequate space has been achieved before removal of the orthodontic appliance. The adjacent root alignment can sometimes be palpated, but usually requires verification radiographically. Spaces that are 5 mm wide mesiodistally may be amenable to treatment with a narrow diameter implant/abutment (e.g., 3.3 mm rather than 4 mm diameter), provided the forces it is subjected to are not too high (Fig. 3.5). For example, utilization of narrow implants would be contraindicated in a patient with a parafunctional activity such as bruxism.

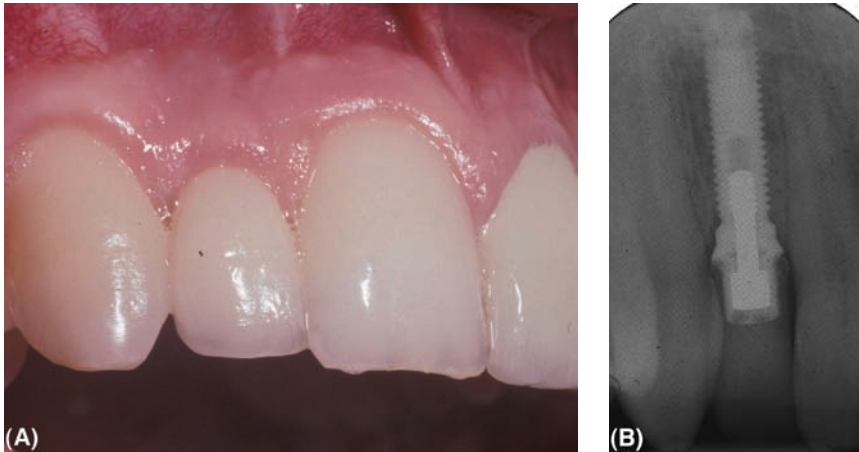
However, patients with a spaced dentition have excess mesiodistal space. Provided the ridge has an adequate buccolingual width, the clinician could plan to place a wider diameter implant that more closely matches the root of the tooth that is being replaced (Figs. 3.6 and 3.7). The selection of the most appropriate diameter implant has a bearing on the aesthetics and surgery. This is dealt with in more detail in the surgical section (see chap. 9), which also compares some of the implant systems available.

### Examination of the Occlusion

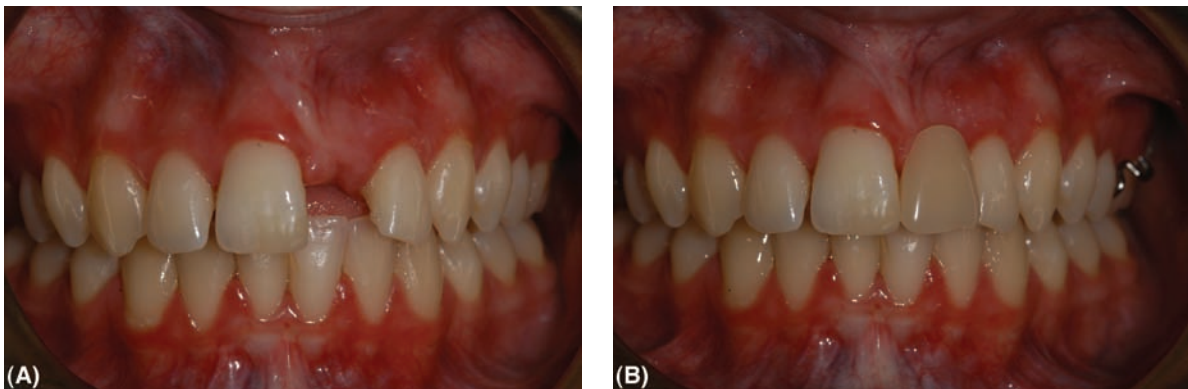This can be usually be accomplished by simple clinical examination. The adjacent tooth contacts (and that of the preexisting prosthetic replacement if available) should be examined in centric occlusion, retruded contact, and protrusive and lateral excursions. Occlusal contacts on the single tooth implant restoration should be designed such that contacts occur first on adjacent teeth. This takes account of the normal physiologic mobility of the teeth compared to the rigid osseointegrated implant. Difficulties can arise when replacing canines in a canine-guided occlusion. Under these circumstances, attempts should be made to achieve group function and light contacts on the implant restoration. Similar precautions are required with central and lateral incisor replacements in class 2 division 2 incisor relationships with deep overbites (Fig. 3.8).



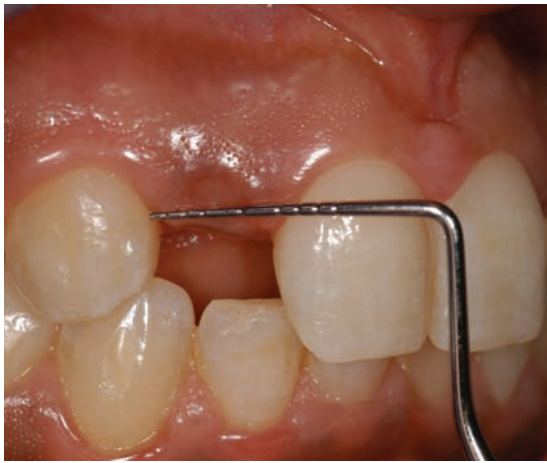**Figure 3.1** (A) This patient who has tooth 11 replaced with a single tooth implant does not expose any gingival tissue when he smiles. (B) An intraoral view of the single tooth implant at position 11. Note that the adjacent incisors have small amounts of gingival recession on the labial and proximal surfaces, which was present before treatment. This loss of attachment on the proximal surfaces affects papillary height and is very difficult or impossible to regain. (C) The same patient before implant treatment, confirming the position of the gingival margins on the natural teeth. The prosthesis is a simple gum-fitted spoon denture, which provides acceptable aesthetics but poor function. It is a useful diagnostic aid.



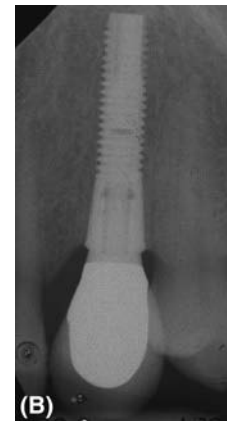
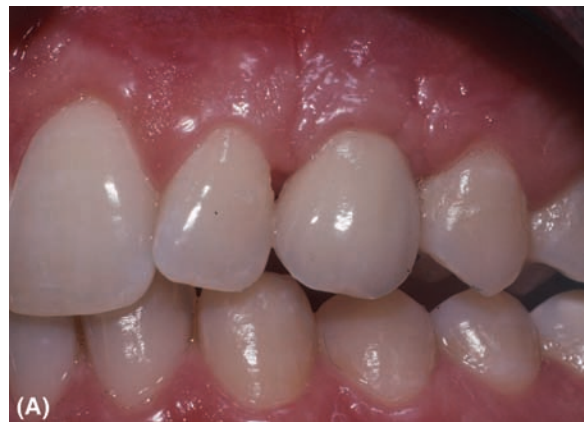**Figure 3.2** (A) Replacement of a small upper lateral incisor with a single tooth implant showing good soft tissue form and aesthetics. (B) Radiograph of the single tooth implant, which in this case is a narrow diameter (3.3 mm) Nobel Biocare implant. Narrow implants are normally only suitable for low load situations.



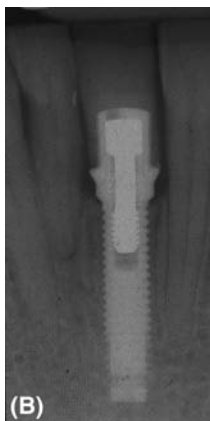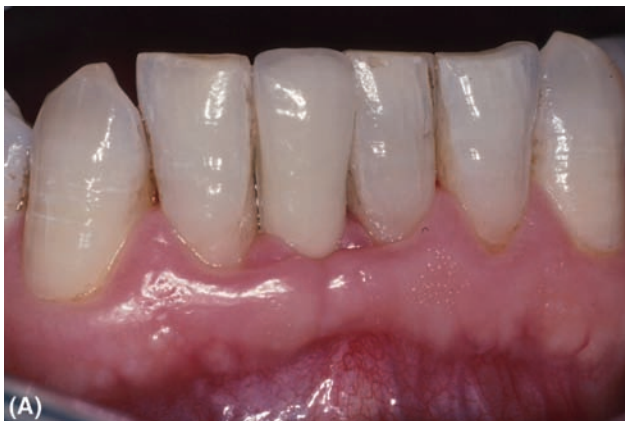**Figure 3.3** (A) A patient with a missing maxillary central incisor tooth. (B) The same patient with a simple removable diagnostic denture showing the relationship between the cervical margin and the underlying ridge.



**Figure 3.4** Measurement of the edentulous space can readily be performed with a calibrated periodontal probe or caliper. It is important to measure the narrowest point between the crowns of the adjacent teeth at the level of the soft tissue. This clinical assessment will be supplemented with radiographic measures.



**Figure 3.6** (A) The maxillary canine has been replaced with an Astra Tech implant of suitable diameter to withstand the high forces in this application. (B) Radiograph of the implant showing ideal bone levels at the top of the implant, a titanium abutment and a metal ceramic crown. The design of the implant abutment junction and the material selected are important in reducing future mechanical complications.



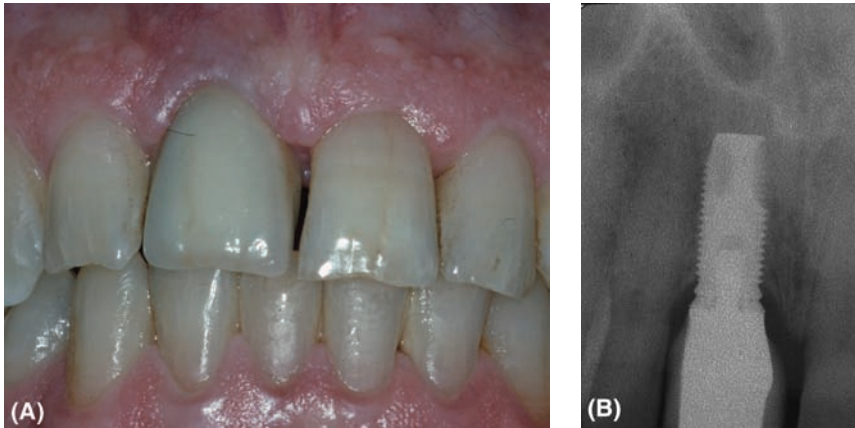
**Figure 3.5** (A) Replacement of the lower right central incisor with a single tooth implant is particularly challenging because of the limited space available. (B) Radiograph of a narrow diameter (3.3 mm) Nobel Biocare implant. The standard abutment is relatively wide and may compromise the soft tissue morphology. A resin-bonded bridge is often a more suitable method of replacement of single mandibular incisor teeth.

## RADIOGRAPHIC EXAMINATION

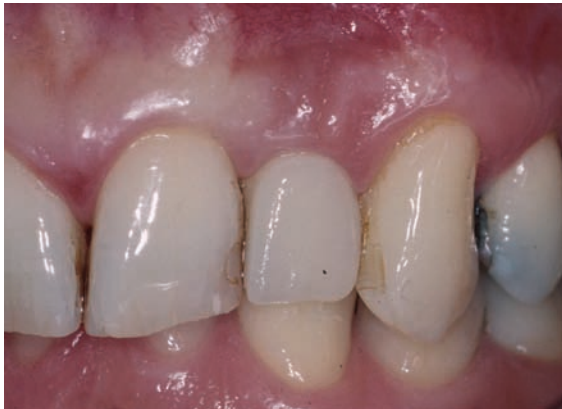Radiography for single tooth replacement in individuals with little bone loss can normally be accomplished by intraoral radiographs taken with a long cone paralleling technique (Fig. 3.9). However, it must be remembered that an overall evaluation of the mouth should be made for a full assessment of treatment needs. Image quality is of the utmost importance and the clinician should ensure that all relevant anatomical structures are shown on the image being used and that any allowances for distortion of the image are made. It can be surprisingly difficult to obtain accurate radiographic mesio-distal measurements of spaces at sites in the arch such as the maxillary lateral incisors/canines and the mandibular canines (Fig. 3.9). This is due to the curvature of the arch and the difficulty of achieving parallel film alignment with the space. The clinical measures can be checked against the radiographic ones to obtain a more accurate estimate.

## Sectional Tomography

Although some clinicians routinely use CT scans for single tooth planning, we would consider this to be in excess of what is normally required. CT scans, however, may be very important aids with some areas such as the maxillary central incisors



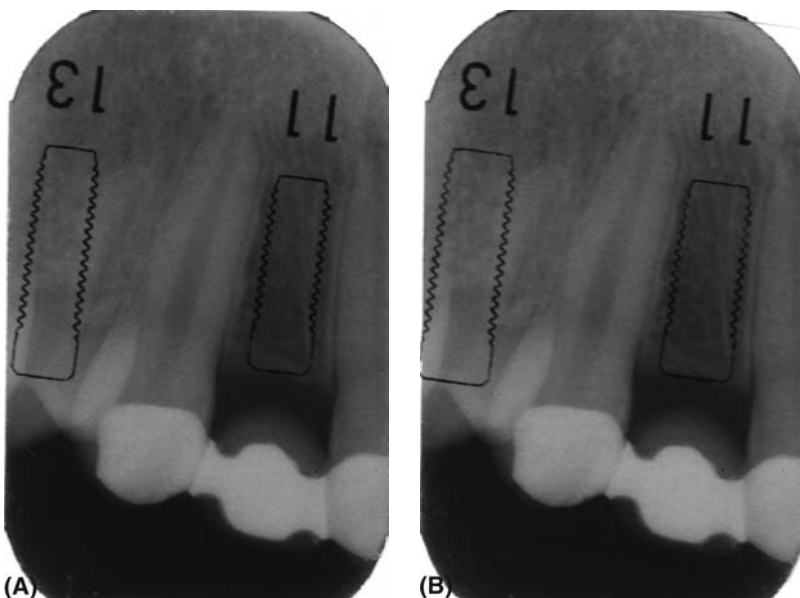
**Figure 3.7** (A) The upper right central incisor has been replaced with a 5-mm-diameter Nobel Biocare implant. (B) Radiograph of the wide diameter implant showing bone at the first thread. Standard diameter implants of approximately 4 mm in diameter are more commonly used in the incisor region, whereas wider diameter implants are indicated in the molar regions where forces are higher.



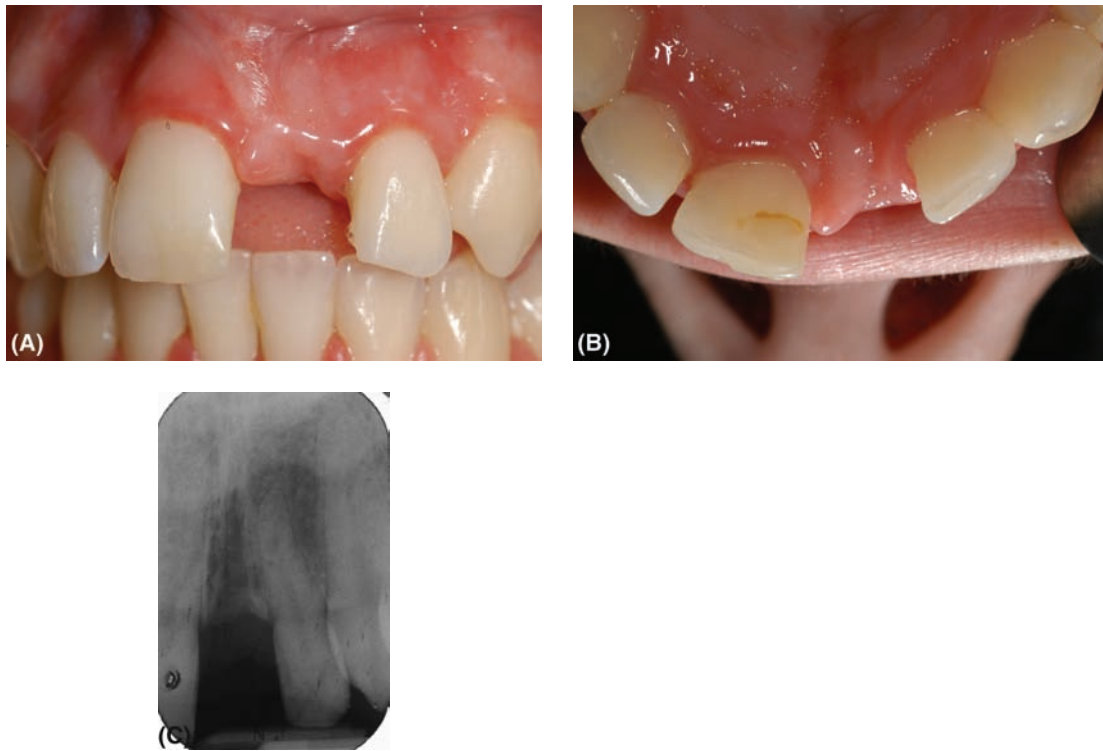
**Figure 3.8** The upper lateral incisor has been replaced using an Astra Tech implant six years ago. There has been complete stability and no complications despite the difficult class 2 division 2 incisor relationship.

where the presence of the incisive canal may compromise implant placement (Figs. 3.10 and 3.11). CT scans are more commonly used in complex cases and they are also dealt with in the chapter on fixed bridge planning (see chap. 5). Many modern dental panoramic tomogram (DPT) machines now offer sectional tomography for implant planning (see below).

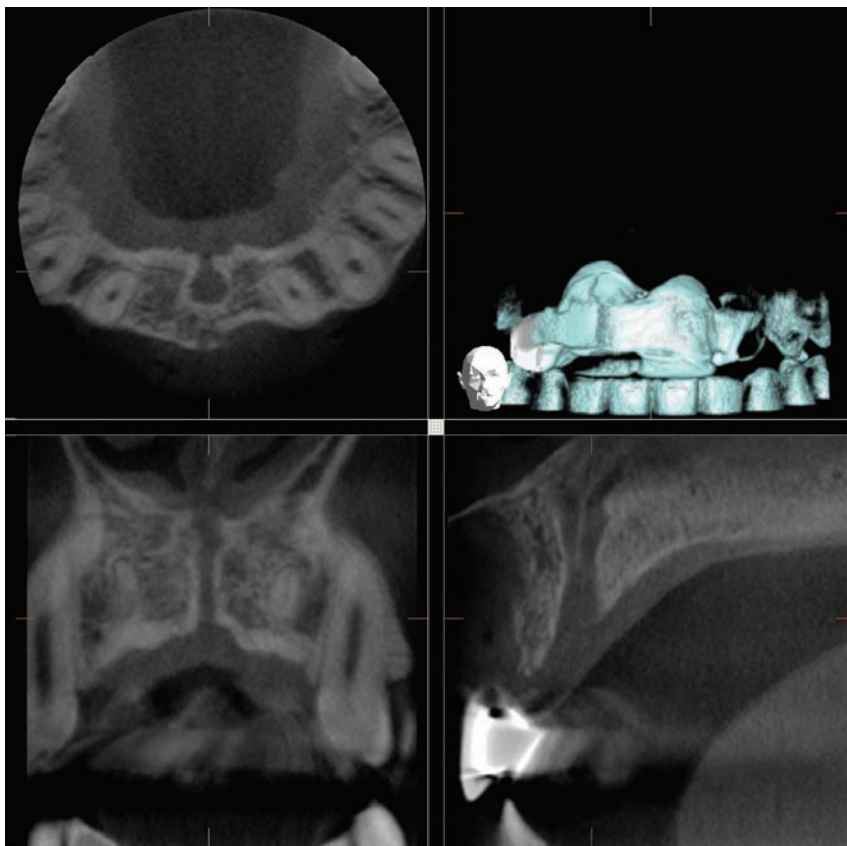
To optimize the information provided by 3D radiographic techniques, it is helpful to provide information about the planned final restoration. A suitable existing partial denture or a customized stent that mimics the desired tooth setup is constructed and radiographic markers incorporated. The radiopaque marker can be placed in the cingulum area of the tooth if a screw-retained crown is planned to indicate the access hole for the screw. Alternatively, the labial surface of the stent can be painted with a radiopaque medium such as TempBond to show the labial profile and cervical margin of the planned crown in relation to the underlying bone ridge (Fig. 3.12). Simpler types of stent involve placing radiopaque markers, for example, ball bearings of various diameters, into a baseplate, designed to help determine mesiodistal distortion and location.



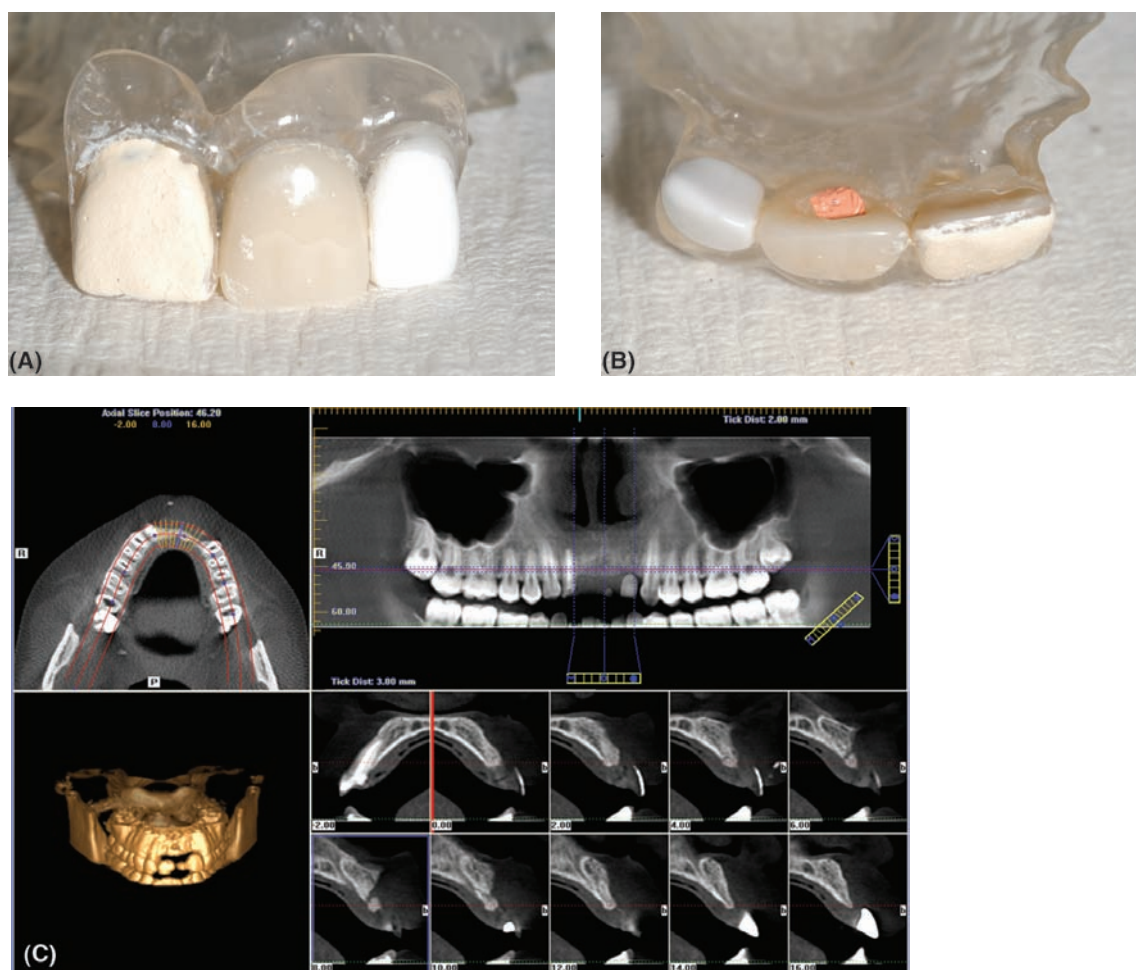
**Figure 3.9** (A) An intraoral radiograph of a maxillary lateral incisor space with an overlay showing an 11-mm-long  $\times$  3.5-mm-diameter implant allowing an assessment of distance between the implant surface and adjacent tooth root. (B) The same radiograph with the outline of a 4-mm-diameter implant suggesting that there would be no more than 1 mm of bone available between the implant surface and adjacent tooth root. This would require very precise implant placement to avoid damage to the adjacent teeth.



**Figure 3.10** (A) The labial view of the missing maxillary central incisor suggests good ridge height and morphology. (B) The occlusal view of the same case shows a prominent incisive papilla and relatively narrow space. (C) A radiograph of the case shows that the incisive canal occupies most of the edentulous space and there is slight convergence of the adjacent tooth roots. If an implant were planned, this may require both orthodontic tooth movement and bone grafting of the incisive canal.



**Figure 3.11** A series of cone-beam CT sections of the incisive canal. The upper left shows the canal in the axial plane, the lower left in the coronal plane, and the lower right in the sagittal plane. The top right is a 3D reconstruction showing the radiographic stent. The incisive canal occupies a larger proportion of the bone volume between the adjacent incisor roots.



**Figure 3.12** (A) A radiographic stent shown from the labial aspect. The upper right central incisor has a radiopaque medium on the labial surface and the upper left lateral incisor is a manufactured radiopaque tooth. (B) An occlusal view of the radiographic stent showing the upper left central incisor with a gutta percha restoration placed in the cingulum denoting the point of ideal screw access. (C) A cone-beam radiograph of the same case with the radiographic stent in situ showing the relationship of the various radiopaque markers to the underlying ridge form.

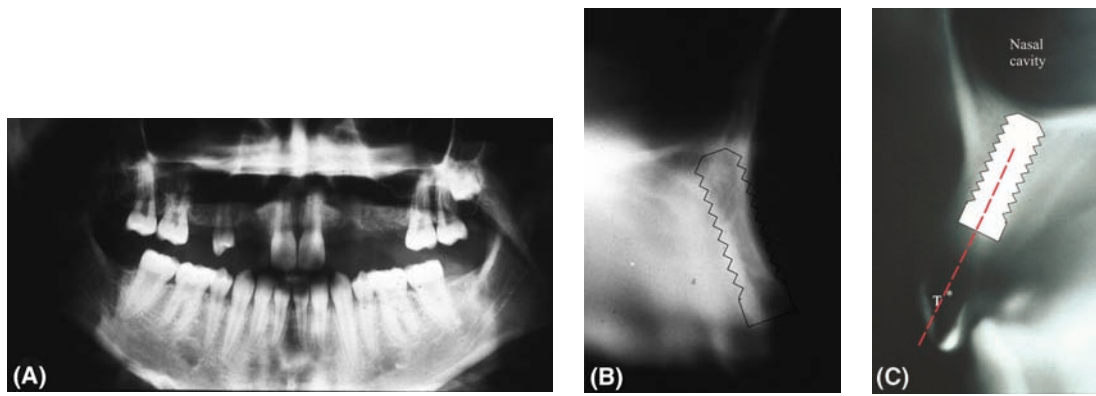
The early Scanora (Soredex, Finland) was an example of a tomographic machine with facilities to generate high-quality sectional images, although these have largely been superseded by cone-beam CT. In contrast to CT scanning where the sectional images are software generated, the Scanora produced a tomographic image directly onto film. It used complex broad beam spiral tomography and was able to scan in multiple planes. The scans were computer controlled with automatic execution. They relied on good patient positioning and experience in using the machine. The patient's head was carefully aligned within the device and this position recorded with skin markers and light beams. A conventional DPT image was produced from which the sites which require sectional tomographs were determined (Fig. 3.13). The patient was repositioned in exactly the same alignment and the appropriate tomographic programme selected for the chosen region of the jaw.

The Scanora magnification was  $\times 1.3$  or  $\times 1.7$  for routine DPTs but  $\times 1.7$  for all sectional images. Tomographic sections were normally 2 mm or 4 mm in thickness. As with all tomograms the image produced includes adjacent structures which are not within the focal trough which therefore appear blurred and out of focus.

To facilitate planning using images at different magnifications, transparent overlays depicting implants of various lengths and diameters at the corresponding magnifications can be superimposed directly on the radiograph (Figs. 3.9A, B, and 3.13B). These provide a simple method of assessing implant sites and implant placement at different angulations.

### DIAGNOSTIC SETUPS

Patients with aesthetically acceptable provisional restorations may not require diagnostic wax-ups. There are considerable advantages in using the preexisting prosthesis or a new provisional restoration that can be worn by the patient to provide a realistic potential end-result. This can be agreed upon between patient and clinician and recorded. Wax-ups are difficult for the patient to judge, and computer-manipulated images may not be entirely realistic or achievable. We routinely use simple acrylic removable prostheses for this purpose (Fig. 3.3, and see below). The setup should establish the emergence profile of the crown and estimate the level of emergence from the soft tissue at the planned cervical/gingival margin.



**Figure 3.13** (A) A dental panoramic tomogram taken on a Scanora at  $\times 1.7$  magnification. The young patient has a large number of developmentally missing teeth, including maxillary lateral incisors and canines. (B) A sectional tomogram of the anterior ridge, which is angled labially and is thinner than the outline of the superimposed 4-mm-diameter implant. (C) The sectional profile of the tooth (T\*) to be replaced can be visualized by coating the radiographic stent with a radiographic medium. The Scanora section of this wider ridge profile has been assessed using a transparent overlay of the appropriate implant design, which can be accommodated within the available bone volume. The red dashed line shows that the angle at the implant would pass through the labial face just apical to the incisal tip. A cemented restoration would be satisfactory.

### CEMENTED OR SCREW-RETAINED CROWNS

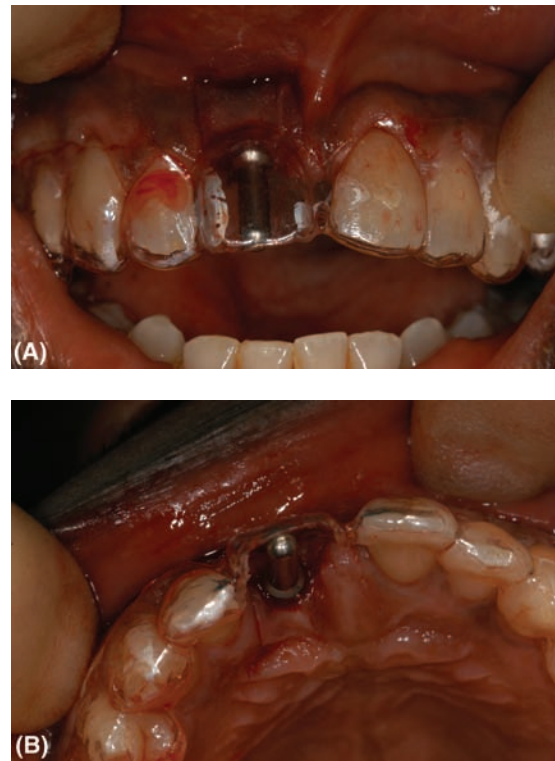
The preceding information should provide the clinician with sufficient information to indicate whether it is possible and/or desirable to provide a cemented or screw-retained crown (Fig. 3.14). This is dealt with in some detail in chapter 9, but needs to be considered here. Nowadays most anterior single tooth crowns are cemented. This produces very good aesthetics without a visible screw hole on the palatal surface, even though this can be carefully restored with tooth-colored restorative material. Optimum labial contour and emergence profile is achieved with an implant that is angled with its long axis passing through the incisal tip or slightly labial to it (Fig. 3.15). This restoration cannot be screw retained. However, in cases where there has been fairly extensive ridge resorption that has not been corrected by bone grafting, the position and angle of the implant may be more palatal (Fig. 3.15D). Screw retention through the palatal surface permits full retrievability of the crown and would make it possible to retighten a loose abutment should it occur (Fig. 3.16). The disadvantage is that it is usually associated with a ridge lap labial margin (Fig. 3.15C). The above mainly applies to the upper incisors and canines. In the premolar zone, the implant is normally in the long axis of the crown allowing either cementation or screw, according to the clinician's preference.

### PROVISIONAL RESTORATIONS

In the majority of treatment plans, the provisional restoration is an essential component. It helps establish the design of the final reconstruction and is used by the patient throughout the treatment stages. The following provisional restorations are most commonly used for single tooth restorations.

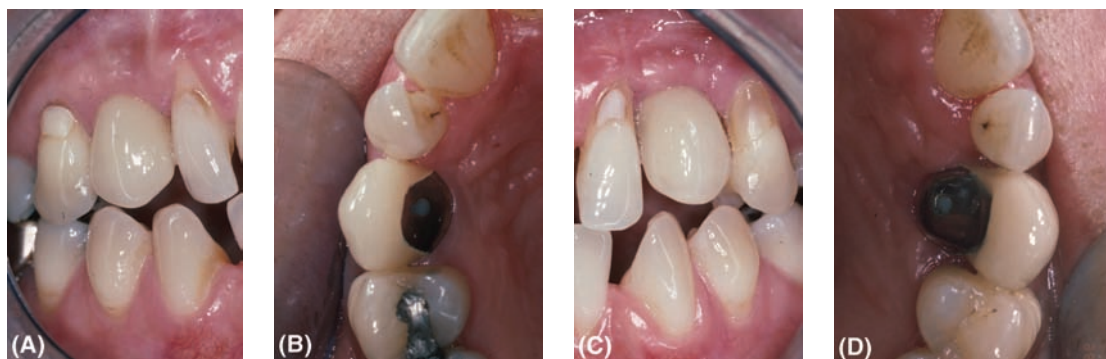
#### Removable Partial Dentures

Although it has been suggested that dentures should not be worn for one or two weeks following implant surgery, this does not usually apply to the single tooth cases. Single tooth or short span dentures can usually be worn immediately after surgery.

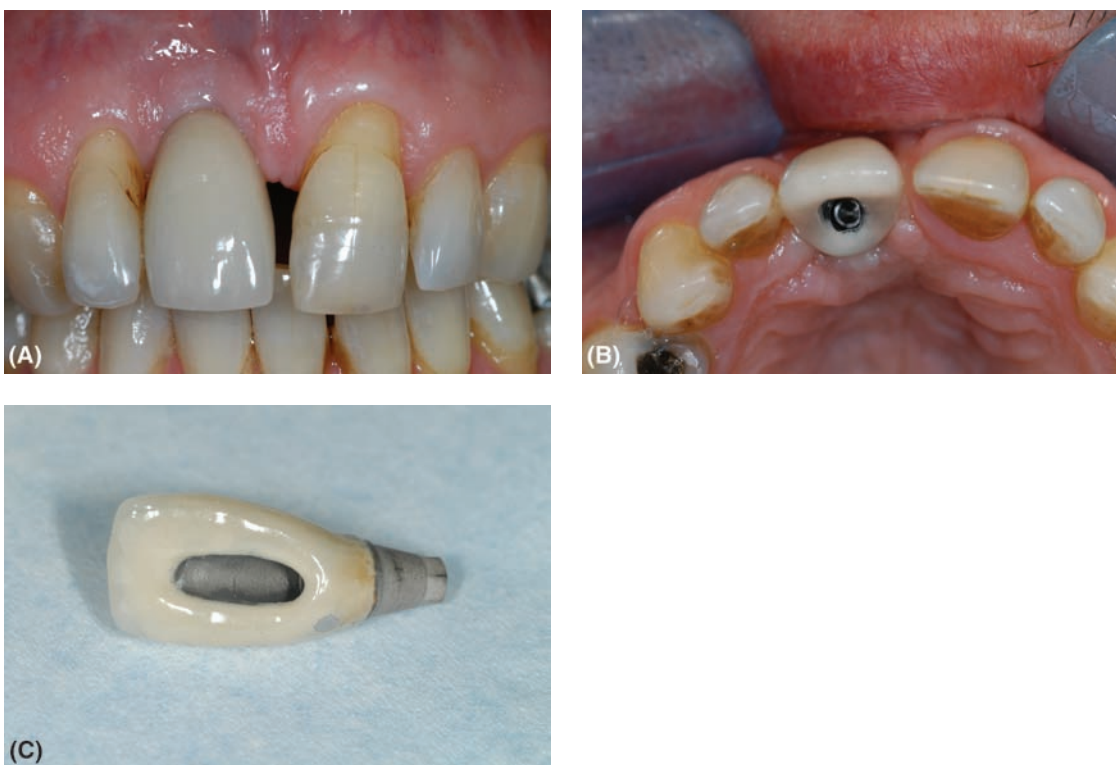


**Figure 3.14** (A) A surgical stent viewed from the labial surface with an indicator pin inserted in the initially prepared implant site. The indicator pin is in good alignment in the mesiodistal plane. (B) The same case reviewed from the occlusal aspect showing the indicator pin is aligned with the incisal tip and consistent with the planned cemented restoration.

The denture can be adjusted so that little or no pressure is transmitted at the site of the implant. Acrylic dentures are simple and inexpensive to construct and allow easy adjustment to



**Figure 3.15** (A) The upper right canine has been replaced by a single tooth implant in an ideal position, giving a very good buccal emergence profile. (B) The palatal view of the crown of the upper right canine shows that it is a cemented crown with a good contour. The angle of the implant was close to the long axis of the tooth, passing through the cusp tip. (C) In contrast, the single tooth implant replacing the upper left canine has a more ridged lapped buccal profile. (D) The palatal view of the upper left canine shows the cemented crown with a much more bulbous palatal contour because the implant is palatally placed and the angle of the implant goes through the cingulum area. In this case it would have been possible to have provided a screw-retained restoration.



**Figure 3.16** (A) The upper right central incisor single tooth implant has a long clinical crown, consistent with the adjacent teeth, which have considerable gingival recession. (B) The palatal view showing the abutment screw through a cingulum access hole. (C) The single piece crown and abutment and large access hole for the abutment screw.

accommodate any changes in tissue profile following implant placement and the transmucosal abutments when they are fitted. When used as an immediate replacement following tooth extraction, the shape of the gum-fitted pontic can be adjusted to develop a good emergence profile and soft tissue contour.

### Adhesive Bridgework

Many patients prefer the idea of a fixed provisional restoration. Adhesive bridgework is normally retained by a single adjacent retainer that should permit removal by the clinician. Therefore, the Rochette design is recommended as drilling out

the composite lugs within the framework holes should allow removal. However, this occasionally proves to be more difficult than one might expect and removal and replacement of adhesive bridges considerably adds to the treatment time particularly in the restorative phase. It is worthwhile making the prosthetic tooth from acrylic or composite to allow more rapid adjustment when the bridge is recemented over a protruding abutment. The fixed restoration has considerable advantages in case where it is important to avoid any loading of the ridge/mucosa, for instance where grafting or regenerative techniques have been used (see chap. 12).

## TREATMENT SCHEDULES

The treatment schedule for single tooth replacement in most cases should be relatively simple.

1. Initial consultation, clinical evaluation, and radiographic examination
2. Agreement of aesthetic/functional demands using existing prosthesis or diagnostic setup/new provisional prosthesis
3. Treatment of related dental problems, which could compromise implant treatment
4. Surgical placement of the implant and provision of temporary prosthesis
5. Healing phase to allow osseointegration according to established protocol
6. Abutment connection
7. Prosthodontic treatment

However, there are a number of situations that will need modification:

1. Immediate replacement following extraction (see chap. 11).
2. Soft tissue or bone augmentation prior to implant placement (see chap. 12).
3. Early loading or immediate loading protocols. Provided bone quality is good and implant stability is good, im-

mediate or early loading (e.g., 4–6 weeks following implant placement) should not compromise success. However, failure rates can be higher particularly where loading is difficult to control (see chap. 11).

## CONCLUSION

This chapter has dealt with most of the basic planning issues of anterior single tooth replacement. However, many of the more detailed issues are best considered in the surgical chapter (chap. 9) and the prosthodontic chapter (chap. 13).

## BIBLIOGRAPHY

- Andersson B, Odman P, Carlsson GE. A study of 184 consecutive patients referred for single-tooth replacement. *Clin Oral Implants Res* 1995; 6:232–237.
- Bragger U, Krenander P, Lang NP. Economic aspects of single-tooth replacement. *Clin Oral Implants Res* 2005; 16:335–341.
- Bragger U, Karoussis I, Persson R, et al. Technical and biological complications/failures with single crowns and fixed partial dentures on implants: a 10-year prospective cohort study. *Clin Oral Implants Res* 2005; 16:326–334.
- Chang M, Wennstrom JL, Odman P, et al. Implant supported single-tooth replacements compared to contralateral natural teeth. Crown and soft tissue dimensions. *Clin Oral Implants Res* 1999; 10:185–194.
- Cordaro L, Torsello F, Mirisola DT, et al. Retrospective evaluation of mandibular incisor replacement with narrow neck implants. *Clin Oral Implants Res* 2006; 17:730–735.
- Engquist B, Nilson H, Astrand P. Single tooth replacement by osseointegrated Branemark implants. *Clin Oral Implants Res* 1995; 6:238–245.
- Puchades-Roman L, Palmer RM, Palmer PJ, et al. A clinical, radiographic and microbiological comparison of Astra Tech and Branemark single tooth implants. *Clin Implant Dent Relat Res* 2000; 2:78–84.

## Single tooth planning for molar replacements

### INTRODUCTION

The considerations for replacement of single molars are not primarily aesthetic as in the preceding section on anterior teeth, but the mechanical considerations are far more important. It is not generally recommended to replace a molar with a single implant of 4 mm diameter or less because of the potentially large cantilever forces that it could be subjected to (Fig. 4.1), resulting in biomechanical failure (abutment screw loosening/fracture or implant fracture—see chap. 16). The basic alternatives are therefore, placement of two standard implants or a single wide-diameter implant. The space requirements and potential costs are quite different.

### TWO-IMPLANT SOLUTIONS

Molar spaces of 11 mm mesiodistal width can theoretically be treated with placement of two 4-mm-diameter implants. This requires extreme care and skill to avoid damage to adjacent tooth roots. The space between the two implants may also prove to be too small to allow a properly contoured restoration and an adequate bone and soft tissue zone (Fig. 4.2).

In most cases, the space should be at least 13 mm to allow the two-implant solution (Figs. 4.3 and 4.4). The space has to be measured at the level of the crestal bone and the adjacent tooth roots must not converge within the space.

It is also important to measure the space available at the occlusal plane, particularly if there is tilting of the adjacent teeth. Under these circumstances, an unfavorable path of insertion of prosthodontic components may prevent the reconstruction or the implant abutments may touch. The choice of implant diameter, implant system, and implant abutment will have a marked impact on the available space as illustrated in Figures 4.5–4.7.

### SINGLE-IMPLANT SOLUTIONS WITH WIDE-DIAMETER IMPLANTS

Many molar spaces are less than 12 mm, and economic considerations often indicate the use of single-implant replacements (Figs. 4.8 and 4.9). Wider-diameter implants are available in most systems, and in all systems described in this book. Wide-diameter implants have been defined as equal to or greater than 4.5 mm diameter, although we would recommend implants equal to or greater than 5 mm diameter for molar replacements. Wide diameter may apply to the diameter of the main body of the implant (Fig. 4.10) or the prosthodontic platform (Fig. 4.11). The wide body is better at distributing

forces to the surrounding bone and a wide platform and larger abutment screw should reduce mechanical complications.

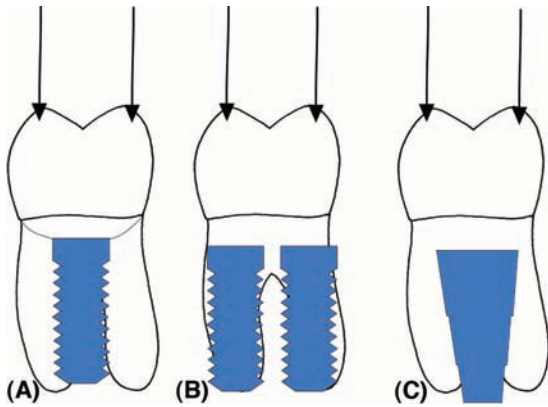
The mechanical advantages of a wide-diameter implant for molar replacement are as follows:

1. Better force distribution with reduction of leverage forces because the implant diameter more closely matches that of the crown.
2. The implant is stronger and less likely to fracture.
3. The abutments and abutment screws are usually bigger and stronger.
4. The surface area of the abutment is usually larger and will provide more retention.

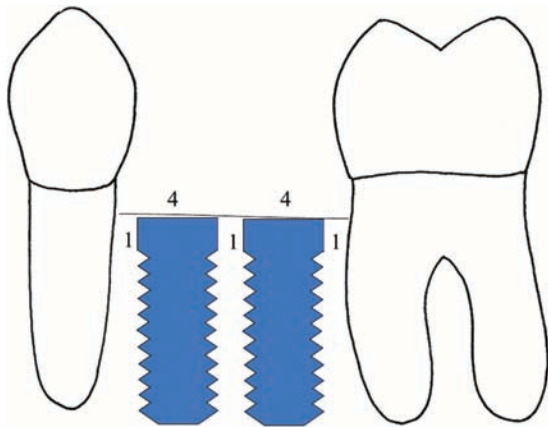
The mesiodistal molar width should always provide sufficient space for a wide-diameter implant. However, this is not always the case in the buccolingual dimension. Narrow ridges occur in both posterior maxilla and mandible, often only allowing placement of normal-diameter implants without recourse to grafting. In many cases (particularly, shortly after loss of the molar), there is sufficient buccolingual width and the wide-diameter implant should be ideal. The increased surface area it provides also has a distinct advantage in the molar regions, where bone height is often limited by the expansion of the maxillary sinus and the position of the inferior alveolar nerve (where a safety margin of at least 3 mm is recommended). In the posterior maxilla, the implant can engage the floor of the sinus to achieve adequate length or a sinus augmentation can be carried out (see chap. 12). The minimal length of implant recommended would normally be 8 mm (Fig. 4.12). The selection of an implant with a surface that has been treated to further increase its area and improve the rate and quality of osseointegration is preferred in these circumstances.

### CONCLUSIONS

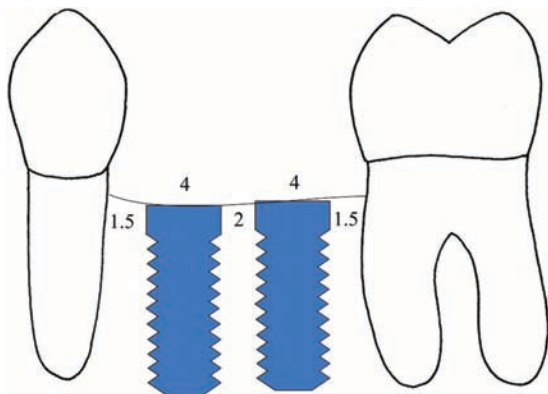
In most cases a molar tooth can be replaced with a single wide implant, thus simplifying treatment and reducing cost. Ensure that the buccolingual width will accommodate a wide-diameter implant, and there is sufficient bone height. If in doubt, check with 3D radiographic imaging. If the molar space is large (over 14 mm mesiodistal) and economics allow, choose the two-implant option. Caution should be exercised in patients with bone height insufficient to allow placement of an 8-mm-long implant, poor bone quality, or high functional demands. Check the prognosis of the adjacent and opposing teeth.



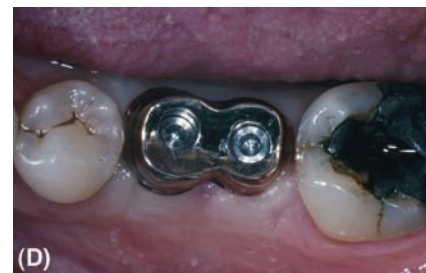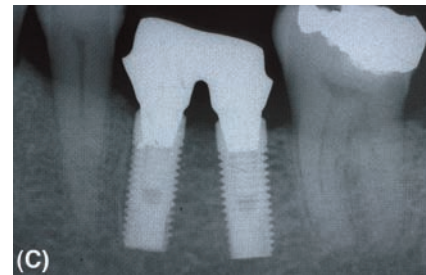
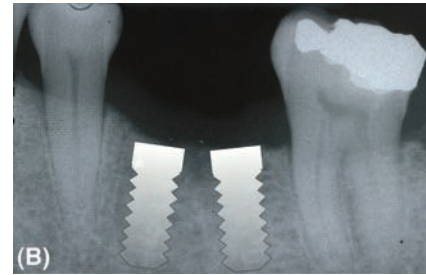
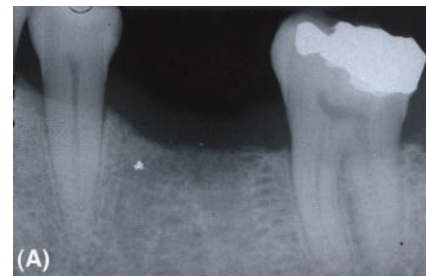
**Figure 4.1** Alternative implant solutions for a single molar. The size discrepancy between a single 4-mm implant (A) and the normal occlusal table of a molar may subject it to too high leverage forces and biomechanical failure. The situation is considerably improved by using two implants (B) or a single wide implant (C).



**Figure 4.2** An 11-mm space at the level of the crestal bone could theoretically accommodate two 4-mm-diameter implants and allow a space of 1 mm between them and the adjacent teeth.



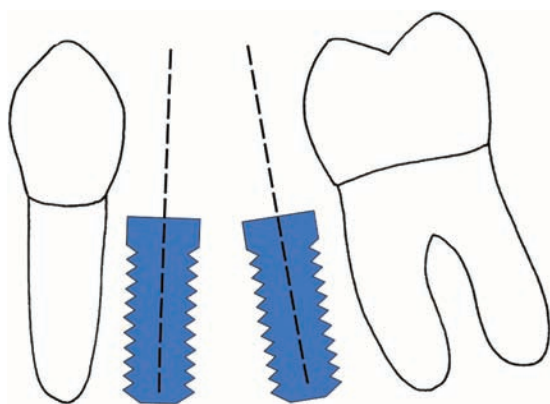
**Figure 4.3** A 13 mm space at crestal level allows placement of two 4 mm diameter implants. A safer margin between implants and teeth (1.5 mm) is provided and a minimum of 2 mm between implants. A 3 mm space between implants is often advocated.



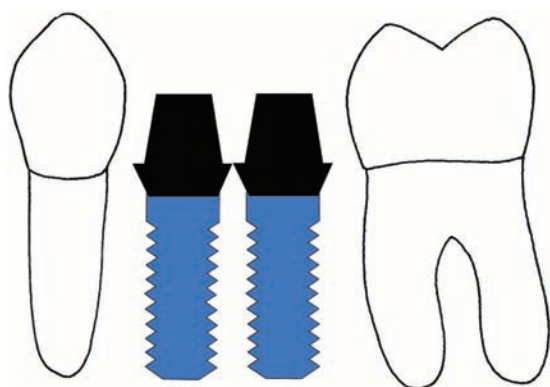
**Figure 4.4** (A) Radiograph of a mandibular molar space indicating adequate room for two implants. (B) Radiograph with transparent overlay of two standard-diameter implants, confirming adequate mesiodistal space. The implants are no longer than the adjacent natural roots and are above the inferior dental canal. (C) Radiograph of two Astra Tech 4-mm-diameter implants used to replace the mandibular first molar. The two implants have been joined together with a gold casting fabricated on two cast design abutments. The abutments are narrower than the implants at the level of the implant head and the shape of the casting facilitates soft tissue contour and plaque control. (D) Occlusal view of the screw-retained casting on the two implants. (E) Lingual clinical mirror view of the completed restoration. A porcelain fused metal crown has been cemented on to the gold substructure. (F) Buccal view of the completed restoration. The space between the implants has been contoured to facilitate oral hygiene with a bottle brush. (G) Occlusal view of the completed cemented crown without access to the abutment screws.

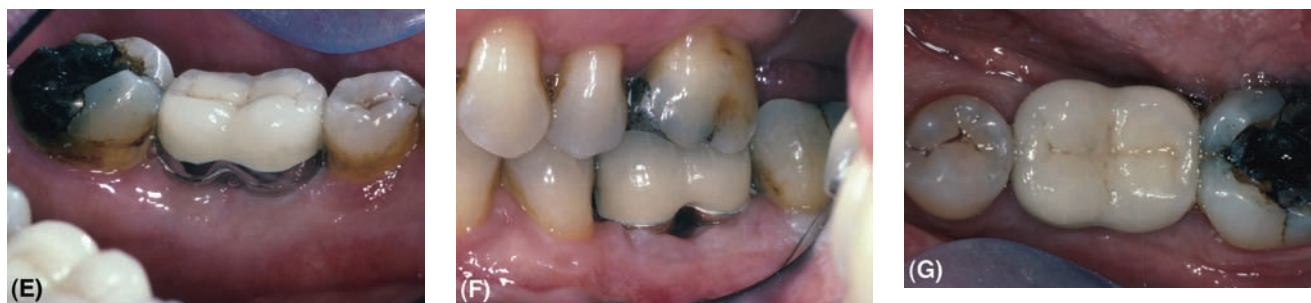

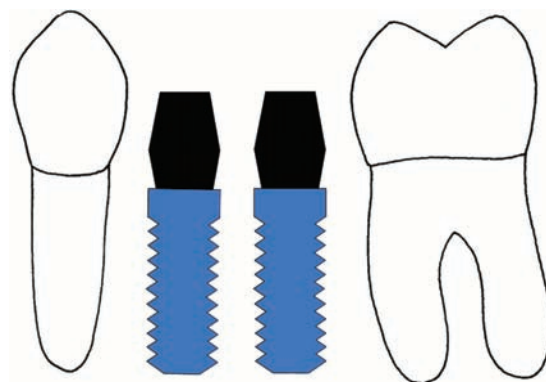
Figure 4.4 (Continued)



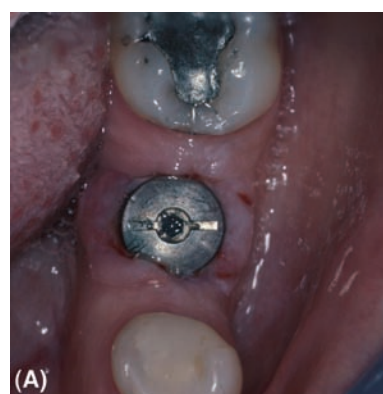
**Figure 4.5** The space at the level of the occlusal surface is reduced due to tilting of the distal molar, although there is more bone width available apically. The surgery may be easier but the prosthodontics could be compromised and in severe cases made impossible.



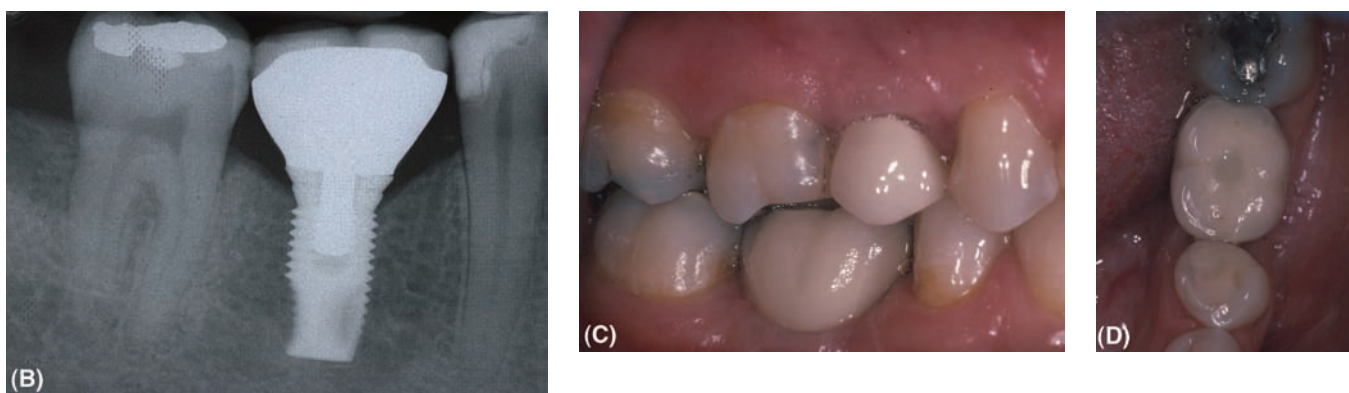
**Figure 4.6** Two 4-mm-diameter implants have been placed with wider margins between them and the adjacent teeth. The abutments that flare to a wider diameter may touch or leave insufficient space for a healthy soft tissue collar. This could be improved by using narrower abutments.



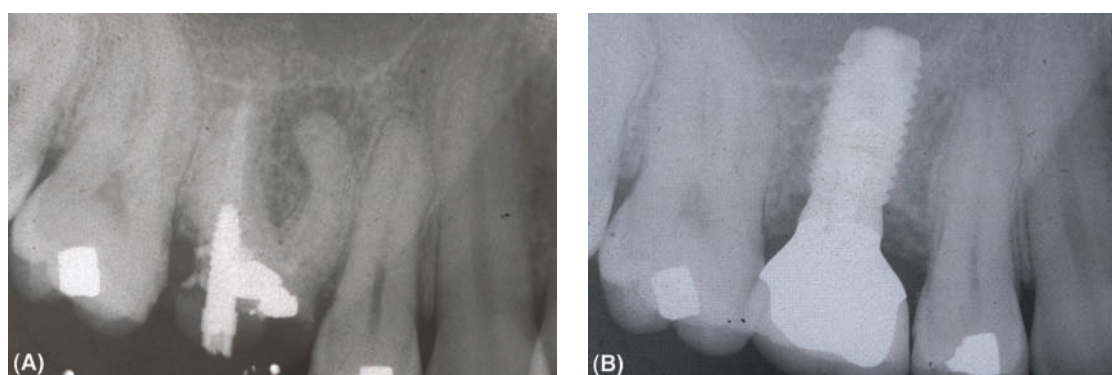
**Figure 4.7** When space is limited, the selection of an alternative implant system can help enormously. This figure illustrates placement of two Astra Tech implants. Selection of the 3.5-mm-diameter implant rather than 4 mm would provide an additional saving of 1 mm. The Astra Tech abutments are narrower than the implant heads and provide space saving for the superstructure and soft tissue.



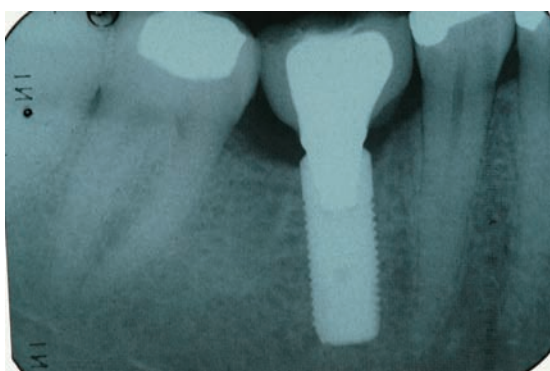**Figure 4.8** (A) Occlusal view of a single implant healing abutment to replace a lower molar. (B) Radiograph of the mandibular molar replaced by a 10-mm-long Nobel Biocare 5-mm-diameter wide-platform implant. (C) Clinical photograph of the mandibular first molar replaced by a single wide-diameter implant. The appearance and soft tissue contours are good. (D) Occlusal view of the completed restoration. The crown has been cemented to a standard abutment. However, an access hole (filled with composites) has been fabricated to allow the crown to be retrievable, this allows tightening of the abutment screw if it should become loose due to the considerable occlusal forces in the molar region.



**Figure 4.8** (Continued)



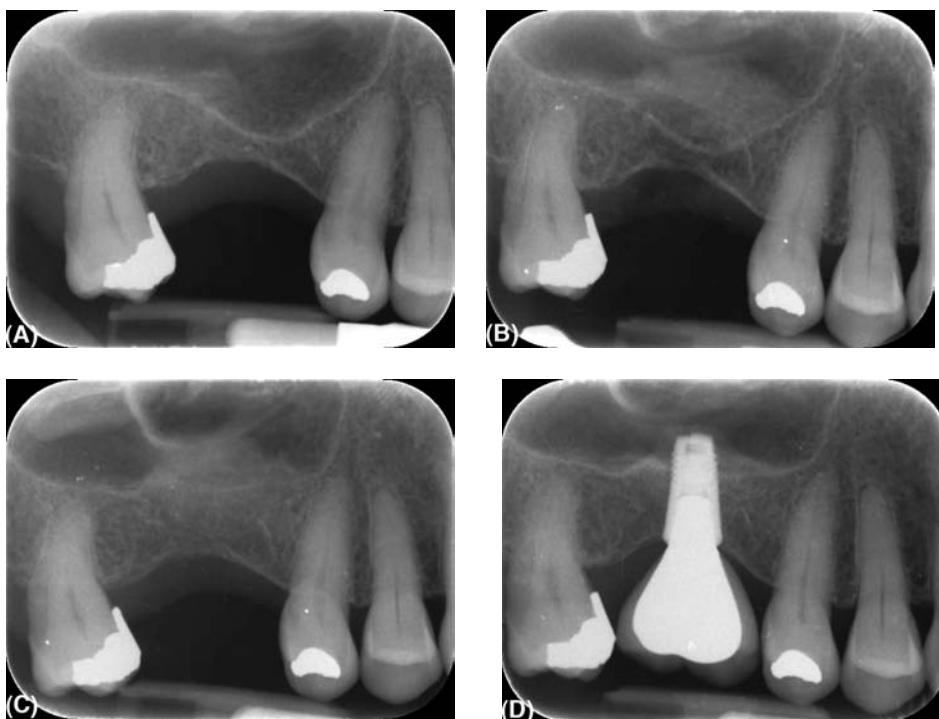
**Figure 4.9** (A) Radiograph of a maxillary first molar with failed endodontic treatment and a broken down crown. The adjacent teeth have small restorations. (B) The first molar has been replaced by a single tooth implant: a 5-mm-diameter wide-platform Nobel Biocare. The implant is 10 mm in length and extends to the maxillary sinus.



**Figure 4.10** A mandibular molar restored with a single 5-mm-diameter Astra Tech implant. Because of mesial tilting of the adjacent molar, there is less space at the occlusal level compared to the bone level.



**Figure 4.11** A Straumann wide-bodied, wide-necked implant. This is a good choice for single molar replacement.



**Figure 4.12** (A) Radiograph of a maxillary first molar space showing insufficient bone due to an enlarged maxillary sinus. (B) Radiograph immediately following bone grafting using a lateral window approach to the sinus. (C) Healing of the sinus bone graft after a period of four months. (D) Completed molar restoration using an Astra Tech 5-mm-diameter implant and a single-piece screw-retained crown.

## BIBLIOGRAPHY

- Bahat O, Handelsman M. Use of wide implants and double implants in the posterior jaw: a clinical report. *Int J Oral Maxillofac Implants* 1996; 11:379–386.
- Balshi TJ, Hernandez RE, Pryszyk MC, et al. A comparative study of one implant versus two replacing a single molar. *Int J Oral Maxillofac Implants* 1996; 11:372–378.
- Becker W, Becker BE. Replacement of maxillary and mandibular molars with single endosseous implant restorations. *J Prosthet Dent* 1995; 74:51–55.
- Levin L, Laviv A, Schwartz-Arad D. Long-term success of implants replacing a single molar. *J Periodontol* 2006; 77:1528–1532.

Levine RA, Ganeles J, Jaffin RA, et al. Multicenter retrospective analysis of wide-neck dental implants for single molar replacement. *Int J Oral Maxillofac Implants* 2007; 22:736–742.

Polizzi G, Rangert B, Lekholm U, et al. Branemark System Wide Platform implants for single molar replacement: clinical evaluation of prospective and retrospective materials. *Clin Implant Dent Relat Res* 2000; 2:61–69.

Wolfinger GJ, Balshi TJ, Wulc DA, et al. A retrospective analysis of 125 single molar crowns supported by two implants: long-term follow-up from 3 to 12 years. *Int J Oral Maxillofac Implants* 2011; 26:148–153.

## Fixed bridge planning

### INTRODUCTION

Planning for implant-supported fixed bridges follows the lines described in the previous chapters. The chapter on single tooth replacement in the anterior region dealt with the aesthetic demands and the chapter on molar replacements with some of the loading and spacing considerations. Small edentulous spans with adequate bone volume can be relatively straightforward (Fig. 5.1A,B). Extensive bridgework in partially dentate and edentulous jaws involves planning for placement of multiple implants in sites that may be more demanding surgically (see chaps. 10 and 12). The number and distribution of implants in such cases is a complex variable and is discussed below.

### CLINICAL EXAMINATION AND DIAGNOSTIC SETUPS

Patients requiring extensive fixed bridgework often need more detailed examination and consideration of treatment alternatives than those requiring more simple restorations. In addition, evaluation of the edentulous patient needs additional considerations when compared to the partially dentate patient. In partially dentate patients:

1. A thorough examination of the restorative, endodontic, and periodontal status of the remaining teeth is required. This should reveal treatment needs and give an indication of the prognosis of the remaining teeth. This is extremely important as implant restorations can offer a good long-term prognosis and adjacent teeth or opposing teeth should for the most part offer a comparable prognosis. This is not always the case and the patient should be made aware of the potential prognosis of the natural dentition and the possibilities for future replacement, should this become necessary. A good example would be the replacement of missing units in one jaw opposing teeth in the other jaw that have a limited prognosis. Although replacement of the opposing teeth may be straightforward with conventional dentistry or implants, implant replacement in the opposing jaw may be impossible without involving major bone grafting (Fig. 5.2A,B), a treatment that the patient may not be willing to undergo.
2. The degree of ridge resorption is evaluated. It is important to recognize not only the degree of resorption that would compromise implant placement but also that which would compromise aesthetics because of a high lip line or insufficient lip support (Fig. 5.3A–C). These factors should be further assessed using diagnostic wax-ups and diagnostic removable prostheses.
3. The occlusal relationship in centric jaw relationship and protrusive and lateral excursions of the lower jaw should

be examined and recorded. The vertical height within the existing and planned occlusal vertical dimension is the other important factor. There may be insufficient height to accommodate the prosthesis from the implant head due to overeruption of the opposing teeth or where the other teeth in the jaw have reduced crown heights (Fig. 5.4A–C). The other extreme is where there is a large vertical space to be restored, which would produce an unfavorable restoration height. The crown-implant ratio is often compared to the crown-root ratio in the natural dentition. However, this situation is quite different in the case of osseointegrated implants where forces are concentrated at the marginal bone and the abutment-implant interface compared to a distribution of forces via the periodontal ligament. This can make the abutment connection vulnerable to technical complications where the restoration height is excessively high (Fig. 5.5A,B). The forces on the planned prosthesis are also increased where the prosthesis is likely to be cantilevered, either distally in a free-end saddle or anteriorly where the jaw has resorbed relative to the required tooth position. These factors assume greater importance in patients who exhibit parafunctional activities and who have limited bone volume and/or quality (Fig. 5.6A,B).

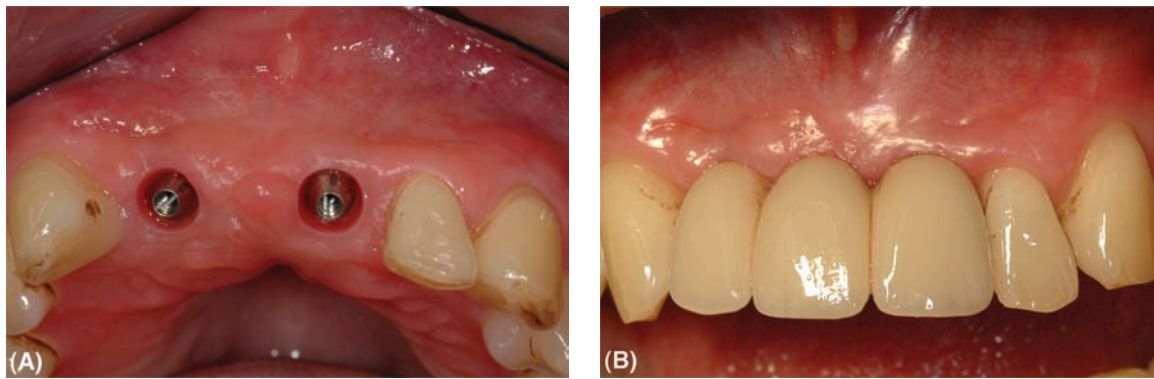
Additionally, in edentulous patients, the degree of ridge and jaw resorption affecting soft tissue support and maxillary-mandibular relationships should be evaluated. With progressive resorption, patients are more likely to acquire a pseudo class 3 jaw relationship and very poor lip support. The potential solutions to this problem are extensive bone grafting/osteotomy (chap. 12) or provision of overdentures, which is dealt with in detail in chapter 6.

Other points to remember are as follows:

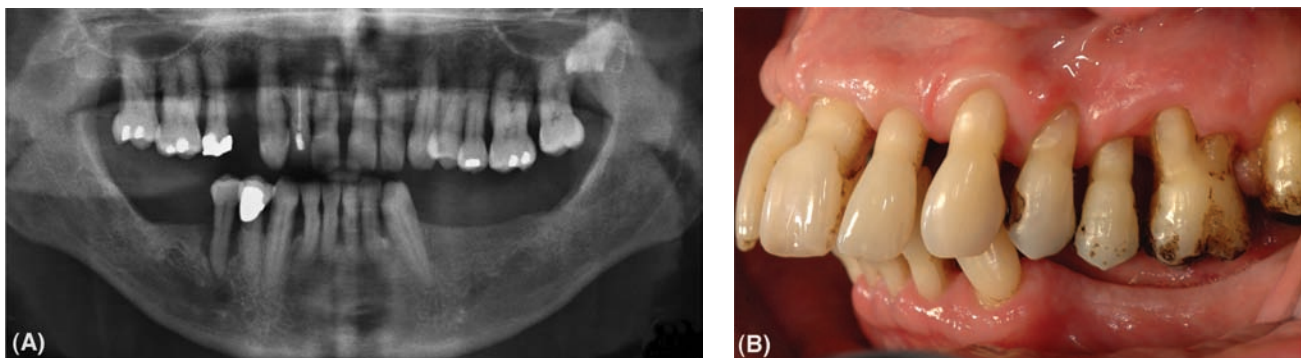
- In severely resorbed cases, a fixed bridge prosthesis will almost certainly require the addition of prosthetic gingivae.
- The restoration height is more likely to be unfavorable.
- Resorption of the ridge produces a smaller arc of bone to support the implants than that existed to support the teeth (Fig. 5.7A,B).

### Diagnostic Setups

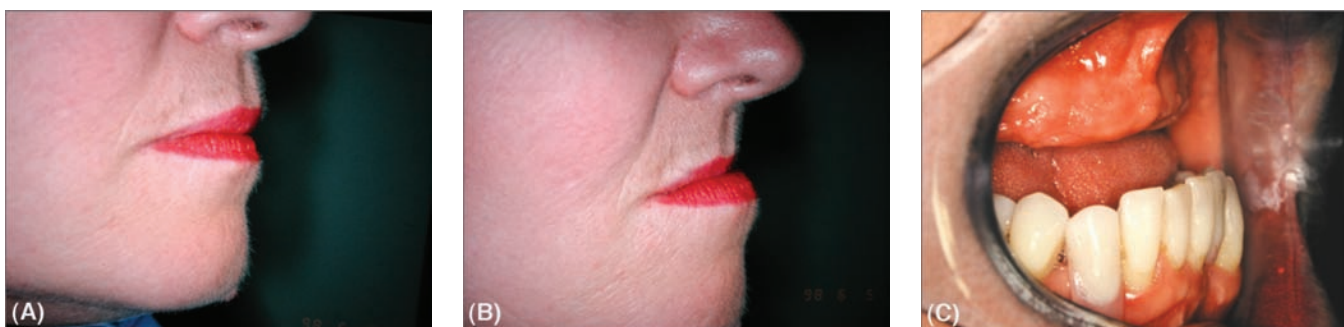These should follow the principles described in the chapter on general planning and single tooth planning. The larger the restoration, the more complex the evaluation. There is also a greater need for the patient and clinician to be able to visualize the potential end result. We would advocate the use of removable dentures with gum-fitted teeth (and labial flanges for comparison) to achieve this (Fig. 5.8).



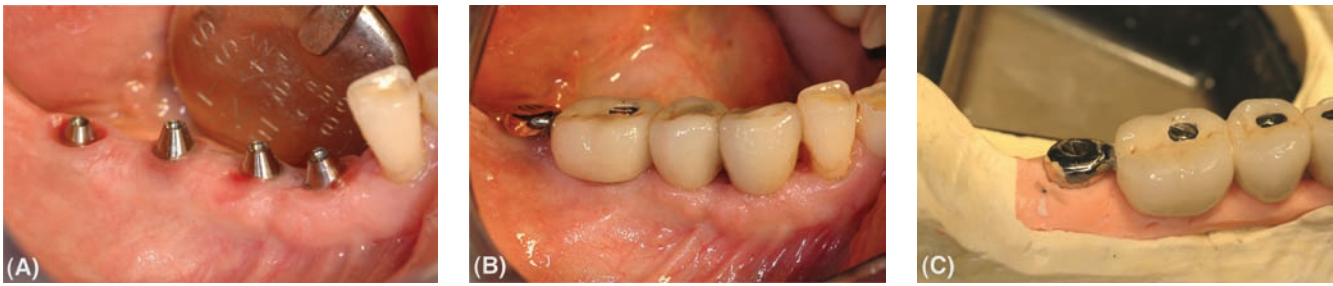**Figure 5.1** (A) Clinical appearance of two implant abutments in a favorable edentulous space with good bone volume. Implant positioning is ideal for a screw-retained prosthesis. (B) Fitted bridge with a ridge-lap configuration allowing for the cervical margins to be positioned in an optimal position.



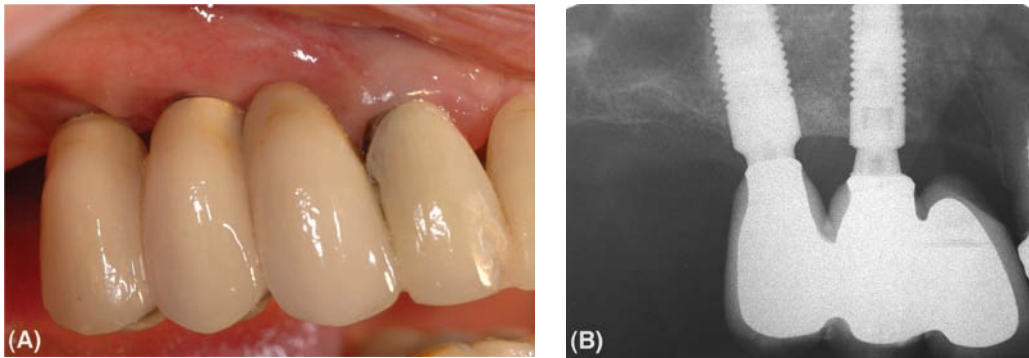
**Figure 5.2** (A) Radiograph showing good bone height in the mandible. (B) However, the prognosis for the maxillary teeth may be poor. Loss of these teeth would put a different perspective on the management of the lower jaw.



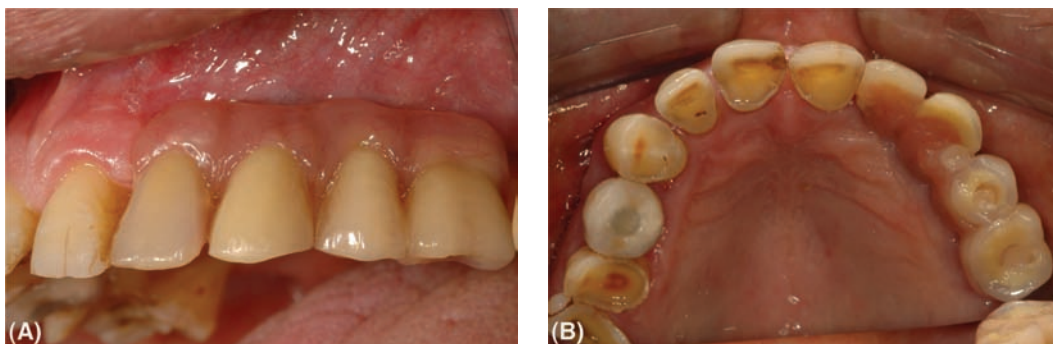
**Figure 5.3** (A) Patient with an upper complete denture with lips at rest showing good lip support. (B) Removal of the denture and in particular the flange results in collapse of the upper lip and giving the presentation of a pseudo class 3 jaw relationship. (C) The degree of ridge resorption that could compromise implant placement and subsequently affect the nature of reconstruction possible without bone grafting.



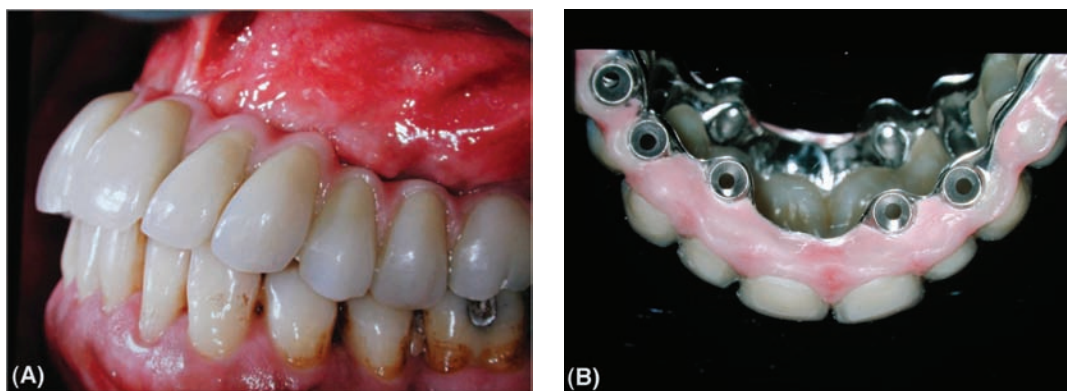
**Figure 5.4** (A) Implant patient with short clinical crown heights (due to bruxism) that restricts the available space for the prosthesis from the implant head. A shorter abutment height has been placed in the most distal implant to accommodate the superstructure. (B) Screw-retained restoration in situ. With reduced space, screw retention offers retention that could be compromised with a cement-retained bridge. (C) Diminutive distal crown due to compromised space.



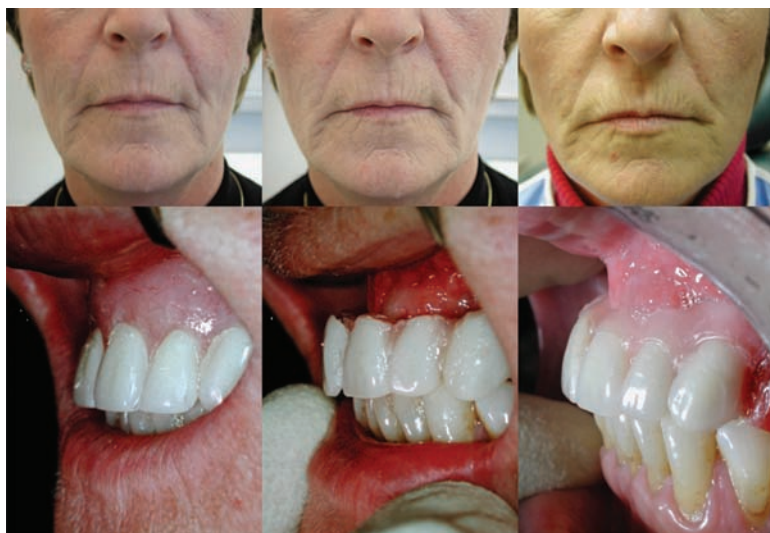**Figure 5.5** (A) A patient with a three-unit implant-supported bridge in the upper right quadrant distal to the lateral incisor. The bridge has long crowns because of pronounced vertical bone resorption following tooth loss. (B) Radiograph showing sufficient bone to engage implants of 11 mm in length. Lip coverage was favorable.



**Figure 5.6** (A) Implant replacement of missing teeth in the upper left quadrant in a parafunctional patient with buccal bone resorption. Adequate support provided by the provision of prosthetic “gumwork.” (B) One-year appearance of screw-retained bridge constructed with acrylic denture teeth to allow resilience and ease of long-term maintenance.



**Figure 5.7** (A) A patient exhibiting a pseudo class 3 jaw relationship with a full-arch maxillary implant bridge. A fixed option was possible in this case without grafting. (B) Fit surface of the bridge showing extent of buccal buildup and position of implants that are palatally placed in a smaller arc.



**Figure 5.8** Patient with anterior tooth loss where the existing denture had a large labial flange to provide lip support (*left*). The use of a diagnostic denture without the flange can help the clinician and patient visualize the end result intraorally and assess the lip support (*center*). The slight loss of lip support with a gum-fitted setup (*right*) was acceptable to the patient to achieve an eventual fixed result (*right*).

## RADIOGRAPHIC EXAMINATION

In some situations, the simpler radiographic techniques of dental panoramic tomographs (DPTs) and conventional film tomography will be entirely adequate (see chap. 4). However, complex cases often demand 3D imaging with computed tomography (CT) scans offering multifformat images for detailed planning. They are particularly useful for cases involving

1. Posterior mandible sites, where the position of the inferior alveolar nerve is important.
2. Large-span edentulous spaces in the maxillary arch. In the anterior region, thin ridges may be revealed where DPT images have suggested adequate bone height, and in the posterior region, more detailed images of maxillary sinus involvement are often required.

CT uses X rays to produce sectional images as in conventional tomography. High- resolution volumetric images are achieved by initially scanning using a fan-beam in an axial plane, keeping the sections thin, and by making the scans contiguous or over-

lapping. The scans should be limited to the area of interest and avoid radiosensitive tissues such as the eyes. The patient's head is aligned in the scanner with light markers, and a scout view obtained that gives an image similar to a lateral skull film. The radiation dose of this scout view is low and can be repeated if the alignment is incorrect. Generally, the mandible is scanned with slices parallel to the occlusal plane and the maxilla, using the same plane or one parallel to the hard palate. Deviation from this alignment will result in the cross-sectional slices not being in the same direction as the proposed implant placement (see radiographic stents). In place of conventional film the radiation is detected by highly sensitive crystal or gas detectors, which is then converted to digital data. This data can be reconstituted using a software program to create multiplane sections.

Images can be produced as

1. Standard radiographic negative images on large sheets
2. Positive images on photographic paper, often in book form
3. Images for viewing on a computer monitor

The various scan images can be measured for selection of length and diameter of implant. Although the nominal magnification of the images is 1:1, some machines and cameras produce images where the magnification may vary. A scale is usually incorporated alongside the various groups of images and the real magnification can be determined from this. A correction factor can then be applied to measurements taken directly from the films.

Metallic restorations can produce a scatter-like interference pattern if they are present in the slice under examination and the interference will therefore appear in all the generated sectional images. These beam-hardening artifacts may render a CT scan unreadable and can be produced by large posts in root canals or heavily restored teeth where the plane of examination passes through such a tooth as well as an area of critical interest. Conventional tomography can be considered as an alternative if interference is likely to be an issue.

One of the advantages of the computer-based image software programs (e.g., SimPlant) is that it is possible to generate images of implants (and their restorative components) that can then be "virtually placed" within the CT scan (Fig. 5.9). This enables the clinician to evaluate the relationships between the proposed implants and ridge morphology, anatomic features, and adjacent teeth. It is also possible to assess the abutment space, implant angulation, as well as the restorative space. Approximation of bone density is also possible (Fig. 5.10A,B). Planning data can be used to produce anatomical stereolithographic models useful for the planning, simulation, and optimization of complex surgical cases. These models can be used to provide patient-specific surgical guides, which translate planning to a drill guide allowing correct angulation and location of planned implant sites. These drill guides can be bone, mucosa, or tooth supported (Fig. 5.11A,B).

Further evolution of this technology has led to the concept of computer-guided flapless surgery. A mucosa-borne drill guide is secured to the jaw with fixation screws and implant surgery is performed with a specific surgical protocol, using dedicated instruments to position the implants into predetermined sites. This allows for the precise intraoperative transfer of preoperative planning facilitating the insertion of a prefabricated provisional prosthesis on the day of implant

surgery. Reconstructions of this nature must be considered complex and only embarked on with appropriate further training.

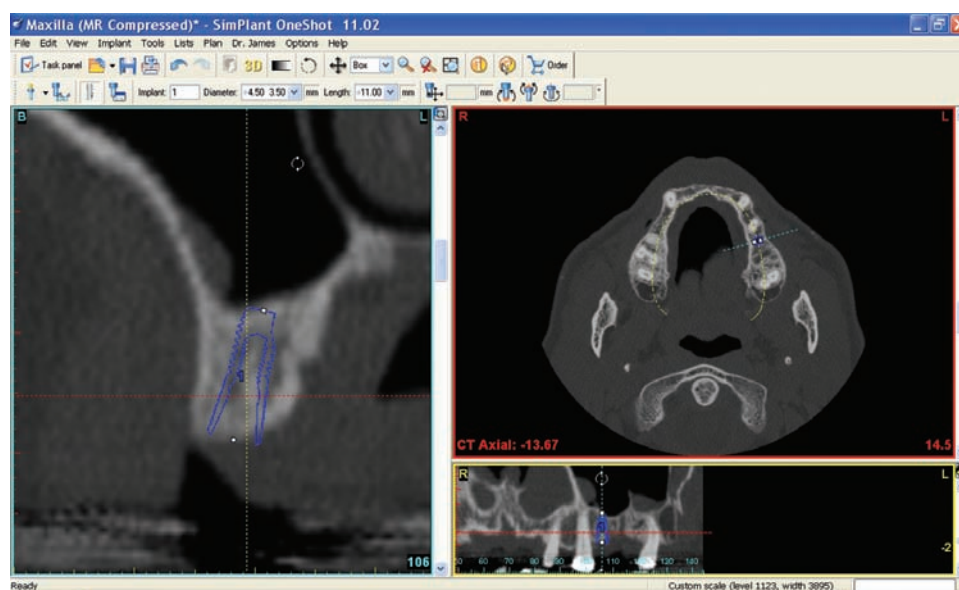
More recently, the advent of cone-beam computed tomography (CBCT) has led to the development of imaging equipment specifically for dental practice. Imaging is based on the production of a cone-shaped X-ray beam revolving around the object, which captures 2D data allowing reconstruction into 3D images using a software program. Apart from cross-sectional images, CBCT is also capable of producing 2D panoramic images without the superimposition of adjacent structures (Fig. 5.12). CBCT images also tend to be clearer as the effects of beam-hardening artifacts such as metallic restorations are less severe. Exposure to ionizing radiation is substantially reduced when compared to conventional CT. CBCT machines can also capture varying volumes of data. This allows radiation exposure to be further limited to the field of interest. It is, however, still greater than conventional dental radiography and its use therefore needs to be justified.

## PLANNING IMPLANT NUMBERS AND DISTRIBUTION

In planning fixed bridgework supported by implants, there are recommendations regarding the minimum number of implants that would be required (Table 5.1). Increasing the number of implants allows for failure of an implant (or more than one) and may provide improved long-term predictability. Current concepts have been developed where full-arch implant bridges are supported by four implants and these seem to show promising results. Multiple implants (i.e., more than two) can be staggered and not necessarily placed in a straight line to improve the mechanical loading (see below).

## Configuration and Angulation of Implants

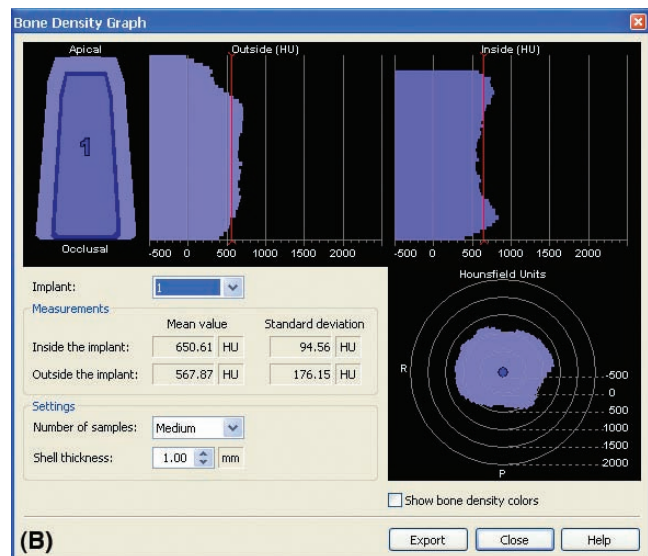
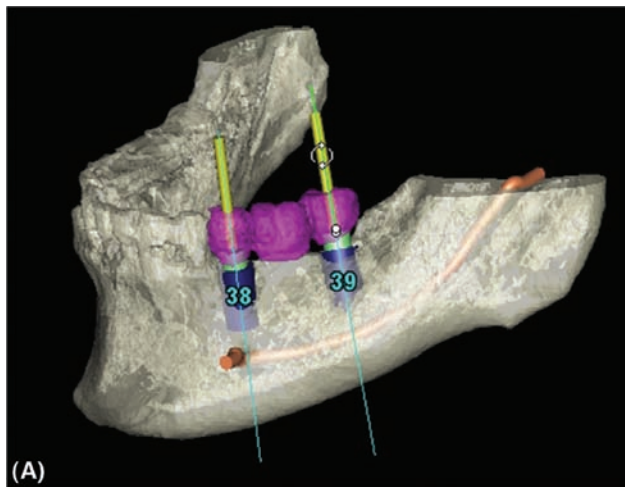
The configuration of the implant sites, the angulation of the implant sites, as well as the angulation of the implants have considerable impact on the structural/load bearing capacity of the prosthesis. In edentulous full-arch cases, it is important to distribute implants throughout the curve of the arch and



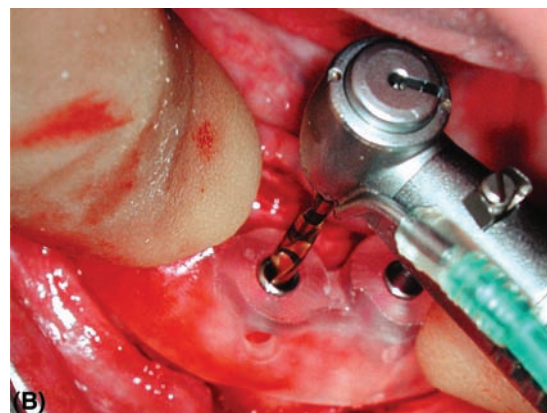
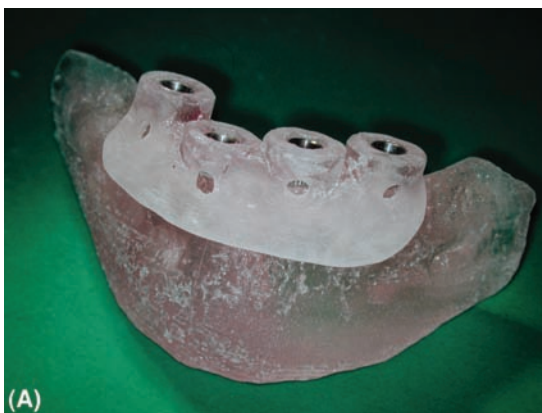**Figure 5.9** SimPlant (Materialise Dental NV, Leuven, Belgium) software showing "mock" implant placement in the maxilla. The image on the left is a cross-sectional image showing the contours of a virtually placed implant. The mesiodistal position of the implant can be seen in the panoramic view (*bottom right*) and also in the axial view (*top right*).

**Table 5.1** Guide for Implant Numbers in Various Circumstances

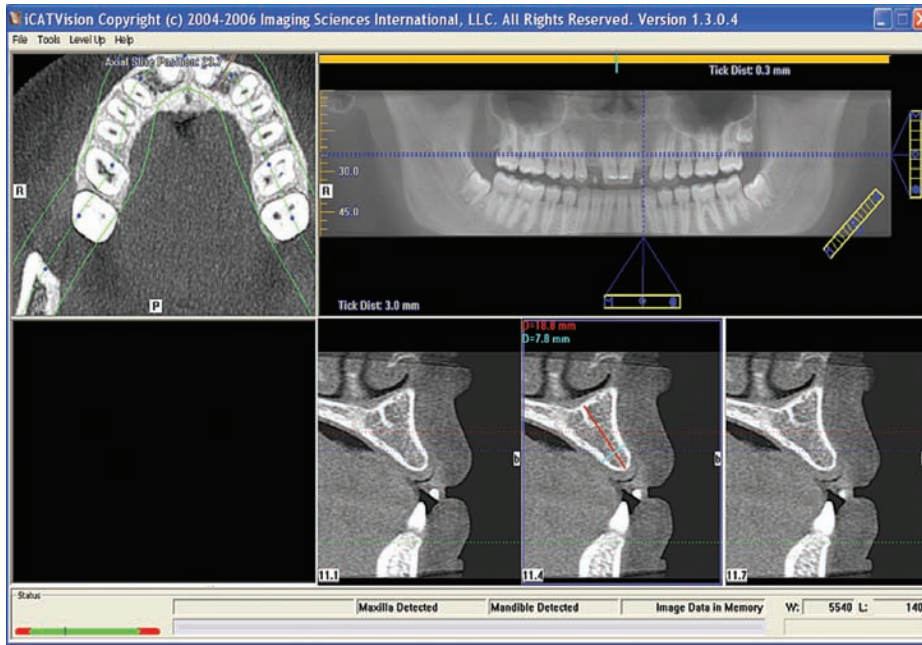
Examples of types of replacement required	Suggested number of implants and prosthetic solution
Full-arch bridges in edentulous maxilla	At least five or six implants—preferably extending to second premolar region. Additional implants in molar regions recommended by many clinicians
Full-arch bridges in edentulous mandible	At least four or five implants in the region between the mental foramina. Additional implants in molar regions recommended by many clinicians
Missing molars	Two missing molars normally require three standard-diameter implants. Two wide-diameter implants could be used to support a bridge or two single tooth molar units.
Three missing maxillary anterior teeth	Two or three implants supporting a bridge If there is sufficient space for three implants, consider three single tooth units
Four missing maxillary anterior teeth	Four upper incisors would require two implants to support a bridge. If there is sufficient space for four implants consider four single tooth units
Four missing mandibular incisors	Four lower incisors could be replaced using two implants and a fixed bridge. There is usually not enough room for more implants. The same solution may be adequate to replace mandibular canines and incisors (which is not the case in the maxilla)



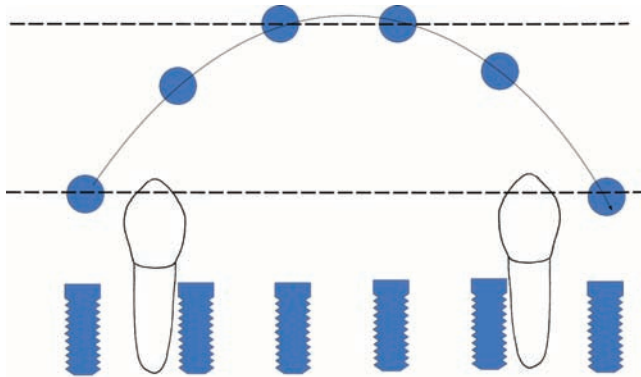
**Figure 5.10** (A) Additional 3D capabilities allowing 3D implant manipulation as well as a realization of the abutment and restorative spaces. Nerve tissue can be highlighted within the jaw using a transparency tool. (B) The SimPlant software program can also depict bone density levels around the implant as measured by Hounsfield units.



**Figure 5.11** (A) 3D planning used to create an anatomical model as well as a custom-made drill guide (SurgiGuide, Materialise Dental NV). (B) Drill guides can be used at the time of surgery to provide a seamless link between planning and actual treatment.



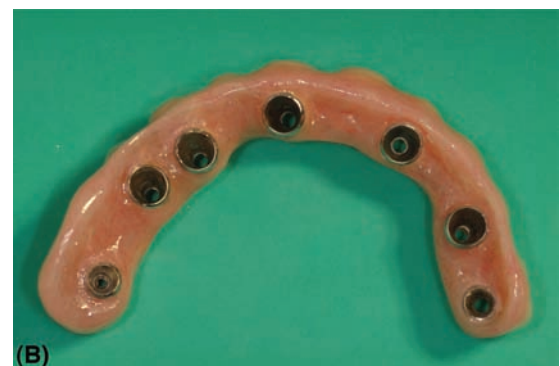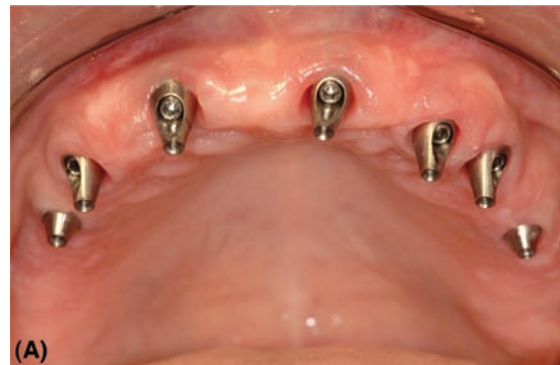**Figure 5.12** An i-CATVision (Imaging Sciences, Hatfield, Pennsylvania, U.S.) scan using cone-beam technology that leads to a reduction in radiation exposure. The images are 1:1 allowing distances to be measured on the cross-sectional images (*bottom right*). The panoramic view generated (*top right*) is free of superimposition of adjacent anatomical tissues. Manipulation of the “focal trough” on the axial view (*top left*) can be carried out to yield an accurate view.



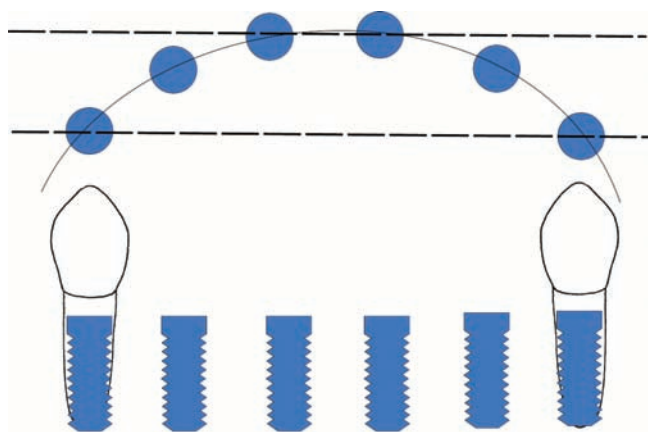
**Figure 5.13** Six implants have been arranged so that the most distal implants have been placed distal to the first premolars. The anteroposterior distance between implants has been increased greatly, providing an improved biomechanical arrangement. Additionally, this arrangement could more adequately support distal cantilever extensions.

ideally beyond the premolar areas to the molar zones as this offers a biomechanical advantage (Fig. 5.13). The possibility of extending the implant placement beyond the premolar zone into the molar zone depends on the amount of available bone (Fig. 5.14A,B). Unfortunately, adequate bone in these zones is not always present in completely edentulous jaws and faces the clinician with three choices:

1. Surgery to create sufficient bone (see chap. 12)
2. Angling the implant to place the head of the implant into a more posterior position
3. Not utilizing the area for implant placement (Fig. 5.15)



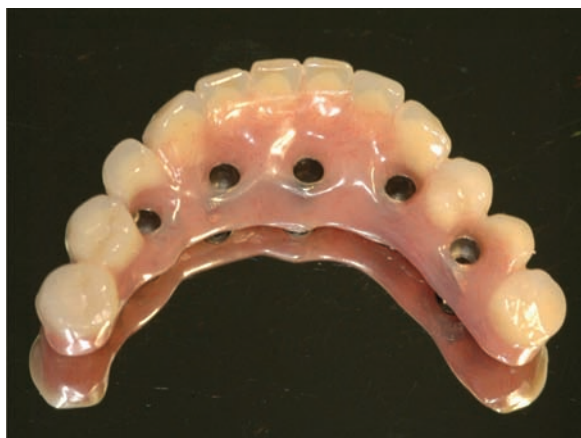**Figure 5.14** (A) Intraoral view showing abutments corresponding to the distribution and arch form of the implant positions. Implant placement in the molar regions was possible. (B) Maxillary full-arch bridge viewed from the under surface showing full distal support avoiding cantilevers. This configuration is biomechanically advantageous.



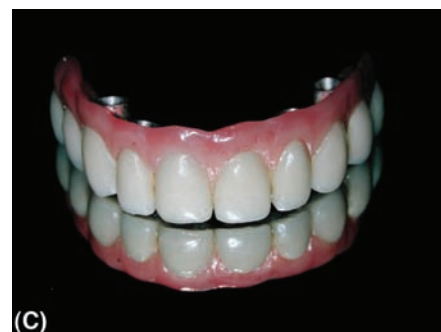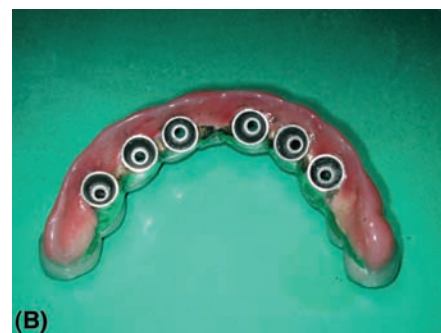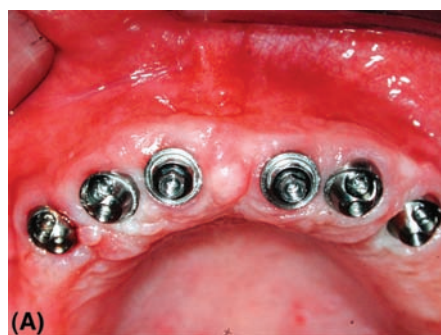**Figure 5.15** An example of six implants arranged in the lower jaw in the region between the mental foramina with the most distal implant in the first premolar site. In this case, the anteroposterior distance between implants shown by the dashed lines is not very great because of the shape of the jaw.

The latter situation may be overcome by distal cantilevering of a prosthesis. This can often be the case when implants are placed in the interforaminal region in the mandible (Fig. 5.16). There are limits to this strategy. The cantilever should extend no more than twice the anteroposterior spread of the implants placed (Fig. 5.17A–C).

In edentulous zones in the partially dentate individual, the configuration of implants assumes the same degree of importance. It is generally recommended to avoid placement of multiple implants in a straight line (Figs. 5.18 and 5.19). In the situation where three implants are provided, offsetting one implant to produce a tripod arrangement is recommended (Fig. 5.19). This will improve the situation even if the offset is minor, which is often the case in the posterior mandible and maxilla (Fig. 5.20A–C). Two wide-diameter implants can also be used to support three units in posterior regions if ridge width is adequate (Fig. 5.21).

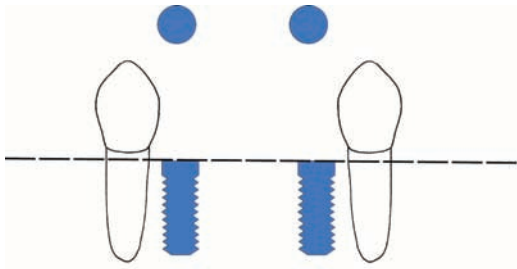


**Figure 5.16** A mandibular full-arch bridge showing a reduced anteroposterior span between the most anterior and distal implants. This restricts the length of the possible cantilever.

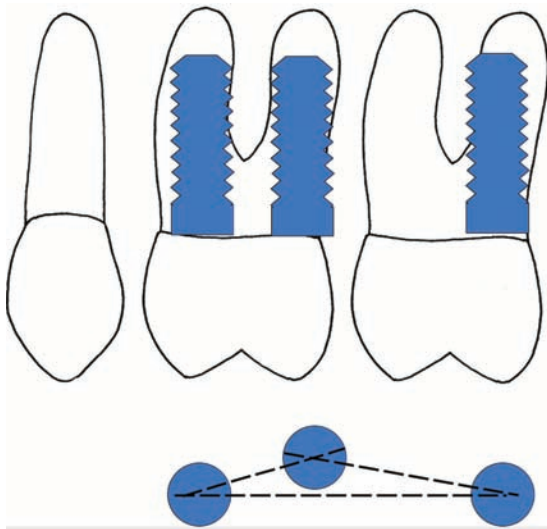


**Figure 5.17** (A) A square arch form in the maxilla coupled with poor bone volume in the molar regions can affect anteroposterior positioning as shown by this intraoral view. (B) Fit surface of the maxillary full-arch bridge restricted cantilever extensions to control leverage forces. (C) "Shortened dental arch arrangement" that, in this case, was sufficient to maintain function and appearance.

The angulation of the implant sites more or less mimics the angulation of the natural teeth, with modifications according to the design of the final prosthesis and the degree of ridge resorption. A surgical stent provides important guidance. If the final prosthesis is designed to be retrievable/screw retained, the ideal angle of the implant passes through the cingulum area of the anterior teeth and the occlusal surfaces of the premolar/molar teeth. In a cemented prosthesis, the angulation should be the same in the posterior teeth as this is also consistent with loading the implants through the long axis. However, in the anterior zone, the angulation can be more labially inclined through the incisal tip or toward the labial surface, potentially improving the emergence aesthetics (see chap. 9). However, force transmission through the anterior implants may be less favorable as it will be far removed from axial loading (Fig. 5.22). Further consideration of the angulation and spacing of different implant designs is given in the surgical chapters (chaps. 9 and 10).



**Figure 5.18** Two implants are always in a straight line. This arrangement may be entirely adequate for replacing the four lower incisors using two implants, and with favorable conditions could apply to the four upper incisors or the six lower anterior teeth (incisors and canines). However, it is generally considered an inadequate number for replacing three posterior units with standard-diameter implants, where the advantage of a three-implant tripodization arrangement is recommended.

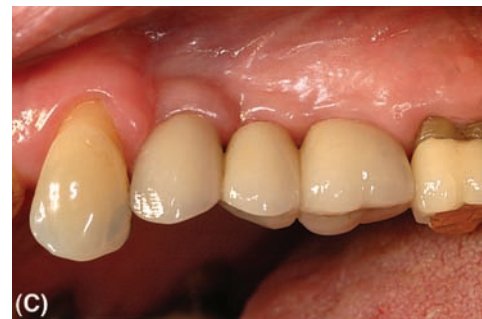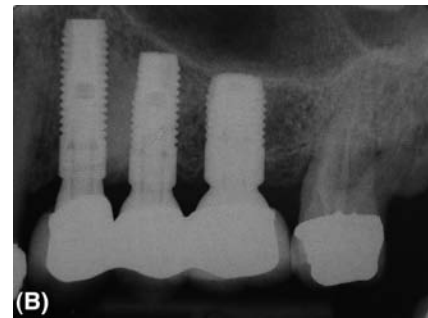
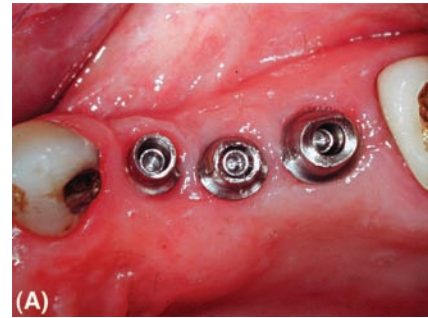


**Figure 5.19** Three implants have been placed to support two molar units. The lower part of the figure represents a plan view with the middle implant offset slightly to produce a tripod arrangement (*dashed lines*) and improved biomechanical properties.

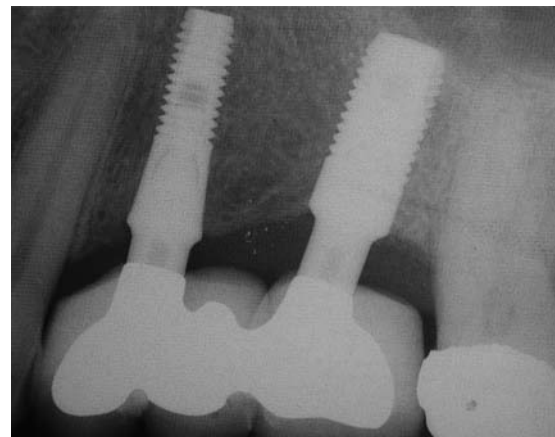
### FIXED BRIDGES OR MULTIPLE SINGLE UNITS

There is a trend to place an implant for each individual missing tooth, in which case it would be possible to restore each as a separate single tooth unit. This approach, although first appearing very logical, is difficult to achieve in practice and may not be as predictable in its outcome. There are a number of potential problems with this approach:

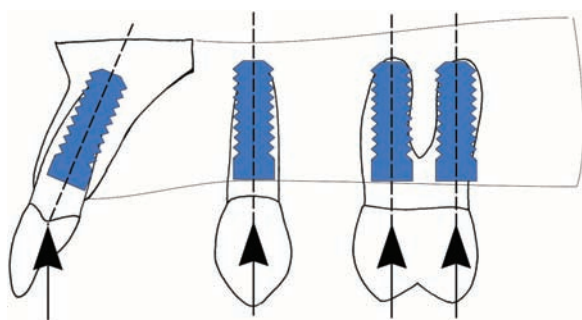
1. Some teeth, such as lower incisors, have a small mesio-distal dimension that is less than most implants.
2. Teeth can function perfectly well with very small amounts of intervening hard and soft tissue (less than 1 mm), unlike implants.
3. As teeth are lost and the jaws resorb, the perimeter of the arch decreases, thus reducing the space for implant



**Figure 5.20** (A) Implants placed with a "staggered" effect to produce a tripod arrangement. The degree of tripodization can be restricted by the available bone volume as well as the prosthetic demands. (B) Radiograph showing three Astra Tech implants supporting the bridge. (C) A buccal view of the completed bridge.



**Figure 5.21** Radiograph showing the use of two wide-diameter implants to support a three-unit posterior bridge.



**Figure 5.22** Forces directed through implants placed in the posterior jaw will usually be in the same long axis as the premolar and molar teeth. Labial angulation of the anterior implants means that normal forces are not directed down the long axis.

placement. The implant spacing requirements are naturally affected by the system selected.

4. The angulation of natural roots in the healthy alveolus may be impossible to mimic in the resorbed jaw. Proclination of natural anterior teeth and anatomical variations such as crown/root angulations are difficult to mimic with implants.
5. Tapering of normal root forms may allow more teeth within a given area of jaw bone. Tapered implants may have an advantage in certain cases, although few designs mimic pronounced tapering seen in some natural teeth.
6. Failure of a single implant in a multiple single-unit case requires replacement of that unit. The fixed bridge solution may still be workable with one implant less.
7. Provision of a fixed bridge with fewer implants than the teeth that are being replaced is more economical/cost effective.
8. The splinting afforded by the fixed bridge may improve the biomechanical properties.

The potential advantages of multiple single units are as follows:

- More natural appearance
- No need for complex casting to precisely fit multiple abutments
- Simpler prosthodontic procedures
- Patient can floss between units

But there are additional disadvantages:

- Multiple cementation of units
- Multiple paths of insertion and contact points

## PROVISIONAL RESTORATIONS

### Removable Dentures

The most simple provisional prosthesis is a complete or partial removable denture. When constructed in acrylic, they provide an inexpensive and readily adjustable prosthesis that can be modified to produce a radiographic stent or duplicated and modified to produce a surgical stent. In cases where the implant surgery has been extensive, for example, placement of four or more implants in an edentulous jaw, it is commonly recommended to avoid wearing the denture for a period of at

least a week. This avoids early transmucosal loading of the implants and allows adequate reduction of post surgical edema to take place, facilitating proper adaptation of the denture. A complete upper denture can usually be relined and refitted after one week, but the atrophic edentulous lower jaw can require a period of up to two weeks of healing before a complete denture can be worn satisfactorily.

### Essix Splint

With small spans, consideration can be given to an Essix splint modified by the incorporation of artificial teeth as an alternative to a partial denture. This also has the benefit of avoiding transmucosal loading.

### Fixed Bridgework

Provisional fixed bridgework retained by full-coverage restorations may be the treatment of choice, particularly for patients having extensive treatment who are not prepared to undergo a period of time without a fixed restoration. This assumes the presence of a sufficient number of teeth to support the provisional restoration. Transitional mini implants (very narrow diameter implants) placed between the definitive implants can be considered as provisional bridge supports and removed before the final prostheses is constructed. Fixed provisional bridgework enables ridge augmentation procedures to be carried out without the risk of transmucosal loading and the associated micromovement affecting the healing, and should reduce complications. The bridgework may have to remain in place for some considerable time, with frequent removal and replacement. Abutment teeth must be adequately prepared to allow for the casting of a metal framework of sufficient strength and rigidity and for the acrylic/composite. Allowance should be made for the fact that the bridge will have to be modified following abutment connection.

## TREATMENT SCHEDULES

These are usually more complex than those described for single tooth, but follow the same principles:

1. Initial consultation, clinical evaluation, and radiographic examination that often involves tomography.
2. Agreement of aesthetic/functional demands using existing prosthesis or diagnostic setup/new provisional prosthesis. Decision on whether to provide a fixed bridge or an overdenture (see chap. 6).
3. Treatment of related dental problems that could compromise implant treatment, including timing of further extractions and relationship to implant placement (see chap. 11 on immediate implant placement).
4. Planning number, type, and location of implants in relation to planned prosthesis and available bone. Decision as to whether bone or soft tissue augmentation is required prior to implant placement.
5. Arranging type of anesthesia—local, local plus sedation, or general anesthesia.
6. Surgical placement of the implants and provision of temporary prosthesis.
7. Healing phase to allow osseointegration according to established protocols and complexity of case.
8. Abutment connection and modification of prosthesis or construction of new implant-borne provisional prosthesis.
9. Number of appointments for prosthodontic treatment.

## CONCLUSION

The treatment planning for extensive bridgework has a far greater number of variables to contend with and a number of alternative solutions. The patient needs to be made aware of these, but in many cases will have to rely upon the treating clinician for guidance. Good recording, documentation, and communication are required to maintain a good patient-clinician relationship. Patients should also realize that the maintenance requirements of extensive prostheses are likely to be much higher than those described for single tooth restorations (see chap. 16).

## BIBLIOGRAPHY

- Arvidson K, Bystedt H, Frykholm A, et al. Five-year prospective follow-up report of the Astra Tech Dental Implant System in the treatment of edentulous mandibles. *Clin Oral Implants Res* 1998; 9:225-234.
- Bahat O. Treatment planning and placement of implants in the posterior maxillae: a report of 732 consecutive Nobelpharma implants. *Int J Oral Maxillofac Implants* 1993; 8:151-161.
- Belser UC, Mericske-Stern R, Bernard JP, et al. Prosthetic management of the partially dentate patient with fixed implant restorations. *Clin Oral Implants Res* 2000; 11(suppl 1):126-145.
- Brånemark PI, Svensson B, van Steenberghe D. Ten-year survival rates of fixed prostheses on four or six implants ad modum Brånemark in full edentulism. *Clin Oral Implants Res* 1995; 6:227-231.
- Harder S, Kern M. Survival and complications of computer-aided designing and computer-aided manufacturing vs. conventionally fabricated implant-supported reconstructions: a systematic review. *Clin Oral Implants Res* 2009; 20(suppl 4):48-54.
- Makkonen TA, Holmberg S, Niemi L, et al. A 5-year prospective clinical study of Astra Tech dental implants supporting fixed bridges or overdentures in the edentulous mandible. *Clin Oral Implants Res* 1997; 8:469-475.
- McAlarney ME, Stavropoulos DN. Determination of cantilever length from anterior-posterior spread ratio assuming failure criteria to be the compromise of the prosthesis retaining screw-prosthesis joint. *Int J Oral Maxillofac Implants* 1996; 11:331-339.
- Rangert B, Gunne J, Glantz PO, et al. Vertical load distribution on a three-unit prosthesis supported by a natural tooth and a single Branemark implant. An in vivo study. *Clin Oral Implants Res* 1995; 6:40-46.
- Rangert B, Jemt T, Jorneus L. Forces and moments on Branemark implants. *Int J Oral Maxillofac Implants* 1989; 4:241-247.
- Rangert BR, Sullivan RM, Jemt TM. Load factor control for implants in the posterior partially edentulous segment. *Int J Oral Maxillofac Implants* 1997; 12:360-370.
- Tan K, Pjetursson BE, Lang NP, et al. A systematic review of the survival and complication rates of fixed partial dentures (FPDs) after an observation period of at least five years. *Clin Oral Implants Res* 2004; 15:654-666.

## Diagnosis and treatment planning for implant overdentures

### INTRODUCTION

This chapter describes the diagnosis and treatment planning of patients for implant overdentures. These prostheses can be defined as complete or partial dentures supported, retained, or stabilized by one or more dental implants. In this book, the term “denture” refers to a patient-removable prosthesis.

The consequences of total tooth loss are well known and include bone resorption, changes in orofacial morphology and psychological effects. Treatment with conventional complete dentures has been shown to be reasonably successful when the residual alveolar ridges are favorable, when the dentures have been well made, and when the patient is reasonably philosophical about wearing dentures. However, such treatment has not been so successful when

1. The residual alveolar ridges are resorbed and even well-made dentures have poor support and stability.
2. Where movement of the dentures leads to discomfort, pain, and poor function.

This may be compounded by poor neuromuscular control in, for example, Parkinson's disease or following a stroke.

3. Where the dentures are not well tolerated because of emotional reasons or because of a strong gag reflex.
4. Where a single denture has poor stability because of opposing natural teeth. The worst combination is remaining maxillary teeth opposing a mandibular denture on a severely resorbed residual ridge.

These difficulties can be overcome by the use of osseointegrated implants to support, retain, and stabilize dentures, and such treatment has been shown to be effective in longitudinal studies. Many of the principles of treatment with implant overdentures are identical to those of treatment with conventional dentures and those of tooth-supported overdentures.

### INDICATIONS FOR IMPLANT OVERDENTURES AS DEFINITIVE TREATMENT

There are four main indications for implant dentures:

1. Where complete dentures have been worn successfully for many years but severe resorption (Figs. 6.1–6.3), or loss of neuromuscular control, now limits retention or stability causing movement of one or both dentures; where the patient has accepted the tooth loss and does not really mind wearing dentures.
2. Where a fixed restoration cannot provide sufficient replacement of resorbed hard and soft tissues to produce an acceptable appearance.
3. Where remaining natural teeth have an unfavorable distribution for retention and support of a removable partial denture (Fig. 6.4).

4. Where patients have had head or neck surgery that results in an alveolar defect/compromised anatomy (Fig. 6.5).

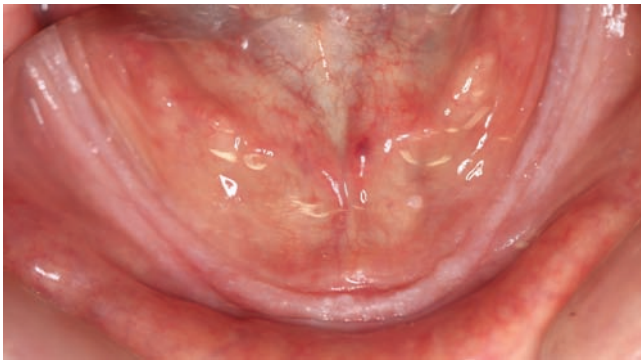
Where conventional complete or partial dentures are not well tolerated because of emotional reasons, the patient may not accept implant dentures because these prostheses are still patient-removable and may carry the “stigma” of “false teeth.” In this situation, the patient may wish to settle for nothing less than a completely fixed implant bridge. Where conventional dentures are not well tolerated because of a strong gag reflex, it may be possible to provide a maxillary implant denture with reduced palatal coverage, with impression making being more of a challenge. If sufficient numbers of implants can be placed, with grafting if necessary, it may be preferable to plan for an implant bridge at the outset. In the edentulous mandible, as few as three implants in good quality bone have been used to retain implant bridges.

Where the complaint is of lack of confidence and fear of movement of the denture, implant stabilization of the denture may be indicated even though ridge resorption may not be severe (Fig. 6.6). Where the residual ridges have undergone little resorption, however, there may be a shortage of vertical space for implant components. A lack of saliva especially in patients who have had radiotherapy or have been diagnosed with Sjogren's syndrome may also benefit from implant overdentures in spite of favorable ridge morphology (Fig. 6.7).

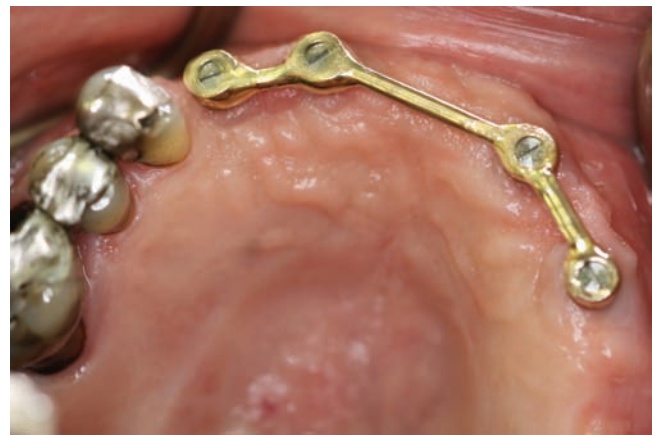Many alternative treatment plans in practice are developed because patients find their ideal treatment plan too expensive. This can lead to dissatisfaction in implant treatment because the apparently lower-cost option may be denture based, whereas the patient's ideal treatment is a fixed restoration. In reality, implant overdentures require considerable maintenance. Not only do the prostheses need repairing, relining, or replacing but the various attachment mechanisms between the implants and the overdenture are also subject to wear, fracture, and loss, and it is time consuming to replace them. The cost of this maintenance must be included in any comparison between the costs of fixed and removable implant prostheses.

### INDICATIONS FOR IMPLANT OVERDENTURES AS PROVISIONAL PROSTHESES

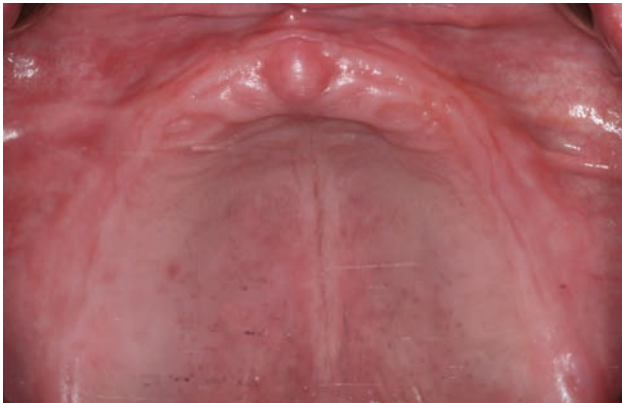
In those situations where a fixed implant bridge has been planned but some implants have failed, it may be necessary to provide a provisional implant overdenture until further implants can be placed. If the original clinical problem indicated a fixed solution, then that should be pursued. The factors that caused the first implants to fail may still be present and any remaining implants are more likely to fail.



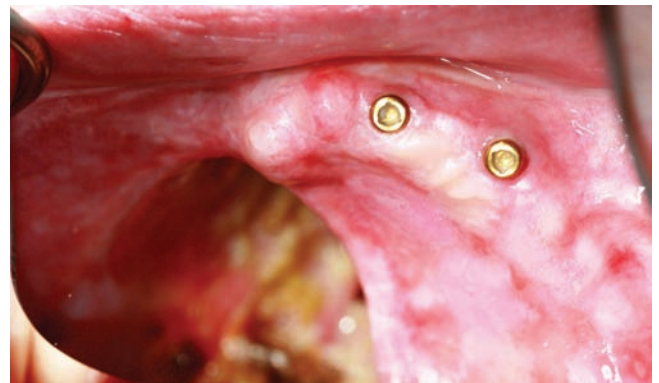**Figure 6.1** A resorbed mandibular ridge. The patient has a reduced denture bearing area, resulting in poor support for a conventional denture.



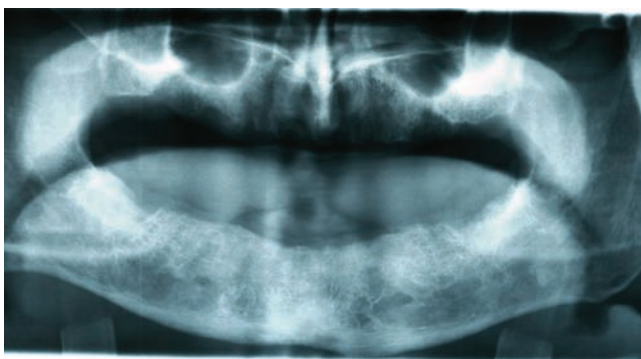
**Figure 6.4** Partially dentate patient with unilateral loss of teeth. Four implants were placed in the anterior region and a cast bar constructed to support and retain a partial overdenture. The extensive resorption meant that a fixed prosthesis could not provide the same facial support.



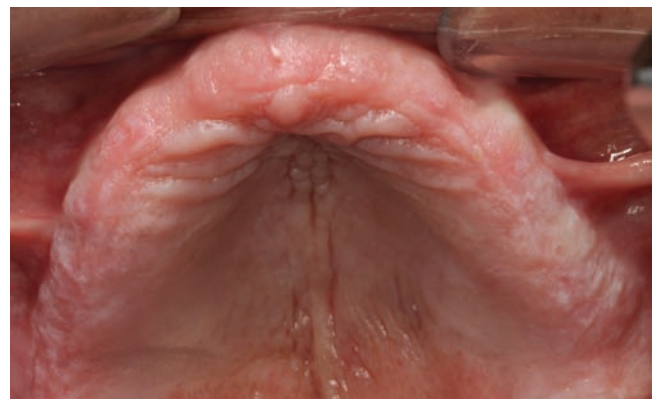**Figure 6.2** Maxillary ridge with extensive resorption in the tuberosity region. The prominent incisive papilla and remnant of the palatal gingival margin can act as guides to the position of teeth.



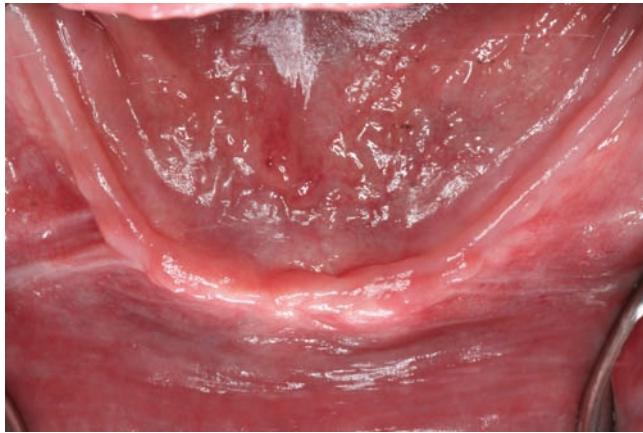**Figure 6.5** Maxillectomy with residual defect. The lack of support for the obturator will not be corrected by placement of the two implants, however the retention will be greatly improved.



**Figure 6.3** Dental panoramic tomograph (DPT) is useful for showing reduced bone height. Caution should be exercised when evaluating structures near the midline as distortion and magnification tend to be maximized in this area.



**Figure 6.6** Substantial alveolar ridges. Despite the good height and width of bone, the patient had not been able to tolerate a fully extended upper complete denture.



**Figure 6.7** Mandibular ridge of a patient with Sjogren's syndrome. The lack of alveolar ridge is made worse with a lack in saliva. An implant-retained overdenture will move less over the overlying mucosa causing less ulceration.

### ASSESSMENT OF THE PATIENT

The commonest denture complaints are about looseness, excessive size, pain or discomfort, inability to eat, lack of enjoyment of eating, lack of choice in foods to eat, poor appearance, and poor speech. Patients should be encouraged to describe their complaints in their own language. This will enable the dentist to gain insight in not only the patients concerns but also their personality. Some patients are very demanding, and will make much of a relatively minor problem, and are usually those who have not come to terms with the limitations of prosthetic dentistry. Patients, however, cannot be categorized into specific types, their prosthetic experience is dependent also on their previous experiences, experiences their friends have had, their social background, and any personal difficulties.

The recommended method of history-taking is well covered in standard textbooks about conventional complete dentures and so will not be repeated here. What you are trying to find out is whether or not the patient's clinical situation comes under the indications mentioned above and whether or not the patient would benefit from implant treatment. Every dentist has examined the patient who attends with a bag full of dentures made by numerous other dentists all of which are unacceptable. In such cases, it is essential that the treatment plan recommended is based on reality rather than hope.

Provision of an implant-retained overdenture will not correct the problems caused by a poorly constructed conventional denture. These problems are generally resolved by better conventional dentures construction and these should certainly be attempted prior to implants unless it is evident that implant treatment is also indicated. Complaints about poor appearance cannot be resolved by implant treatment per se, and poor implant placement may result in a more compromised appearance. But by setting the denture teeth in a more favorable position and utilizing appropriate size and shades of teeth will help. Using photographs of original teeth when available would be of use.

The medical history should be discussed, although there are very few contraindications to conventional complete dentures as they, and the treatment stages required to make them, are among the least invasive of any dental procedure. Some patients consider having dentures as the "beginning of the end,"

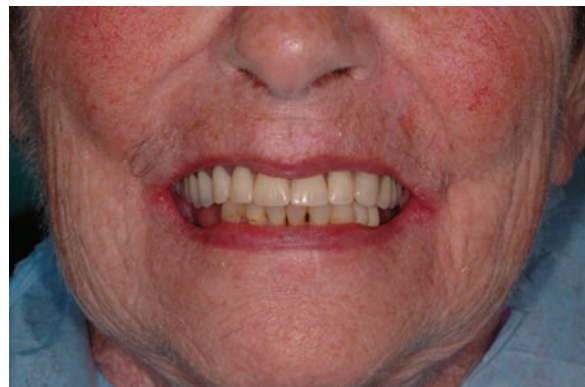related to aging and the loss of youth. Psychological problems caused by the loss of all teeth may be helped by implant treatment, but the outcome may be uncertain: unresolved conflict over the loss of the teeth may lead to an irrational response to treatment.

Inserting implants into bone is a surgical procedure and contraindications to surgery have been discussed in an earlier chapter. Prosthodontic contraindications would include lack of space in which to place components and parafunctional forces greater than those which the components can bear. However, if the implants themselves can withstand these forces, then you and the patient must accept that there will be more maintenance and repairs of the dentures than normal. The alternative is greater potential for pain, lack of function, and bone resorption with conventional complete dentures. The patient must be informed prior to treatment so that any subsequent explanation as to why bits keep breaking off the dentures is not perceived to be a lame excuse.

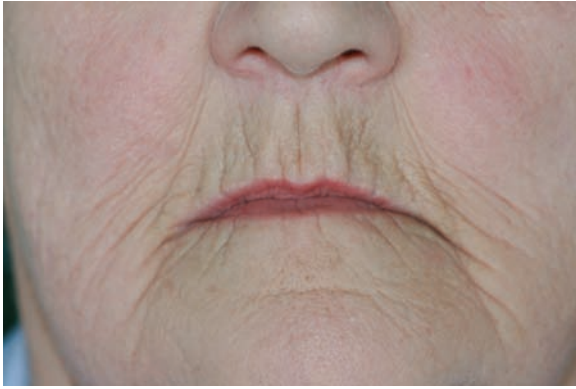Severe mental illness has generally been included in lists of contraindications for implant treatment because of the difficulties of reasonable informed consent. However, the mental problems that lead to severe denture intolerance and failure to come to terms with the loss of teeth are the same as those that would pose difficulties were implant treatment to fail. For patients in this group, it is crucial to know the likely response to failure of treatment. It is a difficult area to judge and referral to a clinical psychologist or psychiatrist may be necessary for advice.

### EXAMINATION OF THE PATIENT AND THE EXISTING DENTURES

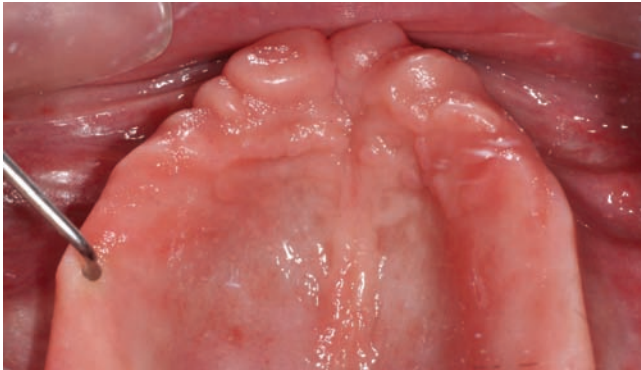While taking a history, the dentist is able to observe the patient's lip activity, support, and appearance. The face and mouth should be examined in a systematic manner for pathological conditions such as angular cheilitis (Fig. 6.8). Extraorally, the amount of lip and cheek support provided by the existing dentures should be noted as well as the occluding vertical relationship with the dentures in place (Fig. 6.9). Intraorally, the resorption of the residual alveolar ridges should be recorded using one of the established indices as described earlier in this book or simply as mild, moderate, or severe. The sulci should be examined for displaceability,



**Figure 6.8** Angular cheilitis. A condition associated with a local fungal infection but may also be an indicator of dentures providing poor lip support. The condition should be resolved prior to implant placement.



**Figure 6.9** Lip support of previous denture. A lack of adequate lip support from the maxillary denture results in the patient showing deep vertical folds in the upper lip, there also appears to be a reduced occlusal vertical dimension.



**Figure 6.10** Assessing fibrous replacement in the edentulous ridge. Despite the appearance of a large maxillary edentulous ridge, examination with a ball-ended burnisher reveals extensive fibrous replacement, with little underlying bone.

width, and depth. A ball-ended burnisher is useful for examination of displaceable tissue and fibrous replacement of ridges (Fig. 6.10). The vibrating line of the palate should be graded as being a broad area or sharply demarcated and the depth of the hamular notches should be noted. The position of the coronoid process should be noted as it sometimes occludes the pterygomaxillary fossa in lateral movements of the mandible. The mucosa should be examined carefully in particular reference to the availability of keratinized tissue around the potential implant site and any inflammation, ulceration, sinuses, retained roots, etc., noted. The quantity and quality of saliva should be assessed.

The existing dentures should be examined for basic details, such as

1. Retention and stability
2. Extension
3. Occlusal vertical dimension
4. Occlusal plane
5. Occlusion and articulation of the dentures
6. Shape and color of the denture teeth

7. Anterior and posterior tooth position
8. Contour and color of the denture base material

It is generally accepted that the occluding vertical relationship of conventional complete dentures must allow for sufficient freeway space and that the denture teeth should meet evenly when the patient closes in the retruded position.

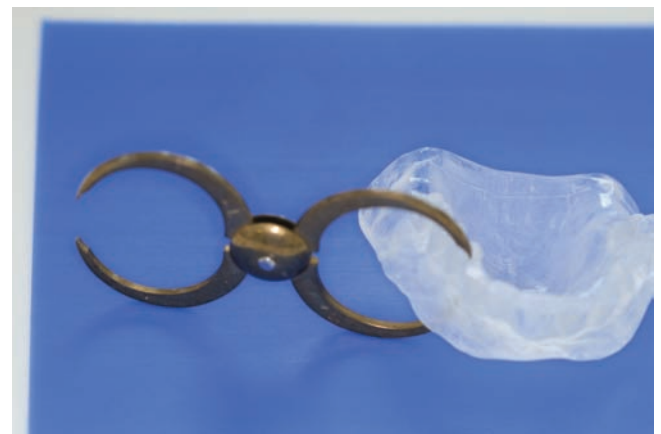Examination of the dentures out of the mouth will reveal whether or not there may be sufficient space for implant components within the denture base should implant treatment be considered, and give an approximate idea of where the implants should be placed. This is obviously easier, the better the technical quality of the dentures. If they have been made at the correct vertical relationship with a correct occlusal plane, then the thickness of the denture can be measured with a caliper. This is the maximum space available from which something must be subtracted to allow for denture teeth (Fig. 6.11).

Where existing dentures have too many technical errors to be useful in assessing proposed implant position, a trial setup (Fig. 6.12) will be needed as part of the special investigations. When grafting is planned, such a trial setup will indicate how much space is available for the graft when the space for the components and teeth is subtracted (Figs. 6.13 and 6.14).

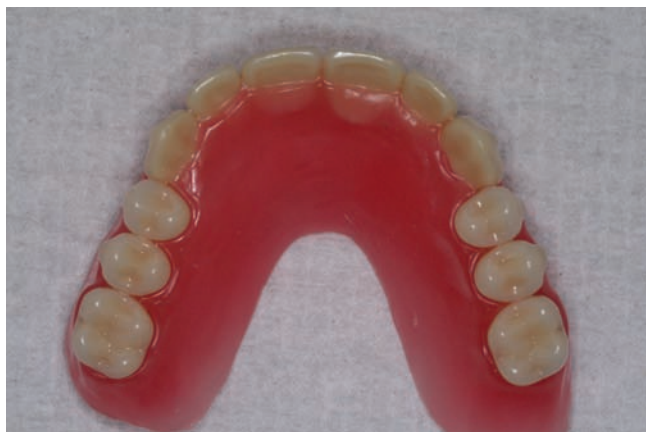By this stage, you have listened to your patient and examined the mouth and existing dentures, and it should be possible for you to arrive at a provisional diagnosis. This may include

1. moderate or severe alveolar ridge resorption;
2. unstable dentures;
3. incorrectly constructed dentures with one or more errors of base extension, tooth position, occlusion, etc.;
4. poor adaptation to dentures after loss of teeth;
5. pathological conditions such as retained roots, mucosal ulcers, hyperplasia, etc.

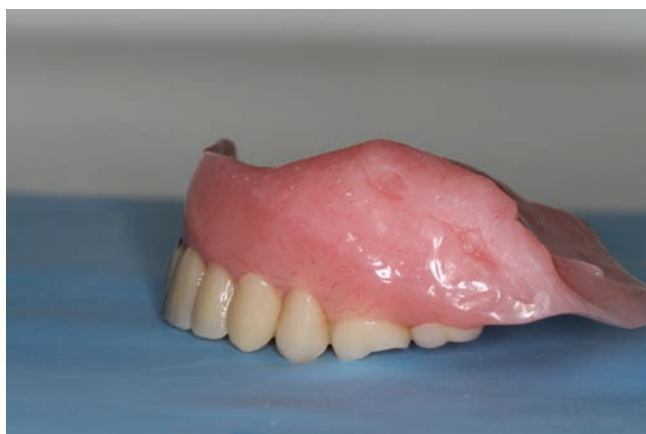Other special investigations may include radiographs to complete the diagnosis and referrals to other specialists for suspicious ulcers, etc. If the clinical situation comes under the indications mentioned earlier, you will certainly be thinking



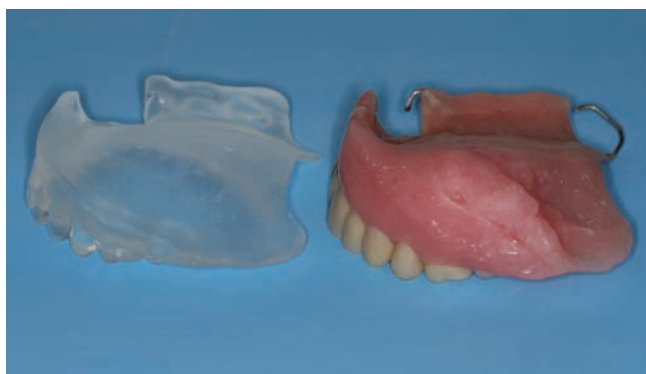**Figure 6.11** Maximum denture thickness. The thickness of a denture constructed at the correct occlusal vertical dimension can be measured with calipers. This is the maximum space that is available from which the space needed for the housing is subtracted to allow for the denture teeth.



**Figure 6.12** Trial setup. This can be used to assess not only tooth position, shade, and size but also soft tissue support. It is useful to perform this stage in patients requesting a substantial change in appearance.



**Figure 6.13** Trial setup for grafting. Denture constructed for a patient who underwent surgery in the maxilla, the thickness of the denture gives an idea of the volume of bone lost.



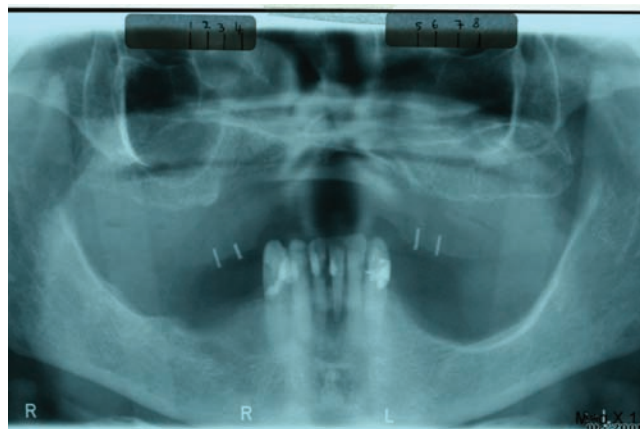
**Figure 6.14** Surgical guide for bone grafting. A clear acrylic stent had been duplicated and the fit surface reduced to give the surgeon an idea of tooth position and the volume of bone to be grafted.

of implant treatment, and a radiographic examination will be needed.

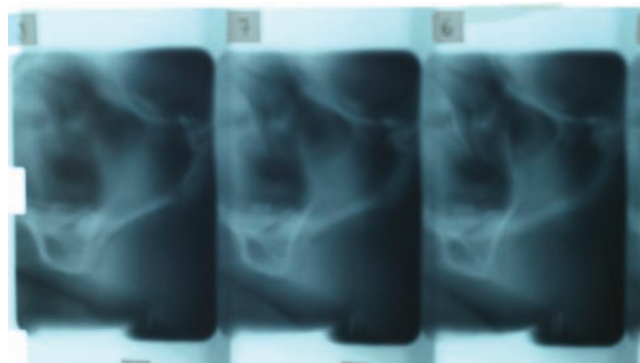
### RADIOGRAPHIC ASSESSMENT

The standard view is the dental panoramic tomograph (DPT) with some way of working out the magnification. Many DPT machines now produce films to a known magnification and the bone dimension can be measured directly using a ruler supplied by the manufacturer or a digital ruler on the computer screen. Alternatively, transparent overlays with printed images of different length implants to known magnifications can be used to select proposed implant size directly (Figs. 6.15 and 6.16). There is some horizontal distortion with all DPT machines.

A lateral skull view can be useful for the anterior maxilla and mandible. But to accurately assess the amount of bone in other areas, a sectional tomogram will be required. For example, a cone-beam CT scan can be used. A stent with radiographic markers is useful to match the scans with the clinical sites.



**Figure 6.15** A Scanora DPT. The radiograph is of a known magnification, the four radiopaque lines are markers made in the denture indicating implant positioning, the numbers at the top indicate where radiographic sections have been taken.



**Figure 6.16** Scanora sections based on the DPT in Figure 6.15 at position 6, 7, 8 indicating width and height of bone available.

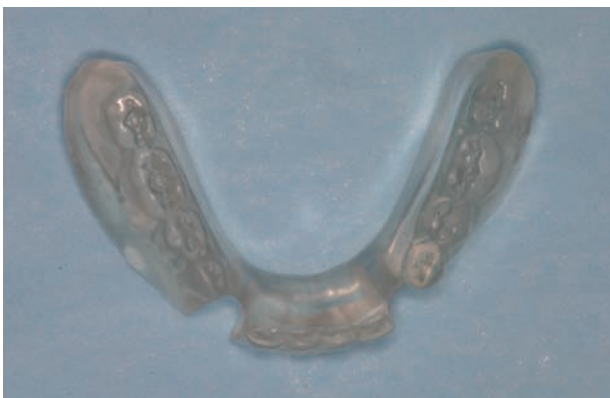For mandibular implant dentures, a DPT film will probably suffice since the implants need only to be placed in the canine region. This image will indicate whether there is sufficient ridge height, but it is less useful for assessing ridge thickness. Palpation or ridge mapping under local anesthesia are other ways of assessing ridge thickness.

The 3D sections either from CT scans or from tomograms while frequently needed in other areas of the jaw are rarely necessary in the edentulous mandible. These surveys will, however, indicate the quality and volume of bone available for implant placement. In our experience, grafting is very rarely indicated in the mandible but is sometimes needed in the maxilla when either the vertical height or width is insufficient.

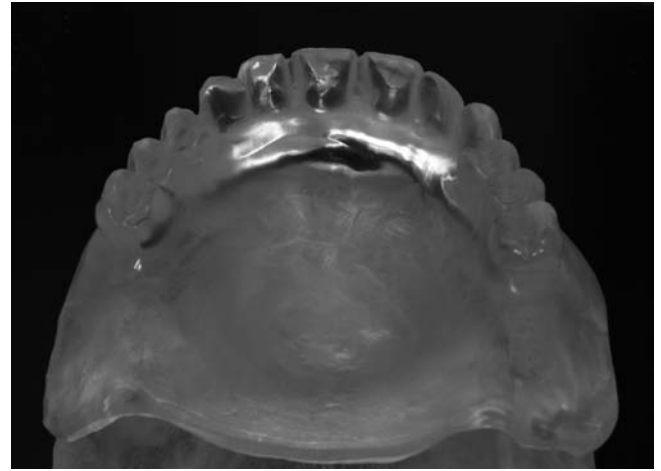
## DIAGNOSIS AND TREATMENT PLANNING

By this stage, sufficient information should be known to confirm the diagnosis and to decide what treatment is appropriate. If the patient's clinical situation comes under the indication categories mentioned above, you can decide whether implant treatment is indicated, whether there is sufficient bone of good quality, and whether there are any contraindications to the treatment. The outcome may be that new conventional dentures are indicated and that there is no real indication for implant treatment. There is, however, an argument that all edentulous patients would benefit from implants in the mandible to support the denture and to prevent further bone resorption. Certainly, if there were evidence of fairly rapid bone resorption even though the patient was not suffering any problem, it would be good clinical practice to inform the patient of the fact and suggest treatment. The effect of implant treatment in the mandible on a conventional maxillary complete denture must also be considered and it may be necessary to consider implants in both jaws. Fixed implant bridges may be indicated with or without grafting; these restorations are covered in the earlier chapters.

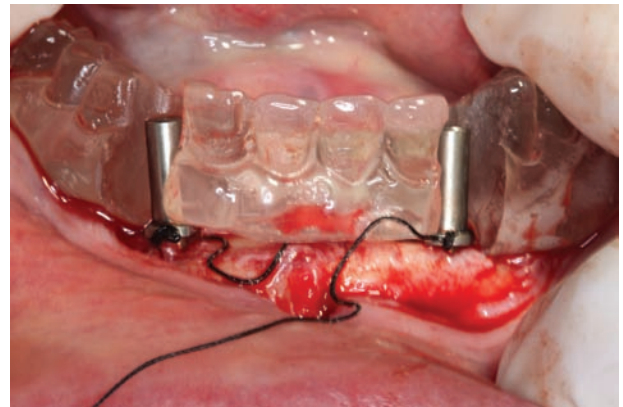
Once treatment has been decided, the next step is to plan the sequence of the stages. Unless the existing dentures are technically correct, a trial setup is essential to decide proposed tooth position (Fig. 6.12) and to confirm the amount of space for the components. Once tooth position is confirmed, a stent can be made from the trial denture (Fig. 6.17) or duplicate of the existing denture (Fig. 6.18). Guide holes are then cut in the stent to indicate proposed implant position and opened out



**Figure 6.17** Surgical stent. The access holes in the surgical stent prevent implants been placed in a too lingual position but does not prevent them being placed to far buccal.



**Figure 6.18** Duplicate denture. If the patient's denture is technically and aesthetically of a good quality, it should be duplicated to construct a radiographic stent, which subsequently can be used as a surgical guide.



**Figure 6.19** Surgical stent in place. The same guide as in Figure 6.17, with the implants in the same position as the guide holes.

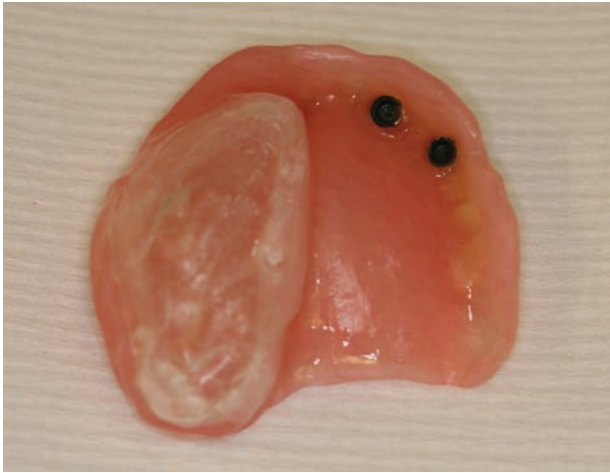buccally or lingually so that the guide pins used during implant placement can be directly observed (Fig. 6.19). In general, the proposed implant position should be that which allows the components to be sited in the thickest part of the denture resin and within the normal contour (Fig. 6.20).

## WHAT PROSTHODONTICS COMPONENTS ARE AVAILABLE?

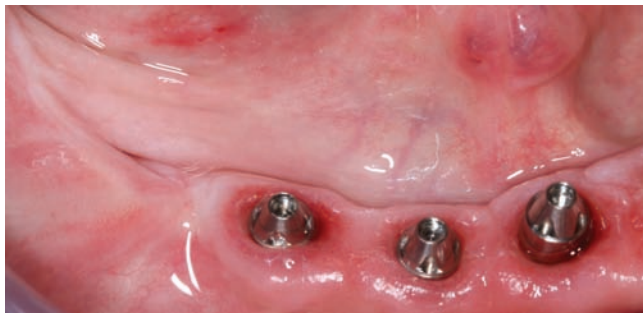All the major implant systems provide various cast and computer-designed bars, and various single attachment systems.

### Astra Tech (Sweden)

This manufacturer supplies a 1.9-mm-diameter round gold alloy bar, 50 mm in length, with small riders (clips) manufactured by Cendres & Metaux (Biel-Bienne, Switzerland). The bar is soldered to gold alloy cylinders, which are screwed to 20° or 45° uniAbutments ranging in gingival cuff height from 0 to 8.0 mm (Fig. 6.21). There is also the profile bar system where



**Figure 6.20** Denture implant components. Utilizing the surgical guide ensures the implants are positioned favorably and the denture components are in the thickest part of the denture.



**Figure 6.21** Astra Tech 20° uniAbutment. Made of commercially pure titanium, grade 4. This abutment can manage implants that have a 20° convergence or divergence.

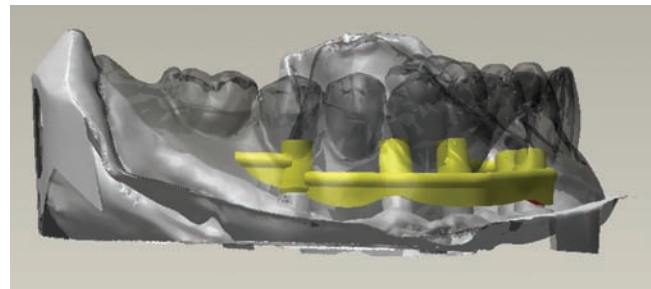
a customized cast bar is attached to 20° uniAbutments. A metal housing is cured into the denture and plastic inserts can be put inside the housing to activate the retention. Three inserts are available: reduced, normal, and increased.

Astra implants can be restored by a CAD/CAM titanium milled bar, which can be supported by 2 to 12 implants (Fig. 6.22). A 3D scanning program is used to design an optimal bar based on the patient's wax try-in (Fig. 6.23). The advantage of the titanium milled bar is its light weight property and the milling process ensures a precision fit with a lack of porosity.

There is a 2.25-mm-diameter ball attachment, in gingival cuff heights of 0 to 8.0 mm (Fig. 6.24). Retention can be achieved either with an adjustable four-tine gold alloy matrix (Fig. 6.25) that is processed into the acrylic resin of the denture or the Clix system (Fig. 6.26). This manufacture also supports the Locator® abutment; this is a titanium alloy abutment with a self-aligning design, which allows for a 40° angle implant correction (Fig. 6.27). The height of the abutment selected should be based on the highest levels of tissue measured with the depth gauge. This will allow the retention groove to be at the appropriate supragingival level (Fig. 6.28). Different levels of retention



**Figure 6.22** Milled bar. Custom made utilizing CAD/CAM technology made of titanium, aluminum, vanadium alloy; notice the lack of welding seams or visible porosities.

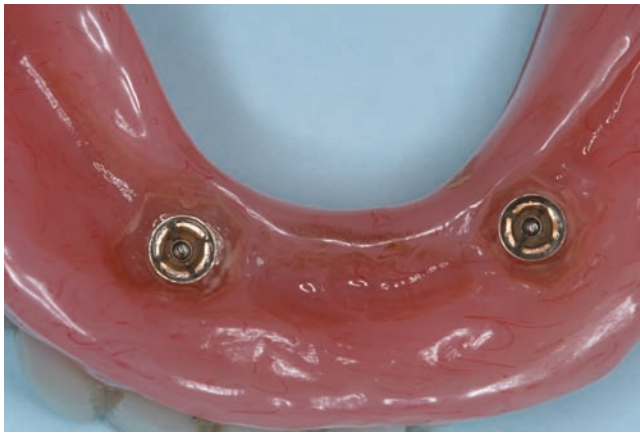

**Figure 6.23** 3D scan. The wax try-in is scanned and CAD software is used to design the bar within the confine of try-in and related to the position of the implants. The scan shows a Hader bar design.

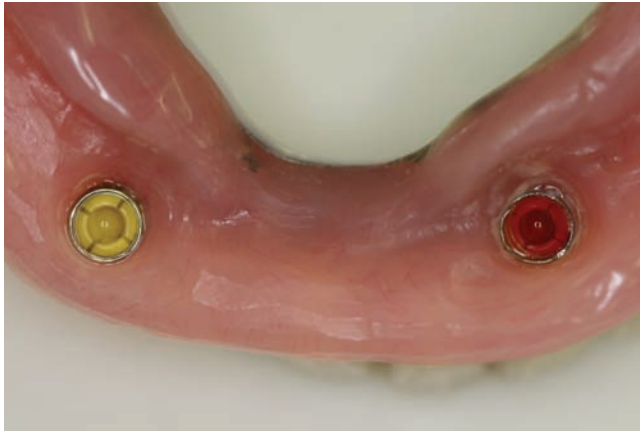

**Figure 6.24** Astra Tech ball attachment. The gingival cuff height of this abutment is 8 mm, which is the largest size available; there is an additional 2.85 mm, which is the height of the ball.

are available, depending on which nylon inserts are being used. Five inserts are available: blue (680 g), pink (1361 g), clear (2268 g), red (680 g), and green (1361–1814 g). The red and green are used when the implants are nonparallel (Figs. 6.29 and 6.30). The metal Locator processing cap is cured into the overdenture (Fig. 6.31).



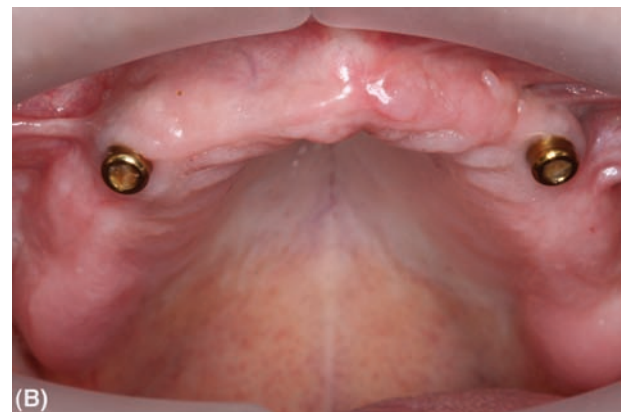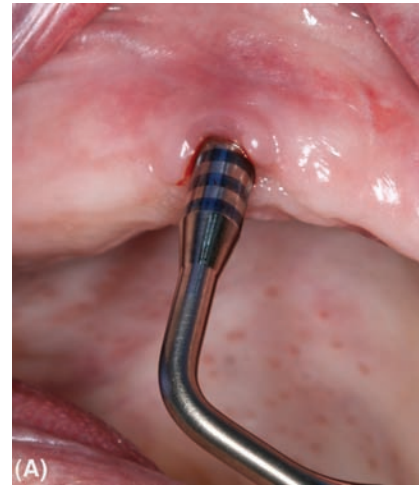
**Figure 6.25** Gold cap Astra. Four-tine gold alloy matrix.



**Figure 6.26** Clix system. Anodized titanium cap is processed into the denture, the plastic inserts are then clicked into place with the insertion tool. Yellow inserts have average retention and the red insert has greater retention; in this case the red insert needs replacing.



**Figure 6.27** Locator® abutment. Made of titanium alloy with a TiN-coating, it has a self-aligning design, making it easier for patients to position and correctly seat the overdentures into place.



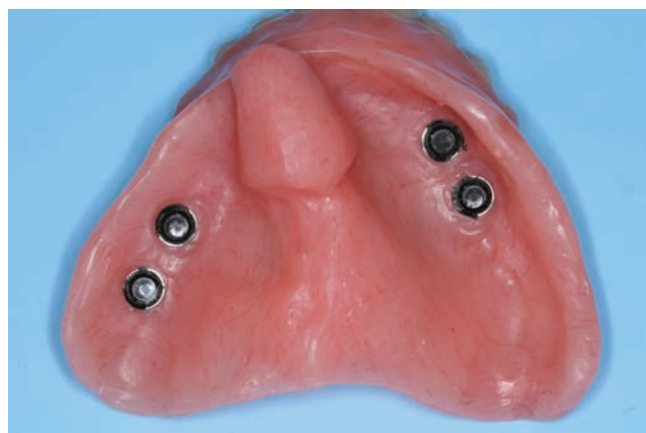
**Figure 6.28** (A) Depth gauge used to measure the gingival cuff height to ensure the retentive portion of the abutment is supra-gingival with the lowest profile achievable. (B) Locator® abutments in the maxilla with the retentive rim at the appropriate level.



**Figure 6.29** Standard nylon Locator® blue, pink, and clear inserts in increasing order of retention.



**Figure 6.30** Nonstandard nylon Locator® red and green inserts, used in cases in greater implant convergence or divergence.



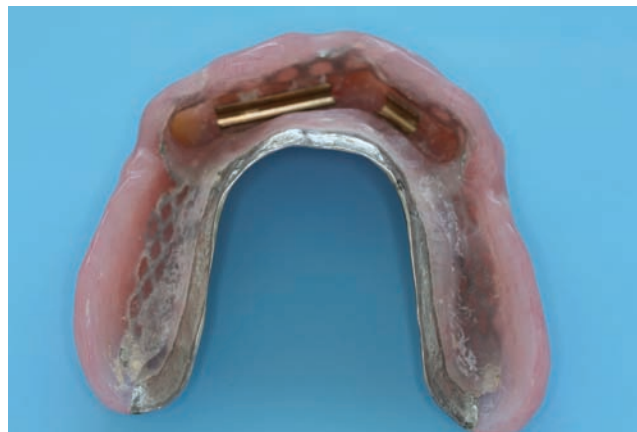**Figure 6.31** Locator® housing cap processed into a maxillary overdenture in a patient with an unrepaired cleft.

### Nobel Biocare® (Switzerland)

This manufacturer offers various bars and ball attachments for implant dentures. The original 2-mm-diameter round bar and small clip system has been expanded to include Dolder® macro and micro ovoid bars, and Dolder macro and micro U-shaped bars all with clips that can be cut to the required length (Fig. 6.32).

These preformed gold bars can be soldered to gold cylinders, 4.2 mm and 5.5 mm in height, which are screwed to multiunit abutments or fixture head. They are very useful, however, for rather superficially placed implants to obtain a low bar profile.

Nobel Biocare now also supports a CAD/CAM titanium milled bar. The bar can be designed to fit into the implants directly or onto multiunit abutments. There are a variety of attachments, Locator abutments, ball attachments, Hader bar, or Dolder bar, which can be incorporated into the bar design.



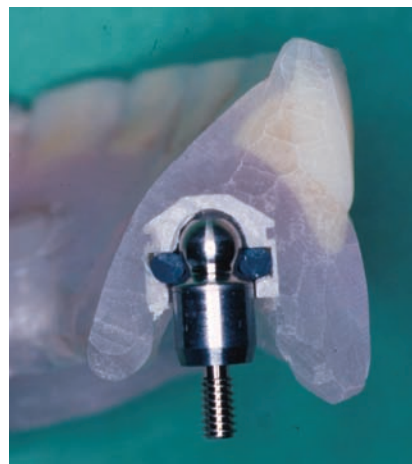**Figure 6.32** Dolder® bar clip processed into a maxillary overdenture with the palate cutout.

The original standard ball attachment consisted of a ball-headed titanium screw and a 3- to 5.5-mm sleeve similar to the standard abutment sleeve (Fig. 6.33). The matrix consisted of a plastic cap (with rubber O ring), 5.5 mm high and 7.2 mm diameter, which was processed into the denture. This abutment was replaced by a 2.25-mm ball attachment (Fig. 6.34) with an adjustable gold cap. The gold cap is 3.14 mm high. This gold cap is processed into the acrylic resin of the denture base. The 2.25-mm ball abutment is available in sizes of 1 to 5 mm for all implant platforms and can be used where there is a maximum implant divergence of up to 30°.

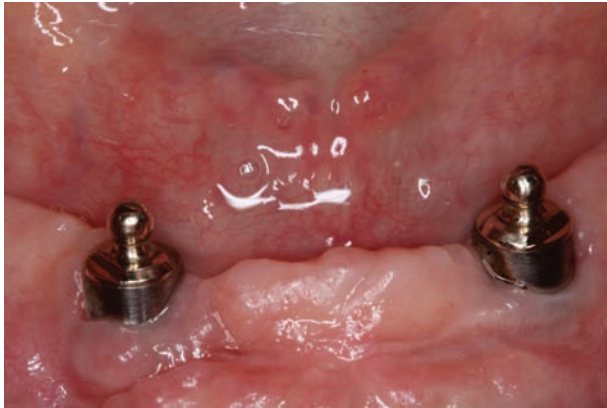The Locator abutment is also available to use with this implant system and available in heights of 0 to 6 mm.

### Straumann (Switzerland)


This manufacturer supplies mini and regular egg-shaped gold alloy Dolder bars and clips and U-shaped regular and mini



**Figure 6.33** Nobel Biocare large ball. The ball attachment is screwed into the implant and the sleeve fits around the external hex. The driver engages an internal hexagon on the top of the ball. The cross-section shows the fit of the ball within the attachment in the denture.



**Figure 6.34** Nobel Biocare 2.25-mm ball attachments in place. The ball attachment is screwed into the implant retaining sleeve around the external hex. The driver engages the flat surfaces on the collar of the ball attachment.



**Figure 6.35** A Straumann spring.

Dolder bars. The bar is soldered or laser welded to a gold alloy coping that is screwed to the SynOcta<sup>®</sup> abutment. Straumann also supply mini and regular titanium bars and clip for laser welding to titanium copings as well as plastic burnout patterns for casting titanium bars and copings. There is a 2.25-mm-diameter ball retentive anchor that screws directly into the implant. There are two types of retentive matrices that are cured into the overdenture. The titanium elliptical matrix with an adjustable four-tine gold alloy lamella and a Ti-alloy matrix with replaceable stainless steel spring (Fig. 6.35). The matrix requires a special screwdriver to activate or deactivate the retention.

### CHOOSING THE IMPLANT SYSTEM AND RETENTIVE DEVICE

There is much debate over the type of retention that should be used with implant overdentures. Whether the implant overdenture should be mostly implant supported, tissue supported, or both. Should the retention be resilient or rigid? How many implants are needed and do they have to be splinted with a bar? Are distal extensions necessary? In a recent review by Stoumpis and Kohal (2011), it was con-

cluded that there is no evidence to show a difference in implant survival between splinted and nonsplinted design and that the attachment mechanism did not affect patient satisfaction.

### Mandibular Overdentures

Among the large body of studies on mandibular overdentures, no evidence supports the superiority of one attachment over the other. In general, two to four implants placed between the mental foramina have been suggested with the denture being retained by clips onto a bar joining the implants, by ball attachments onto the individual implants, or by magnets. Bars have been round or ovoid to allow some rotation of the denture, but it has been shown that the bar configuration does not appear to be significant.

The results from medium and long-term studies, however, have shown that two implants placed in the canine region are sufficient to stabilize a mandibular denture. Moreover, two ball attachments have been shown to be as effective as a bar and clip system. The implants for ball attachments should be parallel for best results, although manufacturers state that divergences of up to 30° are correctable. The Locator abutment allows for a 40° correction. The major systems that we have used (Nobel Biocare, Astra Tech, Straumann) have all been shown to be effective in stabilizing mandibular dentures whether by bar and clip systems or by ball/Locator attachments. Since the latter have been shown to be as effective as bar and clip systems, they should be the first choice since they are simple to use, require less laboratory work, and produce no dead space for overgrowth of soft tissue.

We have no particular recommendations as to which implant system should be used in the mandible; all major systems appear equally effective. If there is sufficient space, the Locator abutment appears to be the simplest and the easiest to maintain. The implant should be placed so that the retention cap will be sited within the thickest part of the acrylic resin and within the normal contour of the denture (Fig. 6.31).

Where the implants are divergent, a bar/clip system can be used. The amount of space available must be sufficient for both the bar and the clip to lie within the contour of the denture (Fig. 6.32). The final decision as to the exact position of the bar should be made after the final setup of the implant denture teeth. It may be necessary to solder the bar lingual or buccal to the gold cylinders to enable the clip to be positioned within the contour of the denture or to avoid encroaching on the lingual sulcus. The original round bar worked well but the small clips sometimes fractured. The later ovoid bars, both micro and macro, come supplied with long clips that can be cut to size. Occasionally, these clips come out of the acrylic resin entirely. However, advantages of the CAD/CAM titanium milled bar has resulted in this being our bar system of choice.

### Maxillary Overdentures

Fewer studies are available for retention systems of the maxillary overdenture. Although the consensus appears to be that the minimum number of implants in the maxilla for an overdenture is four, there seems to be evidence that they do not necessarily have to be splinted with a bar. The retention device can be a clip or clips directly onto the bar or studs or other attachments can be soldered to the bar with matrices in the denture. Some studies show higher failure rates for implants in the maxilla, but they had too many variables to enable

comparisons to be made between various retention systems. One study followed 49 patients for up to 10 years comparing the Nobel Biocare round bar/clip system with the Nobel Biocare standard ball attachments and found no difference between the two retention systems (Bergendal and Engquist, 1998). What appeared to be more significant was the quality of the bone since the bulk of failures occurred in poor quality bone. It would seem sensible to place four or more implants in poor quality bone and splint them together. For the maxilla, it may be more important to select an implant system with recorded high success rates in poor quality bone.

For bar/clip systems, the implants need to be spaced so that there is room for clips between the implants. Most manufacturers have clips that can be adjusted for length. Clips can be placed on cantilevered bars but the added strain will lead to occasional solder joint failure and a higher rate of clip fracture or dislodgement. Whether distal extension fatigue in milled bars is a problem has yet to be evaluated.

### SINGLE-STAGE OR TWO-STAGE IMPLANTS

The surgical aspects of single-stage or two-stage implant placement have been covered earlier. There are no real advantages or disadvantages of either approach from a prosthodontic point of view. Certainly, the patient will get the finished implant denture in a slightly shorter time, but the existing denture may have to be highly modified in order for it to be worn safely while the implants are deemed to be integrating. If the denture can be modified with an appropriate soft material, it will probably be more stable over healing abutments after a single-stage procedure than over the edentulous ridge following the implant placement in a two-stage procedure.

### BIBLIOGRAPHY

- Allen PF, McMillan AS. A longitudinal study of quality of life outcomes in older adults requesting implant prostheses and complete removable dentures. *Clin Oral Implants Res* 2003; 14:173-179.
- Alsabeeha N, Atieh M, Payne AG. Loading protocols for mandibular implant overdentures: a systematic review with meta-analysis. *Clin Implant Dent Relat Res* 2010; 12(suppl 1):28-38.
- Bergendal T, Engquist B. Implant-supported overdentures: a longitudinal prospective study. *Int J Oral Maxillofac Implants* 1998; 13:253-262.
- Chan MFW-Y, Johnston C, Howell RA, et al. Prosthetic management of the atrophic mandible using endosseous implants and overdentures: a six year review. *Br Dent J* 1995; 179:329-337.
- Cooper LF, Scurria MS, Lang LA, et al. Treatment of edentulism using AstraTech implants and ball abutments to retain mandibular overdentures. *Int J Oral Maxillofac Implants* 1999; 14:646-653.
- Davis D, Packer M. Mandibular overdentures stabilised by AstraTech implants with either ball attachments or magnets. *Int J Prosthodont* 1999; 12:222-229.
- de Albuquerque Junior RF, Lund JP, Tang L, et al. Within-subject comparison of maxillary long-bar implant-retained prostheses with and without palatal coverage: patient-based outcomes. *Clin Oral Implants Res* 2000; 11:555-565.
- Ellis JS, Burawi G, Walls A, et al. Patient satisfaction with two designs of implant supported removable overdentures; ball attachment and magnets. *Clin Oral Implants Res* 2009; 20:1293-1298.
- Emami E, Heydecke G, Rompré PH, et al. Impact of implant support for mandibular dentures on satisfaction, oral, and general health-related quality of life: a meta-analysis of randomized-controlled trials. *Clin Oral Implants Res* 2009; 20:533-544.
- Fenlon MR, Sherriff M, Walter JD. An investigation of factors influencing patients' use of new complete dentures using structural equation modelling techniques. *Community Dent Oral Epidemiol* 2000; 28:133-140.
- Gotfredsen K, Holm B. Implant-supported mandibular overdentures retained with ball or bar attachments: a randomized prospective five-year study. *Int J Prosthodont* 2000; 13:125-130.
- Heydecke G, Boudrias P, Awad MA, et al. Within-subject comparisons of maxillary fixed and removable implant prostheses: patient satisfaction and choice of prosthesis. *Clin Oral Implants Res* 2003; 14:125-130.
- Jemt T, Chai J, Harnett J, et al. A five-year prospective multicentre follow-up report on overdentures supported by osseointegrated implants. *Int J Oral Maxillofac Implants* 1996; 11:291-298.
- Makkonen TA, Homberg S, Niemi L, et al. A five-year prospective clinical study of AstraTech dental implants supporting fixed bridges or overdentures in the edentulous mandible. *Clin Oral Implants Res* 1997; 8:469-475.
- Mericske-Stern R. Clinical evaluation of overdenture restorations supported by osseointegrated titanium implants: a retrospective study. *Int J Oral Maxillofac Implants* 1990; 5:375-383.
- Mericske-Stern R, Zarb GA. Overdentures: an alternative implant methodology for edentulous patients. *Int J Prosthodont* 1993; 6:203-208.
- Mericske-Stern RD, Taylor TD, Belser U. Management of the edentulous patient. *Clin Oral Implants Res* 2000; 11(suppl 1):108-125.
- Meijer HJ, Raghoobar GM, Batenburg RH, et al. Mandibular overdentures supported by two or four endosseous implants: a 10-year clinical trial. *Clin Oral Implants Res* 2009; 20:722-728.
- Naert I, Gizani S, Vuylsteke M, et al. A 5-year randomised clinical trial on the influence of splinted and unsplinted oral implants in mandibular overdenture therapy. Part 1: Peri-implant outcome. *Clin Oral Implants Res* 1998; 9:170-177.
- Palmqvist S, Sondell K, Swartz B. Implant supported maxillary overdentures: outcome in planned and emergency cases. *Int J Oral Maxillofac Implants* 1994; 9:184-190.
- Stoupis C, Kohal RJ. To splint or not to splint oral implants in the implant-supported overdenture therapy? A systematic literature review. 2011; Apr 11. doi: 10.1111/j.1365-2842.2011.02220.x; [Epub ahead of print].
- Vercruyssen M, Marcelis K, Coucke W, et al. Long-term, retrospective evaluation (implant and patient-centred outcome) of the two-implants-supported overdenture in the mandible. Part 1: survival rate. *Clin Oral Implants Res* 2010; 21:357-365.

## Basic factors in implant surgery

### INTRODUCTION

After planning, the surgical execution of implant placement is the next critical procedure in attaining successful osseointegrated implants. The most important factors to control in implant surgery are as follows:

1. A sterile technique avoiding contamination of the implant surface.
2. Avoiding damage to the bone by thermal injury during the drilling process.
3. Carefully preparing the bone site so that the implant is stable at placement.
4. Placing the implant in an aesthetically and functionally acceptable position.
5. Avoiding excessive loading in the healing period. Some protocols advocate no loading for three to six months. Newer protocols that allow immediate loading depend on very careful control of the magnitude of loading (see chap. 11).

Poor control of these factors can lead to failure of osseointegration, which may be manifested subsequently as

1. Infection at the implant site.
2. Implant mobility or the implant may be rotated when attempting to detach or attach a component.
3. Pain from inflammation in the bone surrounding the implant. This may be manifested as pain on pressure on the implant.
4. A radiolucent space surrounding the implant, which is consistent with fibrous encapsulation. However, a failed implant may have a normal radiographic appearance.

Under these circumstances the failed implant would have to be removed and treatment recommenced or an alternative sought.

### AVOIDANCE OF THERMAL INJURY TO THE BONE

Bone cells will be irreversibly damaged if the temperature is raised in the bone to 47°C for more than one minute. Bone cell death will result in more extensive resorption and failure of osseointegration. This is avoided by

- careful cooling of the bone and drills with copious sterile saline;
- use of sharp drills;
- control of the cutting speed;
- periodic withdrawal of the drill to allow bone cuttings to be cleared from the drill flutes.

Coolant is applied to the external surface of the drills or via the internal aspect in specially designed internal irrigation drills. The harder and more dense the bone, the more difficult it is to maintain adequate cooling. In situations where the bone is dense, the surgeon runs the risk of overheating the bone as the depth of

the drilling increases. This can be minimized by accepting shorter implant preparations or by improving the cooling efficiency of the bone preparation (e.g., more frequent withdrawal of the drill). The drills should be extremely efficient at cutting bone and the likelihood of burning the bone must be low if new disposable drills are used or reusable drills are replaced regularly. A record of the number of sites prepared (and the hardness of the bone) may be useful in determining when drills should be replaced.

In all systems, the implant site is prepared with small diameter drills in the first place and the site gradually made larger with increasing diameter drills (Figs. 7.1 and 7.2). In addition to minimizing heat production, the initial use of small diameter drills also allows modifications to the initial angle or site of preparation when required.

The cutting speed of the drills during the main preparation of the sites is approximately 1500 to 2000 rpm. The flutes of twist drills may be clogged up with bone debris, and therefore it is important to withdraw them from the preparation site at regular intervals during the preparation process to wash away the debris and cool the drill. If the site needs to be tapped, this is done at speeds comparable with those used to insert screw-threaded implants (approximately 20 rpm).

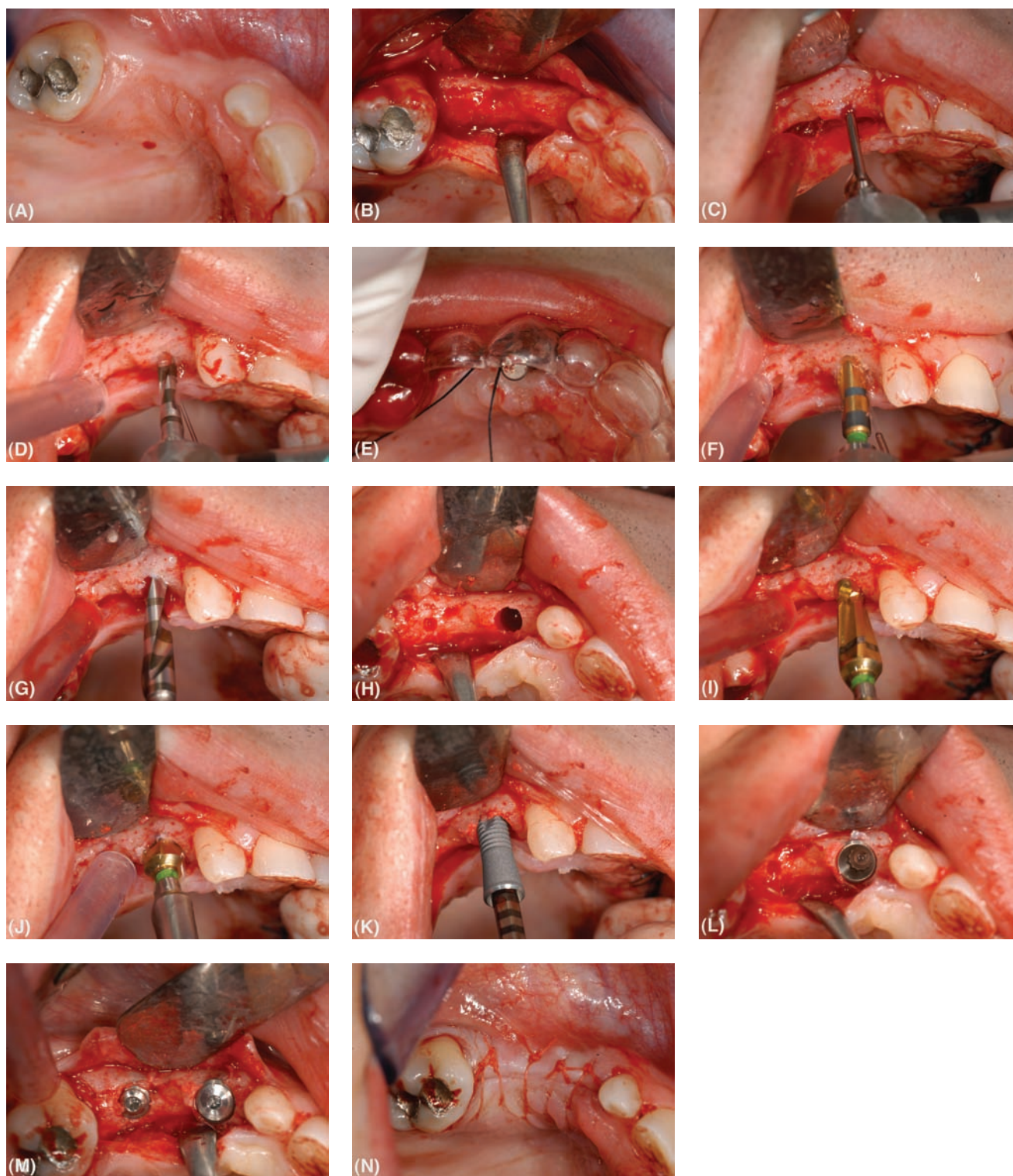
### ENSURING GOOD INITIAL STABILITY OF THE IMPLANT

The surgical preparation aims to provide an implant that feels stable following insertion. This can be judged by

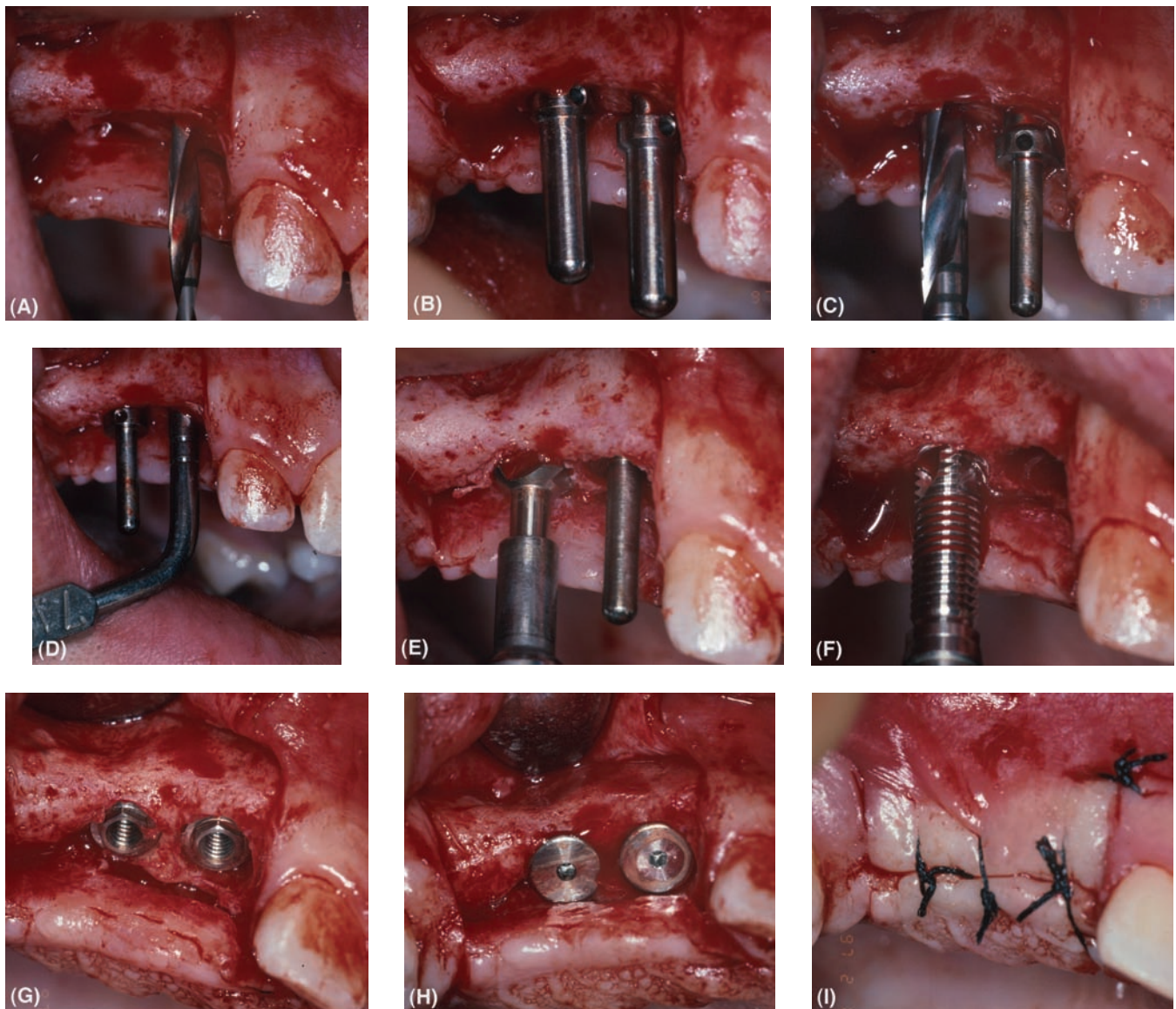
- simple clinical evaluation (dependent on operator experience);
- torque insertion forces—these can be set on the drilling unit and are usually between 10 and 50 Ncm. Some units record the torque and provide a print out;
- periotest values—the mobility can be measured with an electronic instrument that was originally designed to measure tooth mobility;
- resonance frequency analysis—this device measures the stiffness of the implant within the bone through electronic vibration and recording.

An implant that is loose within the prepared site is unlikely to osseointegrate. In the early phases of healing, the implant must not be subjected to forces that will cause movement of the implant, even if the movement is small. It has been suggested that micro-movement up to 100 µm may be compatible with healing by osseointegration, but beyond this, fibrous encapsulation is more likely to occur. It is not possible to offer comparative data between implants in this respect. However, various approaches can be adopted to ensure a stable implant with the different implant systems. Initial stability of the implant depends on the following:

1. Length of the implant
2. Diameter of the implant



**Figure 7.1** A series of photographs illustrated surgical preparation and placement of an implant using the Astra system in the upper right jaw. (A) The upper right jaw with missing canine and premolar teeth. The canine site is to be treated with routine implant placement and the premolar site using an osteotome sinus elevation. (B) A crestal incision and elevation of buccal and palatal flaps. (C) Initial site preparation at the upper right canine with a round bur. (D) Establishment of the angle and depth of the site using a 2-mm twist drill (the black bands mark the lengths of available implants). (E) The surgical stent/guide tried in place with an indicator post in the initially prepared site. (F) Increasing the diameter of the surgical site using a 3.2-mm pilot drill. (G) Full-depth preparation of the site with a twist drill of 3.2 mm diameter. (H) An occlusal view showing the 3.2-mm-diameter hole. (I) A conical drill is used in the coronal part of the site to accept the conical head of the implant. (J) Final preparation with the conical drill establishes the level of the head of the implant. (K) Insertion of the implant using slow revolutions on a handpiece adapter. (L) The implant fully seated. (M) A cover screw has been placed on the implant at the canine site and the insertion of another implant at the premolar site has been completed. (N) The wound is closed with vicryl sutures.

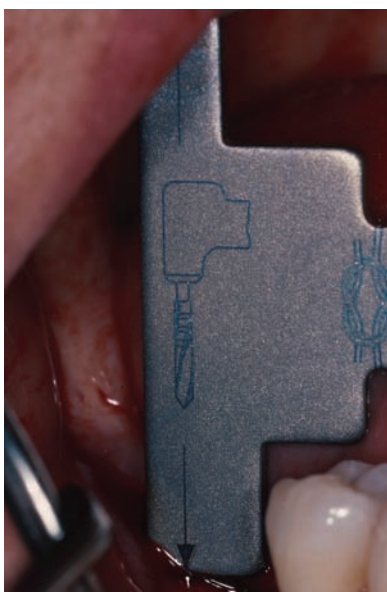


**Figure 7.2** A series of photographs illustrating surgical preparation and placement of two implants of the Branemark system. (A) Buccal and palatal flaps have been raised to reveal the bone ridge. The initial entry point of the site has been achieved with a round bur. A 2-mm twist drill is used to establish the angulation and depth of the site. (B) The position and angulation of the two implant sites is verified with direction indicators. These should be viewed from various angles and checked against the surgical stent and the opposing teeth (by asking the patient to close and gently touch the indicators—they should be directed to the buccal cusps of the lower teeth). The angles can be adjusted slightly at this stage. (C) Provided that the position and angulation are satisfactory, the sites can be enlarged by using pilot drills and twist drills. (D) Both sites have been drilled to 3 mm in diameter. A direction indicator is in the distal site and a measuring probe is being used to verify the depth of the anterior site. (E) The bone cortex is countersunk to accept the implant level with the bone crest. (F) The threaded implant is inserted using the slow revolutions of the handpiece. (G) Two implants are in place. They have at least 2 mm of intervening bone between the outer surfaces. The anterior tooth has about 2 mm of bone between it and the adjacent tooth. (H) Cover screws have been placed on the implant heads to protect the inner aspect of the implant during healing. They are level with the surrounding bone. (I) The flaps are closed with black silk sutures in this submerged protocol.

3. Design of the implant
4. Surface configuration of the implant
5. Thickness of the bone cortex and how many cortices the implant engages
6. Density of the medullary bone trabeculation
7. Dimensions of the preparation site compared with that of the implant

The philosophy of what constitutes adequate implant length varies between systems. The original Branemark concept was

that of bicortical stabilization. This required that an implant extended from the superficial cortex of the edentulous ridge to the inferior cortex of the anterior mandible or the nasal floor or floor of the antrum in the maxilla. This is clearly not possible in the posterior mandible because of the presence of the inferior dental canal, and in this situation shorter implants with unicortical fixation are used. Bicortical fixation is probably only advantageous in areas of poor bone quality in the medullary space. The Straumann system routinely uses shorter implants of



**Figure 7.3** The Straumann measuring device is used to check that there is adequate interarch space to accommodate the hand-piece and drill.

8 to 12 mm in length. This type of implant may be a good choice for bridgework in the posterior mandible and posterior maxilla where there may be little height of available bone.

There is one other important proviso about implant length, and that is to ensure that there is adequate vertical space when the patient opens mouth to permit insertion of the planned length of implant together with its insertion device (Fig. 7.3). The latter could include the handpiece head, hand-piece connector, and implant mount. Although many systems offer low profile versions of these components, the length of the implant may be the most critical feature. This is not usually a problem for the anterior region of the mouth but is very important in the molar regions.

Most systems produce implants in wider diameters to improve stability and strength (see chap. 4). The increased diameter provides an overall greater surface area and theoretically may provide the equivalent of bicortical stabilization by engaging both buccal and lingual cortices.

Alternative approaches to improve stabilization in areas of limited bone height and limited bone quality include the following:

- Tapered implant shapes
- Modifications to the thread design, for example, double thread
- More effective self-tapping end designs

The initial stability of an implant can be improved easily by inserting an implant into a site that is prepared smaller than the implant. This approach is used in the Astra system to good effect. Therefore, when using a 3.5-mm-diameter implant, the site is routinely prepared to a diameter of 3.2 mm (or 2.7 mm with the newer tapered apex design) and the implant self-tapped into position. If, however, the bone at the site is very dense, the surgeon is advised to prepare the site to a diameter of 3.35 mm. Similar recommendations are given with the standard 4-mm-diameter Astra implant with twist drills of 3.7 and 3.85 mm according to the available bone density.

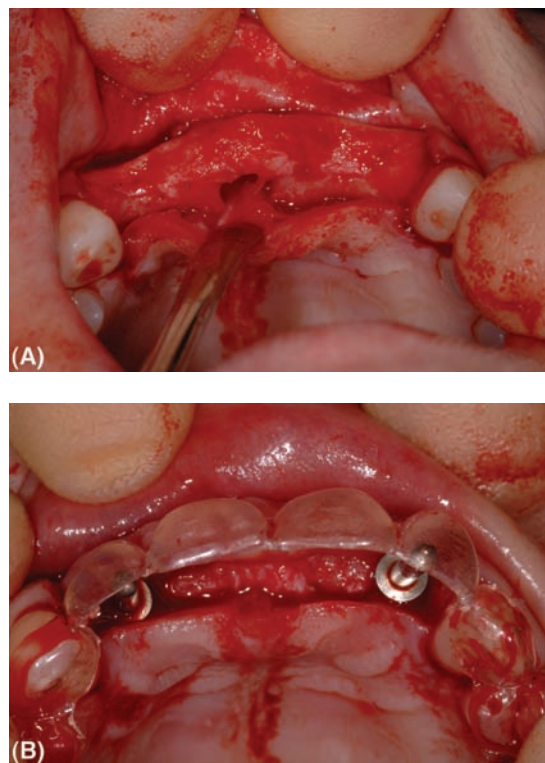
Implant surface roughness may do little to improve primary stability but may achieve higher bone-to-implant contact in the healing period compared to a machine surface, thereby developing a more rapid secondary stability.

### PLACEMENT OF THE IMPLANT IN AN ACCEPTABLE POSITION

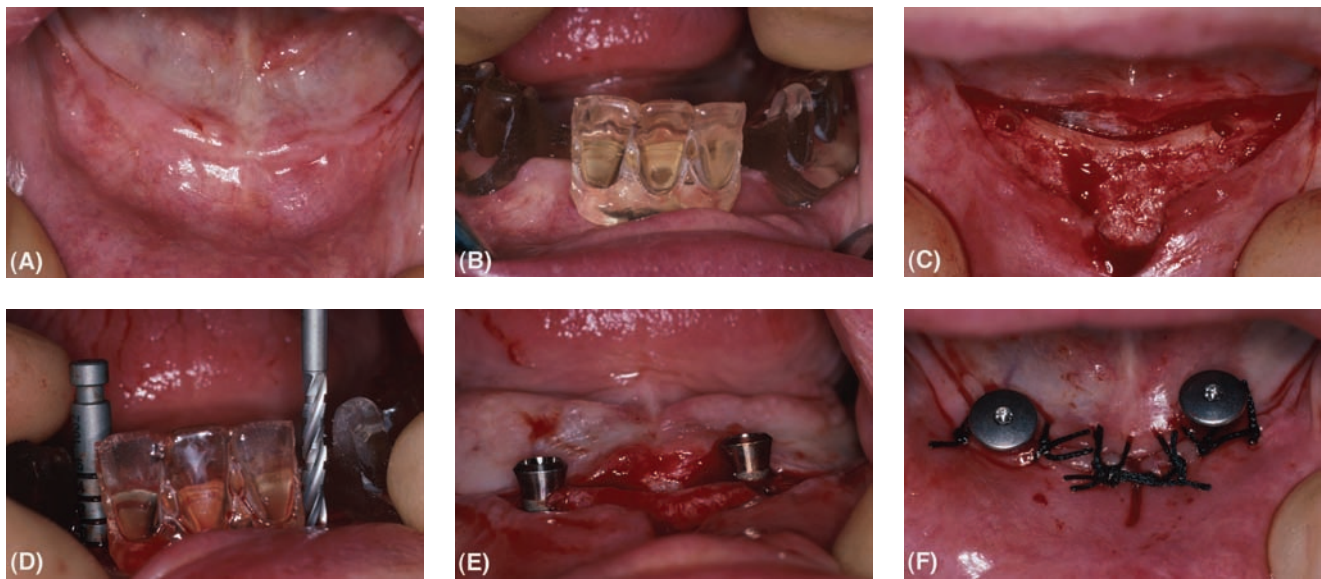
This is dealt with in considerable detail in the chapters on single teeth (chap. 9) and fixed bridges (chap. 10). Problems should be avoided by

1. careful planning;
2. using surgical stents;
3. reviewing each stage of the preparation process.

Surgical stents should be constructed using the diagnostic setups or provisional prosthesis. They should be rigid enough to prevent distortion and stable to minimize movement (Figs. 7.1E, 7.4, and 7.5B). Stents constructed in cold-cure acrylic or a rigid blowdown plastic using adjacent teeth for stability are ideal. The stent helps the surgeon with the mesiodistal positioning of the implant (avoiding placement in the embrasure spaces) and the buccolingual positioning and angulation. In replacing anterior teeth, it is particularly important to provide the profile of the buccal aspect of the prosthesis, including the cervical margin to give the planned emergence profile to optimize aesthetics. It is more difficult to provide a stable stent in an edentulous jaw. Under these circumstances, the stent needs to be extended on to stable



**Figure 7.4** (A) Flaps have been raised in the upper incisor region to reveal good ridge thickness but a moderately large incisive canal. (B) Sites for implants have been prepared in the lateral incisor regions. The surgical guide is in place showing the direction indicators angled toward the incisal tips for this cement-retained prosthesis.



**Figure 7.5** A series of photographs illustrating surgical preparation and placement of Straumann implants in a mandibular denture case. (A) The atrophic mandibular ridge with little keratinized mucosa. (B) A cold-cure acrylic stent has been constructed and tried in the mouth. The stent is a duplicate of the patient's denture, with slots cut in the regions of the planned implant placement (right and left canine). Initially trying in of the stent helps to plan the flap design and length of incisions. (C) A crestal incision has been made and midline relieving incision. The flaps have been raised to reveal the buccal bone contour and to release the soft tissue from the inner aspect of the mandible. The initial sites in the canine regions have been prepared with a round bur. (D) The stent in position with a depth gauge/indicator post in the patient's right side and a twist drill on the left side. The stent is removed to allow complete preparation of the site but is inserted at different stages to check on the position and alignment. (E) The implants have been placed with the polished collars just above the bone crest. (F) Closure screws have been attached to the implants and the flaps have been sutured.

mucosa (which is more readily accomplished using the palate), yet still allow access and retain stability once the mucoperiosteal flaps are raised. In completely edentulous jaw stents and long span edentulous spaces, it is important to construct stents in a material that is sufficiently rigid to retain its shape and not flexible so as to compromise implant positioning (Fig. 7.5).

The stages of placement can be reviewed using indicator posts in the prepared sites. These can be evaluated against the surgical stent (Fig. 7.4). It is recommended that the surgeon reviews the angles of the indicator posts from various aspects. Failure to do so can lead to surprising parallax errors.

The position of the indicator posts should also be reviewed in relationship to the opposing dentition. In the buccal segments in a patient with a normal buccopalatal relationship, the maxillary indicator should be directed toward the buccal cusps of the lower teeth and the mandibular indicators toward the palatal cusps of the maxillary teeth. This ensures that the implant is placed in the central fossa area of the tooth and forces are directed down the long axis.

The level of the head of the implant should be placed to allow adequate vertical space from the opposing dentition and to produce good aesthetics. These important issues are dealt with in detail in the following chapters.

### PREOPERATIVE CARE, ANESTHESIA, AND ANALGESIA

Basic preoperative care should include the following:

1. Antiseptic rinsing of the oral cavity. Chlorhexidine gluconate (2% or 1.2% proprietary rinses for 1 minute) is recommended.

2. Administration of analgesics. Oral analgesics (ibuprofen 200 mg or 400 mg or paracetamol 1 g) are usually sufficient in most outpatient cases. Control of pain is more effective if analgesics are given prior to surgery and the levels maintained to prevent development of pain.
3. Administration of antibiotics. This used to be a routine procedure and there is some evidence to suggest that preoperative antibiotics may reduce implant failure. However, placement of one or a few implants under ideal circumstances probably does not warrant antibiotics. Where antibiotics are indicated (e.g., multiple implants where bone is exposed for long periods or grafting is carried out), the clinician could use a standard protocol (e.g., amoxicillin 0.5 to 1 g preoperatively followed by a 5-day course).

Antibiotic and analgesic regimes will differ according to the status of the patient, the viewpoint of the clinician, and the country that the treatment is being carried out in. It is therefore beyond the remit of this book.

### Anesthesia

Many cases can be satisfactorily managed with local anesthesia, depending on the skill and experience of the surgeon and the attitude of the patient. The magnitude and duration of implant surgery is considerably increased with multiple implant placement, especially where more than one quadrant is involved. As a general indication, it is worthwhile considering sedation techniques in procedures likely to exceed one hour (e.g., the equivalent of the placement of three implants or more for the experienced operator). Prolonged difficult

procedures and those requiring extensive grafting may require general anesthesia.

Local anesthesia has advantages over general anesthesia. In particular, the conscious patient is able to cooperate by performing normal jaw movements in centric and lateral excursions to help verify appropriate implant positioning. The vasoconstrictor in the local anesthetic is useful in providing improved hemostasis and prolonged analgesia. Longer-acting local anesthetics may be useful in this type of surgery.

## BASIC FLAP DESIGN AND SOFT TISSUE HANDLING

Some surgical texts describe implant placement without flap elevation, but this can readily lead to lateral perforation of the bone in inexperienced hands. It is more suited to single implant placement directly into extraction sockets, and this is considered in chapter 11. Flap design (see chap. 8) and elevation should achieve complete exposure of the edentulous ridge, including any bony concavities and identification of important anatomical structures. The flap should also be easily closed with sutures under minimum tension with incision lines based on sound bone as in any good surgical practice.

Elevation of flaps is best accomplished using periosteal elevators with a fairly sharp edge especially where the bone ridge is uneven. Fibrous and muscle attachments, which tether the flap margins, may need to be released by sharp dissection. Flaps should be elevated to allow good visualization of the ridge form but not excessive in opening tissue spaces unnecessarily, for example, distal lingual aspect of the mandible. However, good reflection of the soft tissues on the lingual aspect of the lower incisors to premolars is advised because implant preparations in this area may inadvertently perforate the lingual plate in a natural concavity and damage a branch of the sublingual artery. This can result in extensive bleeding in the unreflected tissue, which is not noticed by the surgeon, and results in a deep-seated sublingual hematoma. This may present sometime within the next 24 hours and has been reported to threaten the patient's airway.

Before closure of the flaps, it is important to check that there is no residual bone debris or clot beneath the flaps by careful irrigation with sterile saline and inspection with suction. The flaps are carefully closed with sutures of the surgeon's choice, either nonresorbable or resorbable. Simple interrupted 40 black silk or vicryl sutures are satisfactory. Vertical mattress sutures are recommended by some operators where a more secure seal is required, for example, over a grafted site. Finer 60 or 70 polypropylene sutures as used in plastic surgery are recommended by others, in which case a larger number are required and fine suturing instruments are mandatory. However, the most important factor is to ensure that the wound closure is free of tension. In difficult cases requiring flap advancement, periosteal releasing incisions, vertical relieving incisions, and stabilizing sutures remote from the wound edges can be helpful. Firm pressure with moist packs should be applied to readapt the flaps and control bleeding.

## BASIC POSTOPERATIVE CARE

Patients should be prescribed appropriate analgesics, antibiotics if indicated, and a chlorhexidine mouthrinse. They should be advised to use ice packs to reduce swelling and bruising, which do not usually occur with simple cases. Post-operative pain should not be severe. Pain should not arise from the bone because this would indicate poor technique and damage possibly leading to failure. Surgery close to the inferior dental nerve may result in transient altered sensation and the patient should be made aware of this possibility.

In many cases patients are advised not to wear their removable dentures for one to two weeks to avoid pressure on the wound and implants. This requirement is probably still valid with implant surgery in the edentulous mandible. It is acceptable for the patient to wear a removable denture after surgery with placement of a small number of implants, where swelling is less likely and there is good wound and denture stability. However, the denture normally needs to be relieved and sometimes a soft lining added. The patient should be seen one week later for suture removal and further adjustment to their denture if required. Patients who are provided with a fixed provisional prosthesis have an advantage in this respect, but may need adjustment to the under-surface of pontics to accommodate healing abutments and soft tissue changes.

## BIBLIOGRAPHY

- Benington IC, Biagioni PA, Briggs J, et al. Thermal changes observed at implant sites during internal and external irrigation. *Clin Oral Implants Res* 2002; 13:293-297.
- Bruggenkate CM, Krekeler G, Kraaijenhagen HA, et al. Haemorrhage of the floor of the mouth resulting from lingual perforation during implant placement: a clinical report. *Int J Oral Maxillofac Implants* 1993; 8:329-334.
- Buser D, von Arx T. Surgical procedures in partially edentulous patients with ITI implants. *Clin Oral Implants Res* 2000; 11(suppl 1):83-100.
- Eriksson RA, Adell R. Temperatures during drilling for the placement of implants using the osseointegration technique. *J Oral Maxillofac Surg* 1986; 44:4-7.
- Eriksson RA, Albrektsson T. The effect of heat on bone regeneration: an experimental study in the rabbit using the bone growth chamber. *J Oral Maxillofac Surg* 1984; 42:705-711.
- Ivanoff CJ, Sennerby L, Lekholm U. Influence of initial implant mobility on the integration of titanium implants: an experimental study in rabbits. *Clin Oral Implants Res* 1996; 7:120-127.
- Jaffin R, Berman C. The excessive loss of Brånemark fixtures in type IV bone. *J Periodontol* 1991; 62:2-4.
- Kuzmanovic DV, Payne AG, Kieser JA, et al. Anterior loop of the mental nerve: a morphological and radiographic study. *Clin Oral Implants Res* 2003; 14:464-471.
- Meredith N. Assessment of implant stability as a prognostic determinant. *Int J Prosthodont* 1998; 11:491-501.
- Meredith N, Book K, Friberg B, et al. Resonance frequency measurements of implant stability in vivo. A cross-sectional and longitudinal study of resonance frequency measurements on implants in the edentulous and partially dentate maxilla. *Clin Oral Implants Res* 1997; 8:226-233.

## Flap design for implant surgery

### INTRODUCTION

This chapter deals primarily with flap design for partially dentate cases, describing most examples in the aesthetic zone for single implant placement. The same principles are applicable to larger edentulous spaces. The last section briefly describes some aspects of flap design in the edentulous jaw.

### FLAP DESIGN IN THE AESTHETIC ZONE

Some surgical texts describe implant placement without flap elevation, but this can readily lead to lateral perforation of the bone in inexperienced hands. It is more suited to single implant placement directly into extraction sockets, which is considered in chapter 11. Flap design and elevation should achieve adequate exposure of the ridge, including any bony concavities and identification of important anatomical structures. The flap should also be easily closed with sutures under minimum tension with incision lines based on sound bone as in any good surgical practice.

A midcrestal incision can be employed in most cases. The incision can be extended within the gingival crevice of adjacent teeth (Fig. 8.1) and the mucoperiosteum can be elevated quite extensively in an apical direction to allow adequate visualization of the bone contour.

However, in many cases, we advocate the use of relieving incisions to aid flap reflection and exposure (Fig. 8.2). Relieving incisions next to teeth require particular attention. The incisions can be kept vertical and parallel overlying sound bone so that on closure the flaps revascularization is not compromised. The apical extent can be flared if desired to improve visualization of the apical bone contour. It is important to avoid placing obliquely inclined relieving incisions over prominent root surfaces, as the wound can break down if there are underlying bone dehiscences and this can result in gingival recession (Fig. 8.3).

On placing relieving incisions or reflecting the flaps care should be taken to protect important anatomical structures such as the mental nerve. Elevation of flaps over the incisive canal region has minimal consequences in terms of resulting paresthesia, and bleeding is seldom a problem (Fig. 8.4). Short relieving incisions into the palate can also be helpful and do not need to be extended far enough to cut any major vessels.

Where there is little keratinized tissue it is sometimes useful to locate the crestal incision toward the palatal aspect in the maxillary arch, which has considerably more keratinized tissue as it extends on to the palate (Fig. 8.5). This design is also a useful strategy in cases where bone augmentation procedures may be required on the labial aspect, to ensure adequate wound closure remote from any implant surfaces, graft materials, or guided bone regeneration (GBR) membranes. However, in these latter cases it is probably prudent to place relieving incisions at least one tooth width lateral to the area of augmentation treatment (Fig. 8.6).

The main controversy in flap design for single tooth implants is whether to involve and reflect the adjacent papillae or not. Avoidance of papilla reflection aims to preserve the aesthetics of these structures, which are difficult or impossible to reconstruct if lost (Fig. 8.7).

However, in many cases the single tooth space is narrow mesiodistally and elevation of the papillae may be unavoidable (Fig. 8.8). If one can only preserve a narrow strip of soft tissue on the proximal surfaces of the adjacent teeth, it may have its blood supply compromised to such an extent that full reflection of the tissue would be no more damaging. The present authors have routinely elevated papilla as in the flap design shown in Figures 8.1 and 8.5 with no detriment to the soft tissue profile subsequently. We would therefore recommend the following:

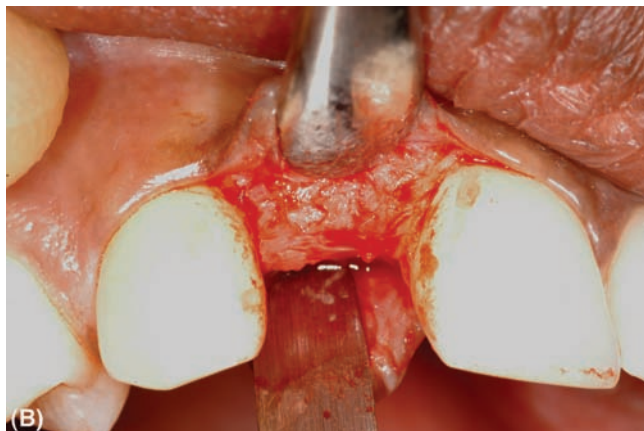
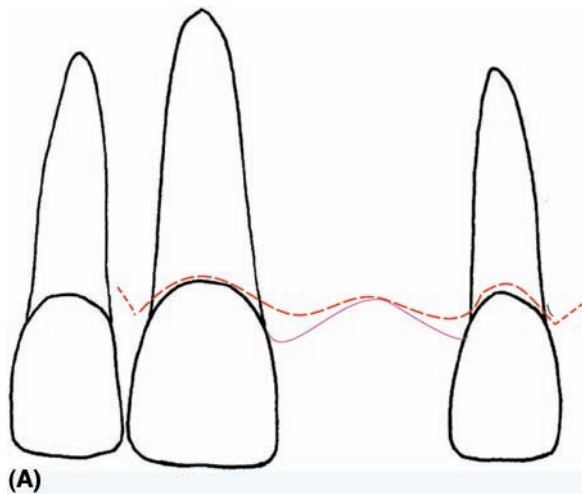
1. In sites that are less than or equal to 7 mm mesiodistally, to reflect the papillae.
2. In sites that are 8 mm or greater, a mesiodistal crestal incision of 5 to 6 mm and relieving incisions will allow nonreflection of an adequate width of papillary tissue to recommend the technique.
3. If doubt exists as to the need to expose anatomical structures such as the incisive nerve or if augmentation techniques may be indicated, then the wider flap design incorporating papillae is again recommended.

The incisions described above are simple incisions through epithelium, connective tissue, and periosteum down to bone. More sophisticated incision lines can be used where the tissue is thick in order to produce overlapping flap margins rather than a simple butt joint (Fig. 8.9). This requires incision through the epithelium at one point, horizontal extension of the incision in the midzone of the connective tissue, followed by a vertical incision down through periosteum. The resulting halving joint may provide more secure coverage in areas where bone augmentation is planned.

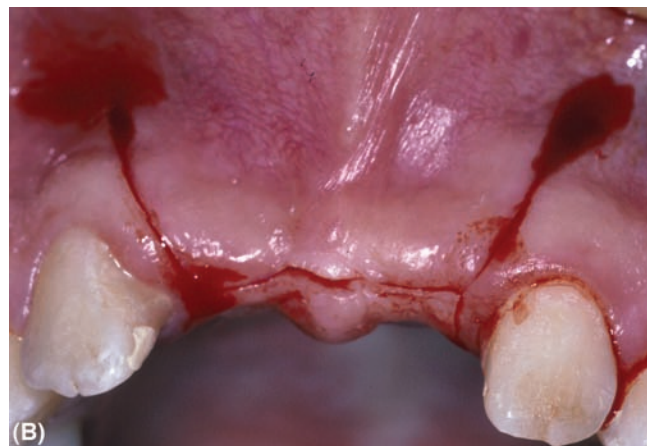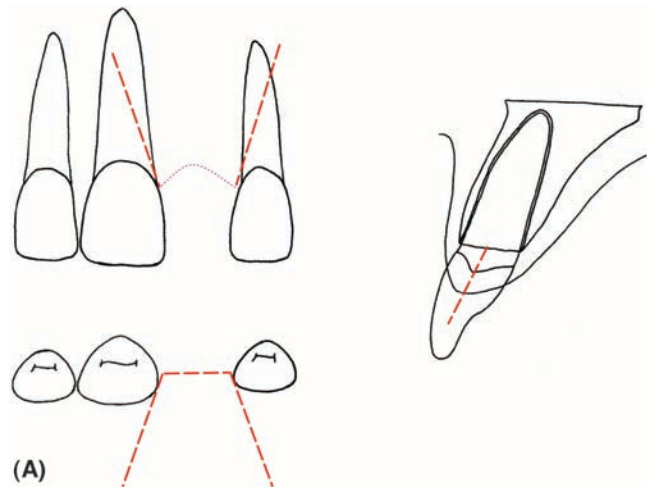
### ADDITIONAL CONSIDERATIONS IN EDENTULOUS JAWS

As described in the previous section, a midcrestal incision can be employed in most cases. Where there is little keratinized tissue, for example, in the case of the resorbed edentulous mandible, it is recommended that the incision is made in the middle of this tissue to retain some keratinized mucosa on each side of the wound. The maxillary arch has considerably more keratinized tissue as it extends on to the palate, and it is sometimes useful to locate the crestal incision toward the palatal aspect. This strategy can be used to relocate more keratinized tissue on the buccal surface of the nonsubmerged implant (or the same at abutment connection surgery).

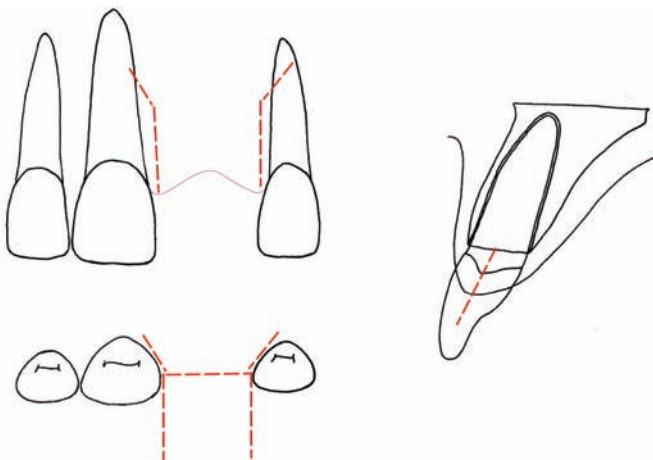
In the edentulous maxilla or mandible, a midline labial relieving incision extending into the sulcus enables the



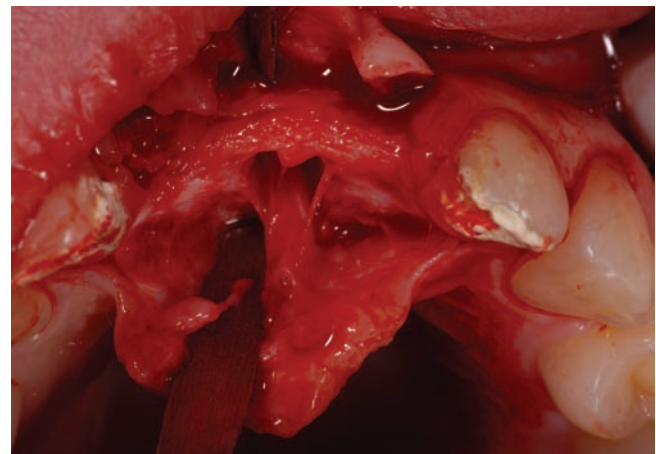
**Figure 8.1** (A) An incision on the crest of the edentulous space is extended in the gingival crevices of the adjacent teeth to allow adequate exposure of the ridge. (B) A crestal incision extended into crevices of adjacent teeth to provide adequate access to the bone ridge.



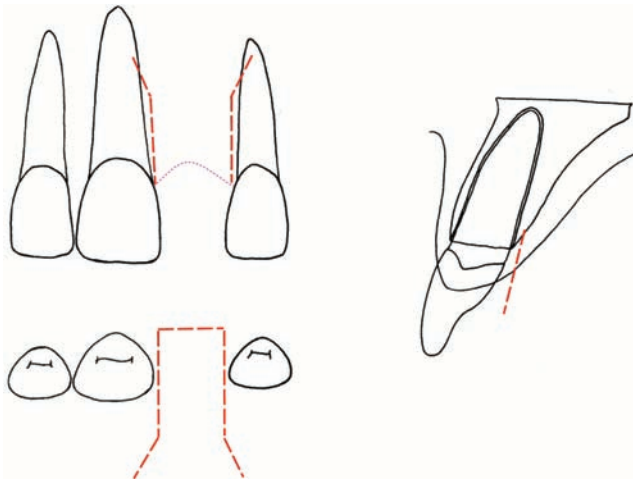
**Figure 8.3** (A) It is advised to avoid placing oblique relieving incisions over prominent root surfaces as recession may result if there is an underlying bone dehiscence. A broad base to the flap is not necessary for flap survival as the blood supply and nutrient bed for mucosal flaps are excellent. (B) A midcrestal incision leaving papillae in situ. The oblique relieving incisions do not pass over the adjacent root surfaces.



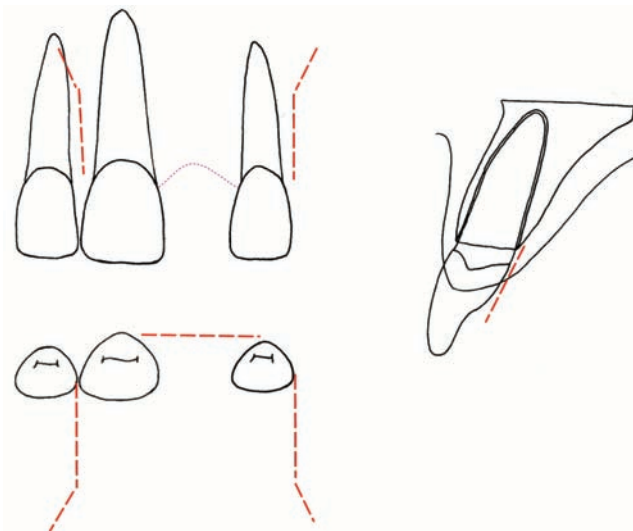
**Figure 8.2** A normal incisor space with a midcrestal incision, vertical relieving incisions on sound bone that are flared at their apical extent. The relieving incisions extend a short distance into the palatal mucosa to allow adequate elevation.



**Figure 8.4** Elevation of a palatal flap with the incisive canal contents under tension.



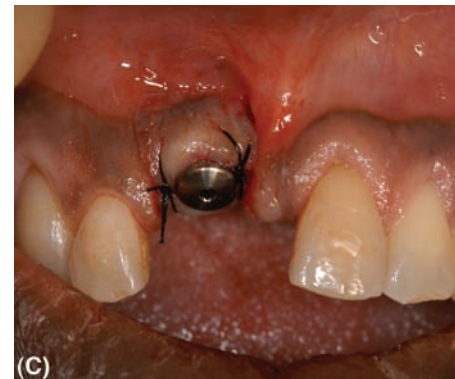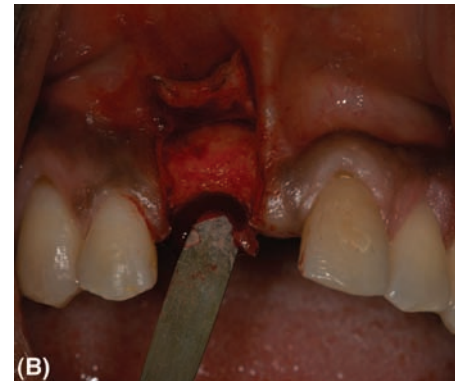
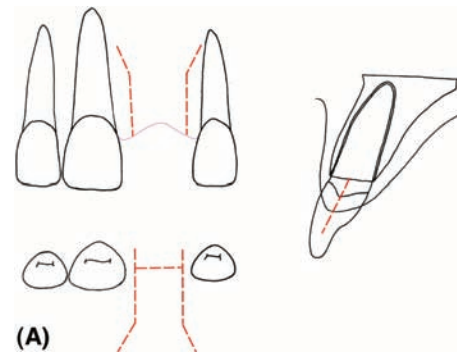
**Figure 8.5** The crestal incision has been made on the palatal aspect of the ridge. Reflection of the flap may be slightly more difficult and the wound margins are more remote from the implant head. This was once considered to be important in submerged implant surgery.



**Figure 8.6** If augmentation procedures are thought to be required, it is prudent to base incision lines more remotely to avoid exposure of grafted materials. The incisions have therefore been made one tooth laterally on each side and the crestal incision toward the palatal side.

surgeon to elevate under the periosteum more easily, especially where the crest of the ridge is knife-edged or uneven. The relieving incision also reduces tension on the buccal flap making retraction much easier (Fig. 8.10).

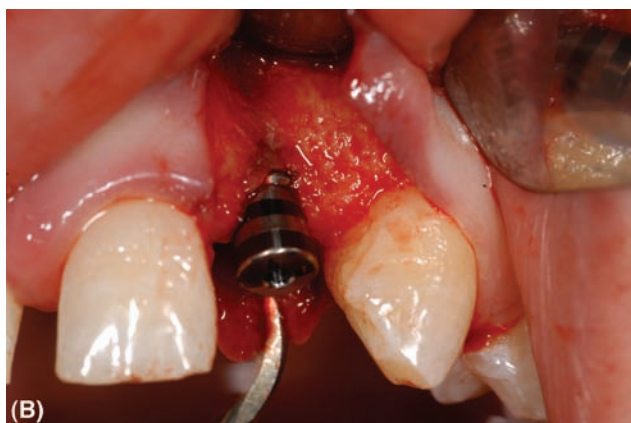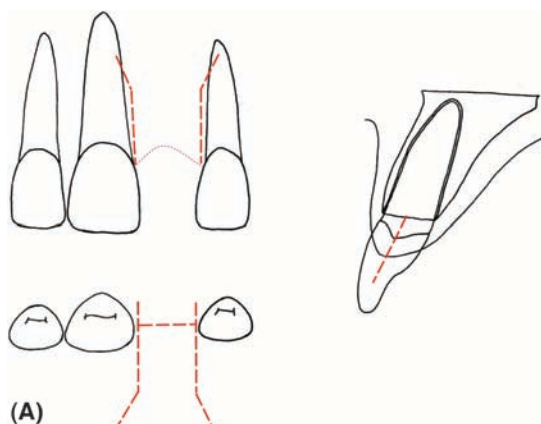
When providing just two implants in the lower jaw to support an overdenture, it is often possible to achieve this using two small flaps on either side of the jaw (Fig. 8.11) rather than a single but larger flap extending across the midline.



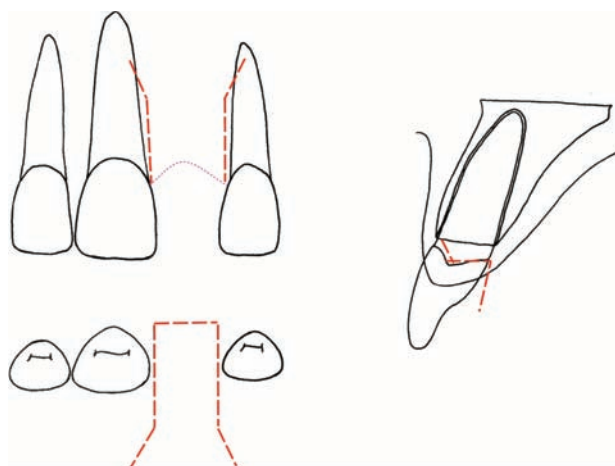
**Figure 8.7** (A) The wide central incisor space allows an adequate width flap to be developed in the middle of the space, while allowing preservation of the papillae. (B) A clinical example showing preservation of the papillae on the adjacent teeth in this wide central incisor space. The flap design and reflection has provided good visualization of the bone during implant insertion. (C) The same case with the flap nicely approximated around the healing abutment with two sutures. Relieving incisions may require suturing if they tend to gape.

## FLAP DESIGN IN ABUTMENT CONNECTION SURGERY

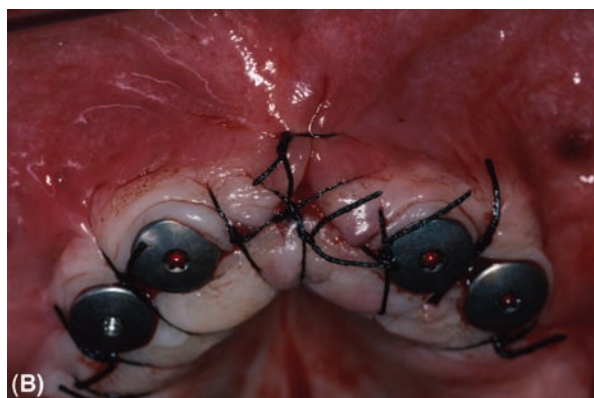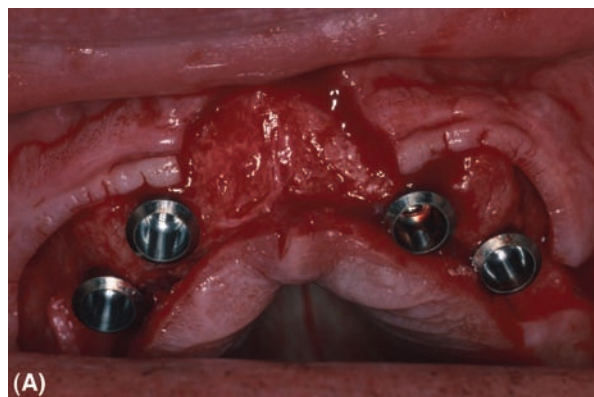
Flap design for abutment connection surgery is important as it gives the surgeon a chance to modify the soft tissue profiles. Many of the points raised also apply to handling of the flaps in single-stage nonsubmerged implant surgery. In general, incisions are made directly over the implant heads unless the surgeon wishes to preferentially relocate some of



**Figure 8.8** (A) The narrower incisor space (as is often the case with lateral incisors) does not allow an adequate width of flap and avoidance of disturbing the proximal papillae, which are routinely raised in this flap design. This example uses a mesial and distal relieving incision. (B) All the soft tissue in the space has been elevated using a labial relieving incision at the distal line angle of the central incisor and a crevicular extension at the canine.

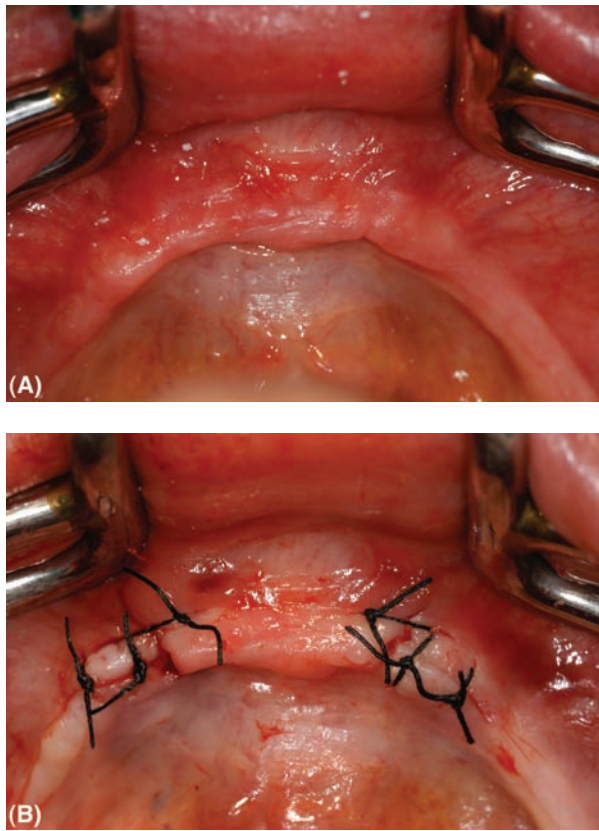


**Figure 8.9** Where the ridge soft tissue is thick, a split thickness incision can be employed, which produces a "halving joint." This is designed to minimize the chance of breakdown of the incision but can only be made in thick tissue where this problem is less likely to occur anyway.

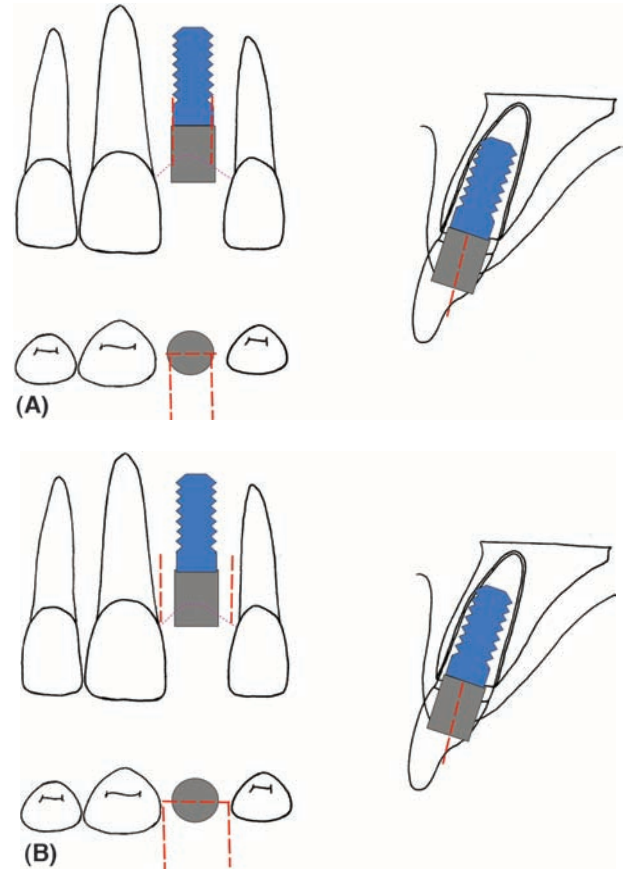


**Figure 8.10** (A) Flap design in the edentulous maxilla being treated with nonsubmerged Straumann implants. The crestal incision has been made toward the palatal aspect of the planned placement site. This allows retention of more keratinized tissue on the buccal aspects of the implants. A midline relieving incision helps flap reflection and lengthens the flap margin to improve adaptation around the implant collars. (B) The flaps sutured with simple re-adaptation and no resection of tissue.

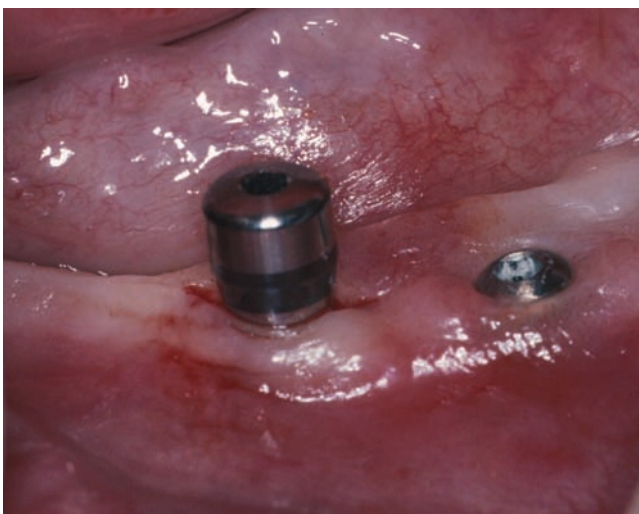
the available keratinized tissue more on one aspect than the other. In severely resorbed jaws with minimal keratinized tissue it is important to preserve it all, and in some cases soft tissue grafting may be required (see chap. 12). Small crestal incisions over the implant head and minimal soft tissue reflection to allow abutment connection are easier with systems that have an internal abutment/implant connection such as Astra (Fig. 8.12). In systems where abutment seating is more difficult we would generally advocate more extensive exposure of the implant head to facilitate abutment connection, and to allow visual checking of the fit. This should eliminate the need for radiographic verification of component seating. Full flap reflection is also needed if bone has grown over the implant head and this has to be removed with small hand chisels (our preference), burs, or purpose designed mills, taking care not to damage the implant. More flap reflection is required if bone removal is needed, including use of relieving incisions. It is important to have relieving incisions remote from the edges of the transmucosal abutment (or collar of a nonsubmerged implant) where the wound may break down at these points because the flap margins are not based on sound tissue (Fig. 8.13).



**Figure 8.11** An edentulous mandible treated for two implant supported overdenture. (A) The atrophic jaw with little keratinized tissue. (B) Two small flaps in the canine regions following suturing.



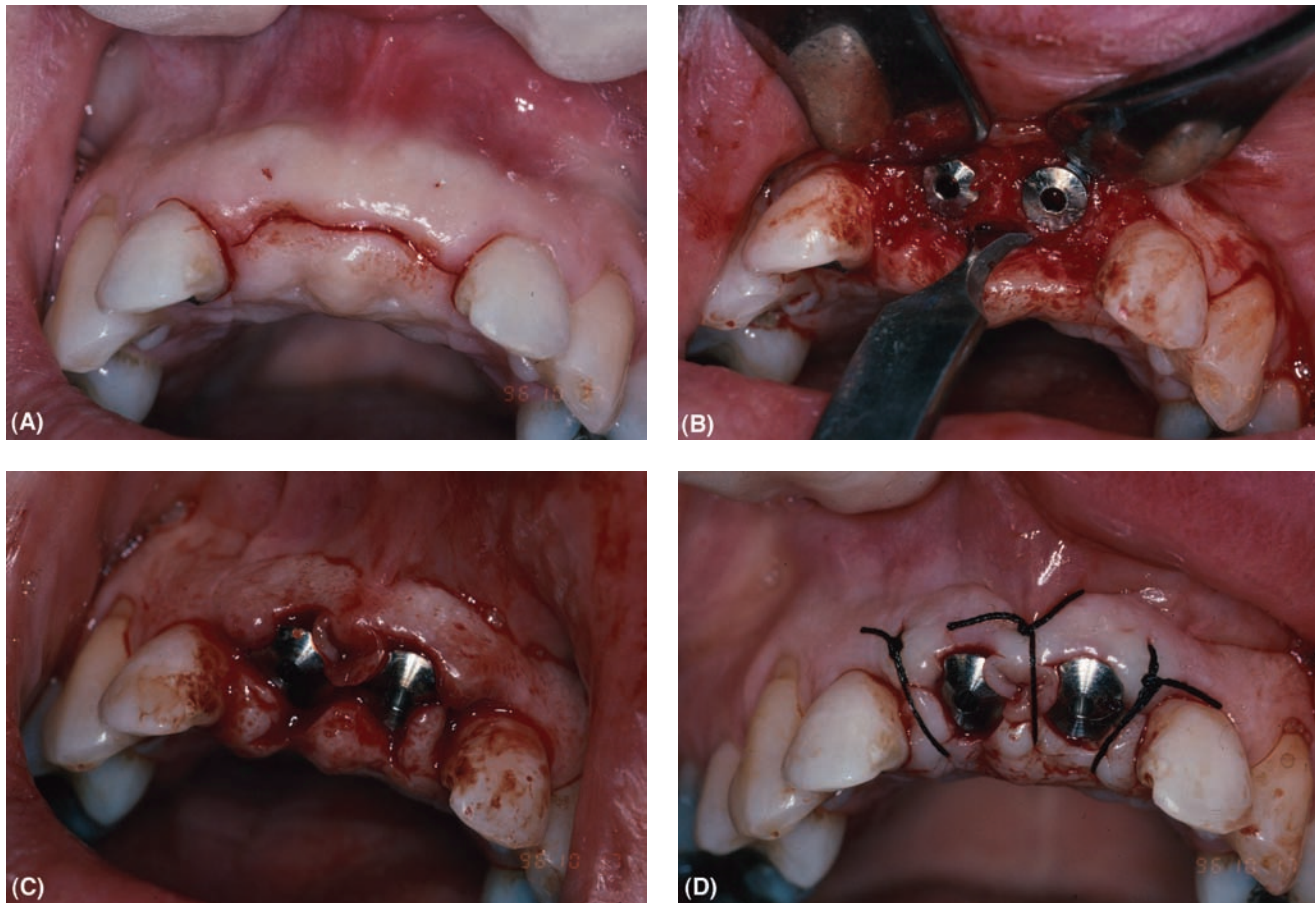
**Figures 8.13** (A) The relieving incisions are made at the line angles of the abutments and may subsequently breakdown. The more remote relieving incisions (B) are more likely to heal uneventfully and do not generally compromise the papillary form.



**Figure 8.12** Small incisions over an Astra implant allow connection of a healing abutment. The implant to the right has the cover screw exposed.

In some circumstances the initial straight-line incision can be closed around the abutments without resecting/reshaping tissue, provided a good soft tissue profile is achieved. This is easier where the mucosa is relatively thin or elastic. In other circumstances, the flaps need to be reshaped by making curved incisions to match the shape of the abutments. Instead of simply excising this tissue, it is often worthwhile adopting the strategy described by Palacci, of retaining the attachment of this tissue at one end and rotating it around the abutment to ensure good coverage of the bone. (Fig. 8.14). This will aid the soft tissue profile but will not necessarily produce papillary height between adjacent abutments as originally described. Papillary form is more dependent on the presence of natural adjacent teeth with good gingival attachment on the proximal surface and careful development of adjacent emerging crown profiles.

The healing abutment length should be chosen so that it just emerges through the soft tissue and does not require too much modification of the provisional prosthesis. There has been a vogue for advocating different width healing abutments to match the size of the tooth being replaced, thereby developing a more appropriate soft tissue form at an early stage.



**Figure 8.14** A series of clinical illustrations of abutment connection surgery. (A) A crestal incision over the heads of the implants extends just into the crevice of the adjacent teeth. (B) Good flap reflection has allowed removal of bone, which has grown over the cover screws, with a hand chisel. (C) The flaps are re-adapted around healing abutments. The flaps are reshaped and the tissue that would normally be excised is preserved and rotated between the healing abutments. (D) The flaps are closed with simple interrupted sutures.

However, the width of the healing abutment can be extreme and compromise the soft tissue profile. We would advocate using healing abutments that are slightly narrower than the tooth being replaced and then “stretching” the tissue with the final or provisional prosthesis.

## CONCLUSION

This chapter has simply dealt with the issue of flap design. Suturing and postoperative care were dealt with in chapter 7. The following chapters deal with the finer points of implant placement.

## Surgical placement of the single tooth implant in the anterior maxilla

### INTRODUCTION

This chapter deals with some of the most important issues of implant placement that are directly applicable to chapter 10 on fixed bridgework. Single tooth restorations may be the most aesthetically demanding of all implant restorations because they are most frequently used to replace maxillary anterior teeth where they can be judged against adjacent natural teeth. To produce the optimum aesthetics, the restoration should emerge from the soft tissue at the same level and contour as the natural teeth. This is facilitated by good preexisting soft tissue and bone contours, meticulous planning, precise positioning of the implant at surgery, and a high standard of prosthodontics. It is easiest to consider the ideal situation in the first place and then more compromised situations. The ideal situation is where there has been no or minimal bone loss and the soft tissues are perfectly contoured around the adjacent natural teeth.

### CONTROLLING VARIABLES IN IMPLANT PLACEMENT

All implant placements rely on a good 3D perspective by the operator. There are relatively few variables that affect this:

1. Mesiodistal positioning
2. Buccolingual positioning
3. Angulation of the long axis of the implant
4. Vertical positioning of the implant head

These variables may be easier to consider when judged against a surgical stent, which provides information on the position and shape of the labial face and the cervical margin of the restoration (Fig. 9.1).

### Mesiodistal and Buccolingual Positioning

These are decided upon with the initial penetration of the drill into the bone site. The mesiodistal positioning is relatively straightforward and in most instances will be in the middle of the single tooth gap (Fig. 9.2), unless there is planned spacing to accommodate a wider diastema on one side of the restoration. In anterior sites where more than one implant is placed, the initial positioning becomes more critical to ensure adequate space between implants and adjacent teeth. This is illustrated in Figure 9.3, which shows a sequence of surgical site preparation for the installation of two implants to replace the maxillary central incisors.

However, in many instances bone resorption will affect the buccolingual position of the ridge and the angulation, factors that are more difficult to cope with especially for the inexperienced clinician (Fig. 9.4). The site may also be affected by localized ridge defects or the presence of anatomical

structures such as the incisive canal (Figs. 9.5 and 9.6). Therefore, a more palatal positioning of the implant is more likely. In the unusual situation of a very well-formed/broad ridge in the buccolingual dimension, it is important not to site the implant too buccally outside the profile of the adjacent teeth.

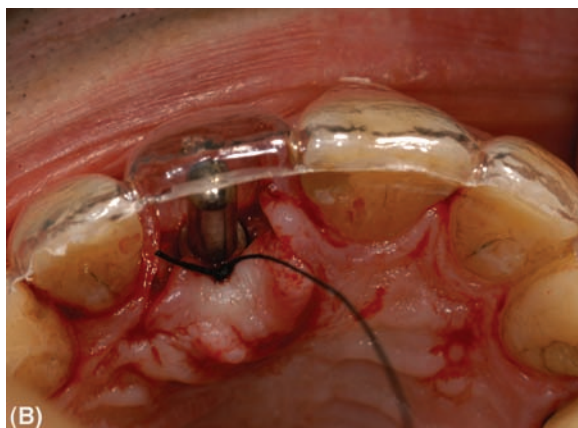
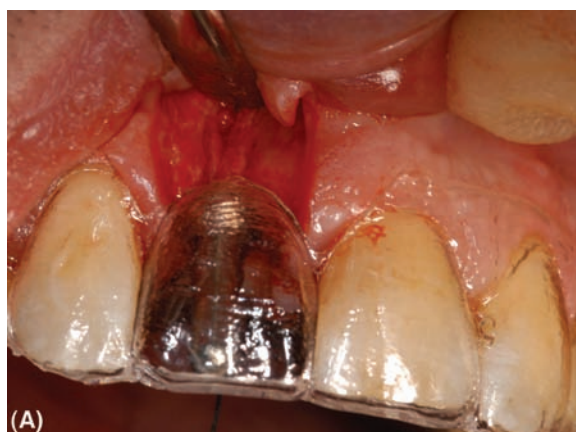### Buccolingual Angulation of the Implant

Figures 9.7 and 9.8 demonstrate the potential variation in implant angulation. The implant can be placed in the same long axis as the crown. This is shown in Figure 9.7A with the implant/crown at the average angle from the Frankfurt plane of  $110^\circ$ . The long axis of the implant and abutment passes through the incisal tip of the crown. This is a common situation and dictates that the crown is cemented to the abutment. In many cases the profile of the bone ridge dictates a more labial inclination of the implant.

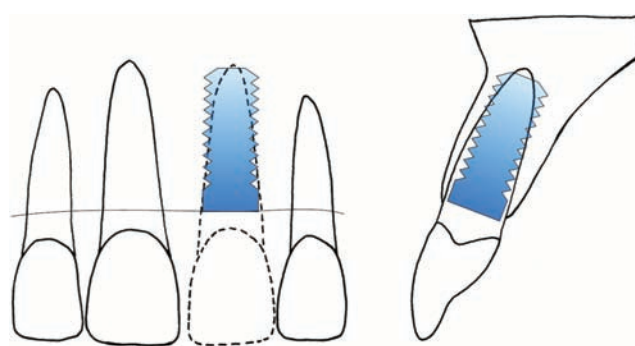
In Figure 9.7B, the implant has been angled a further  $10^\circ$  labially with the crown maintaining its previous position/angulation. The long axis now passes labial to the incisal edge and produces a slight crown/implant angulation, which mimics the crown/root angulation seen in many natural incisor teeth. This angulation may produce very good aesthetics giving a natural form and prominence to the labial cervical margin similar to the adjacent teeth, that is, optimum emergence profile (Fig. 9.9). Increased labial angulation (Figs. 9.7C and 9.10) by a further  $10^\circ$  will still produce a restorable aesthetic solution, but beyond this the restorative problems will increase to a point where it may be impossible to provide an acceptable restoration (Fig. 9.7D).

In contrast, resorption of the bone ridge toward the palate may promote more palatal angulation of the implant. Figure 9.8 shows progressive  $10^\circ$  angulations of the implant toward the palate. Up to  $10^\circ$  palatal angulation there is little compromise, although there will be a tendency toward less favorable buccal cervical contour/emergence profile. As the palatal angulation increases, there will be a need to make up the loss of buccal cervical contour by progressive ridge lapping of the restoration. This results in a restoration, which does not emerge from the soft tissues but a ridge lap that "sits" on the tissues in a similar way to a conventional pontic in fixed prosthodontics. The only advantage of the palatally angled implant is the possibility of access to the abutment screw through the cingulum of the restoration permitting a screw-retained restoration rather than a cemented one (Fig. 9.11). The screw-retained design of single tooth restoration is less important than it used to be because of lower incidences of abutment screw loosening (through better design and adequate tightening of abutment screws using controlled torque devices).

Figures 9.7 and 9.8 would suggest that an acceptable angle would be between  $20^\circ$  proclined and  $10^\circ$  retroclined to the



**Figure 9.1** (A) Labial view of a surgical stent for an upper right central incisor tooth, the blowdown plastic has been trimmed to indicate the cervical margin. A direction indicator post has been placed in the initially prepared site. (B) Palatal view showing the indicator post in the long axis of the tooth to be replaced.



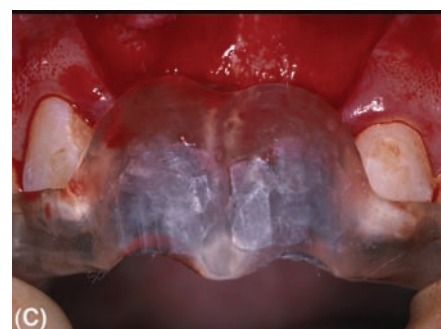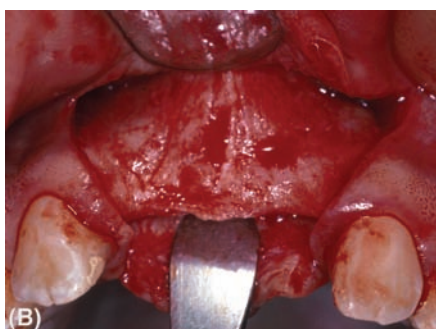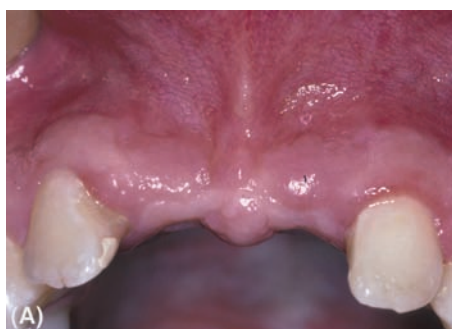**Figure 9.2** The implant is placed in the middle of the gap of the tooth it is replacing, in the same position as the root would have been. This is also indicated in the lateral view in this idealistic situation where minimal or no bone loss has occurred.

“ideal/normal” long axis. Angulations outside these parameters will compromise the aesthetics and test the skills of the prosthodontist to the limit where the implant is unrestorable or aesthetically unacceptable. The following points should help avoid this situation:

1. Good preoperative assessment and planning
2. Grafting of sites where these difficulties are predicted
3. Utilization of surgical stents and guide pins at each stage of the preparation to check on angulation and vertical positioning of the implant head

The above guidelines are approximate (and relatively crude 10° increments) and each case should be judged on its own merits, particularly with regard to patients who have pronounced natural crown/root angulations and/or class 2 or 3 incisal relationships.

A difficult angulation problem encountered at the time of surgery may be reduced by preparing the initial entry site of



**Figure 9.3** A series of photographs showing the placement of two Astra Tech implants to replace both maxillary central incisors. (A) The preoperative situation showing good ridge form. (B) Buccal and palatal flaps have been elevated. (C) A cold-cure acrylic stent has been tried to assess the position of the labial faces of the central incisors to the underlying ridge. (D) The outer cortex of the ridge is penetrated with a round bur in the appropriate mesiodistal and buccolingual positions. (E) The angulation of the sites is developed with twist drills of increasing dimensions. Changes to the angulation can be made at the early stages of drilling. References should be made using direction indicators (in patient's right site) and the stent. (F) Direction indicators viewed from the labial side. (G) Direction indicators viewed from the occlusal aspect. (H) After establishing that the site positions and angulations are satisfactory, the sites are enlarged with a larger-diameter twist drill. (I) The sites are prepared with a conical drill to accept the conical head of the Astra Tech ST implant. (J) The implant is inserted connected to an adapter. Adapters vary in design and can be used in a handpiece or by hand using slow revolutions. (K) The implants have been placed with their heads just below the crest of the bone. This is to allow a good emergence profile of the central incisors, which are quite wide compared with the implant head (4.5 mm). (L) Closure of the flaps in this submerged two-stage protocol.

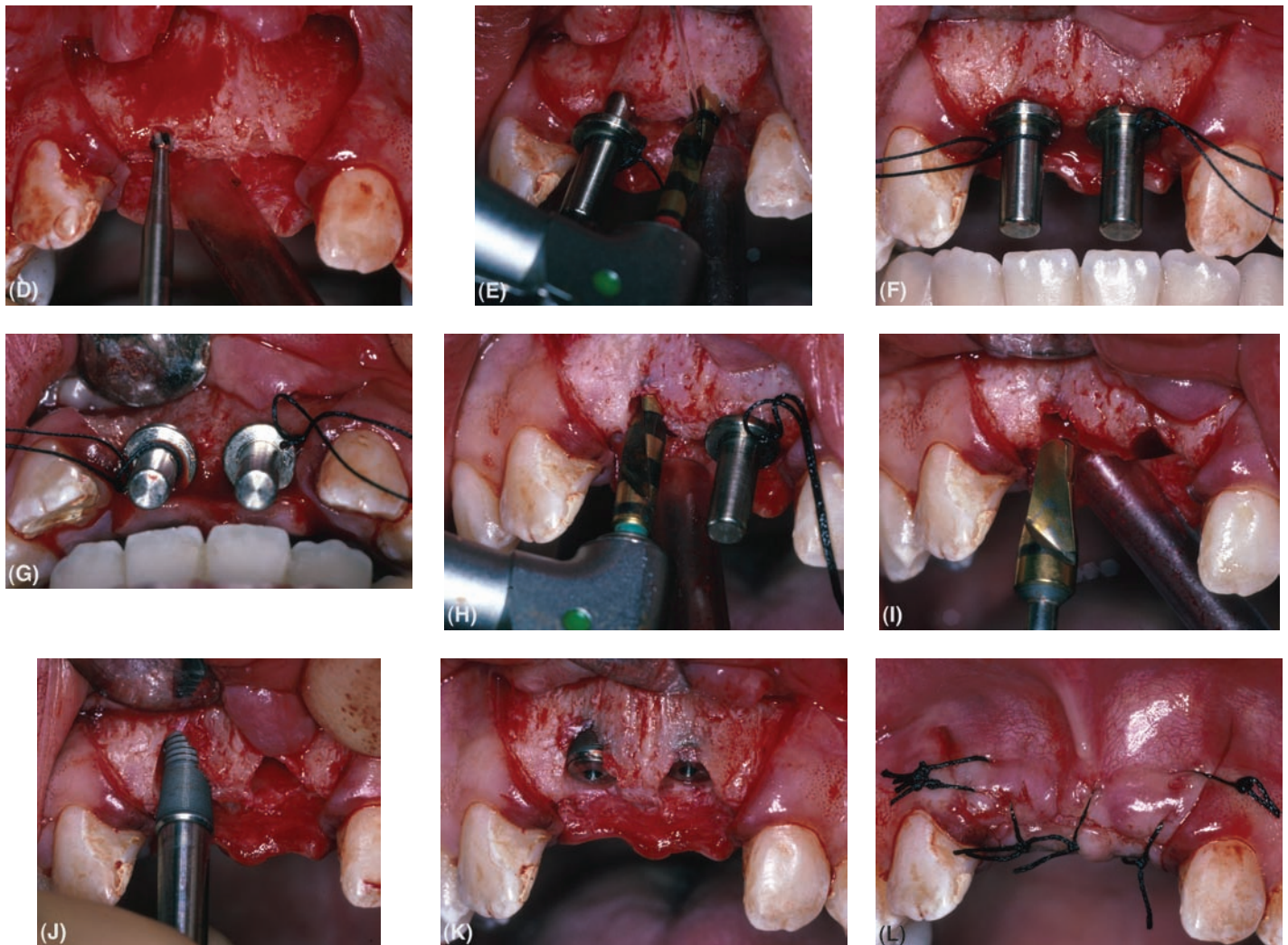
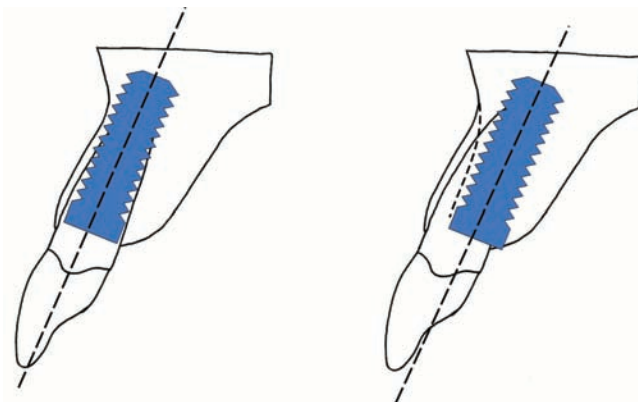
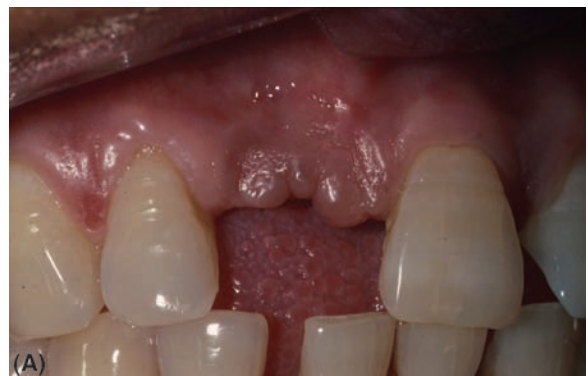

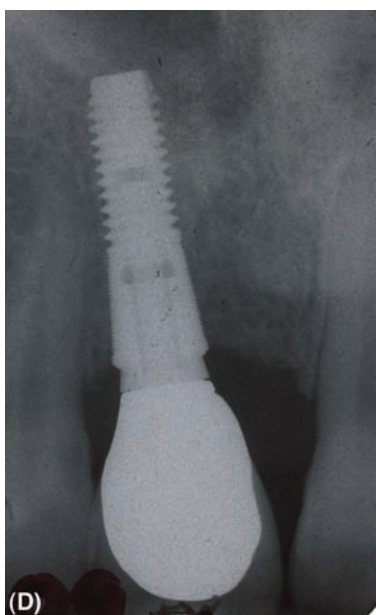
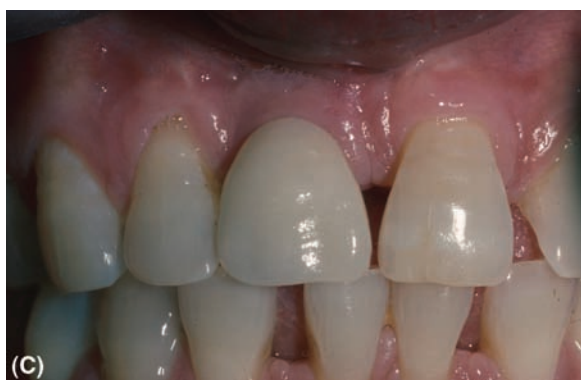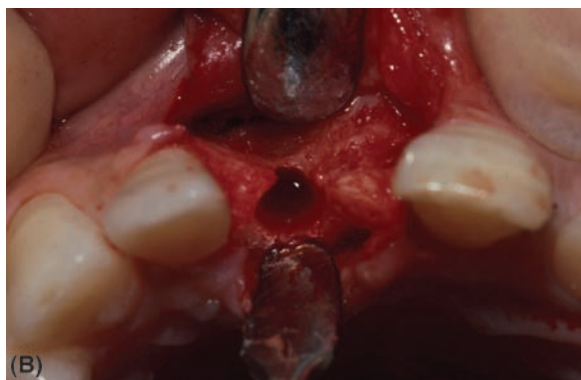Figure 9.3 (Continued)



**Figure 9.4** The diagram on the left shows an implant in the long axis of the root in an ideal situation. The more common situation is illustrated in the diagram on the right where the implant has been positioned palatally as the ridge has resorbed in this direction. The angulation of the implant has been maintained and now passes through the cingulum of the incisor such that a screw-retained retrievable restoration would be possible. There is, however, sufficient bone volume to allow proclination of the implant so that the angle passes through the incisal tip.



**Figure 9.5** A series of photographs illustrating the effects of palatal placement of the implant. (A) A patient with a missing maxillary central incisor. (B) Flaps have been raised and the implant site prepared in the available bone. It is slightly palatal because of the loss of labial bone, and slightly distal because of the presence of a prominent incisive nerve canal. (C) The completed result showing satisfactory aesthetics, but with the implant crown slightly ridge lapped to compensate for the palatal placement. (D) A radiograph of the completed case showing bone levels at the top of this Astra Tech single tooth implant.

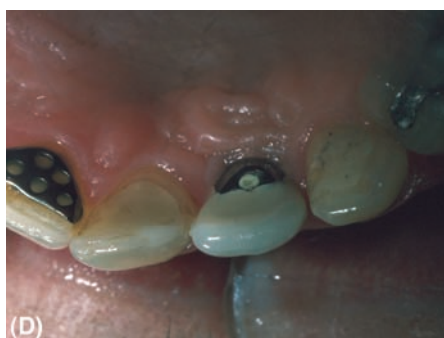
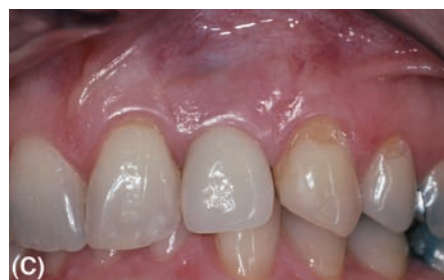
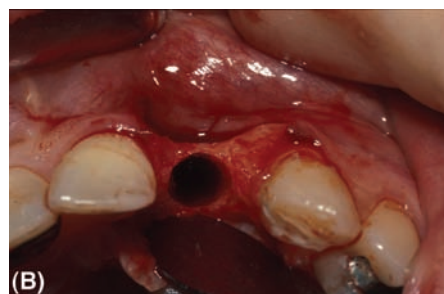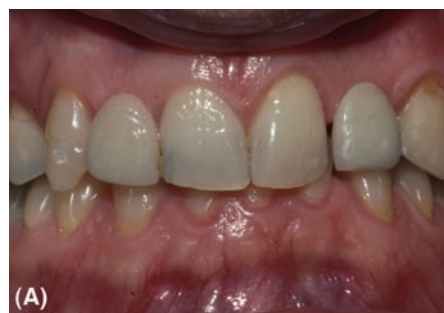**Figure 9.5** (Continued)

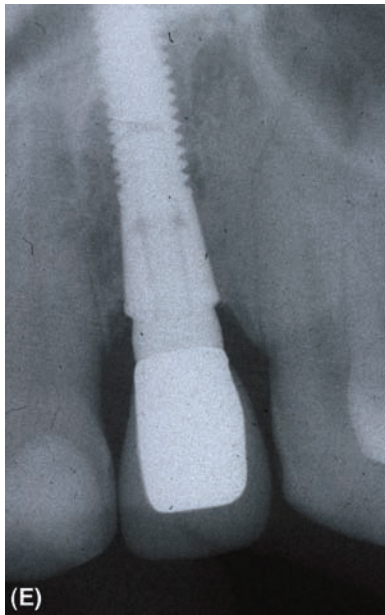
the implant toward the palatal aspect, which would allow a change in angulation and keep the implant preparation within the bone contour. It is therefore important to consider whether the buccopalatal position is in keeping with the required angulation of the implant and to adjust this if required.

#### Vertical Positioning of the Implant Head

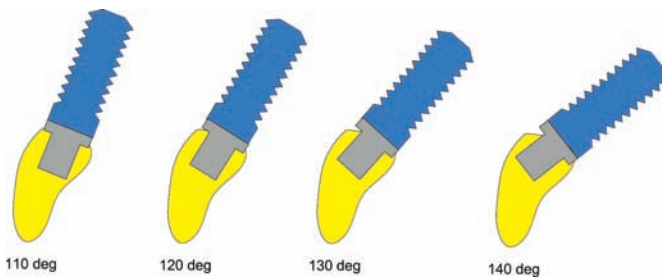
The vertical position of the implant is important to provide space for the planned abutment and a restoration margin that is placed at an aesthetic level in relation to the thickness of the



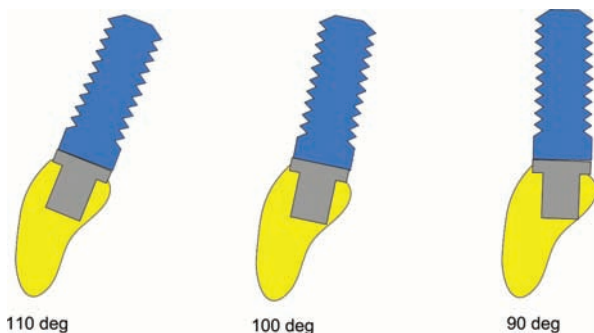
**Figure 9.6** A series of photographs showing the replacement of a maxillary lateral incisor with an Astra Tech single tooth implant where the implant angle is through the incisal tip. (A) Initial presentation showing that the left and right maxillary lateral incisors had been replaced previously with minimal preparation resin-retained bridges. The left side had failed and is being replaced with an implant restoration. (B) Preparation of the site is complete. There has been little labial resorption allowing very good placement and an angulation that passes close to the incisal tip. (C) The completed case showing good aesthetics and emergence profile of the implant crown. (D) Palatal view of the cemented implant crown showing normal contour and a small vent hole to allow escape of excess cement. (E) Radiograph of the completed case showing bone at the top of the implant and the good emergence profile of the restoration.



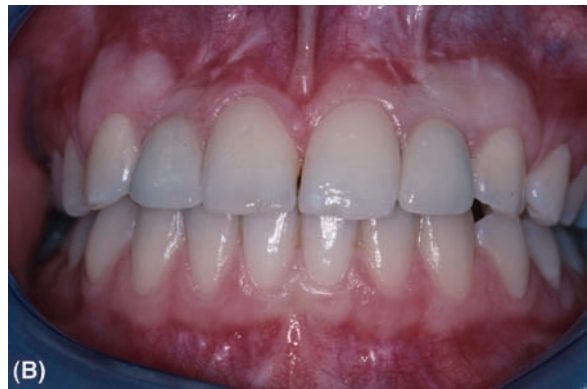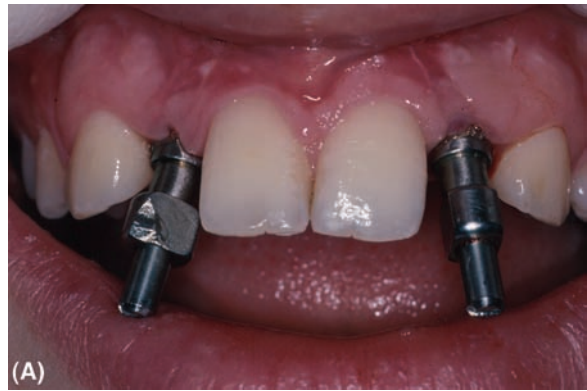**Figure 9.6** (Continued)



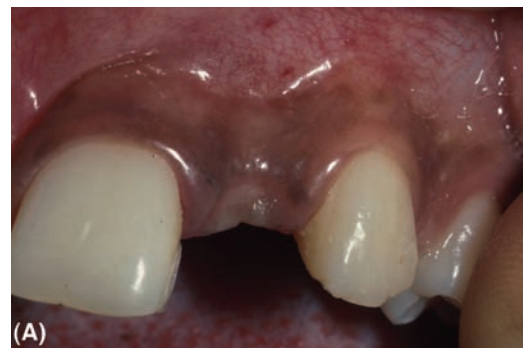**Figure 9.7** Implants drawn at various angles from the Frankfurt plane, with 110° considered to be the average root angulation in a class 1 incisor relationship. The crown of the restoration has not had its angulation changed and in each case the implant and abutment have been progressively labially inclined by 10° increments.



**Figure 9.8** Implants are drawn at various angles from the Frankfurt plane, with 110° considered to be the average root angulation in a class 1 incisor relationship. The crown of the restoration has not had its angulation changed and in each case the implant and abutment have been progressively palatally inclined by 10° increments.



**Figure 9.9** (A) Replacement of both maxillary lateral incisors in a young patient. This figure shows the impression copings on the implants during the prosthodontic phase. There is a labial angulation of both implants compared with the adjacent natural teeth. (B) The completed result showing good emergence profiles.



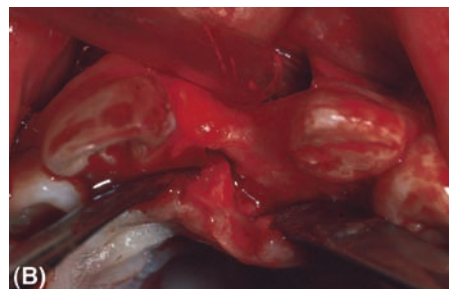
**Figure 9.10** A series showing replacement of a maxillary lateral incisor with labial angulation of the implant. (A) The wide missing lateral incisor space. (B) A surgical stent in place, with a direction indicator in the initially prepared site. (C) The implant has been inserted and an inserting device is still connected. The implant will be seated a further millimeter apically. (D) A side view of the implant inserter showing quite marked labial angulation of the implant, corresponding to a line through the mid-labial point of the crown. It is also apparent that the natural teeth have a pronounced crown/root angulation. (E) The completed result showing good aesthetics of this cemented implant crown.

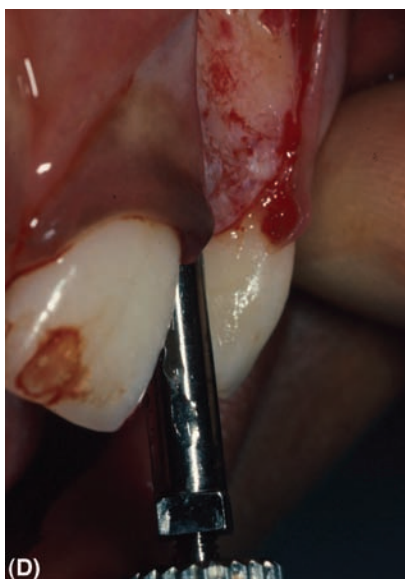
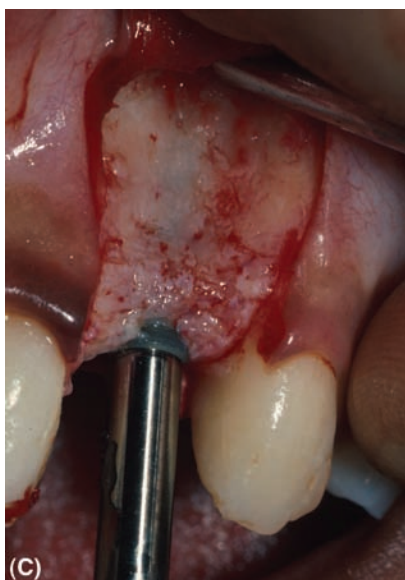
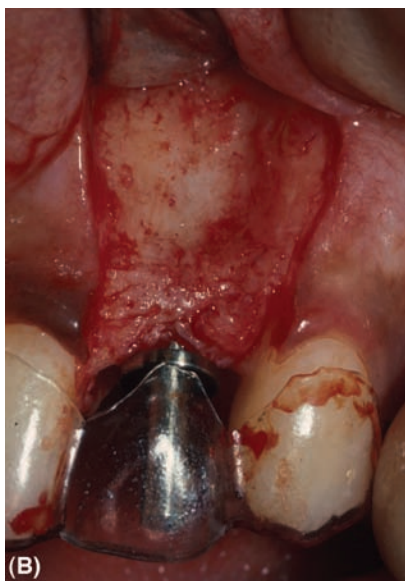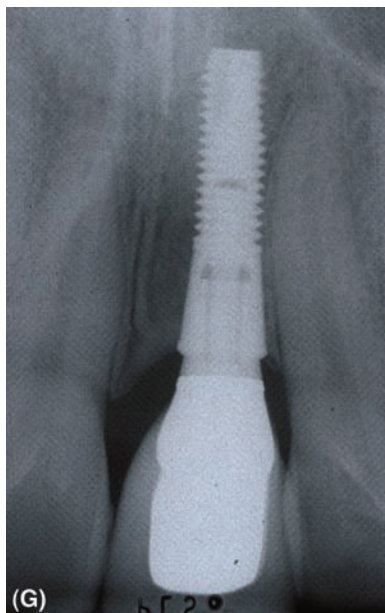
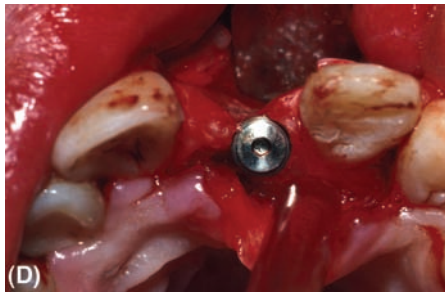
Figure 9.10 (Continued)

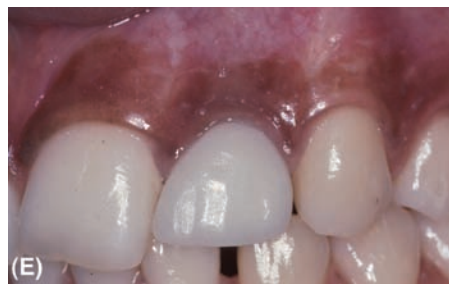
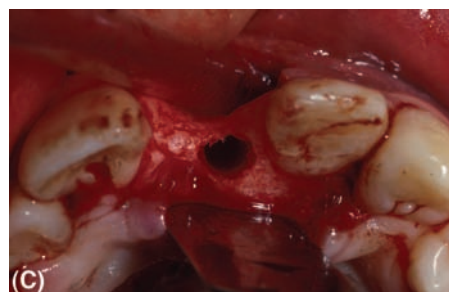
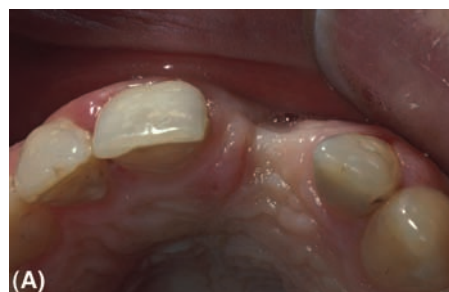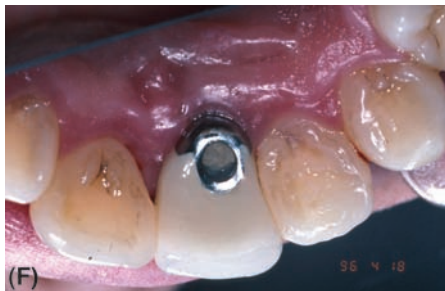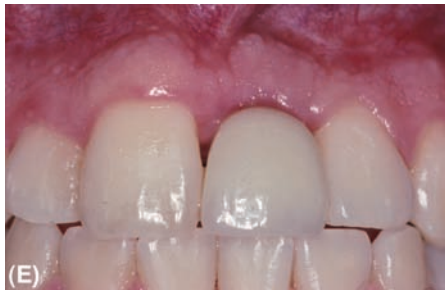Figure 9.10 (Continued)

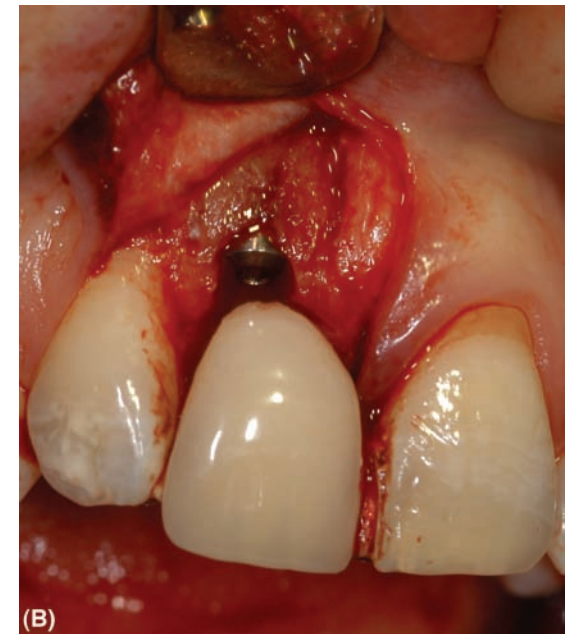
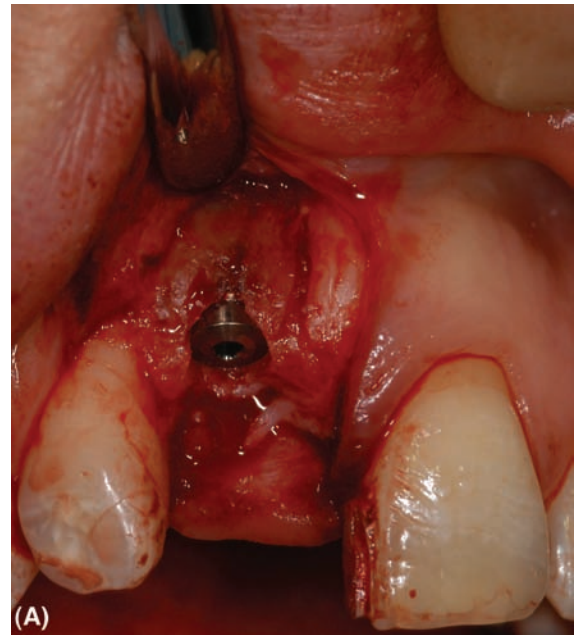

**Figure 9.11** A series showing marked palatal positioning of an implant replacing a maxillary central incisor. (A) Occlusal view of the ridge form showing a labial concavity. (B) Elevation of the flaps reveals a large incisive canal, further compromising the site. (C) The site has been prepared in the available bone volume without compromising adjacent structures. (D) An Astra Tech single tooth implant has been placed. (E) The completed result showing compromised aesthetics because of the palatal position of the implant. The crown is ridge lapped. The area would have required a moderate sized graft to overcome this. The patient was prepared to accept the compromise, particularly as the cervical area did not show during normal function. (F) Palatal view of the completed case showing the access hole to the abutment screw. The crown is cemented to a standard abutment, but the crown/abutment assembly could be removed or the abutment screw tightened through this access hole. (G) Radiograph of the completed case showing good contour/emergence in the mesiodistal plane, concealing the ridge lap profile in the buccopalatal plane.



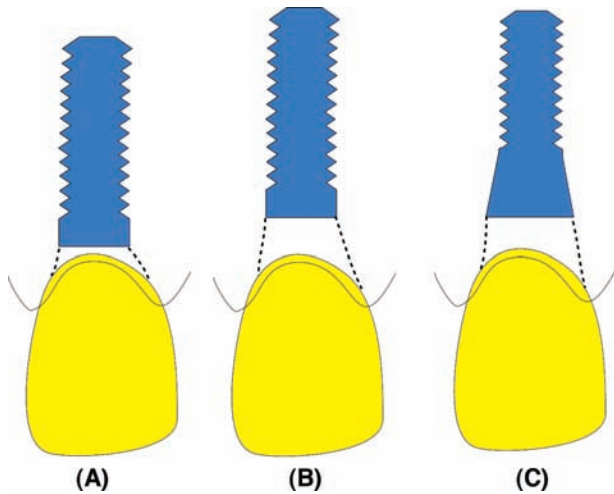
**Figure 9.11** (Continued)

soft tissue. Figure 9.2 shows a frontal view with the ideal arrangement of the implant in the middle of the space in the long axis of the tooth with the head of the implant about 3 mm apical to the cervical-gingival margin of the restoration. There should be little variation in the angle of the implant in this plane and most of the variation relates to the vertical level of



**Figure 9.12** (A) An implant has been placed to replace an upper right maxillary central incisor. The implant has been countersunk approximately 2 mm below the crest of the adjacent bone and a long cover screw has been attached to the implant. The cover screw is almost level with the adjacent bone and this will reduce the possibility of bone overgrowing the cover screw. (B) The temporary prosthesis in place showing the difference in level between the cervical margin and the head of the implant. Countersinking of the implant will allow development of a better emergence profile, particularly as the implant was placed more distally in the space to avoid involvement of a prominent incisive canal.

the head of the implant. The distance of 3 mm between implant head and adjacent tooth cement-enamel junction is quoted as it usually allows a smooth transition of restoration profile from an implant of average diameter (4 mm) to the natural crown contour/dimensions of maxillary central or lateral incisors or canines (Fig. 9.12). An implant head that is too close to the



**Figure 9.13** Labial view of emergence profile contours from implants placed at different vertical levels (A–C), apical to the desired restoration.

crown (Fig. 9.13A) will necessitate an abrupt highly angulated profile and the possibility of unaesthetic exposure of the abutment or implant head. An implant head that is located further apically will allow a very smooth transition profile (Fig. 9.13B), but if this is too extreme it will produce a very long restoration

that may be more prone to mechanical complications (see chap. 16). The deeply placed implant head may be more difficult for the prosthodontist to deal with and failure to maintain soft tissue height will compromise aesthetics.

The emergence profile therefore depends on

1. the size of the crown to be replaced;
2. the diameter of the implant/abutment;
3. the vertical distance between implant and crown cervical margin.

An implant diameter can be selected to more closely match the size of the tooth it is replacing, but the diameter is limited by the width of available bone. The vertical level of the implant is still very important to maintain soft tissue aesthetics.

## CONCLUSIONS

It should be clear from the preceding discussions and diagrams that the angulation, buccopalatal position, and the vertical level of the implant head have a marked effect on the contour and aesthetics of the single tooth restoration. It is very important that the clinician who is surgically placing the implant has a thorough appreciation of these factors. The utilization of a stent indicating the labial aspect of the planned restoration will help avoid many of the potential problems, particularly for the inexperienced operator. The placement of an implant in an unrestorable or unaesthetic position must be avoided, and in situations where the bone profile, position, or quantity is compromised, grafting should be carried out to correct this, ideally as a separate procedure prior to implant placement (see chap. 12).

## Implant placement for fixed bridgework

### INTRODUCTION

The planning and placement of implants for fixed bridgework follows the basic rules set out for those described in the chapter on single teeth, but with more complications of site selection, the relationship between adjacent implants, and their relationship to the planned prosthesis. Ideally all of these factors will have been resolved in the planning phase with careful matching of the radiographic data, diagnostic setups, and clinical verification. However, despite the most careful planning, there are occasions when modifications have to be made at surgery and it is under these circumstances that it is advantageous if the surgeon has knowledge of the prosthodontic implications, either through his own experience or through that of an attending prosthodontic specialist.

The requirements for surgical stents, anesthesia, flap design, and soft tissue handling are dealt with in the chapter of basic surgery (chap. 7).

### IMPLANT POSITIONING AND INSTALLATION

When placing multiple implants it is especially helpful to be able to refer to a written plan of site location, estimated implant length and implant diameter, and reference to relevant radiographs and study casts. Following elevation of the flaps, the surgical stent is tried in and referred to at various stages during the site development. The proposed sites of the implants are marked in the cortical bone with a round bur with positioning planned in three dimensions. The initial preparation is checked against adjacent teeth and anatomical structures, tooth positions on the stent, bone contour at the site, and implant spacing. Spacing is required between adjacent implants (and implants and teeth) for an adequate width of bone (and soft tissue). Interimplant distance should be between 2 and 3 mm while a space of 1 to 2 mm can be sufficient for an implant next to a tooth. The angulation of the site is then developed with the smallest twist drill and checked with a guide pin. Remember that modifications to the position and angle can only be made at the early stages of the preparation process (e.g., the 2-mm twist drill stage). The length of the site is then established and the system protocol followed with increasing diameters of drills until the preparation is complete and the implant can be placed (Fig. 10.1).

### IMPLANT SPACING IN MULTIPLE IMPLANT PLACEMENT

This was dealt with in some detail in the planning chapters (chaps. 4 and 5), but is helpful to remind the surgeon with appropriate illustrations. The spacing requirements will vary depending on whether there is an adjacent implant or pontic space. The dimensions of the implant and the characteristics of the implant system will also have a bearing on spacing (Fig. 10.2). In addition to the surgical criteria, it is important to

have a full understanding of the dimensions of the prosthetic components that exist for the system being used. All abutments will exhibit a coronal flare from the dimension of the implant and this can have an impact on the space available for the soft tissue, the eventual emergence and appearance of the restoration, and the long-term stability of the soft tissue.

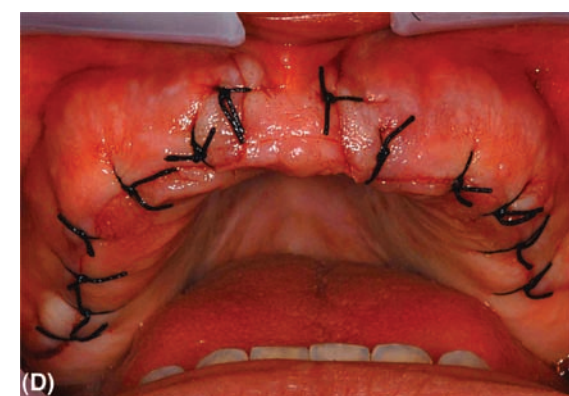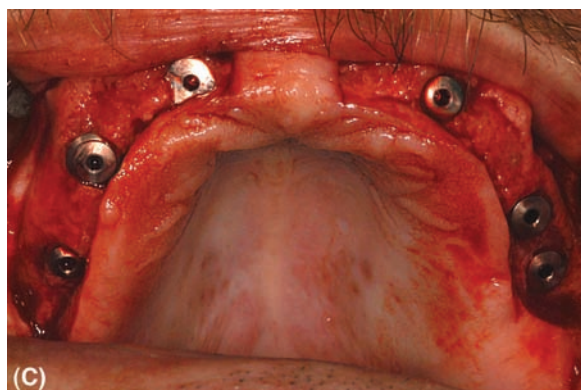
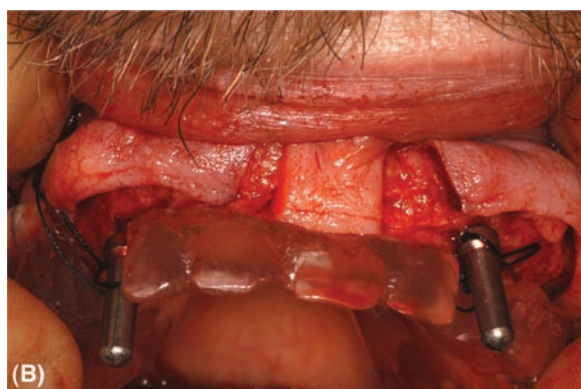
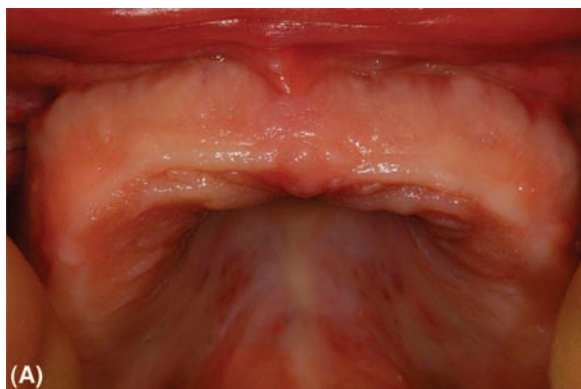
The emergence of the abutment is usually related to the nature of the implant-abutment connection. There is a general tendency for "flat top" implant systems to have a greater flare as the emergence of the abutment starts from the edge of the implant (Fig. 10.3). Many such systems now offer a capability to "platform switch" where the width of the abutment, at emergence, is narrower than the width of the implant.

Systems based on an internal cone abutment connection have abutments that are narrower than the implant head at emergence. This is the case with the Astra system illustrated in Figure 10.4. Standard implant diameters range from 3 to 5 mm at the implant head but the conical abutment fits within the head of the implant. The reduced width of the abutment at the implant head expands to a maximum diameter that matches the implant diameter at a distance of 2 mm above the head of the implant. This conical profile allows a good soft tissue cuff to be formed and, therefore, permits slightly closer positioning of the implants. Implant spacing also needs further consideration when implants of a wider diameter are used. As the initial sequence of drills is the same, additional space for a wider diameter implant has to be accounted for in the early phases of site preparation (Fig. 10.5).

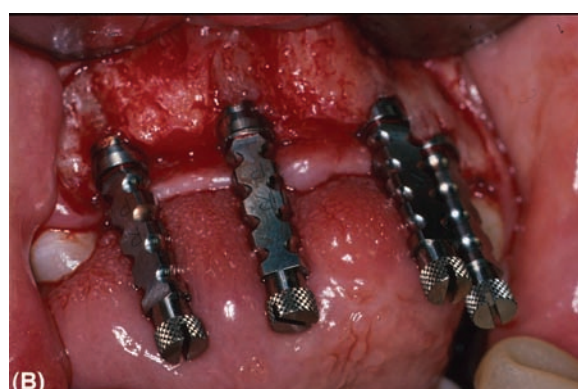
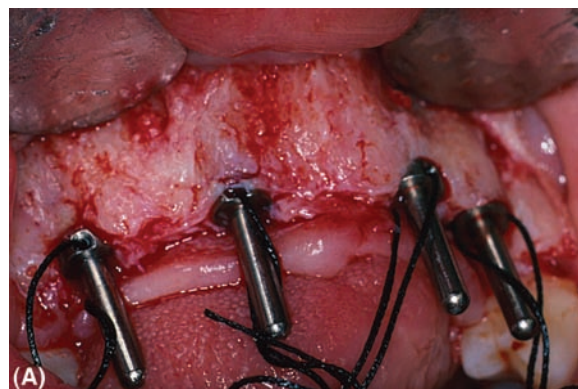
Problems can arise when implants are placed too close together. Not only can the viability of the interimplant bone be compromised but problems also exist relating to restorative emergence and maintenance of soft tissue (Fig. 10.6).

Tissue level implant systems like the Straumann system require a different approach. A standard 4.1-mm-diameter implant (measured in the endosseous part) has a transmucosal collar, which enlarges to 4.8 mm in diameter at the top. It is therefore the width of the collar that determines implant spacing. The implants should be placed so that there is at least a 1-mm gap between adjacent collars at their maximum width, which gives an additional soft tissue space apical to this (and in turn an adequate dimension of bone) (Fig. 10.7).


In implant systems with a wide range of implant diameters, such as the Frialit system, a different approach may be required. In this system, the implant sites are first prepared to an acceptable final depth (Fig. 10.8). The sites are then widened with successive stepped conical drills that exactly match the range of implants, which have diameters of 3.8, 4.5, 5.5, and 6.5 mm. Therefore, the initial siting of the implant centers is very dependent on the planned diameter of the final implant. If there is a miscalculation and it appears that the implants of the planned diameter will be too close, then a narrower preparation and implant would have to be utilized. The Frialit implants are tapered apically and, therefore, this provides



**Figure 10.1** A series of photographs illustrating placement of Astra Tech implants in the maxilla. (A) The preoperative view of the maxilla. (B) Flaps raised buccally and palatally revealing the ridge form with implant positioning checked with guide pins. (C) All implants have been placed and cover screws inserted. (D) The flaps closed with multiple sutures.



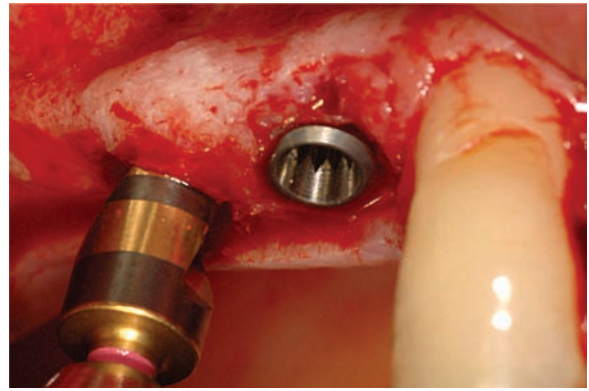
**Figure 10.2** Placement of Nobel Biocare implants into the anterior maxilla. (A) Ample space has allowed placement with center-to-center spacing of about 8 mm with no restorative issues. (B) Transfer copings have been attached so that an impression recording the position of the implants can be taken. This allows construction of a provisional bridge that can be fitted at exposure surgery.



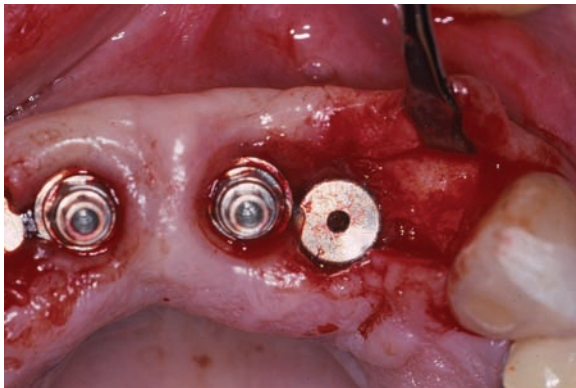
**Figure 10.3** Implant positioning needs to account for the emergence of restorative components, the flare of which can start from the edge of "flat top" implants.



**Figure 10.4** The internal conical connection of the Astra Tech implant allow abutment emergence from within the diameter of the implant. This can allow closer positioning and still maintain adequate width for the soft tissue.



**Figure 10.6** A 4-mm-diameter Astra Tech implant has been placed distal to the upper canine with adequate spacing. The site distal to the implant is being prepared for a 5-mm-wide-diameter implant. Position of the osteotomy has been determined in the early stages to allow adequate spacing.

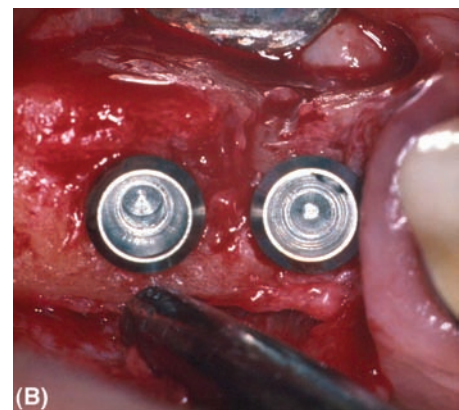
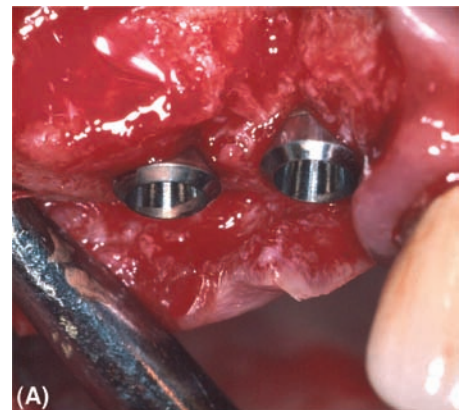


**Figure 10.5** An example of Nobel Biocare implants that were placed too close together. The implants in the central incisor sites (those with the abutments connected) have good spacing between them. The implant in the lateral incisor space (cover screw in place) has been placed too close. Abutment connection would be hampered by the proximity of the adjacent implant.

adequate bone between implants in the apical zone. However, this is not so much of a problem as the coronal aspect where the breach in the epithelium occurs where complications are far more likely in terms of inflammation or aesthetics.

The initial selection of the site has to take into account:

- the planned diameter of the implant,
- the proximal contour of the tooth,
- the periodontal ligament space of the tooth,
- allowance of between 1 and 2 mm of bone between implant and root,



**Figure 10.7** A series of photographs showing the installation of Straumann tissue level implants. (A) Two implants have been inserted in the maxilla distal to the canine. The flare of the transmucosal collar from the implant diameter is evident. (B) An occlusal view of the implants showing a gap of approximately 2 mm between the outer aspects of the polished collars and the same gap between the anterior implant and the tooth. (C) A radiograph of the implants with closure screws in place. The shape of the implants means that there is more space between them at the bone level than at the soft tissue level.

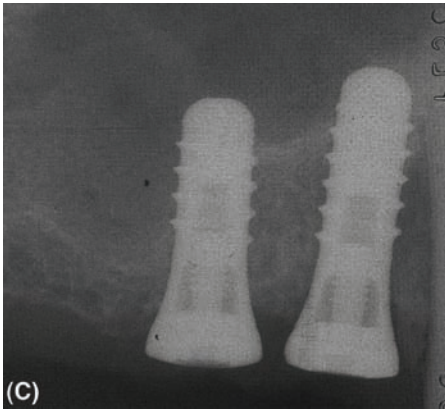
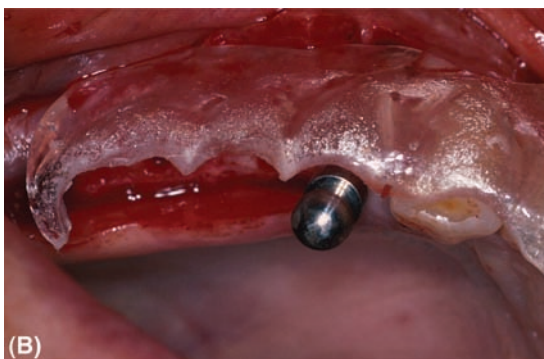
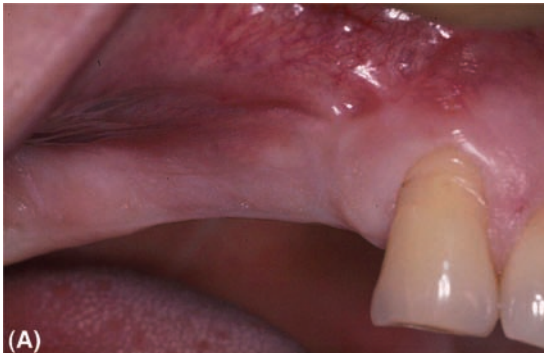

Figure 10.7 (Continued)



**Figure 10.8** A series of photographs showing the installation of four Frialit implants in the posterior maxilla. (A) The edentulous ridge prior to surgery. (B) An acrylic stent is in place with a guide pin to evaluate the position and direction of the mesial site. Note the stent reflects the size of the intended final restorations allowing positioning of implants with different diameters. (C) The use of a step drill to widen the initial site to 3.8 mm. (D) Mesial implant in place. Initial preparation of the other sites reflects the intended use of wider implants. (E) All four implants have been inserted with the distal three being 4.5 mm in diameter. The cover screws are color coded to reflect the underlying implant diameter.

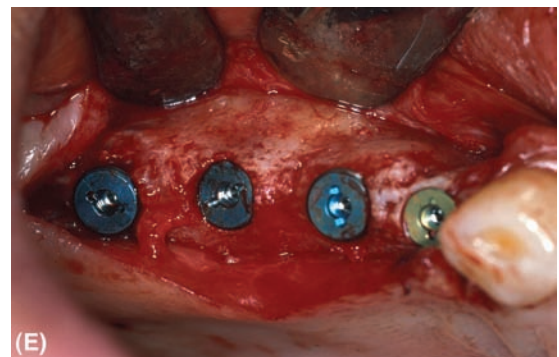
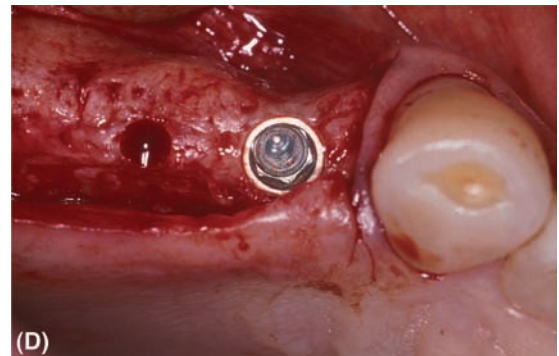
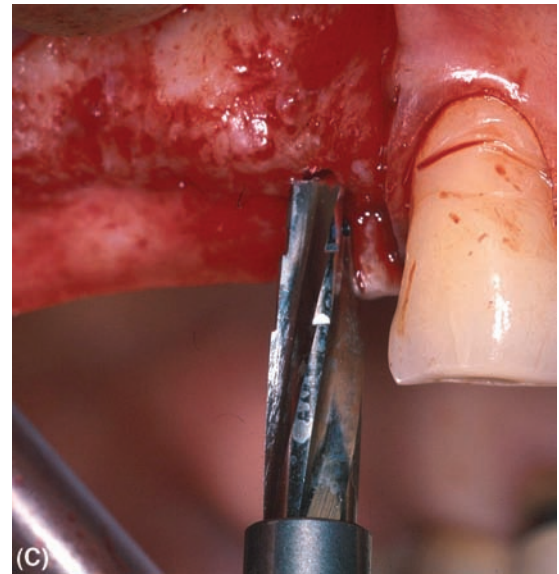
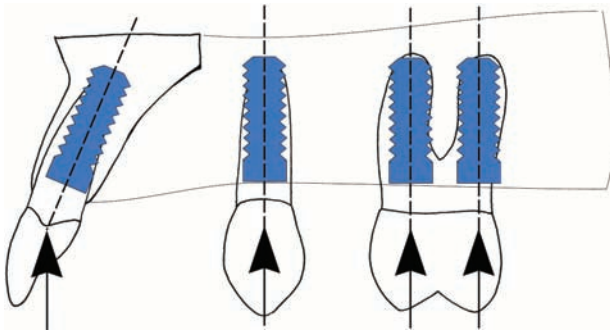


Figure 10.8 (Continued)

- allowance of adequate space for the proximal soft tissue papilla,
- a path of insertion of the implant, which is not affected by the tooth contour.

### IMPLANT ANGULATION

Guide pins placed in the developing implant sites should be checked against the surgical stent and the opposing dentition, and modifications made as necessary. This is very helpful and should prevent unacceptable angulation of the implants. Ideally the angulation of the implant sites should more or less mimic the angulation of the natural teeth with modifications



**Figure 10.9** Forces directed through the implants placed in the posterior jaw will usually be in the same long axis as the premolar or molar teeth. Labial angulation of the anterior implants means that normal forces are not directed down the long axis.

according to the design of the final prosthesis and the degree of ridge resorption. A decision as to whether the final restoration is going to be cement or screw retained should be made during the planning phase as this will have an impact on implant angulation. If the final prosthesis is designed to be retrievable/screw retained, the ideal angle of the implant passes through the cingulum area of the anterior teeth and the occlusal surfaces of the premolar/molar teeth. In a non-retrievable cemented prosthesis, ideally the angulation should be consistent with loading the implants through the long axis. However, in the anterior zone, the angulation can be more labially inclined through the incisal tip or toward the labial surface, potentially improving the emergence aesthetics (see chap. 9 on single tooth implant). Although masticatory forces are lower in the anterior region, force transmission through the implants may be less favorable as it will be far removed from axial loading (Fig. 10.9).

An acceptable degree of implant angulation at time of surgery can also be managed through the prosthetic phase. This can be of benefit where surgical anatomy may have resulted in a change of orientation of the implant at time of placement. For example, implants may be angled more than usual to engage more bone length at sites next to the maxillary sinus.

Manufactured abutments can allow for angular variations between implants when screw retention is intended. Customizable abutments can be used if these values are exceeded (see chap. 14). Excessive angulation (over 30°) should be avoided.

### LEVEL OF THE IMPLANT HEAD

The last factor to consider in the implant placement is the level of the implant head. This level will dictate

- available vertical space to the occlusal plane or incisal plane for abutments and restoration;
- vertical space for the emergence profile of the restoration.

Submerging the implant head may be necessary to provide much needed space to accommodate abutments and restoration in individuals with little vertical space, for instance, patients with minimal ridge resorption. Minor ridge reduction may also be indicated in such cases. More often ridge resorption is to such an extent that submergence of the implant head is not required other than to optimize the emergence profile and aesthetics. The deeper the implant head, the easier it is to

make a gradual smooth transition to the emerging crown. In contrast, it will have an adverse effect on the height of the restoration. This can, therefore, produce unfavorable force distribution and leverage onto the implant-abutment connection.

It is perhaps easiest to contrast the effects of implant head level between submerged systems such as the Branemark or Astra with that of a nonsubmerged system such as the Straumann tissue level system. In the prescribed use of the Branemark implants, the implant head is countersunk to a point that allows the cover screw (which protects the external hexagon) to be level with the crest of the bone ridge. This facilitates soft tissue coverage and minimizes the chance of subsequent wound dehiscence and implant loading. However, to achieve this, the implant site is countersunk and this places the implant head either within the superficial cortex or below this if the cortex is thin. This may therefore negate one of the prime aims of bicortical stabilization with this system. Countersinking could, therefore, be viewed as destructive of the cortical anchorage, which could be critical in areas of poor bone quality, such as the posterior maxilla. It is even more pertinent when one considers that in the first year of loading the implant there is bone resorption to the level of the first thread, further accentuating loss of previous cortical bone. However, the advantage of this is that the abutment-implant junction is placed sufficiently far apically to allow good emergence profile of the restoration and an aesthetic subgingival placement of the restoration margin. The design of the Astra system allows placement of the implant head at the level of the crestal bone without countersinking and thereby preserves cortical bone. This is because the standard implant head has nearly the same diameter as the main threaded portion of the implant and the cover screw fits within the implant head. This system is therefore very useful in the resorbed maxilla, which may have little crestal cortex, as it can be used to fully utilize the limited bone height and maintain cortical anchorage.

The standard design of Straumann tissue level implant has an integrated smooth transmucosal collar that is 2.8 mm in length incorporated onto the sand blasted and etched and chemically modified implant body. The transmucosal collar effectively reduces the height of the crown and thereby the leverage forces at the implant-abutment junction. In areas of thin mucosa, the implant head will be above the mucosa and the aesthetics may be compromised. However, the Straumann esthetic line has a reduced transmucosal collar height of 1.8 mm to allow placement within an aesthetic area. Tissue level implants often need further considerations. As they are not submerged, it may be necessary to carry out any soft tissue correction normally considered at exposure surgery at the time of implant placement. In addition, the transmucosal collar adds to the height of the implant and this can have a restorative implication that needs to be considered during surgery.

### CONCLUSION

The surgeon must be very familiar with the system used in multiple implant placement because of the large number of variables. The dimensional comparisons of the various implant systems used in this book were described in chapter 1 and an appreciation of their differences and respective dimensions is vital to the clinician planning the treatment and those providing the surgical and prosthodontic phases of treatment. The surgeon may have to modify the plan during surgery and can only do this if he has an extensive range of implants at his disposal and knowledge of the prosthodontic solutions that exist for any surgical modifications.

## Immediate and early replacement implants

### INTRODUCTION

Early traditional implant protocols advocated leaving extraction sites for 12 months to allow complete healing and maturation of bone before implant placement. However, the resorption of bone over extended time periods often led to a situation where there was insufficient bone for routine implant placement. Protocols have therefore developed in which implants are placed at the time of extraction of the tooth/root, or soon after, before significant bone resorption occurs. Bone loss and resorption can also be minimized by careful extraction of teeth. Following placement, the implant can be submerged beneath the soft tissue, left exposed with a healing abutment/cap attached or restored with a provisional prosthesis. This chapter will consider the application of these various protocols for the replacement of single teeth, starting with extraction and implant placement followed by protocols for immediate restoration or loading. This chapter will not consider more complex multitooth/full-arch replacement, the prosthodontic management of which is considered in chapter 14.

### TIMING OF EXTRACTIONS AND IMPLANT PLACEMENT

There are various recommendations regarding timing of implant placement following tooth extraction. The implant can be placed

1. months or years following tooth loss;
2. immediately following extraction during the same surgical procedure ("immediate implant placement");
3. following a delay of a few weeks ("early implant placement"); this is normally two to six weeks to allow resolution of infection/inflammation or some soft tissue coverage; or
4. following a delay of three to six months ("delayed implant placement") to allow some bone healing.

The differences between "immediate," "early," and "delayed" implant placement are summarized in Table 11.1. The timing can be related to the normal healing of an extraction socket. Healing follows a sequence of clotting, granulation tissue formation, epithelialization, osteoclastic resorption, and osteoblast deposition of woven bone followed by mature lamellar bone. Any factors that compromise these healing events will delay the process and may be implicated in implant failure. The choice of protocol also depends on the complexity, difficulty, and predictability of the case. The immediate protocol is more applicable if an anterior tooth is being replaced. The extraction should be relatively straightforward and the socket not too large to compromise implant stability (Fig. 11.1). In contrast, a case requiring multiple and/or difficult extractions and temporization may be best handled in a separate dedicated surgical operation to that of implant placement. Most of the following considerations apply to anterior tooth replace-

ment, as the situation with molar teeth is usually far more compromised because of the larger extraction sockets and less bone available apical to the socket because of proximity of the maxillary sinus or inferior dental canal.

### ASSESSMENT

The assessment for timing of implant placement mainly relates to the effect of the extraction socket on the implant placement. It has already been stated that the area should be free of overt infection, and if any doubt exists the implant surgery should be delayed and, if necessary, appropriate antibiotics given.

The main factors to assess can be obtained from a careful clinical examination and good-quality radiographs of known magnification and include the following:

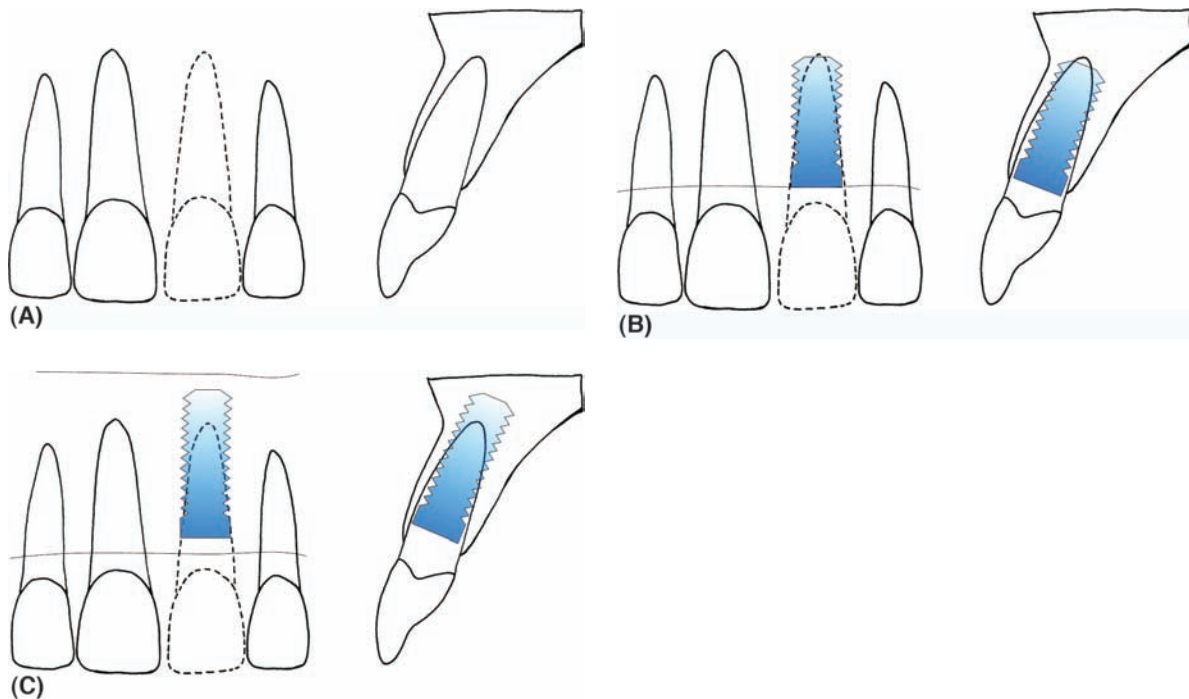
1. Periodontal condition of the tooth to be extracted and adjacent teeth
  - a. Gingival health/contour of labial gingivae and interdental papillae (Fig. 11.2A)
  - b. Probing depths, recession, attachment levels
2. Restorative and endodontic status
  - a. Appearance and position of tooth crown
  - b. Sinuses/infection
  - c. Root fractures (Fig. 11.2B)
  - d. Post crowns
3. Size and shape of roots (Figs. 11.1 and 11.2B)
  - a. Length
  - b. Width
  - c. Taper
  - d. Number of roots in the case of molars
4. Bone support (Figs. 11.1 and 11.2B)
  - a. Height of marginal bone supporting the tooth root
  - b. Distance between apex of root and anatomical limit of bone (e.g., floor of nose, maxillary sinus, inferior dental neurovascular bundle)
  - c. Apical, furcal, and lateral bone lesions
5. Difficulty of extraction procedure
  - a. Simple elevation/forceps
  - b. Surgical procedure involving bone removal

### TOOTH/ROOT EXTRACTION

Tooth extraction can be described as a technique whereby dilatation of the tooth socket along with severance of the periodontal ligament allows removal of the tooth. Alongside this, movement of the tooth preferentially toward the thinner buccal or palatal socket wall (depending on the individual anatomy) allows increased dilatation but may also cause fracture of the weaker wall and its concomitant or subsequent loss. Where immediate implant placement is planned, any fracture of the socket wall is undesirable and therefore techniques to minimize such collateral damage need to be employed.

**Table 11.1** Summary of Immediate, Early, and Delayed Implant Placement

	Immediate placement	Early placement	Delayed placement
Timing	Implant placement at the same surgical procedure as tooth extraction	Implant placement 2–6 weeks following tooth extraction	Implant placed 3–6 months following tooth extraction
Advantages	<ul style="list-style-type: none"> <li>-Reduced number of surgical procedures</li> <li>-Optimizes visualization of extraction socket</li> <li>-Flap elevation may be unnecessary</li> <li>-Immediate restoration possible</li> </ul>	<ul style="list-style-type: none"> <li>-Allows resolution of any infection</li> <li>-Allows soft tissue healing to cover socket</li> <li>-May allow early healing of bone (woven bone)</li> </ul>	<ul style="list-style-type: none"> <li>-As for early placement, but allows more fill of socket with woven bone to provide initial implant stability in large socket</li> <li>-High predictability</li> </ul>
Disadvantages	<ul style="list-style-type: none"> <li>-Contraindicated if overt infection is present</li> <li>-Caution required if extraction sufficiently traumatic to complicate healing process</li> <li>-Immediate restoration/loading may suffer higher failure rate</li> </ul>	<ul style="list-style-type: none"> <li>-Additional surgical procedure required</li> <li>-May be insufficient bone to achieve primary stability of the implant</li> </ul>	<ul style="list-style-type: none"> <li>-May be loss of thin labial plate in resorptive process</li> <li>-Protracted treatment schedule</li> </ul>

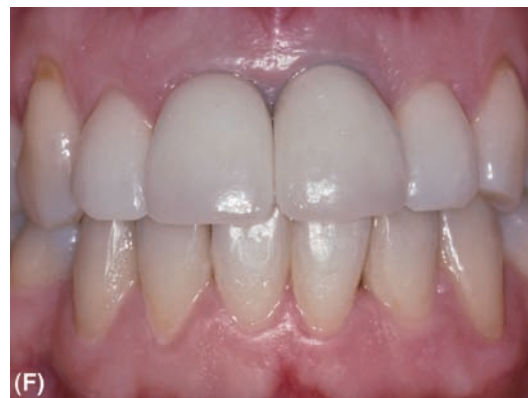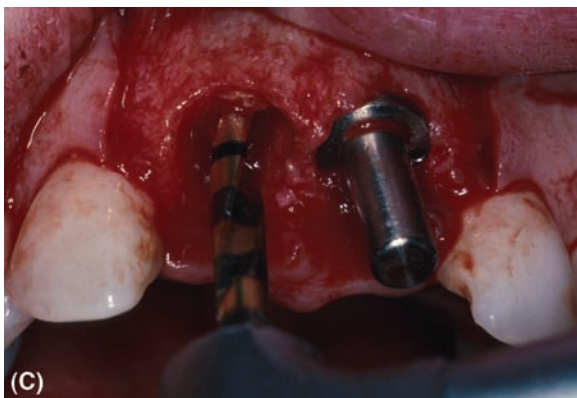
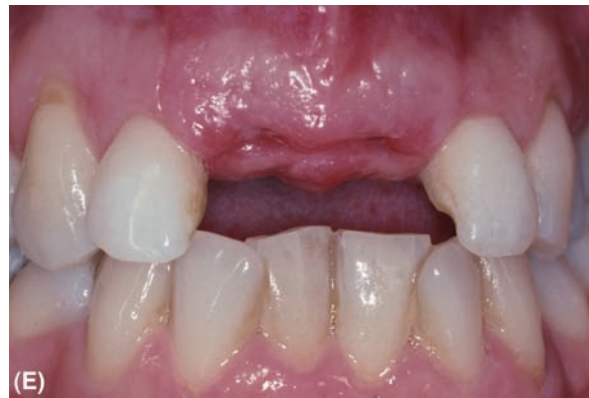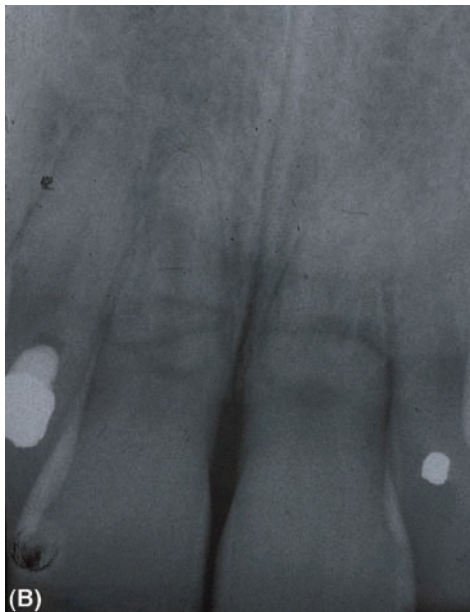
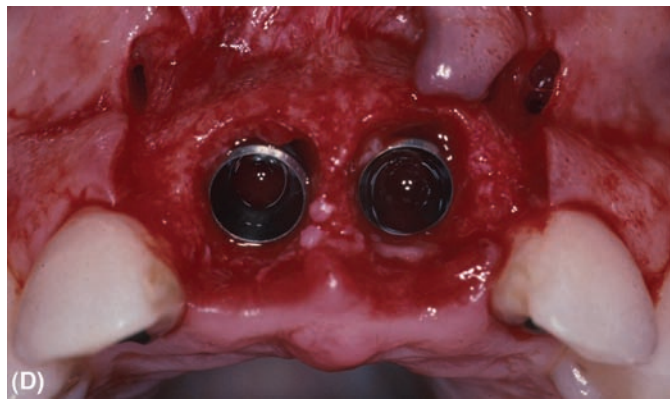


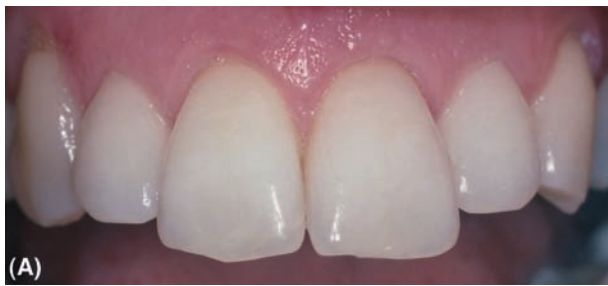**Figure 11.1** (A) The central incisor root is longer and wider than the lateral incisor. The distance between the apex of the root and the floor of the nose varies considerably. The bone apical to the root may be important to secure initial stability of the implant. (B) A standard 4-mm-diameter implant of the same length as the central incisor root may only just attain stability in the apical portion. A longer implant could be used. (C) A longer 4-mm-diameter implant has been placed more apically in a site prepared apical to the apex of the socket close to the floor of the nose. The apical bone provides good stability for the implant. There is a reduction in the space between the implant and the socket walls. The alternative strategies are illustrated in Figures 11.6 and 11.7.

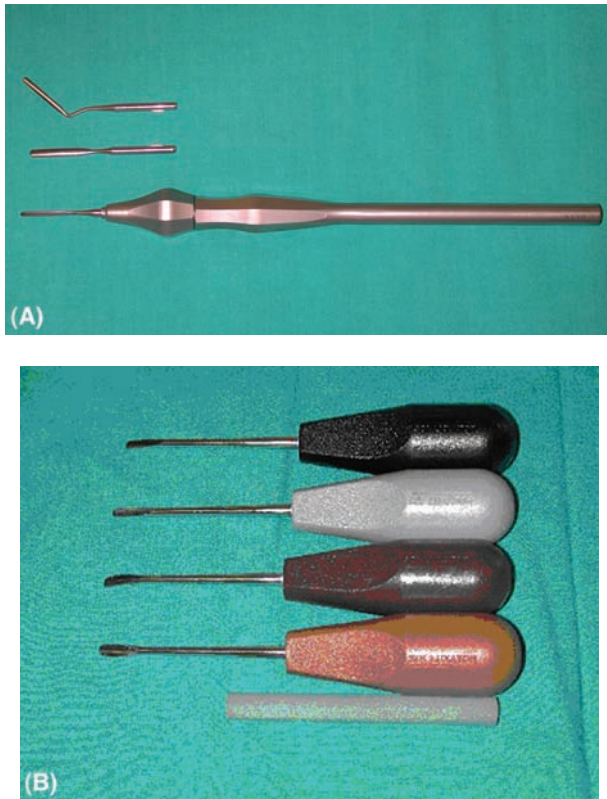
It is essential to carry out the tooth/root extraction atraumatically to preserve as much of the socket profile as possible and to prevent the following:

1. Fracture of the socket walls
2. Loss of the labial or palatal plates of bone
3. Excessive trauma to the socket wall that could lead to necrosis of bone or a localized osteitis

In most cases, it is recommended to use gradual and careful loosening and elevation of the roots with specifically designed periostomes and luxators (Fig. 11.3A, B). Periostomes allow gradual dilatation of the coronal part of the socket and severance/rupture of the periodontal ligament fibers. The periostome should be worked circumferentially around the root, working gradually deeper until the tooth is displaced



**Figure 11.2** (A) A series of photographs showing immediate implant placement for replacement of maxillary central incisors with Astra Tech ST implants. Preoperative photograph showing aesthetic natural teeth. (B) Radiograph showing fractures of roots in the cervical third. (C) Flaps have been raised and the roots carefully elevated. The sites are being prepared within the sockets. A stent (not shown) has been used to check the position of the guide pin in the partially prepared site. (D) The Astra Tech ST implants have been placed. Stability is achieved by extending the implant length apical to the natural socket. There is only a small void on the labial aspect of the implants that will fill in with bone without recourse to grafting. (E) The area has healed very well two weeks after surgery. There is complete soft tissue coverage. The implants were left buried for six months. The abutment connection surgery for this case is illustrated in chapter 8 (Fig. 8.14). (F) The completed result two years after crown cementation on preable abutments.



**Figure 11.3** (A) A Periotome® (Friedrichsfeld GmbH, Mannheim, Germany) with different ends to allow dilatation of the socket and atraumatic extraction. (B) A selection of luxators with sharpening stone. It is important to preserve a sharp edge on the instruments to facilitate insertion into the periodontal ligament space.

with little force. Failure to use the blade of the periotome with a rocking action along the long axis of the blade will cause bending or fracture of the blade, it is not possible to exert an elevatory force with the periotome, it is solely a severance/dilatation instrument. If a socket is dilated circumferentially close to the apex, a conical root can be eventually displaced coronally by the apical force of the periotome blade.

In some instances the forces that can be applied via the small periotome handle are insufficient and greater forces may then be applied using a luxator. Luxators have larger blades and handles and are therefore more efficient but can also cause more damage to the adjacent bone. They can also be used with a rocking action like the periotome but can also be rotated around their long axis to dilate the socket further. A combination of alternate apical instrumentation with the periotome followed by coronal action of an appropriate luxator can expand the socket very efficiently. Once an appropriate level of dilatation has been achieved, final delivery with appropriate forceps can be achieved.

Careful forceps extraction without prior use of dilators is also permissible, particularly if small rotational movements are used and leverage against the labial and palatal plates of bone can be avoided. This is, however, largely restricted to roots that have a circular cross-sectional profile. In some cases, exposure of the alveolus through flap elevation is necessary and this allows

inspection of the bone and effect of the transmitted forces upon it. Surgical bone removal should be kept to a minimum and performed with copious irrigation if burs are used.

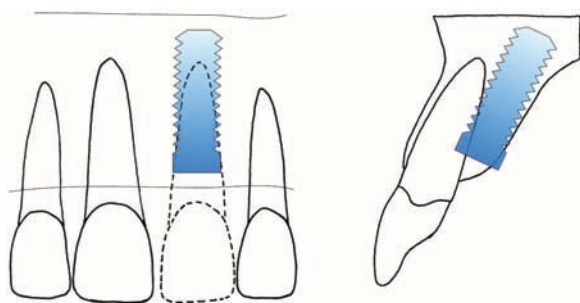
Fracture of the root leaving a small apex should not precipitate the use of excessive bone removal to affect removal. In cases where there is sufficient bone apical to the fragment (usually a prerequisite in immediate placement/loading scenarios), consideration may be given to removing the apex with the implant drills as part of the implant placement procedure. Alternatively, if the labial plate is thin over the apex of the root, a small fenestration can be prepared in the bone overlying the apex through which it can be delivered. In some cases longitudinal division of the root with a bur is required with elevation of the root fragments into the space created. It should be noted that the more complex the extraction becomes, the more consideration should be given to delaying implant placement.

Following successful removal of the root, any inflammatory/granulation tissue should be curetted from the socket and any inflamed periodontal pocket tissue excised. Removal of residual periodontal ligament fibers by curetting the socket walls has also been previously advocated, but there is little evidence to support this protocol. Implant placement should be postponed if any doubts exist regarding the likelihood of persistent infection or possibility of osteitis due to traumatic removal of the tooth root. Under these circumstances and in planned early-placement protocols, the soft tissue should be closed as much as possible with sutures. Placement of various graft materials into sockets to promote bone fill has been widely described but has not been the subject of vigorous appraisal. It is the authors' opinion that such sites are best left to heal naturally and then measures used to make up for any deficiencies in healing subsequently. Soft tissue closure can be facilitated by flap advancement following releasing incisions and incision of the periosteal surface of the flap. Antibiotics should be given where appropriate, particularly where an implant is placed immediately into the socket.

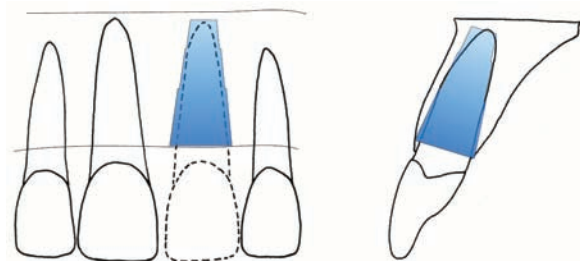
## IMPLANT PLACEMENT

It is important to prepare the site for insertion of an implant that achieves high primary stability. The insertion torque should be at least 10 Ncm for an implant where restoration is delayed, but should be at least 30 Ncm for immediate and early loading/restoration protocols. The primary stability can also be measured using resonance frequency analysis where an implant stability quotient (ISQ) of over 60 is recommended. Preparation of implant sites within extraction sockets may not be as easy as it first appears. In immediate placement, the socket will have been gently curetted to remove any residual soft tissue. With the early-placement protocol, the soft tissue is elevated to allow reinspection of the socket and removal of any ingrowth of soft tissue. Any woven bone should be left undisturbed. The surgical preparation (with drills matched to the system being utilized) more or less follows the angulation of the socket, provided the tooth was in a satisfactory position and an implant angle through the incisal tip or labial to it is acceptable (Figs. 11.1 and 11.2C). However, in some cases involving the maxillary anterior teeth, the bone on the palatal aspect of the socket is the best to provide a good site preparation to secure implant stability (Fig. 11.4).

It may also provide more palatal angulation of the implant to facilitate screw retention of the prosthesis if this is desirable. It is helpful if the initial preparation of the site is started with a round bur, which readily penetrates the socket wall. Drilling into an angled surface within a socket is more



**Figure 11.4** At times the most suitable bone to secure stability of the implant is on the palatal aspect of the socket, especially where the labial plate is very thin or has been lost. However, the implant will be palatally placed and aesthetics may be compromised. A thin labial plate may be compressed to reduce the volume of the residual socket.

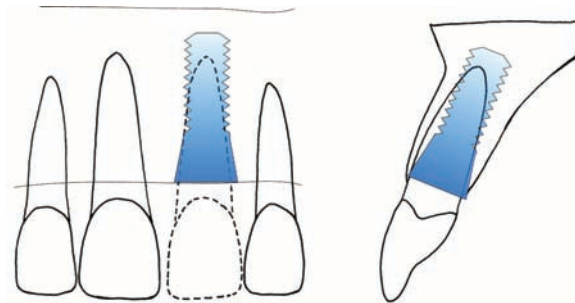


**Figure 11.5** A stepped cylinder implant, Frialit 2, developed for immediate replacement has a wide enough diameter and length to almost obliterate the socket. This implant also has a series of threads to help stability in the immediate replacement situation.

difficult than into a relatively flat crestal platform of bone. A standard sequence of drills follows the round bur and the angulation of the site is checked against a guide stent and opposing teeth. It is usually more difficult to check the angulation with standard indicators present in most surgical kits because they are too short and unstable within the socket. The angulation can always be checked with a twist drill removed from the handpiece (but with precautions taken to make sure the drill cannot be swallowed/inhaled). In most cases it is essential to prepare the site apical to the natural socket to ensure implant stability and predictable osseointegration into mature bone (Fig. 11.1C). In situations where there is little or no bone available apical to the socket, a wider-diameter implant has to be selected (Fig. 11.5) or the procedure delayed to allow adequate bone healing of the socket. The level of the implant head is usually placed just within the socket or slightly apical, according to the aesthetic requirements. A more apically placed implant head often reduces the size of gap between implant surface and socket wall (Fig. 11.6), but there is a limit to this compensatory strategy.

## IMPLANT SELECTION

It is very helpful to overlay the radiograph with transparent outlines of the implant design to be considered in the various



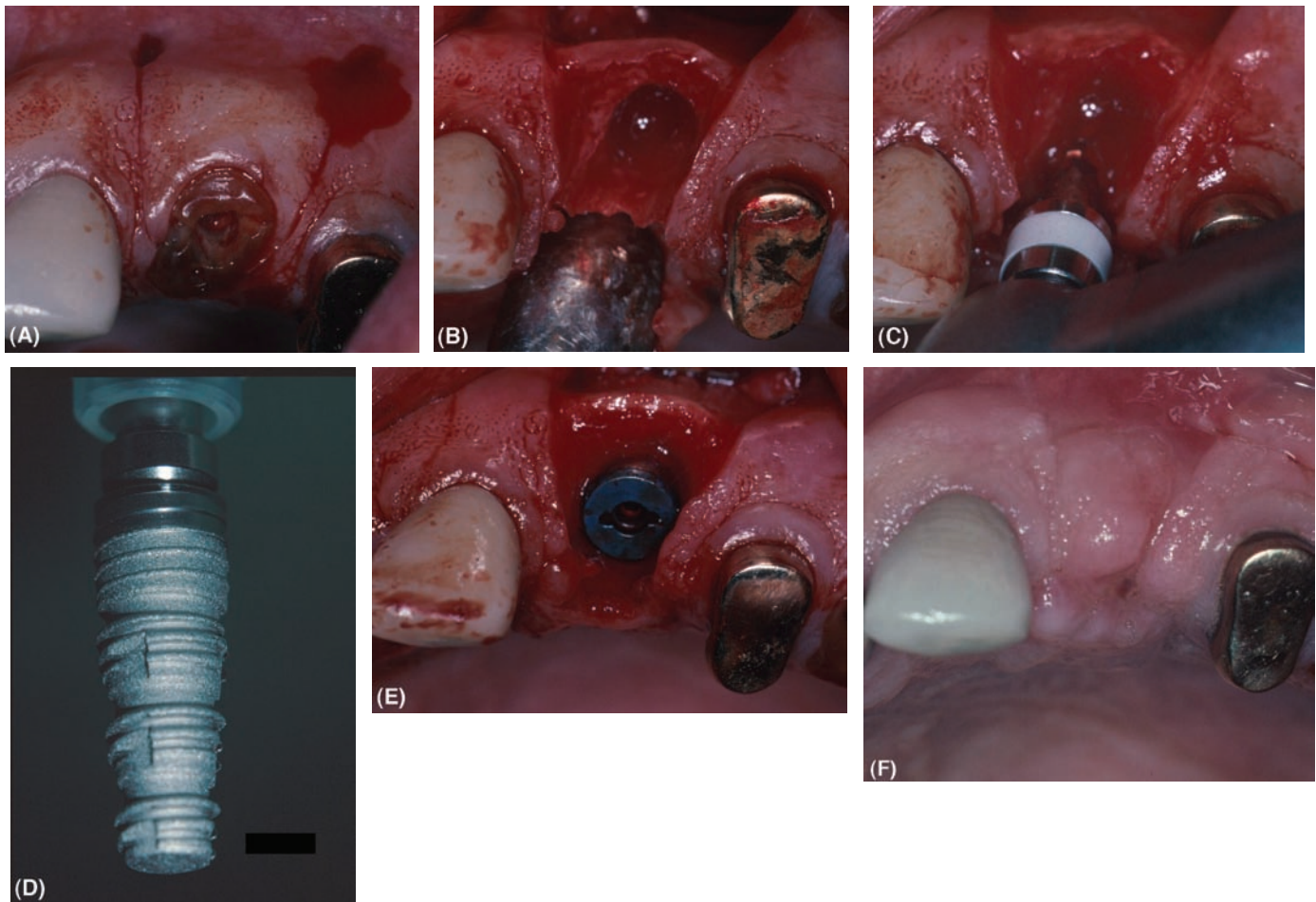
**Figure 11.6** An Astra Tech ST implant has an apical threaded portion that can be used to engage bone apical to the socket and provide good stability. The conical microthreaded collar is wider at the top (4.5 or 5 mm) and reduces the dead space.

lengths and diameters available. Ideally the implant should be slightly bigger than the root it is replacing to ensure a good fit in the prepared site within the socket and hence a high degree of primary stability. This is one of the claimed advantages of a system specifically designed for this purpose, such as Frialit. The Frialit 2 has a stepped cylinder design of various diameters to more readily achieve these objectives (Fig. 11.5). Another implant that is good in such situations is the Astra Tech single tooth (ST) implant (Fig. 11.6). These have a wider conical collar (4.5 mm and 5 mm diameters at the fixture head) than the apical portion (3.2 mm and 3.7 mm, respectively), giving a good fit in most anterior tooth sockets. The apical threaded portion gives good initial stability, especially if it can be extended into bone apical to the socket. This latter feature is the main way of achieving good stability with parallel sided, screw-threaded implants. Ideally there should be 4 to 5 mm of sound bone apical to the socket to prepare and engage with the implant. There is often a gap between the coronal part of the socket and the implant surface, normally on the buccal aspect (Fig. 11.2D). The size of the gap is critical. A gap of 1 mm up to 2 mm should fill with bone and osseointegration should occur. Where the gap is larger this may be grafted, preferably using autogenous bone collected from the site preparation or an adjacent area of suitable donor bone. In addition it is often possible to reduce the size of the gap by compressing the walls of the socket by finger pressure or gentle fracturing of the thin coronal walls of the socket with a suitable instrument. Implants designed with a wider coronal portion should help to minimize the gap. However, care must still be taken to avoid placing an implant too close to an adjacent natural tooth.

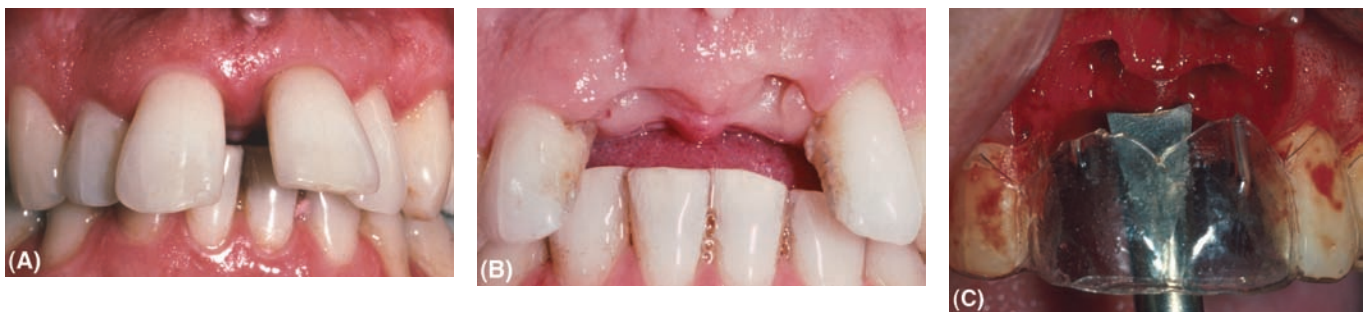Most of the foregoing discussion is mainly applicable to placement into anterior single root socket and is not usually possible with molar sites. The sequence of implant placement in anterior extraction sockets is shown in Figures 11.2, 11.7, and 11.8, which illustrates some of the points mentioned above.

## IMMEDIATE AND EARLY RESTORATION/LOADING

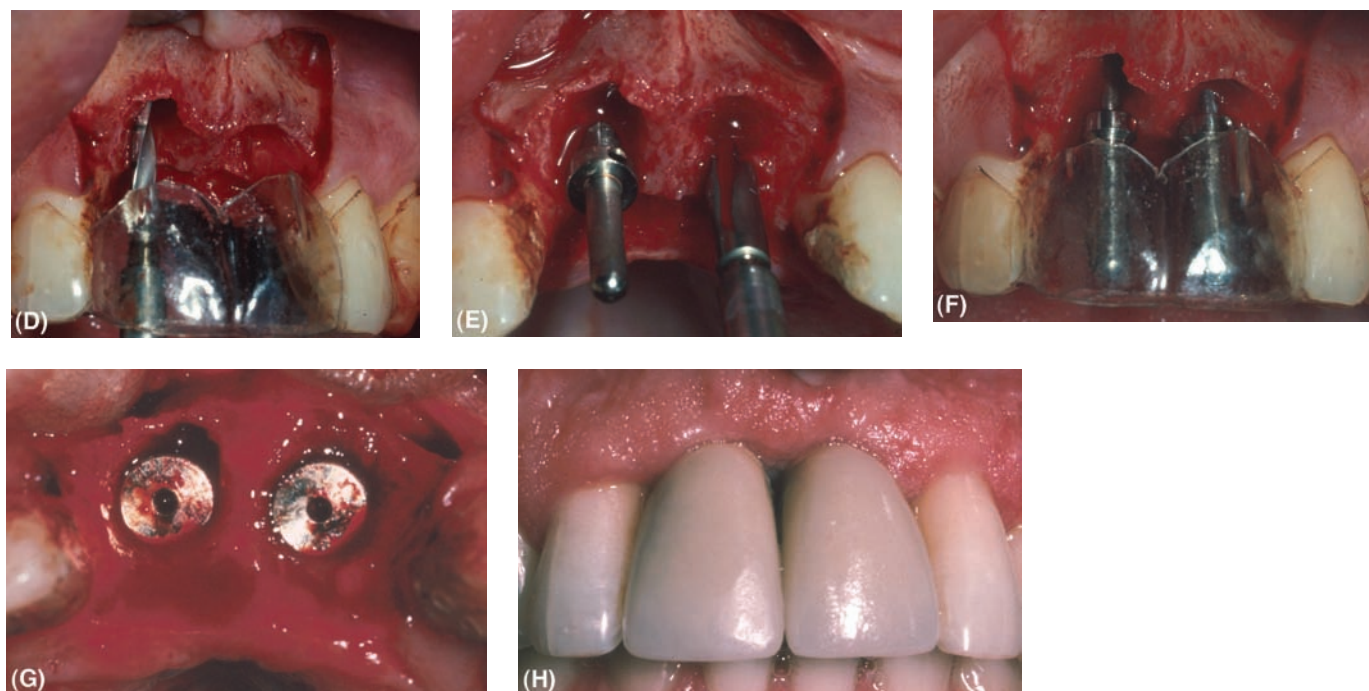
Following immediate and early implant placement protocols, there has been further developments in immediate restoration and loading, protocols that also apply to implants that have been placed at healed sites. It should be reemphasized that



**Figure 11.7** (A) A series of photographs showing immediate replacement of a maxillary canine in a patient with dentinogenesis imperfecta, using the Frialit 2 system. The crown of the maxillary canine has fractured and worn after many years with a conventional restoration. The flap design is evident. (B) The root has been carefully elevated. (C) The initial preparation of the socket with the twist drill. The length of the preparation is established and then increasing widths of stepped drills are used according to the final diameter of the implant that can be accommodated at this site. (D) The chosen implant, a 4.5-mm-diameter threaded stepped cylinder (Frialit 2). This design achieves very good stability by preparing the lateral walls of the socket and is aided by the threads. (E) The implant completely fills the prepared site without any voids. (F) The healed soft tissue showing complete closure at two weeks postsurgery.



**Figure 11.8** (A) A series of photographs showing early placement of two Branemark implants to replace the maxillary central incisors. The maxillary central incisors have drifted and are very mobile due to extensive root resorption. (B) Four weeks following extraction of the incisors, soft tissue healing of the sockets is good. The patient has been wearing a Rochette provisional bridge, which has been removed to allow installation of the implants. (C) Buccal and palatal flaps have been raised and residual soft tissue has been removed from the sockets. A plastic stent, based on a diagnostic setup and provisional Rochette, is stabilized on the adjacent teeth. The measuring indicator, held palatally, has a width of 7 mm (corresponding to the recommended center-to-center distance between two Branemark 3.75-mm implants). (D) A 2-mm twist drill is used to prepare the initial implant angulation. (E) A guide pin is placed in the right central incisor socket and the left site is being enlarged from 2 to 3 mm in diameter. (F) The guide pins show the position and angle of the prepared sites within the sockets in relation to the stent. (G) The implants have been placed and the cover screws connected. The implants are toward the palatal aspect of the sockets. The small voids labially were grafted with osseous coagulum collected from the drilling process. (H) The completed result showing the two single tooth implants in an acceptable aesthetic position.

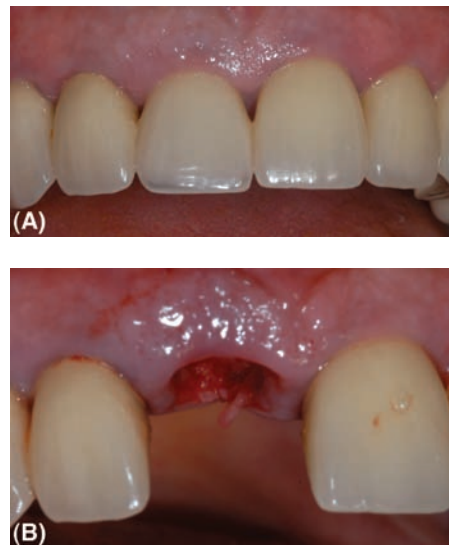


**Figure 11.8** (Continued)

successful osseointegration does require a period of healing during which movement is avoided. Very small degrees of movement, micromovement less than 100  $\mu\text{m}$ , may be compatible with successful osseointegration. The definitions of the various loading protocols vary. Immediate loading/restoration is where the prosthesis is fitted within one week of implant placement. This often depends on the logistics of how rapidly the prosthesis can be fabricated, which in many cases is on the same day as implant placement. Early loading has been defined between one week and two months. Following placement of the implant, the early healing events result in some bone resorption that may reduce the primary stability of the implant at two to three weeks postsurgery. This would therefore be the most critical period where the implant is vulnerable to loading. Bone deposition at four to six weeks should improve the implant stability (secondary stability), and this osseointegration can occur rapidly with implant surfaces that are moderately rough (see chap. 1). Therefore, regardless of the definition an implant that is restored/loaded within the first three to four weeks may be more vulnerable to loading, and this is especially the case with implants that have been placed into extraction sockets.

Single tooth implants can be restored with a provisional prosthesis with no occlusal contacts but could still be subjected to functional forces by the patient. In all cases the patient is strongly advised to minimize functional forces through the prosthesis. The immediate extraction, implant placement, and restoration protocol for a single tooth is illustrated in Figure 11.9. Full-arch and extensive prostheses will inevitably be subjected to loading but splinting together of several implants can at least distribute the forces and reduce them on individual implants (see chap. 14).

The immediate protocol should achieve very good aesthetics, and claims have been made for preservation of



**Figure 11.9** (A) Preoperative view of crowned anterior maxillary teeth. (B) Clinical fracture of the crown of the upper right central incisor. (C) Radiograph of retained root. (D) Following extraction of the root, the site was prepared and an Astra Tech 4.5-mm-diameter implant placed—no flap reflection was performed. (E) An impression coping has been attached to the implant to record the position of the implant so that a laboratory prepared provisional crown can be made. (F) A healing abutment is connected to the implant while the crown is being made. (G) The screw-retained one-piece provisional crown on the laboratory cast. (H) The provisional crown fitted within 24 hours. (I) A permanent abutment fitted after three months of healing. (J) The permanent crown cemented to the abutment. (K) The radiograph of the completed case.

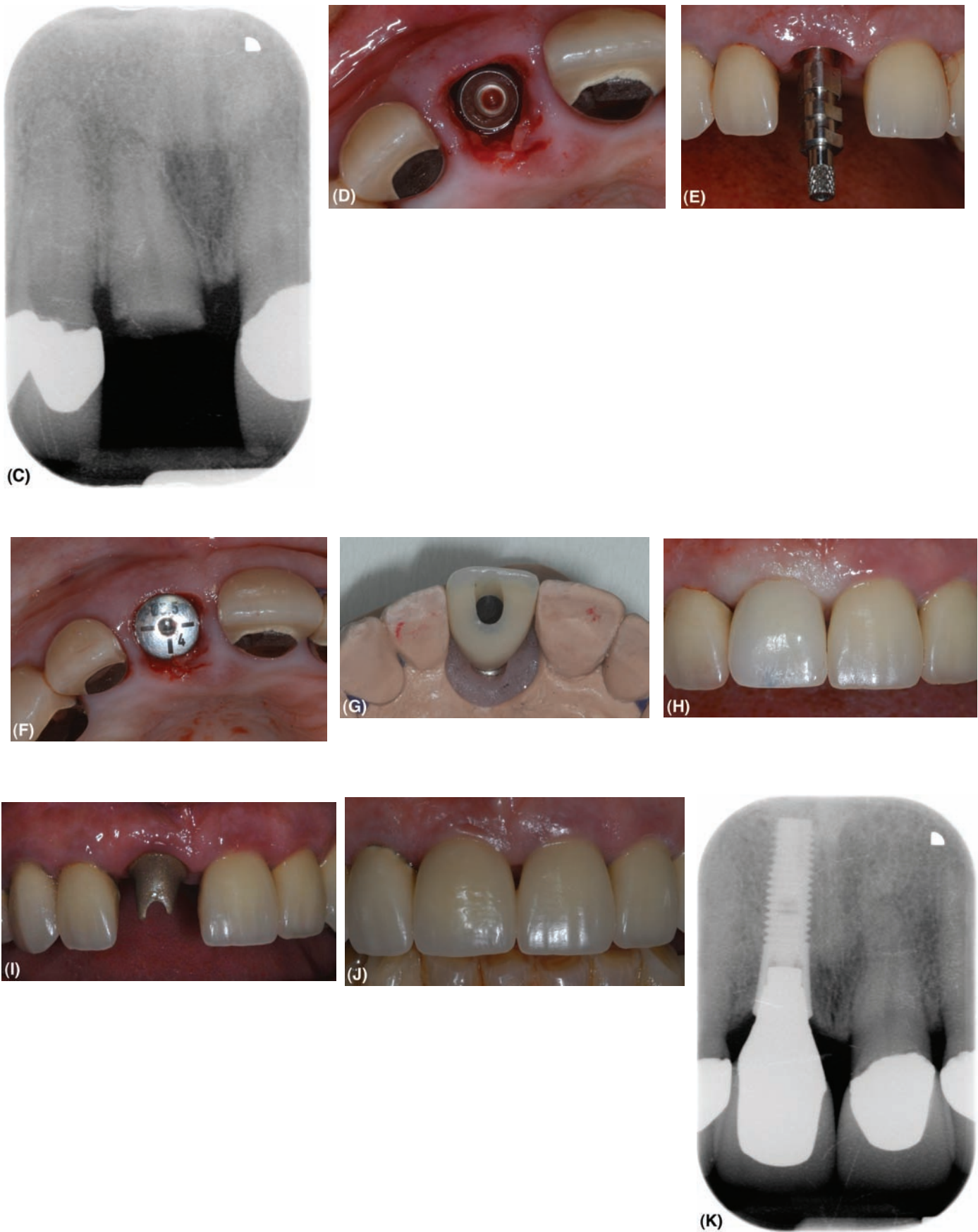

Figure 11.9 (Continued)

superior soft tissue profiles using these protocols. This has never been tested with a properly controlled trial. It is important to appreciate that the protocol aims to preserve soft tissue aesthetics rather than correct them. It is easier in many cases to improve the appearance of the crown of the tooth. In most cases the implant is restored with a provisional restoration (Fig. 11.9G, H) and a permanent restoration provided after several months when soft tissue maturation and osseointegration have occurred (Fig. 11.9K). Screw-retained provisional restorations tend to make the process easier. In all cases the costs of treatment are likely to be higher than conventional protocols as they involve more laboratory procedures or more clinical time.

## CONCLUSIONS

Immediate and early implant placement protocols can offer highly predictable results, which in clinical trials have been shown to be comparable to traditional protocols. Immediate and early loading protocols may present higher risk of failure, especially in the hands of less experienced clinicians. Many patients seek implant treatment for the benefit of a predictable, long-lasting restoration and are quite prepared to undergo a more protracted treatment schedule. Therefore, immediate protocols should be used where there is a good clinical or patient-centered indication.

If one is to adopt these protocols, the following simple guidance should help reduce complications and failure:

1. Avoid using these protocols in patients who have compromised healing, for example, smokers and poorly controlled diabetics.
2. Do not treat patients with bruxism or other parafunctional activities.
3. Avoid in high force situations such as single molar replacements.
4. Use provisional restorations that are kept free of the occlusion as far as possible, especially in protrusive and lateral guidance.
5. Make sure that the placed implant has a high primary stability, for example, over 30 Ncm torque value on insertion.
6. Use on patients with proven compliance and who are likely to follow simple rules and minimize functional forces on the restoration.
7. Make sure the patient is fully aware of the risks and consents to the procedure.
8. Do not use in areas of inadequate/poor bone or where grafting is indicated.

9. Only employ these protocols when you have demonstrated high success rates with conventional protocols.
10. Be prepared to abandon the immediate protocol and adopt a more conventional/safer one.

## BIBLIOGRAPHY

- Botticelli D, Renzi A, Lindhe J, et al. Implants in fresh extraction sockets: a prospective 5-year follow-up clinical study. *Clin Oral Implants Res* 2008; 19:1226–1232.
- Collaert B, de Bruyn H. Immediate functional loading of TiOblast dental implants in full-arch edentulous maxillae: a 3-year prospective study. *Clin Oral Implants Res* 2008; 19:1254–1260.
- Cosyn J, de Rouck T. Aesthetic outcome of single-tooth implant restorations following early implant placement and guided bone regeneration: crown and soft tissue dimensions compared with contralateral teeth. *Clin Oral Implants Res* 2009; 20:1063–1069.
- de Bruyn H, van de Velde T, Collaert B. Immediate functional loading of TiOblast dental implants in full-arch edentulous mandibles: a 3-year prospective study. *Clin Oral Implants Res* 2008; 19:717–723.
- Degidi M, Nardi D, Piattelli A. A comparison between immediate loading and immediate restoration in cases of partial posterior mandibular edentulism: a 3-year randomized clinical trial. *Clin Oral Implants Res* 2010; 21:682–687.
- Donati M, La Scala V, Billi M, et al. Immediate functional loading of implants in single tooth replacement: a prospective clinical multicenter study. *Clin Oral Implants Res* 2008; 19:740–748.
- Esposito M, Grusovin MG, Willings M, et al. Interventions for replacing missing teeth: different times for loading dental implants. *Cochrane Database Syst Rev* 2009; (1):CD003878.
- Esposito MA, Koukouloupoulou A, Coulthard P, et al. Interventions for replacing missing teeth: dental implants in fresh extraction sockets (immediate, immediate-delayed and delayed implants). *Cochrane Database Syst Rev* 2010; (9):CD005968.
- Galli F, Capelli M, Zuffetti F, et al. Immediate non-occlusal vs. early loading of dental implants in partially edentulous patients: a multicentre randomized clinical trial. Peri-implant bone and soft-tissue levels. *Clin Oral Implants Res* 2008; 19:546–552.
- Glauser R, Sennerby L, Meredith N, et al. Resonance frequency analysis of implants subjected to immediate or early functional occlusal loading. Successful vs. failing implants. *Clin Oral Implants Res* 2004; 15:428–434.
- Gomez-Roman G, Schulte W, d'Hoedt B, et al. The Frialit-2 implant system: five-year clinical experience in single tooth and immediately postextraction applications. *Int J Oral Maxillofac Implants* 1997; 12:299–309.
- Heggeler JM, Slot DE, van der Weijden GA. Effect of socket preservation therapies following tooth extraction in non-molar regions in humans: a systematic review. *Clin Oral Implants Res* 2011 (in press).
- Jokstad A, Ellner S, Gussgard A. Comparison of two early loading protocols in full arch reconstructions in the edentulous maxilla using the Cresco prosthetic system: a three-arm parallel group randomized-controlled trial. *Clin Oral Implants Res* 2011; 22:455–463.

## Grafting procedures for implant placement

### INTRODUCTION

The overriding requirement for successful implant placement is to have enough bone volume of sufficient density to enable an implant of the appropriate size to be placed in a desirable position and orientation. Many of the grafting procedures described in this chapter have been developed as localized procedures to overcome small anatomical limitations. There is also occasionally a need to employ more complex techniques to change the entire alveolar ridge form that may additionally involve an associated change in skeletal base.

Besides the obvious osseous component to this problem, there are also many situations where the soft tissue in the area of proposed implant placement is deficient. The soft tissues play a vital role in maintaining the long-term health of the peri-implant environment, and also contribute greatly to the resulting aesthetics, particularly in the anterior region. The peri-implant soft tissues must be able to maintain their structural integrity during normal function and oral hygiene procedures.

Grafts may therefore be employed to

- enable implant placement;
- enhance aesthetics and improve soft tissues;
- change the preexisting jaw relationship.

The initial planning stages as described in previous chapters take on even greater levels of importance in potential graft cases. By their very nature they are more difficult to plan and execute and the end result may fall short of both the clinician's and the patient's expectations. It is important that all alternatives are considered and presented to the patients so that they can make an informed decision with regard to their treatment. In particular, it is important to consider whether a compromise solution using prosthetic techniques may be more desirable and achievable as well as more predictable in the long term. Another alternative is to consider whether the utilization of the various implant designs available may overcome the problem.

### BONE GRAFT MATERIALS

The degree of bone grafting required for implant placement varies from localized deficiencies to cases where there is a need to change the entire arch form and/or jaw relationship. There exist, therefore, a great many techniques and materials available to facilitate such grafting procedures, many of which may be used in combination. The interaction between the graft and the surrounding host bone is very important and is the subject of much research. Although some grafts will act merely as space fillers, the ideal graft will be osseointegrative and osseointegrative. Osseointegration is the property of promoting bone growth from the surrounding host bone onto the surface of the graft material, using the graft as a framework. The graft material in such cases may be resorbed or remain virtually intact, depending on the material used. Osseointegration is the

ability to promote de novo bone formation remote from the host bone even within noncalcified tissues. Bone morphogenetic proteins and other bone-promoting factors have this latter property and are used increasingly in an effort to optimize the effects of bone augmentation materials.

### Autogenous Bone Grafts

The ready availability of autogenous bone has always meant that it is the first choice of bone grafting material for many clinicians. However, patient acceptance of autogenous bone harvesting may be low, given the potential morbidity associated with such techniques. Although a great amount of research and clinical time has been spent over many years to develop substitutes for autogenous bone, it remains the gold standard by which all other materials are judged and remains the material of choice for the present authors. Its main advantages are as follows:

- Availability
- Sterility
- Biocompatibility
- Osseointegrative potential
- Osseointegrative potential
- Ease of use

The main disadvantages are as follows:

- Limited volumes available particularly intraorally
- Access to good donor sites
- Postoperative pain and other operative sequelae
- Potential damage to adjacent structures

The graft acts as a scaffold for the ingrowth of blood vessels and as a source of osteoprogenitor cells and bone-inducing molecules. The graft is eventually resorbed as part of the normal turnover of bone.

### Other Graft Materials

Although the gold standard for bone grafting remains the patient's own bone, the limitations on the amounts available (particularly from sites other than the iliac crest) and the morbidity associated with harvesting techniques mean that there remains a great demand for alternative graft materials. Xenografts are derived from another species, allografts (allografts) from a member of the same species, and alloplasts are synthetic materials.

The macro- and microstructure of these grafts have an enormous influence on their efficacy. The pore diameter and volume in particular are considered to be important. The ideal characteristics of a bone graft material have been described (Hammerle, 1999) as follows:

1. Sterile
2. Nontoxic

3. Nonimmunogenic
4. Osteoconductive or osteoinductive
5. Favorable clinical handling
6. Resorption and replacement by host bone
7. Synthetic
8. Available in sufficient quantities
9. Low in cost

### Allogenic Grafts

Bone derived from cadavers has been widely used in orthopedics and implant dentistry as well as periodontics. The graft may be freeze-dried or decalcified freeze-dried bone allograft (DFDBA), both of which are thought to be a good source of bone morphogenetic protein. It is harvested from donors with well-documented medical histories and tested for all the common infective antigens and is considered to be a safe source of grafting material. The grafts are produced as particulates with a reasonably uniform grain size or as sheets and large blocks. They are osseointegrative, providing a framework for new bone growth, and should be resorbed as part of the normal turnover of bone but some particles appear to remain intact for some time after the graft has been placed. The ability of DFDBA to induce new bone formation (i.e., osteoinductive) has been the subject of a great amount of research with conflicting results. This is thought to be due partly to the differences in the way humans react to graft materials as opposed to animal models, as well as differences in the source and processing of the DFDBA grafts.

Demineralized laminar bone sheets are available in varying thicknesses of 20 to 700  $\mu\text{m}$ , and those between 100 and 300  $\mu\text{m}$  have similar physical properties to the original polytetrafluoroethylene (PTFE) membrane, Gore-Tex<sup>TM</sup> (W.L. Gore & Associates, Flagstaff, Arizona, U.S.), allowing them to be used as membranes for guided bone regeneration (GBR) procedures.

Despite the rigorous testing of the donors, there remains the possibility of some cross-infection from the graft, and the development of other sources of graft materials is likely to reduce the demand for allografts in the future.

### Deproteinized Bovine Bone Mineral

Probably the mostly widely used and documented xenograft material is Bio-Oss<sup>®</sup> (Geistlich Pharma, Wolhusen, Switzerland), which is bovine sourced deproteinized bone. Deproteinized bovine bone mineral has similar properties to human cancellous bone, both in its macrostructure and its crystalline content. The physical properties are also close to that of the bone that it is used to replace. As a purely mineral graft it is osseointegrative and is thought to undergo some resorption, although this has been found to be limited. When used in a particulate form it is mixed with the patient's blood and packed into the defect. Some authors have described improved results when combining this with a membrane to protect the blood clot.

As deproteinized bovine bone is available in large quantities, it has been used in sinus lift procedures instead of autografting. The particles may also be used as a filler to increase the volume of autogenous graft material. In addition, the graft material is available as thin sheets of bone to cover and protect defects while retaining their shape as described above for allografts.

Bio-Oss used in combination with a collagen membrane bilayer of porcine origin has been well documented as a technique for augmenting single and multiple implant sites

in the aesthetic zone but has not been the subject of a randomized clinical trial comparing it to other techniques.

Bio-Oss Collagen is the latest version of this material combining bone mineral and collagen to produce a block of material that can be carved to shape or used as a particulate graft. The ease of manipulation and lack of patient morbidity makes this an attractive graft material for many clinicians.

The use of bovine and other animal-derived material, albeit in a purely mineral and nonantigenic form, may not be completely acceptable to some clinicians or indeed some patients.

### Alloplastic Graft Materials

Synthetically produced materials have the advantage of having no risk of cross-infection but may still give rise to an antigenic response. Their physical properties can be manipulated to a great degree and they may also be used in combination with bone-promoting molecules to enhance their effectiveness. They act as a framework for bone formation on their surface and are therefore osseointegrative. They include the following:

- Hydroxyapatite
- Calcium phosphate
- Tricalcium phosphate (TCP)
- Bioactive glasses

This is an ever-expanding field with new products introduced to the market on an almost daily basis. Although many can be used on their own, they are increasingly used in combination within the same product, sometimes with the addition of collagen to optimize the overall characteristics of the material. Several have been introduced, which are plastic at the time of placement and subsequently set to provide a solid graft that has the optimum shape and does not require covering with a membrane. Few, if any, of these products have been subject to randomized clinical trials comparing them with autogenous bone.

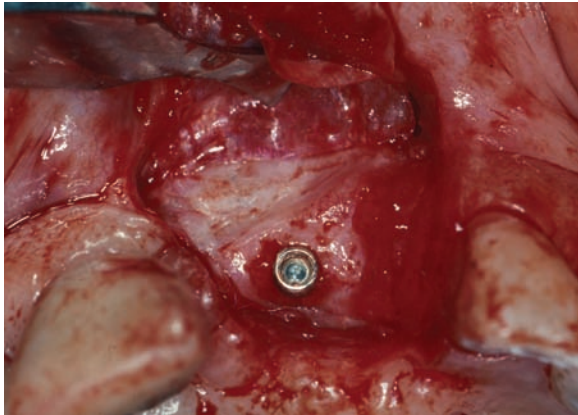
### GUIDED BONE REGENERATION

GBR membranes were originally developed to promote new tissue growth within a protected volumetric defect for periodontal attachment regeneration. The desire to promote new bone growth without resorting to grafting procedures led to widespread use of this technique in implant surgery. In implant dentistry, membranes are largely used in combination with particulate or block grafts to protect the graft material rather than creating a protected clot that regenerates as de novo bone. The main aim is to allow ingress of osteoprogenitor cells and promote bone formation within the defect. The original membranes were expanded PTFE. This is an occlusive membrane that prevents ingress of soft tissue cells into the regeneration site without unduly compromising the nutrient supply to the overlying tissues. It is a nonresorbable material and requires removal at second-stage surgery. The need for membrane removal and therefore a second surgical procedure led to the development of resorbable membranes made of synthetic polymers such as polylactate and polyglycolic acid, as well as collagen membranes. Resorbable materials should be functional for between three and six months after insertion. However, they may be resorbed or lose their shape too quickly and limit the amount of bone regeneration achieved.

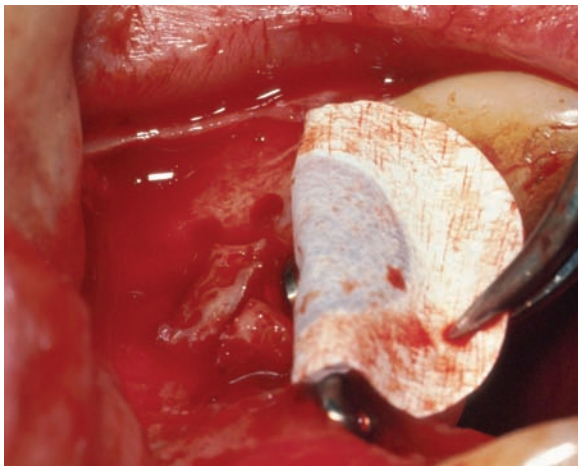
The creation and maintenance of a volumetric defect is critical and this may be improved by reinforcing PTFE

membranes with titanium strips. Further enhancement of the space-maintaining properties is achieved by the use of fixation pins and screws that serve to “tent” the membrane (Fig. 12.1). This can also be achieved by placing small bone chips within the defect, which will also act as osteoconductive/osteoinductive grafts (Fig. 12.2). The underlying cortical bone should be perforated with surgical burs to promote osteogenic cells to occupy the space created (Fig. 12.3). In cases where a significant change in topography is required, a titanium-reinforced membrane or a titanium mesh can also be used.

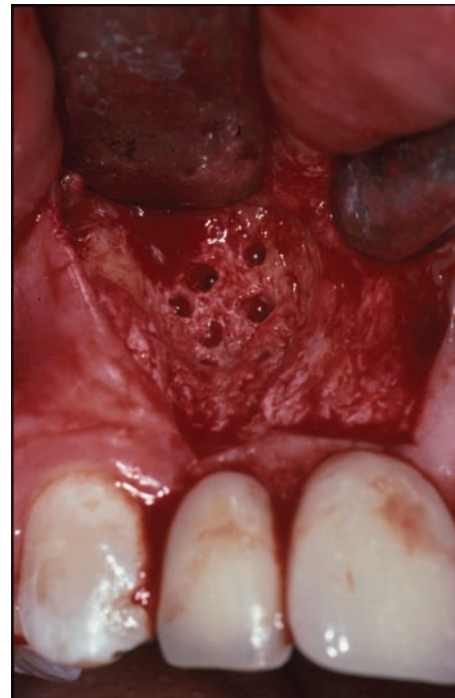GBR is also commonly used at the time of implant placement to repair small fenestrations and dehiscences



**Figure 12.1** The use of screws or pins may be advocated in the absence of autogenous bone to retain the shape of ridge and stabilize the membrane, thus optimizing healing. Here, a Memfix™ (Institute Straumann, Waldenburg, Switzerland) tenting screw has been placed in the middle of the defect to prevent the soft tissues from collapsing, therefore reducing the volume of bone created.



**Figure 12.2** Small bone chips have been placed under a PTFE membrane to maintain the volume of the graft site. The underlying cortical bone has been perforated with a small round surgical bur to encourage ingress of bone cells from the underlying cancellous bone. *Abbreviation:* PTFE, polytetrafluoroethylene.

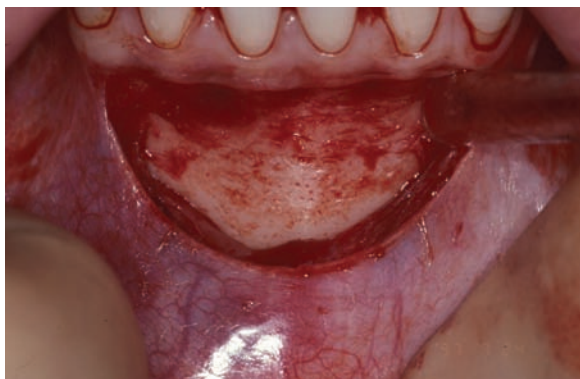

**Figure 12.3** Perforation of the host bed with surgical drills allows proliferation of bone cells and vascular tissue underneath the membrane and between the recipient site and the grafted bone material.

around implants (Figs. 12.20 and 12.21). It should be remembered that any such bone created using this technique will not function to stabilize the implant at the time of placement and that initial implant stability remains the overriding priority. The amount of new bone created can be quite substantial but the degree to which it becomes osseointegrated is variable. The amount of bone to implant contact of the newly generated bone is thought to change with time and loading. GBR is most predictable when attempting to increase the buccolingual dimension, but increasing the vertical dimension using this technique is very difficult and unpredictable. Although membranes are designed to allow the passage of nutrients, they nonetheless tend to compromise the blood supply to the overlying soft tissues. This can result in breakdown of the soft tissues, exposure of the membrane, and infection. This may result in a net loss of bone in the surgical area or failure of implants to osseointegrate. It is important that all incisions are kept as remote from the grafted area as possible and that the wound is sutured hermetically and without undue tension. Supporting the tissues with sutures that take large bites and “sling” the flaps can reduce tension at the wound edges.

### INTRAORAL HARVESTING AND GRAFTING OF AUTOGENOUS BONE

Autogenous bone grafts may be taken as trephine or block specimens both from intra- and extraoral sites. Fairly large grafts may be taken from the interforaminal region of the mandible under local anesthesia. Great care is required in order to avoid compromising the nerve/blood supply to the anterior teeth. Careful radiographic assessment of the region is important preoperatively in order to ascertain the amount of

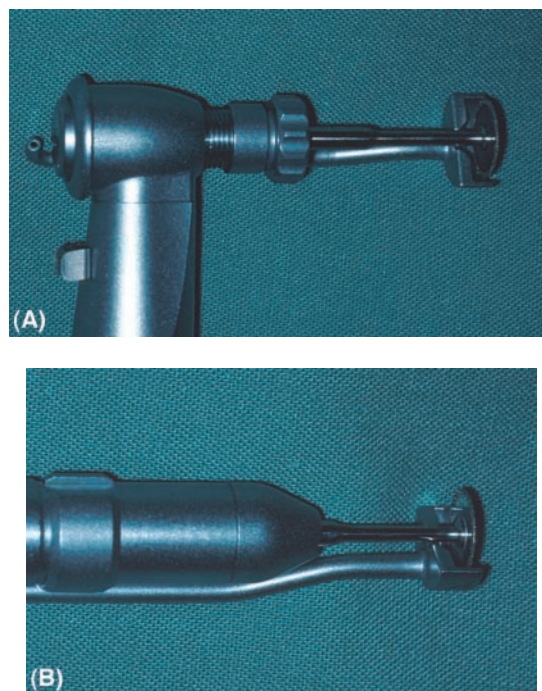


**Figure 12.4** By using a wide-based flap close to the mucogingival junction, a large portion of the anterior mandible may be exposed. Owing to the thick labial plate in this case, the roots of the lower teeth are not visible. Care must be taken to avoid compromising the vitality of the teeth.

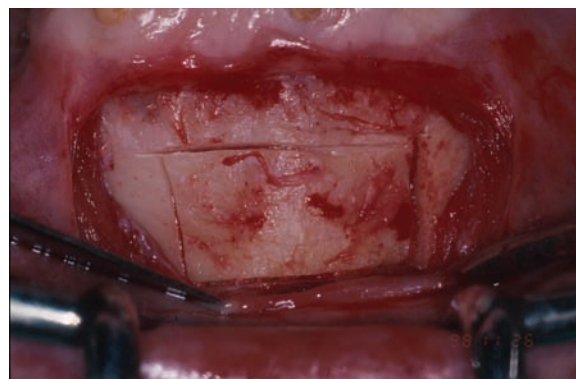
bone available. Once the mucoperiosteal flap has been raised via a sulcular incision to give wide exposure of the mandible, the graft can be outlined leaving at least 5 mm of clear bone below the apices of the incisor teeth (Fig. 12.4). Recent research has recommended a safety margin of 8 mm below the incisor apices and no more than 4 mm in depth to avoid compromising tooth vitality. The root contours and apices can often be visualized directly once the alveolus is exposed and careful reference to accurate radiographs is required. For harvesting blocks of bone, the surgeon has a number of choices:

1. Fissure burs
2. Oscillating saws
3. Rotating discs
4. Piezo surgery
5. Trephines

The use of standard oral surgery techniques utilizing fissure burs and a straight handpiece may be the technique of choice for many operators as they are more familiar with these instruments. The use of high-speed diamond discs in either straight or contra-angled handpieces when obtaining large bone blocks has the advantage of limiting the depth of cut to 2 to 3 mm as well as having excellent guards to prevent soft tissue trauma (Fig. 12.5). Piezosurgery has the advantage of ease of access with a variety of tips available to overcome access problems, potentially reducing patient morbidity. The relative difficulty of cutting dense bone with a piezosurgical unit may in turn limit its use in certain situations. Copious saline irrigation is required throughout any harvesting procedure and this is readily achieved with this technique. It is vital to cut completely through the labial cortex so that the graft can be cleaved from the underlying cancellous bone (Fig. 12.6). In some areas the initial cuts may have to be deepened using standard fissure pattern burs to the desired depth. Care is required to limit the cuts to within the body of the mandible because lingual perforation may lead to hemorrhage from the lingual soft tissues, which can be difficult to arrest. Once the outline cuts have been completed, the graft can be elevated using osteotomes or curved chisels specifically designed for that purpose. Attempting to elevate the block while the cortical bone is intact will cause fracture of the graft. Large blocks that



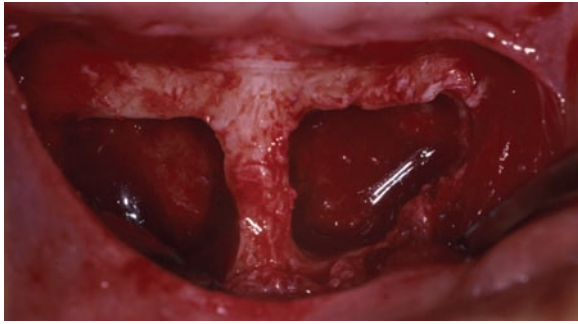
**Figure 12.5** (A, B) Contra-angled and straight handpieces for the use of diamond discs for bone grafting (FRIOS Microsaws, Friatec, Mannheim, Germany). Owing to the guards, these may be used in fairly confined spaces without traumatizing the adjacent soft tissues.



**Figure 12.6** Diamond discs cut very finely at a controlled depth, minimizing the chance of damage to adjacent structures. It is important to ensure that the cuts meet at each corner to allow elevation of the block. Bleeding from the depths of each cut indicates that the cuts are completely through the cortex and into the cancellous bone.

extend across the midline can prove difficult to elevate and may need to be divided and delivered in two pieces (Fig. 12.7).

Trephine specimens may also be harvested from the chin and there are many different sizes of trephine available for this purpose (Fig. 12.8D). Access to this region with fairly unwieldy handpieces and large trephines can make this a more difficult




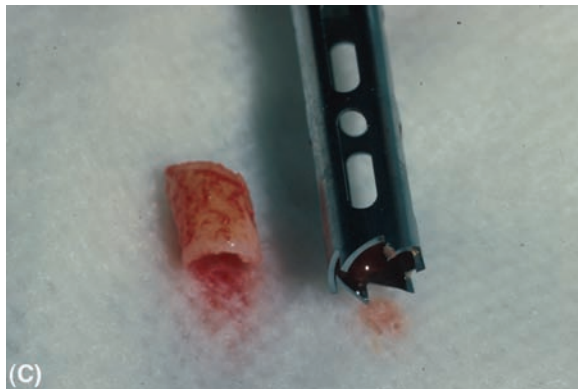
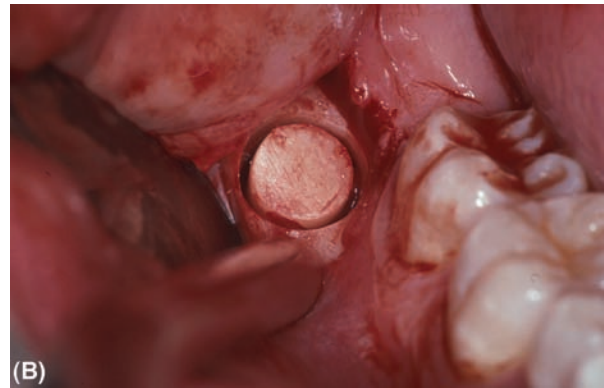
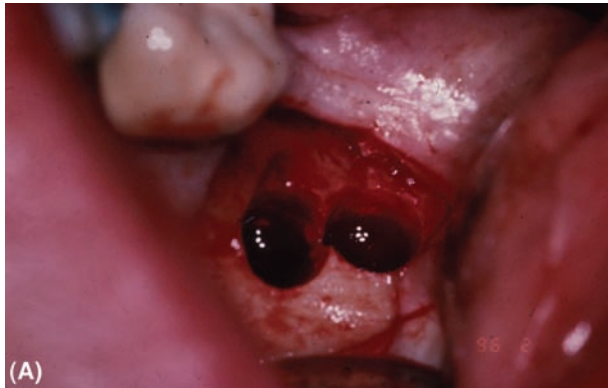
**Figure 12.7** In order to harvest a large graft from the anterior mandible, the blocks are taken in two pieces, reducing the force required to mobilize the blocks and minimizing the risk of fracturing them. Note the depth of the donor sites, which have been deepened by harvesting of the underlying cancellous bone.

procedure than taking blocks, unless extensive soft tissue reflection has been achieved. Once the corticocancellous block has been removed, further harvesting of cancellous chips can be undertaken from the graft bed as well as cortical

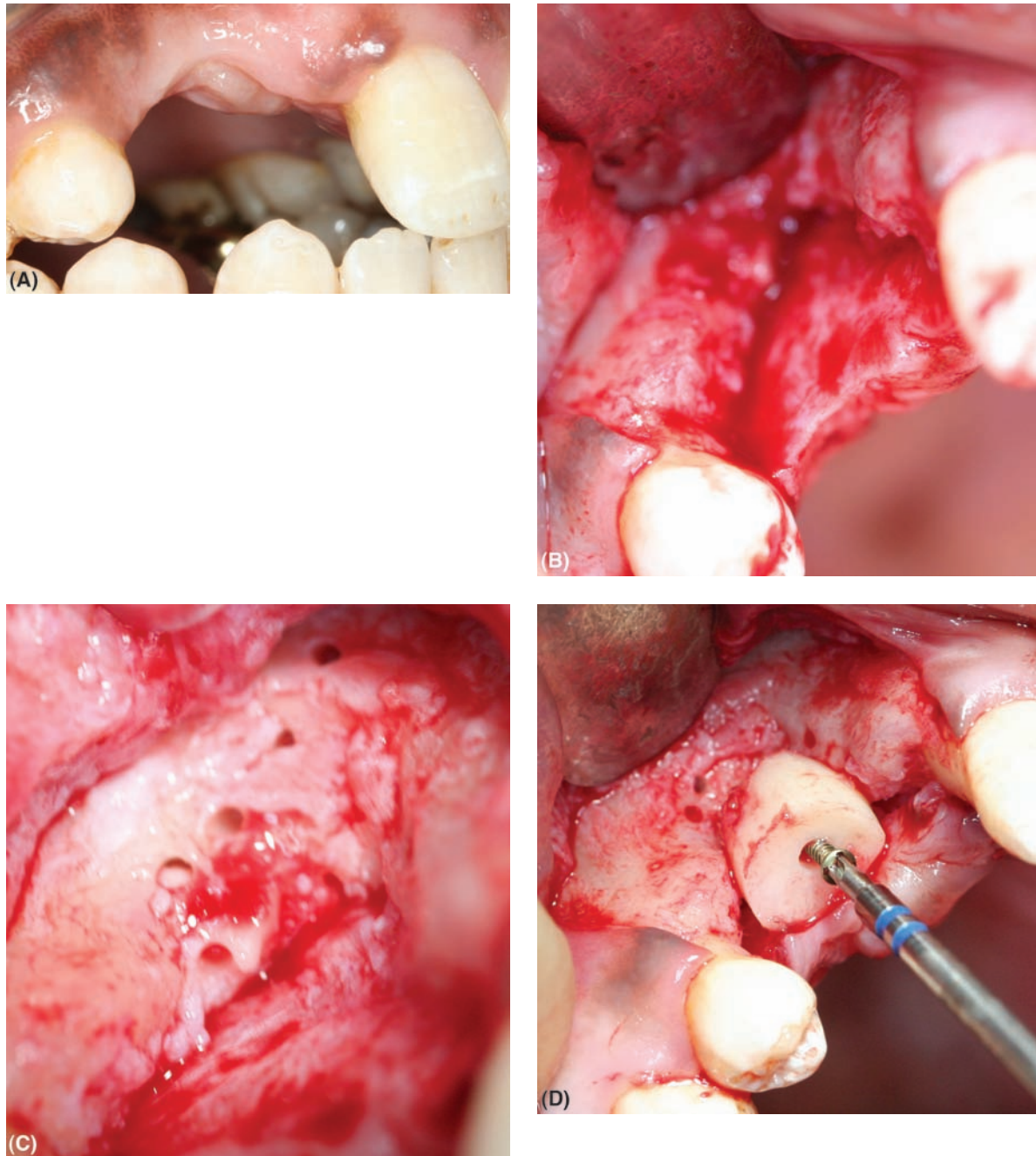
chips from the wound edge. Control of any bony hemorrhage is important before soft tissue closure, and for this the authors prefer carboxymethylcellulose mesh packed into the graft bed, although bone wax may be preferred by some operators. Others advocate packing the defect with bone substitutes held in place with barrier membranes in order to minimize any potential change in the bony profile. Good closure of the soft tissue at the donor site is critical because the tendency for wound breakdown is quite high and a hermetic-type wound closure should be aimed for.

Other intraoral harvesting sites are also available but may be more limited in the amount of bone available. Trephine specimens taken from the mandibular retromolar area can provide good-sized grafts of high-density bone (Figs. 12.8A, B and 12.9). The maxillary tuberosities may also be used but the bone density in this region may be poor. Larger blocks may be taken from the ascending ramus and external oblique ridge/coronoid process as well as the buccal aspect of the body of the mandible, using rotary or piezo instrumentation. This site is preferred over the chin by many operators (Fig. 12.10).

The amount of bone harvested from any site while using cutting instruments can be increased by employing harvesting sieves within the suction apparatus (Fig. 12.11). These collect the osseous coagulum produced during drilling, which is considered to have good osseointegrative potential. Owing to aeration and hydration during cutting, the volume of



**Figure 12.8** (A, B) Trephine donor sites from the lower retromolar area. This region can yield good-quality bone grafts but the size of the grafts can be limited. By increasing the size of the access flap, the ascending ramus may be used as a donor site—in such cases the use of diamond discs or piezosurgical instruments may be easier and increase the size of the graft obtained. (C) The amount of bone available from the trephine specimens is variable; in dense bone the graft may be largely cortical as shown. In areas of low density, such as the maxillary tuberosity, there may be minimal bone recovered. (D) Trephines of various sizes are available for different graft sizes and to allow for limited access. It is useful to have depth indication lines on the outer aspect to allow monitoring of the cut depth.



**Figure 12.9** (A) A case showing significant loss of alveolar height and buccopalatal width. (B) The extent of the bony defect after raising buccal and palatal mucoperiosteal flaps. (C) Perforation of the recipient site. (D) A trephine specimen is secured to the underlying bone with a 1.2-mm-diameter titanium microscREW (Mondeal Medical Systems GmbH, Am Gewerbering 7, 78570 Muhlheim a.d. Donau, Germany). (E) Once in place, any voids may be packed with osseous coagulum or bone chips. (F) A connective-tissue graft taken from the palatal flap ensures good primary closure and bulks out the soft tissue profile. (G) The healed site three months after grafting. (H) The bone graft has maintained volume during the healing phase—this is due in part to the fact that the graft was dense cortical bone. (I) Implant placement into the graft showing good implant coverage and ideal implant orientation.

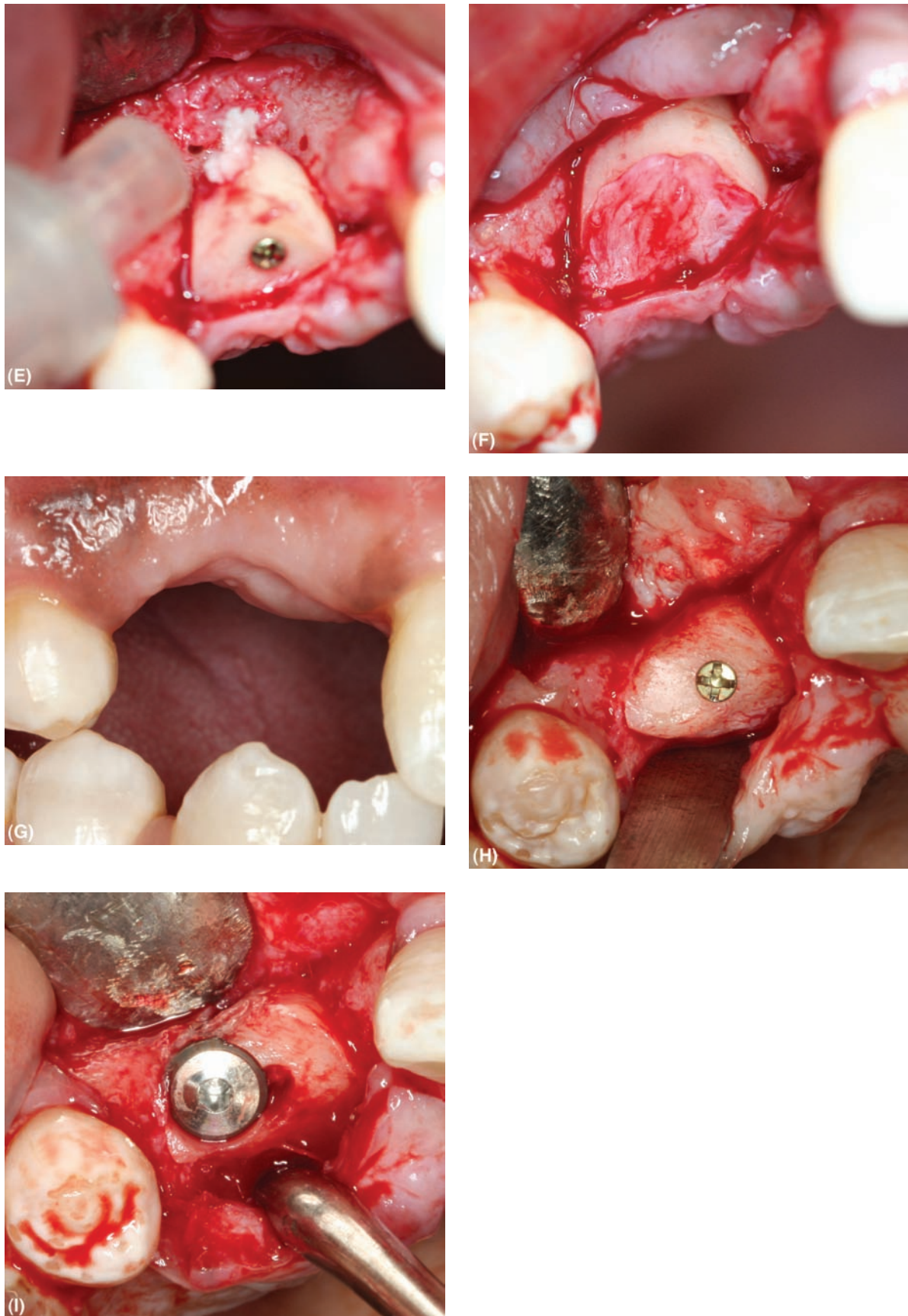
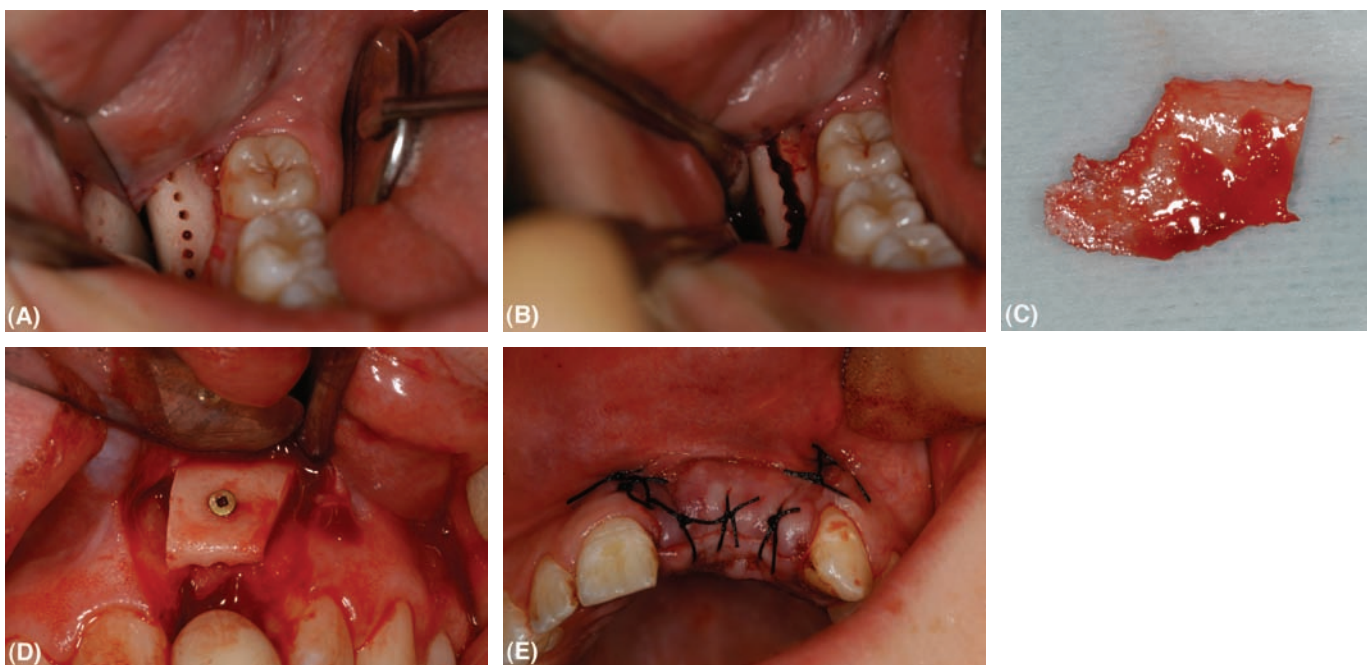
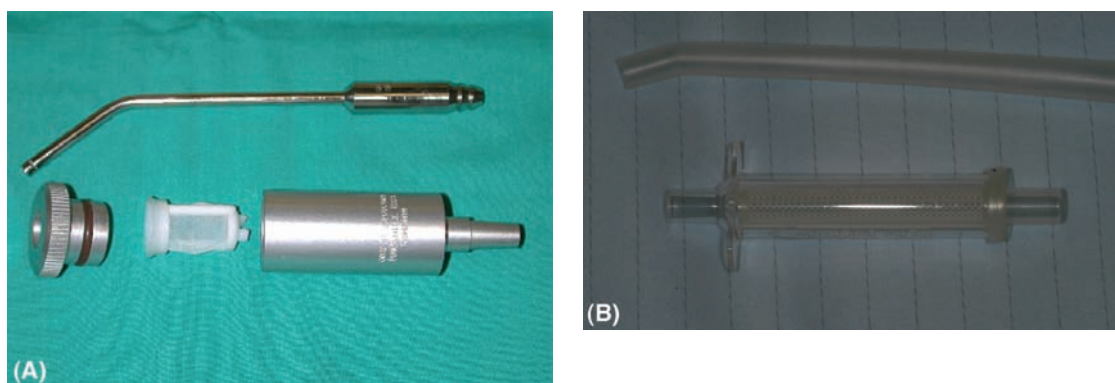


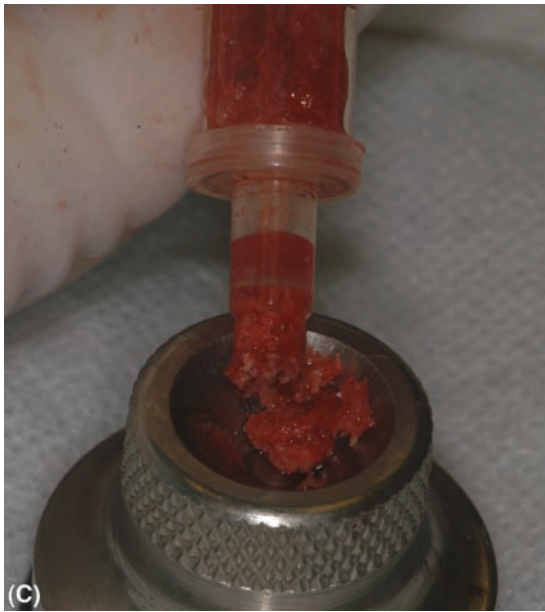Figure 12.9 (Continued)



**Figure 12.10** A series of photographs to show harvesting of a block of bone from the buccal aspect of the mandible to augment an upper central incisor site. (A) A buccal mucoperiosteal flap has been raised and the crest perforated with a fissure pattern surgical bur. Mesial and distal limiting cuts have been made to control the size of the specimen. A further cut through the cortical bone has been made inferiorly to encourage the block to fracture at the appropriate level. (B) The graft is mobilized buccally with a bone chisel and then elevated. (C) The graft having been removed, the level of fracture may be difficult to limit inferiorly. (D) The graft is then trimmed to shape using burs and irrigation or rongeurs to achieve the correct alveolar profile and allowing for some loss of bone during the healing phase. Having perforated the recipient site, the graft is secured in place with a micro screw. (E) Good primary closure is achieved by mobilizing the buccal flap, including relieving the periosteum.



**Figure 12.11** (A) A bone trap used for harvesting bone chips and osseous coagulum during bone preparation with rotary instruments. The disposable white plastic filter collects the bone, which can be used to pack small voids. Fairly large volumes may be collected using this method, particularly when using coarse cutting instruments such as twist drills and in sites with high-density bone. (B) A BoneTrap™ (Astra Tech, Sweden). This is a completely disposable bone trap, which allows self-delivery of the recovered bone material directly to the graft site, minimizing handling of the graft and reducing loss of material. (C) Bone cuttings from BoneTrap being expressed from the end of the delivery tip.



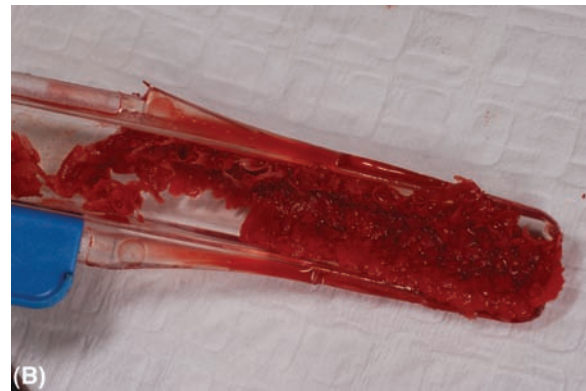
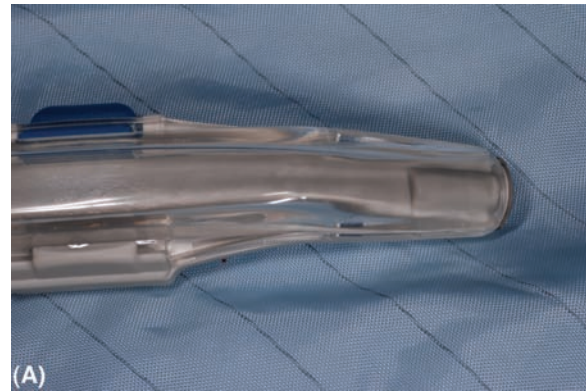
**Figure 12.11** (Continued)

coagulum produced can be significant, particularly if fairly coarse rotary instruments have been used. It is desirable to use a dedicated suction line for bone traps to reduce the risk of contamination particularly with saliva, etc. When not being used, the trap should be removed from the suction source to prevent dessication of the bone material within the trap. The coagulum forms a paste-like substance that is readily manipulated and can be placed in any residual voids between graft and recipient bed. Where a change in alveolar profile is sought, the particulate graft needs protection with a space-creating membrane or mesh.

An alternative to block grafting for small defects where osseous coagulum is unlikely to provide enough good-quality material is the use of bone scrapers such as the Safescraper® TWIST and Micros instruments (Meta, Reggio Emilia, Italy) (Fig. 12.12). These allow access to restricted access sites through small flaps particularly the retromolar area. The chips harvested may be used to pack voids around grafts or as graft materials in self-preserving volumetric defects, for example, sinus lift procedures/extraction sockets or underneath space-creating membranes.

Intraoral bone harvesting has become more popular with the introduction of some of the techniques above and is particularly attractive in that the dental surgeon is working in a familiar environment. The fact that these procedures can be performed under local anesthesia with a relatively low morbidity also makes them the treatment of choice for small grafts. However, if there is a need for larger blocks of bone, extraoral donor sites are required. Historically, the site of choice has been the iliac crest as bone is readily available in large volumes (Fig. 12.13). However, this requires an appropriately trained surgeon, a general anesthetic (unless trephine specimens are considered adequate), and the procedure is associated with significant morbidity.

Once the graft material has been harvested, it can be shaped to fill the defect with irrigated burs or hand instru-

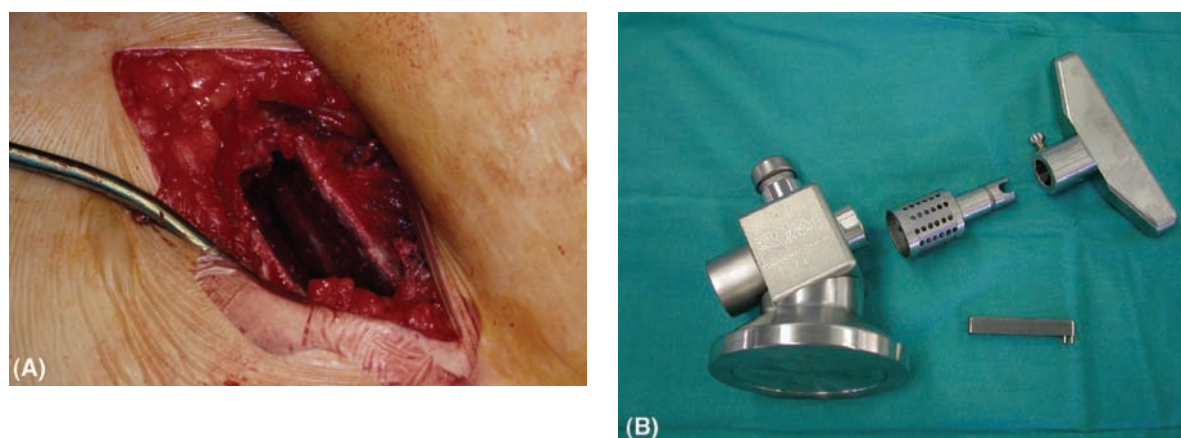


**Figure 12.12** (A) The Safescraper® TWIST is an example of a fully disposable bone scraper and is available in a straight and curved design to optimize access. When used on cortical bone, particularly the mandibular retromolar/external oblique ridge area, substantial volumes of good-quality bone material can be recovered via minimal flaps/incisions. (B) A view of the collection chamber full of bone material from the retromolar area.

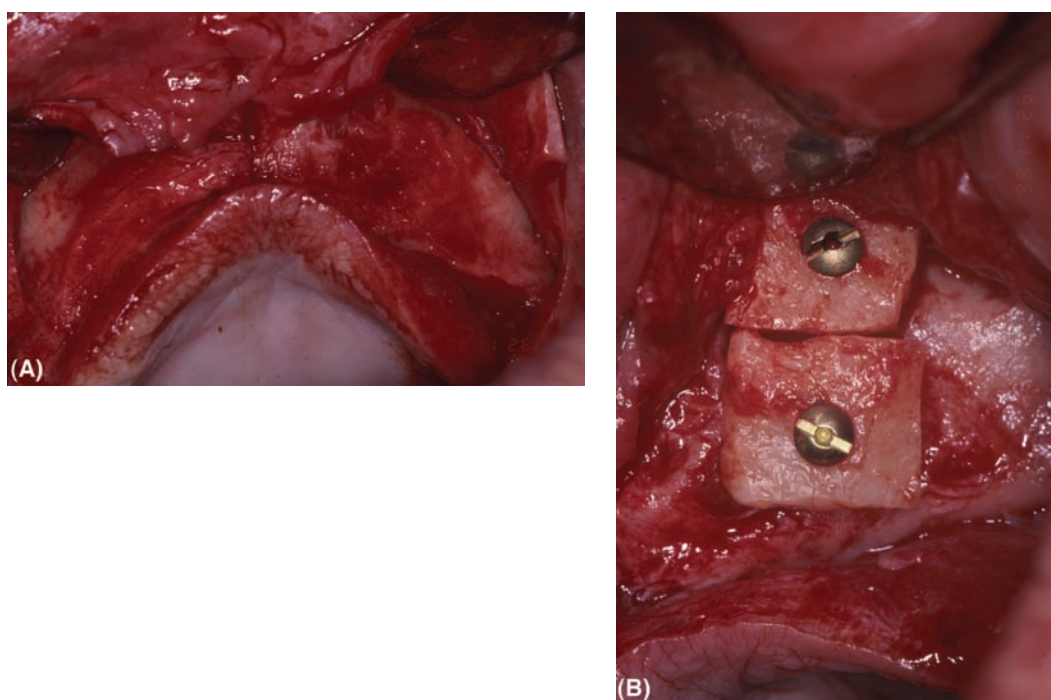
ments such as rongeurs and chisels. Ideally the graft should be adapted to give a close fit to the recipient bed, with any small residual deficiencies made good with bone chips and osseous coagulum. The recipient bed should be perforated with round surgical burs to promote bleeding from the underlying cancellous bone, to encourage vascularization and union of the graft.

The success of the graft, like that of the implants, is dependent on the stability of the graft and associated blood clot. The graft should, therefore, be held firmly in position using titanium screws (Figs. 12.10D and 12.14B). Further stability and protection of the graft may be achieved by using titanium mesh or barrier membranes to cover the graft. These may be stabilized using small screws or tacks. The use of barrier membranes in particular has been advocated to reduce the amount of resorption of the graft that occurs in the healing phase, which may be as much as 50% over six months. However, the use of membranes also poses an increased risk of infection, particularly if they become exposed. The present authors do not advocate their use with block grafts but accept that they may be necessary with particulate/milled grafts.

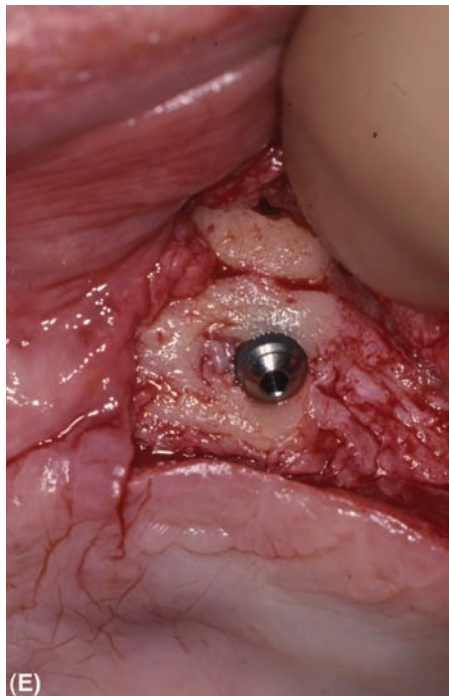
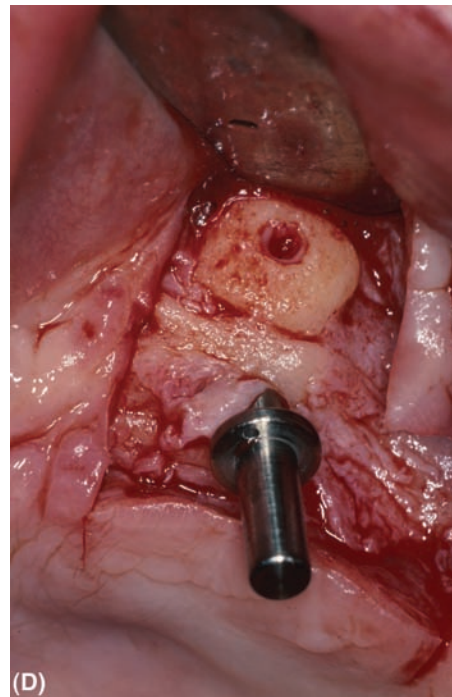
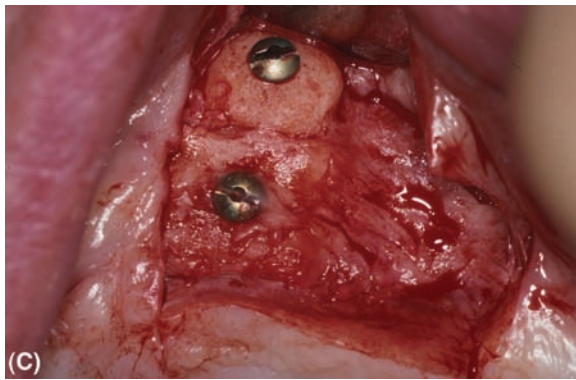
Wound closure at the grafted site must be complete, with great emphasis on achieving a hermetic seal with as little tension on the soft tissue flaps as possible. This can be difficult to achieve with large changes in bone profile and may require



**Figure 12.13** (A) The favored extraoral site for bone harvesting remains the iliac crest, from where substantial blocks of bone and significant amounts of cancellous chips may be harvested. (B) A bone mill can be used to fragment large bone grafts to produce a particulate graft that is more readily packed into voids and awkward or confined spaces. Such grafts may be used in sinus lift procedures.



**Figure 12.14** (A) View of the upper jaw showing the left canine region requiring grafting prior to implant placement. The crestal ridge profile appears to be of adequate dimensions on the right but there is a significant buccal concavity present on the left. (B) Two corticocancellous blocks have been trimmed to shape and secured using 2.0-mm-diameter titanium microscrews that engage the residual ridge. Prior to this the host site cortical plate is perforated with a small surgical drill (see Fig. 12.3). The grafts are larger than the required ridge profile to allow for some resorption during healing. Any spaces between the grafts and the host bed are packed with cancellous bone chips and osseous coagulum. Further osseous coagulum is packed between and over the grafts to produce a smoother profile to the grafted site. (C) Three months later there has been a little resorption of the grafts, but this underlines the importance of placing larger grafts than are ultimately required. Protection of the grafts with membranes or titanium mesh may reduce the amount of resorption but can increase the risk of infection and total loss of graft material. (D) A direction indicator in place after drilling with a 2.5-mm twist drill to show the planned implant orientation and adequate available bone on the buccal aspect. (E) Placement of an implant in an ideal orientation without any dehiscences or fenestrations has been facilitated by the use of the grafts.



**Figure 12.14** (Continued)

further soft tissue reflection and periosteal relief to advance the soft tissues. Due consideration should be given to the potential problems of closure preoperatively, in particular placing relieving incisions remote from the grafted site when gaining surgical access. The potential for wound breakdown over grafted areas is higher and carries with it a high morbidity. Patients should receive appropriate pre- and postoperative antibiotics to minimize the risk of infection.

The length of time between grafting and implant placement has been the subject of much controversy. When using onlay grafts, the authors prefer a time interval of three to four months, whereas in GBR techniques it may be better to delay implant placement for up to six months. Screws and membrane tacks are readily removed at the time of implant placement but the complete removal of PTFE membranes can be difficult to achieve. When placing implants in areas that have

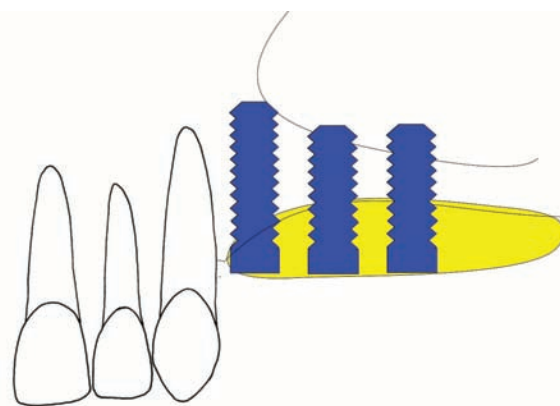
recently undergone an onlay graft, great care is required not to cleave the graft off the underlying alveolus during implant placement. Incremental drilling procedures and low forces are therefore mandatory when preparing grafted sites for implants.

### SURGICAL MANAGEMENT OF LARGE ALVEOLAR DEFECTS

More demanding ridge defects arise from long-standing tooth loss and denture wearing, as well as trauma and as a result of some pathological conditions. Grafting in such cases may be undertaken to allow implant placement but also to change the profile of the alveolus to enable placement of implants in a more ideal orientation. Long-standing tooth loss can lead to a considerable change in skeletal relationships (pseudo-class 3 jaw relation) that may need correction. Treatment of cases with gross loss of vertical height of the alveolar ridge without grafting can necessitate the use of short implants, which may be considered undesirable because it results in a tall, restorative stack that may cause biomechanical failure in the long term through component failure or loss of osseointegration (Fig. 12.15). Bone grafting techniques should not only increase the volume of bone but also create an implant bed of good-quality bone to ensure long-term implant success.

Large grafts taken from the iliac crest can be fashioned to produce an entire new alveolar form. This technique is favored in cases where there is a skeletal base discrepancy or where a large change in the vertical component of the ridge is required, particularly where there is a desire to reduce the height of the prosthesis. Onlay grafting can be performed as a one- or two-stage procedure, with the implants used to secure the graft in the one-stage approach (Fig. 12.16). This requires that there is enough residual basal bone to secure the implants and graft. In full-arch cases, at least six implants are required to achieve this. In the two-stage approach, implant placement should take place around three to four months after the graft procedure.

In cases where the vertical height of the maxillary ridge is inadequate, inlay grafts may be the treatment of choice. Large inlay grafts spanning the entire maxillary complex in combination with a Le Fort I downfracture have been used successfully, particularly in cases where a change in skeletal



**Figure 12.16** Onlay grafts may be secured to the residual alveolus by placing implants simultaneously, provided that there is enough bone to stabilize the implants. Soft tissue closure may be difficult in these situations.

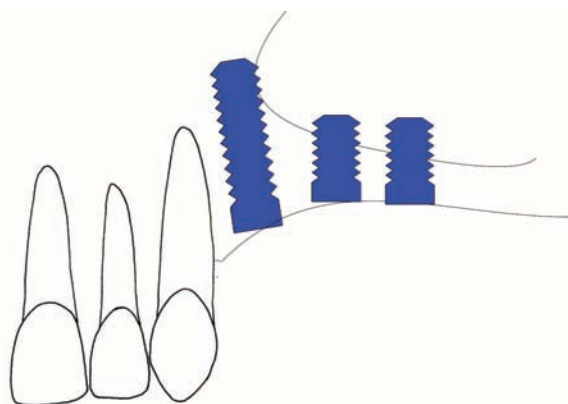
relationship is desirable. This technique preserves the intraoral ridge profile but allows substantial gains in available vertical height for implant placement (Fig. 12.17).

### SINUS LIFT PROCEDURES

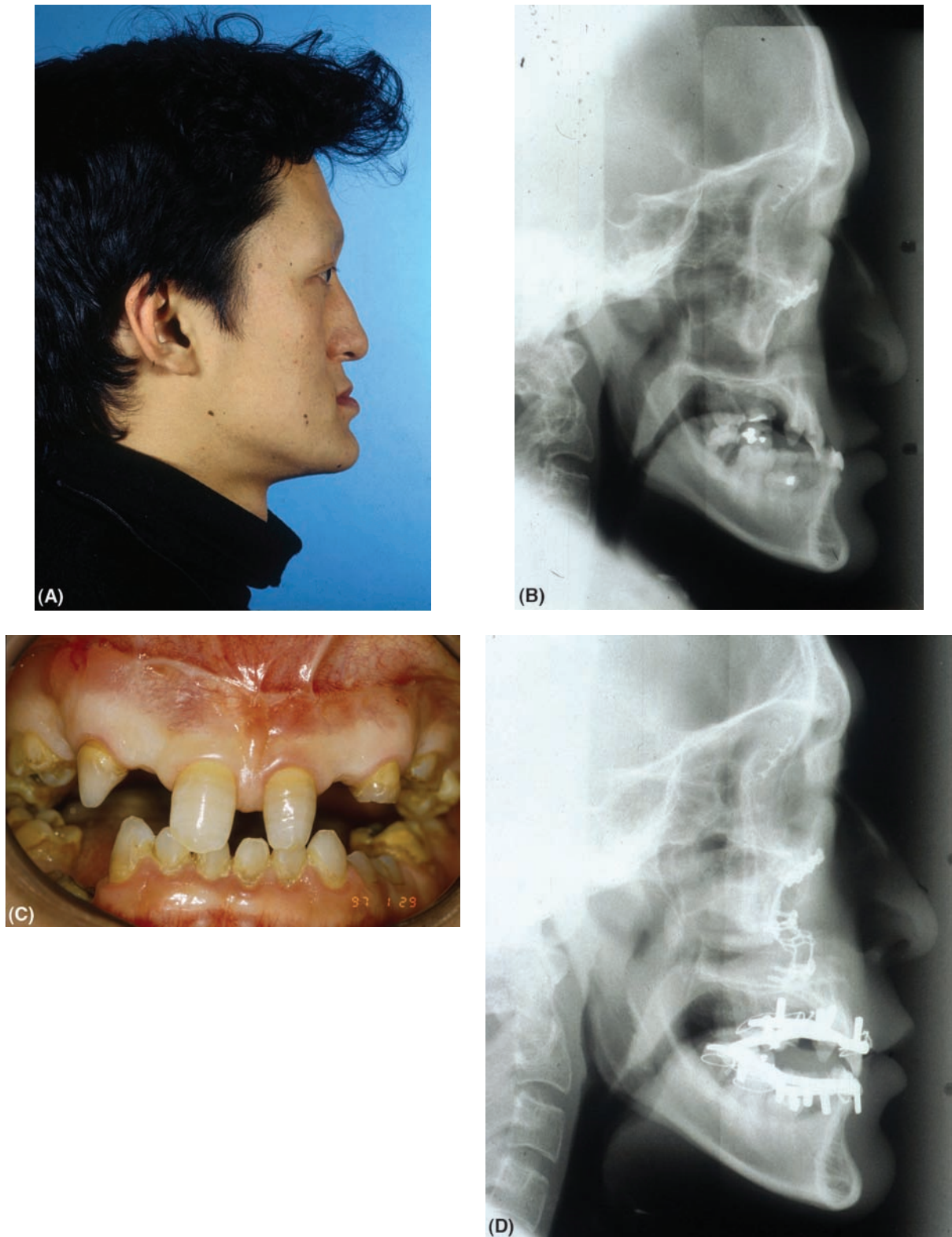
Loss of alveolar ridge height, particularly in combination with pneumatization of the edentulous posterior maxilla, means that there is frequently a lack of bone height for implant placement. It is also often the case that any residual bone in this area is of poor quality. Sinus floor grafting procedures were developed by Tatum in the late 1970s to overcome these problems and have been used with great success worldwide following the principles described by him. There is little evidence of disturbances to sinus drainage following these procedures.

In the classic approach, a bony window or trapdoor is created in the buccal sinus wall to gain access to the sinus. It is vital that clear radiographs are available preoperatively to show the topography of the sinus, particularly the presence of any bony buttresses or septa that may prevent elevation of the window (Fig. 12.18A). In addition, it is useful to ascertain the buccopalatal dimension of the sinus to ensure that if a trapdoor is created it will have space to rotate upward within the sinus cavity (Fig. 12.18B). The presence of any sinus disease or a history of severe recurrent sinus infections are contraindications to this procedure.

The procedure can be carried out under local anesthesia, and the use of infraorbital blocks is advocated. Good access is obtained through a wide-based soft tissue incision with its boundaries remote from the proposed point of entry to the sinus. Commonly, the sinus wall is thin and the sinus cavity can be seen as a bluish gray area on the bone surface. This is helpful in delineating the site for creating the window, which must be cut over the sinus cavity or it will be impossible to elevate a trapdoor and/or the sinus membrane. Where the sinus wall is thick the surgeon has to rely on the preoperative radiographs or computed tomography (CT) scans to mark out the shape of the window. The window should extend



**Figure 12.15** Placing implants into the residual ridge will require the use of short implants and produce a tall restorative stack. An onlay graft would increase the bone volume, allowing the use of longer implants and reducing the height of the prosthesis (see Fig. 12.14).



**Figure 12.17** (A, B) This patient has a severe skeletal base discrepancy, as well as many developmentally absent teeth. A combination of bone grafting and maxillary osteotomy using a Le Fort 1 downfracture and advancement is required to alter the skeletal relationship. Additionally, large maxillary sinuses dictate the use of short implants, unless bone grafts are placed. (C) Intraoral view showing degree of hypodontia (post-osteotomy). (D) Lateral cephalogram showing the skeletal profile after Le Fort 1 osteotomy and iliac crest inlay graft. (Orthognathic surgery by Dr Paul Robinson.) (E) Dental panoramic tomograph showing implants in place in the maxilla with the completed implant-retained bridge in the mandible. The increased available alveolar height provided by the inlay graft allows placement of long implants with a favorable prosthesis height. (F) The final result with bridges in place. Despite the grafting procedure, the alveolar orientation dictated the placement of labially inclined implants and buccal access holes for the bridge screws. (G) Lateral cephalogram showing the final bridgework in situ. Note the improved facial profile and the orientation of the maxillary implants. (H) Clinical photograph showing the final result, with good profile and facial height.

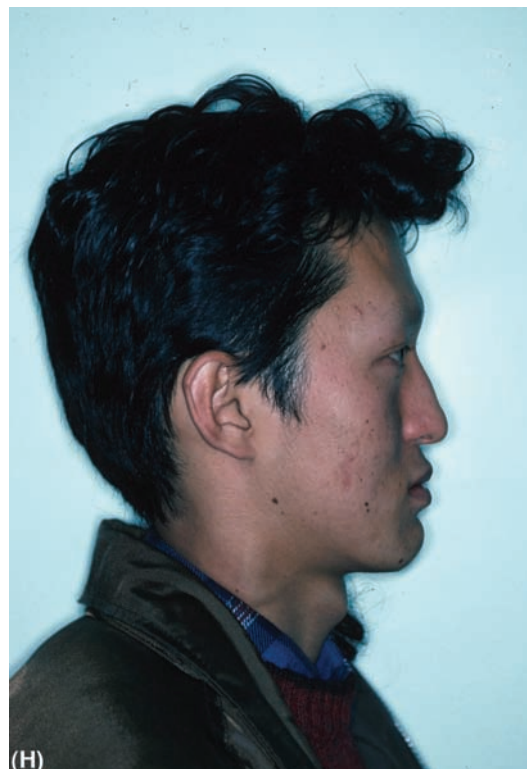
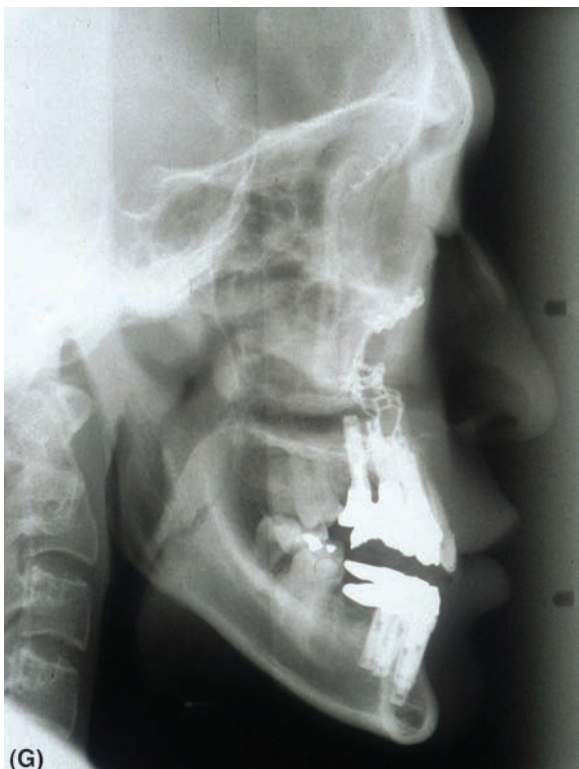
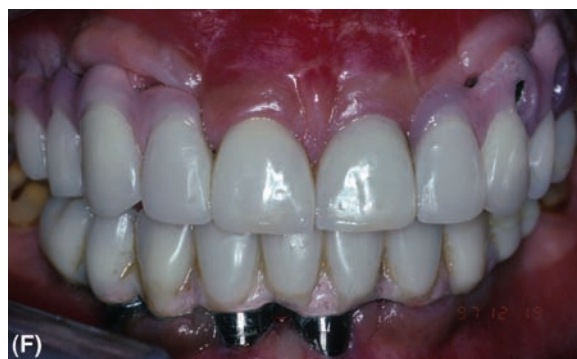
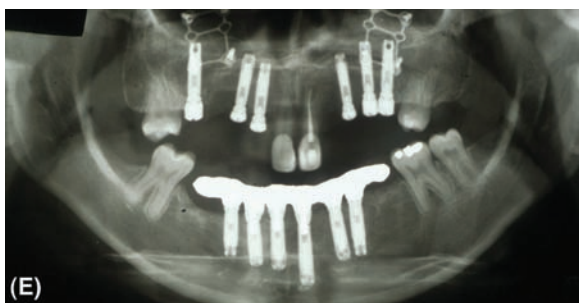Figure 12.17 (Continued)

mesiodistally as far as the proposed implant sites. If a pronounced bony septum is present, it may be necessary to create two separate windows or use an alternative approach (see next section). When raising a trapdoor, the outline is preferably created with diamond-coated surgical burs using copious irrigation, with great care taken not to perforate the underlying sinus membrane.

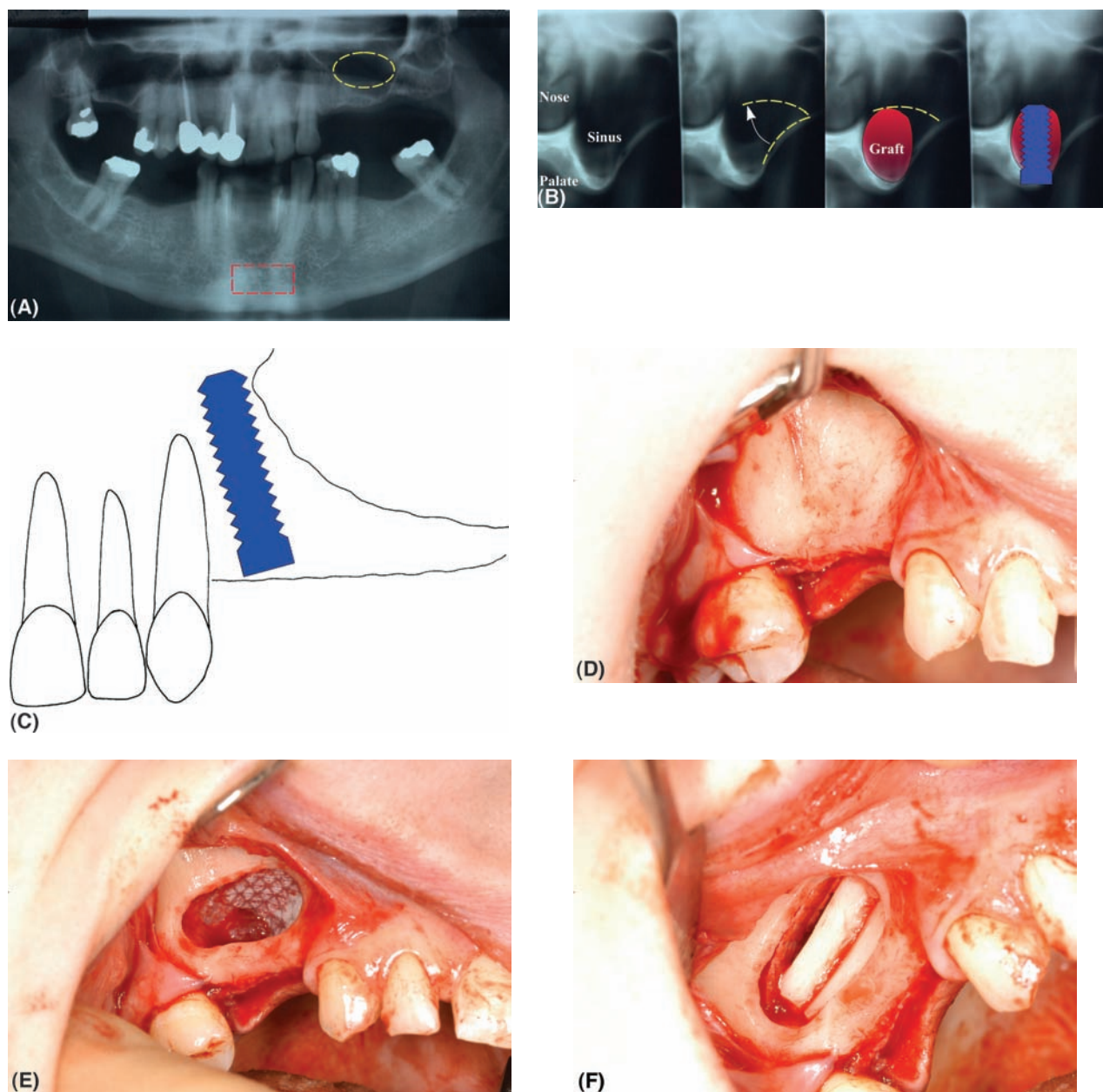
The inferior and lateral cuts are taken completely through the bone but the superior cut is partially perforated to allow the window to be infractured, leaving the superior aspect as a hinge. Once the cuts are complete, the surgeon should be able to move the window inward with fairly gentle pressure.

As the trapdoor is elevated, the sinus membrane is gently lifted off the surrounding bone. It is important to keep the sinus membrane intact throughout this procedure because it is exceedingly difficult or impossible to suture tears in the membrane. Small perforations may be patched with

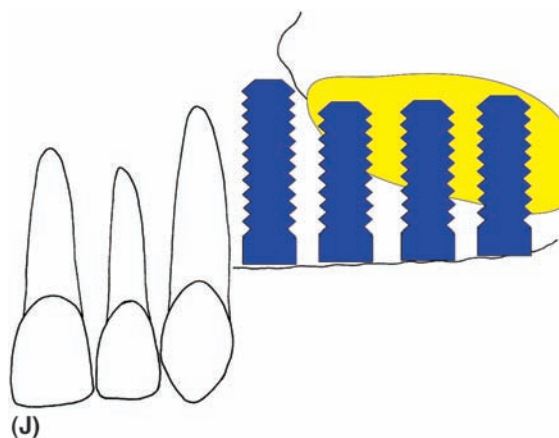
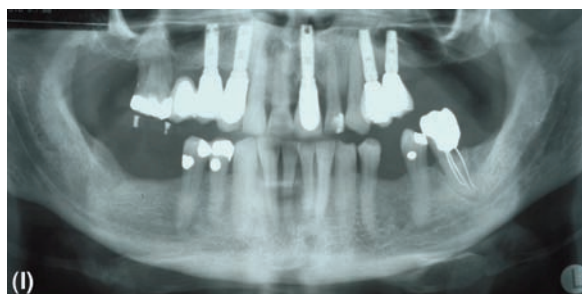
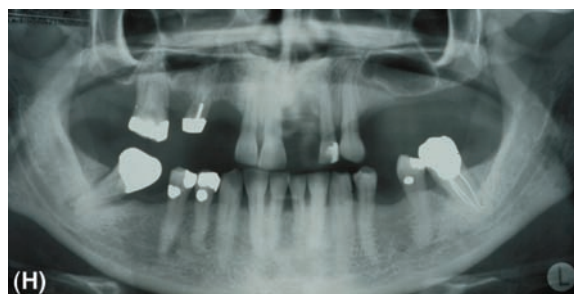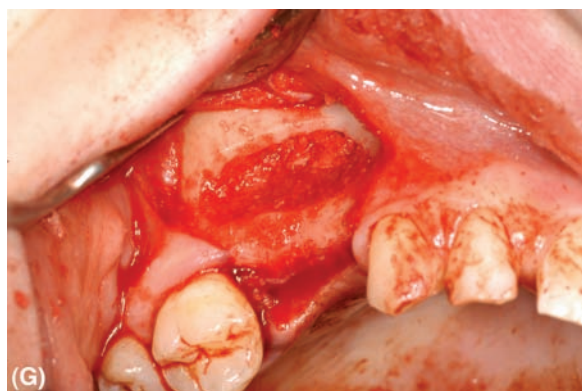resorbable membranes or carboxymethylcellulose mesh. Large tears may dictate that the procedure is abandoned, particularly if the intention is to graft the sinus with a particulate graft material rather than a corticocancellous block. The elevation continues until the desired size of void has been created, with the membrane pushed medially and superiorly along with the trapdoor.

The alternative method is to create a window directly in the lateral wall by removing the bone in its entirety. This can readily be achieved using an acrylic bur and irrigation. The bur tends to displace the membrane once the covering bone has been removed and the lining can then be further elevated from the perimeter of the window.

The degree to which the sinus floor may be lifted is also dictated by the position of the osteon on the medial wall, which allows drainage of the sinus. Once the space has been created within the sinus, two different approaches may be taken. If there is enough residual alveolar bone to accept and



**Figure 12.18** (A) Dental panoramic tomograph of a patient requiring implants in the posterior maxilla. The alveolar ridge has a good intraoral height but the extension of the maxillary sinus on the left side makes it impossible to place more than one implant without using a grafting procedure. There is no indication of sinus pathology or fluid levels/mucosal thickening. Additionally, there would appear to be no bony septa running across the lateral wall. The proposed site for a corticocancellous graft from the chin is also outlined. (B) Sectional tomographs of the patient shown in part A allow evaluation of the space available to elevate the trap door (shown by the yellow line). An indication of the likely volume of graft required can be ascertained as well as the length of implant that may eventually be placed. The amount of residual alveolus in this case would not be enough to stabilize the implant at the sinus grafting stage. Implants would be placed as a separate procedure three months later. (C) Placement of a single implant into the residual alveolus distal to the upper left cuspid is possible for the patient shown in part A. This may be enough in patients with a restricted smile line or in low load situations but is rarely the treatment of choice unless solely replacing the upper second bicuspid. (D) A preoperative view of the lateral wall of the sinus. Here the antral wall is thick and there is no indication of where the sinus cavity lies, often shown by a bluish appearance where the bone is thinnest. (E) The window has been prepared with an acrylic bur and the membrane has been elevated. The membrane has not remained intact and the fenestration created in it has been protected with a resorbable membrane. There is not enough residual alveolus (5 mm) to allow simultaneous sinus lift and implant placement, therefore a graft will be placed into the void created. (F) Residual space within the cavity is packed with autogenous bone, here sheets of bone have been recovered from the ascending ramus of the mandible. (G) Further bone material including osseous coagulum is placed around the graft and on the buccal aspect of the void. The graft may be covered with a resorbable membrane on the buccal aspect to ensure it remains within the void. The flap is then sutured back into place. (H) Preoperative radiograph showing limited bone height in the posterior maxilla. (I) Postoperative radiograph after a sinus lift has been performed in the upper left quadrant. The new level of the sinus floor in relation to the installed implants can be seen. Enough residual alveolus was present in the upper right quadrant to allow implant placement without grafting. (J) Large blocks of corticocancellous graft material may be stabilized by placing implants through both the residual alveolus and the graft. Ideally the graft should be orientated so that the cortical plate is superior allowing good fixation of the apices of the implant.



**Figure 12.18** (Continued)

stabilize implants (usually at least 5 mm in height), then they may be placed immediately, with any residual voids being packed with graft material. If large blocks of bone are being placed into the sinus, these may be stabilized by placing the implants through both the alveolus and the graft (Fig. 12.18J). In cases where there is little residual alveolar bone, the void is first grafted and implants are then placed three months later (Figs. 12.18 and 12.19). This latter technique is probably the preferred option with more predictable results in all cases. The preferred graft material is autogenous bone, although this is frequently mixed with another graft material (Fig. 12.19). Care should be taken when using particulate graft materials to ensure that the membrane is intact or that any tears are well sealed and protected (Fig. 12.18E). Once the graft material and/or the implants are in place, the trapdoor, if present, is held in its elevated position, closure of the wound is straightforward. The decision to place a GBR membrane over the buccal aspect of the window is operator dependent, with some evidence of higher graft success with a membrane.

### TRANSALVEOLAR SINUS FLOOR ELEVATION

Implants are often placed with their apices extending into the sinus cavity by a few millimeters when attempting bicortical stabilization in the maxilla without any associated problems. Attempts to lift the sinus membrane through the osteotomy site have been described and bone apposition around the apices of the implants has also been shown. A more refined

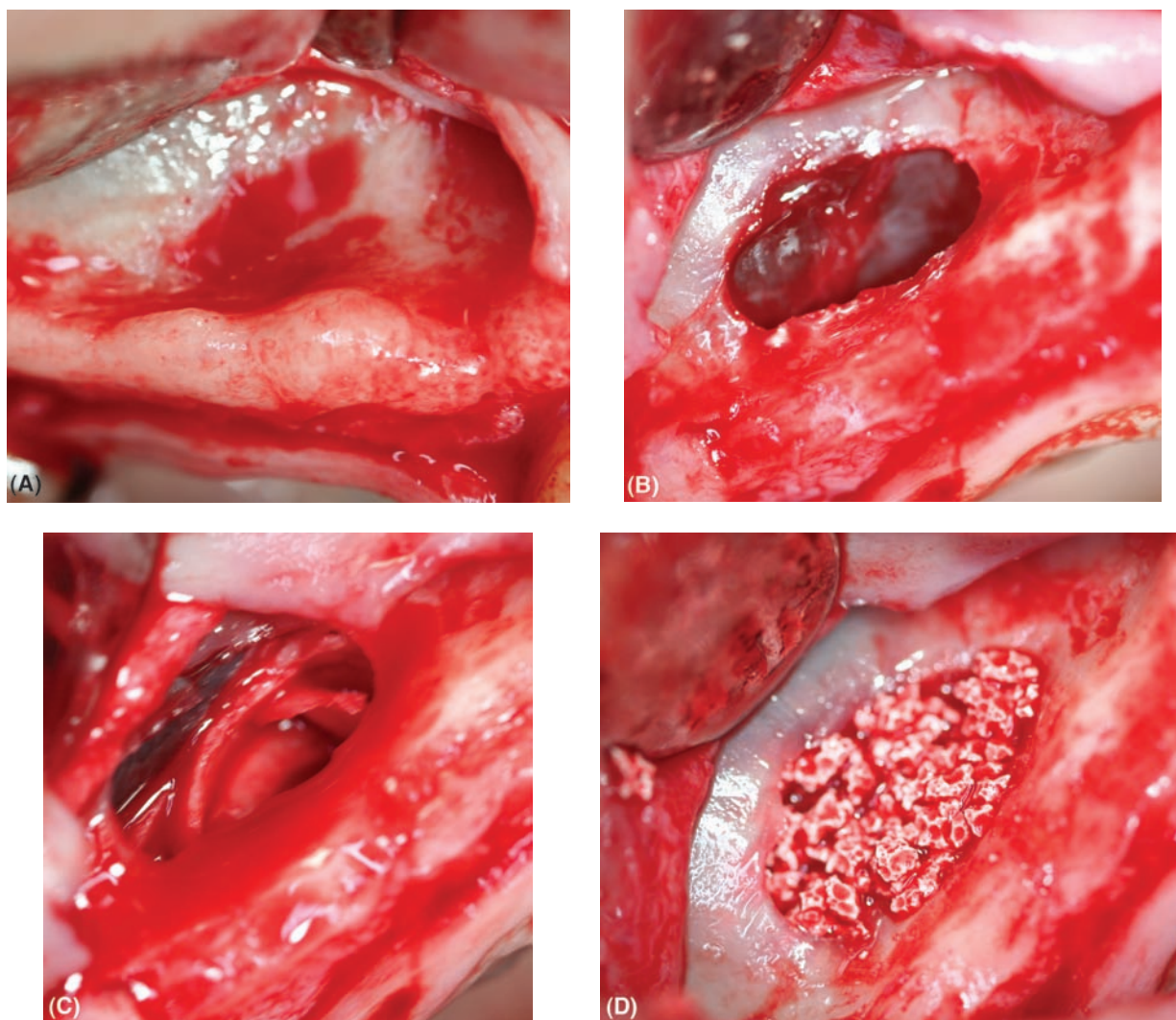
technique has been described by Summers, using specific osteotomes to drive bone apically through the osteotomy site but to retain it under the sinus membrane (Figs. 12.20 and 12.21). A combination of drilling of the cortical bone and some part of the coronal alveolar bone can reduce the forces required to achieve success with this technique. Compacting bone or placing osseous coagulum/bone chips within the osteotomy site before the final breakthrough of the floor dissipates the force delivered through the osteotome and is less likely to cause a perforation of the sinus membrane. Infraction of the sinus floor at each implant site can thus be achieved along with considerable elevation of the sinus. Implants may be inserted immediately with this technique so long as the minimum 5 mm of alveolar ridge height preexists, although this technique has been reported to be successful in sites with less than 4 mm of residual height.

### OTHER TECHNIQUES

#### Management of Extraction Sites

Teeth requiring extraction and subsequent implant placement may be dealt with in several ways. It should be remembered that the majority of extraction sites heal uneventfully with good bone fill of the socket, particularly when only one tooth is involved and there are adjacent standing teeth.

Preservation of the tooth socket is a prerequisite for predictable bone fill and this is best achieved using an atraumatic extraction method, in particular the use of Periotype®



**Figure 12.19** A series of photographs to show a sinus lift in a patient with developmentally missing teeth. **(A)** Clinical presentation showing a significant buccal concavity and exostoses on the buccal aspect of the crest. **(B)** A window has been created and the membrane elevated intact. **(C)** The exostoses have been removed with chisels and the fragments packed into the void. **(D)** The autogenous bone has been augmented with tricalcium phosphate granules to stabilize the graft and to stop the soft tissues collapsing back into the sinus.

(Friedrichsfeld GmbH, Mannheim, Germany) or luxators can be useful in achieving this (Fig. 11.3). Difficult extractions requiring bone removal and the associated soft tissue involvement may be aided in healing by good wound closure, particularly soft tissue advancement to affect primary closure. Placing graft material into the extraction socket and the use of occlusive membranes have been advocated to improve bone fill. Problems may arise, however, if the socket and graft/membrane subsequently become infected, resulting in more bone loss than would have occurred without the graft procedure.

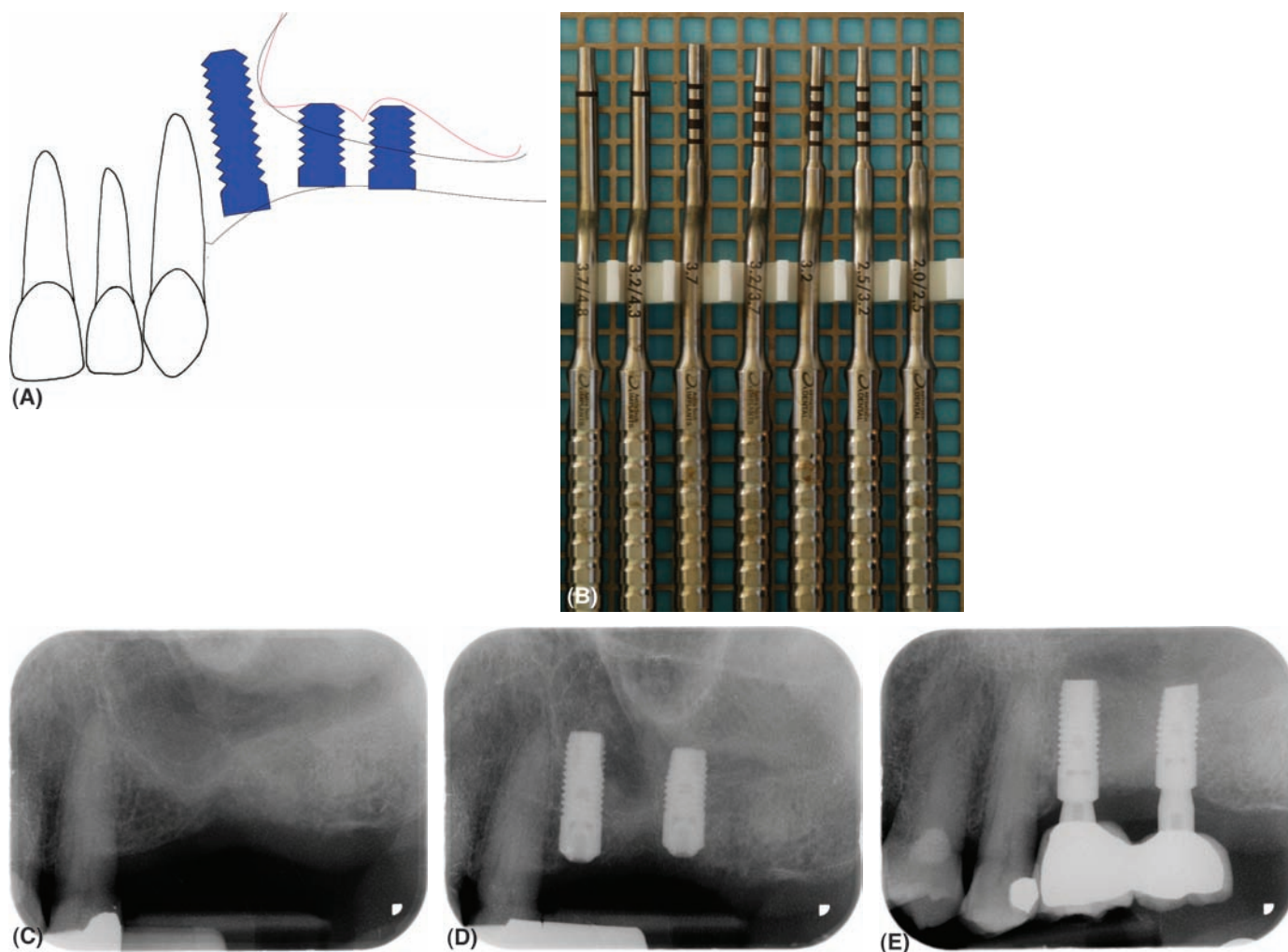
### Dehiscences and Fenestrations

Small defects created at the time of implant placement such as marginal dehiscences or fenestrations may require grafting, depending on their shape, size, and location (Figs. 12.22 and 12.23). The rationale for such procedures must, however, be

questioned as grafts placed in such defects as well as bone created using GBR techniques are unable to contribute to the initial stability of the implant and the bone may not ever integrate with the surface of the implant. Repair of such defects may be useful in situations where the overlying mucosa is thin and there is a risk of the implant showing through the gingiva.

### Crest Splitting and Dilation

Placement of an implant into a ridge that is slightly narrower than the implant diameter can be achieved by increasing the crest width using one of two techniques. Dilation of a site can be achieved in its simplest form by allowing the implant to expand the ridge as it is inserted. This can be achieved where the bone is thin and soft enough to allow this; it can also be facilitated by using tapered implants. Formal dilation of the ridge is achieved using osteotomes, such as Summers'



**Figure 12.20** (A) The floor of the sinus may be elevated at each osteotomy site using Summers' technique. By pushing a plug of bone apically with osteotomes, the floor may be infrafractured leaving the sinus membrane intact. (B) A set of Astra Tech osteotomes for transalveolar sinus lift procedures. The handles are cranked to improve access and the tips are concave to aid cutting and compression of the bone. (C) Preoperative radiograph of the left maxilla showing less than 5-mm bone height. (D) Postoperative radiograph one week after a transalveolar sinus lift. (E) Radiograph after restoration showing bone consolidation around the implants and increase in bone height beneath the sinus floor.

osteotomes or those for specific systems (Figs. 12.24 and 12.25). This technique is dependent on there being enough cancellous bone present between the cortical plates to allow initial site development with a surgical drill. By gentle manipulation and the use of osteotomes of slightly increasing diameters, reasonable expansion of the ridge can be achieved, enabling implant placement.

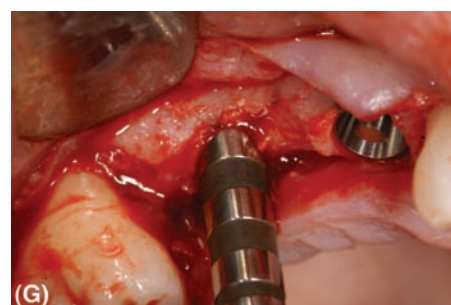
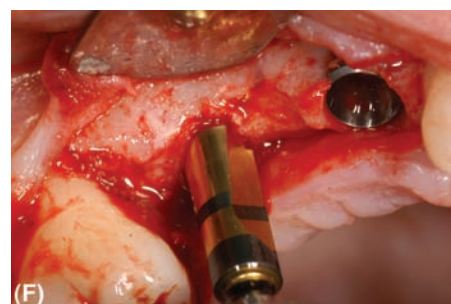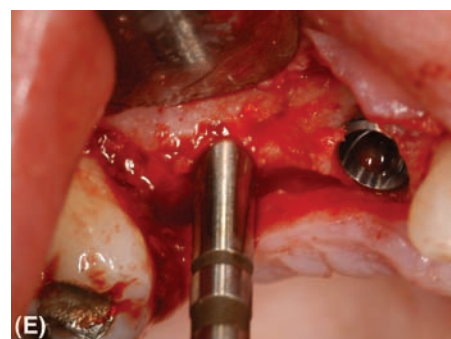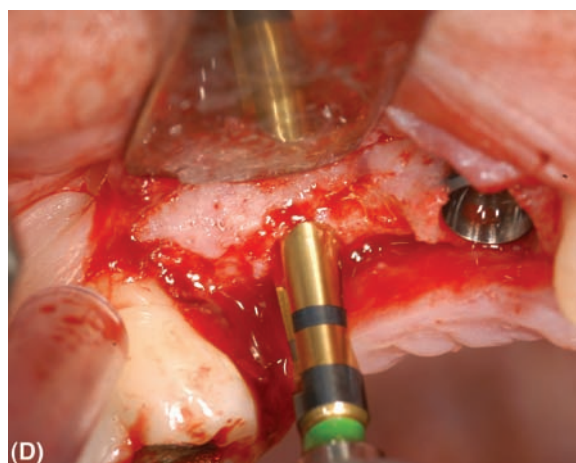
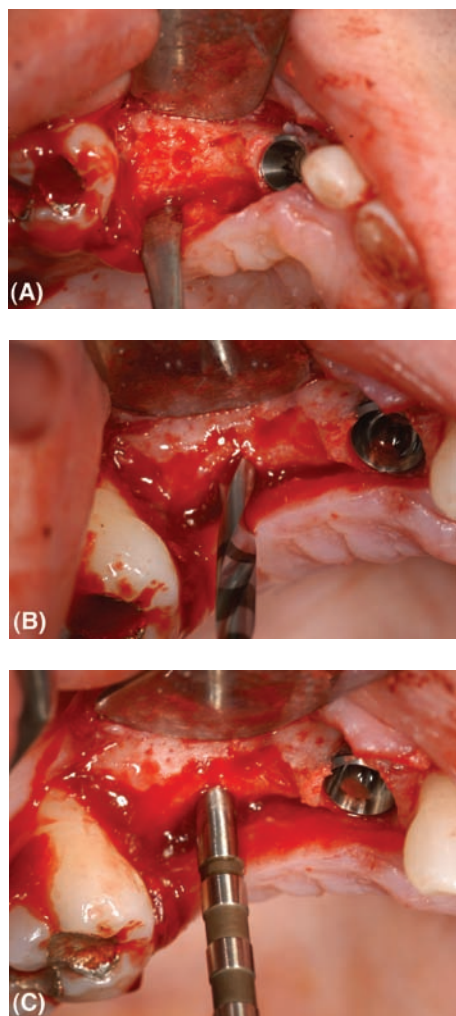
Total expansion of a ridge can be performed using bladed osteotomes or ridge splitting sets. Again, there must be some cancellous bone present within the ridge to allow for a natural plane of cleavage. Care must be taken to limit the area of expansion by placing limiting cuts at each end of the ridge. The danger of fracturing one cortical plate from the other should not be ignored and considerable practice is required to master this technique. In particular, caution should be exercised in sites with brittle bone, especially older individuals and smokers. A combination of ridge splitting and individual site dilation can produce marked changes in ridge profile.

Once the ridge has been expanded, implants, bone graft, or a combination of the two can be placed in the void. Immediate placement of implants into sites that have been ridge split may be complicated by an inability to achieve initial stability of the implants.

A limiting factor for these techniques is that they do not allow for any change in orientation of the ridge and therefore the implant. In areas where implant angulation is important and the ridge does not allow such orientation, other techniques are required to augment bone at the desired location.

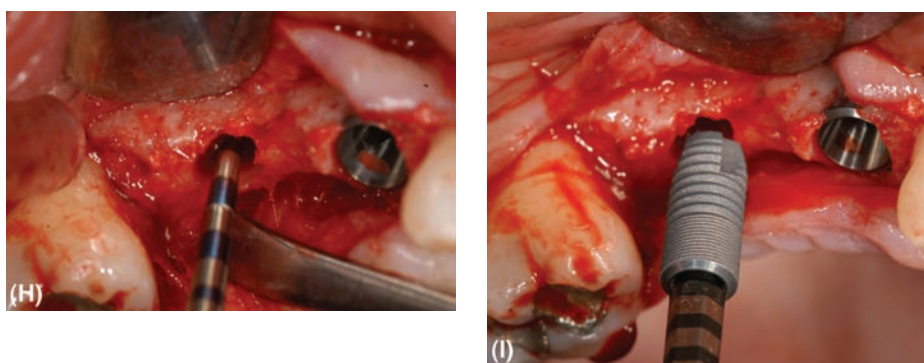
### Distraction Osteogenesis

The use of bone plates secured either side of a surgically created fracture line, which are then mechanically separated incrementally on a daily basis, has been described both in orthopedics and in maxillofacial surgery to increase bone height. Miniature bone distraction sets have now been

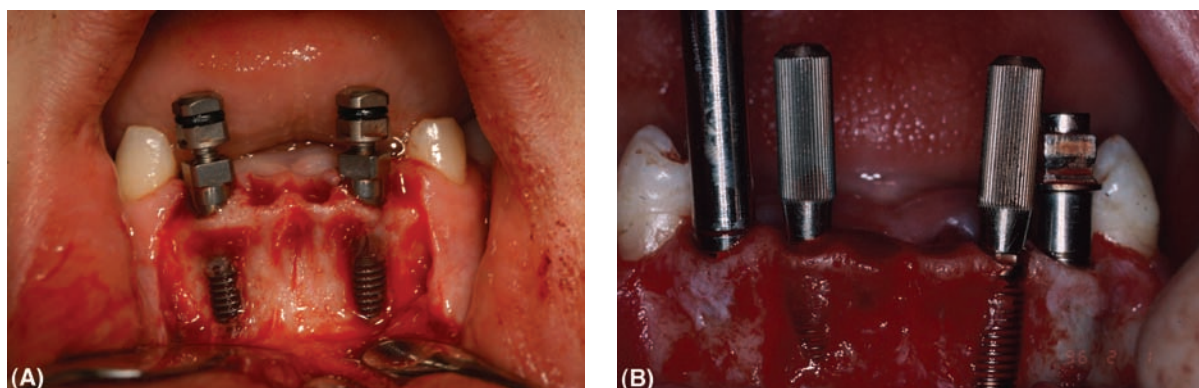


**Figure 12.21** A series of clinical photographs showing a typical sequence of drills and osteotomes for a 4-mm-diameter Astra Tech implant. (A) A guide drill is used to mark the site. (B) A 2-mm-diameter twist drill is used to perforate the cortex and to ascertain the density of the cancellous bone. If there is minimal resistance, the drilling is restricted to the cortical bone only. (C) A 2.5-mm osteotome is introduced and gently tapped apically, and is kept short of the sinus floor by 2 to 3 mm to create a bone plug at the apical part of the osteotomy site. (D) With good-quality cortical bone a 3.2-mm pilot drill is used to open the cortex further. In sites with poor cortical quality an osteotome of 2.5/3.2 diameter can be used to compress and compact the cortical as well as the cancellous bone. (E) A 3.2-mm osteotome is introduced and advanced to the previous depth of the 2.5-mm osteotome. (F) A 3.7-mm pilot drill or a 3.2/3.7-mm osteotome is used to develop the cortex further still. (G) A 3.7-mm osteotome is advanced and used to break through the sinus floor using indirect pressure through the apical plug of bone. The plug may be augmented in low-density sites with bone chips or other graft materials before the final push through. (H) The prepared site prior to implant placement. The integrity of the membrane can be checked gently with a depth gauge. (I) A 4-mm-diameter Astra Tech implant 9 mm in length in a site that was previously 5 mm in height.

**Figure 12.21** (Continued)



**Figure 12.21** (Continued)



**Figure 12.22** (A) Small fenestrations such as this are often created at the time of implant placement. The need to graft such defects or to employ GBR techniques is questionable. The implant has good stability and the majority of it is in good bone; placement of a membrane could lead to infection and loss of bone. (B) Larger dehiscences such as that on the lower left implant may require grafting to encourage bone coverage of the exposed threads. Because the threads are outside the labial cortex, a membrane would tend to collapse onto the threads, thus reducing the amount of bone formed. Support for the membrane to maintain volume should be sought, therefore, by the use of a titanium-reinforced membrane or preferably using bone chips under the membrane. *Abbreviation:* GBR, guided bone regeneration.

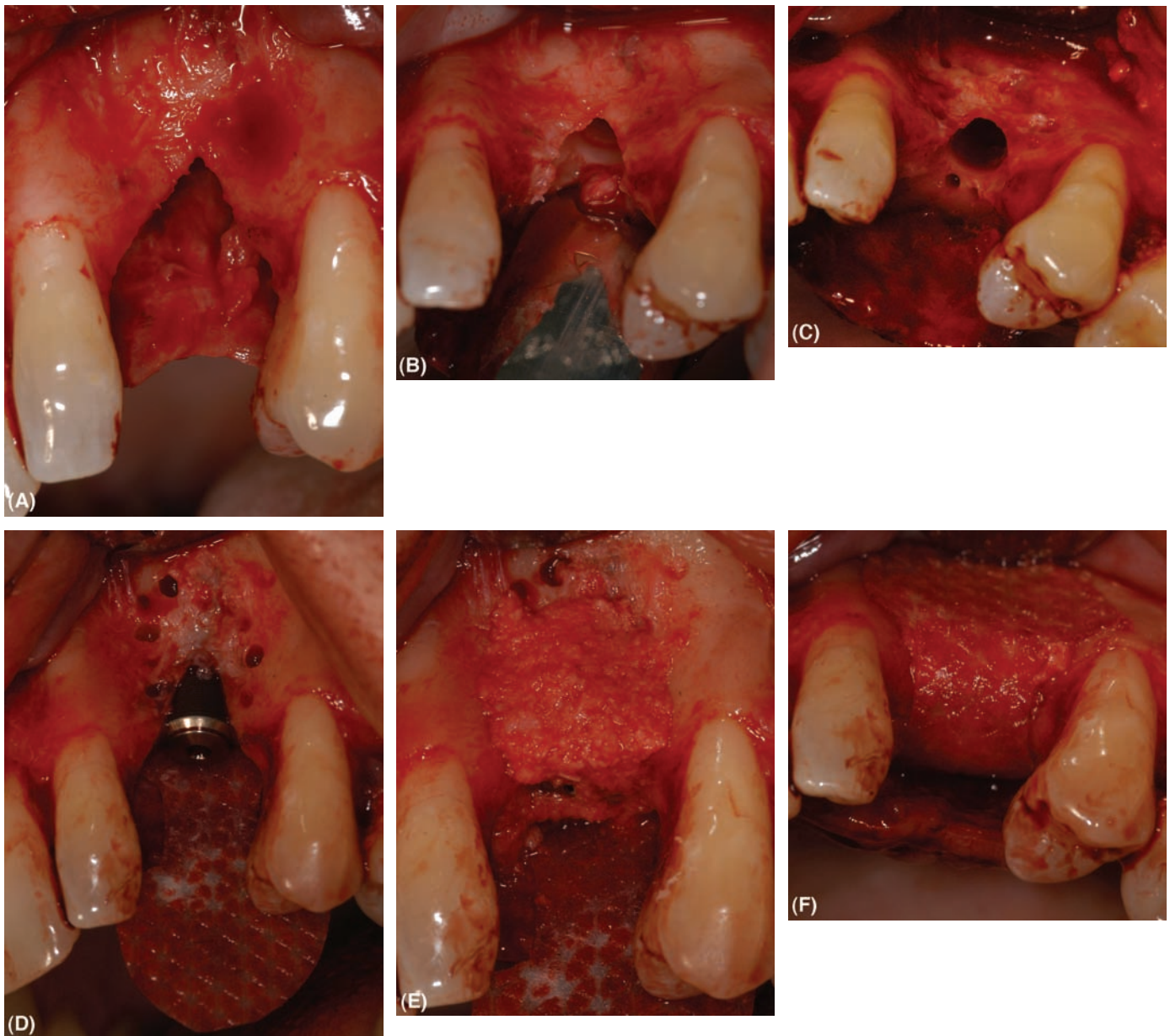
developed to allow ridge height augmentation over limited spans and subsequent implant placement.

### Nerve Transpositioning/Obliteration

Loss of alveolar height in the posterior mandible will eventually compromise implant placement unless the mandible is wide buccolingually and space exists to place an implant to one side of the nerve. In the majority of cases, this is not possible and the operator is left with several other options. Placement of multiple short implants may provide enough support without compromising the restoration biomechanically. Achieving stability of the implants may be difficult because the cancellous bone in this region is often sparse

(Fig. 12.26). Placing implants anterior to the mental foramen and cantilevering distally has been used with great success and is appropriate in cases with well-spaced implants of good length and in the presence of a favorable occlusion. Onlay grafts may also be used in this situation (Fig. 12.27) by reducing the height of the restoration.

The alternative is to surgically expose the inferior dental bundle and to move it buccally to allow implant placement through the bulk of the mandible and thus achieve bicortical stabilization. This is a difficult procedure and the potential morbidity, in particular anesthesia or paresthesia of the mental nerve, should be explained fully to the patient. Good exposure of the mandible is required, with complete dissection of the mental nerve as it exits from the body of the mandible. The



**Figure 12.23** A series of clinical photos to show the management of a small dehiscence. This was undertaken to improve the overall ridge profile and to minimize the chances of the implant showing through the overlying thin mucosa. (A) An upper left canine site with significant loss of crest height and buccopalatal width. (B) The site has been prepared to accept an Astra Tech 4.5 ST implant accepting some exposure of the implant surface in the coronal portion. (C) The surrounding bone has been perforated with a round bur. (D) The implant in situ showing the exposed implant surface. A Resolut® (W.L. Gore & Associates Inc.) resorbable membrane has been trimmed to cover the buccal and palatal voids. (E) Osseous coagulum recovered from the osteotomy site has been compacted against the exposed implant surface. (F) The membrane is molded over the ridge to maintain the desired ridge form—the membrane is being supported peripherally by sound bone and from beneath by the implant and osseous coagulum. (G) Hermetic closure with resorbable sutures.

buccal plate is then gently removed with burs and irrigation to facilitate moving the nerve to the buccal aspect over the required distance. The implants can be inserted and the nerve placed back in close proximity to them.

The only other neurovascular bundle that commonly compromises implant placement is the incisive nerve in the premaxilla. This can be very large and can limit ideal placement of an implant in either of the central incisor spaces. Removal of the bundle and packing of the canal with bone

graft can render this site amenable to treatment after a three-month healing period (Fig. 12.28).

### SOFT TISSUE GRAFTING TECHNIQUES

The soft tissues around implants serve a functional role as well as an aesthetic one. Aesthetic problems are commonly diagnosed at the planning stage of treatment and their management may be carried out alongside the implant treatment.

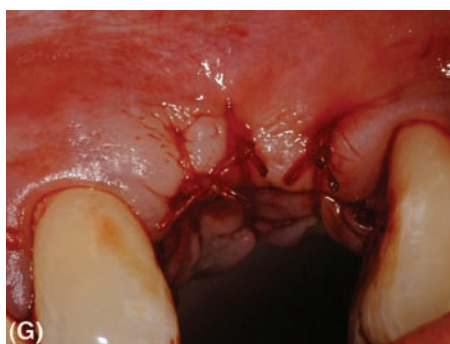

Figure 12.23 (Continued)



**Figure 12.24** A selection of Astra Tech osteotomes for dilation at isolated implant sites. The bandings correspond to the implant lengths available in this system. When used at multiple sites they can be used to further expand and split the alveolar ridge mesially and distally. Great care is required using this technique and case selection is very important.

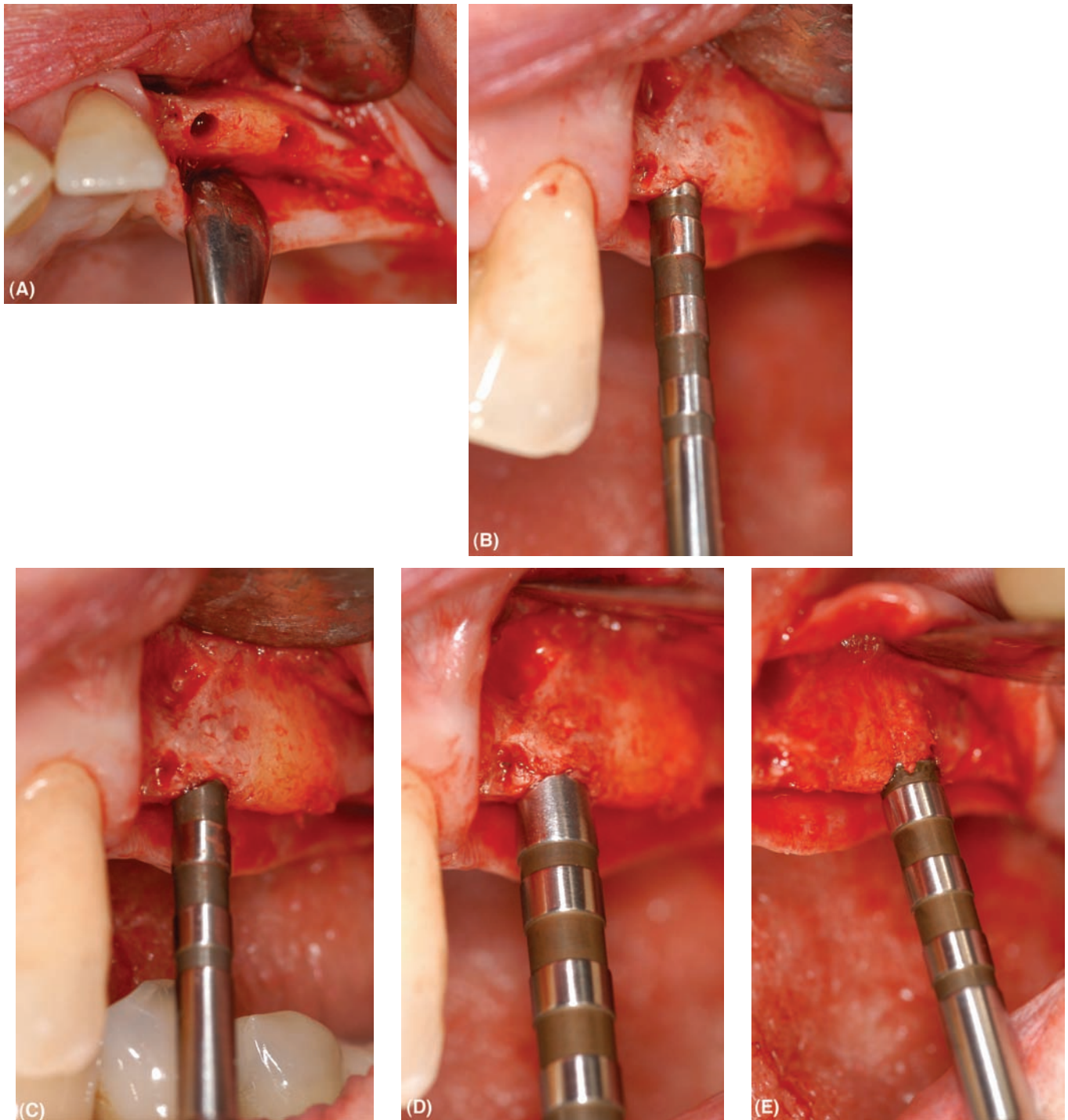
Functional problems often appear once the implant prosthesis is in situ and are frequently managed as a separate entity.

### Functional Soft Tissue Problems

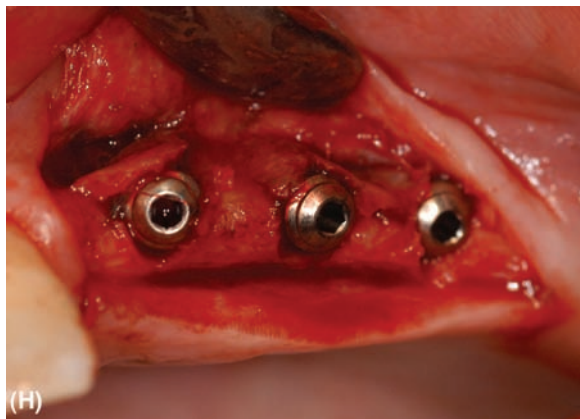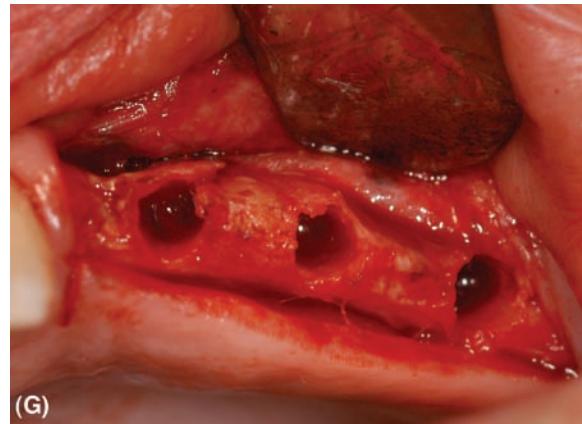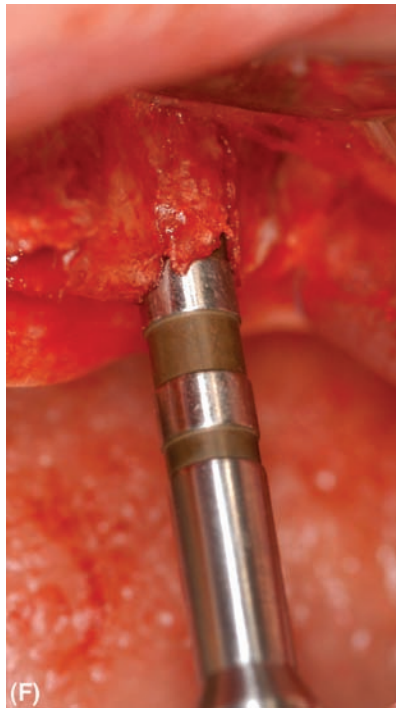
The peri-implant soft tissues have the same functional demands placed upon them as those around the natural dentition. They are therefore required to withstand the trauma of oral hygiene practices and forces placed upon them during mastication. It is therefore preferable to have implants emerging through nonmobile keratinized mucosa. The severely

resorbed edentulous mandible is frequently devoid of attached mucosa, and implants in such cases are prone to soft tissue inflammation and reactive hyperplasia. Recurrent problems associated with mobile and inflamed soft tissues are best treated by the placement of free gingival grafts taken from the palate and sutured to a prepared vascular bed around the implant in the same way as would be performed around a tooth (Figs. 12.29 and 12.30).

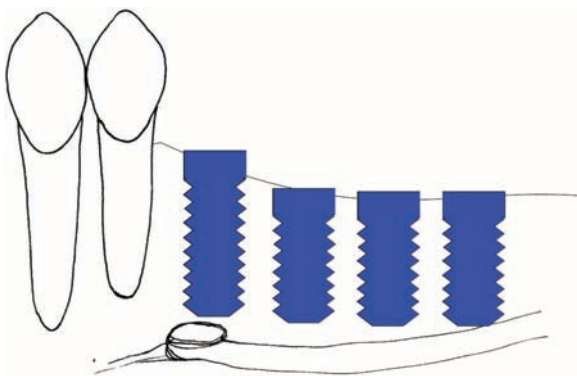
Care must be taken to immobilize the graft during healing, which can be difficult to achieve in sites with a shallow sulcus. The use of interpositional connective-tissue



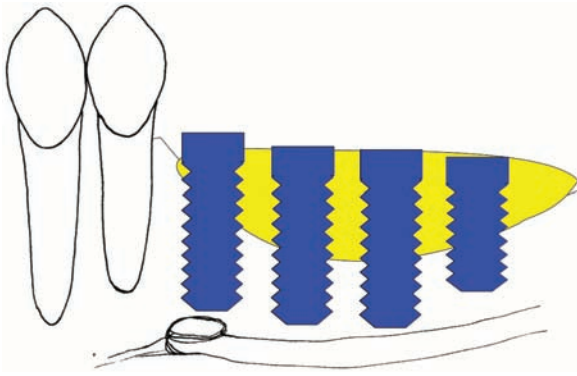
**Figure 12.25** A series of clinical photographs showing Astra Tech osteotomes used to expand the maxillary ridge in a patient with developmentally missing teeth resulting in a very narrow ridge profile. **(A)** The sites have been initially prepared through the cortical crestal bone with a guide drill and 2-mm twist drill. **(B)** A 2-mm-diameter osteotome is introduced and gently tapped and/or rotated apically to expand the bone. **(C)** The osteotome is manipulated to the desired implant length. Note how far the osteotome has now advanced apically. **(D)** A 2.0/3.2-mm-diameter osteotome is then used at crestal level followed by a parallel sided 3.2-mm osteotome that is again gently advanced apically. **(E)** The distal sites are prepared in the same way. Note how the osteotome in this site has to have a more buccal emergence due to the alveolar profile that is present. **(F)** The 3.2-mm-diameter osteotome has been advanced to 13 mm. **(G)** The completed osteotomy sites. Note that there has been mild fracturing of the buccal cortex of the two anterior sites. This is a common occurrence as the palatal bone tends to be stronger than the buccal and is less prone to fracturing. **(H)** The implants in place showing no exposed implant surfaces. Good initial stability can be expected with careful planning and a gentle technique.



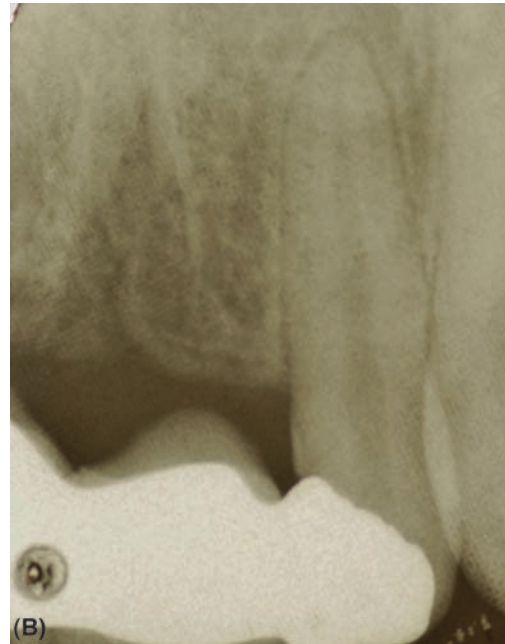
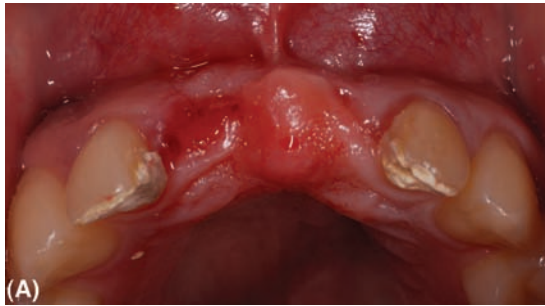**Figure 12.25** (Continued)



**Figure 12.26** With restricted height available above the inferior dental canal, the use of multiple short implants may be advocated. Achieving initial implant stability in such situations can be difficult to achieve because there is often poor cancellous bone and it is not possible to engage the apices of the implants in cortical bone. The need to leave a safe margin of error between the length of the drills and the canal usually means leaving the implants 3 mm short of the canal, in contrast to the distal implant in the figure.



**Figure 12.27** The use of an onlay graft allows the placement of longer implants and reduces the height of the prosthesis. The implants engage the superior cortex of the mandible aiding their stability at the time of placement.



**Figure 12.28** A series of photographs showing nerve removal and canal obliteration of the maxillary incisive canal. (A, B) Preoperative views showing the large incisive papilla and the large radiolucency on the intraoral radiograph. Insufficient space is available to predictably place implants into the central incisor sites. (C) Buccal and palatal mucoperiosteal flaps have been raised to expose the incisive canal and nerve that is held under tension. (D) The nerve is removed with hand instruments and the canal is curetted to its full depth to remove any residual soft tissue remnants. (E) Bone chips harvested from the retromolar area with a Safescraper® TWIST are placed into the void and compacted (E, F). (G) Soft tissue closure is achieved without the use of a membrane as the graft is within the bony contour and is protected by the overlying periosteum. Note that the crestal incision has been placed toward the buccal aspect of the crest to keep it remote from the graft site. (H) Postoperative radiograph to show increased density of bone in the incisive canal region.

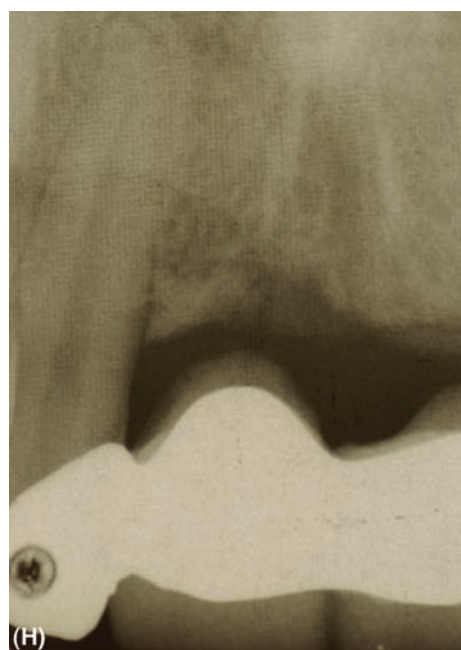
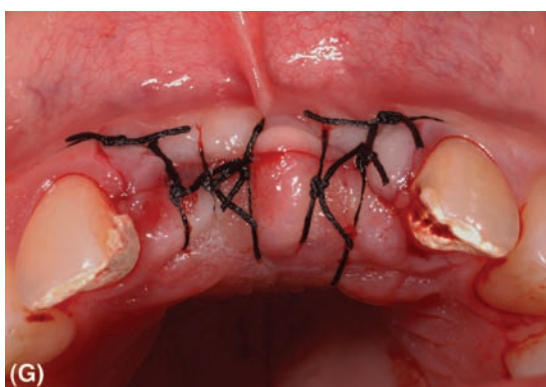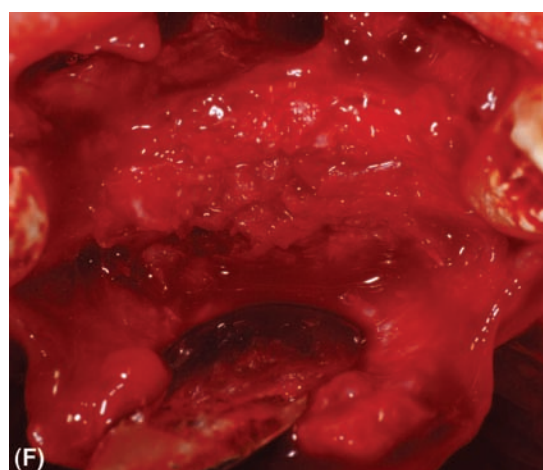
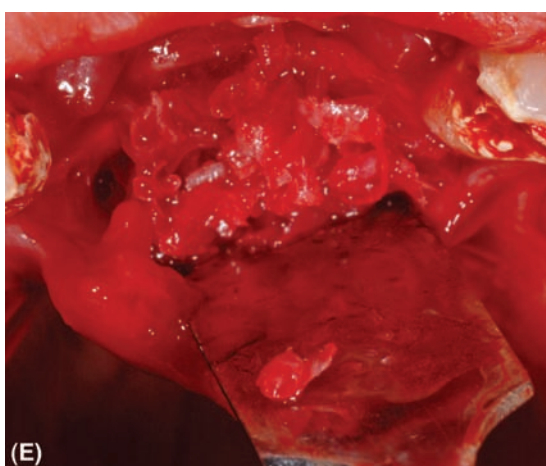
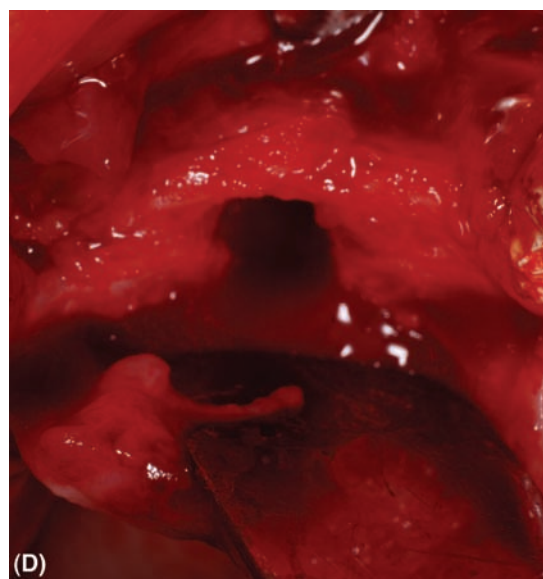
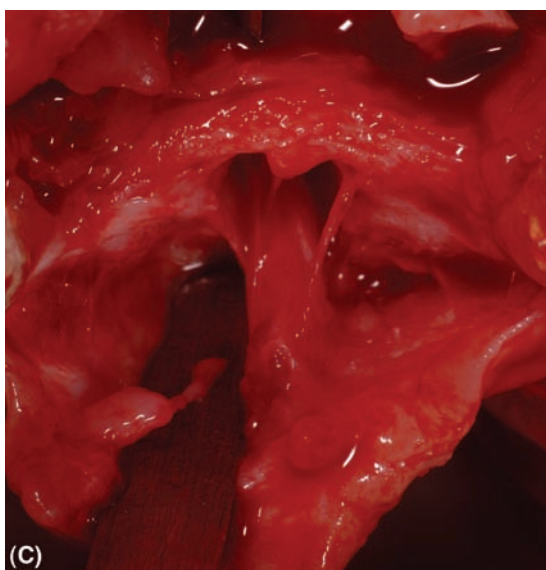
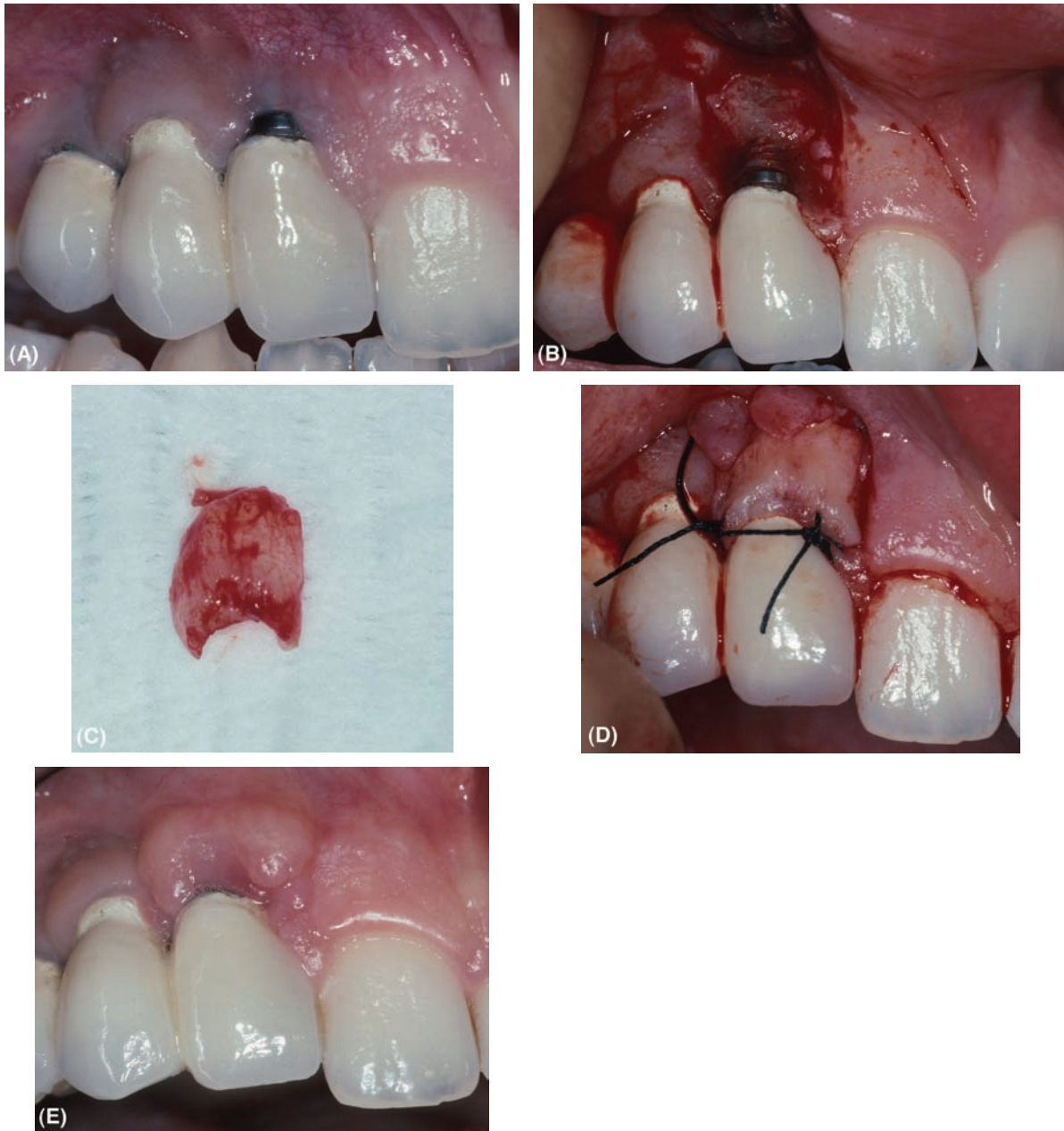
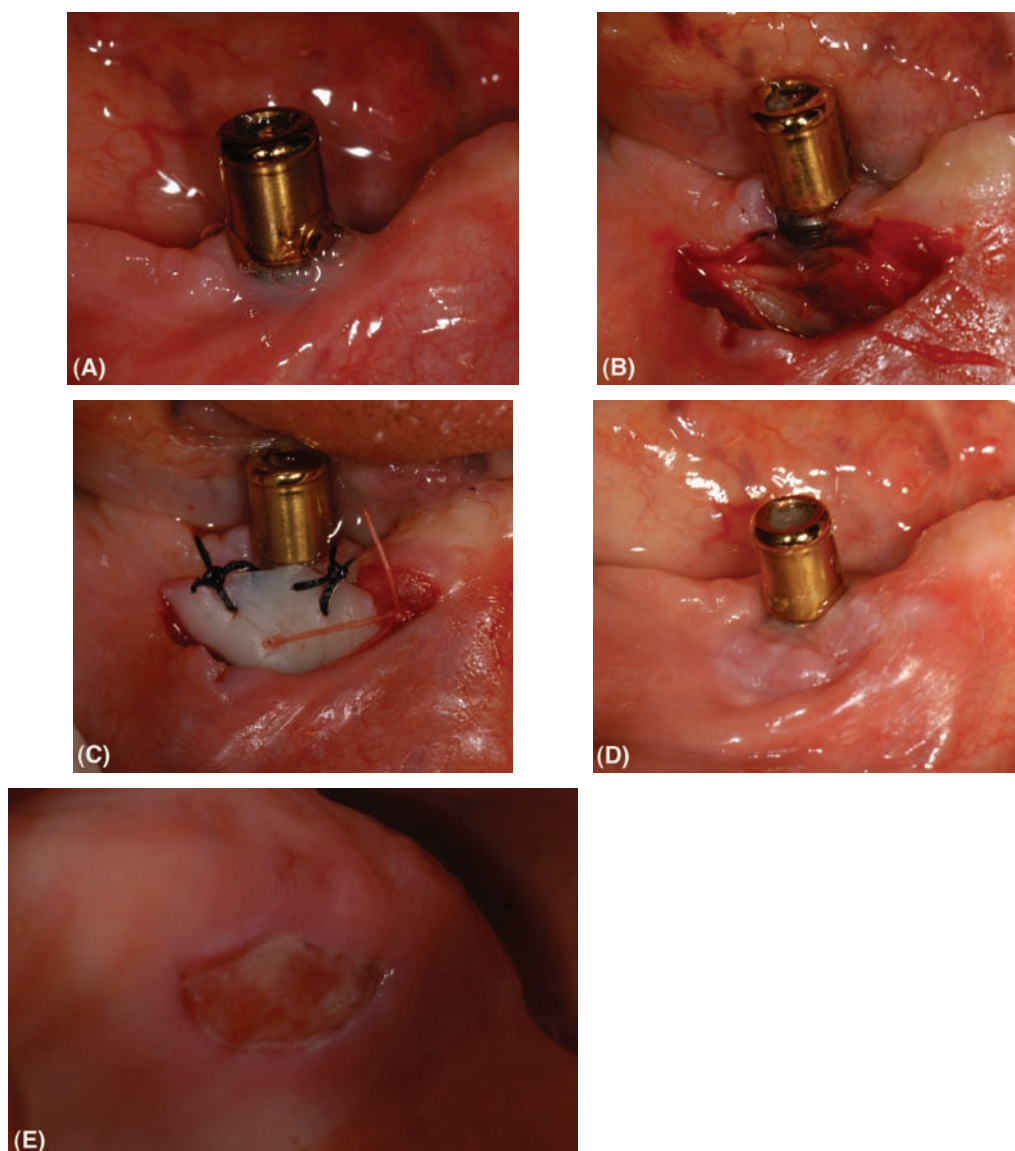


Figure 12.28 (Continued)



**Figure 12.29** (A) The lack of attached gingiva around the abutment of the upper right lateral incisor presents an aesthetic problem for the patient (despite a low smile line) but also prevents good oral hygiene due to the thin friable nature of the mucosa; a soft-tissue graft is therefore indicated. (B) A split-thickness flap is raised to include a sound margin of tissue for the graft bed, leaving the papillae intact. (C) The connective-tissue graft is harvested from the palate and trimmed to the correct shape and size. Some shrinkage should be allowed for and so the graft should be kept slightly larger than is required for the final result. By harvesting via an epithelial longitudinal incision, a cuff of epithelial tissue can be incorporated into the graft. (D) The graft is laid into position and held in place with sutures, ensuring good coverage of the abutment. Note that the epithelialized cuff has been placed around the abutment, with the connective tissue extending apically. (E) Two weeks postoperatively, the increase in bulk of the tissues is obvious. The increased width of attached gingival and coverage of the abutment has been achieved. Further maturation will result in a smoother overall gingival profile.

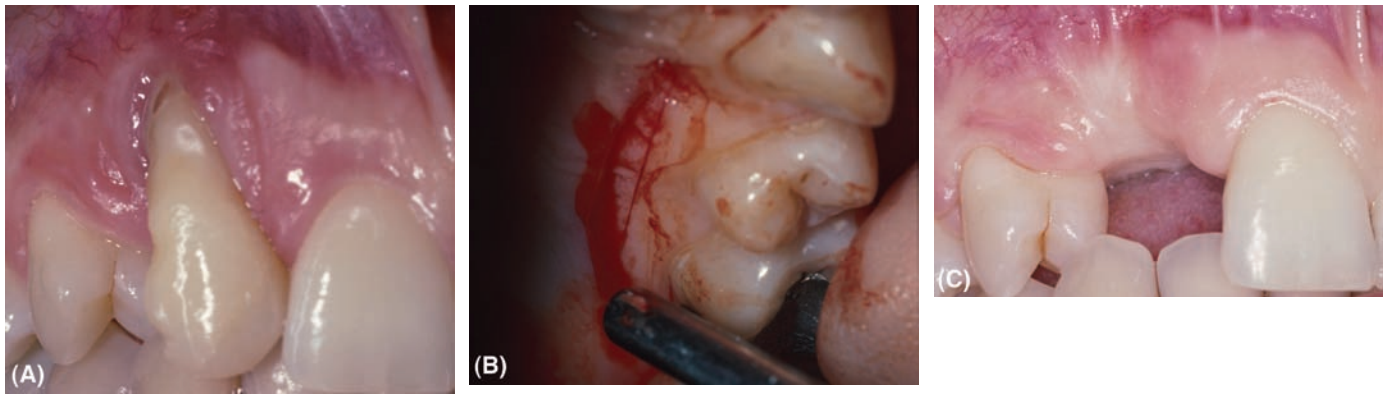


**Figure 12.30** A series of photos to show a free gingival graft to improve the soft tissues around a lower overdenture abutment. (A) Preoperative situation—the lack of attached keratinized mucosa and shallow sulcus are evident. (B) The recipient bed has been prepared using split-thickness dissection leaving periosteum on the underlying bone. (C) A free gingival graft taken from the palate has been stabilized using a deeply placed resorbable suture to the underlying soft tissues. (D) Healing one week later showing an increased band of attached keratinized mucosa and deeper sulcus with a lack of soft tissue pull. (E) The healing donor site in the palate at one week.

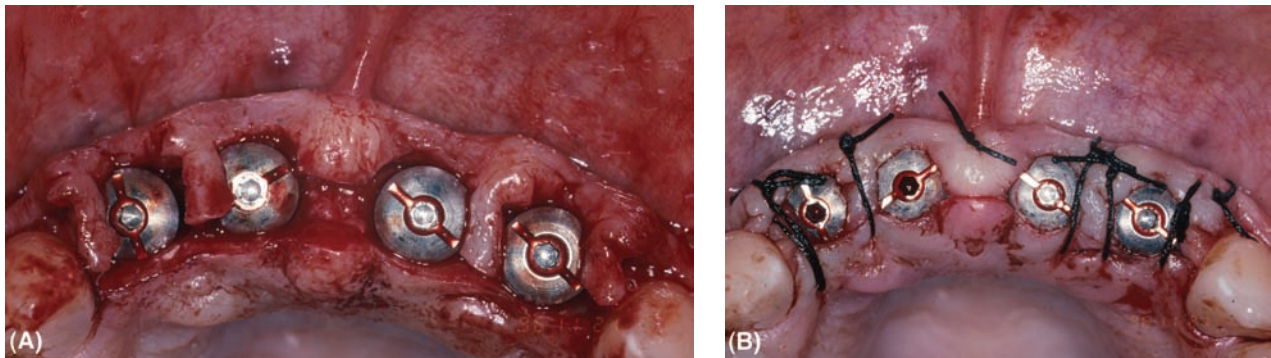
grafts may also provide a more stable and robust gingival margin around the implant. Free gingival and connective-tissue grafts may be used in this way at any stage of implant treatment: preimplant placement, at abutment connection or once the prosthesis is in place. If grafting is required after the prosthetic phase is complete, it may be necessary to remove the prosthesis, bury the implant, and graft the site and then bring the abutment through the attached mucosa once healing has taken place.

### Aesthetic Soft Tissue Problems

Small soft tissue defects, which may also be associated with a bone deficiency, may be considered unaesthetic at the initial evaluation and treatment planning stage, but it should be remembered that such defects will often be rectified once the prosthetic components are emerging through the mucosa. Soft tissue maturation occurs around implants, particularly around lone-standing single tooth implants with adjacent natural teeth. This is optimized by good implant placement, allowing



**Figure 12.31** (A) Gross loss of buccal hard and soft tissues of the upper right canine dictates that grafting of this site is required to achieve an acceptable aesthetic result. The loss of soft tissue is the biggest problem in such cases, particularly the entire loss of the attached gingiva. Placement of a connective-tissue graft at the time of extraction will replace the lost tissues. (B) Connective-tissue grafts are readily obtained from the palatal soft tissues by employing a filleting technique via a limited incision. (C) Two months postoperatively there is a good width of attached gingiva. The height of the adjacent tissues will retain the profile during the healing phase. Once an implant is emerging through the gingival complex, further restoration of the buccal profile will be achieved.



**Figure 12.32** (A) By careful manipulation of the soft tissues at stage II surgery, the gingival morphology may be optimized and the attached gingival preserved. (B) Suturing of the flaps allows for healing by primary intention. The use of vertical mattress sutures, as shown in the midline papilla, maintains the height of the papillary tissues.

a natural emergence profile of the restoration as well as careful soft tissue handling at all stages of treatment.

Larger defects need to be rectified surgically and this can be achieved readily using free gingival grafts and interpositional connective-tissue grafts in combination with hard tissue augmentation for the more severe defects. Such techniques are usually best performed before or at the time of implant placement to achieve the best results (Fig. 12.31). Once again, the use of the patient's own tissue is preferable to any of the other graft materials available.

Papillary preservation or interdental papillary regeneration has been widely advocated; the degree to which this is possible is open to question, but the basis of the technique, careful soft tissue manipulation and the preservation of as

much keratinized tissue as possible, will undoubtedly maximize the soft tissue healing potential (Fig. 12.32).

## BIBLIOGRAPHY

- Andersson B, Odman P, Widmark G, et al. Anterior tooth replacement with implants in patients with a narrow alveolar ridge form. A clinical study using guided tissue regeneration. *Clin Oral Implants Res* 1993; 4:90-98.
- Becker ST, Terheyden H, Steinriede A, et al. Prospective observation of 41 perforations of the Schneiderian membrane during sinus floor elevation. *Clin Oral Implants Res* 2008; 19:1285-1289.
- Bloomqvist JE, Alberius P, Isaksson S. Retrospective analysis of one stage maxillary sinus augmentation with endosseous implants. *Int J Oral Maxillofac Implants* 1996; 11:512-521.

- Bornstein MM, Chappuis V, von Arx T, et al. Performance of dental implants after staged sinus floor elevation procedures: 5-year results of a prospective study in partially edentulous patients. *Clin Oral Implants Res* 2008; 19:1034-1043.
- Burkhardt R, Joss A, Lang NP. Soft-tissue dehiscence coverage around endosseous implants: a prospective cohort study. *Clin Oral Implants Res* 2008; 19:451-457.
- Chiapasco M, Zaniboni M. Clinical outcomes of GBR procedures to correct peri-implant dehiscences and fenestrations: a systematic review. *Clin Oral Implants Res* 2009; 20(suppl 4):113-123.
- Chiapasco M, Zaniboni M, Boisco M. Augmentation procedures for the rehabilitation of deficient edentulous ridges with oral implants. *Clin Oral Implants Res* 2006; 17(suppl 2):136-159.
- Dahlin C, Lekholm U, Becker W, et al. Treatment of fenestration and dehiscence bone defects around oral implants using the guided tissue regeneration technique: a prospective multicenter study. *Int J Oral Maxillofac Implants* 1995; 10:312-318.
- Esposito M, Grusovin MG, Felice P, et al. Interventions for replacing missing teeth: horizontal and vertical bone augmentation techniques for dental implant treatment. *Cochrane Database Syst Rev* 2009; (4): Art. No: CD003607. DOI: 10.1002/14651858.CD003607.pub4.
- Esposito M, Grusovin MG, Rees J, et al. Interventions for replacing missing teeth: augmentation procedures of the maxillary sinus. *Cochrane Database Syst Rev* 2010; (3): Art. No: CD008397. DOI: 10.1002/14651858.CD008397.
- Ferrigno N, Laureti M, Fanali S. Dental implants placement in conjunction with osteotome sinus floor elevation: a 12-year life-table analysis from a prospective study on 588 ITI implants. *Clin Oral Implants Res* 2006; 17:194-205.
- Graziani F, Donos N, Needleman I, et al. Comparison of implant survival following sinus floor augmentation procedures with implants placed in pristine posterior maxillary bone: a systematic review. *Clin Oral Implants Res* 2004; 15:677-682.
- Kahnberg KE, Ekstubb A, Grondahl K, et al. Sinus lifting procedure. I. One-stage surgery with bone transplant and implants. *Clin Oral Implants Res* 2001; 12:479-487.
- Kahnberg KE, Nilsson P, Rasmusson L. Le Fort I osteotomy with interpositional bone grafts and implants for the rehabilitation of the severely resorbed maxilla: a 2-stage approach. *Int J Oral Maxillofac Implants* 1999; 14:571-578.
- Nkenke E, Radespiel-Troger M, Wiltfang J, et al. Morbidity of harvesting of retromolar bone grafts: a prospective study. *Clin Oral Implants Res* 2002; 13:514-521.
- Nkenke E, Schultze-Mosgau S, Radespiel-Troger M, et al. Morbidity of harvesting of chin grafts: a prospective study. *Clin Oral Implants Res* 2001; 12:495-502.
- Nkenke E, Stelzle F. Clinical outcomes of sinus floor augmentation for implant placement using autogenous bone or bone substitutes: a systematic review. *Clin Oral Implants Res* 2009; 20(suppl 4): 124-133.
- Palmer RM, Floyd PD, Palmer PJ, et al. Healing of implant dehiscence defects with and without expanded polytetrafluoroethylene membranes: a controlled clinical and histological study. *Clin Oral Implants Res* 1994; 5:98-104.
- Pjetursson BE, Ignjatovic D, Matuliene G, et al. Maxillary sinus floor elevation using the (transalveolar) osteotome technique with or without grafting material. Part I: implant survival and patients' perception. *Clin Oral Implants Res* 2009; 20:667-676.
- Pommer B, Tepper G, Gahleitner A, et al. New safety margins for chin bone harvesting based on the course of the mandibular incisive canal in CT. *Clin Oral Implants Res* 2008; 19:1312-1316.
- Thoma DS, Benic GI, Zuhlen M, et al. A systematic review assessing soft-tissue augmentation techniques. *Clin Oral Implants Res* 2009; 20(suppl 4):146-165.
- van Steenberghe SD, Molly L, Jacobs R, et al. The immediate rehabilitation by means of a ready-made final fixed prosthesis in the edentulous mandible: a 1-year follow-up study on 50 consecutive patients. *Clin Oral Implants Res* 2004; 15:360-365.
- von Arx AT, Buser D. Horizontal ridge augmentation using autogenous block grafts and the guided bone regeneration technique with collagen membranes: a clinical study with 42 patients. *Clin Oral Implants Res* 2006; 17:359-366.
- Weibull L, Widmark G, Ivanoff CJ, et al. Morbidity after chin bone harvesting a retrospective long-term follow-up study. *Clin Implant Dent Relat Res* 2009; 11:149-157.
- Wikesjo UM, Qahash M, Thomson RC, et al. rhBMP-2 significantly enhances guided bone regeneration. *Clin Oral Implants Res* 2004; 15:194-204.
- Young MP, Worthington HV, Lloyd RE, et al. Bone collected during dental implant surgery: a clinical and histological study. *Clin Oral Implants Res* 2002; 13:298-303.

## Single tooth implant prosthodontics

### INTRODUCTION

Prosthodontic treatment is not just restricted to the final stage of implant treatment. The treatment planning chapter will have demonstrated the need for the correct decision to be taken regarding the suitability of implant treatment over conventional techniques and the desirability for a clear view of the desired end result prior to implant placement. The importance of realistic diagnostic wax-ups or trial restorations and the use of surgical stents cannot be overemphasized. It is also essential that provisional restorations that can function and be adapted during the stages of implant placement and exposure be provided. Whether one operator provides the implant treatment from start to finish or if different dentists are undertaking the surgical and prosthodontic stages, prosthodontic input from the start is mandatory.

In many respects the prosthodontic treatment for a single tooth is straightforward if the planning and placement of the implant is correct. However, if prior assessment of the situation or implant positioning is poor, the prosthodontic correction of the error to achieve an acceptable result can be impossible. Restoration of single tooth implants can therefore be the easiest and the most demanding of all implant restorations. The choice of the appropriate single tooth abutment is one of the most important prosthodontic factors, and this is dealt with in subsequent sections.

### ABUTMENT TYPES

All manufacturers produce a variety of abutments suitable for single tooth restorations. Abutments attach the crown to the implant and prevent rotation between components. Many different types are required to allow for variations in such factors as implant position, angulations, depth, and soft tissue contours, and still achieve an aesthetic end result. The final restoration needs the correct emergence profile to support and contour the soft tissue. This may require a transition from a standard 4-mm-diameter implant to the 7-mm-wide neck of a central incisor tooth within the vertical dimension of only a few millimeters (Fig. 13.1). The abutment needs to resist conventional compressive and tensile loads and rotational forces, as it will not be joined to other implants or teeth. There are few situations in which it is acceptable for a single tooth restoration to show metal at the gingival margin and so there must be adaptability in the abutment design to allow for an aesthetic margin placement. Most anterior single tooth restorations will be cemented onto the abutment and this will get over any problems there may be with labial paths of insertion.

Abutments for single tooth restorations fall into the following categories (Table 13.1):

- Standard abutments (readymade)
- Semiprepared abutments
- Fully customized abutments

- Computer-generated abutments [computer-aided design (CAD)/computer-aided manufacture (CAM)]
- Preparable abutments
- Abutments for screw-retained crowns

Abutments can also be classified by the material they are made from, such as gold, titanium, and ceramic. Specific abutments are also made for permanent and provisional use.


### Standard Abutments

Most implant manufacturers have a premade abutment normally made of titanium. Standard abutments are designed to be used as made by the manufacturer without modification. They are therefore normally symmetrical with a flat fixed gingival margin for the restoration and a set vertical height. As they are designed for single tooth restorations, they have a flat facet on the retentive element of the abutment to prevent rotation of the final crown. This lack of flexibility makes them unsuitable for high aesthetic areas but straightforward to use where aesthetics are not important or in ideal clinical situations. They have the advantage of simplicity, cost effectiveness, and limited laboratory input required. Standard abutments can only be used for cemented restorations.

They are usually two pieces with an abutment that fits onto/into the implant head and a separate abutment screw that can be titanium alloy or gold alloy. A variety of heights are offered with a smooth collar that extends from the implant head to the margin for the crown. Matched impression copings, temporary copings, laboratory analogues, and gold and porcelain cylinders are produced to ease manufacture. The standard technique is illustrated in Figure 13.2.

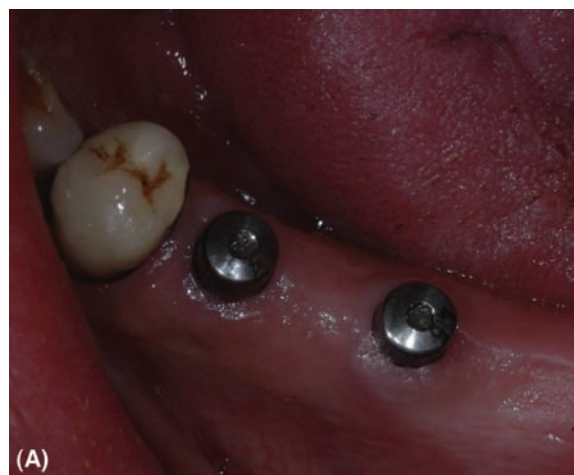For the Nobel Biocare external hex implant, the abutment fits onto the flat top and engages the raised hexagon to give antirotation for the abutment. As with all flat-top implant designs, it is essential that the abutment properly seats onto the implant head, so a verification radiograph is required (Fig. 13.3). The abutment is retained to the implant by a gold alloy screw that is torqued into position at 32 Ncm for a regular platform implant, once seating has been confirmed. To achieve this exact level of torque, a mechanical device such as an electronic or manual torque controller is essential (Figs. 13.2D and 13.20B). Narrow platform implant abutment screws are normally tightened to 20 Ncm and wide platform abutment screws to 45 Ncm.

With conical connection implants (e.g., Astra Tech, Frialit, Nobel Biocare, and Straumann), the abutments have a matched conical fit surface and also an internal antirotational element to give the abutment resistance to rotational forces. Although these implant/abutment connections are self-guiding and easy to engage, it is essential that the abutment is held and rotation attempted prior to tightening the screw to ensure that the abutment is fully seated. A verification radiograph is not usually required but may be used if there is any doubt that the abutment has not seated properly.



**Figure 13.1** Selection of abutment height. (A) A short abutment collar places the margin deeper in the soft tissues but allows more height for development of a suitable emergence angle compared to a longer-abutment collar height (B).

The coronal part of single tooth abutments needs to provide adequate retention and resistance form for the crown to be retained by cement to the abutment. They are usually cylindrical in shape, either parallel sided or with a slight taper. A flat facet is required to provide resistance to rotation. The precision of fit for these restorations, in particular using the matched gold cylinders, is such that difficulty can be encountered cementing them into position and cements with a low viscosity or the provision of a vent hole may be required. The fixed size of the retentive element for the crown makes these abutments unsuitable for extremes of interocclusal space, particularly if the space is under 7 mm when there will be inadequate space for the crown. Similarly, if there has been extensive bone loss prior to implant placement so there is



**Figure 13.2** Two lower molar implants restored using standard direct abutments from Astra Tech. (A) Healing abutments in position. (B) The restorative kit includes the abutment, impression copings, replicas, and cylinders to make the crown and a temporary restoration. (C) The abutments are placed using a holder. (D) A torque wrench is used to tighten the abutments. In this case, a level of 25 Ncm is achieved. (E) The abutments in position. Note the margin for the restoration is just supragingival as the appearance is not paramount. (F) From the occlusal surface the flat facets on the abutment are visible. These act as antirotation for the restoration. (G) Push-on impression copings in place. (H) The impression copings are picked up in Impregum using a closed tray technique. (I) The abutment replicas are attached. (J) A temporary restoration is simply fabricated in the mouth. For simplicity, this is linked at this stage. (K) A master cast is made with a detachable silicone gingival replica. (L) Conventional metal-ceramic crowns on the working cast. (M) Separate crowns have been made to make cleaning easier. (N) The crowns cemented in place. (O) From the occlusal surface. (P) The completion peri-apical radiograph.

excessive interocclusal space (over 12 mm), then the crown may not have adequate retention as the ratio between retentive height and length of restoration is unfavorable.

The abutments are designed to be positioned and left in place while the permanent crown is being made. Therefore, a temporary restoration normally has to be made at the chairside.

**Table 13.1** Examples of Abutment Types

Type	Name	Manufacturer
Standard abutment	Snappy abutment	Nobel Biocare
	Direct abutment	Astra Tech
	Cementable abutment	Straumann
Semi Prepared abutments	Ti Design/Zir design	Astra Tech
	Esthetic abutment	Nobel
	Anatomic abutment	Straumann
Fully customized abutment	AurAdapt	Nobel Biocare
	Cast design abutment	Astra Tech
	Gold abutment	Straumann
Computer-generated abutment	Procera	Nobel Biocare
	Atlantis	Astra Tech
	CARES	Straumann
Screw-retained crown abutment	Gold adapt	Nobel Biocare
	Cast design	Astra Tech

Astra Tech, Astra Meditec AB, Mölndal, Sweden; Friatec AG, Mannheim, Germany; Nobel Biocare, Nobel Biocare AB, Göteborg, Sweden; Straumann, Institut Straumann AG, Waldenburg, Switzerland.

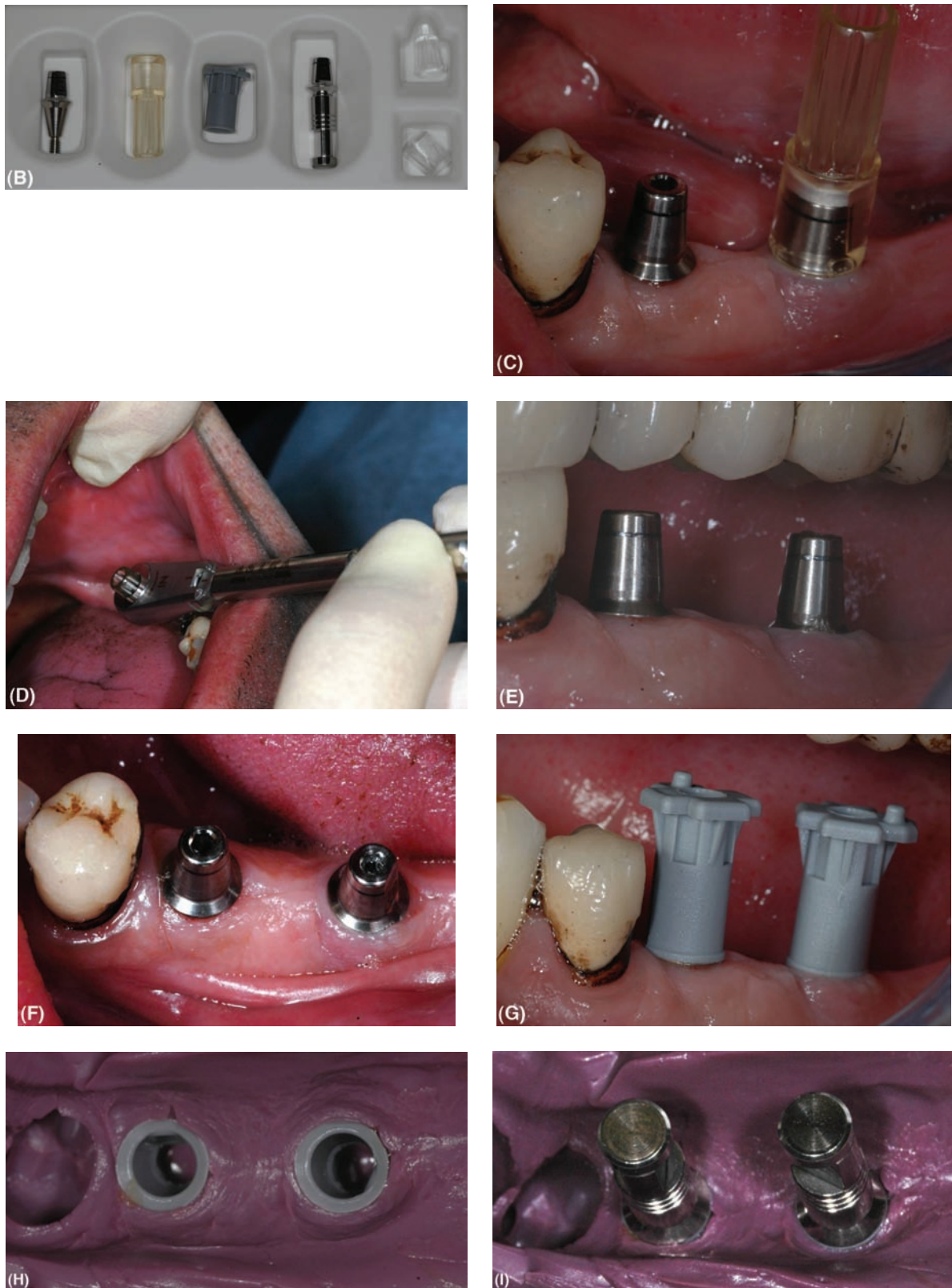

Figure 13.2 (Continued)

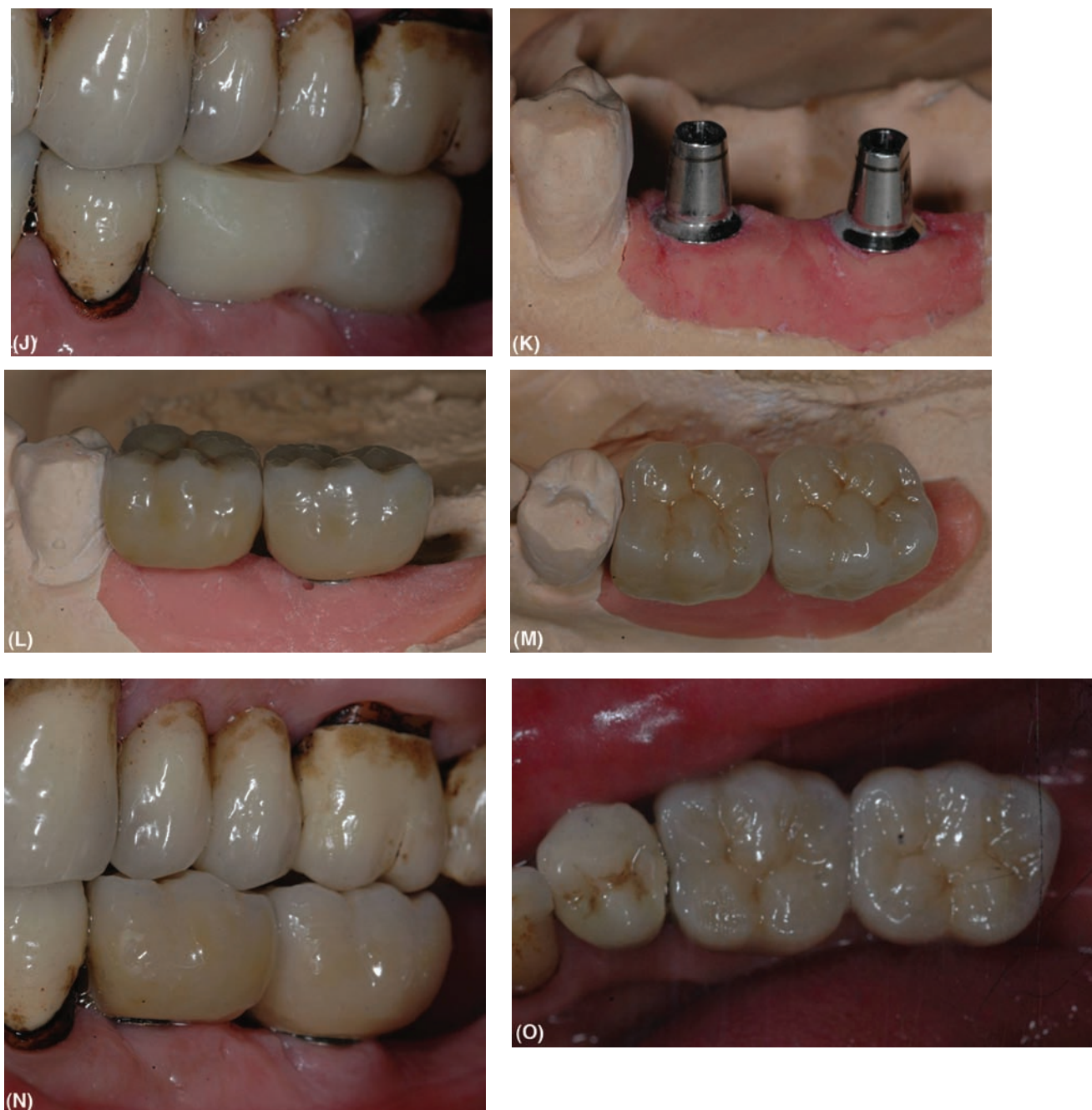

Figure 13.2 (Continued)

There are matched impression copings that are simple push-fit plastic cylinders that can be picked up in an impression material (Fig. 13.4). The gold cylinders provided are designed to have wax built up to a contour necessary for a conventional metal-ceramic crown. Alternatively, plastic “burnout” copings are available that produce a similar result. Some manufacturers produce porcelain copings onto which conventional porcelain can be fired or CAD/CAM techniques can be used for standard ceramic restoration production.

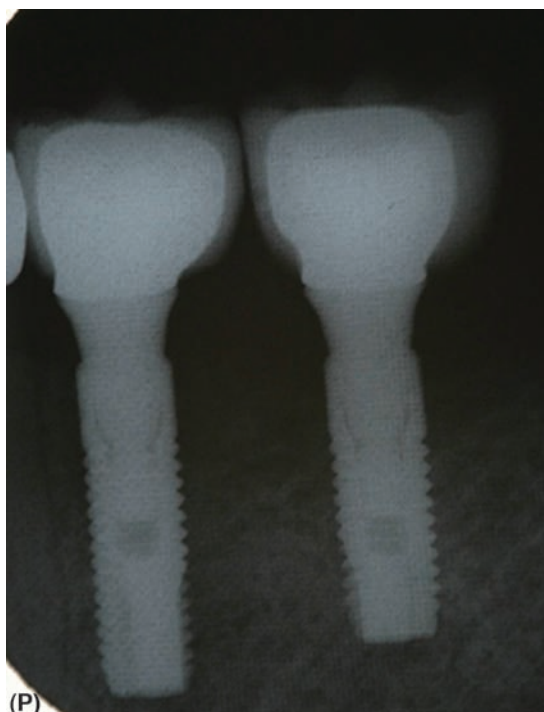#### *Advantages/Indications of Standard Abutments*

- Simple to use

- Minimal chairside and laboratory time
- Predictable fit and retention for crown
- Use in “straightforward” cases where optimal space and implant orientation has been achieved

#### *Disadvantages/Contraindications of Standard Abutments*

- Margin for crown does not follow gingival contour
- Cannot be customized for implant orientation or anatomical features—particularly not suited to very labially inclined implants
- Not suitable for multiple adjacent single tooth restorations as the path of insertion of the crowns is not adjustable.



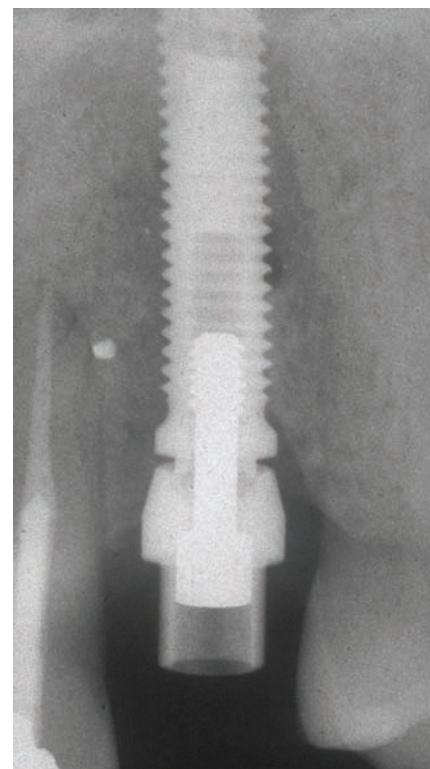
**Figure 13.2** (Continued)

Similarly, they are not suitable where the adjacent teeth are tilted for the same reason

- Not suitable for extremes of interocclusal space

### Customized Abutments

Customized abutments require laboratory input to shape them to optimize the abutment contour for the clinical situation. They can be classified into semiprepared, fully customized (cast or CAD/CAM), or preable. All share the feature of making the abutment more anatomic in shape and control the emergence of the crown through the soft tissue so that it is close to a natural tooth profile as possible. With a conventional abutment the entire restoration is circular in cross section at the implant head and through the abutment. The ideal contour is developed only from the start of the crown. With a customized abutment, the abutment itself can be modified to more accurately resemble the cross-sectional shape of a natural tooth (Fig. 13.5). For example, an upper central incisor tooth is roughly triangular in shape at the gingival level with a flat labial surface. If a circular abutment is put in position this will tend to either be under contoured mesiodistally, or if a larger size is used, it will push down the labial gingival margin in the center, making the clinical crown look longer. Customization also allows for differing paths of insertion between the restoration and implant so solving less than ideal implant positions (Fig. 13.6) and also allows multiple adjacent implants to be aligned so the crowns can be inserted independent to the angle of the implant (Fig. 13.7). Extremes of interocclusal space can also be accommodated by altering the height of the retentive component for the crown.

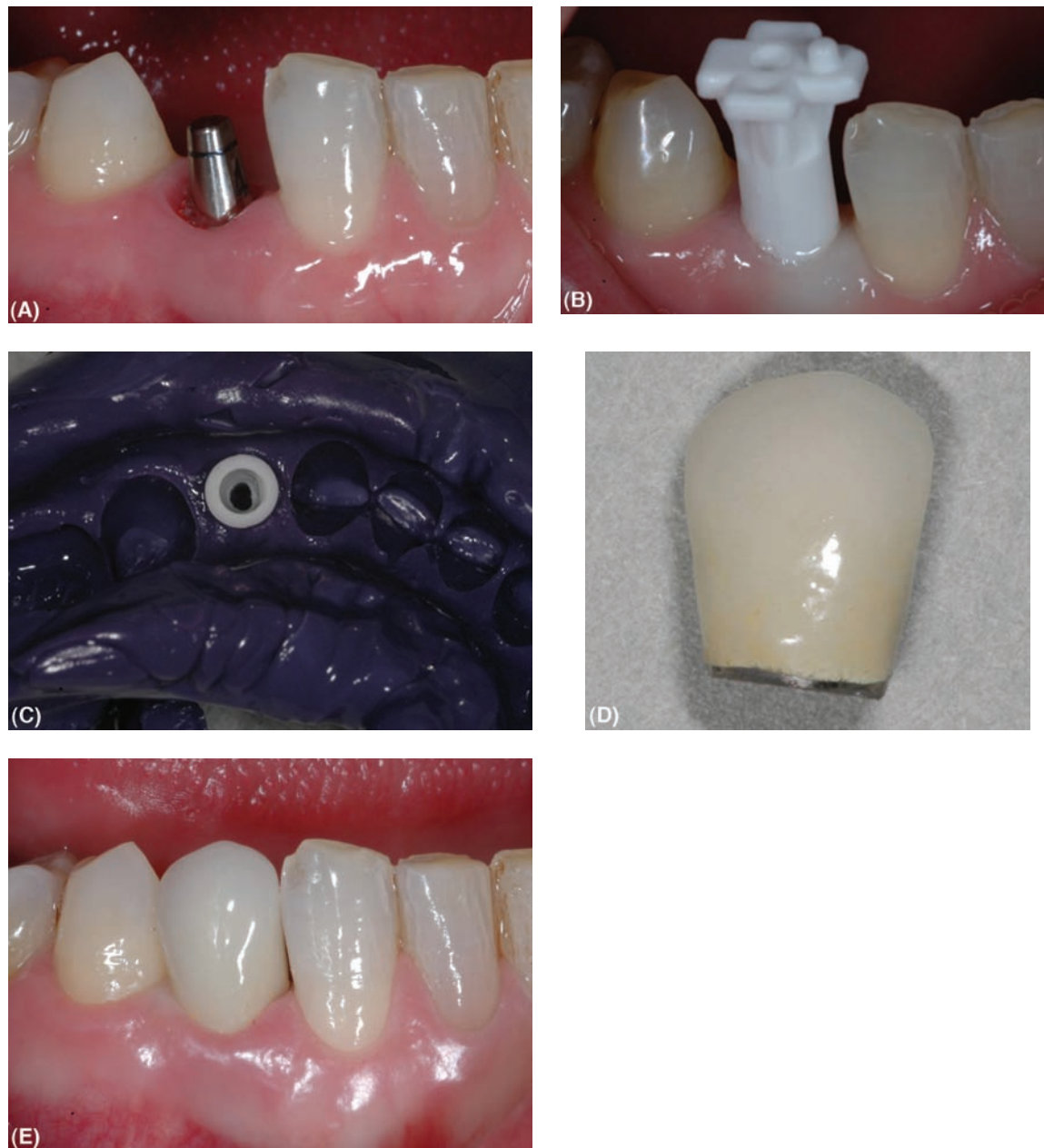

**Figure 13.3** A periapical radiograph demonstration failure to correctly seat a standard abutment onto an external hex Nobel Biocare implant.

### Semiprepared Abutments

These abutments are similar to standard abutments but have a more anatomic shape and are designed to be modified in the laboratory to customize the shape for differing clinical situations. The amount of alteration is limited by the bulk of material present at the start so the manufacturers make them in a variety of widths and heights to suit most clinical situations with minimal alteration. This includes abutments with angulation changes built in. The abutments have a contoured gingival margin to allow for a deeper margin on the labial aspect in the aesthetic zone and this can be further modified (Fig. 13.8). The coronal portion of the abutment can have the height reduced, but not added to, so the abutments may not be suitable for very long clinical crowns. The cross section of the abutment is circular, but this can be modified if required to a limited degree.

As with all customized approaches, the abutment selection and manufacture of the abutment are carried out on a model produced from an impression of the implant head. This is covered later in the chapter. Semiprepared abutments are two-piece with a separate abutment screw. The abutment chosen (many manufacturers have a dummy abutment try-in kit to simplify the choice) is screwed into the working model, and in the laboratory it is ground with drills to customize its shape. Normally, the abutment is then tried in to verify that the correct shape has been produced, in particular that the gingival margin is such that the crown margin will not show.

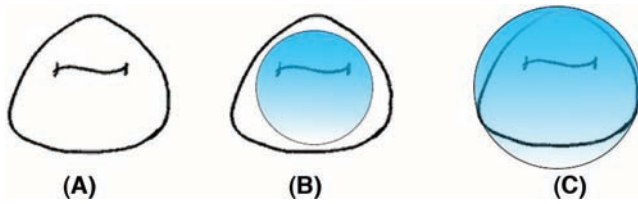


**Figure 13.4** A standard Direct abutment used to restore a lower canine Astra Tech implant. (A) Abutment in position. To give a good appearance the margins for the crown are about 1-mm subgingival. (B) The impression coping in place. (C) The impression coping is picked up in the impression. (D) A conventional metal-ceramic crown constructed. (E) The completed case.

Semiprepared abutments can be used in two ways:

1. Abutment prepared and final crown produced in one stage. This is acceptable for restorations where minor changes are being made to the implant orientation and the soft tissue is healthy and will remain stable. This technique ensures a good marginal fit between abutment and crown, as it does not require a second impression. There is a risk of a poor long-term result if the gingival margin is only placed just subgingivally, because if there is some recession of the gingival margin following cementation, some metal will then show. A margin for error with a slightly deeper margin placement is recommended. It is
2. Abutment prepared and provisional crown produced at first stage. A second impression is taken with the abutment in place and a final conventional crown made. More stages are required for this approach, but a more predictable result may be obtained. However, it can be difficult to take an impression of an abutment in position and deep margins pose a problem, as gingival retraction cord is hard to use. Acrylic copings can be made in advance and a pick-up technique employed. Alternatively, once the abutment has been deemed acceptable, it can be removed from the mouth and the crown framework produced directly on

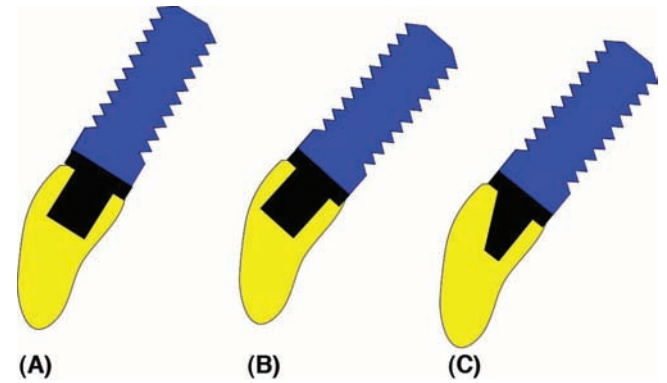
often wise to temporarily cement the crown to allow for soft tissue resolution prior to final cementation.



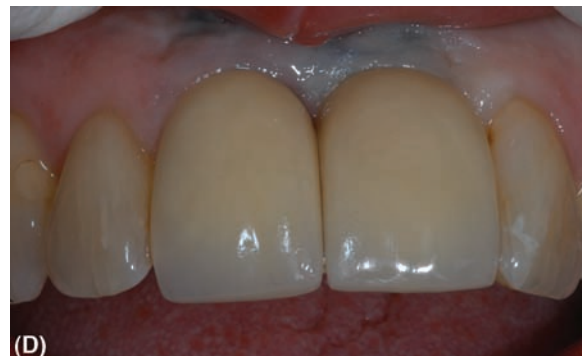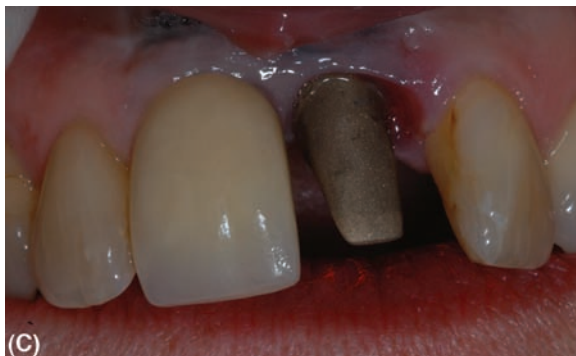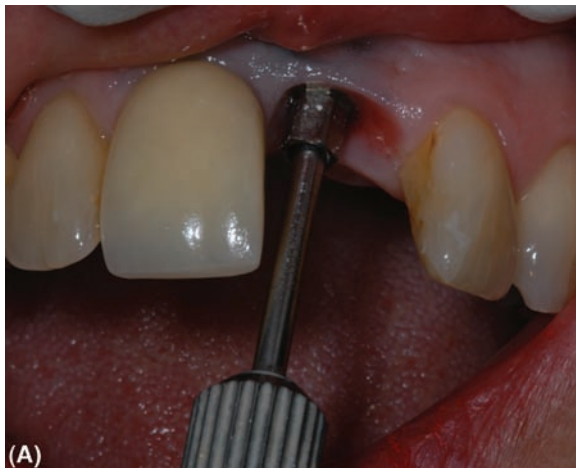**Figure 13.5** An upper central incisor tooth is essentially triangular in cross section (A). Choosing an implant diameter that is narrower than the tooth (B) will allow the emergence to be developed through the contour of the abutment and crown. An oversized implant (C) will not allow a suitable emergence to be developed.

the abutment. Minor changes to the margin carried out in the mouth can result in gingival bleeding and so it is best to remove the abutment and place it back onto the implant head model for chairside adjustment.

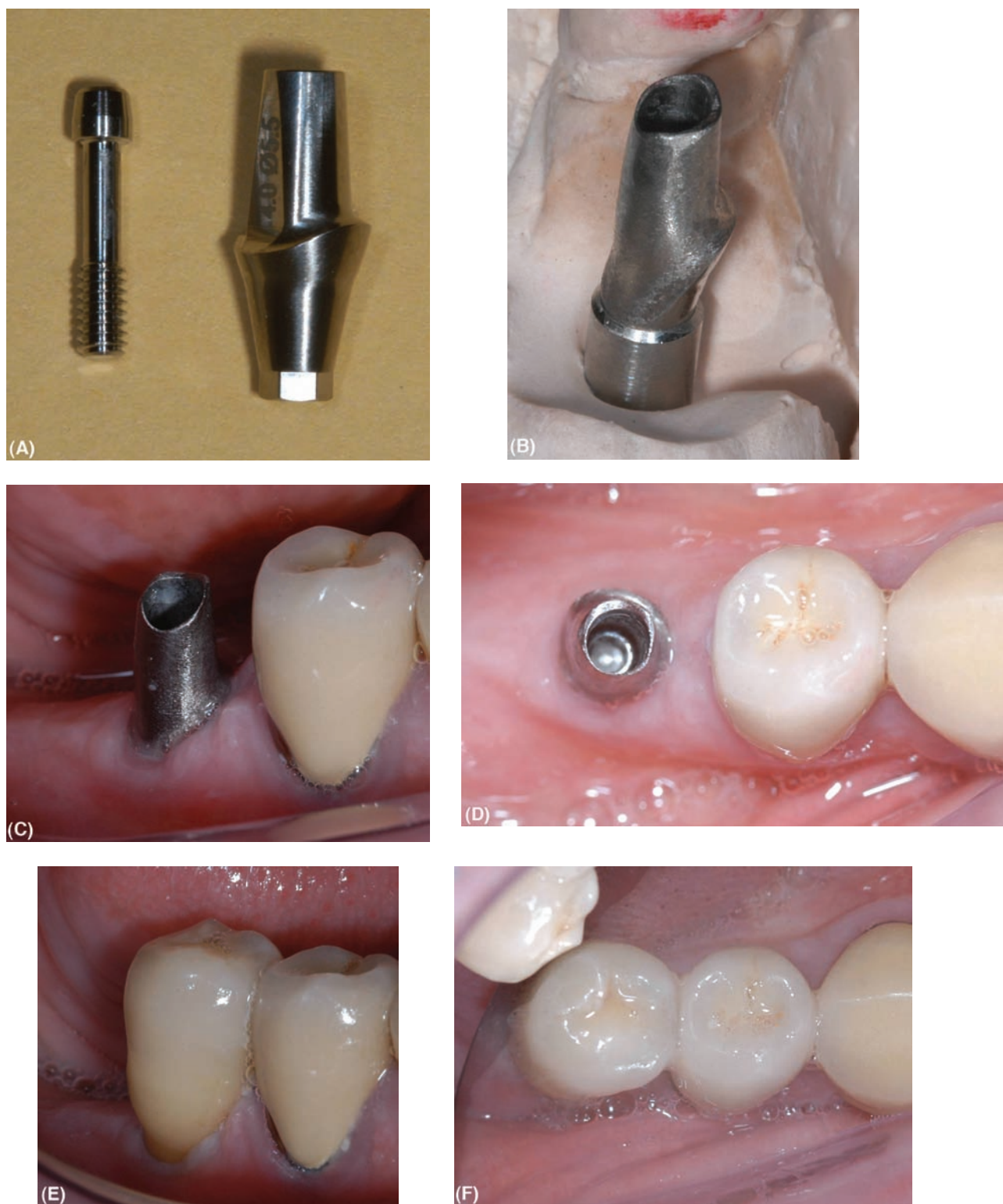This technique is particularly useful if the emergence and profile of the soft tissue needs to be significantly modified. The abutment is produced with a provisional crown that partly satisfies the desired end contour. Following temporary cementation, the soft



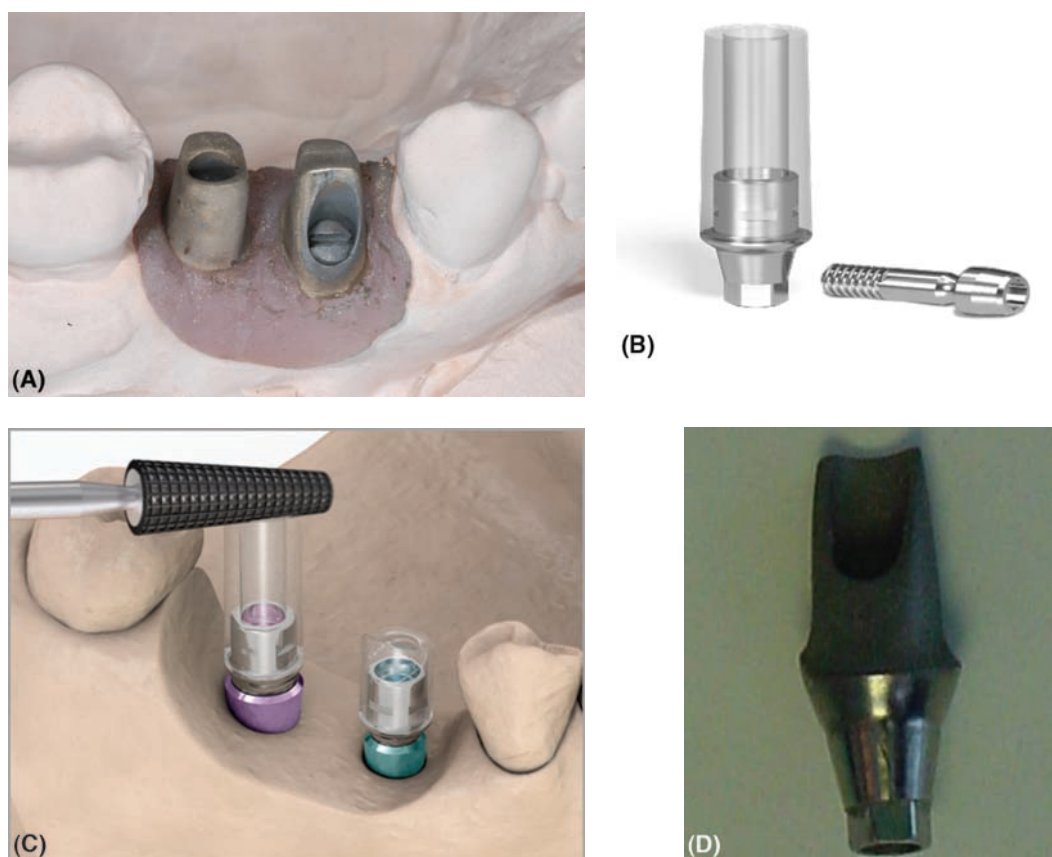**Figure 13.6** When the desired crown is in the same long axis as the implant, a standard abutment will achieve a good result (A). If the implant has a more labial angulation as in (B) and (C) and the path of insertion of the crown needs to be different to that of the implant, a customized abutment may be indicated. The crown in (B) will be too thin on the labial aspect and the customized abutment (C) allows more space for the crown.



**Figure 13.7** A standard abutment has been placed to restore the upper left central incisor tooth. (A) The path of insertion for the restoration is not acceptable—a restoration would not be able to seat into position. (B) A gold customized abutment has been made to change the path of insertion for the restoration to the distal aspect. (C) The abutment in place demonstrates the required path of insertion. (D) The restoration immediately after cementation.



**Figure 13.8** (A) A semiprepared titanium abutment before customization (TiDesign from Astra Tech). (B) On the cast the margins and contours of the abutment are customized. (C) The finished abutment in position. (D) The abutment from the occlusal surface. (E) The crown in place. (F) The final result.



**Figure 13.9** Construction of fully customized gold abutments. (A) Two abutments are constructed to produce a common path of insertion for the restorations. (B) An Astra Tech Cast Design abutment consisting of a precious metal implant connection and a burnout waxable sleeve. (C) On the master cast the sleeve can be adjusted to the correct height. (D) A completed fully customized abutment.

tissue will be deformed and then remodel to the new shape. The contour can be modified over successive visits by addition to the provisional crown until the desired contour and gingival emergence has been achieved. An impression of the abutment and adjacent soft tissue will allow for production of the final crown.

#### *Advantages*

- Allows for changes to angulation and crown path of insertion
- Gingival margin contours can be followed
- Minimal laboratory input

#### *Disadvantages*

- Customization limited by size of abutment at start
- Circular in cross section so not able to fully simulate anatomic contours
- Require abutment selection at start (i.e., multiple sizes/shapes)

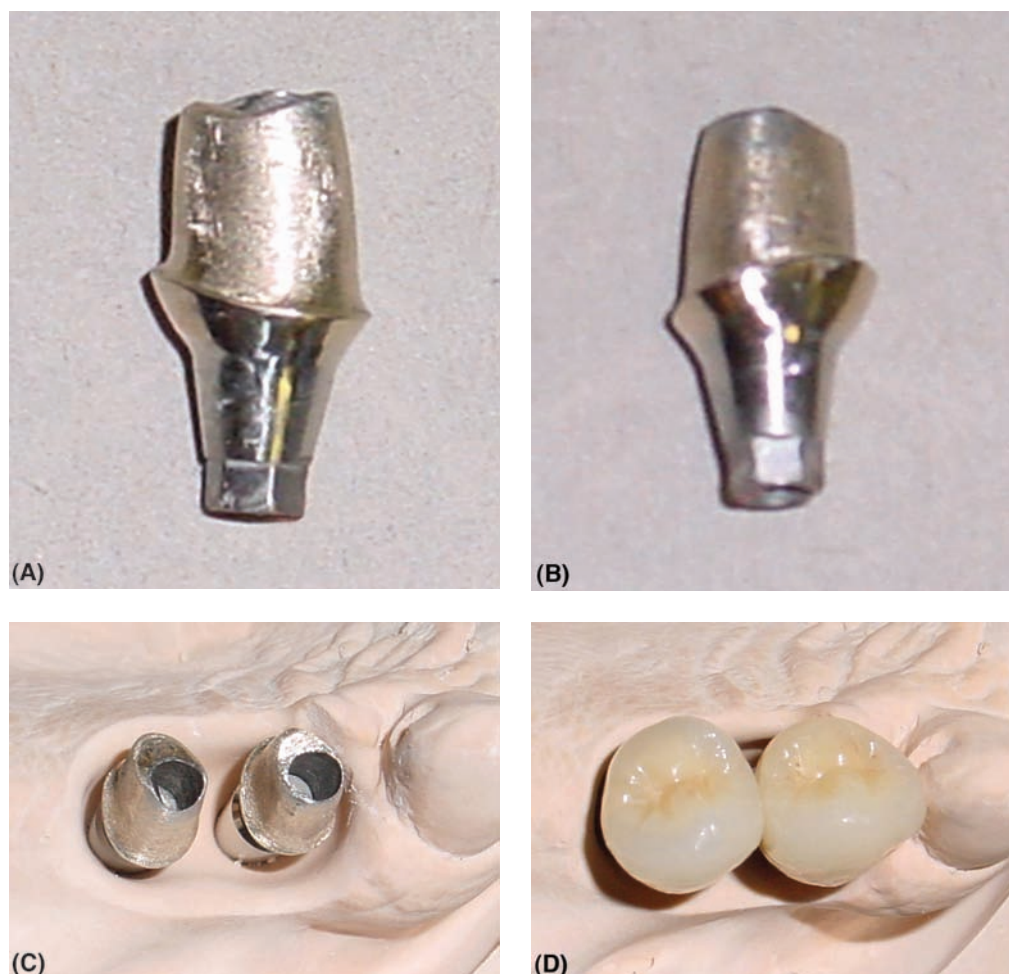
### **Fully Customized Gold Abutments**

These abutments share many properties with semiprepared abutments but they can be produced with even more allowances for compromised implant positioning and customization. The abutments have a readymade precious metal

component that is the abutment/implant connection corresponding to the implant design. This ensures a perfect fit between abutment and implant. The rest of the abutment is a plastic customizable cylinder that the laboratory technician can wax on to. The plastic cylinder is a burnout plastic so the whole abutment shape apart from the fit part is fully customizable by the laboratory technician who can then cast the abutment using conventional techniques (Fig. 13.9). The result is a gold abutment that can have a cross section that is not circular and within limits be the ideal shape required for support of the final crown. These abutments can also be used for screw-retained crowns (see later).

The basic procedure is illustrated in Figure 13.10. The technique has the advantage that only one abutment is required for all situations so no choices need to be made. With this process it is possible for an abutment to be produced to accommodate significant changes in angulation between implant and crown and also to move the apparent long axis of the final restoration to a different position to the implant long axis, although this is limited by the need to retain adequate retentive form for the final crown (Fig. 13.11). The customization also allows for exact positioning of the margin of the restoration (Fig. 13.12).

The extra complexities of this process restrict its use to difficult situations that can only be resolved by full customization. Where the fit surface of the abutment has been cast



**Figure 13.10** (A, B) A cast gold abutment viewed from mesial and distal sides demonstrates an oval contour for the abutment and the gingival margin for the restoration can match the natural gingival contour. (C, D) Gold fully customized abutments and restorations on the cast.

rather than manufactured, the quality of fit may not be as good. Conventional abutment screws retain the abutments and the rest of their use is the same as for all customized abutments.

#### *Advantages*

- Suitable for cemented and screw-retained restorations
- Fully customizable including angulation changes of up to 35°
- Works for extremes of interocclusal space
- Easy to align multiple implants

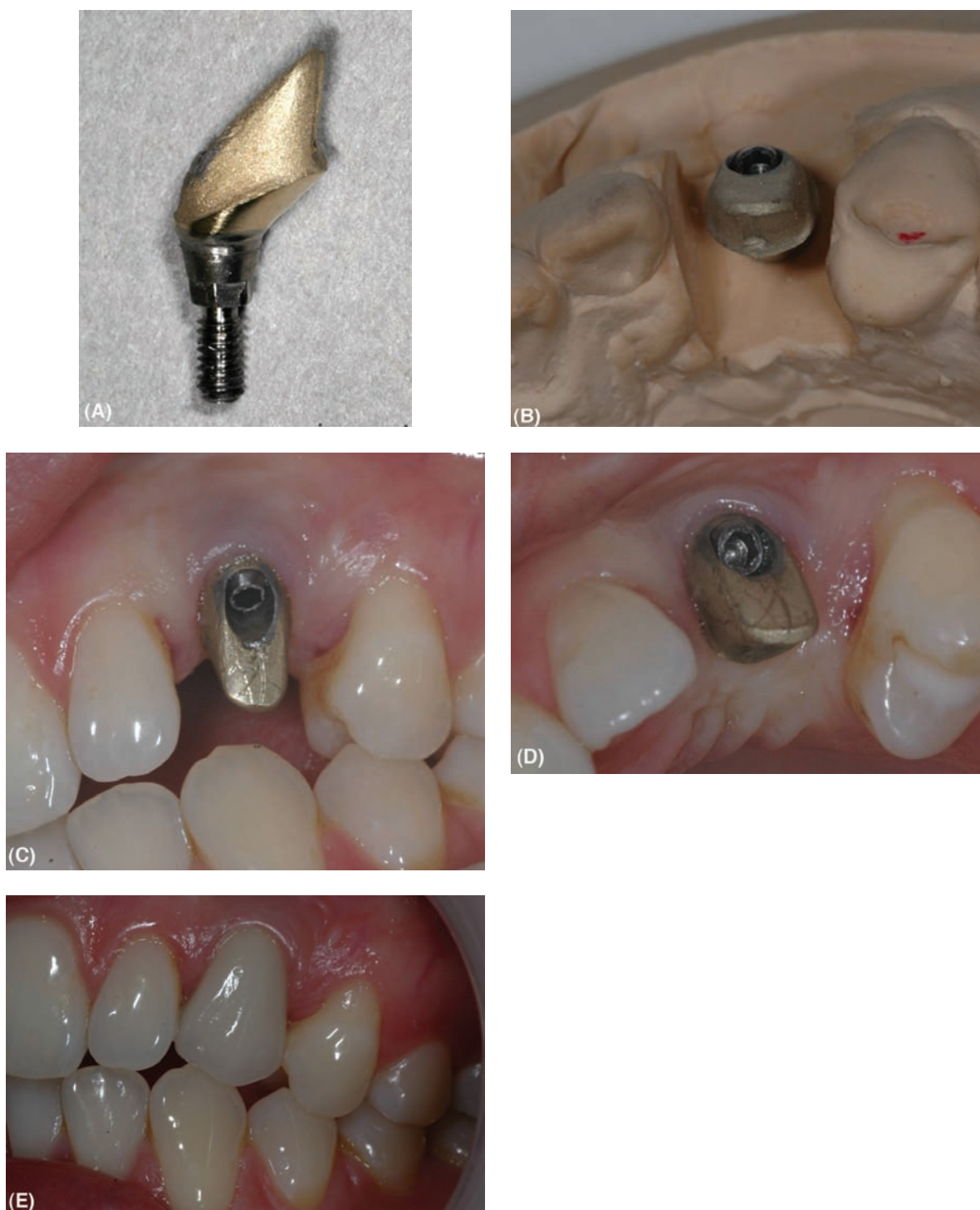#### *Disadvantages*

- Gold abutments only
- Expensive and complex laboratory input required

### **Computer-Generated Abutments**

Several manufacturers have systems available to make abutments, which are fully customized using CAD/CAM techniques (Fig. 13.13). The abutments are produced as part of a factory process so quality control is high and costs should be

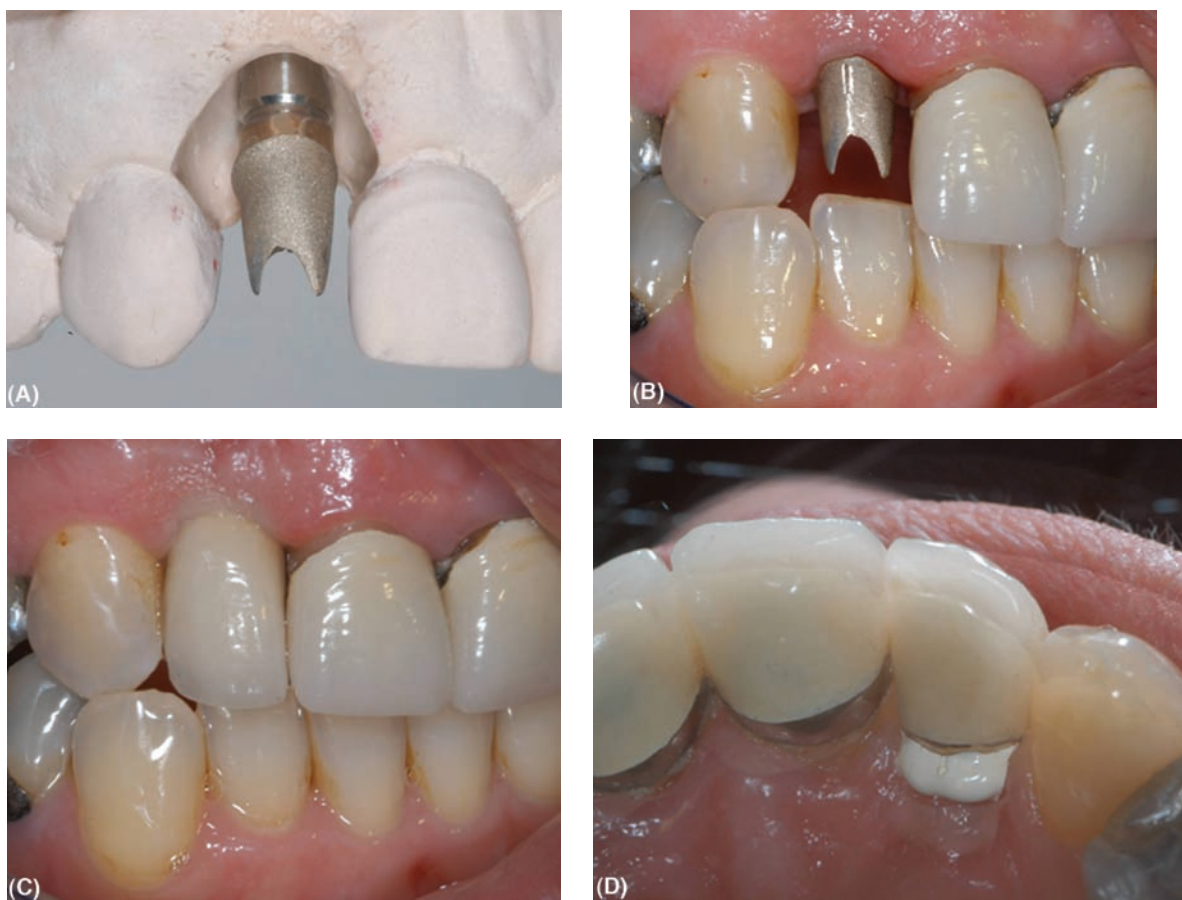reasonable as centralization of manufacture produces high volumes and reduced costs. Of particular advantage is the ability to produce abutments that are fully customized in ceramic (zirconia) and titanium. Head of implant impressions are taken as with all customized approaches. Two ways of manufacture are then available. One technique is to wax up the ideal abutment shape on the master model and then have this laser scanned so its exact dimensions are recorded. This digital information is then sent to the manufacturer and the abutment made by a milling technique. Alternatively, a scan can be made of the desired shape of the final restoration either using a temporary restoration or by a diagnostic wax-up. By orientating this contour with the position of the implant from a scan of the master model, a subtraction technique can be performed by the computer software so that the “ideal” abutment shape can be made to support the final crown. The abutment is first imaged on a computer screen so that the laboratory technician can see and further alter it before the abutment is manufactured. These abutments are often highly retentive as the retentive walls of the prepared surface can be made parallel. As with all fully customized approaches, the gingival margins, cross-sectional shape, height, and angulation are all



**Figure 13.11** A customized gold abutment used to make a 30° change in path of insertion for the restoration compared to the implant. (A) Note the long axis of the implant demonstrated by the abutment screw compared to the angle of the main abutment. (B) On the cast. (C) In place, the labial position of the abutment is in line with the adjacent teeth and the margin for the restoration is subgingival so no metal will show. (D) Adequate space is left for the restoration so the labial contour will not be overbuilt. (E) The completed restoration.

customizable. The end result of these abutments is very similar to gold customized abutments but requires access to highly skilled technicians who are experienced in the scanning technique. The remaining process to complete the restoration is the same as for all customized abutments.

One interesting development of this technique is that spare or copy abutments can be made that are exactly the same as the original. This allows for the abutment to be placed in the mouth and a provisional crown fitted. Rather than have to take a further impression for the permanent crown at a later date, a



**Figure 13.12** A cast gold abutment used to restore an upper lateral incisor tooth. **(A)** On the cast. **(B)** In position—note the labial margin for the restoration is subgingival. **(C)** This allows the metal margin to be disguised so the crown has a good appearance. **(D)** On the palatal aspect the margin can be supragingival, so excess cement can easily be removed.

second abutment can be ordered for the master model and the permanent crown made.

#### *Advantages*

- Fully customized abutments in titanium and zirconia
- High precision
- Costs should be less than gold abutments

#### *Disadvantages*

- Require specialist facilities
- Some control taken away from local laboratory

### **Ceramic Abutments**

These are essentially the same as semiprepared and fully customized CAD/CAM abutments and are used in the same way clinically (Figs. 13.14–13.16). They are made from yttria-stabilized zirconia, although dense alumina “Procera” porcelain can also be used. Clinical trials have demonstrated good success rates, although the number of trials is limited and there is little long-term data. The final crown should also be all-porcelain in construction and be cemented with a tooth-colored lute to achieve optimal results. Ceramic abutments are not suitable for situations where significant angulation changes need to be made, as the porcelain remaining following preparation will be at risk of fracture if it is too thin. The main

indications are for high aesthetic situations where it is desired that all-ceramic restorations are used, for example, to match with other all-ceramic veneers and crowns. They are also useful if there are concerns that metal abutments might show, for example, if the gingival tissue is thin or the implant head is close to the surface.

#### *Advantages*

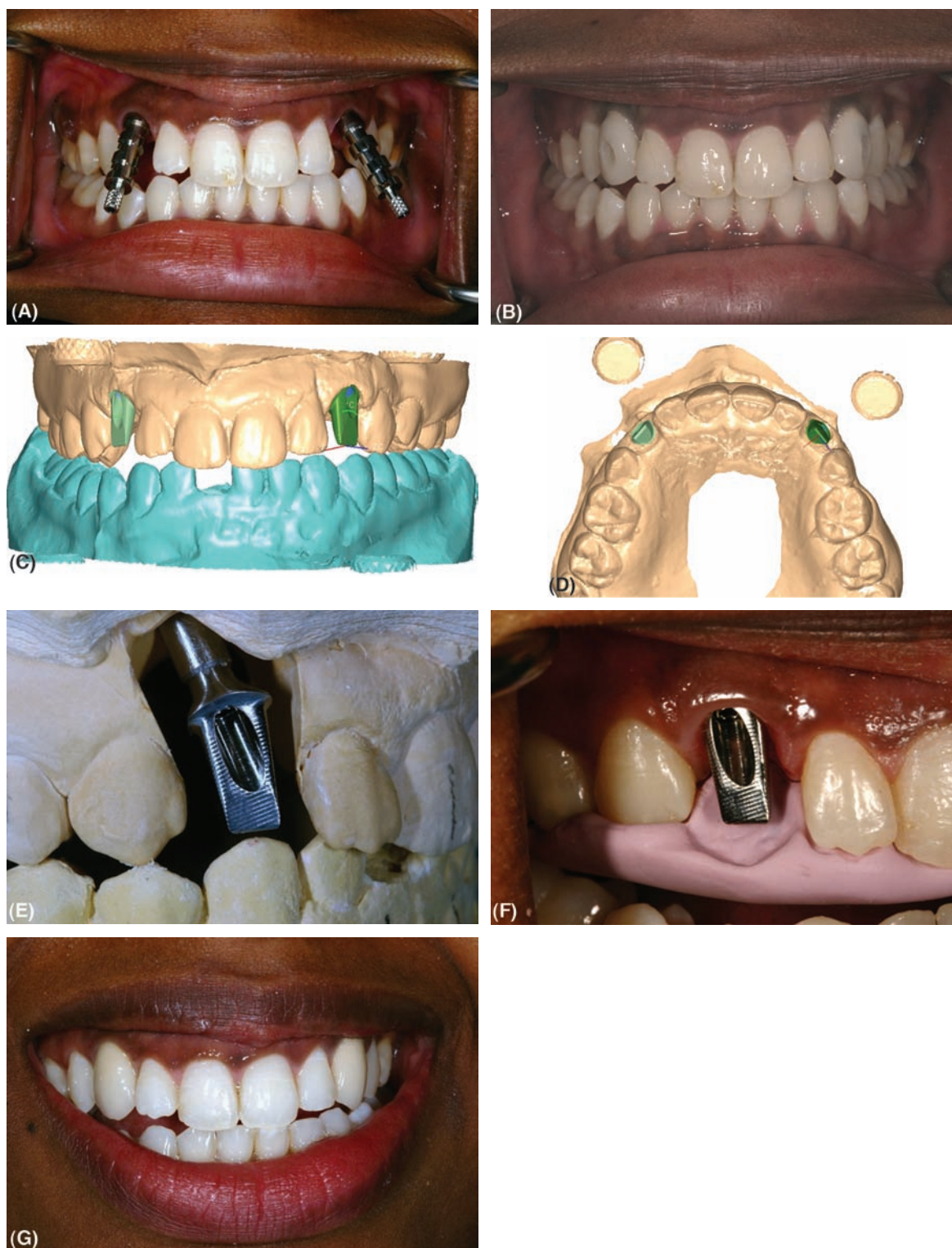
- Highly aesthetic and allows all-ceramic restorations
- Customized contours

#### *Disadvantages*

- Long-term survival not demonstrated in clinical trials yet
- CAD/CAM techniques require complex laboratory input

### **Prepable Abutments**

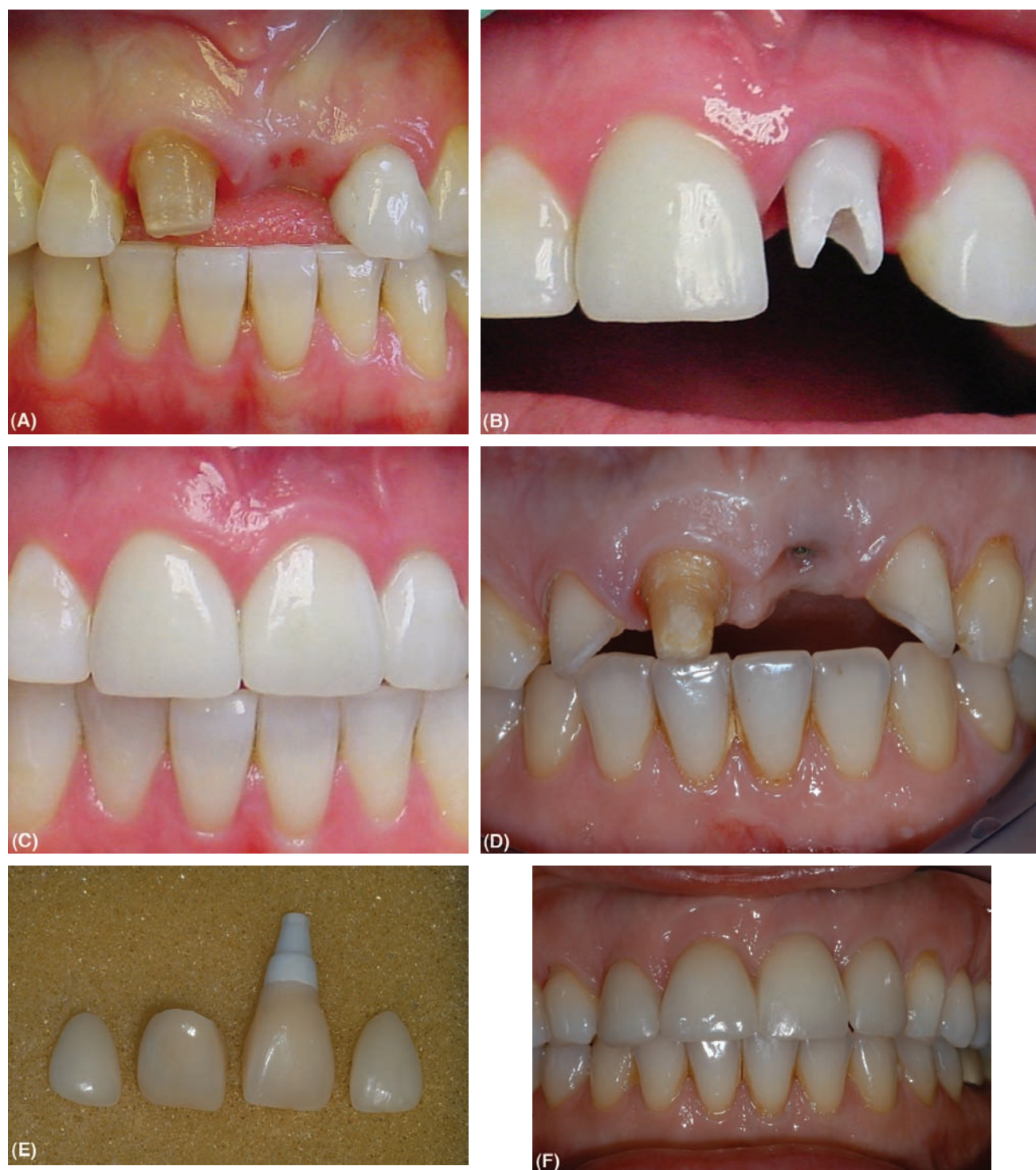Prepable abutments are solid abutments normally made from titanium or titanium alloy that are customized by preparing them with a drill, normally in the laboratory but sometimes in the mouth, into a “crown preparation.” Because they require significant laboratory input but are limited in their adaptability by the fixed size of the abutment, they have mostly been superseded by the other customized and CAD/CAM techniques, although for some implant systems they are still commonly used.



**Figure 13.13** Restoration of missing upper canine teeth using CAD/CAM Atlantis abutments. (A) Impression copings show a labial inclination of the implants. (B) Acrylic screw-retained provisional crowns have labial screw access holes that will be filled with composite resin. (C) On the computer scan, the desired shape of the abutment can be determined. (D) The position of the abutments is checked on the labial aspect—the desired angulation change has been achieved. (E) The titanium abutment on the cast with gingival replica removed. (F) The abutment is tried in the mouth. A putty matrix shows that there is adequate space for the restoration. (G) The completed restorations.

The connection to the implant with these abutments is the same as for standard abutments and the outline of the technique is illustrated in Figure 13.17. The retentive element for the crown is a block of metal, which can be customized to

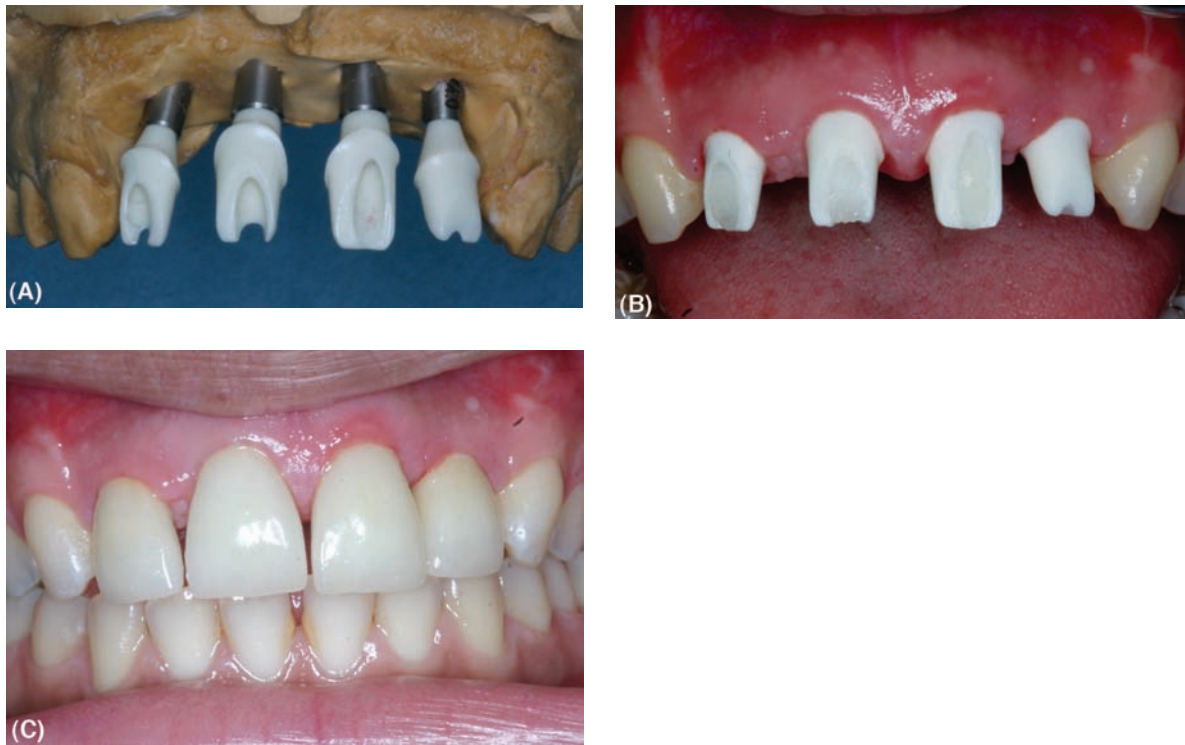achieve an ideal preparation contour. The abutments come in a variety of diameters roughly corresponding to the dimensions of upper lateral and lower incisors (4–4.5 mm), upper central incisors, canines, and premolars (5.5 mm) and molar teeth



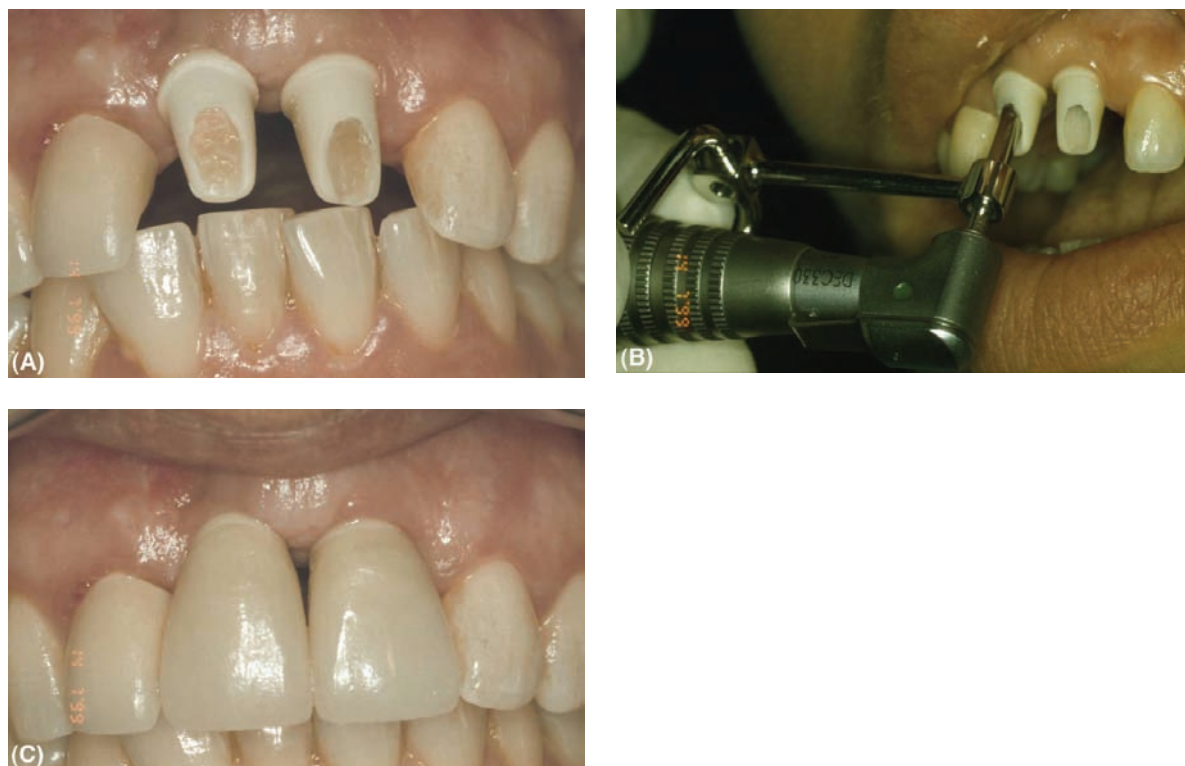
**Figure 13.14** The use of zirconia abutments in cases where other all-ceramic restorations are required. (A) An all-ceramic crown is required for the upper right central incisor tooth. (B) A zirconia abutment is prepared for the left incisor tooth. (C) Both central incisor teeth restored with ceramic crowns. (D) Another case where crowns and veneers are required. (E) Using a zirconia abutment all the restorations can be made from the same material. (F) The completed veneers, crown, and implant restoration.

(6.5–7 mm). A smooth collar extends from the implant head to this dimension. An impression is taken of the implant head and a cast made with a silicone soft tissue replica (see later under laboratory techniques). The abutment is prepared using high-

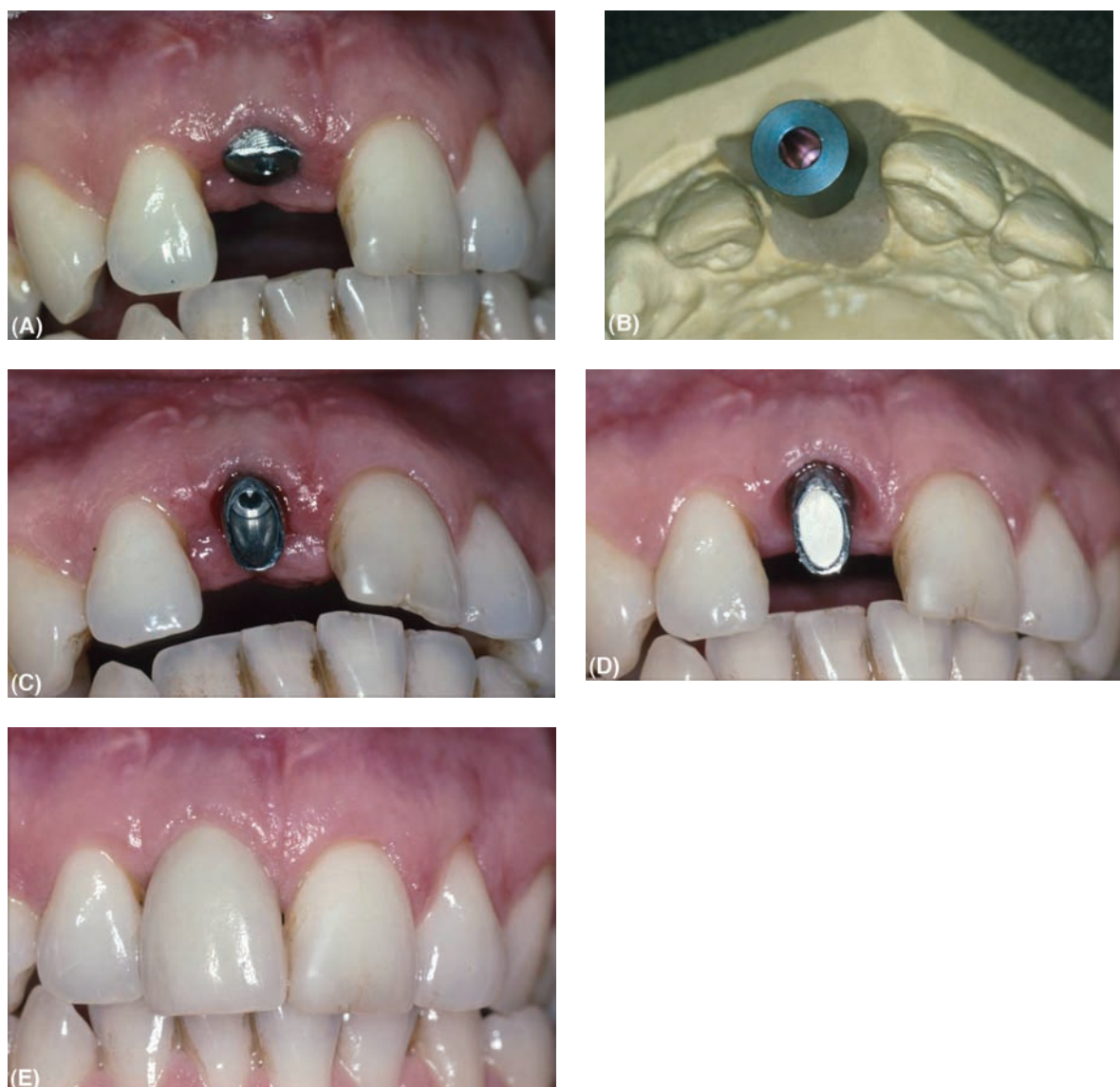speed instrumentation either by the dentist or the dental technician. The metal can be cut back to achieve a preparation comparable to a conventional crown preparation. The gingival margin can follow gingival contours and be placed subgingivally



**Figure 13.15** All four upper incisor teeth restored with individual crowns. (A) Four zirconia abutments were produced using a CAD/CAM technique (Atlantis). (B) Abutments in place. (C) Completed all-ceramic restorations.



**Figure 13.16** Nobel Biocare implants restored with porcelain CerAdapt abutments. The implant heads were close to the surface and conventional abutments could not be hidden. (A) The prepared abutments in position—the abutment screw access holes are sealed with a tooth-colored material. (B) The abutment screws are torqued carefully into place using an electronic torque controller and a counter torque to prevent overstressing the implant. (C) The completed Procera crowns cemented with a tooth-colored composite resin cement.



**Figure 13.17** Missing central incisor tooth where an Astra Tech ST implant has a minor labial angulation—a preable abutment has been used: **(A)** On presentation, the healing abutment has been cut back to preserve labial soft tissue. **(B)** The amount of preparation required and residual abutment can be visualized. **(C)** The prepared abutment in place—note the poorly formed gingival contour at this stage. **(D)** Following provisional cementation of the crown, the gingiva is healthy and well contoured. The abutment screw access hole has been filled with gutta percha. **(E)** The completed restoration.

on the labial and proximal sides but can be supra gingival palatally. Enough reduction must be achieved to allow sufficient space for the crown. The metal surface that will be covered by the crown can be left with a coarse finish to aid retention and does not need to be polished, but any metal that will be in contact with the soft tissue should be as smooth as possible.

As with other customized abutments, preable abutments have the ability to change orientation for the crown relative to the implant. This is normally required to rectify a labial inclination of the implant. A preable abutment can be cut back on the labial surface in the center but still keep adequate width mesiodistally and affect a reasonable emergence profile. Preamble abutments should be prepared out of

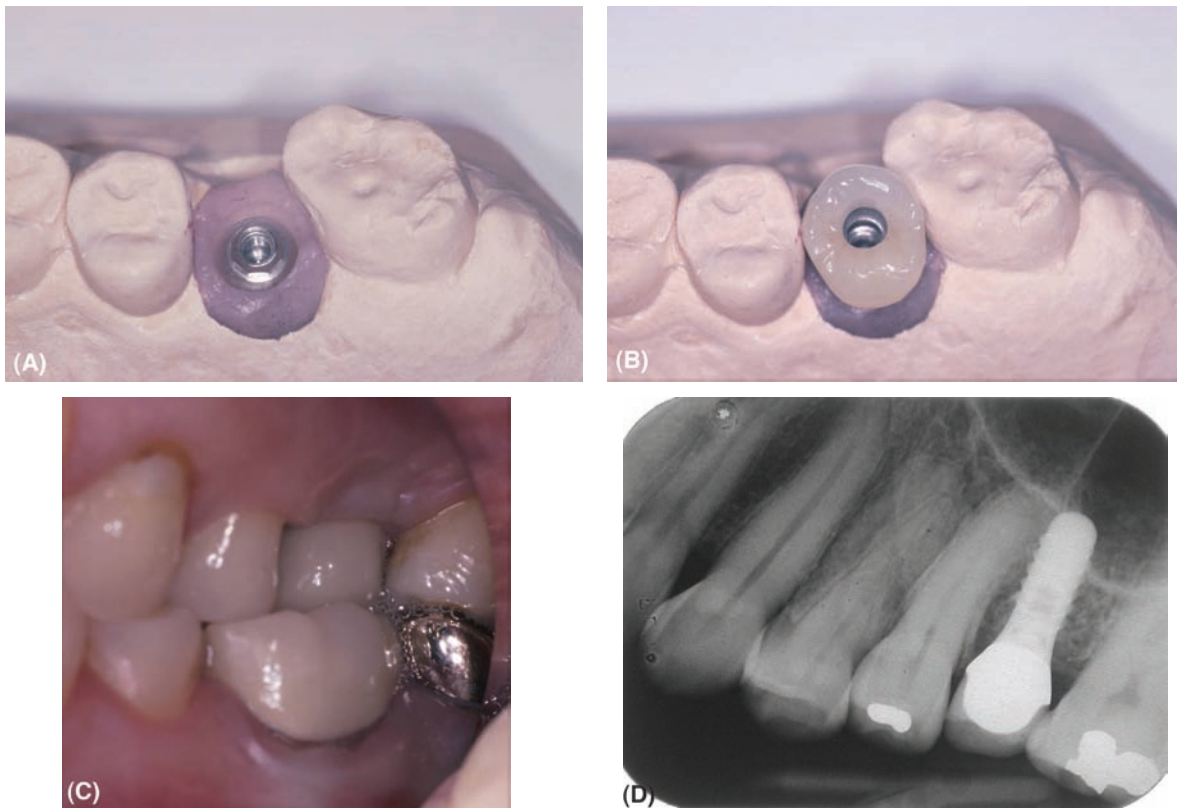
the mouth. Small changes can be made intraorally with an air-rotor under copious irrigation, but are best avoided.

#### *Advantages*

- Improved flexibility over standard abutments
- Copes with angulation changes

#### *Disadvantages*

- More complex laboratory technique than standard abutment
- Customization limited to the basic size/position of the abutment at start
- May require second intraoral impression
- Precision of fit of crown to abutment is less predictable



**Figure 13.18** A single Straumann implant placed for a missing upper second premolar tooth: (A) The working cast with replica of the implant. (B) Completed crown—the screw access hole is centrally placed. (C) Buccal view of the crown in position—the upper teeth are in cross bite with the lower teeth. (D) Periapical radiograph of the completed restoration.

### Abutments for Screw-Retained Crowns

The desirability for screw retention has already been discussed. For single tooth, the main advantage is simplicity and ease of insertion and removal (Fig. 13.18). Problems can arise when cementing crowns (see later), particularly if deep margins are used. With a screw-retained approach, the porcelain can be taken further subgingivally with minimal risks.

Usually screw-retained crowns are more applicable to premolar and molar regions (Fig. 13.19) where occlusal screw access may be less of an aesthetic problem and in situations where there may be more of a need to remove restorations (e.g., to tighten the abutment screw) or join implants to further implants in the future.

The technique utilizes gold fully customizable abutments that are waxed up to the contour ready for porcelain application so that the abutment and crown are in one-piece. Gold suitable for porcelain bonding is used.

#### Advantages

- Predictable retention and removal
- No margins or cement
- Easy access to abutment screw if tightening required
- Very robust
- Takes up less space than conventional two-part technique

#### Disadvantages

- Screw hole must exit in suitable position cosmetically
- Screw hole may make occlusion less stable if in critical occlusal contact position

### IMPRESSIONS AND ABUTMENT SELECTION

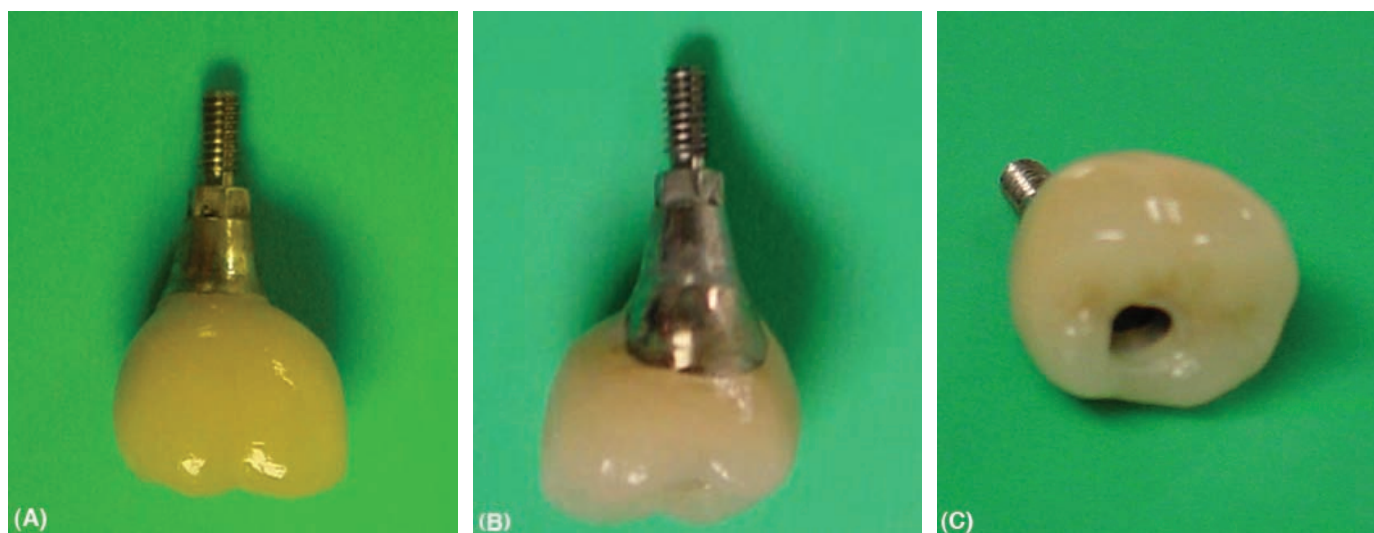The previous section described in detail the various abutments and techniques available. However, before an abutment is selected, a choice needs to be made between two alternative techniques:

1. Abutment impressions
2. Implant head impressions

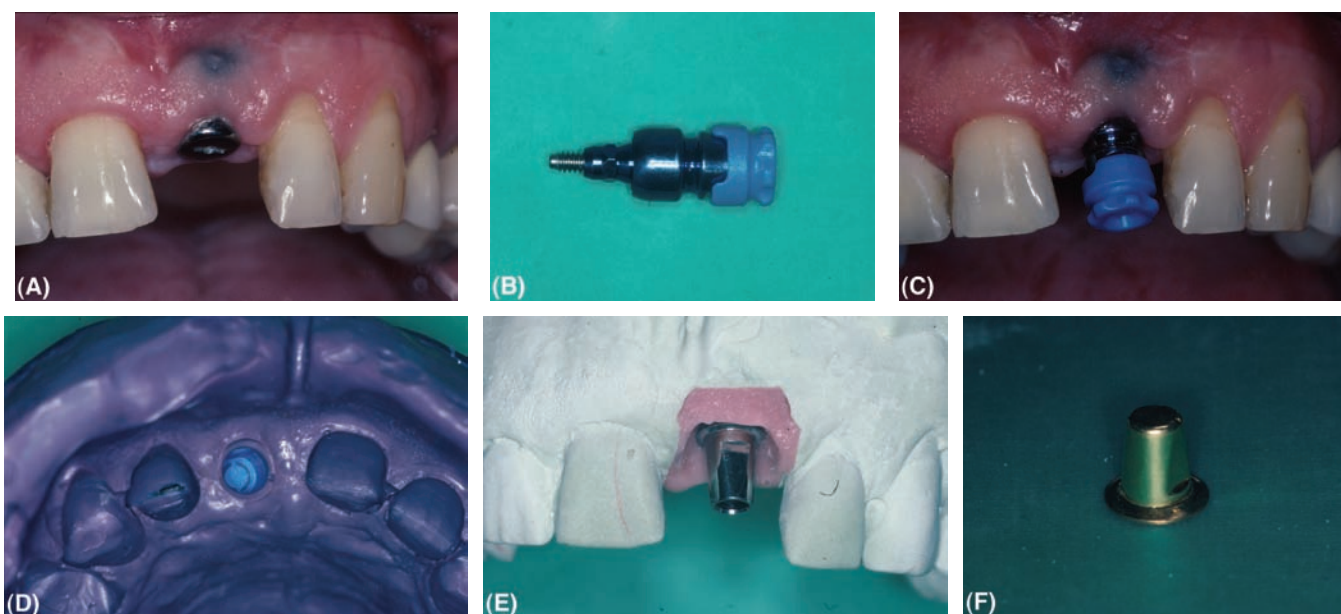
#### Abutment Impressions

The conventional approach for single tooth restorations using standard manufacturer-made components is to choose the abutment and place it into position. An impression is made of the abutment and a working model produced using ready-made components (Fig. 13.20). The abutment can be left in position and covered with a temporary cover or a temporary crown can be build up using conventional crown and bridge techniques (with a temporary component from the manufacturer).

Alternatively, the abutment can be removed following impression taking and stored for use at the next appointment. The healing abutment is therefore replaced. This technique requires less chairside time and the original provisional restoration (denture or resin-bonded bridge) can be refitted. It is important that the abutment is stored in a sterile container and care must be taken to ensure that it will go back into exactly the same position next time.



**Figure 13.19** A screw-retained single molar restoration with the abutment and restoration in one-piece. (A) Buccal view. (B) Lingual view. (C) Occlusal view.

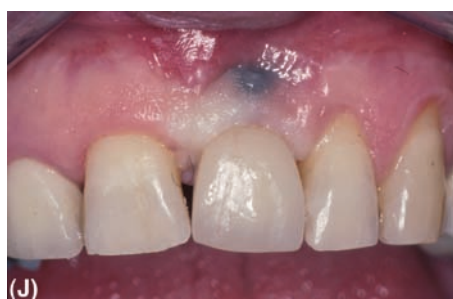
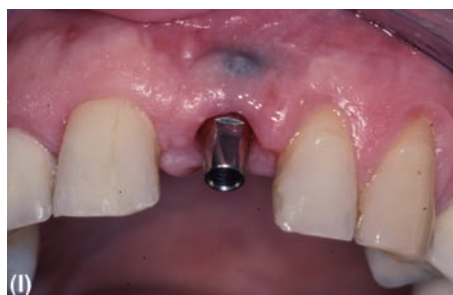
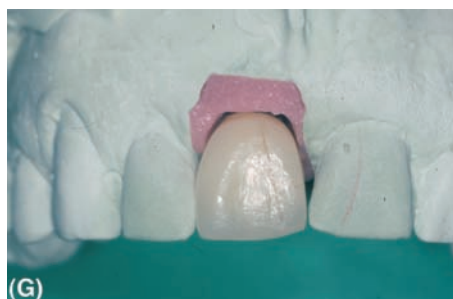
**Figure 13.20** A Frialit 2 implant placed to replace a missing upper central incisor tooth: (A) Healing abutment in position. (B) The impression coping. (C) The coping is seated into the implant—the metal part will stay in the implant following removal of the impression. (D) The blue plastic component is picked up in the impregum impression. The metal coping that remained attached to the implant will reseal accurately back into this. (E) Working cast with abutment in position. (F) The metal coping for crown manufacture. (G) Completed crown on cast. (H) Internally the use of a premade coping ensures an accurate fit. (I) Abutment seated. (J) The crown immediately after cementation. The gingival blanching will resolve in a short time.

### Implant Head Impressions

This technique is mandatory for all abutment types other than standard abutments and has much to recommend it as the approach of choice. An impression is recorded of the implant head using an impression coping (see chap. 14 for more details), which is cast with an analogue of the implant head

to produce a working model (Fig. 13.21). The abutment can be selected and seated onto the model. Choice of the abutment outside of the mouth ensures that the correct decision can be made more easily without taking up clinical time. Any of the abutment types can be used in this way. Care must be taken not to damage the abutment assembly, particularly the screw,



**Figure 13.20** (Continued)

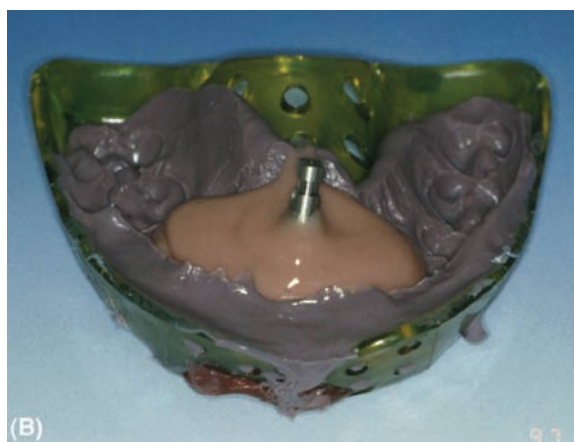
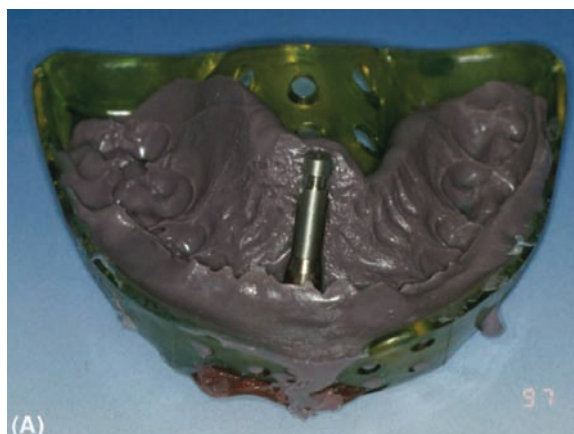
and therefore a laboratory screw should be used and the clinical screw stored until the abutment is seated into the mouth. The abutment should be sterilized before placement in the mouth. Some prosthodontists prefer to choose the abutment using this technique but then place the abutment into the mouth and retake the impression.

### Choosing the Abutment

Abutment selection is based on the following features.

#### Depth of Soft Tissue

The vertical height from implant head to the gingival margin is measured at the shallowest point on the labial surface. This can



**Figure 13.21** (A) An impregum impression of an abutment with the laboratory replica attached. (B) The soft gingival replica is poured into the impression.

be measured intraorally with a periodontal measuring probe or with various devices provided by manufacturers that fit onto the implant head and indicate the depth. To ensure that the metal collar of the abutment does not show, the abutment is chosen so that the labial margin is at least 1 mm subgingival. Care must be taken to ensure that choosing abutments to suit the labial margin does not result in an excessively deep margin elsewhere. The authors find that margins more than 3 mm deep result in restorations that are difficult to seat, and removal of excess cement may be impossible. In situations where there is a marked discrepancy between the gingival heights around the margin, a customized abutment is indicated as it allows the margin to be placed in relation to the gingival contour. This technique assumes that the chosen abutment has a diameter close to that of the cervical margin of the tooth to be replaced.

#### Emergence Profile

It is easier to create a good emergence profile if there is at least 3 mm of vertical space from implant head to gingival margin (Fig. 13.6). This allows a transition from an implant head, which is often at least 2 to 3 mm less in diameter than the cervical margin of the proposed restoration. If it is necessary to flare from the implant head to a wide-necked restoration in a short vertical space, it is most readily achieved using a

wide-diameter customized abutment. These can create a dramatic change in little vertical space, but care must be taken not to excessively overcontour this region, which may then be difficult to seat and maintain. There may be a desire to create a final restoration with a wide gingival dimension, especially where the interdental gingival papillae have been lost leaving "black triangles," which will spoil the final appearance.

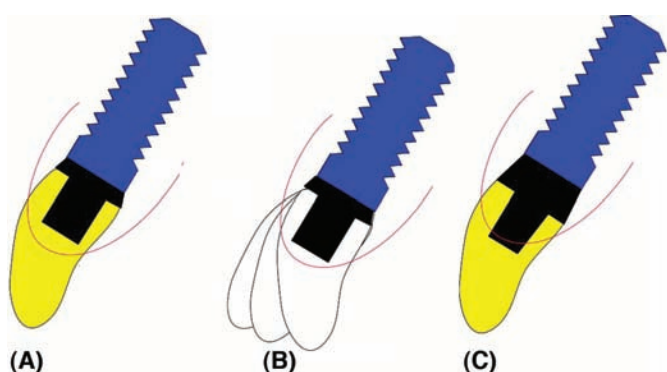
#### Orientation

Ideally the implant will have been placed close to the long axis of the missing tooth crown and adjacent clinical crowns. Implant placement with the long axis of the implant through the incisal tip or just to the palatal surface is easiest to restore and any of the abutments can work in this situation. It is a common scenario, however, for the implant to have a slight or even pronounced labial inclination. There are several reasons why this may be the case, including the following:

- The bony contour following resorption from tooth loss often results in an alveolus that dictates implant placement in a more labial inclination.
- As a result of the natural curvature of the original and adjacent teeth, the roots may be orientated at a different angle to the clinical crown.

Small degrees of labial angulation (see chapters on single tooth planning and surgery) can therefore be desirable and easily accommodated by standard abutments. If standard abutments are used in situations with more labial angulation, they may result in either an excessively overcontoured labial surface or a porcelain surface that is too thin to mask the metal structure underneath (Fig. 13.22). A better result can be achieved by using customized abutments, as the path of insertion of the crown can be different to the long axis of the implant. Changes of up to 35° can be made; the limiting feature is normally the need to retain some abutment structure around the abutment screw hole and the need to provide adequate retention for the crown.

To assist with the correct abutment choice, the best approach is to determine the correct labial contour using either the provisional restoration or from a diagnostic wax-up. A silicone putty labial mask can be produced from this and placed either in the mouth or ideally on a working implant head model. The true orientation of the implant relative to the labial surface is then clear and the correct abutment choice can be made.



**Figure 13.22** Selection of a shorter abutment (A) and (B) allows more vertical space for possible alterations in labial angulation with standard abutments compared to a normal selection (C) where the crown margin has been placed just subgingival.

#### Interocclusal Space

The space from implant head to the opposing tooth needs to be assessed. The shortest standard abutments require a minimum vertical space of between 6 and 7 mm. If less space exists, a fully customized abutment may be indicated, although vertical spaces less than 5 mm are difficult to restore and alternative conventional dental techniques such as increasing the vertical dimension of occlusion or the use of "Dahl" appliances should have been considered or a screw-retained crown could be used. Once again, correct planning and a deeper implant placement can avoid this problem. Excessive vertical dimensions can be restored using any of the abutment types but fully customized abutments where the height of the retentive element for the crown can be optimized produces the best results. The implant crown needs to be made so that the porcelain is correctly supported by the metal framework underneath.

#### Retrievability

A screw-retained restoration will be easier to remove at a later stage if it is envisaged that this will be required. A cemented crown, even placed on a standard abutment with a temporary cement, can be very difficult to remove. In general, a restoration can only be made screw retained if the path of insertion for the screw will be on the palatal or occlusal aspect. Specific abutments for single tooth are available or a standard abutment can have the crown cemented onto the abutment out of the mouth and a larger access hole made through the crown to fit the restoration onto the implant with the abutment screw. Screw retention can be useful in situations where there is limited space between adjacent teeth. Access for the cementation process can be limited and the space needed for the abutment, cement lute, and crown takes up more space than a one-piece screw-retained restoration (Fig. 13.23).

#### Special Aesthetic Requirements

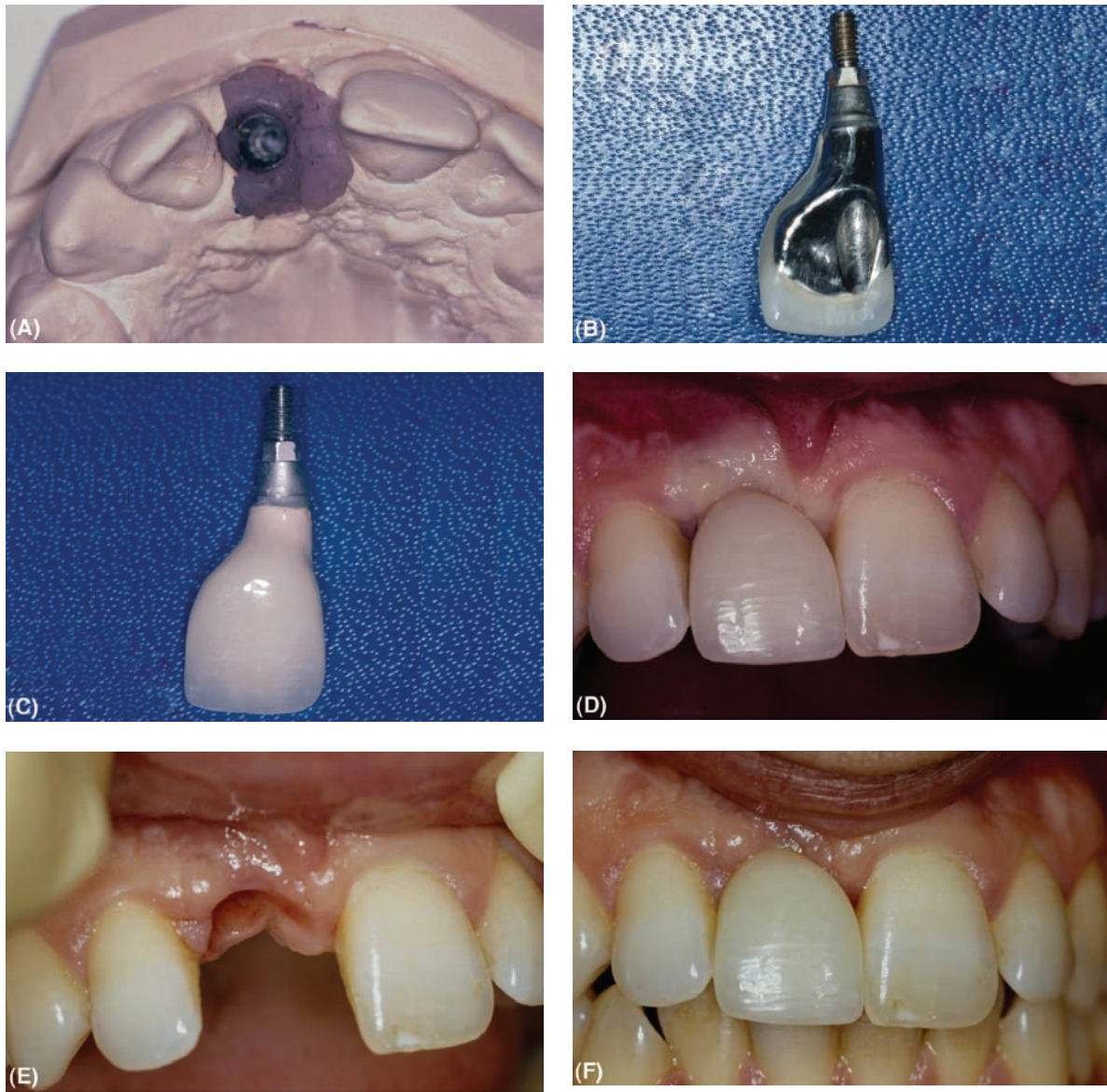
The techniques already outlined aim to provide an aesthetic restoration with no metal showing. Problems can arise if the implant head is close to the surface or the labial gingival tissue is thin so that the metal abutment shows through the gingiva causing graying and a poor appearance. This can be determined by attaching an implant head impression coping and looking for a color change. A ceramic abutment is indicated in these situations.

#### Final Restoration

Before a single tooth implant abutment is chosen, the type of final restoration required must be considered as this will have a bearing on the abutment selection. When using metal abutments, there is little reason for avoiding the use of metal-ceramic restorations. All porcelain restorations cemented onto metal abutments need to be quite thick to avoid the metal showing through and resulting in a gray restoration. Problems can arise when single tooth implants are being matched to adjacent teeth that are already restored with porcelain crowns or porcelain veneers. It is often best to replace adjacent restorations so that they can all be reconstructed together in the same materials, but all-ceramic abutments and crowns give the technician the best chance to match in these situations.

#### Abutment Selection Kits

Several manufacturers produce abutment selection kits that are exact replicas of the different abutments available. They are normally used on implant head casts but can also be used intraorally. As it can be difficult to visualize an abutment in



**Figure 13.23** Restoration of an Astra Tech ST implant that is close to the adjacent tooth. There was a large incisive canal that influenced implant placement. (A) From the implant head model, the lack of space between the implant head and the adjacent tooth can be seen. Use of an abutment and separate crown would therefore be difficult. (B) Using a cast-to abutment, a one-piece abutment and crown has been produced. The abutment is completely customizable using a conventional wax pattern and casting technique. (C) The resulting restoration eliminates the need for cementation and is retained by the abutment screw. (D) On initial insertion, the crown causes blanching to the soft tissues. (E) Removal of the restoration four weeks later demonstrates a healthy contoured gingival cuff. (F) The completed crown.

position and an incorrect choice can be very costly, their use is highly recommended (see also chap. 14).

Having chosen the abutment and decided on the final restoration, the clinical techniques can now be outlined.

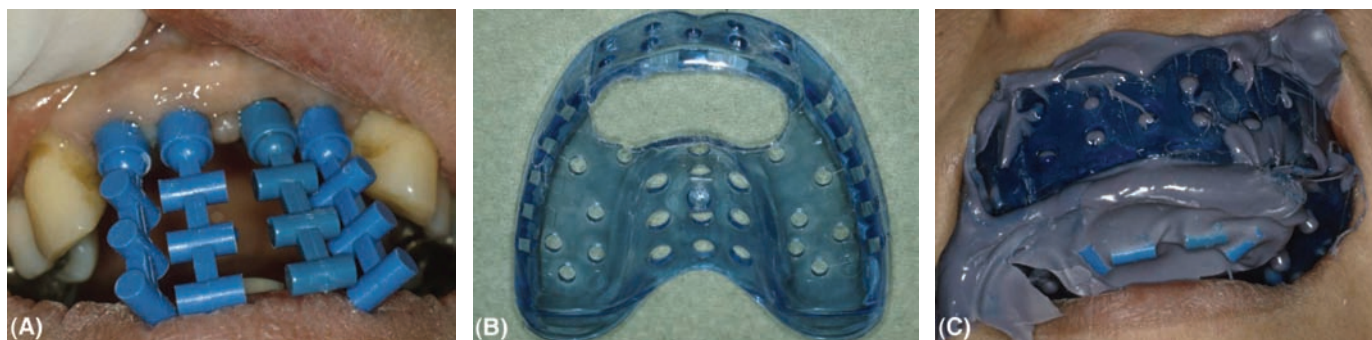### Abutment Connection

Deep soft tissue “tunnels” will make abutment seating purely a tactile process. It may also be an uncomfortable process for the patient, particularly if the soft tissue is still in a fragile state. It is essential that healing abutments are not left out for any length of time as the soft tissue will quickly contract into the space and will be painful to push back. Local anesthetic may

therefore be required. A degree of soft tissue blanching is to be expected, but patients should feel/see the area return to normal within a few minutes.

If the abutment is to be placed in the mouth and left in place, the abutment screw will need to be tightened to the manufacturer’s recommendations. Electronic and hand torque devices are available. It is essential that the abutment is fully seated and is in the correct position before torquing the screw as the fit surfaces will be damaged and it can be difficult to remove if incorrect, or the screw may fracture.

The complications of removing abutments once impressions have been taken and reseating them in the same position have already been discussed.



**Figure 13.24** Four Nobel Biocare implants to be restored as single restorations. (A) Standard abutment impression copings in place. (B) A stock tray has been modified to allow the copings to project. (C) An impression taken in impregum—note the finger marks over the copings due to the operator holding the copings down to prevent their movement while the impression material sets.

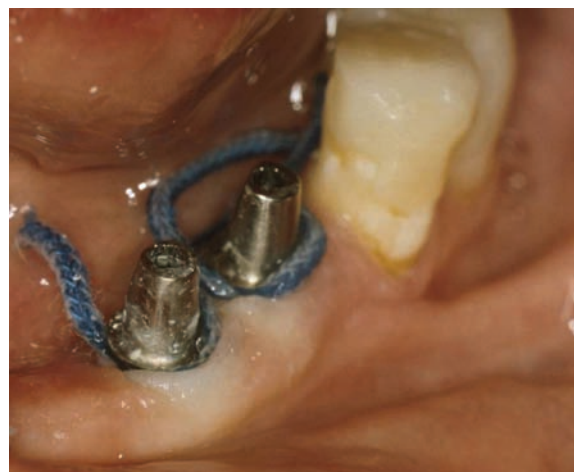## Impressions

For standard abutments, plastic push-on impression copings are seated onto the abutment (Fig. 13.24). These are often a tight fit but they can tend to lift up from the abutment if seating pressure is released. If it is obvious that the coping is not stable, it should be left untrimmed and a hole cut in the impression tray so that finger pressure can be exerted on the coping while the impression material is setting. A retentive impression coping is trimmed so that it does not interfere with an impression tray. Conventional crown and bridge techniques can be employed. A stock tray that is rigid enough to support medium- or heavy-bodied impression material is used. The impression material used needs to be rigid enough when set to hold the impression coping without tearing. Light-bodied materials are therefore not suitable. Putty consistency materials alone are also not suitable, as they will not flow around the copings. Single-phase materials such as polyethers and addition-cured silicones (medium or heavy body pastes) are recommended.

Impression material is syringed around the coping and the tray seated. A full-arch impression is recommended. Once set, the impression should retain the coping and it should be carefully tested for looseness with tweezers. If there is any doubt that the coping may have moved in the impression, it is best to retake the impression. The impression should also record the adjacent teeth and their gingival margins as well as the articular surfaces of all the teeth in the arch. The abutment analogue needs to be attached to the impression coping ready for the laboratory to cast the impression.

Good quality opposing impressions and occlusal records are required. For a single tooth restoration, it is normally not necessary for models to be fully articulated, but similar requirements to conventional crown work should be followed and a complex occlusal relationship that needs to be copied may indicate full articulation on a suitable articulator.

For a customized abutment to be used, an impression of the implant head is required to allow the abutment to be modified on a model in the laboratory. A “pick-up” impression technique is followed with an impression coping held into position with a guide pin. The pin needs to be unscrewed before the impression is removed from the mouth (see also chap. 14). Once a customized abutment has been placed, a secondary impression of the abutment in position and the gingival contour may be required. If the gingival margin of the abutment is only just subgingival, it may be possible to



**Figure 13.25** Gingival retraction cord placed around preable abutments to assist in an accurate impression being taken of the subgingival margins.

record the margin using a conventional impression technique, syringing light-bodied material into the gingival crevice. Deeper margins or situations where there is some gingival bleeding make the use of gingival retraction cord necessary (Fig. 13.25). This needs to be packed with care, as it must not be pushed below the widest contour of the abutment, otherwise it will be difficult to remove. It is important that the margin of the abutment is checked after the impression has been removed to ensure that fragments of material have not torn from the impression and remain trapped under the convexity of the abutment. If an impression is proving difficult to take, it is better to replace a well-fitting provisional restoration and allow the soft tissue to improve, and then try again or alternatively to consider removing the abutment and directly waxing up on the abutment or to construct an acrylic jig of the abutment which can be picked up in a secondary impression.

## Temporary Restorations

Short-term temporary crowns can be constructed at the chair-side using plastic copings supplied to fit on standard single

tooth abutments. These can be time consuming to make, and often it is best to remove the abutment and replace the provisional restoration. Temporary crowns can be constructed from the diagnostic wax-up using either a putty or a vacuum-formed mold, in crown and bridge temporary acrylic materials. The temporary crown will need to extend down to the margin of the coping and the material will not flow down subgingivally. The temporary restoration needs to be carefully contoured to have an acceptable emergence profile, and this is best completed out of the mouth using light-cured composite. It is may be better not to make the choice of the final abutment at this early stage, so a combined abutment and crown can be made to provisionally restore the implant and then a permanent abutment chosen at a later stage. Temporary abutments are made by most manufacturers, and the restoration is better made screw retained so that it can be easily retrieved during the stages of manufacture of the permanent restoration. If the screw hole emerges in an unfavorable position, it can be disguised with composite filling materials.

Longer-term provisional crowns to be placed on customized abutments or to be used for soft tissue molding techniques (see earlier) are best constructed in the laboratory in advance. Provisional/temporary crowns can be cemented using conventional materials such as zincoxide/eugenol or Tempbond.

### SHADE TAKING AND LABORATORY PROCEDURES

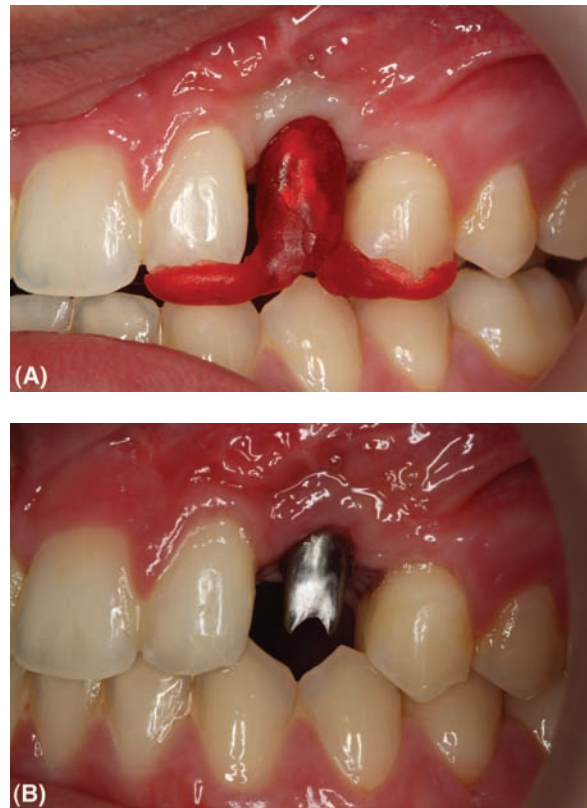
Ideally the shade should be taken with agreement of the dentist, patient, and technician. The design of the abutment should also be a joint responsibility between dentist and technician. For single tooth restorations, the expectations of the patient are often very high and only the highest quality aesthetics will be acceptable.

### Laboratory Techniques

Analogues for either the abutment or the implant head are attached to the coping in the impression. A soft tissue replica in a flexible material needs to be incorporated into the working cast, as a solid material would not allow the restoration to extend subgingivally and create a good emergence. Several silicone materials are available and they are placed into the impression around the impression coping before dental stone is poured. The soft tissue replica is removable to allow access to the margin area. Conventional techniques are followed for crown construction as already outlined.

### FITTING THE COMPLETED RESTORATION Try-in

The restoration can be tried in prior to completion (Fig. 13.26). Straightforward cases can go to completion from the initial impression but where significant changes have to be made to orientation or soft tissue contours, a try-in is advised. The crown can be seated with finger pressure but will often rise up due to the gingiva being displaced. It is often difficult for patients to see the exact result at this time unless the crown is being firmly held in. The contact points are checked with dental floss as for conventional crowns. This is more complex than for teeth as implants are ankylosed and do not move with a periodontal ligament. This means that there is no "give" when the crown is seated, so contacts need to be adjusted so that the crown fully seats and floss passes through the contact point easily. When multiple crowns are being tried in, this problem is magnified.

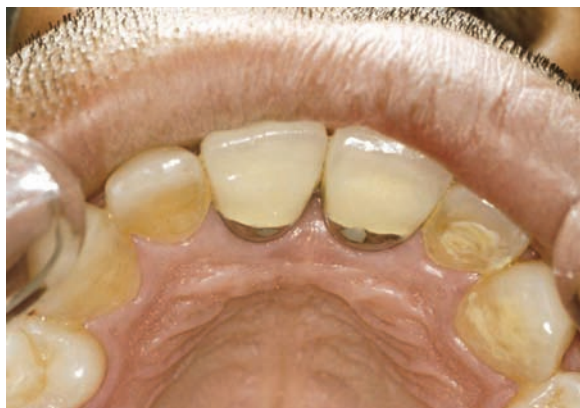

**Figure 13.26** (A) An acrylic jig is used to locate an abutment in position. (B) The abutment in place.

### Occlusion

The occlusal contacts should be checked prior to and after cementation. The ideal arrangement is for the implant restoration to be in very light contact when the patient gently holds the teeth together and to be in full contact only when heavy load is applied. The best test is for the implant restoration not to hold shimstock on light contact, while the adjacent teeth do. As more pressure is exerted, the implant restoration can start to hold shimstock. This can be difficult to determine until the restoration is finally cemented. Prior to cementation, it is probably best to adjust and check the occlusion with occlusal indicator papers for gross overcontact. The crown should be adjusted so that it lightly marks and heavier marks are visible on adjacent teeth. The implant crown should not be placed without occlusal contact as this could result in movement of the opposing teeth.

The occlusal contacts are first checked in the intercuspal position (the position of maximum intercuspation). This may not be in the retruded arc of closure and so the crown should be checked in this position to ensure it will not create an occlusal interference. Next the crown is checked for protrusive and lateral contacts. In protrusive movement, if the crown is to be in contact it should be shared with other teeth and not be the sole point of contact. In lateral movement, the crown should conform to the existing occlusal scheme, either a group contact or canine guided. It is not desirable for the implant restoration to act as the only guiding surface for lateral movement.



**Figure 13.27** Two single tooth implant-supported crowns with cement venting holes just visible above the gingival margin on the palatal aspect. These have been restored with composite resin.

### Cementation

It may be prudent for the final restoration to be provisionally cemented while the patient accommodates to it and to give time for the soft tissue to mature around the new shape. A modified temporary cement should be used as well-fitting crowns can be difficult to remove later, especially as the smooth shape and lack of an accessible margin can make it difficult to hold the crown to remove it.

Prior to finally cementing the crown, the abutment screw should be checked for tightness and some cotton wool or similar soft material placed over the screw head so that it can be easily found, and the head remain undamaged if the crown ever needs to be removed and the abutment taken out in the future.

Traditional cements such as zinc phosphate or glass ionomers are often recommended but care has to be taken to ensure that the viscosity of the cement is low enough for the crown to be fully seated (Fig. 13.27). The quality of fit between abutment and restoration means that softer cements designed for temporary cementation are adequate as the definitive cement. Whatever cement is used, the crown does not need to be completely filled with cement as excess cement extending down below the margin can be difficult to detect and remove. Ideally, exactly the right amount of cement to produce no excess should be aimed for, and there are few complications to having an incomplete cement lute compared to conventional crown and bridgework.

It can often be difficult to seat the crown into position because of a deep position of the implant, the need to recontour the soft tissue by overbuilding the proximal areas, or due to bleeding from the soft tissues. Do not try to force the crown down with permanent cement. Place it provisionally first with a temporary cement and remove it and recement at a later stage once the gingiva have recontoured and matured.

Following cementation, a long cone periapical radiograph should be taken to

- verify seating of the restoration;
- check that no excess cement is present;
- act as a record of the marginal bone height for comparison with follow-up images.

### Instructions to the Patient

The patient must be armed with the knowledge and ability to maintain the restoration. For single tooth restorations, no special oral hygiene techniques are required and the patient should be able to follow the same cleaning techniques that they follow for their other teeth. Patients should be warned that the new implant restoration might feel “hard” and “heavy” to bite on for a few days, a feeling that soon passes. It is not normal for patients to feel any discomfort from single tooth restorations and they should be encouraged to return if they have any symptoms. The complications of single tooth restorations are covered in chapter 16.

### ADDITIONAL CONSIDERATIONS

#### Multiple Single Tooth Restorations

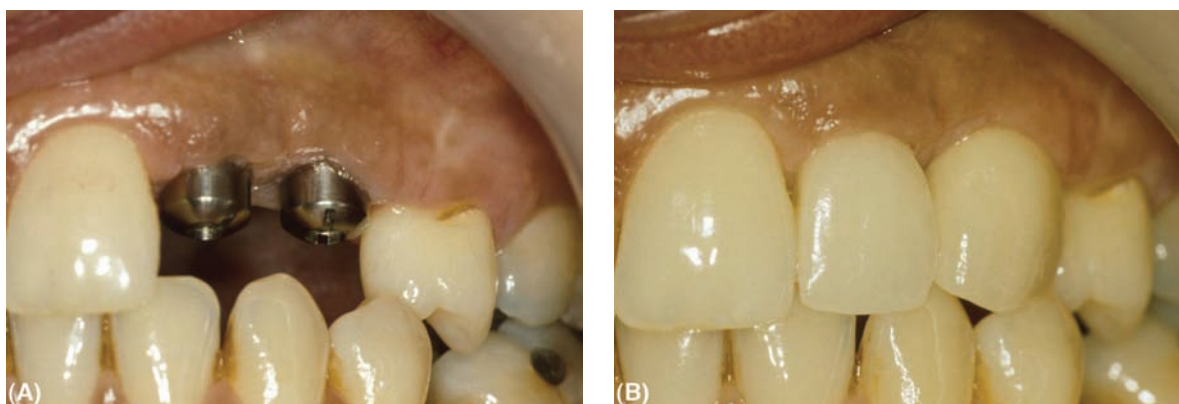
The process of providing multiple single tooth restorations next to each other raises the following issues:

- Is there adequate space, not only to place the implants, but also to place abutments and crowns and allow for adequate space for interdental soft tissue to develop? It is sometimes better to place fewer implants and restore the space with a bridge.
- A single tooth space normally has some interdental papillae left because of the presence of adjacent teeth. If several teeth are lost, the ridge often heals with a flat contour. Placement of individual crowns can result in triangular dark spaces interdentally. This can to some extent be overcome by overcontouring the crowns (Fig. 13.28), but may be better remedied by placing linked crowns. Soft tissue augmentation techniques are considered in chapter 12.
- Customized abutments are normally always indicated as the paths of insertion of the crowns need to be aligned and it is unlikely that all implants are completely parallel to each other.
- Seating adjacent crowns can be difficult because of the contact points and lack of tooth movement on seating. The crowns should be tried in individually first to verify the fit and then tried in together with care to ensure the contact points are correct and all crowns are fully seated.

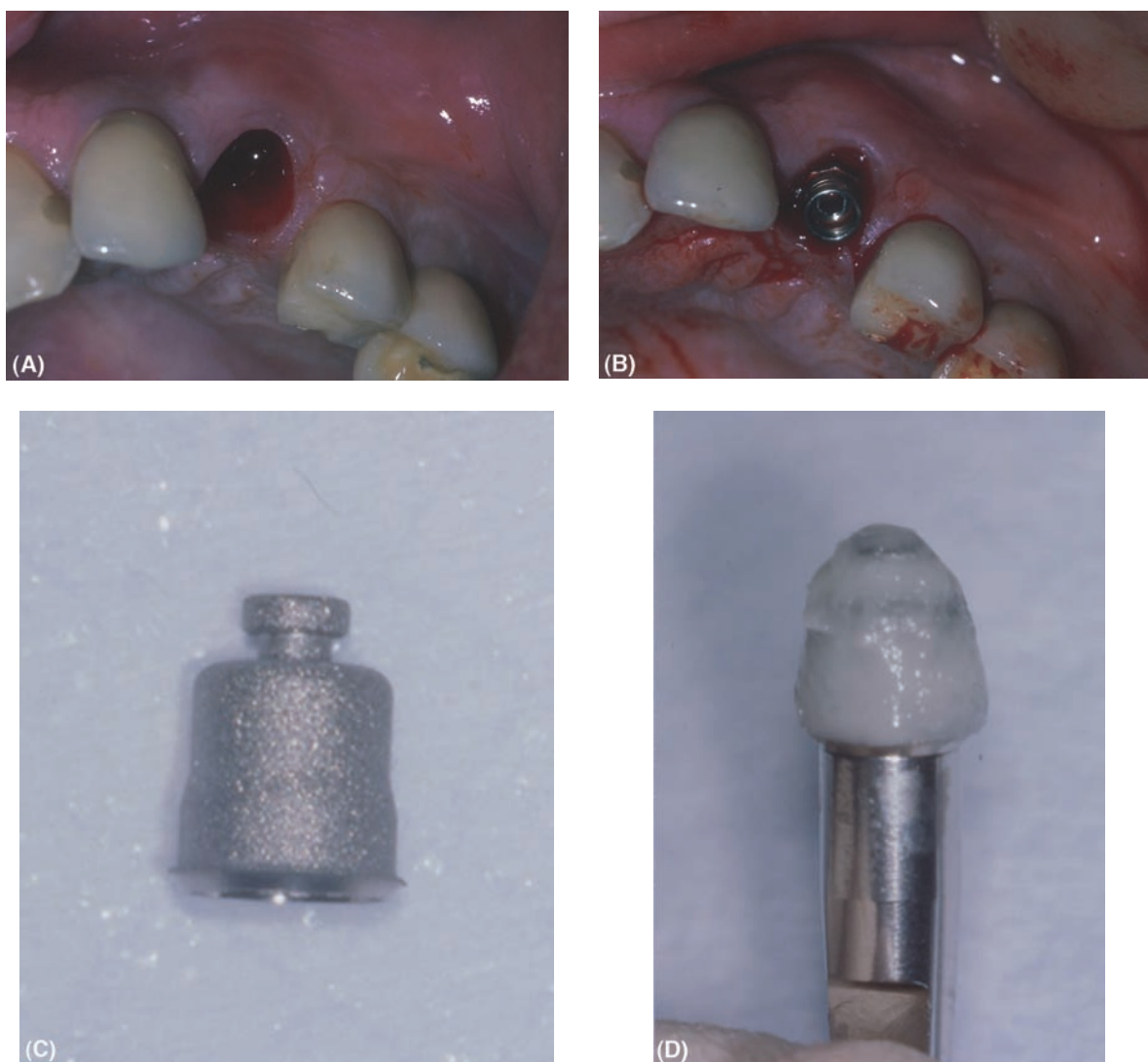
### Restorations from Impressions at Implant Placement

It is possible to provide an implant-supported crown from impressions taken at implant placement and insert the abutment and a provisional crown at implant exposure or on the day of implant placement (see chap. 11 on immediate techniques). This will speed up the process of provision of a restoration and in particular dispense with the need to adjust a temporary restoration to allow for healing abutments. This may be a particular advantage where a temporary partial denture is thin due to the occlusal contacts. Further thinning of the denture to accommodate healing abutments can make the denture unusable. It is also proposed that the soft tissue contours form to the correct shape more speedily, although this will depend on achieving a correct emergence profile and margin placement from the limited information available from the first impression (Fig. 13.29). On the whole, the disadvantages and extra complexity of this technique make it only worth considering in exceptional situations.

If an impression is taken at implant placement (Fig. 13.30), as the implant is not integrated at this stage, care must be taken not to compromise the implant position and stability. An impression coping is placed onto the implant head and an



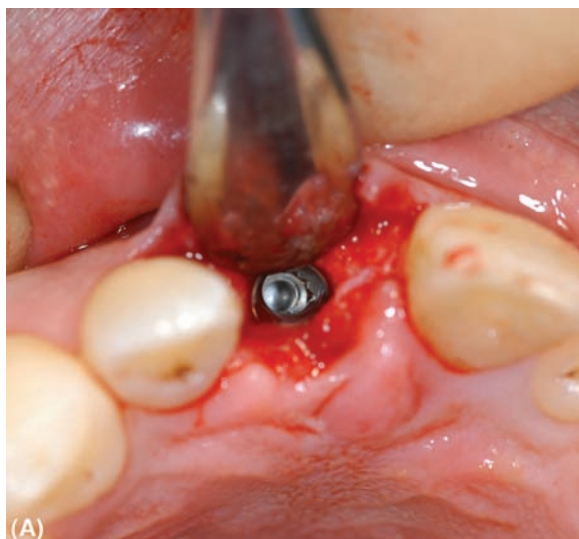
**Figure 13.28** (A) Missing lateral incisor and canine teeth. The gingival contour, particularly between the two implants is evident. (B) An acceptable aesthetic result has been obtained by producing crowns with a long contact area and overcontouring interdently.



**Figure 13.29** A canine tooth is immediately replaced with an implant and restored. (A) The tooth is carefully extracted. (B) The implant has a standard abutment immediately placed. (C) A readymade metal temporary cylinder is used that will fit the standard abutment. (D) The temporary crown is built up in stages in composite filling material. (E) The temporary crown cemented in place. A permanent crown can be made at a later stage.

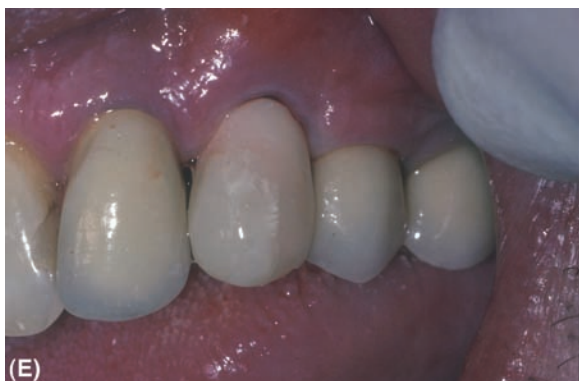
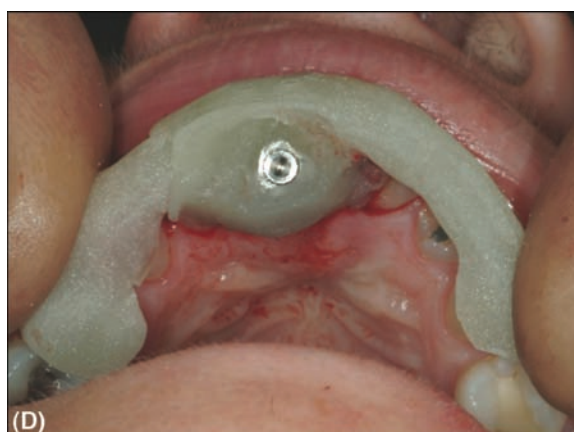
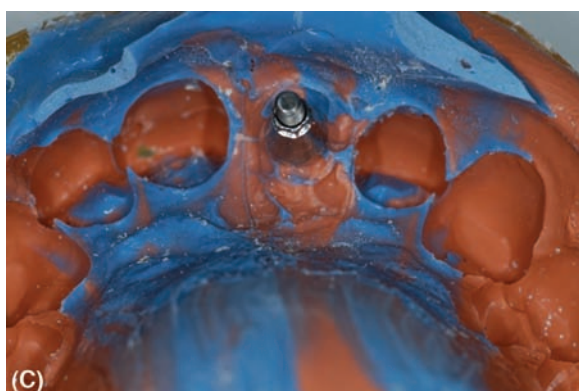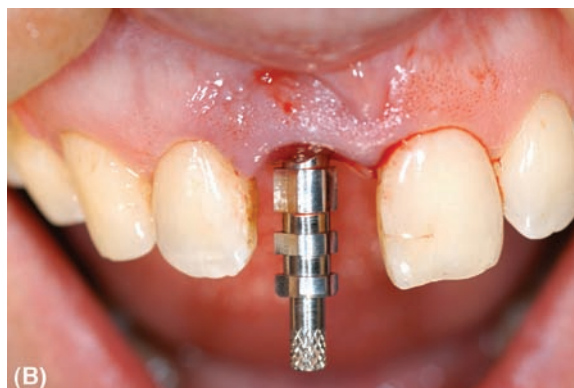Figure 13.29 (Continued)



**Figure 13.30** (A) In a healed site, an Astra ST implant is placed. (B) An impression coping is attached. (C) An impression taken, picking up the impression coping. (D) In a similar case for immediate restoration, a premade acrylic jig is used to attach to an impression coping. (E) A laboratory replica is attached to the impression coping and this can be located back onto a cast. (F) A healing abutment is temporarily placed on the implant and the soft tissue sutured. (G) A temporary cylinder suitable for an Astra implant—the base is titanium and the cylinder acrylic so that a temporary crown can be fabricated on it. (H) The temporary crown is made on the cast. (I) The completed temporary crown is one-piece and screw retained. (J) The crown can be made and placed within a few hours. (K) The occlusion is adjusted so the temporary restoration does not take any direct occlusal load.

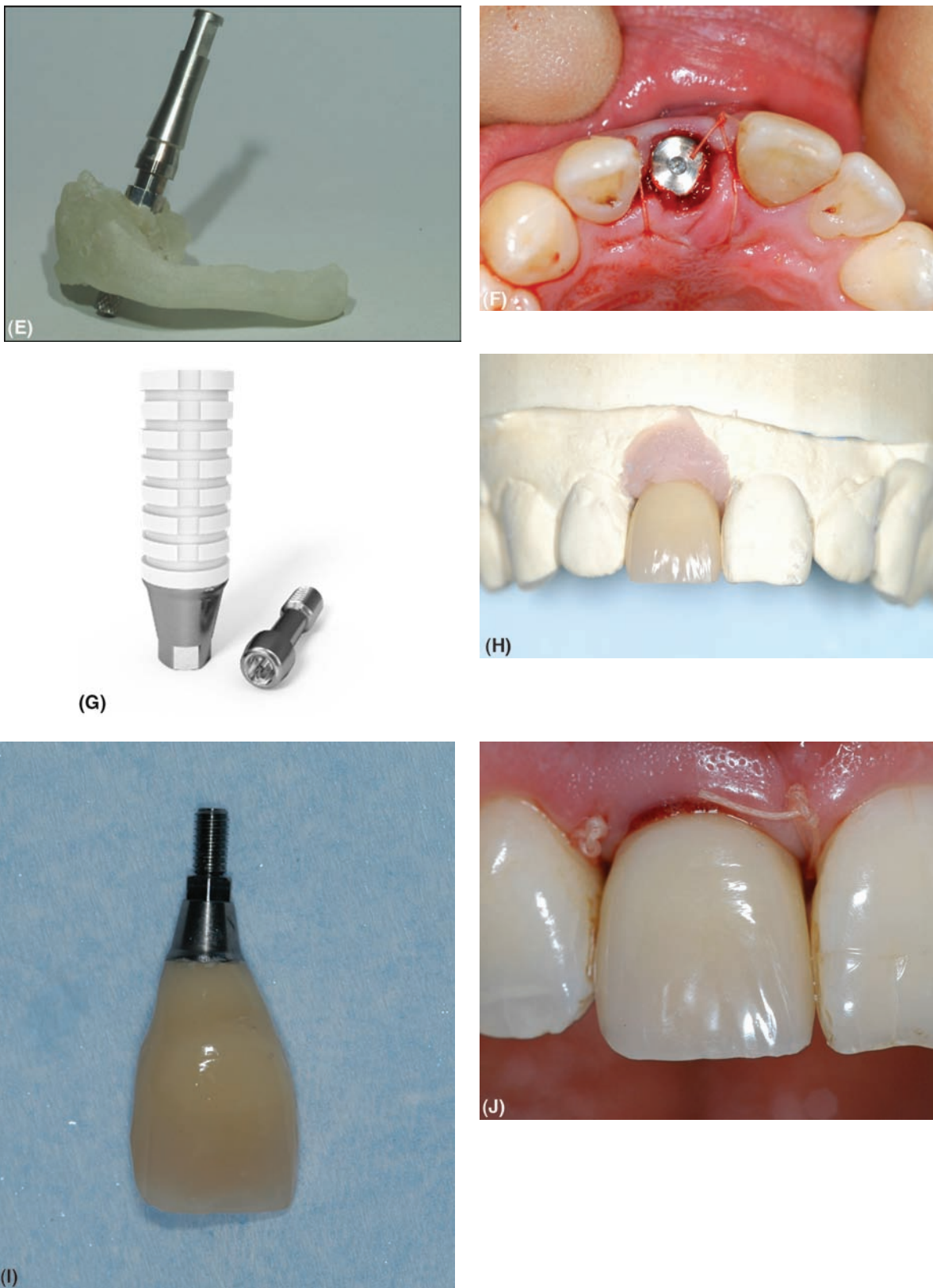
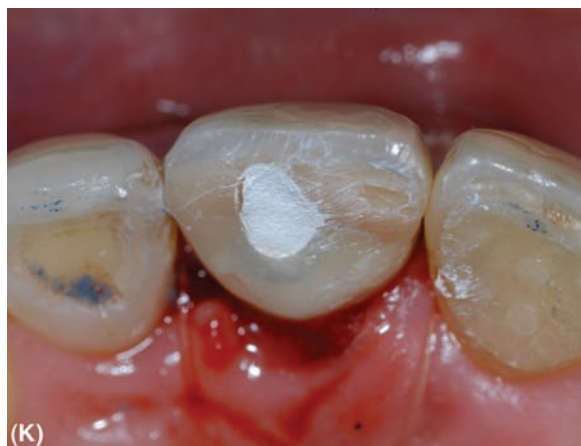

Figure 13.30 (Continued)



**Figure 13.30** (Continued)

impression made using a conventional technique. If a provisional crown is required straight away, this can be sent to the laboratory to fabricate a screw-retained one-piece composite or acrylic tooth and temporary abutment (Fig. 13.30I). An alterna-

tive technique is to pick up the impression coping by linking it with acrylic or composite resin to the surgical stent (Fig. 13.30D). The study model is then adjusted to accept the stent replaced with the impression coping attached to an implant analogue. A new working model is created, which will give a reasonably accurate representation of the implant position, but it will not reproduce the gingival contour around the implant. At implant exposure, the one-piece abutment/crown is seated, and this can be verified visually. Following healing, a customized abutment can be produced and a conventional technique can be followed.

## BIBLIOGRAPHY

- Andersson B, Odman P, Lindvall AM, et al. Cemented single crowns on osseointegrated implants after five years: results from a prospective study on CeraOne. *Int J Prosthodont* 1998; 11:212–218.
- Balfour A, O'Brien GR. Comparative study of antirotational single tooth abutments. *J Prosthet Dent* 1995; 73:36–43.
- Jemt T. Customized titanium single-implant abutments: two-year follow-up pilot study. *Int J Prosthodont* 1998; 11:312–316.
- Jorneus L, Jemt T, Carlsson L. Loads and designs of screw joints for single crowns supported by osseointegrated implants. *Int J Oral Maxillofac Implants* 1992; 7:353–359.
- Laney W, Jemt T, Harris D, et al. Osseointegrated implants for single tooth replacement: progress report from a multicenter prospective study after three years. *Int J Oral Maxillofac Implants* 1994; 6:29–36.
- Palmer RM, Palmer PJ, Smith BJ. A five-year prospective study of Astra single tooth implants. *Clin Oral Implants Res* 2000; 11:179–182.

## Fixed bridge prosthodontics

### INTRODUCTION

The chapters on treatment planning and surgery have emphasized the role of prosthodontic planning prior to embarking on treatment. For fixed bridges, it is essential that thorough planning has been undertaken to determine the end result required. From this, a surgical stent can be produced to guide the surgery and good provisional restorations made that will be able to function during the stages of treatment until the final restoration is achieved.

Making a structure that links together multiple implants requires high clinical and technical standards to take impressions and construct the restoration so that it will fit with a high level of accuracy. With conventional bridgework supported by teeth, the displacement of the abutment teeth within the periodontal ligament can compensate for small errors in the fit of a bridge. Placing a bridge onto implants demands a higher level of accuracy in fit as the bridge needs to seat passively onto the rigid implants. This requirement is increased if the bridge is to be screwed to the abutments rather than cemented.

This chapter uses the term bridge to describe all fixed dental prostheses where implants are linked together. There may not necessarily be a pontic or span between implants.

### PRINCIPLES

#### Short-Span and Long-Span Bridges

The abutments and techniques used to construct implant-supported bridges are the same whether the bridge just involves two implants linked together or if the full jaw is to be restored with six or more implants supporting one fixed bridge (Figs. 14.1 and 14.2). The complexity of achieving an acceptable fit is, however, increased when multiple implants are used. Linking implants in a fixed bridge has the following benefits:

- Shorter implants (under 8 mm) can be protected from overload by the other implants, as the rigid structure will distribute the load over the combined surface areas of the implants.
- Implants placed in areas of high potential stress can be protected by linked structures. For example, linking to other implants can protect the most distal implant in a posterior reconstruction.
- Linked implants allow limited cantilever pontics to be incorporated into a bridge. This is particularly useful with distal extension bridges. It is often difficult to place adequate length implants in distal positions because of lack of bone and anatomic features. By linking implants placed anteriorly, the patient can be provided with teeth in these regions.

Where several implants are available of adequate dimensions, it may be advisable to divide the restoration into separate bridges so it is easier to construct and maintain in the future if

complications arise (Fig. 14.3). Much debate has arisen regarding the desirability of bridges extending across the midline due to the potential jaw flexure (particularly of the mandible) during loading. However, clinical trials have not demonstrated this to be a clinical problem and the authors do not see this as a potential complication.

### Distal Cantilevers

Distal cantilevers may be indicated with free-end saddle restorations where it has not been possible to place an implant as far distal as required for appearance and function. The ability to provide a cantilever depends on several factors (see also chap. 5):

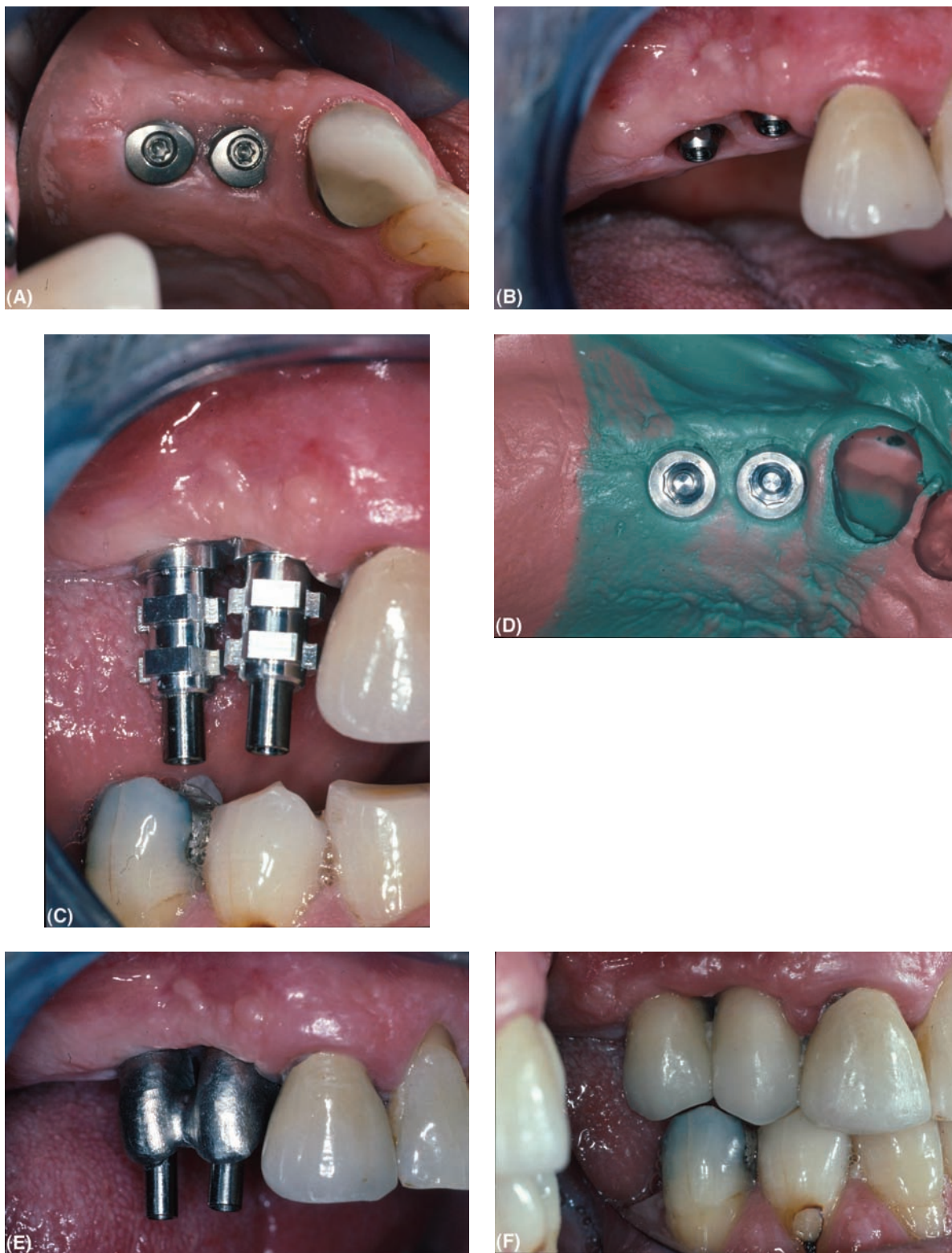
- The potential load that might be placed on the extension. Natural opposing teeth, particularly in a patient with a previous history of parafunction, require caution compared to a cantilever opposed by a removable restoration. The greatest potential loads occur if implant restorations oppose each other.
- The length and diameter of the most distal implant that will take the greatest compressive load.
- The dimensions and position of the most anterior implant as this will take the greatest tensile load.
- The anteroposterior dimension measured from a line drawn between the most distal implant on either side, to the most anterior implant. The greater this distance, the longer the potential cantilever that can be placed as the anterior implant will not be subject to as much stress as if the implants are placed in a straight line.

Some authorities have suggested that cantilevers as long as 20 mm can safely be constructed. The authors would recommend that this figure should be treated with caution and ideally distal cantilevers even with several implants of adequate size in a good arch shape should be restricted to 10 to 15 mm (two premolar-sized pontics).

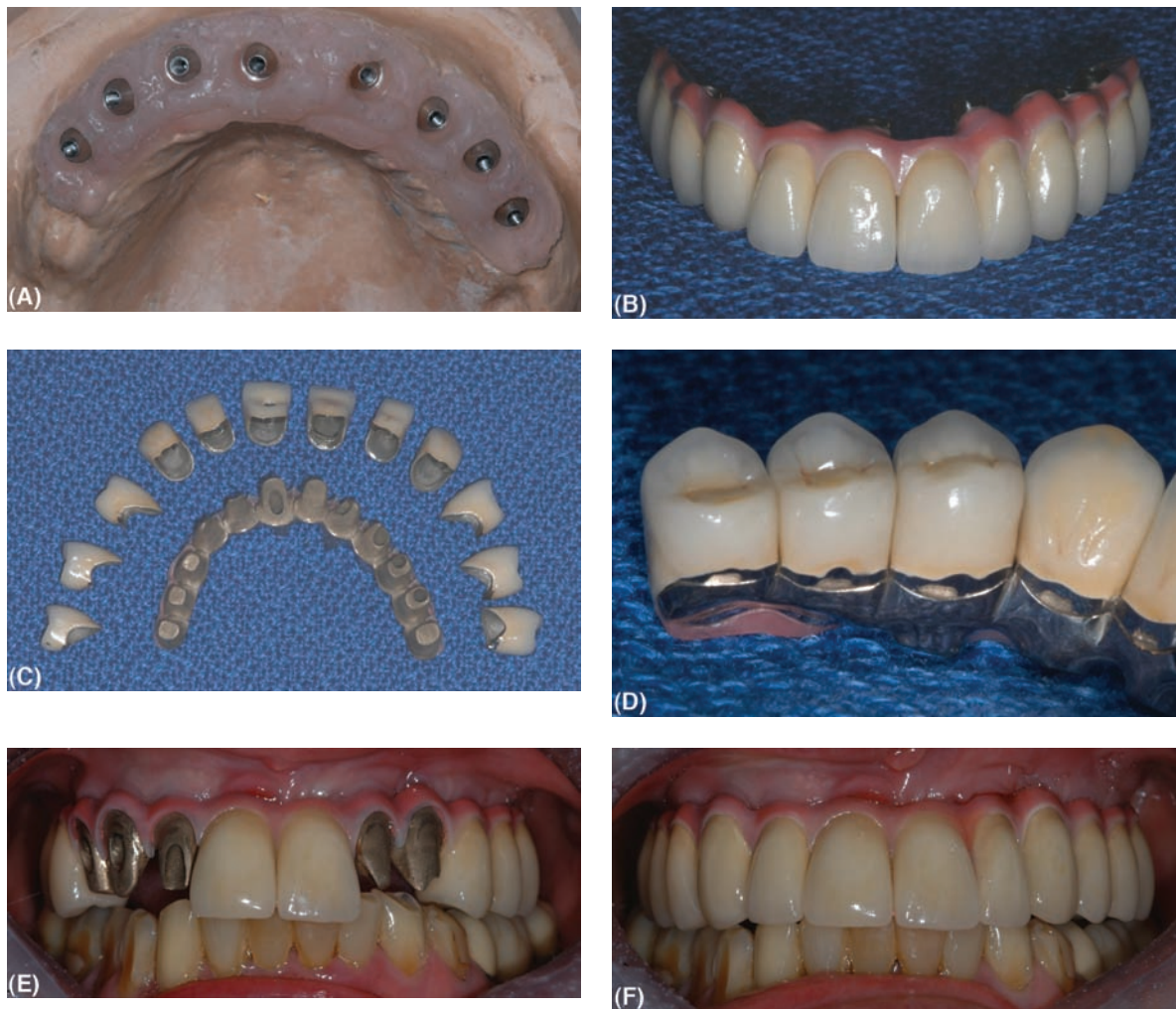The potential complications from cantilevers are mostly mechanical in nature, including screw loosening, veneer fracture, and even bridge framework fracture (see chap. 16).

### Screw-Retained or Cemented Bridges

Attaching bridges to implants with screws allows the possibility of making the restoration easily retrievable and free from the potential problems of cementation, a concept that can offer considerable advantages over conventional bridgework based on teeth. Most implant designs have a manufactured bridge abutment designed for screw-retained bridges (Fig. 14.4). These can be one- or two-piece and locate onto or into the implant head and are held into position with an abutment screw (Fig. 14.5). The abutment is symmetrical and conical in design and on the top has a thread for a smaller "bridge" screw that will retain the bridge. This screw passes through a



**Figure 14.1** Two Straumann implants have been placed in the missing premolar teeth sites. (A) Healing caps in position. (B) SynOcta bridge abutments for a screw-retained restoration have been placed. (C) Impression copings attached to the abutments. (D) Impression copings removed in the impression. (E) Metal framework tried in with guide pins. (F) Completed bridge—note the subgingival margin placement for optimum aesthetics.



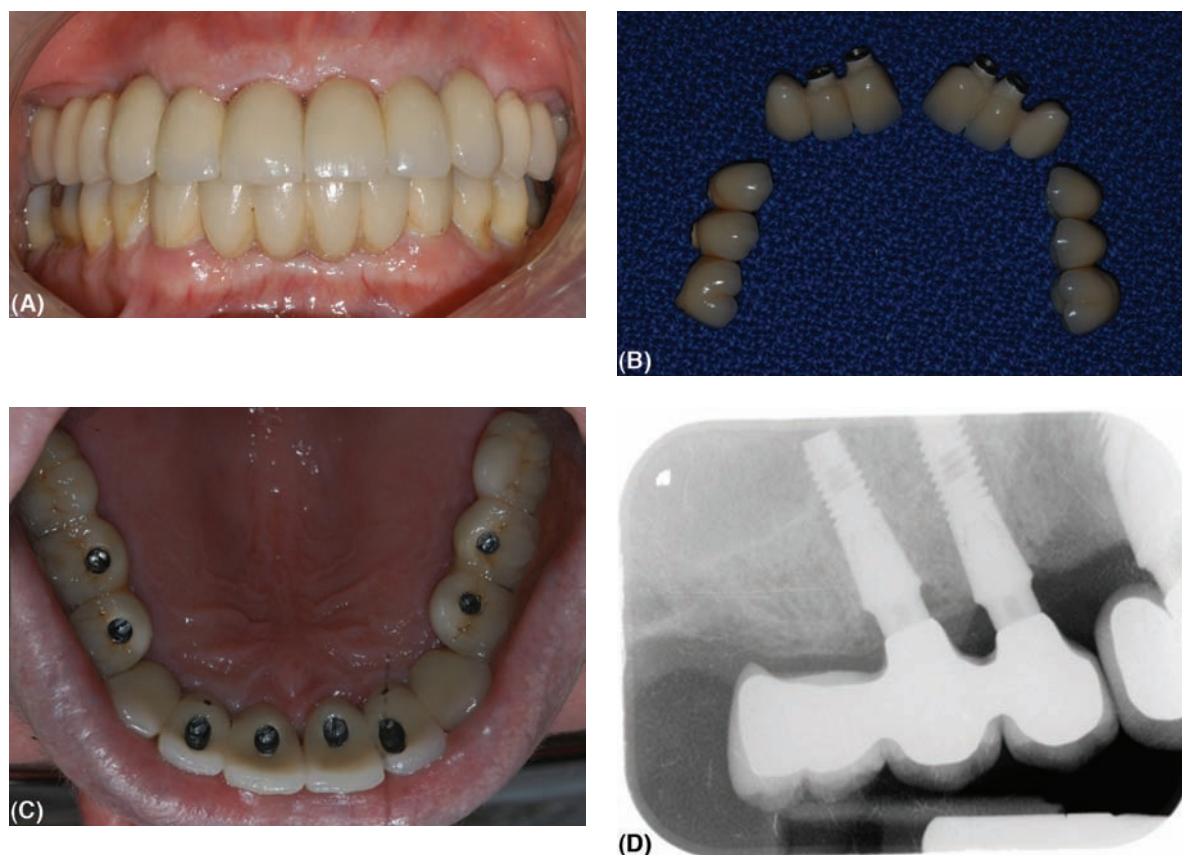
**Figure 14.2** A full-arch screw-retained gold-ceramic bridge on eight Astra Tech implants. (A) The master cast showing the implants in 14,13,12,11,21,22,23,24 sites. (B) The completed bridge prior to placement. Note the use of pink composite resin material to replace some of the missing soft tissue. (C) The bridge is constructed with a gold subframe that is screw-retained and separate cemented metal-ceramic crowns. (D) Small recesses are built into the crowns to aid removal in the future if required. (E) The bridge part way through assembly in the mouth. The individual crowns will be easy to repair or replace in the future should problems occur. (F) The completed restoration.

machined gold cylinder that is incorporated into the bridge structure and seats accurately onto the abutment. Abutments are also made with a built-in degree of angulation to change the orientation of the bridge screw relative to the implant itself. The small bridge screw that retains the restoration is designed to be the weakest link in the implant assembly and should be the part to fail if the restoration is overloaded or subjected to trauma.

The screw-retained bridge needs to be a passive fit onto the abutments. If a bridge screw is tightened into an abutment and the gold cylinder is not seating evenly, the screw will be put under tension and not only will the bridge not be seating down properly and marginal gaps exist, but there is a high chance of the screw loosening or fracturing with time. Each bridge gold cylinder needs to be in this exact relationship and

the complication of constructing a bridge with multiple abutments lies in achieving this degree of accuracy. For many dentists, the advantage of ease of removal of the bridge is outweighed by these potential difficulties.

Cemented bridges do not necessarily demand such high standards of precision, as the cement lute will allow a bridge to seat without putting the structure under tension (Fig. 14.4). This is not a justification for poor technical or clinical standards but reflects a reality that perfection is not reliably achieved. Cemented bridges are constructed on abutments that are prepared in the laboratory to resemble prepared teeth as required for conventional bridges utilizing the same techniques for customized abutments for single teeth. More laboratory time is often required compared to techniques that use standard manufacturer-made components. The



**Figure 14.3** Full upper jaw screw-retained gold-ceramic bridges have been provided on eight implants: (A) The completed case. (B) Four separate bridges have been used, all linking two implants together with one pontic on each bridge. (C) From the occlusal aspect, the screw holes are in favorable positions. (D) One of the completion periapical radiographs showing implants in the premolar sites with one distal cantilever pontic.

retrievability of cemented bridges can be controlled to some extent by the use of temporary cements as these may allow removal of bridges if required. The potential for dissolution of cement from margins will not result in caries as it can with conventional bridges. Cemented bridges do not require an access hole for the gold screw through the bridge. Although this is rarely a problem for most patients, it can present complications if the screw hole has to be positioned in a visible area or at a point of essential occlusal contact. Cemented bridges are therefore often indicated if implants have not been placed in the long axis of the desired restoration. For many dentists, the major advantage of cemented bridges is the similarity to conventional crown and bridge techniques.

The decision between screw-retained and cemented bridges also depends on the ability of the dental laboratory to construct an acceptable restoration. The decision should be based on the clinical situation and articulated working casts prior to abutment selection and the technique most suited to the individual situation chosen. Often the choice has been

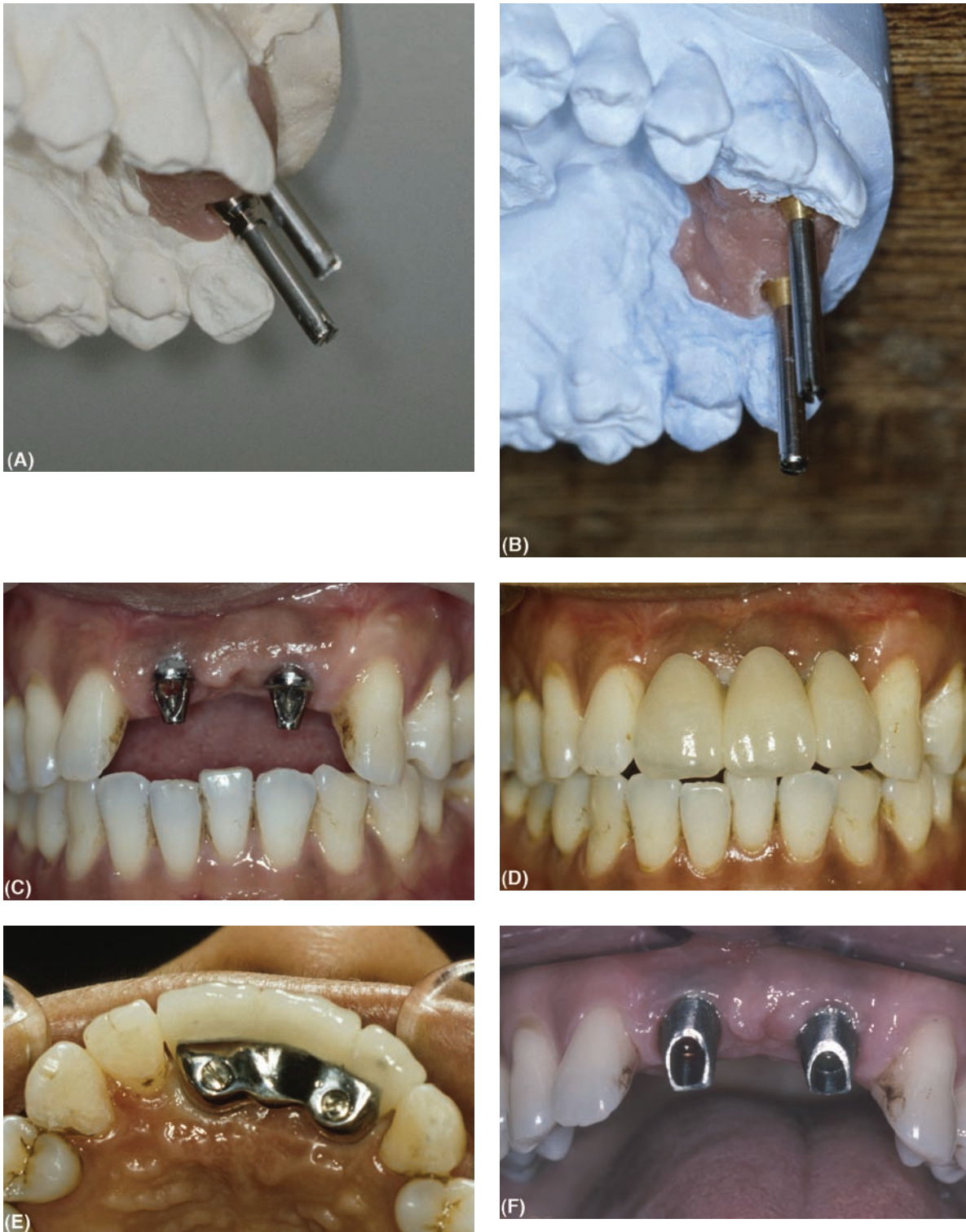
made at the treatment planning stage following discussion with the patient.

### Advantages of Screw-Retained Bridges

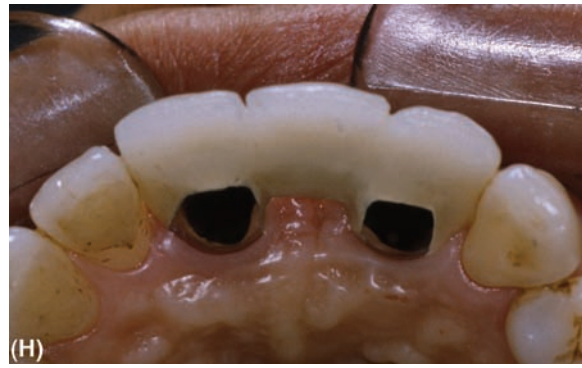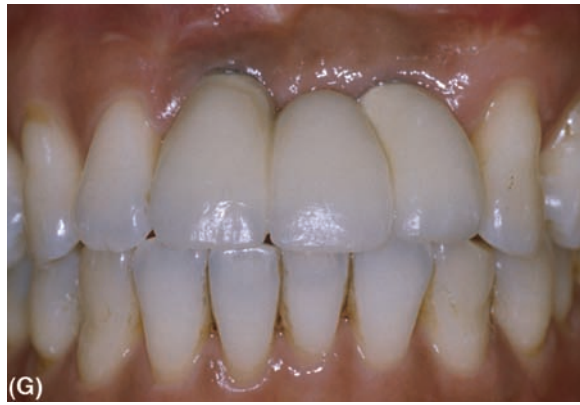- Easily retrieved
- Complete seating of the restoration is more readily ensured
- Utilizes manufactured components for all fitting surfaces
- No risk of cement retained at margin—allows deep margin placement
- Can cope with reduced vertical space between implant head and opposing teeth

### Disadvantages of Screw-Retained Bridges

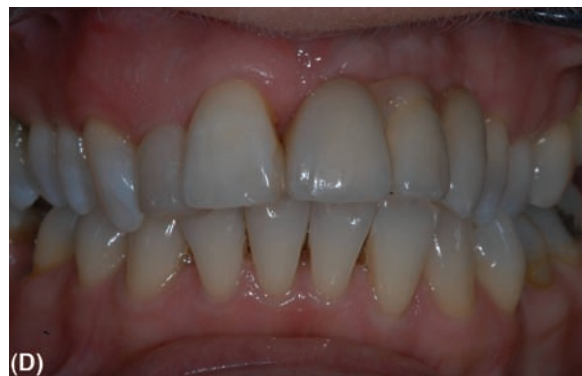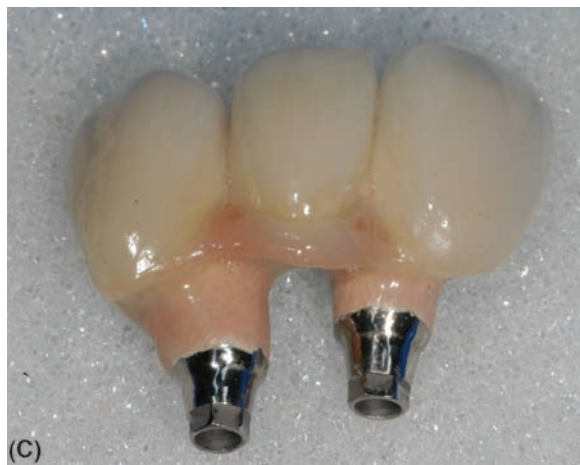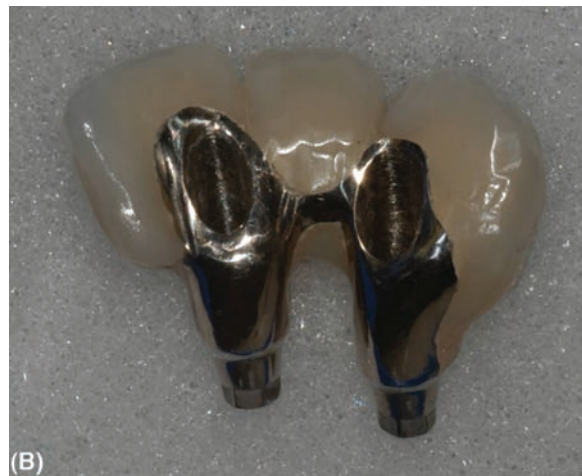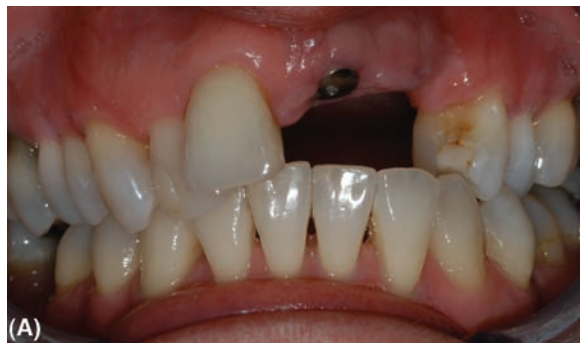- Implants need to be in long axis of the restoration so the screw holes are on the occlusal surfaces or angled abutments need to be used



**Figure 14.4** Two Nobel Biocare implants supporting an anterior bridge: (A) Guide pins have been placed in the implant analogues following head of implant impressions. The path of insertion of the implants would dictate labial screw access holes if convention screw-retained abutments are used. (B) Using angled abutments, the screw access can be realigned to an acceptable position. (C) Angled abutments in position—note the metal collar that is just visible above the gingival margin. (D) The completed bridge. The bridge structure has been extended in front of the abutments to disguise the visible metal. (E) The palatal screw access results in a bulky contour. (F) The same case restored with preapable (TiAdapt) abutments. The angulation change has been achieved by heavily preparing the abutments labially. (G) The bridge cemented to the abutments. It has not been possible to completely disguise the metal abutment margin. (H) The resulting palatal contour more closely resembles natural contours than the previous screw-retained bridge.



**Figure 14.4** (Continued)



**Figure 14.5** A one-piece screw-retained bridge on Astra Tech implants. (A) Before restoration. There has been extensive hard and soft tissue loss. (B) The bridge incorporates the abutments into the gold framework and the screw access holes are for the larger abutment screws. (C) Pink porcelain has been used to make up some of the lost soft tissue. (D) The completed bridge.

- Screw hole may be visible or may be in an important area of the occlusal surface
- Requires a “passive fit” for each gold cylinder onto the abutments
- Risk of bridge screw loosening or fracture

### Advantages of Cemented Bridges

- Passive fit not as critical but is desirable
- No screw access holes
- Similar to conventional bridge techniques
- Can easily overcome differences in angulation between implants and restore implants with adverse angulations

### Disadvantages of Cemented Bridges

- Retrievability more difficult
- More laboratory time required to produce customized abutments
- Cementation needs to be controlled especially with subgingival margins
- Difficult to ensure full seating of the bridge especially with tight or deep gingival “collars”
- Adequate vertical height required to make the abutments retentive

### Index/Location of Abutments

As discussed in chapter 13, single tooth abutments need to engage with the index (which can be the external hex in flat top implants or internal facets in internal conical implants) so that they are able to remain stable with rotational forces. When implants are being linked together, this is not required, and for ease of use, manufacturers make the abutments for screwed bridges so they do not engage antirotational features on the implants. When abutments are being used that are customized in any way, including the use of angled abutments that need to be located in a specific position relative to the implant, the abutments need to engage in the index to ensure they are correctly aligned to each other (Fig. 14.4). This is also essential if abutments are being transferred from a master model to the mouth and vice versa to ensure correct positioning. The laboratory can supply a jig to aid in this positioning.

### ABUTMENT TYPES

As with single tooth restorations, there are several types of abutments, and the manufacturers’ versions are listed in Table 14.1.

### For Screw-Retained Bridges

Bridge abutments can be either one-piece or two-piece and are designed to cope with differences in angulation between implants. The abutments have a tapered top that is normally between 20° and 45° so theoretically severe differences in angulation between implants can be compensated for and a one-piece framework be seated onto the abutment tops (Fig. 14.6).

The original abutments first designed for implants (Nobel Biocare standard abutment) were a simple parallel-sided abutment with a flat top. The bridge construction started at the top of the abutment and this design lends itself to reconstructions particularly in the lower jaw where considerable resorption has occurred and aesthetics are not demanding (often described an “oil rig” design). In areas with higher

**Table 14.1** Examples of Abutments Used for Fixed Restorations

Manufacturer	Type	Name
Nobel Biocare	Screwed	Multiabutment Angled abutment
	Cemented	TiAdapt AurAdapt Procera
Astra Tech	Screwed	UniAbutment Angled abutment
	Cemented	TiDesign abutment Cast design abutment Atlantis abutment
Friadent	Screwed	MP Abutment
	Cemented	Telescopic abutment AuroBase
Straumann	Screwed	SynOcta abutment Multibase abutment
	Cemented	Gold abutment Anatomic abutment Cares abutments

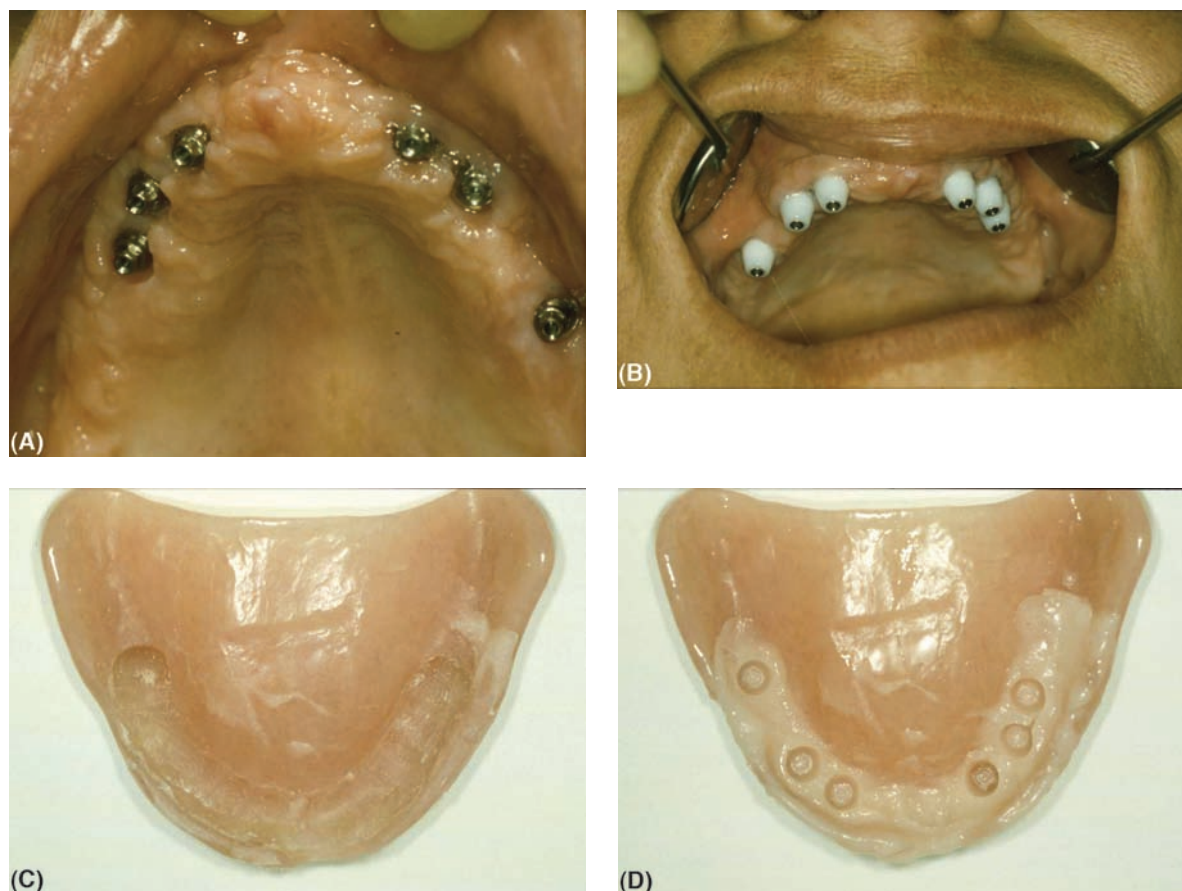
Nobel Biocare, Nobel Biocare AB, Göteborg, Sweden; Astra Tech, Astra Meditec AB, Mölndal, Sweden; Friadent, Dentsply, York, PA, USA; Friadent GmbH, Mannheim, Germany; Straumann, Institut Straumann AG, Waldenburg, Switzerland.

aesthetic demands, the designs already discussed allow the bridge framework to cover the abutment so it is in effect hidden under the bridge. Abutments come in a variety of collar heights to allow for different soft tissue thickness. The collar height is chosen to allow for a subgingival margin placement if required. Variations in design also allow for different abutment head heights. In a situation where there may be little interocclusal space between the head of the implant to the opposing tooth, a shorter abutment will be required. It is not normally possible to restore an implant with a screw-retained bridge if there is less than 5 to 6 mm of interocclusal space. Ideally, there needs to be at least 2 mm of space beyond the bridge screw so that it can be covered with an aesthetic restoration.

### Angled Abutments

The access hole for the bridge screw ideally needs to emerge through the center of the occlusal surface of the restoration. Angled abutments are designed to compensate for a different path of insertion for the bridge and bridge screw compared to the implant (Fig. 14.7). Angled abutments are available in the range of 15° to 35°. Depending on the position in which the abutment is seated on the implant, it is also possible to use this angulation change to “move” the bridge screw access in a mesial or distal direction as well. Angled abutments have matched gold bridge cylinders. When angled abutments are used, it is normally necessary for the laboratory to provide an acrylic jig to allow the clinician to orientate the abutment to the correct position. This can relate either to adjacent teeth or other abutments. The jig should be kept for the future in case the abutments ever need to be removed and replaced.

An interesting development is the use of “curved” screw access holes that allow for small alterations of the position of the screw access hole relative to the long axis of the implant. This technique includes the use of a bendable waxing tube that is incorporated into the bridge structure, which allows passage of a special screwdriver able to negotiate the curvature.



**Figure 14.6** (A) Nobel Biocare EsthetiCone bridge abutments in place. (B) Abutment protection caps used as the abutments will be left in the mouth between appointments. (C) The complete denture is adjusted to accommodate the abutments and caps. (D) Soft relining material is used to adapt the denture for use while the bridge is being constructed.

## For Cemented Bridges

### *Customized Abutments*

These abutments are the same as those already discussed in chapter 13. Semiprepared or fully customized cast or CAD/CAM (computer-aided design/computer-aided manufacturing) abutments can be prepared in the laboratory so that they are retentive, have margins in an aesthetic position, and have an acceptable degree of parallelism to each other to be able to have a conventional bridge cemented onto them (Fig. 14.8).

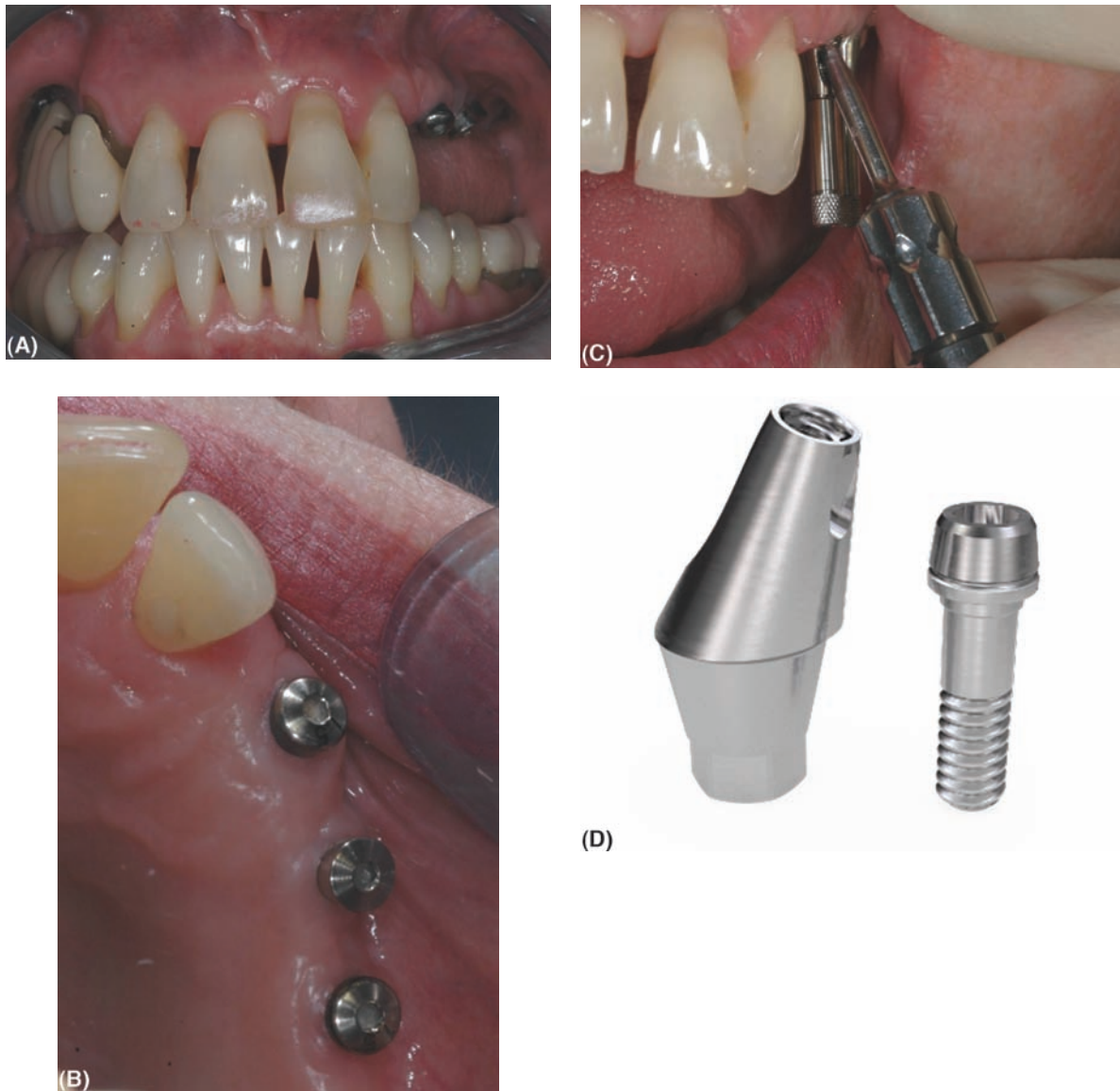To construct a bridge using this approach, a head of implant impression needs to be taken.

Abutments are best chosen using a trial kit of abutment analogues placed onto the working model. They should be chosen with the following features in mind:

- That the dimension and height of the abutment as it sits on the implant allows for the planned emergence of the restoration through the gingiva.
- That there is adequate bulk of metal just below the gingival margin to allow for the abutment to be prepared to accept an adequate thickness of bridge margin subgingivally.

- That there is adequate height of the abutment to allow it to properly support the bridge framework.
- That there is adequate bulk of metal in regions where there may need to be significant reduction of the abutment to allow for changes in angulation and orientation between implants. It is sometimes better to choose a larger abutment.

To accommodate these requirements, it is normal for fully customized abutments to be chosen either using a casting technique following a full wax-up or using a CAD/CAM approach. As implants can be reliably positioned using the implant index from model to mouth, it is possible for the definitive restoration to be made on the customized abutments and then abutments and bridge placed in situ. However, if there is any degree of gingival recontouring required or if implants do not have an indexing feature, the customized abutments need to be seated with a jig and tightened into position. It is best to place a provisional bridge following insertion of the abutments, and then take a further impression of the abutments in position for construction of the definitive bridge at a later stage. A small degree of adjustment of the



**Figure 14.7** Three Astra Tech implants have been placed to replace the upper canine and premolar teeth. The residual ridge was thin and was expanded to receive the implants. As a screw-retained bridge was desired, angled abutments are used to place the screw access holes in the optimum position. **(A)** Prior to restoration, the healing abutments are in place. **(B)** From the occlusal view, the narrowness of the ridge is clear. **(C)** An angled abutment is screwed into place. The screwdriver, which is tightening the abutment screw, is in the long axis of the implant. The guide pin is in the bridge screw hole showing the degree of change the angled abutment has produced. **(D)** A titanium 17° angled abutment from Astra Tech. **(E)** The pick-up abutment impression copings are attached. **(F)** A customized tray with a chimney to support the impression material around the copings is tried in. **(G)** Impression material (Impregum) is syringed around the copings. **(H)** The tray is seated and the tops of the impressions pins identified. **(I)** On removal, the impression copings are visible and are checked for stability. **(J)** Abutment replicas are attached to the copings. **(K)** The metal framework. **(L)** From the occlusal surface, adequate space for the porcelain is prepared. **(M)** The frame work is tried in to check the fit and a further occlusal record taken. **(N)** The completed bridge. Note that there is a small part of the titanium abutment visible on the distal implants but this will not cause an aesthetic problem. **(O)** The completed bridge in position. **(P)** From the occlusal surface, the screw holes are in a favorable place.

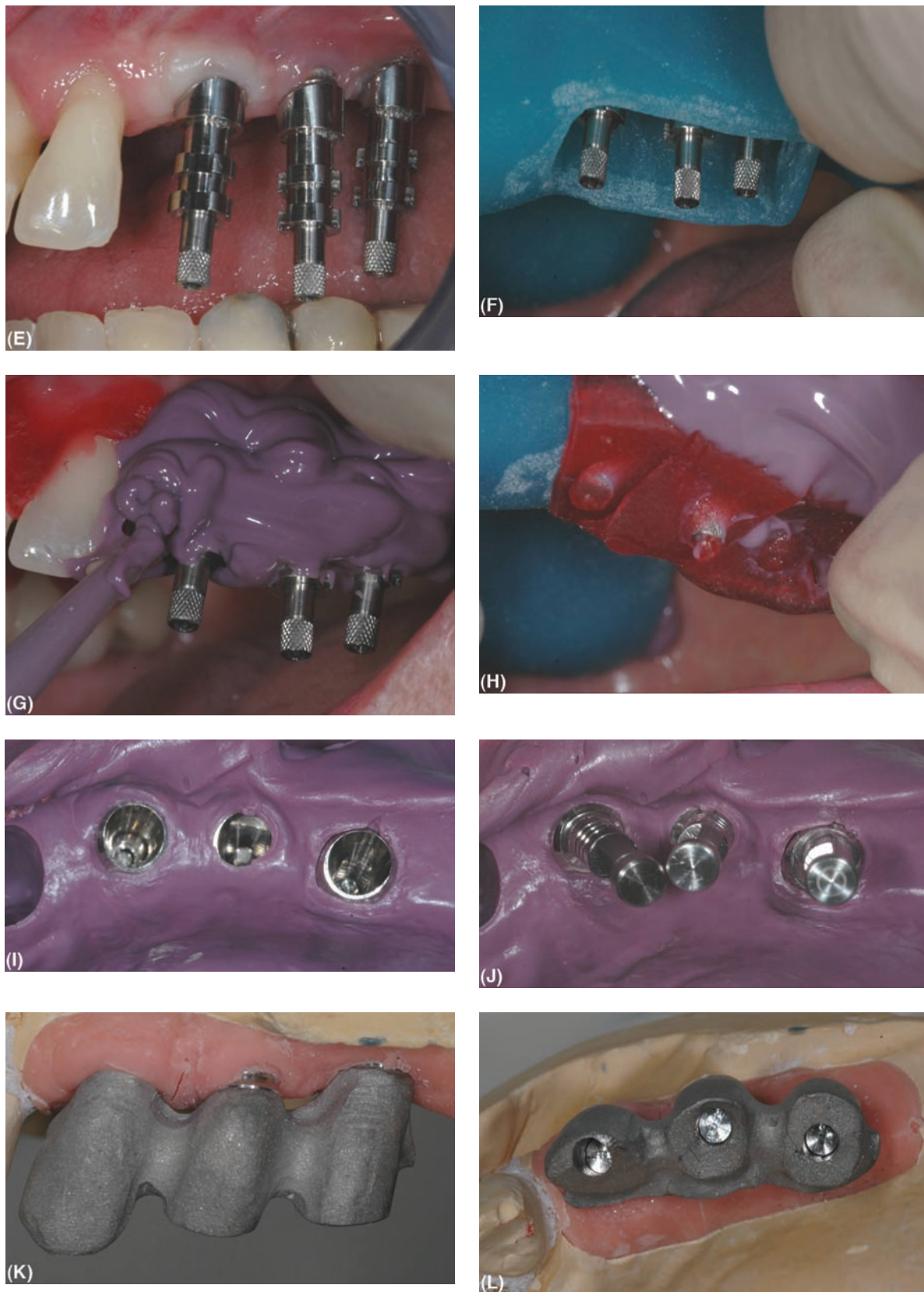
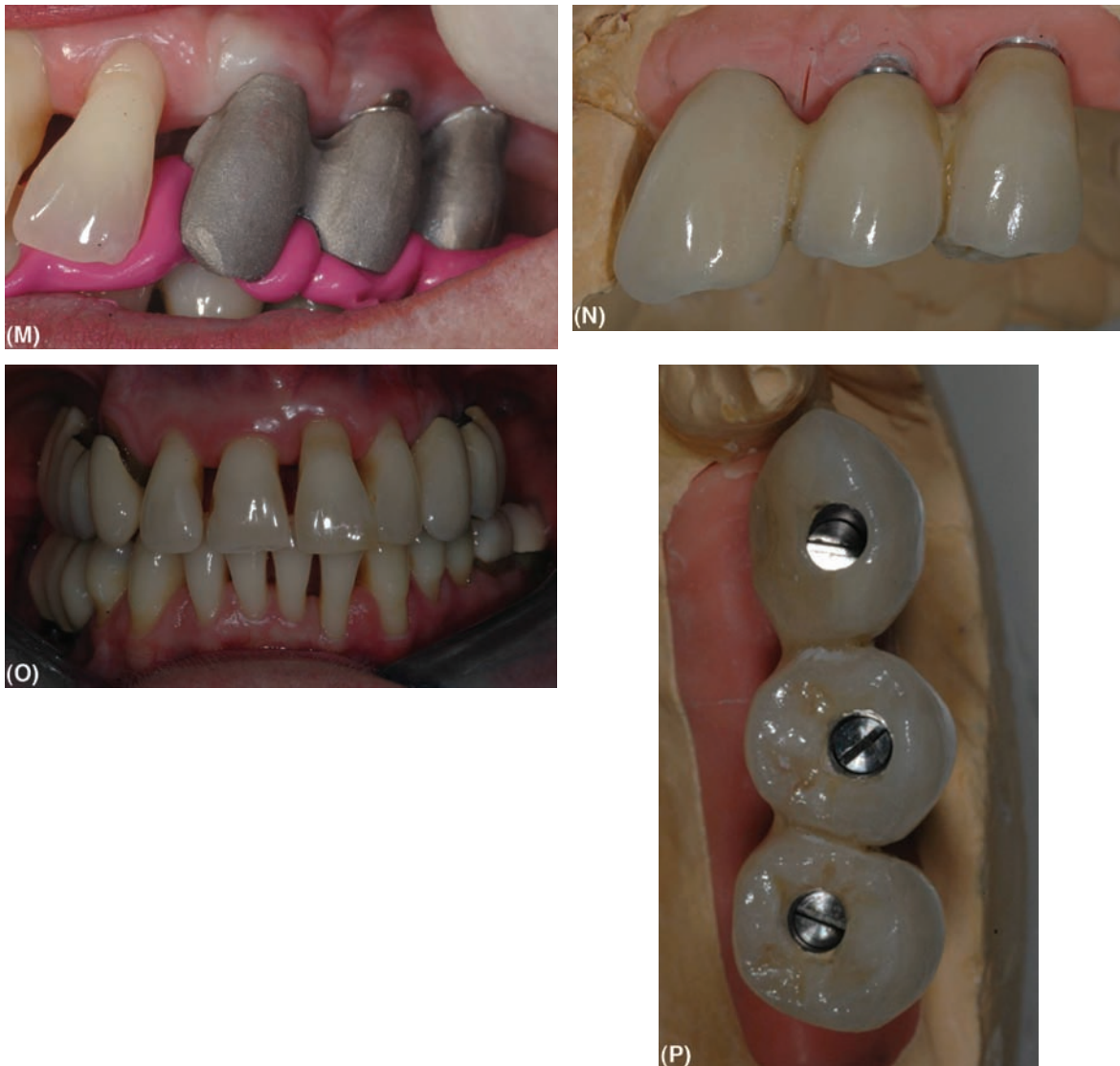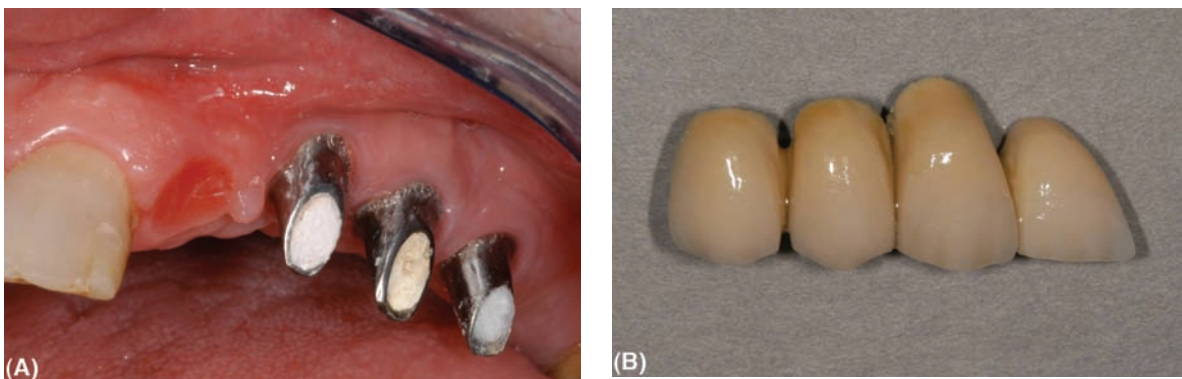


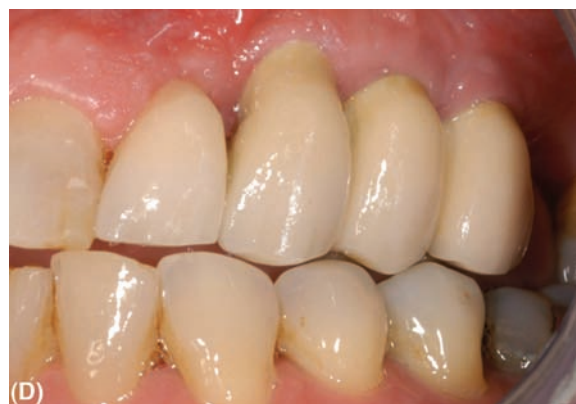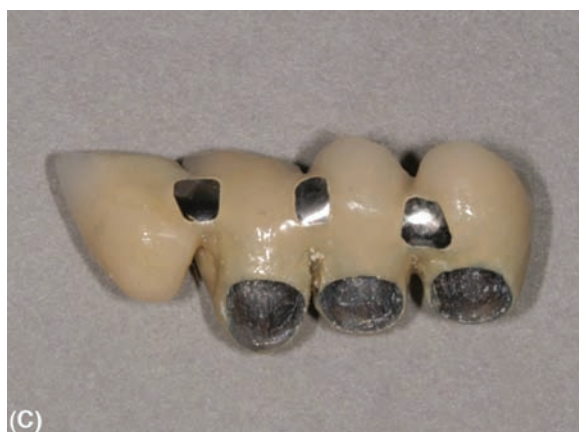Figure 14.7 (Continued)



**Figure 14.7** (Continued)



**Figure 14.8** A cemented four-unit bridge constructed on Astra Tech customized abutments: (A) Three titanium customized abutments have been made parallel to each other. Temporary filling material fills the screw access holes. (B) A metal-ceramic bridge is constructed. (C) The bridge from the palatal aspect. Note the space left for cleaning between the implants. (D) The completed bridge on cementation.



**Figure 14.8** (Continued)

abutment can be safely made in the mouth with a high-speed drill and copious irrigation if necessary.

### ABUTMENT SELECTION AND IMPRESSIONS

Abutments can either be selected directly in the mouth or an impression can be taken of the implant head and the abutments chosen from the resulting cast. Quite commonly, it is not clear exactly which abutment will be required from a clinical examination. The incorrect choice of abutment can be costly especially if the error is not determined until after the restoration has been made. Before the abutment is finally chosen, it is essential that there is adequate information available to know exactly what the shape and position the final restoration should be so that the correct abutment is chosen to achieve that result. This can be just as relevant for short-span bridges with only two or three implants as for extensive full-arch reconstructions.

### Implant Head Impressions

An impression of the implant head to produce a laboratory cast can be used to choose the abutment, to allow preparation of customized abutments, and often to act as the working model for complete bridge construction. Impression copings are placed onto the implant head (Fig. 14.9). With a flat top implant, a verification radiograph will be required to ensure the impression coping is fully seated over the external hexagon. The impression coping is secured to the implant by a guide pin that screws into the abutment screw hole. The top of the guide pin projects beyond the coping and should be longer than adjacent teeth. An impression tray is modified so that the guide pin projects through the tray without touching it (for more details, see later in this chapter). The coping is picked up in an impression material that sets rigid and the guide pin unscrewed. The coping should not move in the impression. An analogue of the implant is attached to the coping prior to pouring a cast. The cast should be produced with a soft tissue replica as the implant head will normally be subgingival and a rigid replica of the gingiva will not allow access to the implant head. Using this cast, the abutments can be selected.

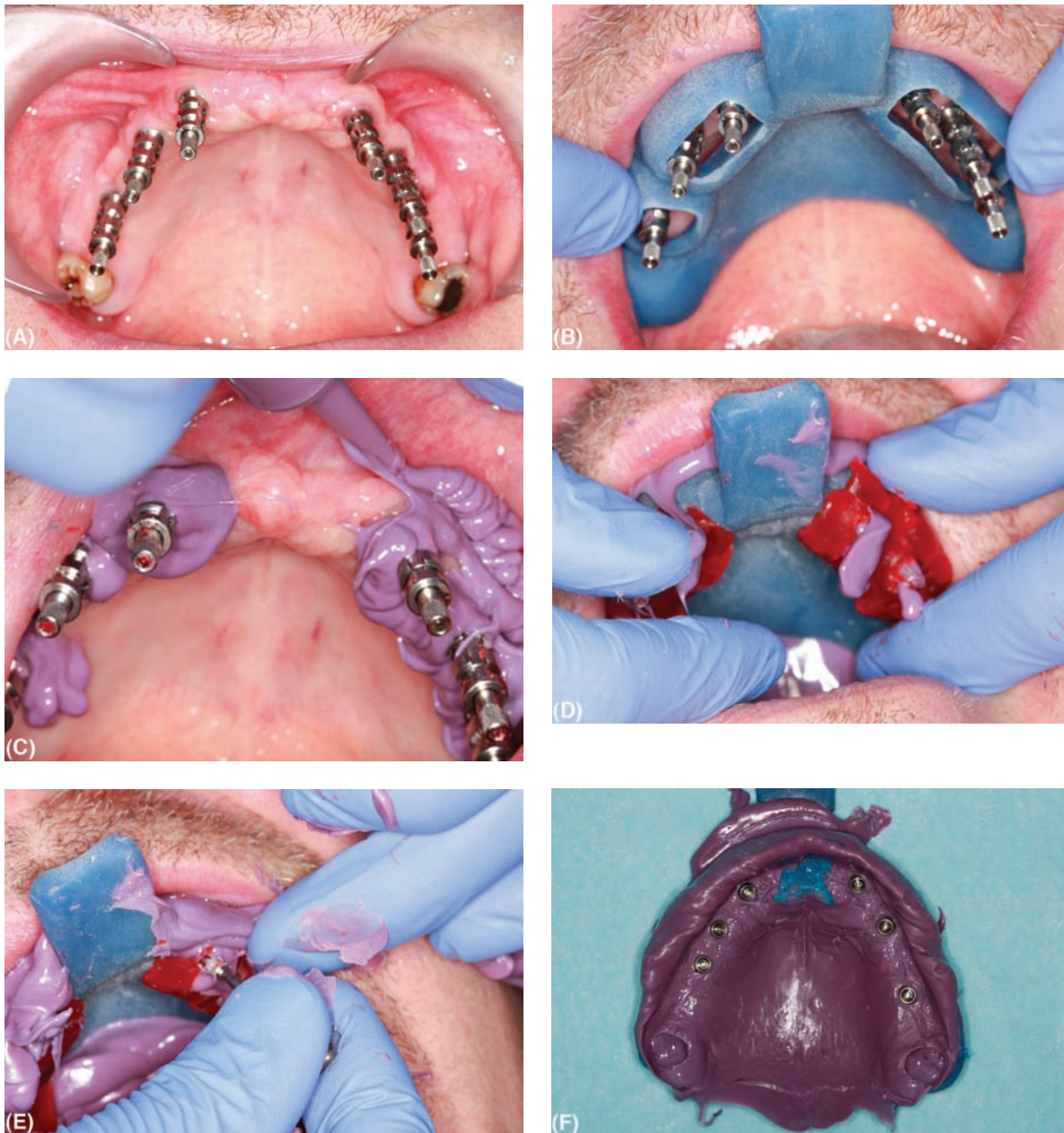
### Evaluation Using a Diagnostic Workup

A guide is needed of the required tooth position to relate the implant head cast to the new restoration. If the patient has a satisfactory existing denture or bridge that is to be copied, an impression can be taken of it and a putty mask made of the labial and incisal surfaces. This can be tried against the implant head cast and will demonstrate the relationship between the tooth and implant. Alternatively, if a diagnostic wax-up has been carried out, from which a surgical stent was provided, this can also be related to the new working cast.

If no accurate guide is available and there is any doubt as to the orientation of the implants, it is advisable to produce a new diagnostic tooth setup that can be tried into the mouth and agreed with the patient before the abutments are chosen. This can either be produced as a denture type setup or ideally a fixed setup. Temporary bridge cylinders are linked together with acrylic or laboratory composite resin on the working cast and a diagnostic setup produced in wax or with denture teeth, which can be tried into the mouth secured to the implants. It can give an exact idea as to the possible complications that may be encountered before expensive abutments and laboratory work has been undertaken. This information can be transferred into a provisional bridge and the patient allowed to live with the restoration for a period to ensure it is satisfactory before the final restoration is made. CAD/CAM techniques are now available to produce bridges directly from a scan.

### Abutment Try-in Kits

Many manufacturers produce replicas of the abutment types that can greatly assist abutment selection (Fig. 14.10). They can either be used in the mouth or more commonly on an implant head cast. Made of aluminum they will not damage the implant or implant replica, and for ease of recognition they are often color coded so that different sizes can be easily recognized. The implant head cast is related to the putty mask. Abutments can be tried in to get the best possible screw access position, marginal height, and emergence. The selected abutment should then be related to the opposing cast



**Figure 14.9** Pick-up implant level impressions: (A) Six implant level impression copings are attached. (B) A special tray is tried in to check there is adequate space around the impression copings for the impression material. (C) Impression material (Impregum) is syringed around the abutments. (D) The tray is carefully seated and the tops of the impression pins are located through the wax that was placed over the open areas in the tray. (E) Once set, the impression pins are unscrewed. (F) The completed impression.

to check for interocclusal clearance. Try-in kits are also produced for semiprepared abutments.

#### Abutment Selection and Seating for Screw-Retained Bridges

In a straightforward situation, where a short-span screw-retained bridge is to be constructed and it can be certain that

the implant is orientated such that the bridge screw will emerge through the occlusal surface (placement of a guide pin into the implant will give a clearer view of the implant's orientation), the following clinical steps can be followed:

- Determine the distance from the implant head to the opposing tooth using a periodontal probe or dividers. If the space is under 7 mm, it might be necessary to use the



**Figure 14.10** (A) The Nobel Biocare abutment try-in kit. Replicas of the abutments can be tried on a cast or intraorally. (B) Examples of the analogues. The 17° and 30° angled abutments can be compared.

shortest abutment with the most conical top (even if the implants are well aligned) as this is going to have the smallest vertical height.

- Using a periodontal measuring probe or a manufacturer's depth-measuring device, determine the abutment gingival collar height. The planned margin should be between 1 and 2 mm below the gingival margin at its lowest point on the visible surfaces.
- Place the abutment but do not tighten it. Check the orientation and the occlusal clearance. Seating may need to be verified radiographically.
- If the abutment is going to be left in position and the temporary restoration can be placed over it, the abutment screw can be tightened to manufacturer specifications. If the abutment is to be removed to allow the healing abutment to be replaced between appointments, it should only be hand tightened.
- A transfer impression of the abutment can be taken (rather than an implant head impression).
- A protective cap can be placed on the abutment if it is to be left in situ (Fig. 14.6B), and the temporary restoration modified to accommodate the resulting dimensions.

If it is not possible for the abutment to be chosen from a clinical examination, an implant head impression should be taken, and the abutment selected on the model as already outlined. The implant head model can be used as the working cast for the final bridge as long as it is accurate and shows sufficient detail of the rest of the arch. Many operators have proposed that for large bridges it is better to choose the abutments from the implant head cast and then retake an impression with the abutments seated in the mouth. The authors find that this is not necessary if the implant head impression is accurate. The chosen abutments are therefore seated onto the implant head cast and hand tightened using laboratory screws (as the gold

or titanium screws used in the mouth might be damaged in the stainless steel implant analogues). The bridge is therefore constructed on the actual abutments that will need to be cleaned and sterilized before placement in the mouth.

Care should always be taken not to leave the healing abutment out for any length of time as the gingiva will quickly contract and it will be painful for the patient when it is stretched back.

#### *Impression Trays*

Custom made trays are useful in a mouth with difficult access or a complex or outsize shape or in cases with multiple implants where the chairside time in modifying a stock tray is longer. They should be rigid in design and should be formed to support the impression coping along its full height by the use of a chimney design (Fig. 14.9B). Spacing of at least 2 mm is recommended.

Stock trays should be of a good quality so that they will still be rigid following cutting an access hole for the guide pin. The stock tray size is chosen in the normal manner and the position of the emergence of the guide pin marked. Access holes are prepared to ensure that the tray does not encroach on the impression coping, as they should not touch the tray.

The access holes for the guide pins are covered in wax to prevent the impression material flowing out through the hole (Fig. 14.9D).

#### *Impression Materials*

Polyethers and silicone impression materials have physical properties that make them suitable for implant impressions:

- The material should set rigid enough to support the coping and prevent movement of the coping on removal from the mouth and casting of the model.

- It should record enough fine detail to properly identify the gingival contours and other teeth in the mouth.
- It should be dimensionally stable and not react with materials used in model production such as the gingival replica.
- It should accept disinfection techniques.

For these reasons, it is not recommended to use light-bodied impression materials around the impression copings as they will not be strong enough and heavy putty materials will not flow around the copings or record fine details. One-phase medium-bodied paste systems are preferred.

Some operators recommend splinting impression copings together with acrylic prior to impression taking to ensure that the copings are stable relative to each other. There is nothing to recommend such extra complexity.

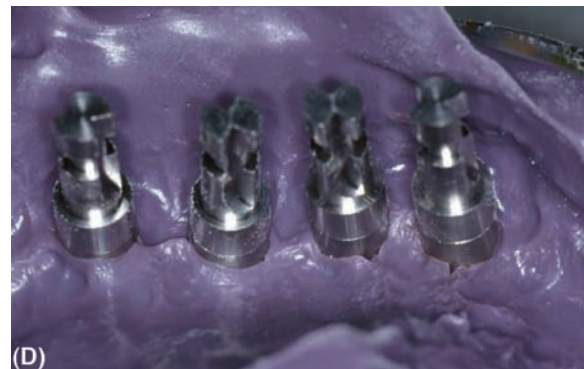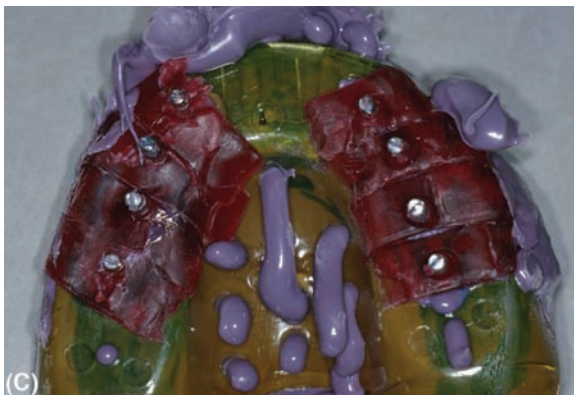
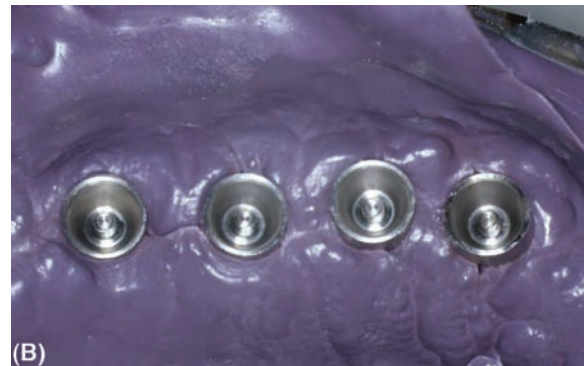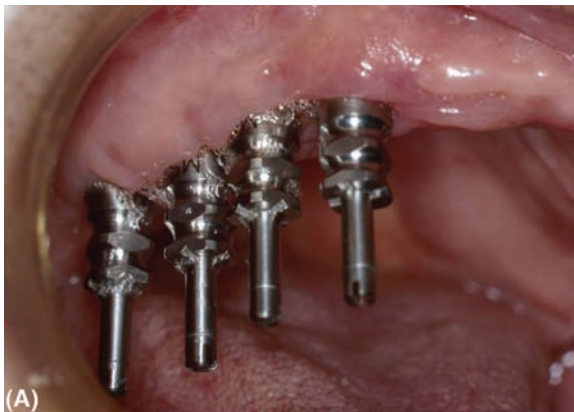#### *Pick-up Impressions (Open Tray Technique)*

The most reliable impression technique to follow is the pick-up technique (Fig. 14.11). As already described, the impression coping is secured to the abutment with a guide pin. These are available in a variety of lengths to ensure the correct projection through the impression tray while still having access with a screwdriver to the pin. The impression material is syringed around the coping and the tray filled. As the tray is seated in the mouth, the guide pins can be felt by the operators' fingers through the wax over the access holes. If the pins are not felt, the tray should be further seated while the impression material

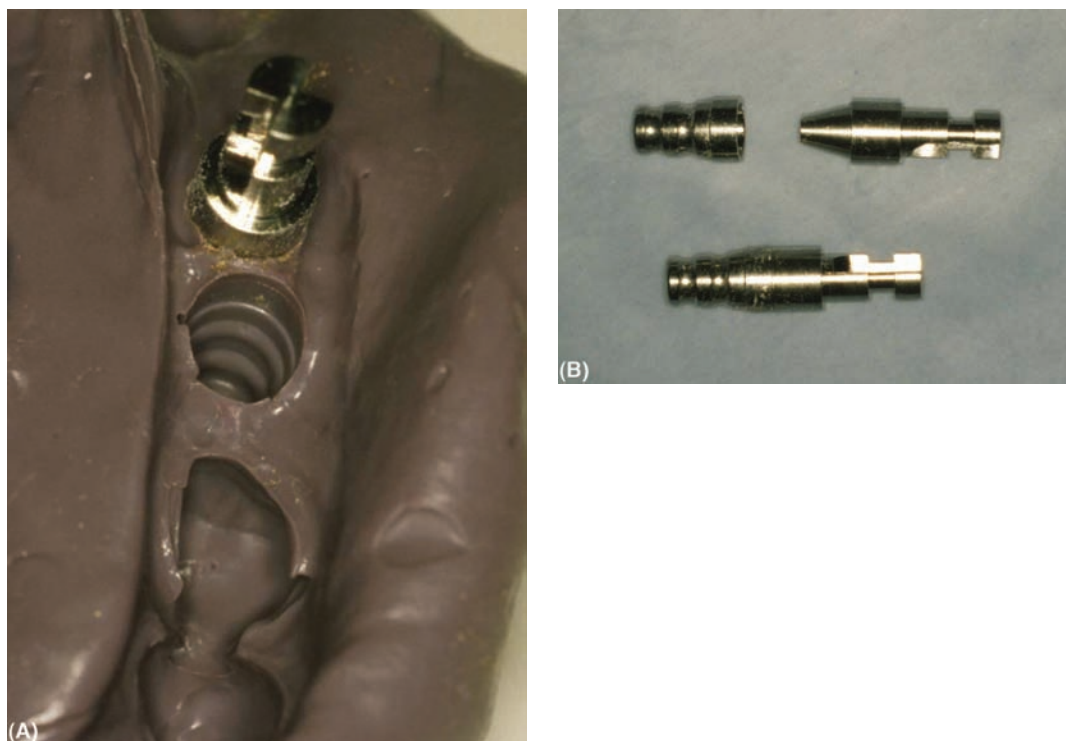
is still fluid. The tray is stabilized while full set is reached and the guide pins are then fully unscrewed. The impression copings will be removed with the tray and so remain fully seated in the impression material at all times. The guide pins are used to locate and retain the abutment analogues for cast production.

#### *Reseating Impressions (Closed Tray Technique)*

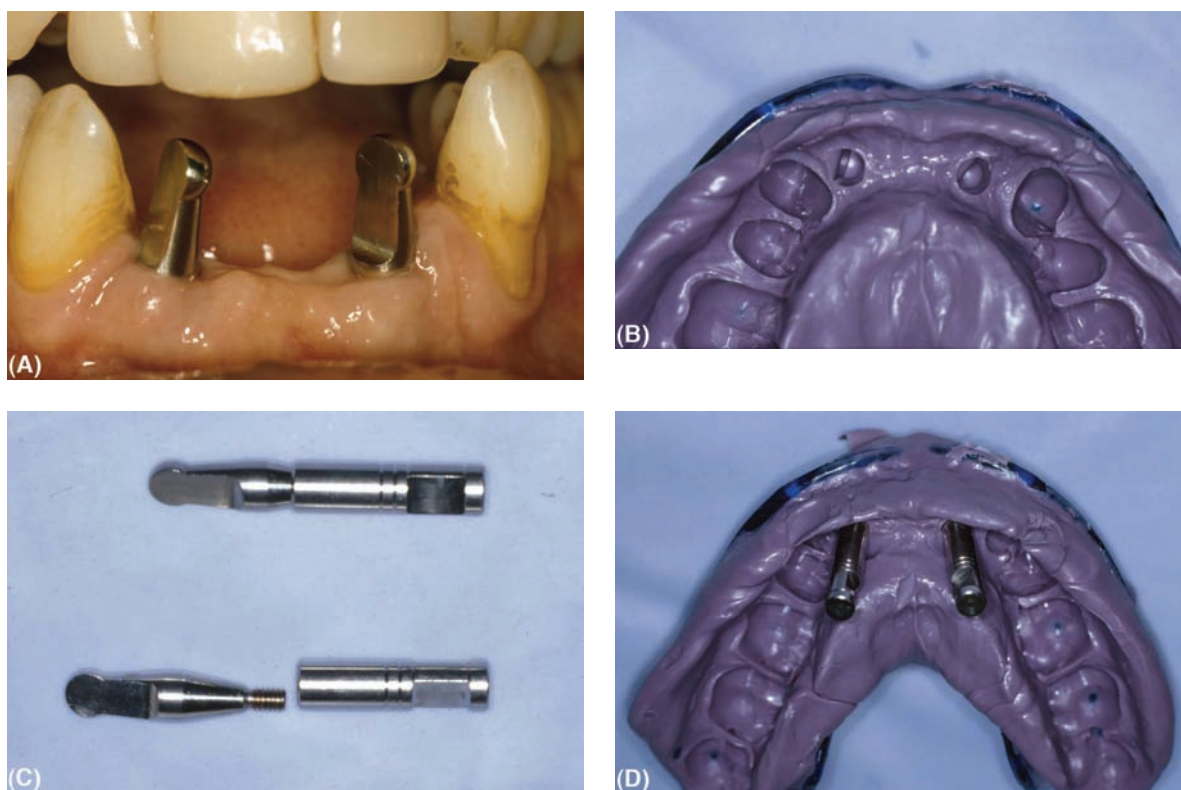
The reseating technique can be used in areas of difficult access where locating and unscrewing the guide pins with an impression tray in the mouth may be difficult. Impression copings, which have a retentive and distinctive pattern on the surface, are fully screwed onto the abutment (Figs. 14.12 and 14.13). They do not project beyond adjacent teeth and a tray should be used with stops so that it will not touch the copings when seated in the mouth. Access holes are not cut in the tray. Impression material is syringed around the coping and the tray seated. Once set, the tray is removed and an impression will have been made of the coping shape. The coping will stay in the mouth following impression removal. The coping is then unscrewed from the abutment and the abutment analogue attached for cast production. The impression coping is reseated into the impression and its stability checked. It is important that adequate material extends around the coping or it will not locate and remain stable. Despite reservations that this technique risks introducing errors, the authors have found it reliable if used correctly and checked carefully to ensure



**Figure 14.11** (A) Nobel Biocare abutment impression copings have been secured to some bridge abutments. (B) The impression copings record the position of the abutment as well as the soft tissue contours. (C) A stock tray was used, as access was straightforward. (D) Abutment replicas are secured to the impression copings prior to cast construction.



**Figure 14.12** (A) A reseating impression using Nobel Biocare bridge impression copings. The ribbed contour of the coping can be clearly seen in the impression. The distal coping and abutment replica have already been reinserted into the impression. (B) Top left the impression coping and top right the abutment analogue. When screwed together, the coping can be reseated into the impression.



**Figure 14.13** (A) Astra Tech implant head reseating impression copings in place. (B) The impression of the copings. (C) The impression coping and analogue—the impression coping has a flat facet to ensure it can be correctly reorientated in the impression. (D) The coping and analogue are together reinserted into the impression.

replica stability. It is a useful technique for patients who gag or have difficulty in accepting impressions as well as in posterior situations where access for screwdrivers is limited.

### For Cemented Restorations

Customized abutments need to be selected and produced on implant head casts and the technique already described should be followed. The customized abutments need to be retied in the mouth with the aid of a transfer jig to assist with correct orientation. If a further impression of the abutments in position is required, conventional bridge impression techniques are employed. Light-bodied materials are syringed around the abutment and a heavy-bodied material used for the bulk of the impression. Recording the fine detail of deep margins can be difficult. Gingival retraction cord does not retain well in the sulcus and care must be taken not to push it down below the bulbosity of the abutment where it may be difficult to remove. Electrosurgery is completely contraindicated. The best results are achieved by careful removal of temporary restorations and treating the soft tissue with great care so that marginal bleeding is avoided. Gingival retraction pastes can also be useful. Acrylic transfer copings can be made in advance in the laboratory at the time of abutment preparation. These can be picked up in a new impression but are only useful if the gingival margins have not needed to be altered intraorally.

#### *Impression Verification for All Techniques*

The impression is checked for

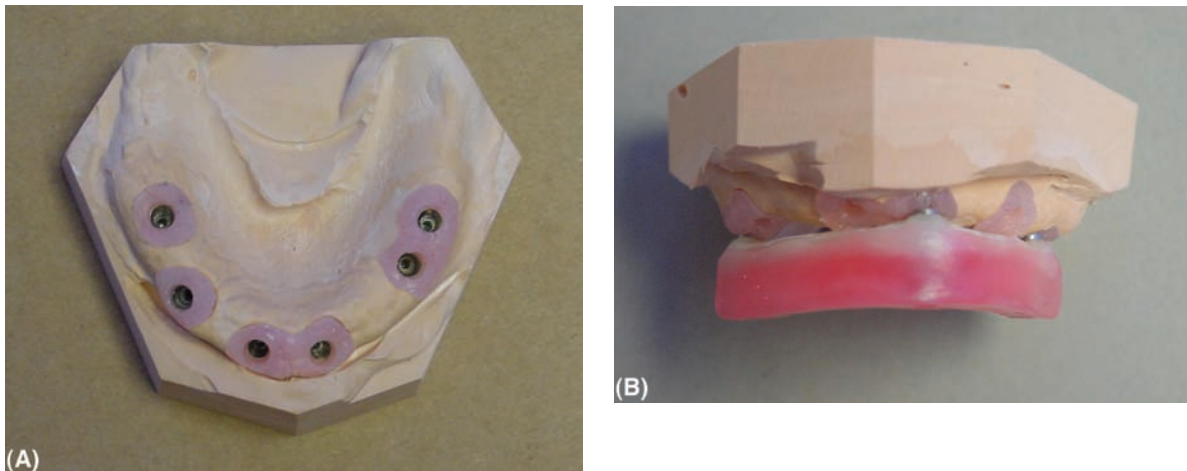
- coping stability—each coping should be tested with tweezers to ensure no more than very limited movement occurs

- adequate record of immediate gingival contours—at least 4 to 5 mm beyond the coping so that a proper gingival replica can be made
- full record of adjacent teeth—to ensure proper contact point construction and harmonious emergence profiles
- full record of articular surfaces of whole arch—to accurately articulate casts

### OCCLUSAL RECORDS

Good-quality opposing casts are essential and it is recommended that these are made using rubber base impression materials rather than alginate. As for conventional bridgework, there are no exact rules to follow; however, it is recommended that a semiadjustable articulator be used as a minimum for all full-arch bridges and shorter-span bridges where the occlusal scheme is likely to be changed by the bridge. This includes all posterior extension designs and anterior bridges where incisal guidance may be altered. If a short-span bridge is to be constructed where adjacent teeth are present and a conformative occlusal scheme is to be adopted, it may be acceptable for full articulation to be avoided. Unlike complete denture jaw relations where stability of a wax rim can be difficult, this is greatly simplified by construction of a wax rim that is secured to the implants (Fig. 14.14). The rim can then be trimmed to the correct vertical height of occlusion and an interocclusal record taken. It is also useful to mark such features as the centerline and smile line.

Full information needs to be sent to the laboratory including occlusal registration (with the abutments in position), records of provisional restorations if they need to be reproduced in the final bridgework, and shade registration. If



**Figure 14.14** Upper and lower full-arch bridges constructed on Astra Tech implants. (A) Upper cast following implant head impressions, implant analogues, and soft tissue replicas are required. (B) Linking three impression copings in a rigid laboratory composite beam, a wax rim can be constructed. (C) The wax rim is trimmed and indexed to facilitate accurate jaw relations. (D) Trimmed occlusal rims are stable in the mouth. (E) The occlusal plane is checked. (F) A facebow record can be taken. (G) A final interocclusal record is taken. (H) A full diagnostic setup of tooth position is produced, supported by the composite beams. (I) The setup is tried in. The jaw relations and appearance is assessed and altered as required. The patient can see the result and changes can be easily made at this stage. (J) Following approval of the tooth position, a putty mask is made of the try-in. (K) The putty mask records tooth position. (L) It can be located onto the working model and the correct abutment chosen to achieve the desired tooth position. (M) The chosen abutments (UniAbutments) in place. (N) The completed bridges from the fit surface. The gold bridge cylinders can be clearly seen. The underside of the bridge is carefully contoured and polished to aid cleaning. (O) Occlusal view of the bridges showing the bridge screw access holes. (P) The completed bridges. (Q) On smiling, the appearance is excellent.

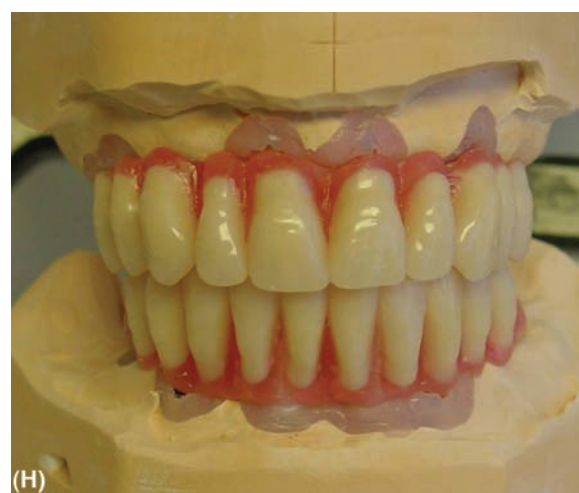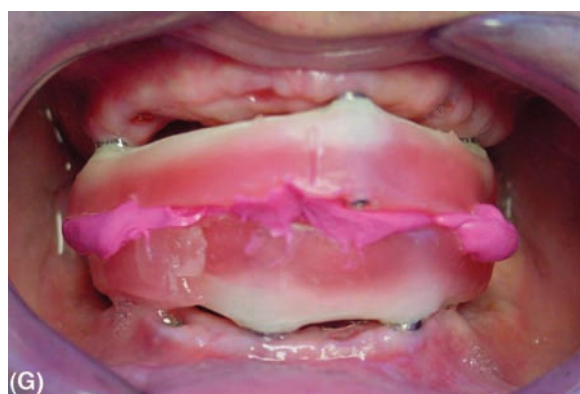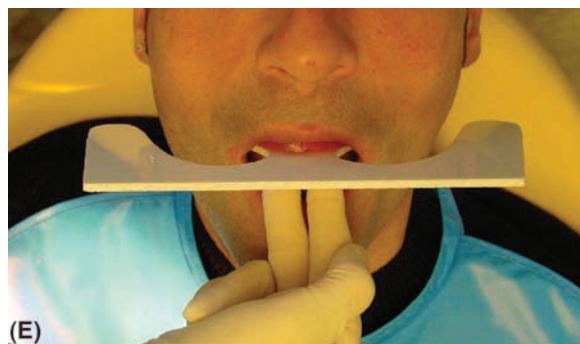


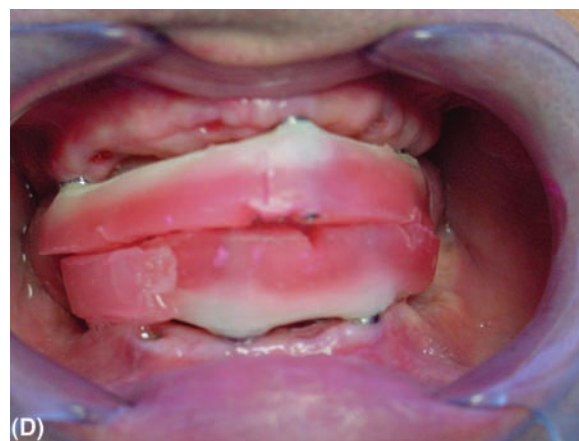Figure 14.14 (Continued)

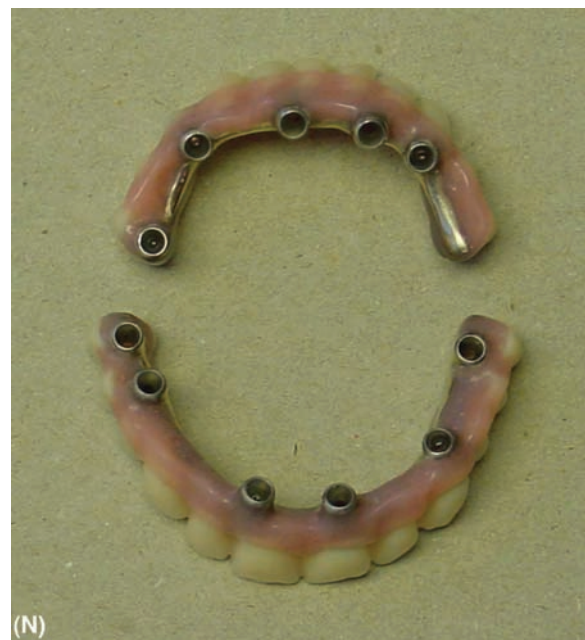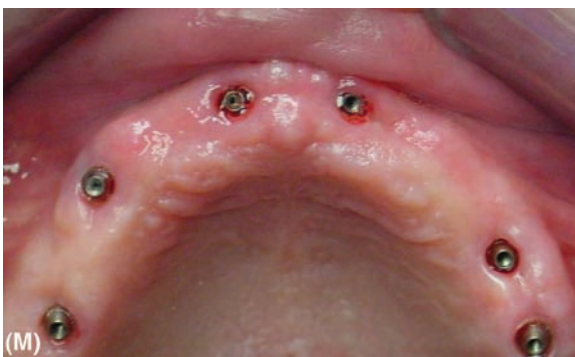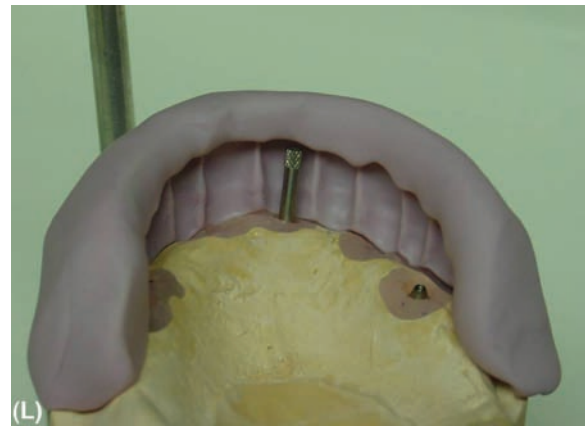


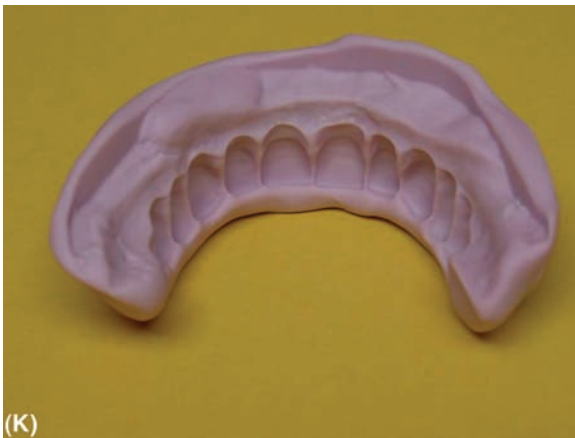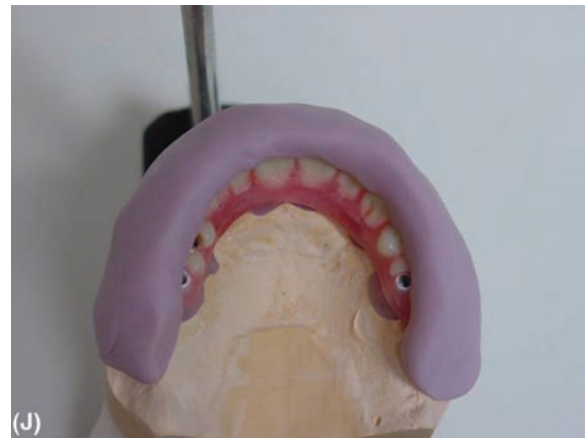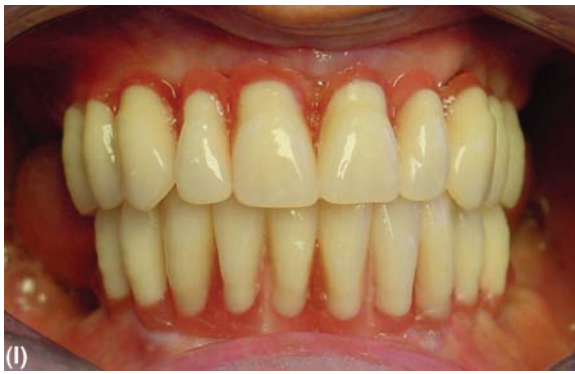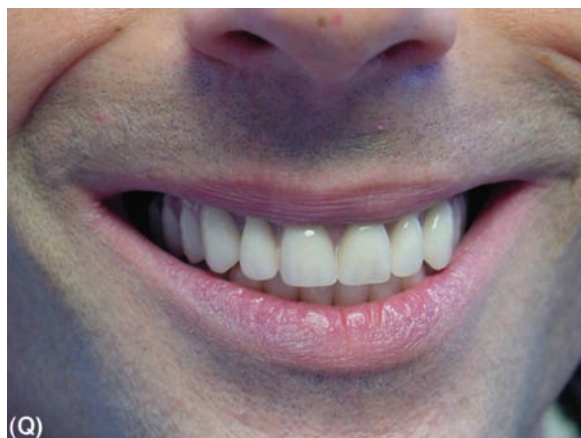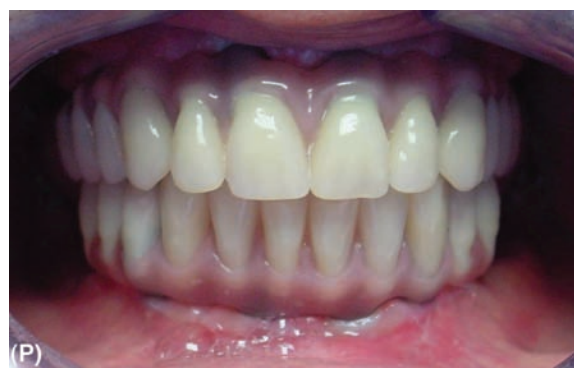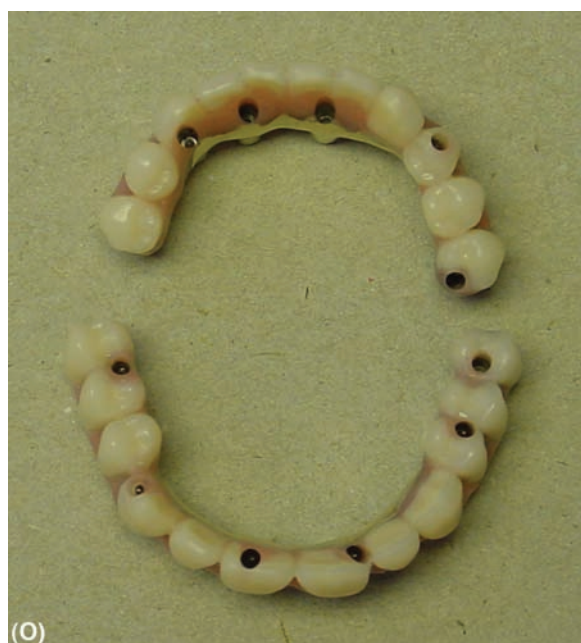Figure 14.14 (Continued)



**Figure 14.14** (Continued)

gingival colored material is to be used to mask long crowns or interdental areas, this should also be shade matched.

### PROVISIONAL BRIDGES

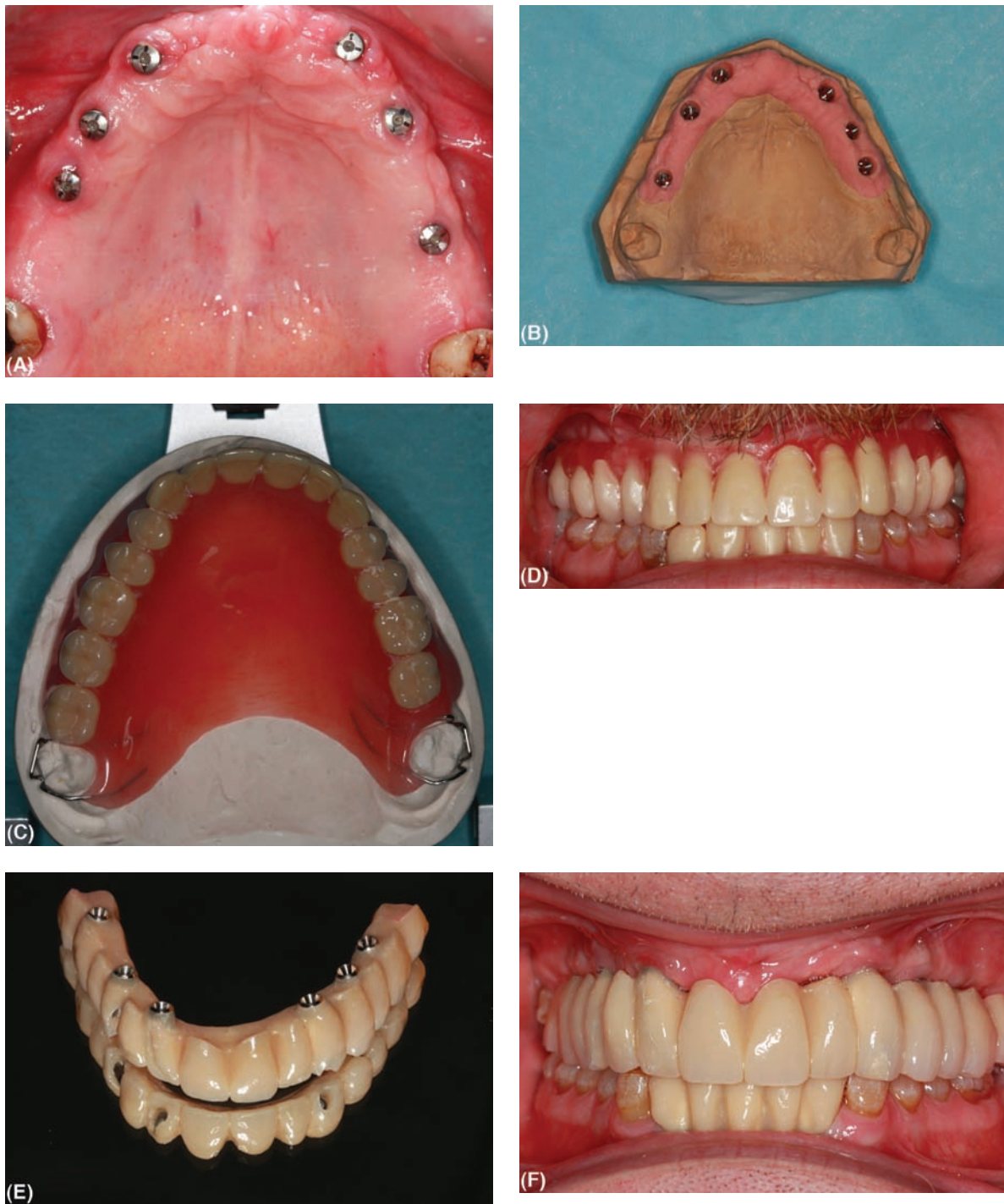The use of provisional bridges to ensure an acceptable appearance has already been discussed. Manufacturers produce temporary components that either attach directly to the implant head (provisional abutments) or can fit onto permanent abutments. These components are made of either acrylic or metal. Although a provisional bridge is not usually indicated for long periods of time, it is still essential that it has an accurate fit. A provisional structure can damage implants if it is screwed down tightly when it does not properly fit. Provisional bridges can also be used to determine tooth position and speech patterns before final bridge construction (Fig. 14.15). Patients who have worn dentures particularly for missing maxillary anterior teeth for many years may have problems adapting

their speech. Placement and subsequent adaptation and modification of a provisional bridge that can be copied in the permanent restoration smooths this process.

Following placement of the abutments, the provisional bridge is used to form the ideal gingival emergence and margin position, and if necessary the bridge can be altered to gradually change the emergence contour. Once the ideal contour has been achieved, a conventional crown and bridge impression of the abutments in position is taken and also an impression of the provisional bridge in place for the laboratory to copy.

### LABORATORY PROCEDURES

The material chosen for the bridge construction has a significant effect on the design and clinical techniques followed. Original designs favored rigid cast gold beams produced by waxing together manufactured gold cylinders supporting



**Figure 14.15** The same case as in Figure 14.9. A provisional bridge is required. (A) Healing abutments in place. (B) The master cast produced from the impression in Figure 14.14F. (C) A diagnostic try-in similar to that used for convention complete denture prosthodontics. (D) This is checked in the mouth to confirm the desired appearance, tooth position, lip support, and occlusion. (E) The try-in is converted to a screw-retained acrylic provisional bridge. (F) The provisional bridge in position. It can be used to verify that the teeth are in the correct position and that the patient is happy with the result before the permanent bridge is made. (G) The provisional bridge viewed from the occlusal surface.

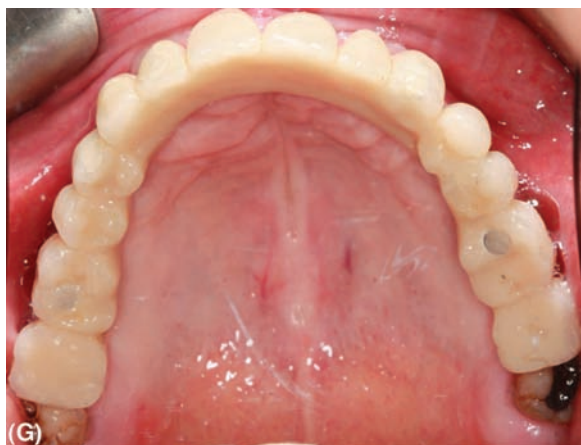

Figure 14.15 (Continued)

acrylic denture teeth embedded in pressure-cured pink denture acrylic. This had the great advantage of being a familiar technique and as the superstructures were removable, the problem of acrylic wear was not an issue as the bridge could easily be refurbished. In a desire to make restorations more aesthetic, clinicians moved toward the use of porcelain on bonding gold or titanium frameworks. When constructing large bridges, this involves a high level of technical expertise, particularly to achieve a good fit as well as a good appearance. Some clinicians prefer to undertake postceramic soldering or welding to ensure that the porcelain firing process does not distort the metal substructure. Large metal-ceramic bridges are subject to a significant incidence of long-term porcelain fractures and so are sometimes divided into smaller units and made easily retrievable where possible.

The development of laboratory composite materials has allowed the production of extensive bridges with a customized, durable, and aesthetic surface similar to porcelain, without the need for firing and possible distortion. These materials are highly suitable for implant-supported bridges, as they are more resilient than porcelain and can be more easily repaired. They are not as resistant to wear as porcelain, although evidence suggests they will wear at a rate similar to natural teeth and are particularly indicated if the opposing restoration is made of the same material. They will not retain their appearance as well as porcelain but for longer-span bridges they are clinically acceptable. Patients who are provided with extensive implant-supported fixed bridges in opposing jaws may report problems with "noise" and the very hard feeling from the porcelain surfaces contacting.

Titanium frameworks may offer considerable advantages over the use of gold from the cost and weight aspects. Titanium is difficult to cast in the conventional way, but manufacturing processes can be employed to produce machined frameworks. These are normally produced by milling a solid piece of titanium—used laser scans of wax-ups using CAD/CAM techniques (Fig. 14.16). Spark erosion techniques can also be employed. In the same way, frameworks of cobalt/chrome are also available, which are comparatively cheap and strong, but these are only used for acrylic teeth/veneers.

Titanium frameworks are also available using laser sintering or printing techniques. All of these developments are highly laboratory specific and can require considerable

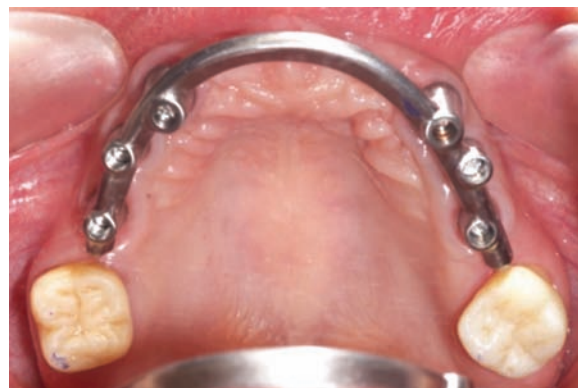

Figure 14.16 A milled titanium framework is tried in to verify the fit.

investment in technology. With the increasing cost of gold, this investment is becoming more cost-effective and the quality of fit of CAD/CAM-manufactured frameworks is excellent if the laboratory is experienced in these techniques.

The technical procedures for implant bridges are similar to conventional crown and bridge techniques, but the following features are of note:

- A soft gingival replica is essential to allow for access to subgingival implant heads and abutment margins. The gingival replica is removable to check marginal fit.
- The highest possible standard of metal framework production is required to achieve a passive fit.
- Care must be taken to ensure no distortion of the framework occurs during firing porcelain. Damage to framework fit has also been reported following acrylic polishing of full-arch bridges if handled roughly.
- Gold frameworks should be cast in a high gold content metal compatible to the gold bridge cylinders provided by the manufacturers.
- The importance of relating the implant position to the desired tooth position before choosing the abutment has

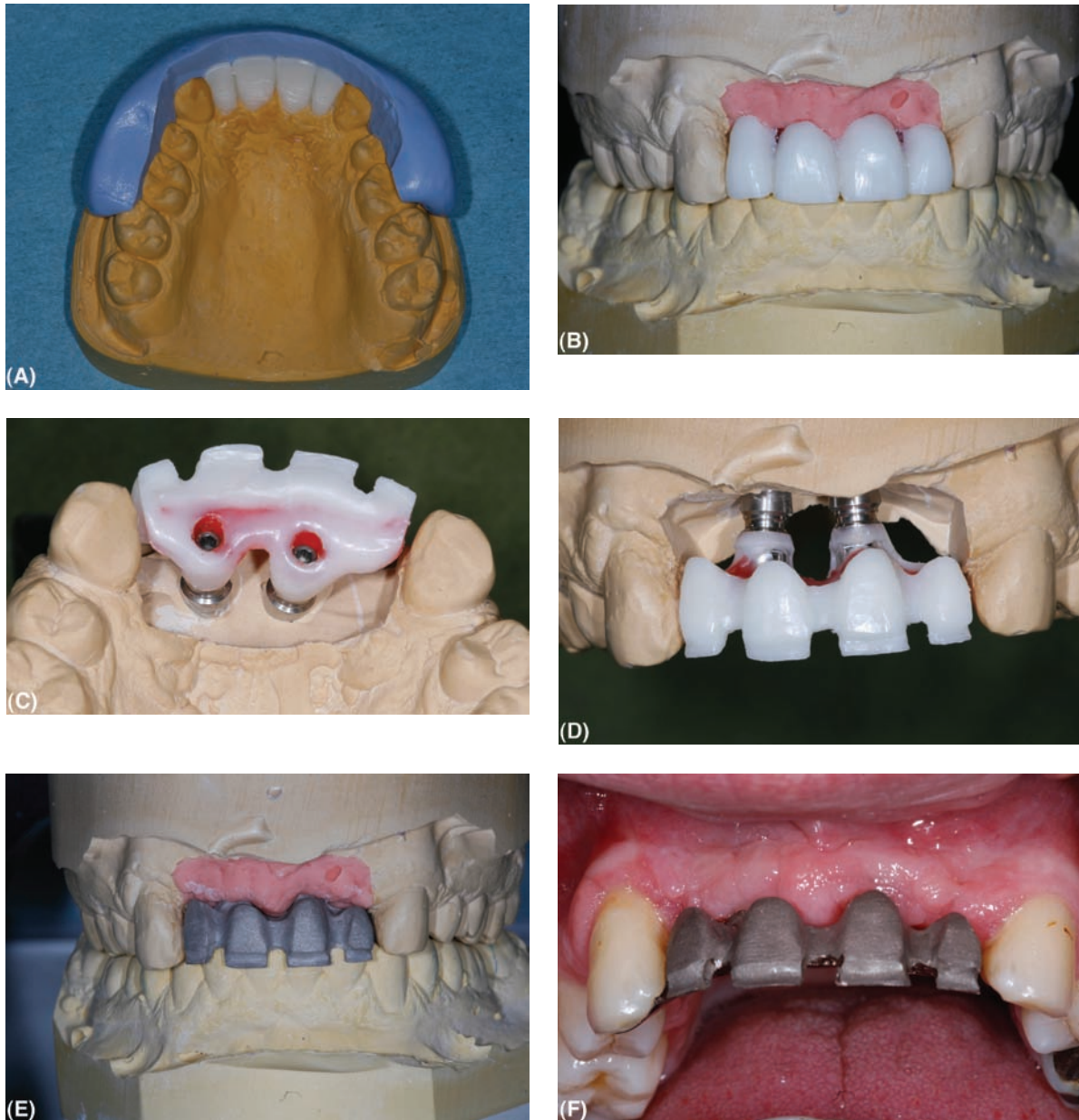
already been discussed. Of equal importance in the laboratory is the relationship of the abutment to the final tooth position so that the framework is the correct contour to support the aesthetic portion of the bridge and the correct occlusal form. Many dental technicians prefer to fully wax-up the whole bridge and then cut the wax-up back to allow space for the porcelain or resin to ensure this contour (Fig. 14.17).

## MATERIALS

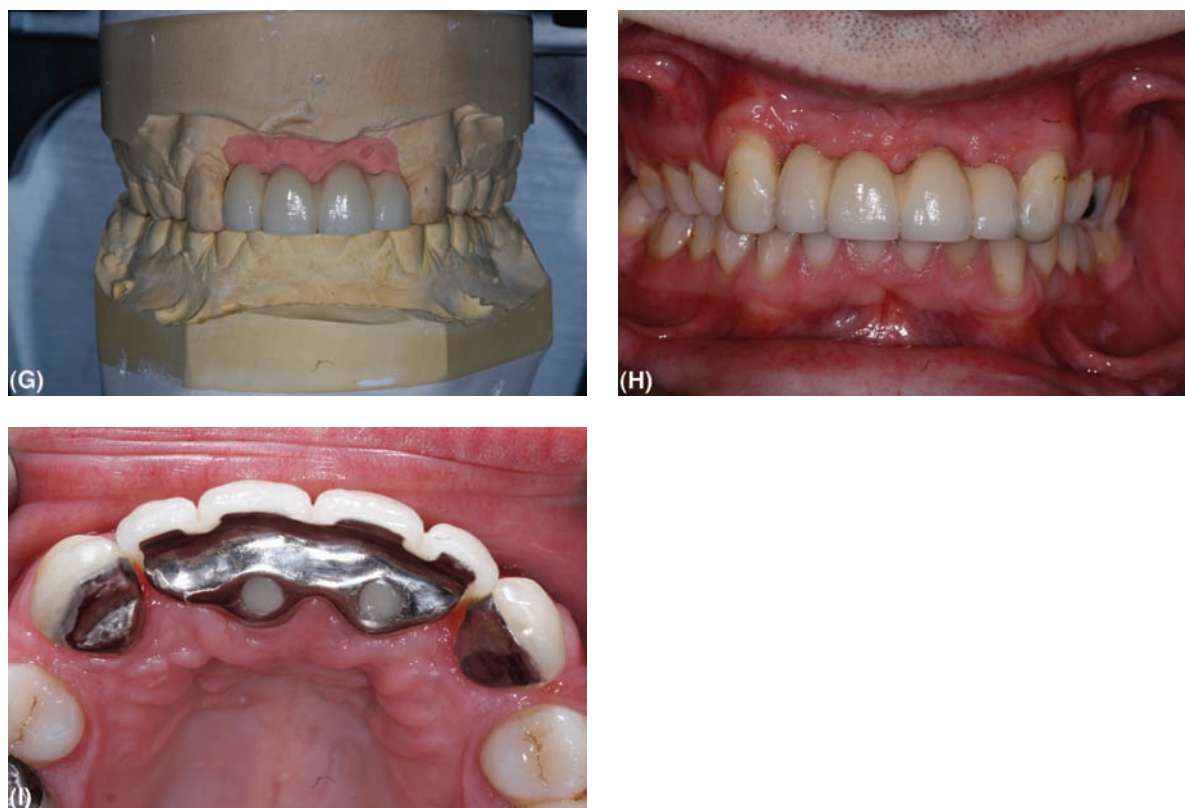### Gold

#### Advantages

- Conventional laboratory techniques and high quality fit with experienced laboratories
- Compatible with porcelain, acrylic, and composite veneering techniques



**Figure 14.17** Two implants have been placed for a bridge to replace the four incisor teeth: (A) A diagnostic wax-up of the bridge has a putty matrix of the labial surfaces made. (B) The diagnostic wax-up is contoured to the ideal tooth position. If required, this could be tried into the patient's mouth to confirm it is correct before making the bridge. (C) The wax-up is cut back to create the ideal metal framework to support the porcelain. Note the two cylinders over the abutments incorporated in the wax-up. The putty matrix is used to ensure the correct space has been achieved. (D) The same wax-up from the labial aspect. (E) The casting on the master cast. (F) The casting is tried in prior to porcelain placement to verify the fit. (G) The completed bridge on the cast. (H) Completed bridge. (I) Completed bridge from the occlusal surface. The retaining screw holes have been covered with a tooth-colored restoration.



**Figure 14.17** (Continued)

- Easy to solder and laser weld
- Use of readymade gold cylinders ensures a good fit to abutments

#### *Disadvantages*

- Higher material cost
- Exacting laboratory technique

### **Titanium**

#### *Advantages*

- Lower material cost
- Light and strong
- Compatible with acrylic and composite veneering techniques but require more complex laboratory facilities for porcelain
- Excellent fit from experienced laboratories

#### *Disadvantages*

- Requires specialized laboratory facilities
- Different porcelains and techniques required for metal/ceramic constructions

### **Porcelain**

#### *Advantages*

- Highly aesthetic and customizable
- Durable

#### *Disadvantages*

- Possibility of framework distortion on large structures
- Difficult to repair
- High incidence of fractures with long-term use

### **Acrylic**

#### *Advantages*

- Good aesthetics if plenty of space available for teeth
- Easy to replace missing gingival tissue
- Easy to repair
- Light and minimal wear to opposing dentition

#### *Disadvantages*

- Wear may be excessive
- Stains
- Acrylic teeth can debond from the framework

## Composite

### Advantages

- Customization more like porcelain
- Easy to repair

### Disadvantages

- Chips and wears
- Not as translucent as porcelain

## TRYING AND FITTING THE RESTORATION

### Try-in

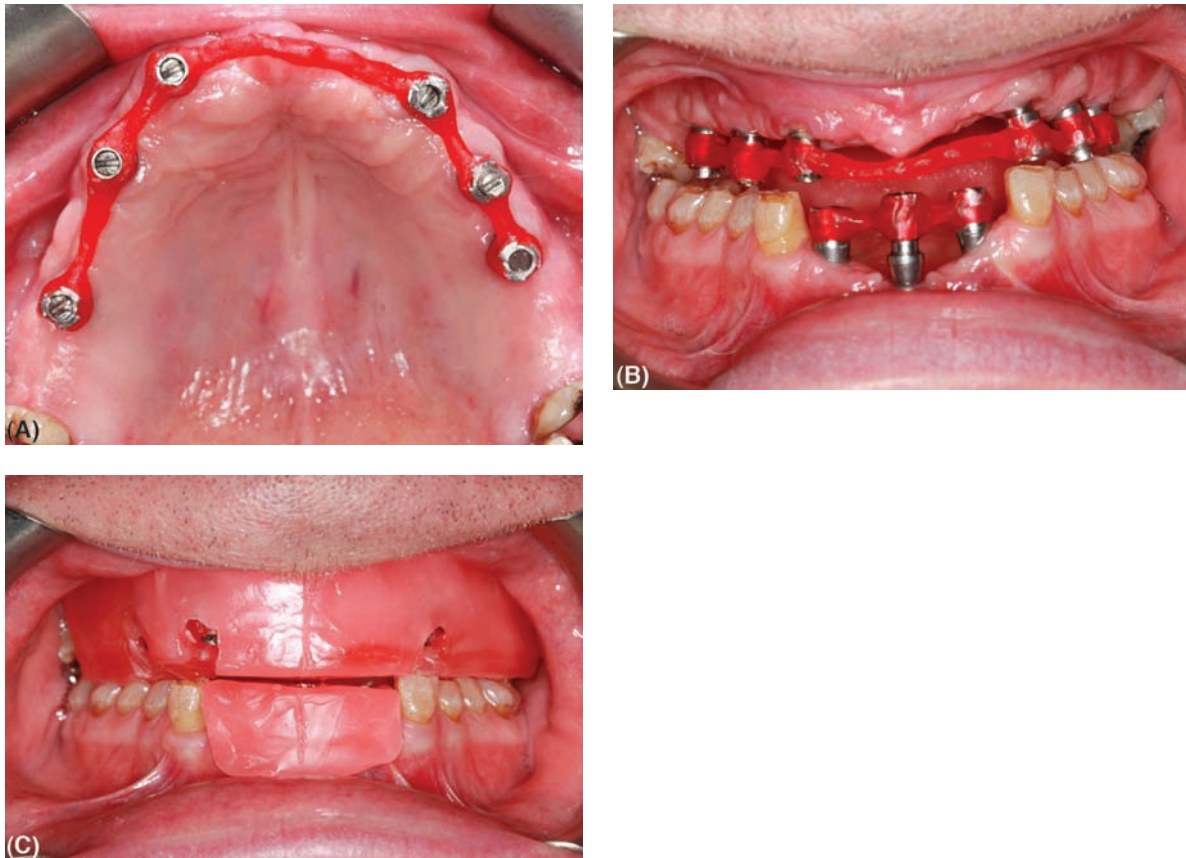
Larger-span or short-span bridges should normally be tried in before fit. Try-in can be carried out at the following times:

- Before framework construction. The gold cylinders are linked together with a rigid material such as laboratory composite resin (Fig. 14.18). The accuracy of the impression can be verified by seating this in the mouth. There should be no displacement of the frame when screwed down at either end and the resin connection will normally crack if the structure is tried in and there is a poor fit. If this occurs, it is best to retake the impression. The linked gold cylinders can be used for occlusal records by attaching a wax rim and they can also support a trial setup of teeth if required.

- Following framework construction, but before placement of the veneering material of teeth. Try-in at this time will allow for full evaluation of the fit of the frame and detection of errors before time is wasted completing a bridge that does not fit. The frame is first seated down with finger pressure and any gross error in fit detected by rocking of the framework. The bridge screws are then tried in one at a time to see if tightening a screw results in movement of the frame away from another abutment. Tight gingival cuffs or a framework pressing on soft tissues can make this difficult. Finally, all the screws are tightened and a misfit may be revealed as discomfort and a tight feeling by the patient. An error in fit detected at this stage is either remedied by retaking the impression or by sectioning the frame and splinting it in the mouth for it to be soldered or welded. A frame that has to be sectioned should always be tried in again before proceeding further.
- Finally, a bridge can be tried in prior to polishing or at a biscuit bake if porcelain. This will allow for checks to be made on appearance and the occlusion prior to completion.

### Placing the Bridge

If the definitive abutments have been removed between appointments, they should be seated and tightened as recommended normally using a torque device. The bridge is seated



**Figure 14.18** (A) An acrylic linkage (in Duralay) is tried in to verify the position of the implants and the master cast. (B) Upper and lower linkages tried in. (C) Wax occlusal rims locate over the linkage to give a stable base for recording occlusal records.

onto the abutments and the fit verified as already discussed. There is little point in trying to verify marginal fit visually unless the margins are supra gingival. It is quite normal for there to be some gingival blanching because of pressure on the soft tissues from the new profile of the bridge. Patients should be reassured that this is a temporary problem. If the fit is acceptable, the occlusion is checked.

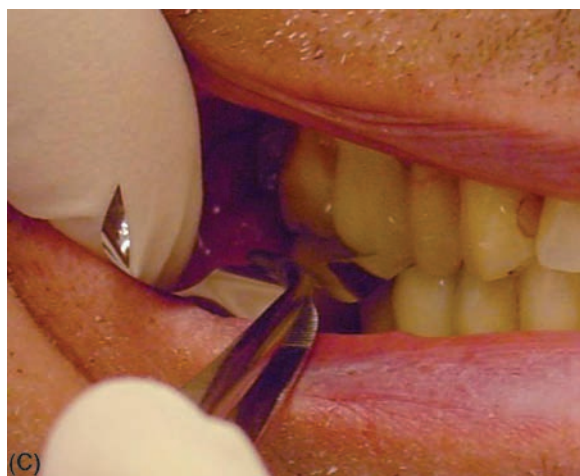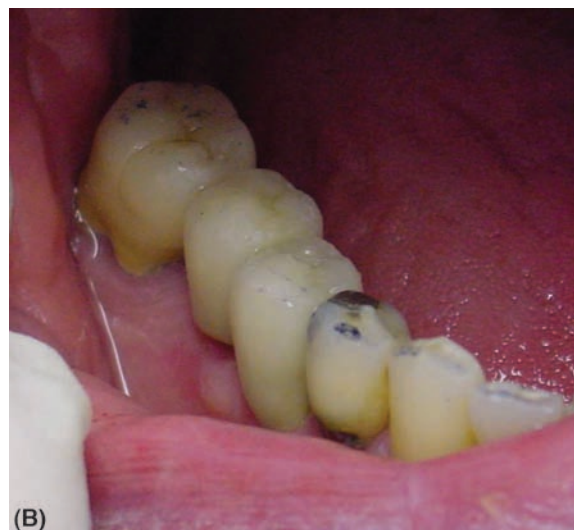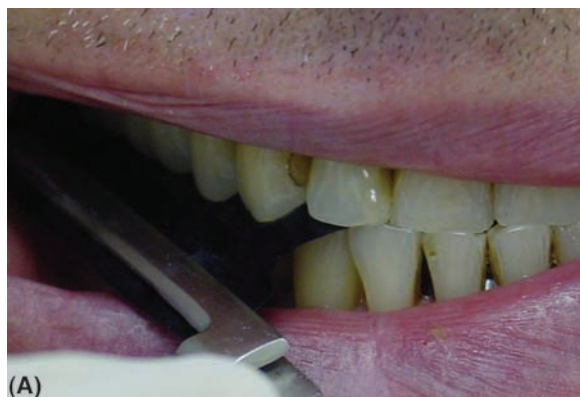### Occlusion

If the bridge is being placed as a conformative restoration (in a partially dentate patient), it should be checked first in the retruded arc of closure to ensure it does not create an occlusal interference. Next the intercuspical position should be checked. Ideally the bridge should be only just in contact when the patient closes lightly and should come fully into contact when the patient exerts heavy force. This will obviously depend on how many natural teeth remain and how good their occlusal contacts are. It can be difficult to properly organize the occlusion if the remaining teeth have any significant degree of mobility. This degree of contact is difficult to quantify, but the best way of proceeding is to first use occlusal indicator paper to get even

contact between teeth and implants (Fig. 14.19). Shim stock should then be used, and on light contact, the implant bridge should not hold the shim stock but the teeth should. As the patient exerts more force so the implant bridge should hold the shim stock as well as the teeth. Ideally the areas of contact should be located as close to the center of the implants as possible so forces are transmitted down the long axis of the implant under loading. Cantilever pontics should be loaded as little as possible.

The bridge is then checked in lateral and protrusive movements. If a natural canine guidance is present, this will protect the bridge from lateral loading. If a group function occlusion exists, the implant bridge should be harmonious with this. If the canine tooth is being replaced as part of the bridge, it is normal practice for the occlusion to be reorganized as a group function occlusion if this can be achieved without sacrificing appearance. If lateral guidance has to be provided, this should be shallow, shared over several teeth if possible, and be centered on the strongest implant.

Protrusive guidance should have been determined prior to construction, as anterior tooth position will dramatically



**Figure 14.19** The occlusion is checked on a lower implant-supported bridge. (A) Articulating paper is used to mark initial contacts under light pressure. (B) The heaviest marks are present on the natural teeth and the implant bridge (the second and third from the back) are only lightly touching. (C) Shim stock is used to confirm that the implant restorations are in contact under loading.

alter this. The protrusive movement should be smooth and spread over as many teeth as possible, once again ideally centered over the implants rather than on pontics.

If a reorganized occlusal scheme were to be adopted, as for example a full-arch bridge, this would follow normal crown and bridge and complete denture prosthodontics without the need for a balanced occlusion. The intercusp occlusion should be provided at the ideal vertical dimension in the retruded arc of closure (retruded contact position), there should be an even and flat forward movement of 1 to 2 mm, the lateral movement should be a group function with multiple contacts and the protrusive movement shallow and even.

### Bridge Screw Tightening

With short-span bridges, the screws can be hand tightened (normally about 10 Ncm of torque). Large implant-supported bridges should be progressively seated to assist with complete seating and prevent overtorquing the bridge screws. The screws in the center should be hand tightened first, moving distally and alternating from side to side. When the bridge is first placed, the screw access holes should be sealed with some cotton wool and temporary filling material. There is a significant incidence of early screw loosening particularly with long bridges. The bridge should therefore be checked after one to two weeks and the bridge screws checked for tightness. Movement of a screw by 90° or less is considered acceptable. Any screws more loose than this must be checked a further one to two weeks later. It is unusual for a screw not to retain its tightness for the second time, and if this occurs, it should be checked carefully as it may indicate a poor fit for the framework or that the bridge is being overloaded.

Once the screws have remained tight and the patient has approved all aspects of the bridge, the screw access holes can be permanently sealed. To allow access in the future without possible damage to the screw heads, they should be covered first with a layer of cotton wool to prevent the screw heads getting blocked with hard material. The occlusal portion of the screw access hole is best restored with a color-matched opaque light-cured composite resin filling material and the occlusion rechecked afterward.

### Bridge Cementation

On completion of a cemented bridge, a decision needs to be made regarding the type of cementation required. With multiple parallel abutments, the restoration does not require a hard (permanent) cement as this will make the bridge difficult to seat fully and will make it impossible to retrieve in the future. Implant bridges can therefore be "permanently" cemented with provisional cements as long as they demonstrate good retention and stability at the try-in.

When the bridge is first completed, it is prudent to provisionally cement it to allow the patient to "live with" the bridge for a short while and check on contour, appearance, and speech before final cementation. Weakened or modified temporary cement is all that will be required. Provisional seating also allows the gingiva to adapt to the new contour and will make final cementation an easier technique, as the bridge will not be prevented from seating by a tight gingival collar.

Prior to final cementation, the abutment screws are checked for tightness and the screw access holes covered with cotton wool. The chosen cement is mixed and placed in the bridge, only a thin layer will be necessary and the excess cement should be kept to a minimum to ease its removal. If hard cement such as zinc phosphate has been chosen, this

should not be mixed as a viscous material or the bridge will not fully seat. The margins must be very carefully checked to ensure complete excess cement removal. The occlusion must be rechecked following cementation.

On completion, long-cone periapical radiographs should be taken for all implants to confirm seating and act as a future guide for marginal bone levels (Fig. 14.20). If a cemented bridge has been placed, excess cement should also be checked for.

### Instructions to the Patient

The patient is given specific hygiene instruction, in particular how to access the areas between implants. They should be warned to be careful with the new bridge during function, as they are more likely to bite their inner cheek, lips, or tongue as they get used to having a fixed structure rather than a denture. Patients who have worn a denture long term prior to implant treatment experience more problems at the start and these are best discussed before problems arise to prevent the patient from becoming dissatisfied.

In particular, speech may be affected when restoring the upper anterior teeth. The perception of speech change is often more apparent to the patient than to anyone else and usually returns to normal after one to two weeks. Longer accommodation times are however sometimes needed.

### Follow-up

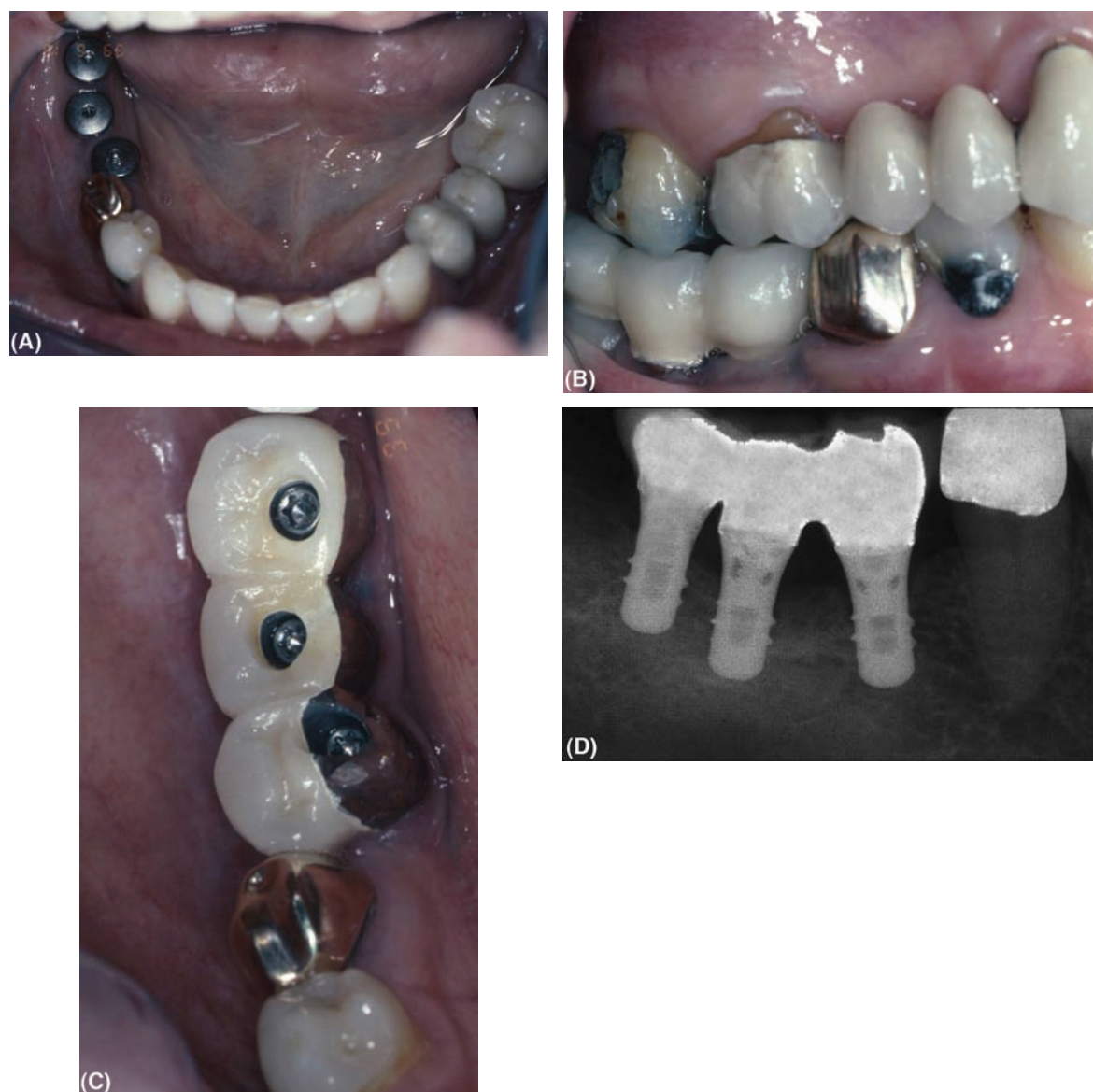Following final completion of the new restoration it is wise to arrange for a review, particularly to check home maintenance, within six months. The marginal bone levels should be checked for stability with new long-cone periapical radiographs after one year and approximately every two years following that.

## ADDITIONAL CONSIDERATIONS

### Joining Teeth and Implants

Ideally, implants should not be linked to natural teeth because of differential mobility. In particular, it is not advisable for a tooth to be linked into a bridge that is supported by several implants. In this situation, the bridge will be purely supported by the implants and the tooth will be superfluous. With time, the tooth may unseat from the bridge and intrude into the alveolus. If design or other factors dictate retention of a tooth, it is advisable that the tooth be protected by a gold coping so that movement of the tooth from the bridge will not result in an unprotected tooth becoming carious.

Success in linking teeth and implants can be achieved if a single sound and nonmobile tooth is linked to a single implant (Fig. 14.21). Although there is still the differential in properties between the two abutments, clinical trials have shown acceptable levels of success with no increased bone loss or technical complications. Once again, it is advisable for the tooth to be protected with a subbridge gold coping that should be cemented with hard cement and the bridge with a weaker material. In the event of bridge cementation failure, the tooth will not be exposed to the potential of caries at the failed margin. Such linked bridges are useful if there is only enough bone volumes for one implant to be placed but the patient requires the provision of two extra teeth. Linking the implant to the adjacent tooth will allow for either a single-unit cantilever bridge or a fixed-fixed design with a tooth and implant separated by a single missing unit. Provision of a joint as in conventional bridgework is not advised, as the joint will still allow the tooth to intrude from the bridge.



**Figure 14.20** A posterior bridge supported by Straumann implants: (A) Three healing abutments are visible. (B) The completed bridge. (C) Occlusal view—screw retention has been used. (D) A periapical radiograph taken at the end of treatment.

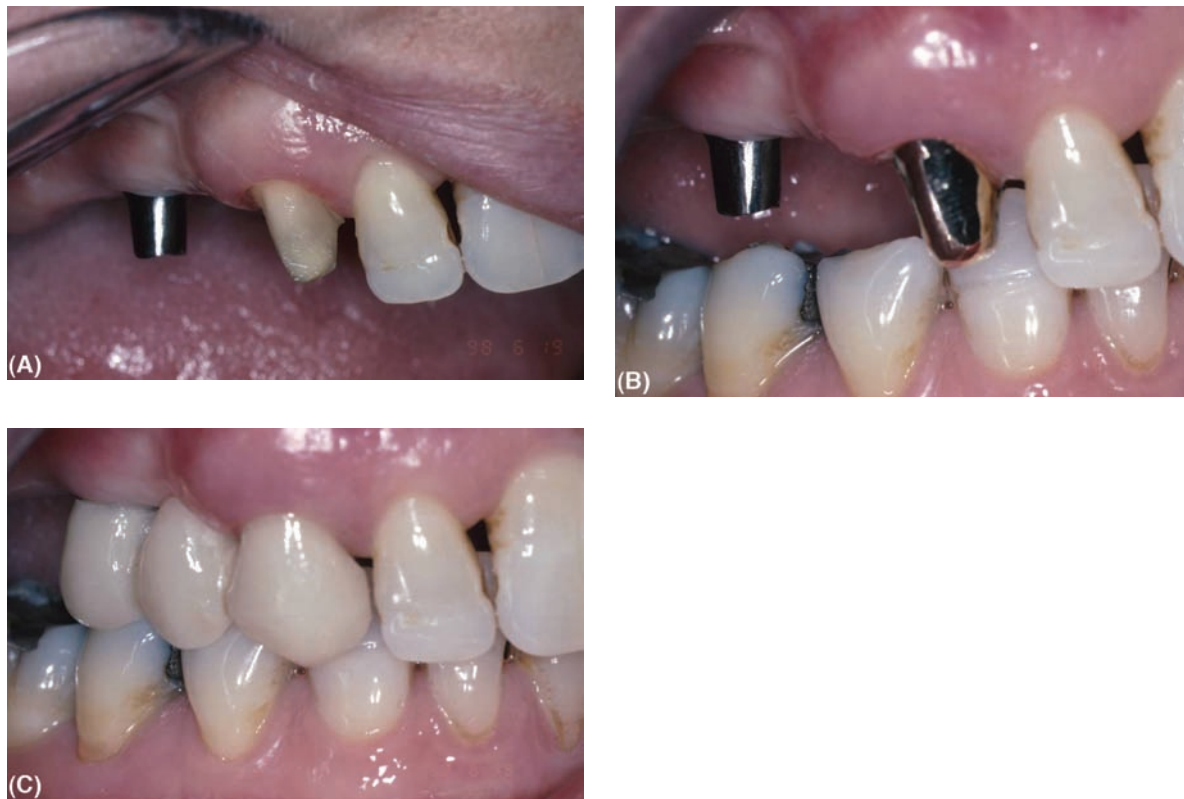### Immediate Bridges

The immediate restoration of multiple implants has become a more common clinical technique and may have much to recommend it as the implants can be immediately splinted and their loading more reliably controlled. Several manufacturer-led techniques are available and these can be categorized as follows:

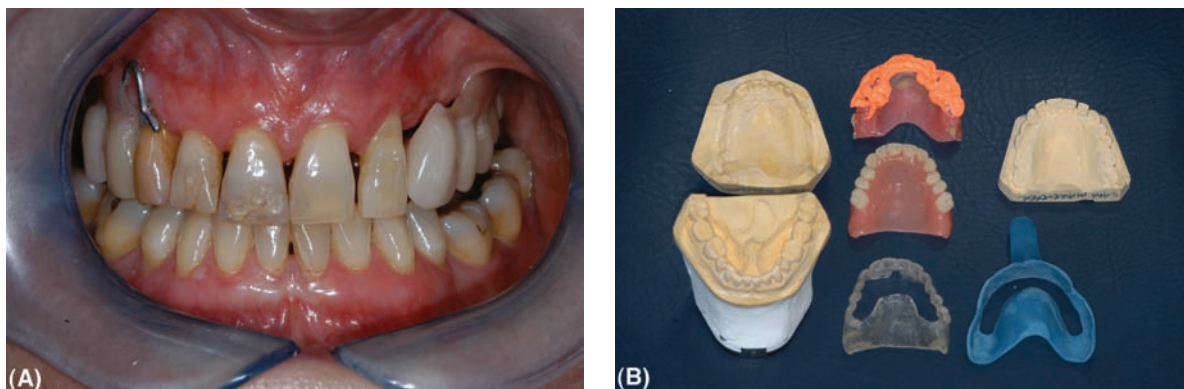
- a. A bridge (normally provisional) is constructed prior to surgery from radiographic scans and diagnostic workups. A surgical guide is also constructed from the same information so that the implants will be placed in a predefined position. If this works exactly, then the premade bridge should fit.

- b. On placing the implants, an impression is made and a bridge constructed quickly. To facilitate this and to speed up the process as much of the provisional bridge as possible is made in advance and this is located to the final implant position on the laboratory cast.

A case is outlined in Figure 14.22. Such cases require the clinician and laboratory to work very closely together prior to the surgery and on the day of surgery to make the bridge as speedily as possible. Ideally, the bridge should be fitted on the day of surgery so the patient does not have to go without teeth.



**Figure 14.21** A three-unit bridge supported by a natural tooth and an Astra Tech ST implant. (A) A Profile BI abutment (preparable) has been placed and the natural tooth prepared. (B) The tooth is protected with a gold coping. (C) The cemented bridge at completion.



**Figure 14.22** An immediate bridge is to be provided on the same day as extracting the remaining teeth and placing the implants. (A) At the start of treatment, the patient has five remaining anterior teeth 13,12,11,21,22, which have extensive bone loss. The patient has a posterior temporary acrylic denture that they cannot tolerate so an immediate bridge is indicated on loss of the teeth as the patient could not wear a complete denture. (B) Prior to the day of surgery, standard prosthodontic techniques have been followed to construct an immediate replacement complete upper denture along with a special tray for implant impressions and a surgical guide (based on the tooth position from the denture). (C) The teeth have been extracted and eight implants placed according to the surgical guide. The anterior implants are into the extraction sockets and the posterior implants into healed bone. (D) The eight Astra Tech implants prior to soft tissue suturing. (E) Standard bridge abutments placed for screw retention. (F) Impression copings attached. (G) The impression with abutment replicas attached. This will be immediately cast in the laboratory. (H) Abutment protective healing caps are placed of varying size. (I) The premade denture is seated into place and located over the healing caps with silicone occlusal registration material. (J) The inner aspect of the denture showing the clear record of the healing caps that allow the denture to be accurately located on the master model in the laboratory. (K) Temporary titanium cylinders are used in the laboratory incorporated into the bridge fitting on to the abutments. (L) The completed temporary bridge consisting of the tooth part of the immediate denture supported on the temporary cylinders and linked by acrylic. (M) The temporary bridge viewed from the occlusal aspect. As the anterior implants were placed in the extraction sockets, the access holes for the bridge are close to the tips of the teeth. This can be remedied during construction of the permanent bridge after healing. (N) The temporary bridge placed approximately four hours after the surgery. Resorbable sutures are visible. (O) The temporary bridge about four weeks later showing good healing.

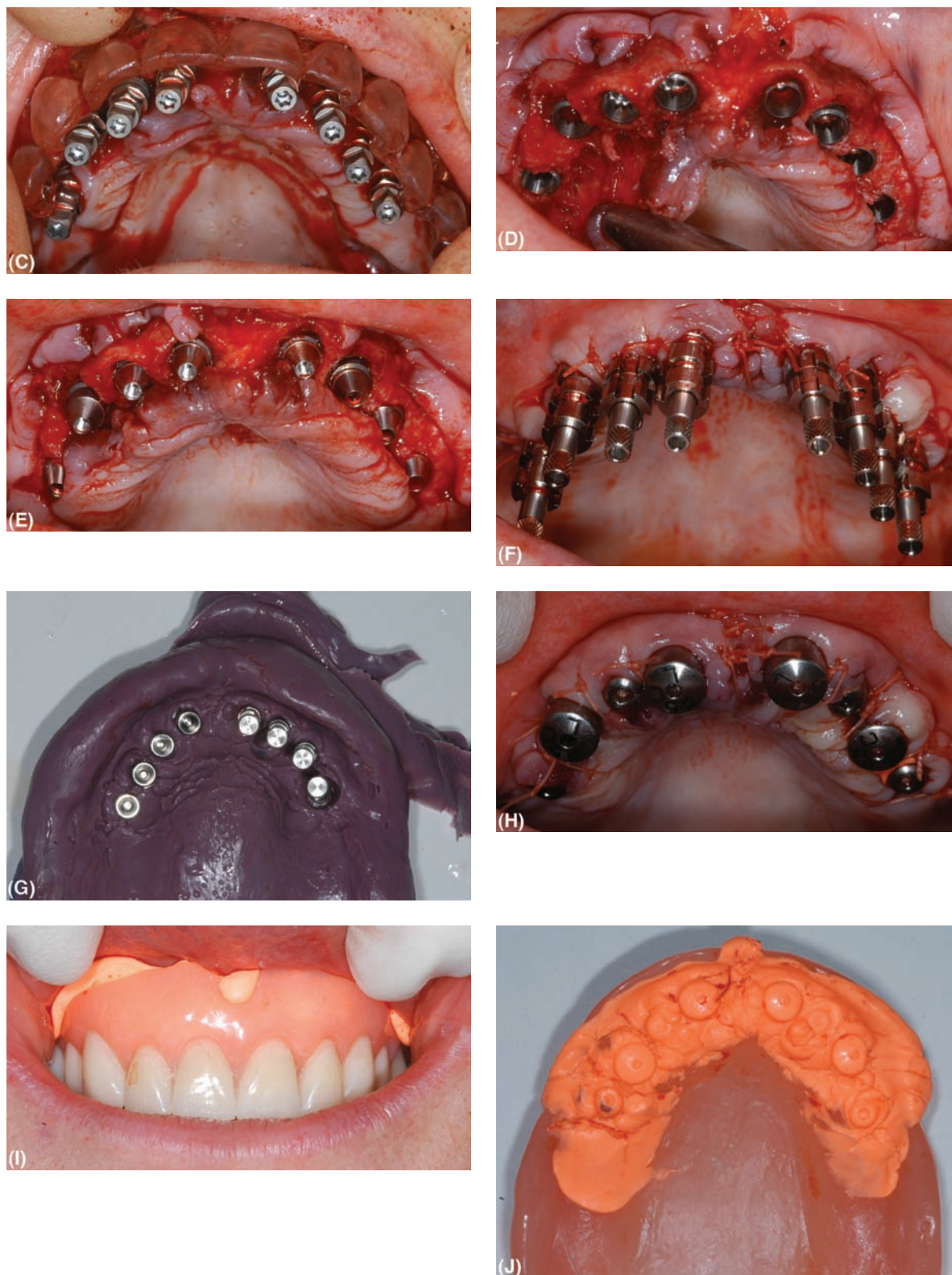
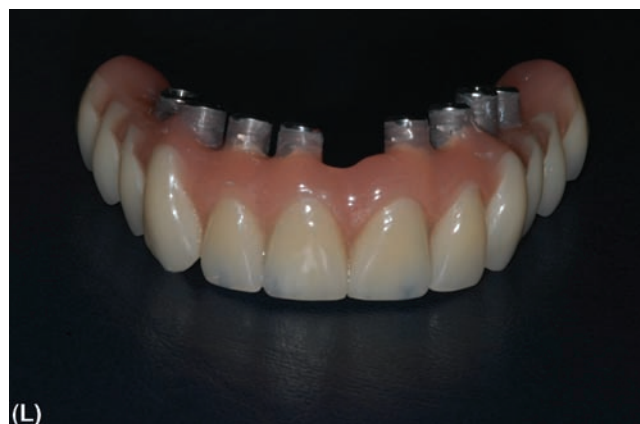

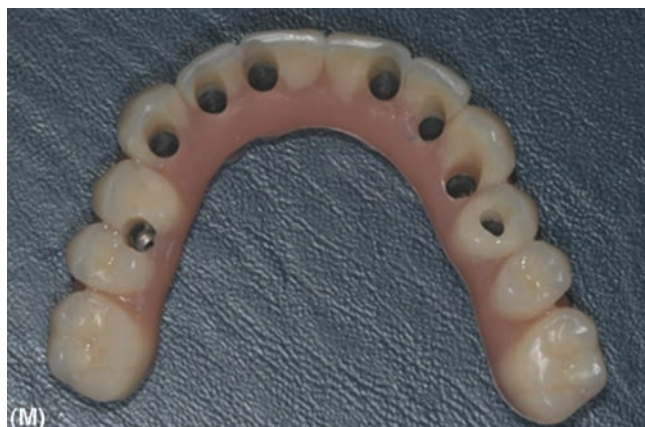Figure 14.22 (Continued)



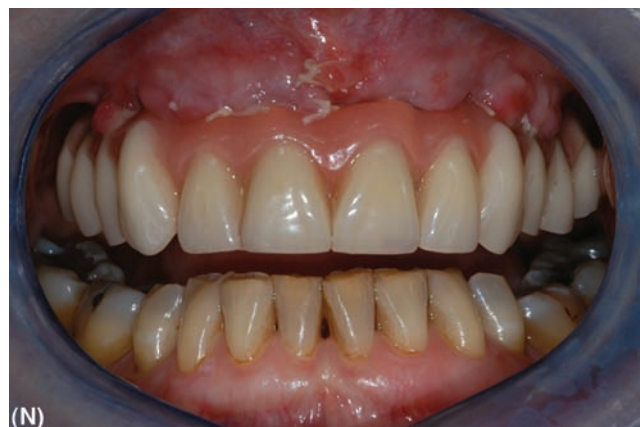(K)



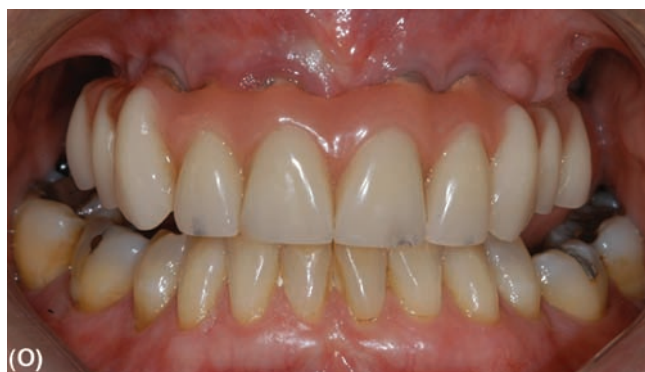(L)



(M)



(N)



(O)

**Figure 14.22** (Continued)

## BIBLIOGRAPHY

- Arvidson K, Bystedt H, Frykholm A, et al. Five year prospective follow up report of the AstraTech implant system in the treatment of edentulous mandibles. *Clin Oral Implants Res* 1998; 9:225-234.
- Cameron SM, Joyce A, Brosseau JS. Radiographic verification of implant abutment seating. *J Prosthet Dent* 1998; 79:298-303.
- Eliasson A, Wennerberg A, Örtorp A, et al. The precision of fit of milled titanium implant frameworks (I-Bridge) in the edentulous jaw. *Clin Implant Dent Relat Res* 2010; 12:81-90.
- Hobkirk JA, Psarros KJ. The influence of occlusal surface material on peak masticatory forces using osseointegrated implant supported prostheses. *Int J Oral Maxillofac Implants* 1992; 7:345-352.
- Jemt T. Three dimensional distortion of gold alloy castings and welded titanium frameworks. Measurements of the precision of fit between completed implant prostheses and the master casts in routine edentulous situations. *J Oral Rehab* 1995; 22:557-564.
- Jemt T, Book K. Prosthesis misfit and marginal bone loss in edentulous implant patients. *Int J Oral Maxillofac Implants* 1996; 11:620-625.
- Jemt T, Lekholm U. Oral implant treatment in posterior partially edentulous jaws: a five-year, follow-up report. *Int J Oral Maxillofac Implants* 1993; 8:635-640.
- Lundgren D, Laurell L. Occlusal aspects of fixed bridgework supported by endosseous implants. In: Lang NP, Karring T, eds. *Proceedings of the 1st European Workshop on Periodontology*. London: Quintessence Publishing, 1994:326-344.
- McAlarney ME, Stavropoulos DN. Determination of cantilever length to anterior-posterior spread ratio assuming failure criteria to be the compromise of the prosthesis retaining screw-prosthesis joint. *Int J Oral Maxillofac Implants* 1996; 11:331-339.
- Olsson M, Gunne J, Astrand P, et al. Bridges supported by free standing implants versus bridges supported by tooth and implant: a five year prospective study. *Clin Oral Implants Res* 1995; 6: 114-121.
- Örtorp A, Jemt T, Back T, et al. Comparisons of precision of fit between cast and CNC-milled titanium implant frameworks for the edentulous mandible. *Int J Prosthodont* 2003; 16:194-200.
- Sailer I, Philipp A, Zembic A, et al. A systematic review of the performance of ceramic and metal implant abutments supporting fixed implant reconstructions. *Clin Oral Implants Res* 2009; 20(suppl 4):4-31.
- Schlumberger T, Bowley JF, Maze GI. Intrusion phenomena in combination tooth implant restorations: a review of the literature. *J Prosthet Dent* 1998; 80:190-203.

## Implant overdentures

This chapter will describe the clinical procedures specific to the construction of implant overdentures. It is assumed that the reader will have a basic understanding of the principles and procedures used in the construction of conventional complete dentures, and this will not be elaborated on. For a more detailed description of generic procedures, the reader is referred to textbooks covering complete denture prosthodontics.

Manufacturers are constantly developing their products, and this new edition covers some of the more recent products and newer techniques.

### SELECTION OF ABUTMENTS

When a two-stage submerged procedure has been carried out, the patient should be seen about four weeks after second-stage surgery for selection of abutments and primary impressions. When a one-stage procedure has been carried out, this prosthodontic stage would normally be carried out approximately three months after implant placement.

The healing abutments are removed and the distance from the top of the implant to the mucosal surface can be measured with either a depth gauge or a periodontal probe (Fig. 15.1). The abutment gingival height selection is based on a measurement using the abutment depth gauge. The height of the soft tissue should be at or just below the tapered neck of the ball abutment. The aim is to achieve the lowest possible profile when selecting a transmucosal abutment for a bar, Locator<sup>®</sup> abutment, or a ball abutment (Figs. 15.2–15.7) so that the prosthodontic components are within the intended contour of the denture. A general idea of what is required should be apparent from the treatment planning and stent construction. However, it is necessary to make the final selection after the mucosa has healed and matured.

Most manufacturers supply a range of abutments in lengths up to 8 mm. The Straumann tissue level implant has the transmucosal element already incorporated into the implant so no choice is possible at this stage; the decision has already been made at the time of placing the implant. There is only one size of ball attachment, which has a 2.25 mm diameter. The original Nobel Biocare standard abutment for bars (Fig. 15.5) and the large ball attachment (Fig. 15.2) had a minimum sleeve length of 3 mm, so there was a potential shortage of space with superficially placed implants; however, this large ball attachment has been discontinued. The Nobel Biocare 2.25-mm ball attachment has a minimum abutment sleeve length of 1 mm (Fig. 15.3). The Nobel Biocare fixture-head gold coping, which fits directly onto the implant, can be reduced in height to allow the construction of a bar very close to the mucosa. The Astra Tech uniAbutments for bars range from 0 mm to 8 mm (Fig. 15.8) and the ball abutments have a similar range. The range of components is described in detail in chapter 6.

### RECORDING PRIMARY IMPRESSIONS

Once the measurements for the planned abutments have been made, the healing abutments should be replaced and primary impressions made. The purpose of these impressions, usually made with alginate impression material, is to produce casts on which custom trays can be made.

A suitable stock impression tray is selected that will allow a minimum of 3 mm even thickness of alginate material and that extends to cover the major landmark areas. In the mandible, these are the buccal, labial and lingual sulci, the retromolar pads, and the retromylohyoid fossae. In the maxilla, these are the buccal and labial sulci, the hamular notches, and the palate. The imprints of the healing abutments are required for the custom tray design.

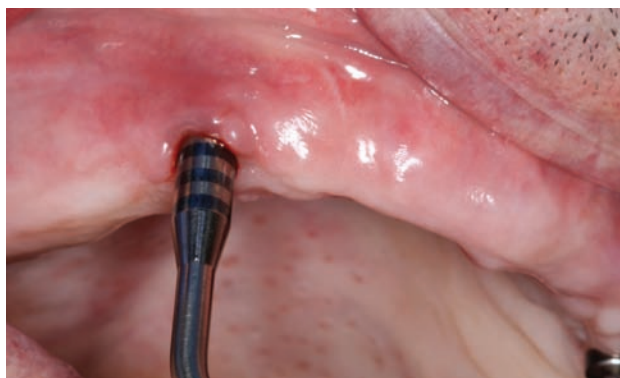The container of alginate impression material should be shaken to homogenize the powder particles. Water and powder are dispensed using the manufacturer's measures, warmer water can be used to accelerate the setting time for patients who have a strong gag reflex. The tray should be loaded, bearing in mind the desired thickness of the final impression. Once a satisfactory impression has been made (Figs. 15.9 and 15.10), it should be rinsed, disinfected, wrapped in damp gauze or tissue, and placed in an airtight box. A polythene box is ideal as it prevents the impression drying out and is rigid to prevent the impression being crushed during transportation to the dental laboratory. Alginate impressions should be poured up as soon as possible.

### CUSTOM TRAY CONSTRUCTION AND FINAL IMPRESSIONS

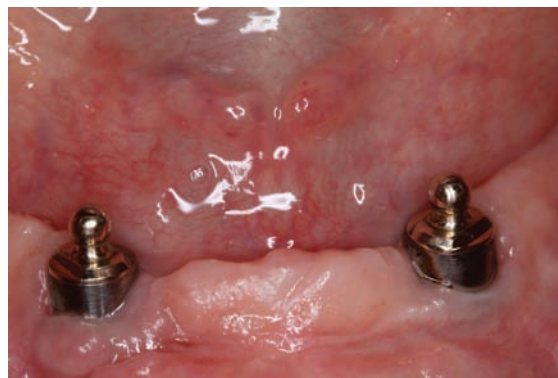A custom tray is made on the primary cast from acrylic resin tray material or light-cured tray material. We favor the use of a polyether impression material for the final impressions because it is sufficiently rigid to hold the various impression copings that will be used during the impression procedure. This material requires a 1.25-mm spacer, so a single sheet of baseplate wax is placed on the primary cast to the desired outline and areas are cut out for the tray stops (Fig. 15.11). Extra wax is placed around the abutments to ensure adequate clearance. In the open tray technique, the custom tray is constructed with windows over the abutments and tray material brought vertically to enclose the impression copings (Fig. 15.12).

The custom tray should be trimmed to be 1 to 2 mm short of the functional sulci and modified with impression compound to record the functional sulcus.

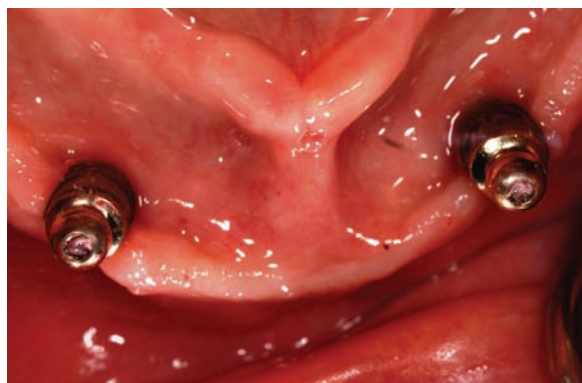The various manufacturers' implant systems have similar principles involved in making the final impressions for implant dentures. The original standard method for bar-retained implant dentures involves the attachment of irregularly shaped impression copings by long pins to the selected abutments that have been attached to the implants. The custom



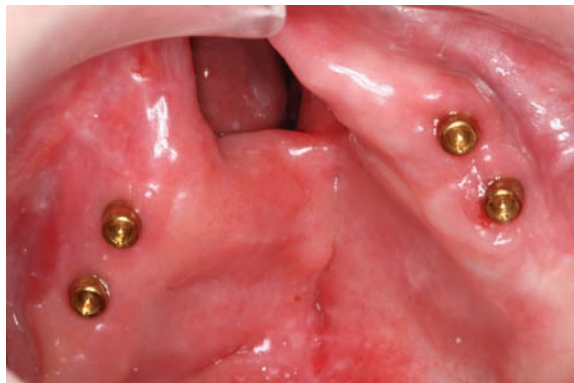**Figure 15.1** Measuring gingival height. The healing abutment has been removed and a depth gauge is used to measure the distance from the top of the implant to the mucosa.



**Figure 15.3** Nobel Biocare 2.25 ball abutment with a sleeve length to give the lowest profile. The abutment driver engages the flat surfaces on the collar of the abutment.



**Figure 15.2** Nobel Biocare standard ball abutment with a sleeve length to give the lowest profile possible. The ball component contains an internal hexagon, covered here with debris, into which the screwdriver is inserted.



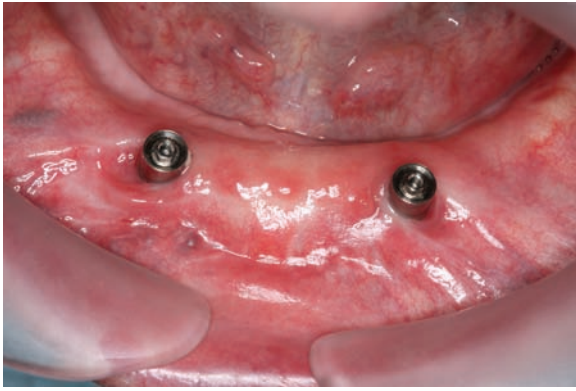**Figure 15.4** Locator® abutment placed so that the retentive collar is wholly above the mucosa.

tray has a window through which the pins protrude when the impression is made. Once the material has set, the pins are loosened and the impression is removed from the mouth with the impression copings now firmly held in the impression (Figs. 15.13 and 15.14). After disinfection, laboratory replicas of the abutments are attached to the impression copings via the long pins prior to boxing the impression and pouring the cast. In the standard method, the position of the abutment is recorded via the coping rather than an impression being made of it. This is also the same procedure when a CAD/CAM milled bar is to be used.

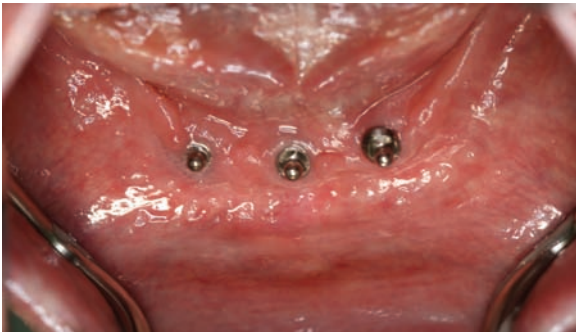
In the ball attachment systems, the abutment screw has a ball head and this is screwed into the implant with the appropriate screwdriver. The ball abutments have drivers that enclose

the ball and engage suitable flats on the collar (Fig. 15.15). The Locator abutment has a specific tool for insertion (Fig. 15.16). The final impression is made of the attachments and laboratory replicas of them are placed in the impression prior to pouring the cast. The Astra Tech ball attachment system has plastic impression copings that are placed over the ball (Fig. 15.17) prior to the impression and that remain in the impression when it is removed from the mouth.

Once the final impressions have been made, the bar abutments, ball attachments, or Locator abutments can be left in place on the implants but protection caps are essential for the bar abutments to prevent food debris and calculus from entering the screw hole for the gold cylinders (Fig. 15.18). The base of any denture that is being worn will, of course, need to



**Figure 15.5** Nobel Biocare standard abutment into which the cast bar is screwed.



**Figure 15.6** Straumann ball abutments placed at the lowest profile possible. This is dependent on the level at which the implant has been placed, the transmucosal component cannot be changed.

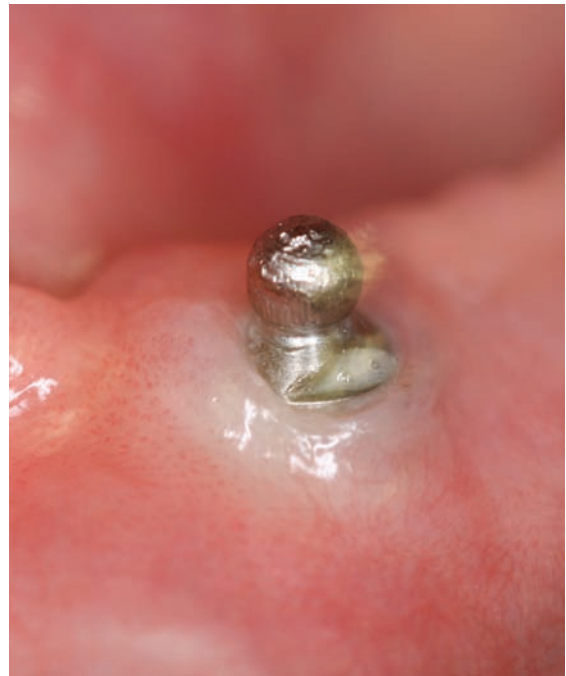be adjusted to accommodate the abutments and protection caps (Fig. 15.19). The abutments or ball attachments can be removed and the healing abutments replaced until the next stage. In this case, the base does not need to be modified. Alternatively, the female components of the ball or Locator abutment could be processed into the previous denture in the interim.

### VERIFICATION OF FINAL CAST

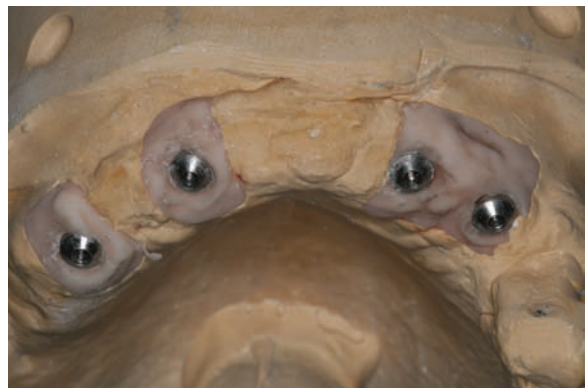It can be helpful to verify the accuracy of the final cast, especially for multiple implants intended for use as bar-retained dentures, to avoid discovering errors late on in the treatment (Fig. 15.20). This can be done by linking impression copings with composite resin in exactly the same way as for extensive fixed restorations (see chap. 14).

### RECORDING THE MAXILLOMANDIBULAR RELATIONSHIP

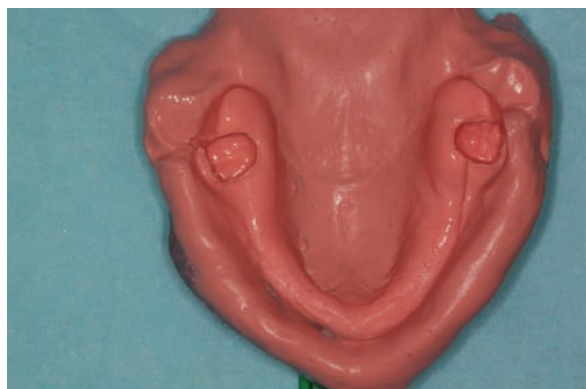
For the construction of implant dentures, just as with conventional complete dentures, the spatial relationship between the maxilla and the mandible is recorded by the use of occlusion rims on temporary or processed bases. The rims are shaped to



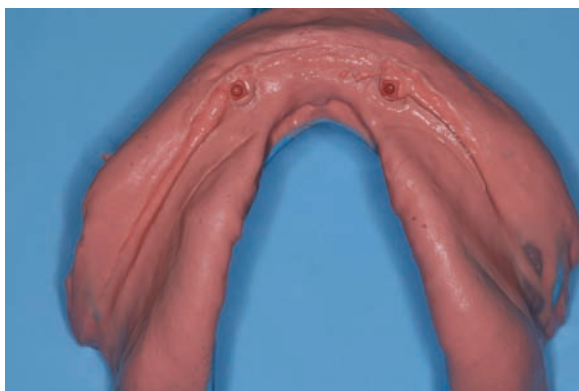
**Figure 15.7** Astra Tech ball abutment placed at the lowest profile possible, this abutment shows signs of wear and tear.



**Figure 15.8** Astra Tech 20° uniAbutment replicas. Placed at the appropriate cuff height to ensure a low profile for the bar.



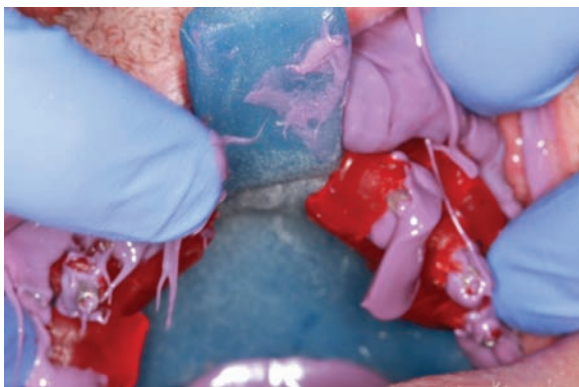
**Figure 15.9** Maxillary alginate impression in alginate.



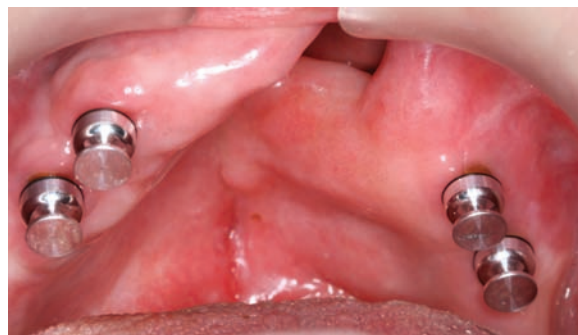**Figure 15.10** Mandibular primary impression in silicon putty with an alginate wash. The major landmarks are recorded and there is an imprint of the Straumann ball abutments in place.



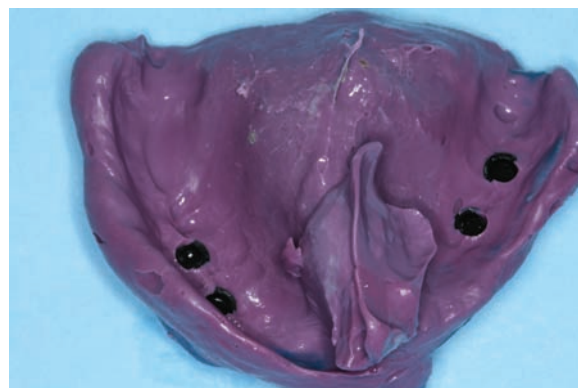**Figure 15.11** Mandibular acrylic custom-made tray. The tray has been constructed with occlusal stops on the teeth and space around the locator. A closed tray technique is used to make the impression.



**Figure 15.12** Maxillary open tray technique. The custom-made tray has windows cut into it to allow the impression coping to poke through. Once the impression material has set, the copings are unscrewed from the implants and are securely held in the impression material.



**Figure 15.13** Locator impression coping on abutment. These impression coping snap onto the abutment, impression material is syringed around the coping and a closed tray impression technique is used. A firm sharp pull once the material has set will dislodge the coping, again these copings are firmly held in the impression material.



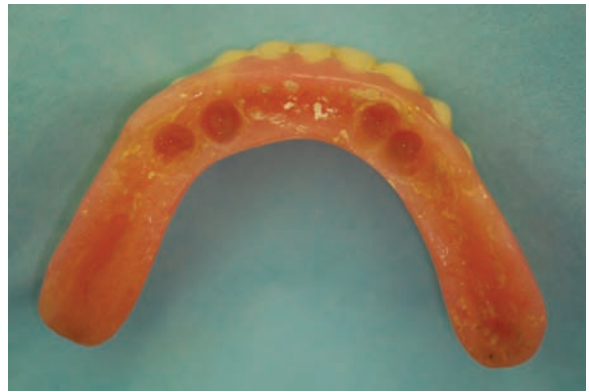**Figure 15.14** Impression with coping in situ. A suitably rigid impression material is needed to ensure the copings held in the impression material do not dislodge or move.




**Figure 15.15** Astra ball abutment driver. This is used to insert the abutment into the implant. The drive is attached to a torque wrench and the ball abutment is torqued to 20 or 25 Ncm according to manufacturer's guidance.



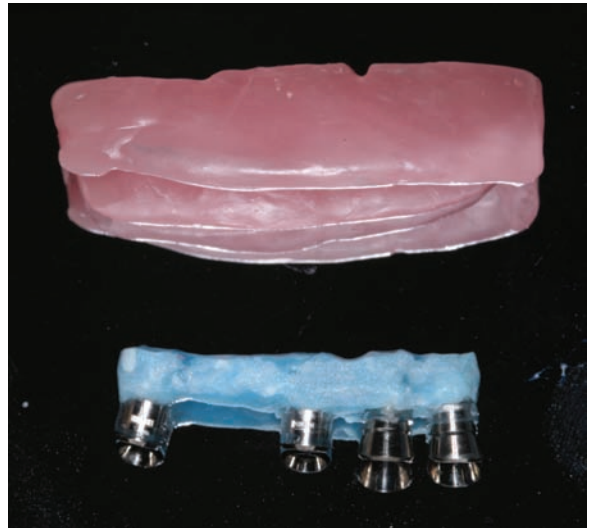**Figure 15.16** Locator core tool. The Locator abutment is inserted with the core tool (*right*) to finger tightness and then torqued down using the locator bit (*left*) in a torque wrench.



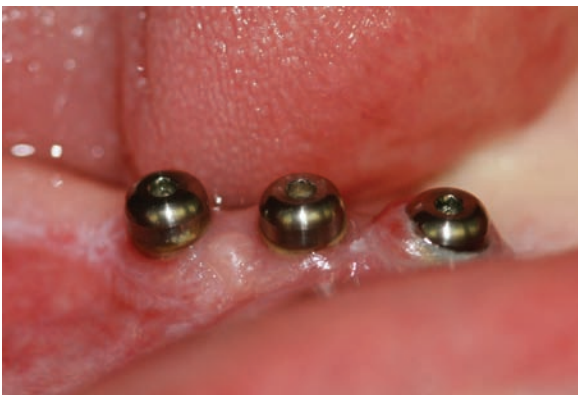**Figure 15.19** Denture modifications. The patient's current denture will require modifications to allow for the newly inserted abutments.



**Figure 15.17** Astra ball impression coping. These blue plastic coping are snapped onto the ball abutments prior to making an impression.



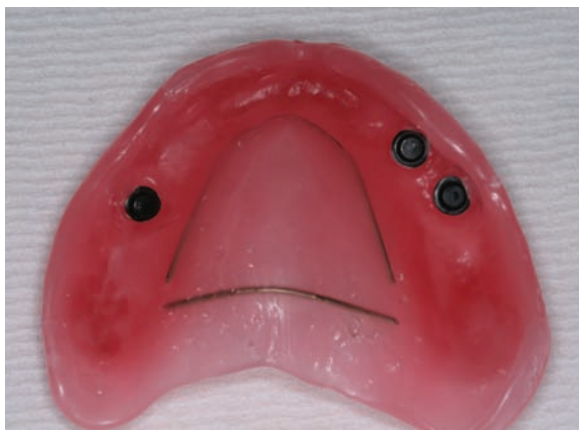**Figure 15.20** Impression verification stent. This is used to verify the accuracy of the impression taken. The stent is made up of the impression copings splinted together by a composite material. The stent should screw into place without the composite bar breaking.



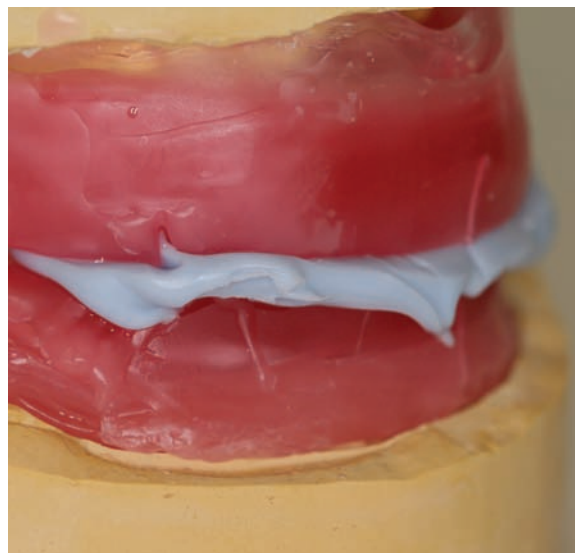
**Figure 15.18** Astra Tech proheal caps. These caps protect the uniAbutments.

prescribe the intended position of the anterior teeth and the occlusal plane. They are adjusted to provide suitable support and meet evenly when the patient closes in the retruded position at an occlusal vertical dimension that allows for sufficient freeway space. A flowable material is then introduced between the occlusal surfaces of the two rims to record their relationship.

The base of the occlusion rim can incorporate all or part of the impression coping to stabilize the rim during the recording procedure for a bar-retained denture. For a ball attachment-retained denture, the base of the rim can incorporate the actual impression caps (Fig. 15.21). The small retention caps of Nobel Biocare, Astra Tech, or Straumann ball attachments are best incorporated into a heat-cured acrylic resin base since they pull out of a wax base.



**Figure 15.21** Locator impression copings in a wax baseplate.



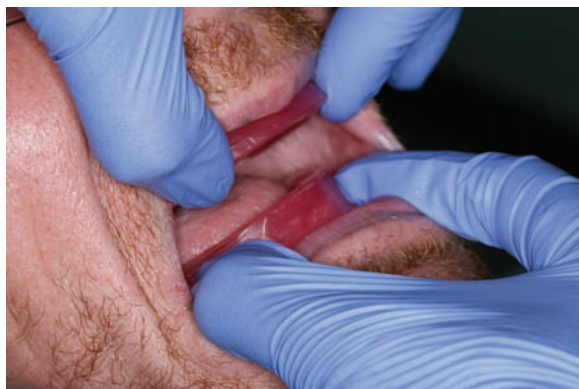**Figure 15.23** Sealed occlusal rims. A flowable registration material is placed on the mandibular rim; the patient is guided to close and held closed until the material has set.

The intended vertical relationship is determined by establishing the resting vertical dimension via a sliding caliper (Willis gauge) or by the use of dividers measuring between marks on the patient's nose and chin. Care should be taken in patient positioning when recording this value. Tilting the patient's head backward will tend to increase the rest vertical dimension, while tilting it forward will reduce this dimension. By convention, 4 mm are subtracted from the measurement of resting vertical dimension to arrive at a proposed occluding vertical dimension. This equates to approximately 2 mm of interocclusal distance (freeway space) at the first molar region. Whatever method is used to assess these dimensions, it has always been considered essential to have sufficient interocclusal distance for maximum comfort for conventional complete dentures. It is not clear whether the presence of implants alters this requirement.

The method of locating the relative position of one occlusion rim to the other is shown in Figures 15.22 and 15.23: a fluid setting material is introduced between the occlusal surfaces of the occlusion rims with a working time sufficiently long to allow an unhurried guided mandibular

closure into the retruded position, a setting time sufficiently short for the material to set soon after this closure, and sufficient durability for the material to remain intact after the occlusion rims are removed from the mouth. A facebow transfer record can be conveniently made at the same time as the interocclusal record by placing the facebow fork into the maxillary rim before the record is made. Once the interocclusal record material has set, the rims are then stabilized by the patient keeping the rims together while the facebow caliper is positioned over the fork and the infraorbital pointer is adjusted (Fig. 15.24).

After the facebow transfer record has been made, the entire assembly is removed from the patient and disinfected. The maxillary cast is then mounted on the upper member of a semiaadjustable articulator with low expansion mounting plaster and with the use of a facebow support. The mandibular cast is mounted once the maxillary mounting plaster has set.

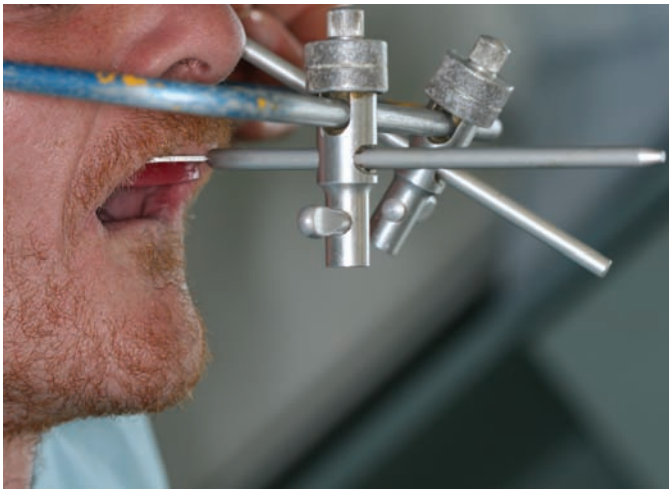


**Figure 15.22** Recording jaw relations. The left index finger and thumb are holding the maxillary occlusal rim in place and the right index finger and thumb are holding the mandibular rim in place. The right hand guides the mandible into the retruded contact position.

## SELECTION OF DENTURE TEETH

In general, the aim should be to select denture teeth that resemble the original natural teeth and to arrange them in a similar way, unless the patient requests a different appearance. This will usually produce the most natural looking dentures and the patient will adapt to them more quickly. Photographs of the patient's original teeth will help in this procedure or previous prosthesis that the patient wishes to duplicate.

Posterior teeth should be selected with as much care as anterior teeth. For the mandibular denture, the space available is from the distal surface of the proposed canine to the commencement of any slope up to the retromolar pad. It may be possible to fit two premolars and two molars into this space but, occasionally, a second molar or a premolar may need to be omitted, especially in a patient with a class 2 jaw relationship. In general, narrow occlusal surfaces are desirable to increase masticatory efficiency, but, in patients with class 2 or class 3 skeletal relationships, wider occlusal surfaces may be



**Figure 15.24** Facebow transfer. To locate the maxillary cast onto a semiadjustable articulator, a facebow record is needed. The bite fork is inserted into the wax, the facebow frame is attached, and in this case an orbital pointer is located and tightened.

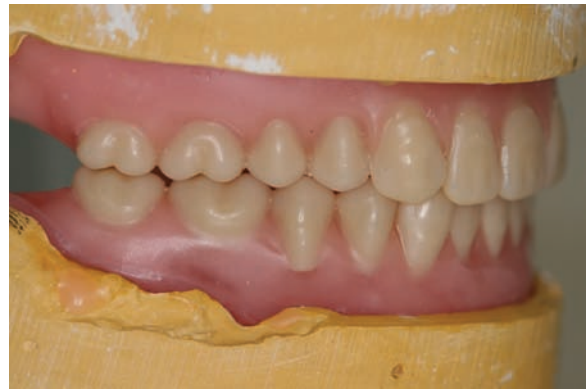necessary to develop and maintain occlusal contact in a range of mandibular positions.

### CONFIRMATION OF CAST RELATIONSHIP ON THE ARTICULATOR

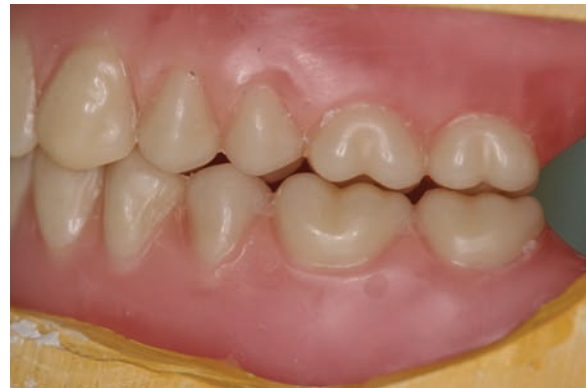The relationship of the casts on the articulator is confirmed by setting up denture teeth (on temporary wax or acrylic resin bases, or on heat-cured acrylic resin bases) in tight intercuspation and in the position prescribed by the occlusion rims (Fig. 15.25). The trial dentures are then placed in the patient's mouth and the patient is guided into closure in the retruded position. If the denture teeth come together evenly with no movement of the trial denture base, then the horizontal relationship of the casts can be considered confirmed. If this occlusion occurs at an occluding vertical relationship with a demonstrable interocclusal distance, then the vertical relationship of the casts can also be considered confirmed.

If the denture teeth do not meet evenly when the patient closes in the retruded position (Fig. 15.26), the occlusion should be examined with the trial dentures back on the articulator. If the teeth are not in tight intercuspation, they should be reset and the trial dentures again placed in the mouth. If the teeth still do not meet evenly, the cast relationship is incorrect and a new interocclusal record will be necessary. This is carried out by removing one set of posterior teeth, marking the mandibular incisors with the degree of overlap required when the new record is being made, and then making a new record as described earlier. The mandibular cast is remounted using the new record, the posterior teeth are reset, and the trial dentures are then replaced in the mouth to test the veracity of the cast relationship.

Occasionally, the denture teeth may meet evenly in the patient's mouth but at a vertical relationship that has insufficient or excessive interocclusal distance. If the amount is small,



**Figure 15.25** Working casts have been articulated and the denture teeth have been set up with good occlusal contacts.



**Figure 15.26** Poor occlusal contact. The posterior teeth do not meet evenly and will need to be reset.

the necessary adjustment can be made on the articulator because a facebow record has been made. If the error is large, it is better to make a new interocclusal record at the correct vertical relationship.

The patient's appearance with the dentures in place should be assessed, in particular the support provided by the prosthesis for the lips and cheeks and allowing for sufficient tongue space. The level of the upper occlusal plane and its arrangement in relation to the lip when the patient is smiling should be evaluated. The position of the centerlines on the dentures should be checked in relation to each other and with the center of the face. Correct anterior tooth position is accomplished by reference to anatomical landmarks such as the incisive papilla, preextraction records such as casts or photographs, speech sounds, and direct patient feedback. The mold and shade of the teeth should be confirmed with the patient.

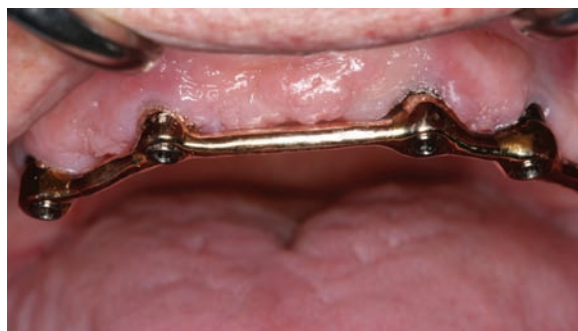The final step at this stage is to decide on the posterior extension of the maxillary denture if this has not already been done.

### COMPLETION OF THE IMPLANT OVERDENTURES

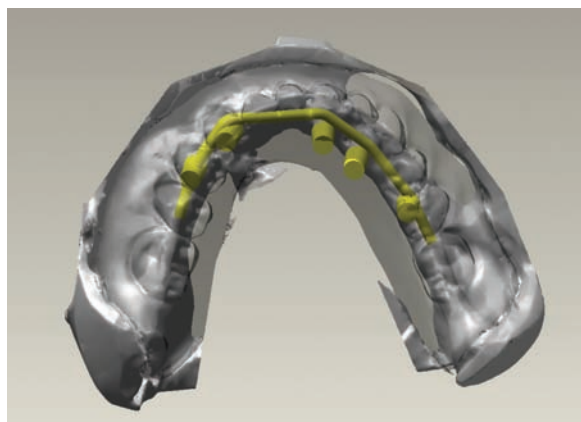
Where a milled bar and clip-retention system is being used, the trial denture setup is sent to the laboratory where the bar is now constructed with reference to anterior tooth position and the contour of the overdentures (Figs. 15.27 and 15.28). If a cast bar is being used, it should be tried in the mouth prior to completion of the dentures. If the bar does not fit the mouth (Fig. 15.29), it should be examined carefully on the cast (Fig. 15.30). If the bar does not fit the cast, it should be cut and resoldered or remade so that it does fit. Then it can again be tried in the mouth. If the bar demonstrates a passive fit on the abutments (Fig. 15.31), then the denture can be finished. If the bar does not demonstrate a passive fit, the final impression must be at fault and will need to be repeated. If, however, the composite verification stent mentioned earlier has been carried out, this can be avoided. The problem of passivity of fit should

not be encountered with milled bars unless the impression/cast is at fault.

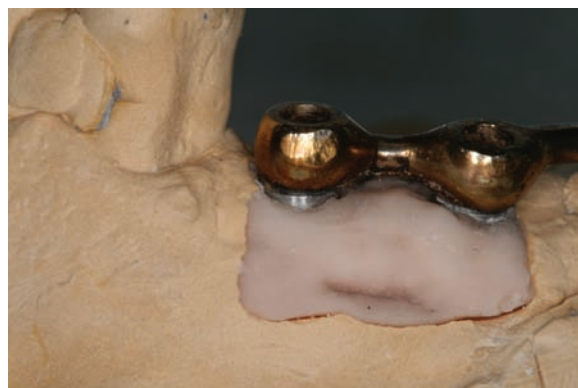Ideally, the posterior teeth should be set in a bilateral balanced occlusion. Much has been written about the advantages and disadvantages of such an occlusion. It is certainly difficult to achieve with some manufacturer's teeth.



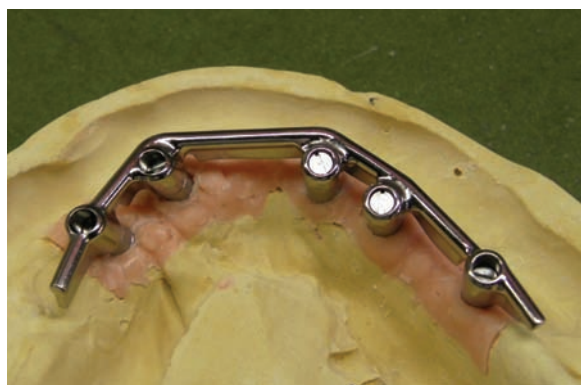**Figure 15.29** A poor fitting bar on the abutments on the patient's right side.



**Figure 15.27** 3D scan of the trial overdenture setup with the CAD bar shown in yellow.



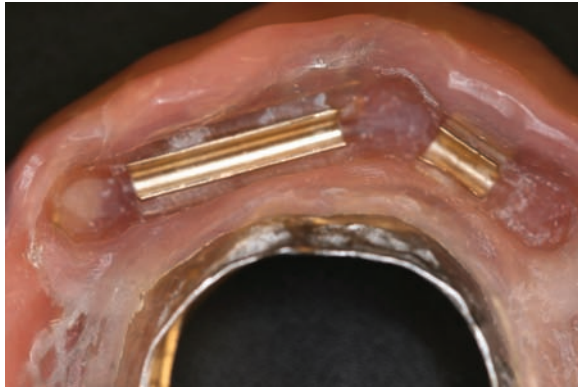
**Figure 15.30** An Astra Tech macro gold bar with a gap between the cylinder and uniAbutment replica.



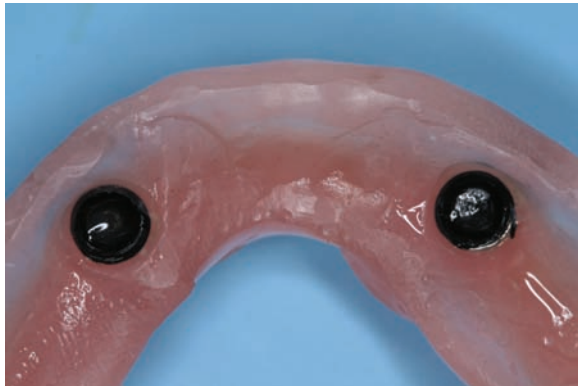**Figure 15.28** Milled titanium Hader® bar. The bar and supporting cylinders are ideally positioned to be in the thickest part of the denture and to provide maximum support.



**Figure 15.31** A well-fitting Nobel Biocare gold bar on standard abutment replicas.



**Figure 15.32** Completed mandibular overdenture with Dolder<sup>®</sup> bar clips.



**Figure 15.33** Astra Tech Locator housing cap processed into a cold-cured acrylic base. The nonactive laboratory black inserts are still in place.



**Figure 15.34** Completed implant overdentures with stained acrylic resin to stimulate melanin pigmentation.

Conventional dentures seem to be more stable with a balanced occlusion, but it is not clear whether such an occlusion has any effect on implant overdenture success. However, where there is evidence of overloading of implants, it would seem sensible to reduce the loading by reducing the anterior guidance.

The implant overdentures should now be finished with any clips attached to the bar over appropriate spaces and all but the retention elements of the clips blocked out with plaster prior to flasking, packing, and processing in the usual way (Fig. 15.32). Where ball attachments are being used, the retention caps are attached to the laboratory replicas and again blocked out with plaster (Fig. 15.33). Occasionally, gingival tinting will be required where the patient has melanin pigmentation (Fig. 15.34).

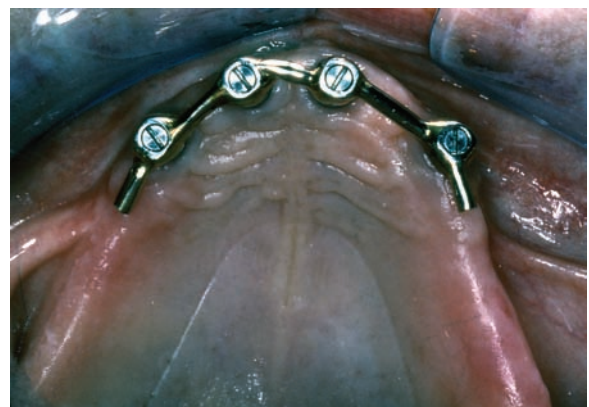### INSERTION OF THE IMPLANT OVERDENTURES

Healing abutments that have been left in place in between clinical stages should be unscrewed and the definitive abutments for bars, Locator, or ball abutment are placed. A torque driver should be used and components torqued down according to manufacturer's guidelines. Bars should now be attached with appropriate screws (Fig. 15.35) and torqued down.

The overdentures should be coated with pressure indicator paste to identify pressure areas, especially those created by the tray stops. These areas should be adjusted with an acrylic resin bur as well as any obvious sharp edges. The occlusion should be examined and minor adjustments can be made chairside. Any major occlusal errors will require a new interocclusal record and rearticulation of the dentures.

The retention of the overdentures should be assessed and increased or reduced as necessary by adjusting the clip for bars or adjusting the female housing for either Locators or ball abutments. At the time of fitting, it is advised to take baseline radiographs of the implants when loaded.

Once the dentures have been fitted, the patient should ideally be seen within one week for any necessary adjustments. The patient should be warned that some soreness is likely. This may be caused by pressure areas in the final impression, overextension, or faults in the occlusion. Use of pressure indicator paste and verifying the occlusion will reduce the prevalence of postinsertion discomfort. Occasionally, overextension will be caused by the viscous nature of the polyether impression material if the custom tray was not correctly



**Figure 15.35** A bar on maxillary standard abutments screwed passively in place.

extended. In addition, it is very difficult to make impressions for implant dentures by any other method than a static method: materials suitable for functional impressions are not really suitable for picking up the components of implant dentures or rigid enough to hold the laboratory replicas.

The patient should be seen regularly until the dentures are comfortable, and then reviewed at least annually as part of a regular maintenance program.

## MAINTENANCE SCHEDULE

After all normal postinsertion adjustments have been carried out and the patient is comfortable with the new implant dentures, the patient should be seen at least once every year for review. The patient should be asked to make contact immediately if there are any sudden changes such as loosening of a bar or ball attachment or loosening of the overdentures. The latter may indicate fracture of a clip or matrix, or deterioration of a rubber ring in a ball attachment retainer.

At the annual visit, overdentures should be tested for stability on the mucosa and any rocking diagnosed, for example, bone resorption or wear or fracture of a prosthodontic component. Ball attachments should be checked for tightness using the appropriate screwdriver. Bars can be removed and individual abutments checked for tightness and implants for any mobility. With the bar off, any calculus can be easily removed from the abutments and bar itself with a plastic instrument. The ball or Locator abutment retainers in the

dentures should be inspected for any fractures of the tines or deterioration of the nylon inserts. Clips in the overdentures should be checked for any fractures or looseness in the resin. Any repairs or replacements of the overdenture components or relining of the overdenture should be completed as necessary.

The implants themselves should be radiographed at one year postloading and subsequently as needed using the same view, otherwise any changes may not be detected. Where changes are visible, overloading may be responsible and it may be worthwhile reexamining the lateral occlusion. The denture teeth can be adjusted to reduce the anterior guidance where necessary. It is also very important that the patient maintains a very good level of plaque control to prevent inflammation of the peri-implant mucosa and bone loss.

## BIBLIOGRAPHY

- Chan MFW-Y, Johnston C, Howell RA. A retrospective study of the maintenance requirements associated with implant stabilized mandibular overdentures. *Eur J Prosthodont Rest Dent* 1996; 4:39-43.
- Hemmings KW, Schmitt A, Zarb GA. Complications and maintenance requirements for fixed prostheses and overdentures in the edentulous mandible: a five-year report. *Int J Oral Maxillofac Implants* 1994; 9:191-196.
- Watson RM, Jemt T, Chai J, et al. Prosthodontic treatment, patient response, and the need for maintenance of complete implant-supported overdentures: an appraisal of five years of prospective study. *Int J Prosthodont* 1997; 10:345-354.

## Complications and maintenance

### INTRODUCTION

Complication rates should be low and in most cases avoidable by careful attention to diagnosis, treatment planning, good surgical and prosthodontic training and experience. This should be helped by following well-established protocols that demonstrate high success and predictability. However, complications can occur in the early treatment phases, either surgical or prosthodontic, or following completion of treatment during the maintenance phase. Failure of initial osseointegration of individual implants should be relatively rare, with most failures occurring during the initial healing period or following abutment connection and initial loading.

Longer-term complications may be associated with

- general wear and tear;
- inadequate attention to oral hygiene;
- poorly controlled occlusal forces;
- poor design of prostheses;
- utilization of an inadequately tested implant system;
- soft tissue deficiencies;
- patient risk factors such as smoking, periodontitis, and bruxism.

To measure treatment success and the incidence of complications, it has been suggested that longitudinal studies of implant systems should be a minimum of five years (preferably prospective studies rather than retrospective), with adequate radiographic and clinical supporting data. The complications relating to surgery are common to all types of implant treatment and systems and are considered together. Prosthetic and late complications and maintenance are dealt with under separate sections for single tooth replacement and fixed bridges, with a separate chapter on removable overdentures.

### SURGICAL SEQUELAE AND COMPLICATIONS

It is important to warn patients about the most common surgical/postoperative complications. Patients may experience some postoperative swelling, bruising, and discomfort, even with straightforward single implant surgery (Fig. 16.1). This is much more likely in cases involving placement of a large number of implants or cases involving grafting. These complications can be minimized with

- gentle surgical manipulation of the hard and soft tissues;
- avoidance of overreflection of flaps;
- preoperative and postoperative analgesics (preferably ones with anti-inflammatory properties such as the non-steroidal anti-inflammatory drugs, e.g., ibuprofen);
- recommendations to use ice packs to reduce swelling;
- pressure applied to the wound postoperatively to control hemostasis and avoid hematoma formation.

In our experience, the majority of patients have little or no postoperative swelling/bruising/pain. The success of osseointegration is dependent on minimal mechanical and thermal trauma to the bone, and therefore the patient should not experience pain in the bone sites. Severe pain would suggest poor technique and may coincide with early failure of the implant. A more controversial topic is whether pre- and post-operative antibiotics are required to prevent infection and subsequent failure of the implant. It was once routine to prescribe antibiotics. However, as the surgery is carried out under good surgical conditions and a sterile implant is delivered carefully into the prepared site, the chance of infection should be low. Recent systematic reviews have suggested minimal differences in implant success rates with and without antibiotic cover. It would be prudent to use antibiotics if

- there has been a recent infection at the site;
- augmentation and grafting is performed;
- the patient has a medical history that suggests a susceptibility to infection;
- the patient has hard bone (type 1) that has been difficult to cut and cool.

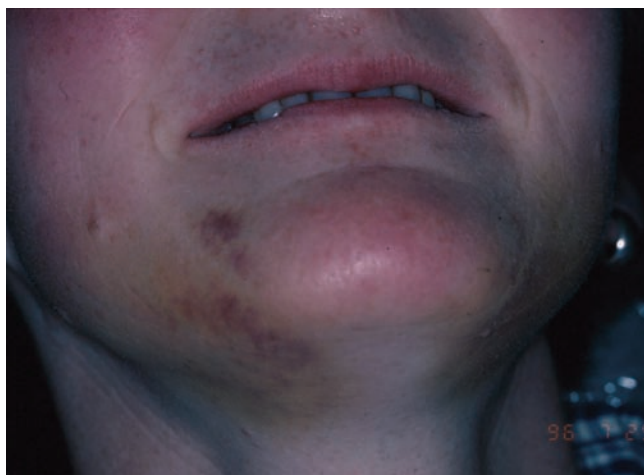The following situations could also be considered for antibiotic cover:

- Immediate replacement techniques are used.
- Multiple implants are placed where flaps have been raised extensively or for a long period of time.
- The patient is a smoker.
- The implant placement has breached the maxillary sinus floor.

In some cases, patients experience infection in the soft tissue if the surgeon has left debris under the flap margins or a large clot has become infected. These cases are largely avoidable.

### Wound Dehiscence

The soft tissue wound may breakdown in the first week following implant installation (e.g., particularly in the severely atrophic mandible where the soft tissue is delicate and deficient). This could be a cause for concern where it leads to implant head exposure in a submerged implant protocol. If an implant head becomes exposed in a case where it was planned to be submerged, it is important to keep the area clean with antiseptic rinses such as 0.2/0.12% chlorhexidine to avoid inflammation and marginal bone loss. This situation may be improved by changing the cover screw on the implant for a healing abutment. Any breakdown of the soft tissue wound can lead to inflammation/bone loss and is most critical in grafting procedures where graft vitality and success can be severely compromised.



**Figure 16.1** Bruising near the chin and submandibular region one week following implant surgery to place six implants in the upper jaw.

### Early Implant Failure

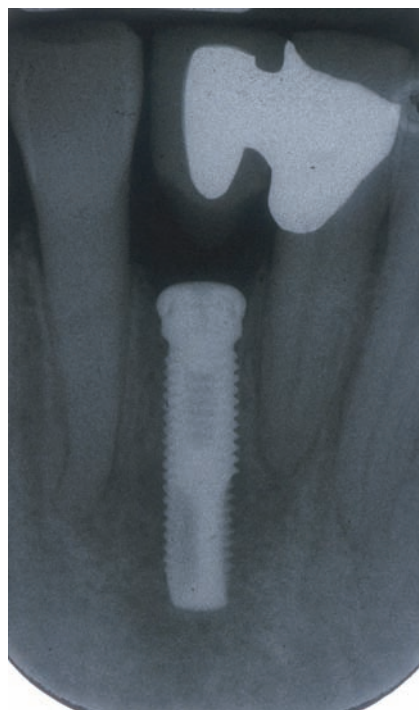
Early implant failures may be associated with the following:

- Poor surgical technique resulting in thermal damage to the bone
- Low initial stability of the implant
- Surgical trauma to an adjacent tooth
- The implant communicating with an adjacent endodontic lesion
- Postoperative infection
- Uncontrolled early loading

Most early surgical failures of osseointegration are due to poor surgical technique or placement of implants into bone of very poor density. Failure of osseointegration may not be obvious until the surgeon carries out abutment connection surgery or when the prosthodontist tries to load the implant. It is sometimes difficult for the clinician to assess implant stability and occasionally a loose abutment may be misinterpreted as a failed implant. The abutment should be tightened and the stability reassessed. Tightening of the abutment should not elicit discomfort/pain unless there is inflammation within the bone (consistent with failure) or trapping of soft tissue between abutment and implant head. In most cases mild discomfort soon resolves and there is no long-term complication. In other cases the discomfort is a sign that there is a problem, and more obvious failure of the osseointegration is revealed some days or weeks later.

Damage to the bone resulting in necrosis, pain, and subsequent infection is more likely where hard bone has been prepared with inadequate cooling and or blunt drills (Figs. 16.2 and 16.3). This is more likely at deep preparation sites (e.g., over 15 mm). Such deep preparations are not usually necessary in good-quality bone and should be avoided. The resultant pain can be severe and an infection that is likely to be deep seated can track through the soft tissues. In the anterior region of the mandible the infection may track to the external skin surface, producing a disfiguring sinus tract, fibrosis, and scarring (Fig. 16.4).

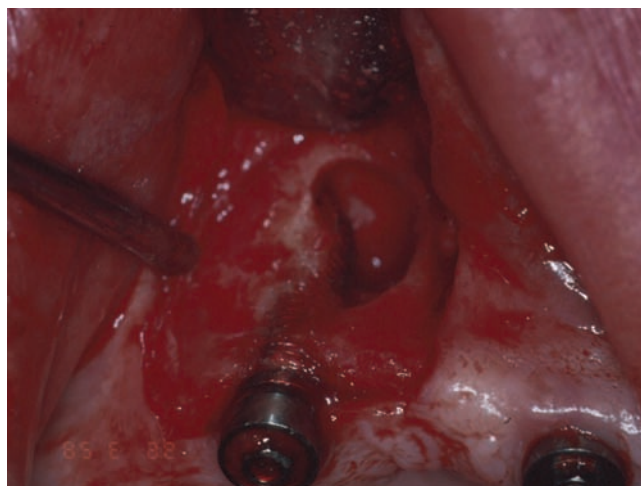
If during preparation of the implant site the drill damages the periodontium of an adjacent tooth root, this can lead to an inflammatory response and early failure of the implant. The patient complains of pain postoperatively and the affected



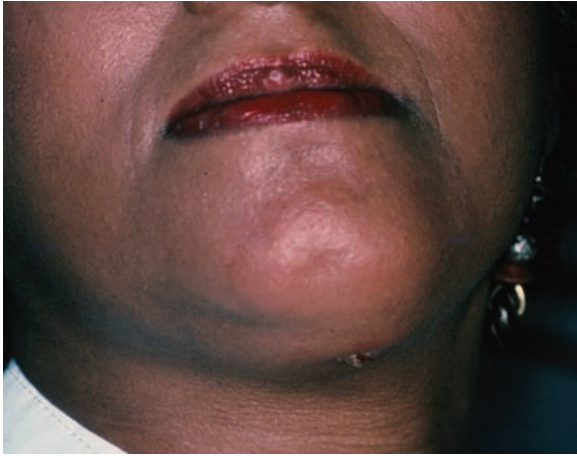**Figure 16.2** Periapical radiograph of an implant placed in the lower incisor region. There is a radiolucency associated with the apex of the implant. This was caused by overheating of the bone during the preparation of the site and presented with considerable pain.

tooth is usually very tender to percussion. Plain radiographic examination may not provide clear evidence of the trauma due to overlap and parallax errors.

Cases of early implant failure may be completely unexplained in some cases. However, in some cases failure has been associated with implants entering undiagnosed residual endodontic lesions that are not visible on plain radiographs.



**Figure 16.3** Surgical exposure of an apical lesion of bone loss, probably caused by inadequate cooling of the end of the drill during preparation of the site. The patient had experienced pain and infection for several months after implant placement.

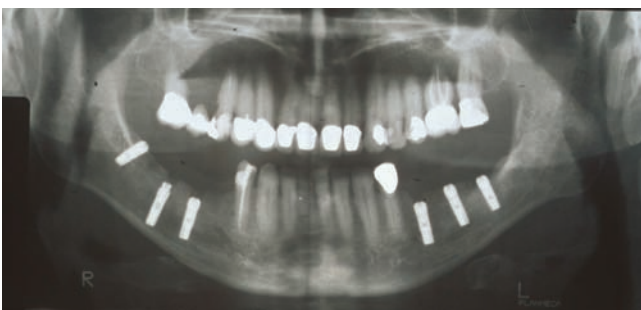


**Figure 16.4** A sinus tract appearing on the skin at the lower border of the mandible. Inadequate cooling of an 18-mm implant site in hard bone was the likely cause.

### Damage to Neurovascular Structures

Loss of sensation to the lower lip caused by trauma to the inferior dental or mental nerve is a serious injury. Implant surgery close to these structures is hazardous and great care should be taken and the patient warned of the possible consequences (Fig. 16.5). The following points should be appreciated to avoid this complication:

- Avoid making relieving incisions in the area of the mental nerve.
- Do not place crestal incisions over the region of a superficially located mental foramen in the severely resorbed mandible.
- Adequately expose, identify, and protect the nerve when operating close to it.
- Check for anterior loops of the inferior dental nerve anterior to the mental foramen if utilizing this site by radiography or by gentle probing of the foramen.
- Plan carefully with good tomographic or CT images that allow good visualization of the inferior dental canal and the superficial ridge.



**Figure 16.5** A dental panoramic tomograph showing placement of implants in the posterior mandible with minimal regard to the position of the inferior dental canal. The implants on the patient's right breached the canal and resulted in mental anesthesia; the implants on the left were placed so close to the nerve that paresthesia resulted.

- Take careful measurements of the available height and width of bone above the canal.
- In some circumstances it may be possible to place an implant in a plane that safely avoids the canal, which could not be appreciated using 2D radiography.
- Avoid thermal damage to the bone that is left between the implant tip and the nerve canal.
- Allow a safety margin for the following:
  - Measurement error
  - A margin of bone between implant tip and canal, which we would suggest to be no less than 2 mm and preferably nearer to 4 mm (although some surgeons will place implants very close to the canal)
  - Drill length at the cutting tip (different drills have various profiles and may overcut 1 to 2 mm longer than the planned implant length)
  - Difficulty of surgical access, vision, and control of cutting pressure at the depth of the site

Patients are unlikely to complain following damage to the incisive nerve in the midline of the anterior maxilla. In some cases this nerve can be removed and the canal grafted to provide adequate bone for implant placement (see chap. 12). Damage to the incisive branch of the inferior dental nerve may go unnoticed in patients with no teeth in the anterior mandible. However, in dentate patients, an implant placed in the canine or first premolar region can sever or damage the incisive nerve supply to the remaining lower incisors. The patient may complain of paresthesia or anesthesia of the lateral incisor periodontium and this can be distressing. Therefore, it is wise to avoid violation of the mandibular incisive canal in dentate subjects. If damage to the inferior dental nerve is suspected, it is recommended to remove the offending implant within 24 hours after placement to allow best chance of recovery.

A related problem can also occur when bone grafts are taken from the chin in dentate subjects. An osteotomy cut too close to the incisor or canine apices can result in alterations of sensation, or worse, loss of pulp vitality. A safety margin of at least 5 mm and preferably 8 mm is recommended between the osteotomy cut and the apices.

### Fractures

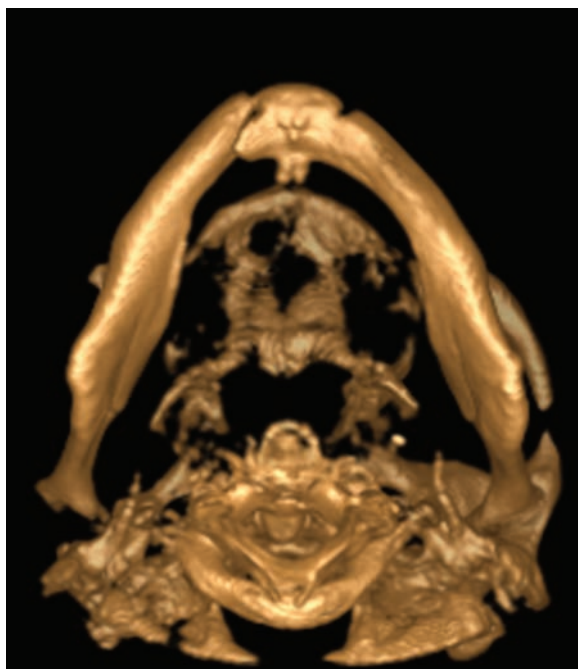
The severely resorbed mandible can be compromised by implant placement such that a fracture occurs at surgery or a short time following this (Fig. 16.6). 3D radiography may be indicated to adequately assess the profile of the severely resorbed mandible and avoidance of the placement of too many implants within zones of low bone volume (e.g., mandibular first premolar region).

### PROSTHETIC COMPLICATIONS AND MAINTENANCE

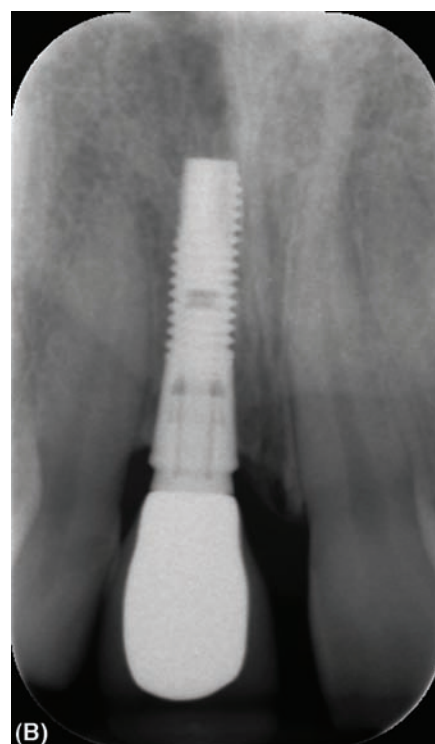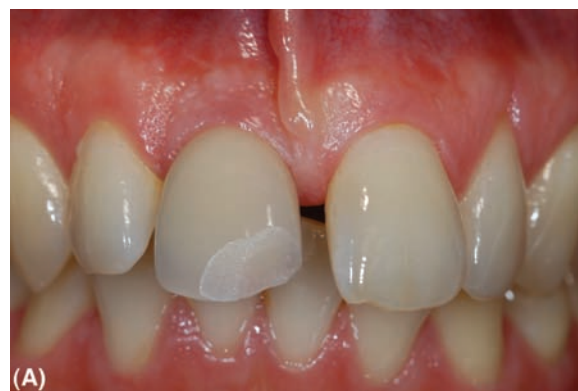Complications and maintenance requirements vary widely between patients, depending on

- susceptibility to caries and periodontal disease in the dentate patients;
- complexity and type of implant-supported prostheses;
- functional demands of the prosthesis;
- the patient's ability to maintain an adequate standard of oral hygiene.

It is generally recommended that patients treated with implant prostheses are seen at least on an annual basis, but in many cases they will also require routine hygienist treatment at



**Figure 16.6** A cone-beam CT of an edentulous mandible reconstructed in a 3D format (and viewed from the under surface) showing a fracture in the right anterior zone. This occurred after implant placement, giving rise to considerable pain and infection. The implant was removed and the fracture required fixation with plates and screws.



**Figure 16.7** (A) Fracture of the porcelain on the implant crown at UR1. This was caused by trauma. (B) Radiograph of the same case showing an otherwise successful implant restoration with good bone levels near the top of the implant, eight years following initial placement. (C) Attempted removal of the fractured crown with crown removal forceps. (D) Attempted removal of the crown using a matrix band tightened around the crown to secure a firm hold. A crown and bridge remover can then be used to apply a sharp force to the matrix retainer in an attempt to dislodge the cementation. (E) In this case the crown could not be removed using forceps or crown removers and an access hole has been prepared in the palatal aspect of the crown to uncover the abutment screw. Fortunately, in this case, the long axis of the implant was in line with the cingulum of the crown. This could be verified by evaluation of the working casts that were used to provide the original crown. (F) A new customized cast abutment has been connected to the implant. (G) A newly fabricated crown has been cemented to the abutment. (H) A radiograph of the new crown confirming the fit of the abutment to the implant and crown to the abutment.

three, four, or six monthly intervals, according to individual requirements (see section "Routine Hygiene Maintenance Requirements," page 203).

### Single Tooth Units

Single tooth units should require little maintenance. The most common reported complication is chipping/fracture of the porcelain/veneer material (about 1% per annum) (Fig. 16.7). This complication is more common in more extensive fixed prostheses. It is thought to be more likely in implant-supported than tooth-supported crowns due to the rigidity of the implant system. Repair of porcelain chips is unpredictable and a new crown may be required.

Many single units are cemented and the integrity of the cementation should be checked. Crown decementation of single tooth units is low (about 1% per annum), even in cases where a relatively weak temporary cement has been used (Fig. 16.8). This is because of the close fit of the abutment to the crown, and in some cases a high degree of parallelism between them, which may make separation difficult or impossible (Fig. 16.7). A complication with parallel abutment designs is failure to seat the crown at the original cementation because of failure to relieve hydraulic pressure within the crown using a cementation vent (Fig. 16.9). The resulting poor marginal fit and exposure of a large amount of cement lute may result in soft tissue inflammation because of the increased bacterial plaque retention (Fig. 16.8). A vent also helps to reduce excess cement being extruded at the crown margins, which can give rise to considerable inflammation, including soft tissue abscess and fistula formation. However, cement extrusion is less likely in abutments with integral

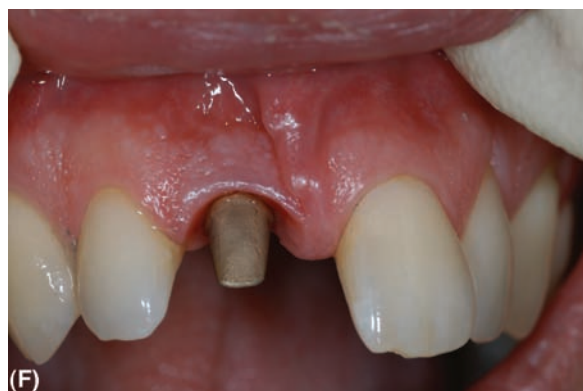
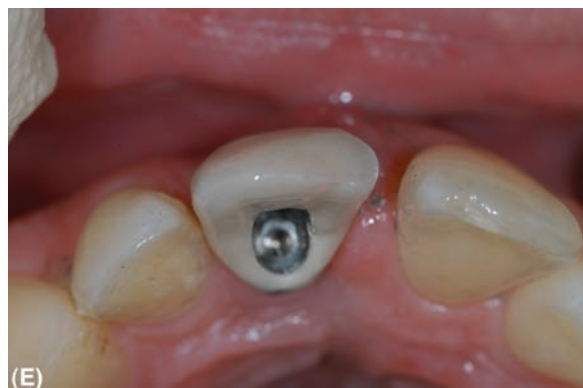
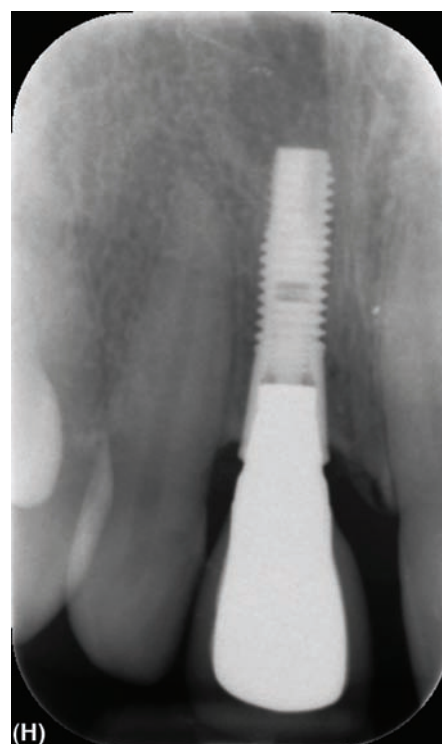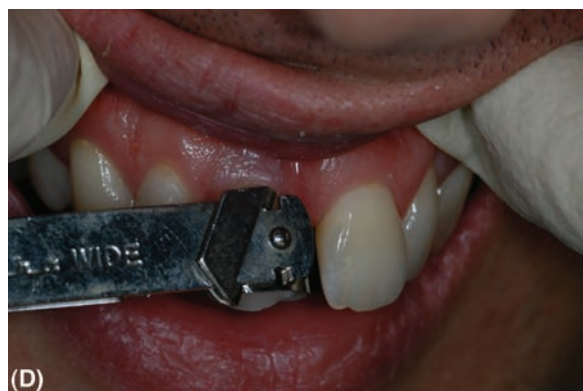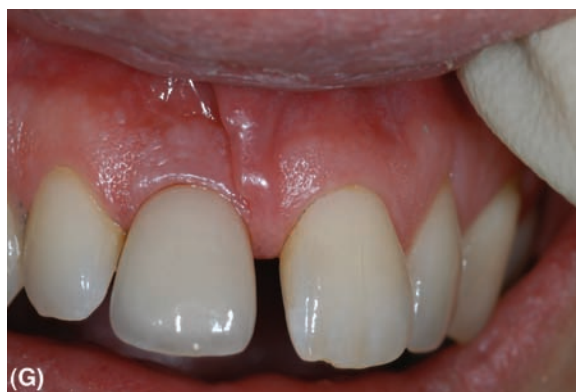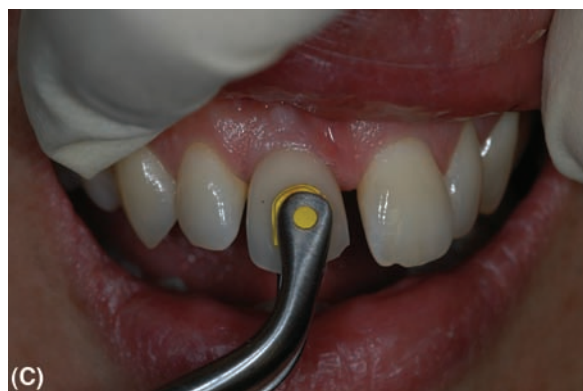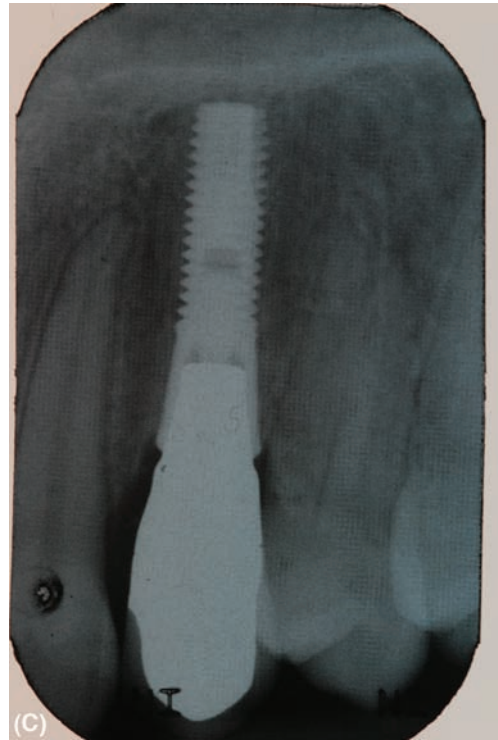
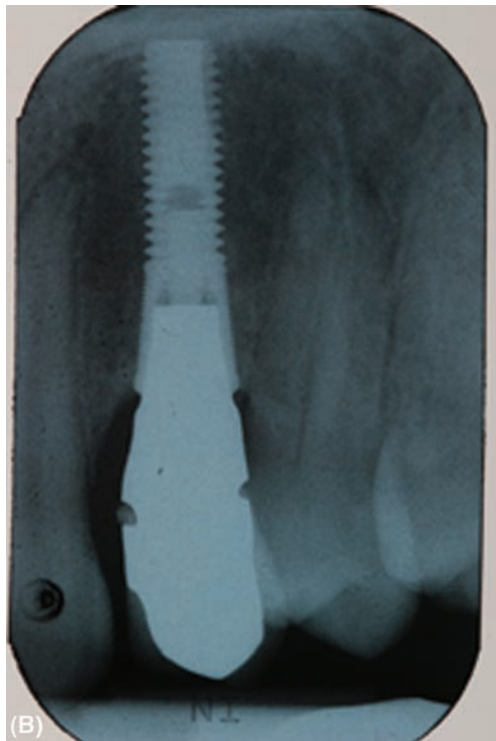
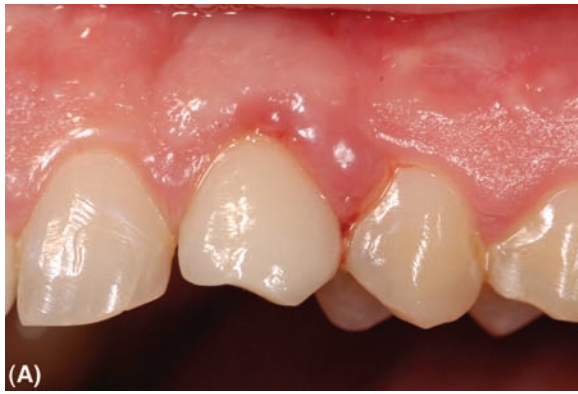Figure 16.7 (Continued)

Figure 16.7 (Continued)

cement venting designs, customized abutments with less parallel walls, and judicious use of cement volume.

Plaque retention and development of inflammation may also be the initial sign of a loose abutment, due to abutment screw loosening. This is easy to deal with in a screw-retained single crown but may be very difficult in the cement-retained crown that may be impossible to remove from a highly retentive and loose abutment. Drilling through the crown to locate the screw is usually difficult and may result in the need to replace both abutment and crown (Fig. 16.7E). Abutment screw loosening has been reduced in recent years compared to earlier reports (about 3% per annum) because of better implant-abutment junction designs and controlled torque when tightening the screws.

Screw loosening, crown decementation, and crown chipping are more likely to occur in patients who have parafunctional habits. These complications are more likely to lead to more serious consequences of abutment screw fracture or even implant fracture (see next section). Patients with nocturnal



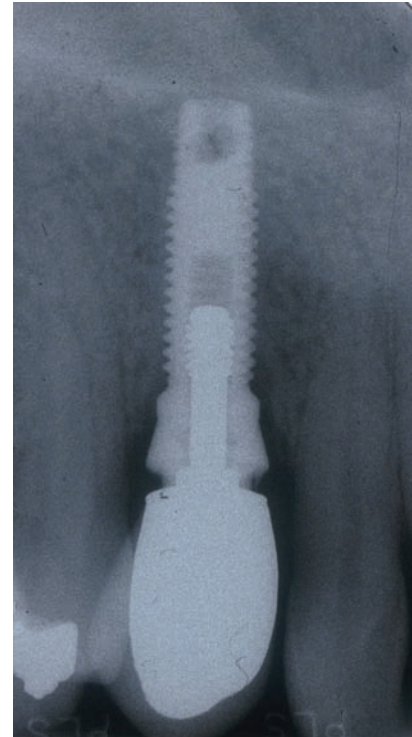
**Figure 16.8** (Continued)

**Figure 16.8** (A) The upper left canine is an implant-supported crown. There is considerable inflammation of the peri-implant soft tissue. (B) A radiograph of the implant and crown shows that there is a large cementation gap between the crown and the abutment and there is excess glass ionomer cement at the joint. It has given rise to plaque accumulation and development of severe soft tissue inflammation. The crown had been recemented following failure a few weeks previously. (C) A base line radiograph of the same case several years before showing proper seating and cementation of the crown.

bruxism should be provided with night guards and careful attention paid to occlusal contacts at each review visit. Occlusal contacts should be evaluated to ensure that initial contacts occur on the natural teeth rather than the implant.

### Fixed Prostheses

The prostheses should be checked for signs of wear or breakage on a regular basis. Fixed restorations should have the cementation or screw fixation checked. This may include checking the screws that retain the prostheses and those that



**Figure 16.9** A radiograph of a gap between abutment and crown. Failure to seat the crown may be due to hydrostatic pressure between a parallel abutment and the close fit of the crown, or premature setting of the cement, or a problem has arisen through recording of the position of the abutment during the impression process.

retain the abutments (see below). The occlusion should be reevaluated, particularly where there has been occlusal wear of the prostheses or coexisting natural dentition. It is not generally recommended to routinely remove screw-retained bridge superstructures unless there is suspicion that there is a problem with one of the implants/abutments. Fixed prostheses that have proved difficult to clean by the patient may require removal to allow adequate professional cleaning, which is easier with screw-retained fixed prostheses than cemented types.

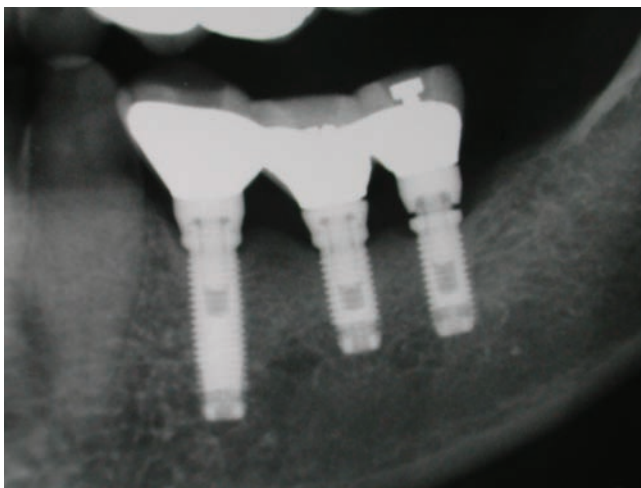
The screws retaining a prosthesis to the abutment are often covered with a layer of restorative material, such as composite or glass ionomer, which may need replacing. Screws that are accessible should be checked to ensure that they have not loosened. This is more likely to occur in an ill-fitting prosthesis or where high loads have been applied.

### Removable Prostheses

Removable prostheses need to be checked for retention and stability. In the case of prostheses with combined implant and mucosal support, it is important to check that the implants are not suffering from overload caused by loss of mucosal support due to further ridge resorption. It has been suggested that removable prostheses often require more maintenance in the form of adjustment and replacement of retentive elements, compared with fixed prostheses. This is dealt with in detail in chapter 17.

### Screw and Abutment Connections

Repeated chewing cycles may produce screw loosening, either at the bridge screw level or at the abutment level (Fig. 16.10). Abutment loosening and development of a gap between abutment and implant will manifest as a loose prosthesis. This can even appear as though there has been failure at the implant level. Screw loosening can be minimized by attention to occlusal contacts and adequate tightening of the bridge and abutment screw, in the first place by using specifically designed torque wrenches/handpieces (see chap. 13). Some implant systems suggest retightening of bridge screws a few



**Figure 16.10** A radiograph of a posterior mandibular bridge on Branemark implants, showing failure to seat the distal abutment on the hex of the implant and an associated loose bridge screw.

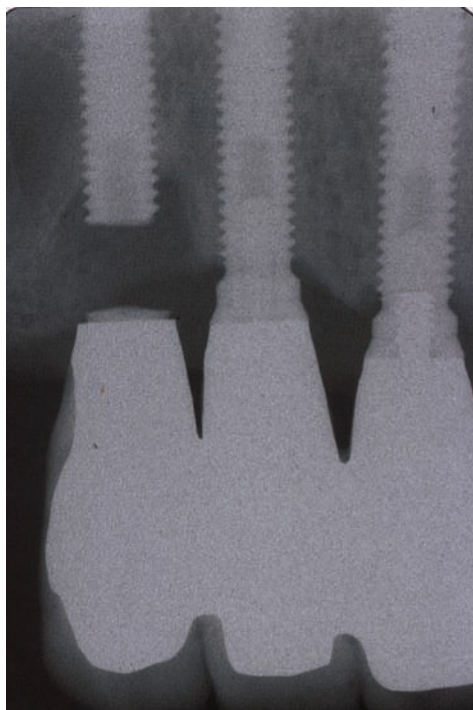


**Figure 16.11** The lower screw is a retrieved fractured Branemark abutment screw, compared with an intact screw above it. The fractured screw was removed from the case illustrated in Figure 16.12.

weeks after initial fitting of the prosthesis superstructure. The designs of abutment-implant interface may also reduce this complication. The internal abutment connection designs should produce a more stable joint than the flat top designs. Even with the latter design, the occurrence of screw loosening is low provided the correct torque has been applied. Screw loosening is often an important sign of overload due to

- poorly fitting prosthesis/nonpassive fit;
- poor design, for example, overextension of a cantilever;
- long crowns/abutments (from implant head to occlusal/incisal edge);
- inadequate attention to occlusal contacts;
- too few implants/teeth to establish an adequate/stable occlusion;
- parafunctional activity.

These factors require identification, correction, and proper management to avoid this complication. Failure to deal with these problems, particularly in patients who exhibit parafunctional activities, may predispose to screw fracture (retention screws or abutment screws), which manifests as a loose prosthesis (Fig. 16.11). The fractured screws need to be removed and replaced. In many instances the fractured screw can be unwound by engaging the fractured surface with a sharp probe and moving the probe round in a counterclockwise direction. Alternatively, a commercially designed retrieval kit may make this process easier. The screw can then be replaced and due attention given to correction of the cause of the problem to avoid a repeat of the problem and possibly ultimate failure of the implant. In some instances, removal of the fractured screw proves to be impossible. Fractured screws are difficult to remove by drilling without causing considerable damage to the implant. This may make subsequent restoration impossible unless it is feasible to construct a custom-made post that can be cemented within the implant.



**Figure 16.12** A radiograph of three Branemark implants supporting a maxillary bridge that had been subjected to excessive loading. The patient was a bruxist. The anterior implant (*right*) had previously suffered a fractured abutment screw, the top half of which was removed and replaced with a gold screw (more radiopaque) but the apical part could not be removed. The distal implant (*left*) had a similar history that was subsequently followed by fracture of the implant at the level of the apex of the abutment screw. The latter situation usually requires removal or burial of the fractured implant.

### Implant Fractures

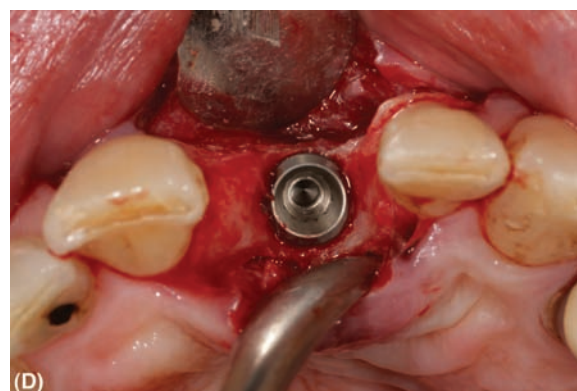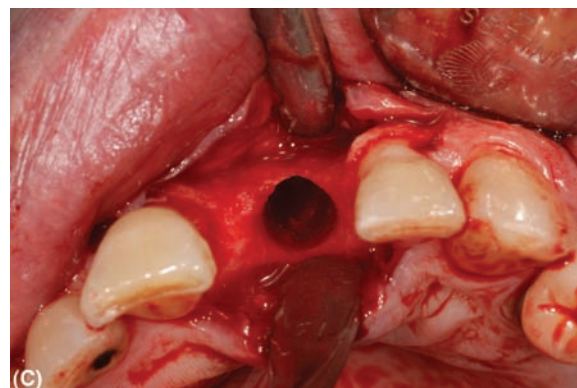
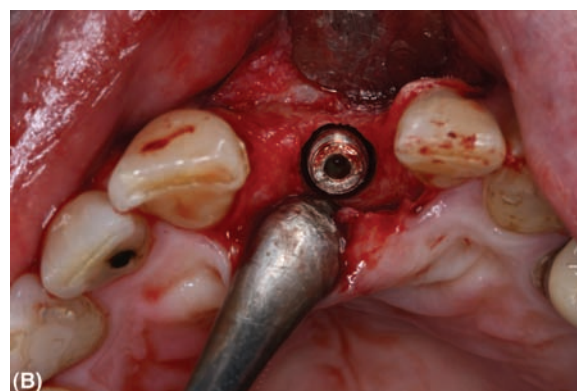
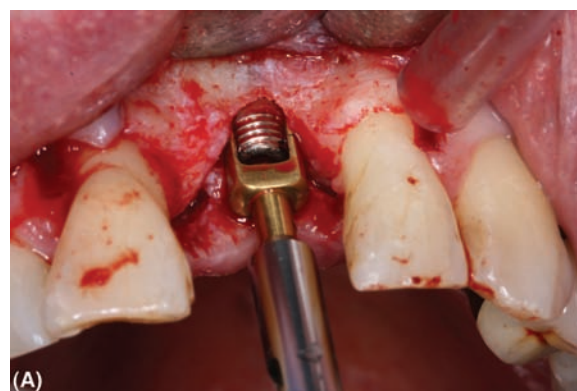
Fortunately, fracture of an implant is rare (0.1% per annum) (Fig. 16.12). It is more likely to occur with

- narrow diameter implants, particularly where the wall thickness is thin;
- excessive load;
- marginal bone loss that has progressed to the level of an inherent weakness of the implant, often the level where wall thickness is thin at the apical level of the abutment screw.

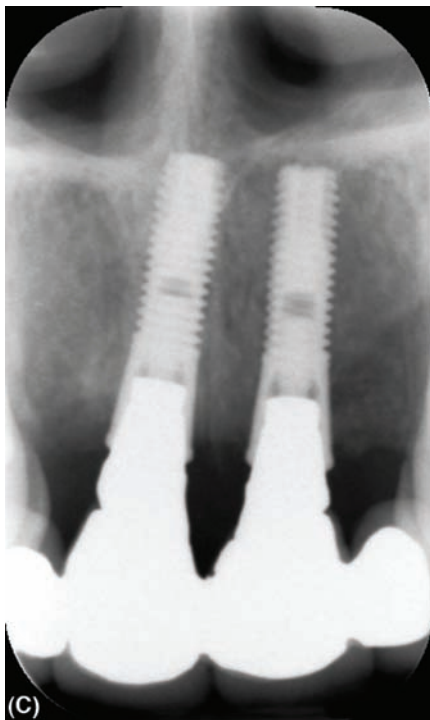
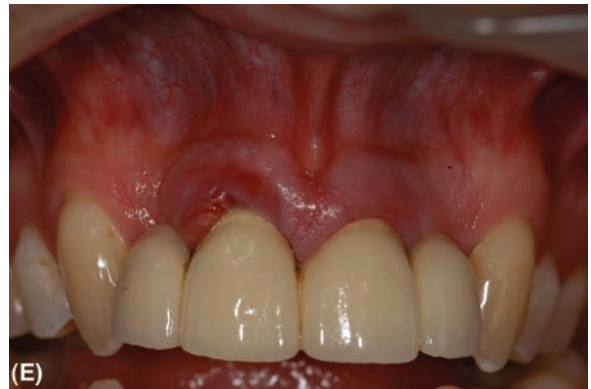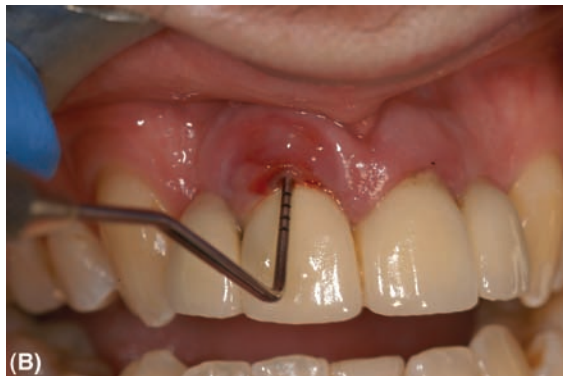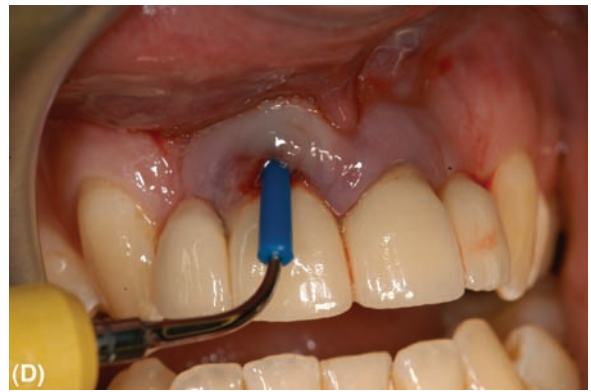
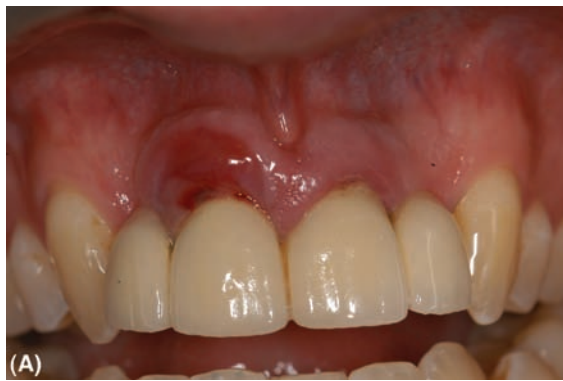Implant fracture is rarely retrievable, and requires either burying the fractured component beneath the mucosa or its removal (Fig. 16.13). The latter can be difficult and traumatic, usually requiring surgical trephining that may leave a considerable defect in the jaw bone.

### SOFT TISSUE EVALUATION AND PROBLEMS

The mucosa surrounding the implant abutments should appear free of superficial inflammation. Gentle pressure on the exterior surface of the soft tissue should not result in any bleeding or exudate and produce minimal or no discomfort. Inflammation of the peri-implant mucosa has been termed “peri-implant mucositis” to differentiate it from the more destructive lesion involving bone loss, so-called peri-implantitis. Probing depths may be evaluated and will depend on the thickness of the original



**Figure 16.13** A series of photographs showing removal of a fractured implant. (A) A trephine is used to drill out the bone from around the implant. The trephine size is closely matched to the outer diameter of the implant. (B) An occlusal view showing the circumference of bone removed from around the implant. (C) The implant has been removed and the size of the resulting defect can be seen. (D) A wide-bodied (5-mm) Astra Tech implant has been inserted into the site achieving a close fit between the implant and the bony walls.



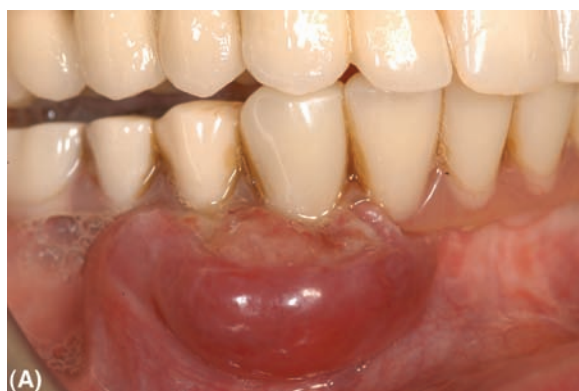
**Figure 16.14** (A) Severe soft tissue inflammation associated with the implant at UR1. (B) A mid-labial probing depth of 6 mm is recorded. (C) A periapical radiograph of the implant bridge. This demonstrates that there has been some bone loss (approximately 2 mm) associated with the right implant. Apical positioning of the implants and the long abutments account for much of the increased probing depth. (D) An ultrasonic scaler with a plastic tip is used to debride the abutment surface. (E) Two weeks after debridement there has been some improvement in the soft tissue inflammation but further treatment is required.

**Figure 16.14** (Continued)

mucosa, any overgrowth of soft tissue, and any loss of attachment/marginal bone loss that may have occurred (Fig. 16.14). Standard periodontal probes with a tip diameter of approximately 0.5 mm and a probing force of 25 g are recommended. Ideally probing depths should be relatively shallow (<4 mm) with no or minimal bleeding. Studies have demonstrated that probing around implants is not dissimilar to probing around the natural dentition. In general, the junctional epithelium is quite delicate and can be breached by the probe. The underlying connective tissue around implants is not connected by well-formed fiber bundles to the abutment/implant surface and forms parallel collagen fiber bundles. This offers less resistance to probing. In general, the probe stops short of the bone margin by about 1 mm. If increased probing depths, soft tissue proliferation, copious bleeding, exudate or tenderness to pressure are found, the area should be examined radiographically (regardless of whether radiographic reevaluation is scheduled) to determine whether there has been any loss of marginal bone or loss of osseointegration (Fig. 16.14C) (see section "Peri-implantitis"). In these circumstances it may be advisable to dismantle a screw-retained implant superstructure to allow adequate examination of individual abutments and implants.

Peri-implant mucositis can be corrected with attention to oral hygiene and professional cleaning. The latter is also considerably facilitated if the prosthesis can be dismantled and cleaned outside the mouth. However, there are a number of instances that may require surgical correction of the soft tissue problem:

- Soft tissue overgrowth
- Soft tissue deficiencies
- Persistent inflammation/infection
- Continuing bone loss (see section "Peri-implantitis")



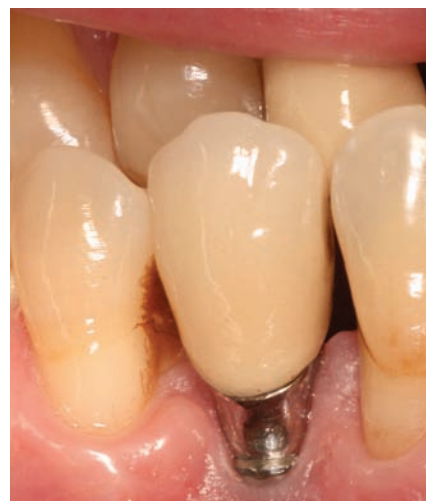**Figure 16.15** (A) A large red firm swelling associated with an implant-supported mandibular bridge. This epulis was diagnosed histologically as a giant cell granuloma. (B) A radiograph of the implant associated with the epulis. There is an area of radiolucency and bone loss associated with the apex of the implant. The marginal bone levels appear to be satisfactory.

### Soft Tissue Overgrowth

Soft tissue proliferation may occur around bridges with poorly designed embrasures and under supporting bars of overdentures (Fig. 16.15). It may require simple excision if there is adequate attached keratinized tissue apical to it, or an inverse bevel resection as used in periodontal surgery to thin out the excess tissue but preserve the keratinized tissue to produce a zone of attached tissue around the abutment.

### Soft Tissue Deficiencies

The transmucosal part of the implant restoration may emerge through nonkeratinized mucosa, particularly in situations where there has been severe loss of bone, for example, edentulous jaws.



**Figure 16.16** Recession of the gingival margin at the implant replacing the upper left canine. The gold abutment is visible, together with the head of the implant. This patient has a thin gingival morphotype and recession associated with the adjacent teeth.

Nonkeratinized mucosa looks redder and more delicate than keratinized tissue and may lack attachment to the underlying bone (Fig. 16.16). This can give rise to soreness and compromised plaque control, particularly in overdenture cases. Persistent soreness and inflammation can be overcome by grafting keratinized mucosa to the site in a procedure that is the same as free gingival grafting using donor tissue from the palate (see chap. 12).

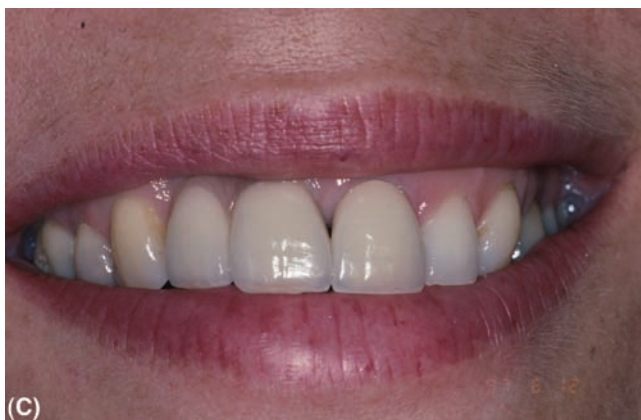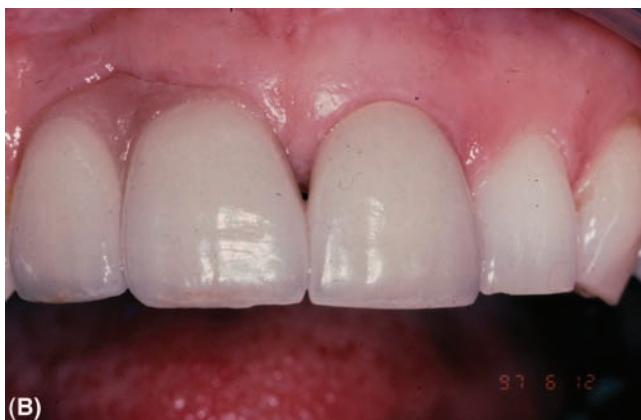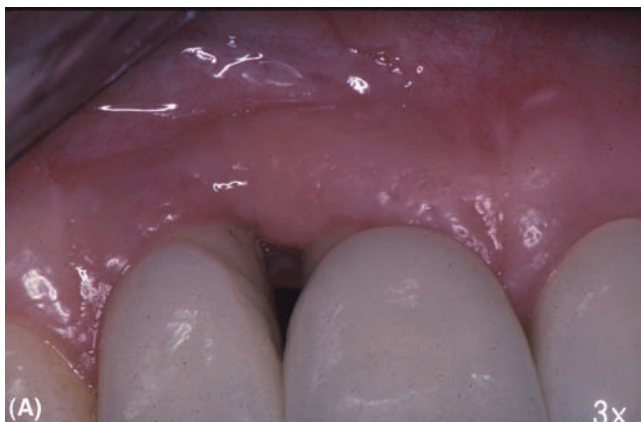
In situations where there has been loss of interdental soft tissue papillae, this is usually impossible to correct surgically (Fig. 16.17).

### Persistent Inflammation

Persistent inflammation or discomfort may arise due to poor implant positioning. It may require recontouring of the soft tissues to allow patient cleaning, and this may reveal the less than satisfactory aesthetics produced by poor planning and execution of treatment (Fig. 16.18). In other more severe cases the only remedy may be to remove the implants or bury them permanently beneath the mucosa. Poorly designed or constructed prostheses may need to be replaced, but in some cases this would also involve correction of the implant position. A compromise solution may therefore be sought.

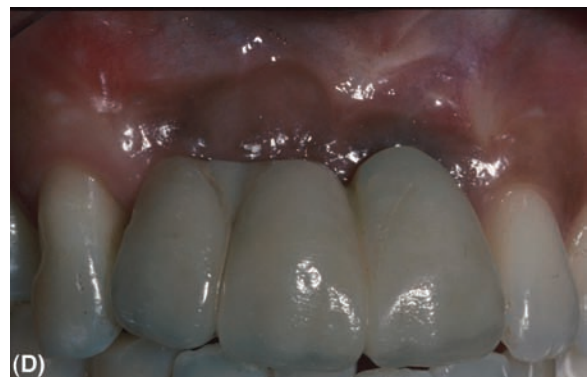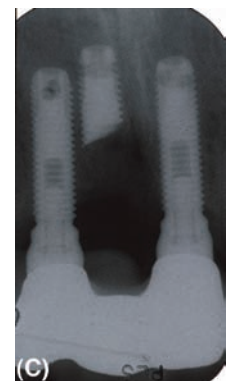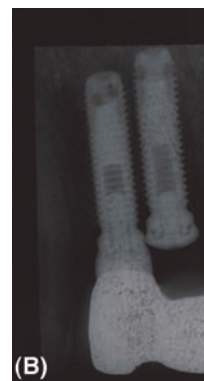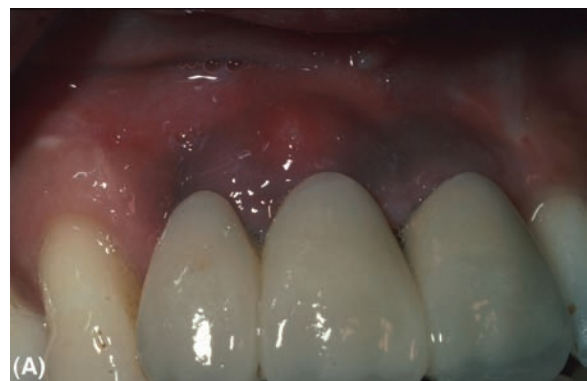### EVALUATION OF MARGINAL BONE LEVELS

It is important to establish baseline radiographs when the prosthesis is fitted. Unfortunately, the timing of baseline radiographs is not universally agreed, with some recommending a radiograph at implant placement. The frequency of subsequent radiographs is also quite contentious. It is advisable to at least repeat radiographs after one year. If there is evidence of stability of the bone levels, then subsequent radiographs could be scheduled after a further two years and with decreasing frequency in cases of radiographic stability and absence of clinical signs of inflammation. In cases where there is doubt about bone level stability, measures should be taken to ensure good plaque control, checking of the occlusion, and more frequent review. In all cases, every effort should be made to minimize radiographic distortion and produce comparable

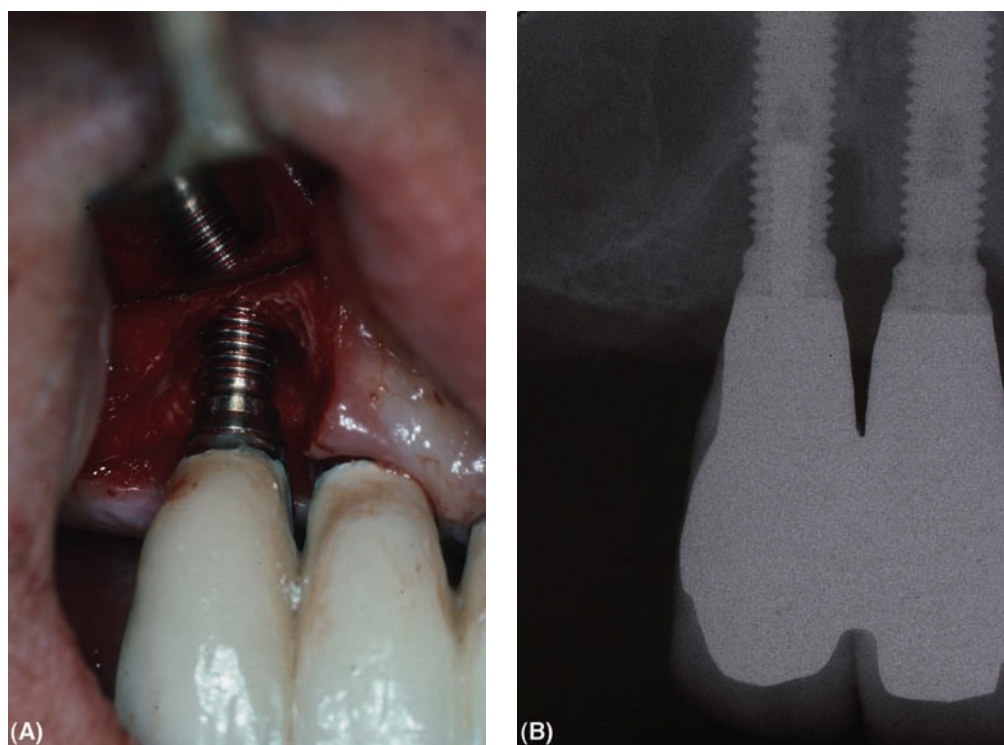


**Figure 16.17** (A) The maxillary central and lateral incisors were replaced with single tooth implants; however, loss of interdental tissue has produced a very unaesthetic result. The soft tissue defect is difficult or impossible to correct surgically. (B) The crowns have been replaced with a splinted unit bearing a pink porcelain prosthetic interidental papilla. (C) The improvement in aesthetics is shown with the patient smiling.

reproducible images to allow longitudinal assessment. Many implant systems report a small amount of bone loss/remodeling in the first year following loading, followed by a steady state in subsequent years in the majority of implants. More marginal bone loss has been reported in patients who smoke. If progressive bone loss is detected, the clinician has to decide whether this is most likely due to excessive loading or more commonly the lesion of peri-implantitis.



**Figure 16.18** (A) Clinical appearance of a three-unit implant-supported bridge replacing a maxillary right lateral incisor and both central incisors. A small soft tissue abscess is visible at the right central incisor unit. Initially three implants had been inserted to replace each of the missing teeth as single units. (B) A radiograph of the bridge shows that there is a buried unused implant beneath the right central incisor unit in very close proximity to and in intraoral communication with the implant in the right lateral incisor region. This has led to a submucosal infection at the head of the buried implant. (C) The buried implant at the right central incisor site had been deemed to be unrestorable as an individual unit and it proved impossible to remove by trephining to resolve the infection. Therefore, the coronal part of the implant was sectioned and removed, leaving the apical part in situ. (D) The healed result with resolution of the infection. The loss of soft tissue contour necessitated addition to the bridgework. The bridge was then remade. This problem could have been avoided by placement of two implants in the limited space, rather than placing three implants too close together.



**Figure 16.19** (A) A clinical photograph of a surgically exposed implant that has suffered from peri-implantitis. The inflammatory tissue has been removed to reveal bone loss that forms a circumferential gutter. (B) A radiograph of the lesion showing the wide saucerized pattern of bone loss, typical of peri-implantitis.

### Peri-Implantitis

The reported prevalence of peri-implantitis is dependent on the case definition, and is more common than was first thought. A diagnosis of peri-implantitis means that an inflammatory lesion has caused obvious bone loss (Fig. 16.19). Usually the marginal soft tissue will appear inflamed, but this is not always the case as the lesion may be deep seated. Probing depths are increased (usually 5 mm or greater) with bleeding or exudation of pus. Radiographs confirm marginal bone loss, either as a definitive loss from a defined landmark (e.g., over 2 mm from implant head) or loss of bone compared to the previous radiographic examination. It is likely that bacteria that are implicated in periodontitis, such as *Porphyromonas gingivalis*, are also the major pathogens in peri-implantitis. There is therefore a possibility of colonization or infection of the implant surfaces from preexisting periodontopathic bacteria. Therefore, implants should not be placed in patients with untreated periodontal disease. The destruction of the supporting tissues of teeth and implants has many similarities, but there are important differences due to the nature of the supporting tissues. This is particularly noticeable with the different patterns of tissue destruction observed. Peri-implantitis almost always affects the entire circumference of the implant resulting in a "gutter" of bone loss filled with inflammatory tissue extending to the bone surface, rather than site-specific lesions around tooth surfaces. It would seem probable that destructive inflammatory lesions affecting both teeth and implants have stages in which the disease process is more rapid (burst phenomenon) followed by periods of relative quiescence.

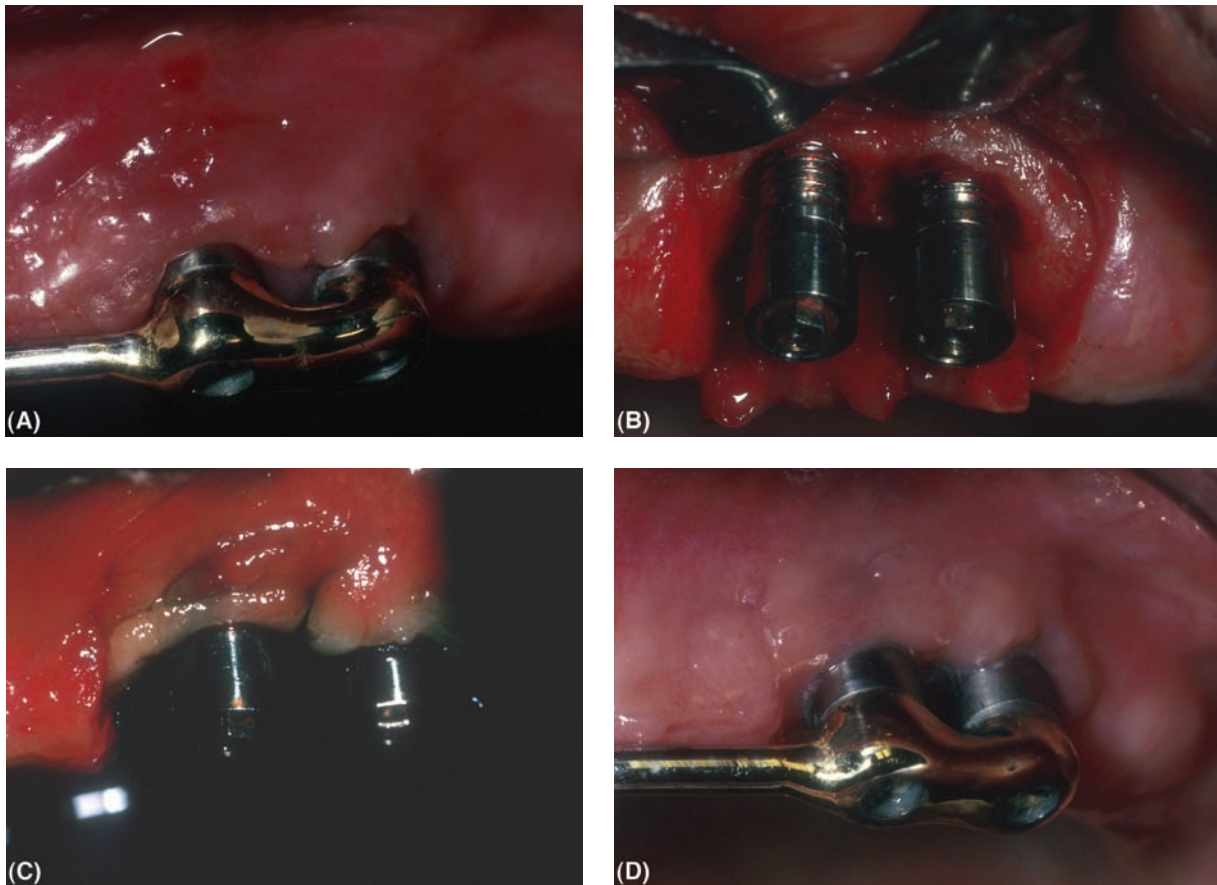
Unfortunately there have been some very polarized views as to the incidence and nature of peri-implantitis. Peri-implantitis occurs more commonly at implants with rough surfaces that allow bacterial colonization. Historically, bone loss at smoother implant surfaces was thought to be due to overload. Clearly, this simplistic distinction is false and unhelpful and is reminiscent of the debate about the importance of occlusal trauma in periodontitis. Destruction of the marginal bone in a bacterially induced peri-implantitis is more commonly reported than bone loss due to excessive forces. It should be clear that any lesion giving rise to marked bone loss should be evaluated for both bacterial and occlusal factors and treated appropriately.

Bacteria-induced factors are more likely to be implicated where there is

- poor oral hygiene;
- a history of periodontitis;
- retention of cement in the subgingival area;
- macroscopic gaps between implant components subgingivally;
- marked inflammation, exudation, and proliferation of the soft tissue;
- wide saucerized areas of marginal bone loss visible on radiographs.

Occlusal factors are more likely to be implicated in situations where there has been

- a history of parafunction;
- a history of breakages of the superstructure;



**Figure 16.20** (A) A clinical case showing marked inflammation of the soft tissue associated with peri-implantitis. (B) Surgical exposure of the affected implants reveals bone loss exposing the implant threads. (C) Following thorough debridement of the implant surfaces, the flaps have been apically repositioned and sutured. (D) The healed result showing improved soft tissue health and a more cleansable situation.

- breakages or loosening of screws;
- an angular/narrow pattern of bone loss;
- too few implants placed to replace the missing teeth;
- excessive cantilever extensions.

### MANAGEMENT OF PERI-IMPLANTITIS

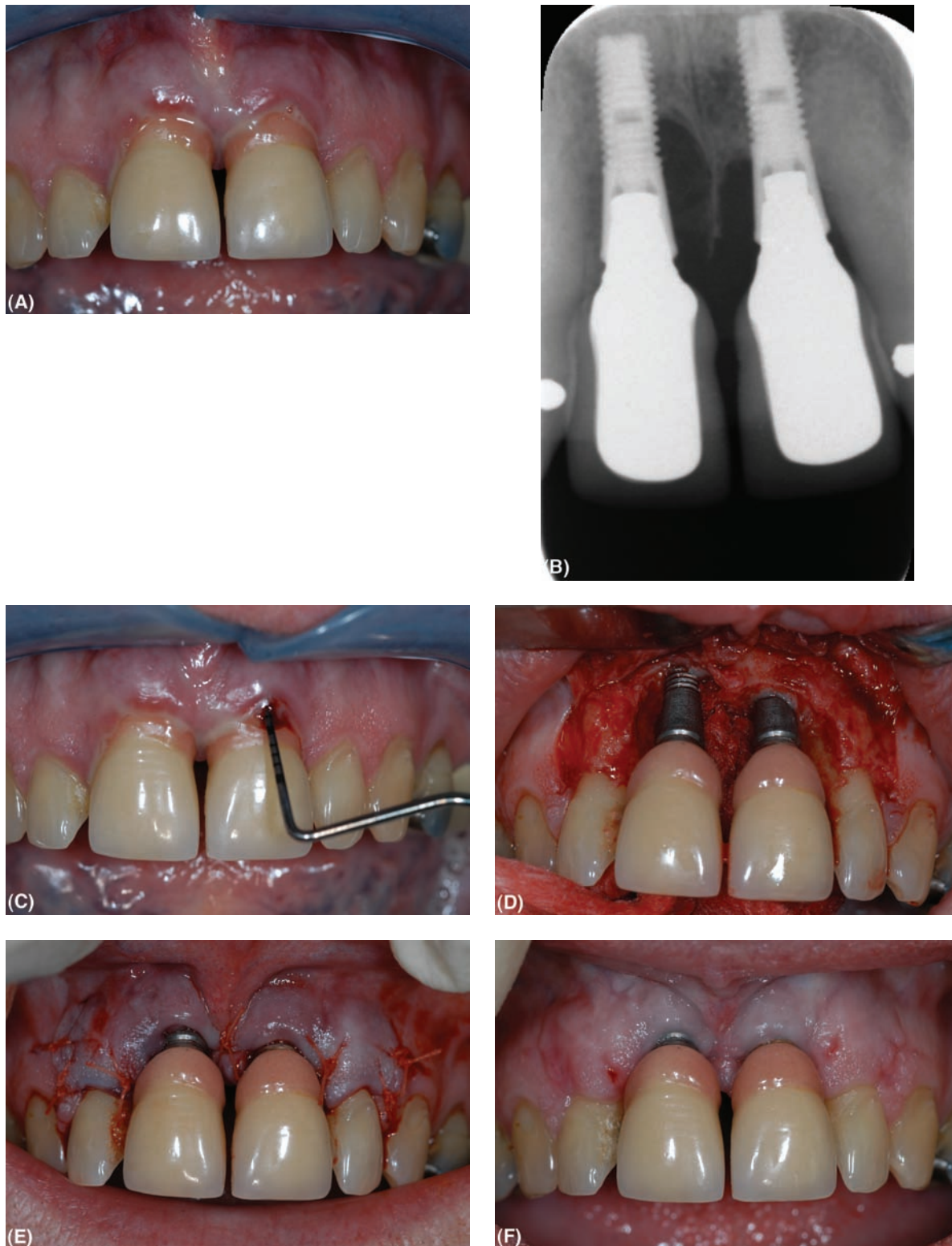Peri-implantitis is currently managed in a similar fashion to lesions of periodontitis around teeth, by improving the patient's level of plaque control, carrying out thorough sub-gingival debridement of the implant surfaces, and surgically correcting the lesion where response to the former has not been adequate. The debridement of the implant surface may be difficult due to surface roughness, presence of threads, and design of the prosthetic superstructure limiting access. It has been suggested that standard metal instruments should be avoided because of damage to the implant surface. However, as the implant surface is heavily contaminated with bacterial plaque, this suggestion is not very practical. Specifically designed curettes and ultrasonic scaler tips have been devised. Other instruments such as smooth diamond burs, titanium brushes, and lasers normally require open access afforded by surgery. During surgery, the keratinized mucosa should be preserved as much as possible, by employing an inverse bevel incision to separate it from the underlying inflammatory tissue. Following incision to bone the soft tissue flaps should be

elevated to expose normal adjacent bone. The inflammatory tissue surrounding the implant is readily removed (Figs. 16.20 and 16.21). The main difficulty is adequately disinfecting the implant surface. This is more readily accomplished on a relatively smooth surface but may be almost impossible on a very porous surface such as a titanium plasma sprayed (TPS). Therefore, rough surfaces require more extensive debridement than a smooth surface. Rougher surfaces may require removal of the contaminated layer with burs. Contaminated surfaces may be disinfected using a topical antiseptic such as chlorhexidine, detergents, or topical antibiotics. Peri-implantitis lesions are not sufficiently common to have allowed comparison of different methods of cleaning. In many cases the soft tissue inflammation can be resolved and there may be some repair of the bone. Some clinicians attempt to regenerate the lost bone using techniques such as guided bone regeneration. In cases where regenerative techniques have been used and bone fill has occurred, most research has concluded that re-osseointegration is unlikely to occur.

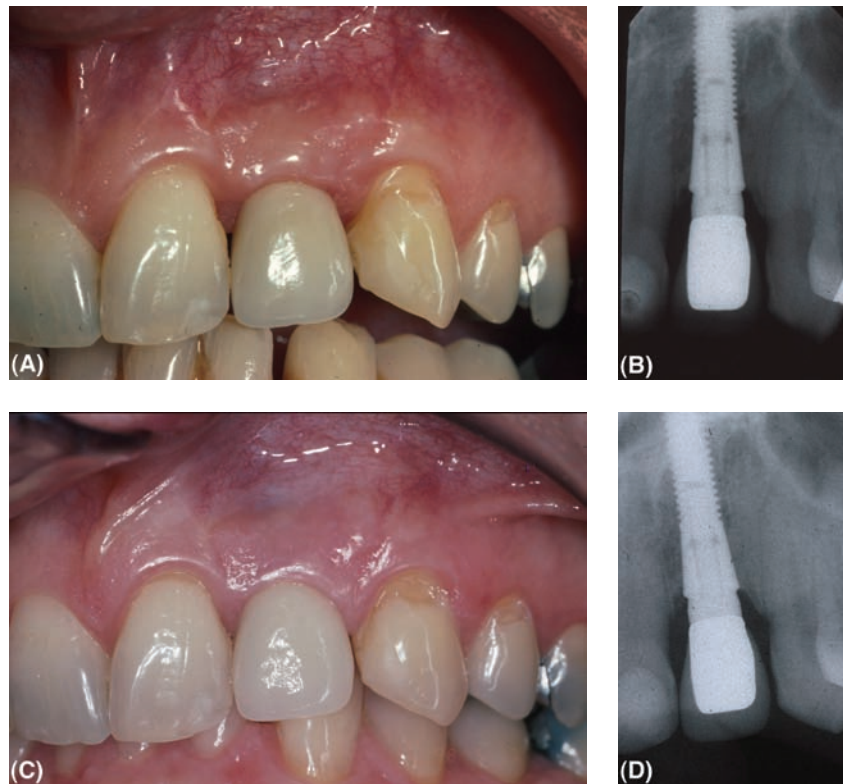
### ROUTINE HYGIENE MAINTENANCE REQUIREMENTS

#### Single Tooth Restorations

An individual with a healthy dentition and a single tooth implant replacement should have the simplest maintenance



**Figure 16.21** A series of photographs showing peri-implants affecting central incisor implants. **(A)** Both central incisors are implant-supported crowns. The patient has noticed swelling and discharge. The patient is a diabetic and has been poorly controlled. The implants were provided four years before. **(B)** The bone levels are at the top of the implant. Periodontal probing confirms a depth of at least 8 mm with pus and blood discharging. **(C)** Intraoral radiograph shows extensive bone loss associated with both implants. On the right implant, the bone loss extends over 50% of the implant length and on the left implant, to the level of the first macrothread. The saucerized bone loss is consistent with the lesion of peri-implantitis. A thin bone spur exists in the midline. **(D)** Buccal and palatal flaps have been raised and the inflammatory tissue removed to show bone loss, consistent with the radiograph. Initial cleaning of the implant surfaces has begun. Excess glass ionomer cement was noted around the abutment and implant heads. **(E)** Following thorough debridement of the implant surfaces, the soft tissue has been positioned apical to the very bulbous crowns. **(F)** The healed result two weeks after the surgery. There has been some further shrinkage of the soft tissue margin but there is no obvious inflammation and no exudate.



**Figure 16.22** A series of photographs showing long-term maintenance of a single tooth implant restoration (Astra Tech) replacing a maxillary lateral incisor. (A) Clinical appearance of the left lateral incisor unit at cementation. (B) Radiograph of the completed restoration at cementation. The bone levels are at the top of the implant. (C) The improvement of the soft tissue profile and excellent healthy appearance six years later. (D) Maintenance of bone levels at the top of the implant after six years.

requirements and few, if any, complications. The patient should be able to maintain the peri-implant soft and hard tissues in a state of health equivalent to that which exists around their natural teeth, almost without professional intervention (Fig. 16.22). This can be achieved with routine tooth brushing and flossing. However, in some circumstances, the contour of the single tooth restoration is not ideal and instead of producing a smooth readily cleansable emergence profile, poor positioning of the implant may have resulted in a degree of ridge lapping. This will require modification of oral hygiene techniques to clean under the overhanging crown morphology, with dental tape or superfloss passed or threaded under the overhang. Single tooth restorations rarely have calculus formation on their highly glazed porcelain or polished gold surfaces. Professional scaling is not therefore normally required.

### Fixed Bridges and Removable Prostheses

In patients with more complex fixed prostheses, development of readily cleansable embrasure spaces by the technician considerably facilitates patients' oral hygiene. Difficulties occur with poor implant positioning, such as placement in embrasure spaces and implants placed too close together. The selection of abutments may have a considerable impact. Smooth titanium abutment surfaces are well tolerated by the soft tissues. With cemented restorations it is advisable to limit

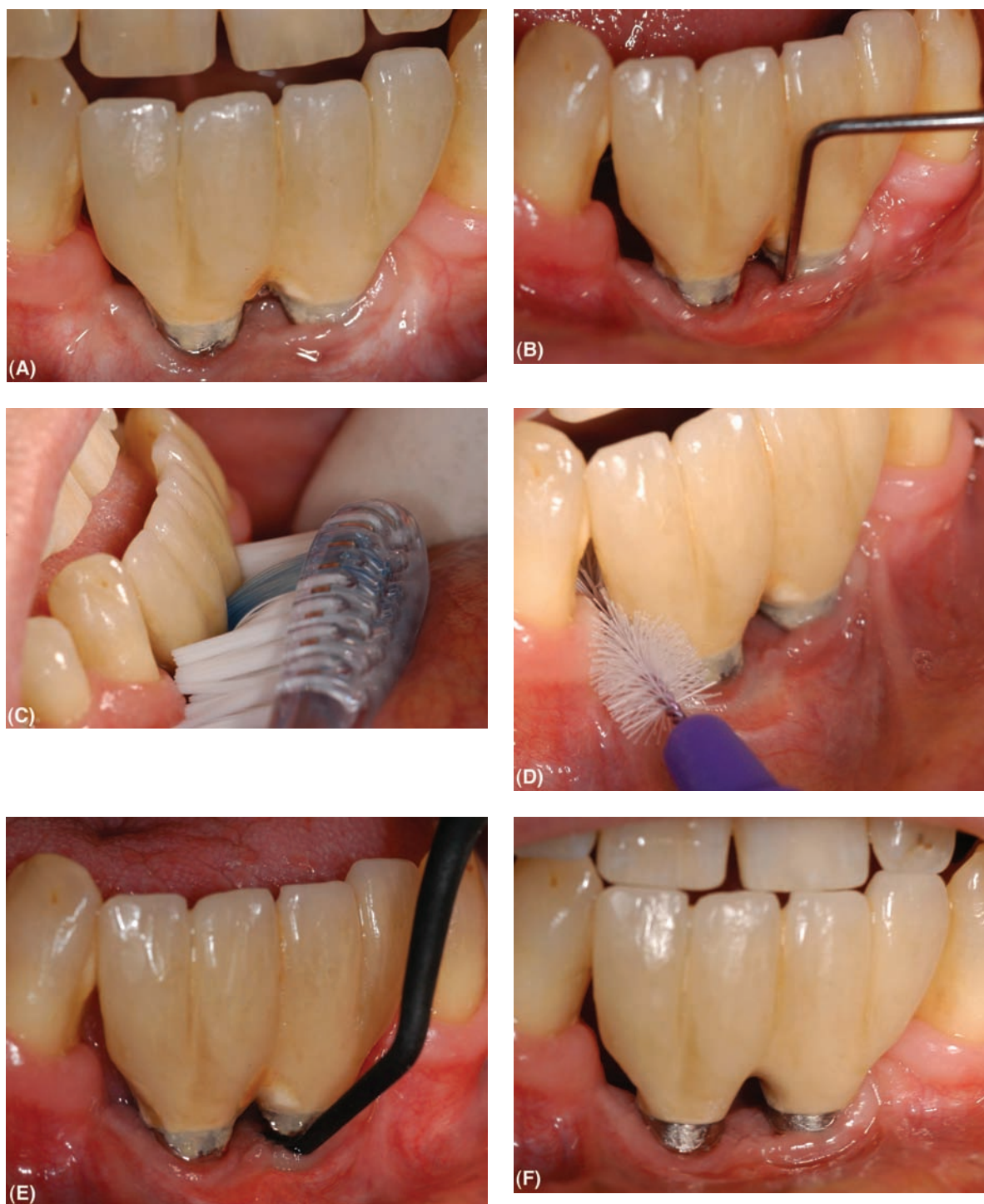the subgingival extent of the cement junction to allow easier cementation, removal of excess cement, and checking of marginal integrity.

### Scaling of Implant Prostheses

Supragingival calculus deposition is most frequently seen in implants in the anterior mandible (often on overdenture abutments), in much the same pattern as natural teeth. Calculus should be removed from titanium abutments with instruments that will not damage the surface (Fig. 16.23). Therefore, instruments are usually made of plastic/composite. In most cases where patients are treated with prostheses that have been optimized to produce good aesthetics, the abutments used are low profile with no exposure of titanium supragingivally and minimal exposure of the titanium surface subgingivally. Therefore, this problem does not arise. Steel-tipped instruments are contraindicated on titanium abutments.

### CONCLUSION

Ideally, all patients should be in a recall/maintenance program. This is particularly important in patients who have complex prostheses, where "servicing" requirements may be greater. Some patients fail to appreciate the importance of follow-up and complications may arise as a result.



**Figure 16.23** A series of photographs showing evaluation and simple maintenance procedures of a mandibular bridge. **(A)** The lower incisor teeth have been replaced with a four-unit prosthesis, supported by two implants. The apical position of the implants and the soft tissue contours made it more difficult for the patient to maintain good oral hygiene. **(B)** A periodontal probe demonstrates that the probing depths are shallow. **(C)** The patient is instructed in an effective tooth brushing regime. **(D)** The interdental spaces can be cleaned with small bottle brushes. **(E)** The supramucosal titanium abutments are cleaned with a plastic composite scaler. **(F)** The situation following careful prophylaxis.

## BIBLIOGRAPHY

- Abrahamsson I, Soldini C. Probe penetration in periodontal and peri-implant tissues. An experimental study in the beagle dog. *Clin Oral Implants Res* 2006; 17:601-605.
- Aglietta M, Siciliano VI, Zwahlen M, et al. A systematic review of the survival and complication rates of implant supported fixed dental prostheses with cantilever extensions after an observation period of at least 5 years. *Clin Oral Implants Res* 2009; 20:441-451.
- Bengazi F, Wennstrom JL, Lekholm U. Recession of the soft tissue margin at oral implants. A 2-year longitudinal prospective study. *Clin Oral Implants Res* 1996; 7:303-310.
- Berglundh T, Zitzmann NU, Donati M. Are periimplantitis lesions different from periodontitis lesions? *J Clin Periodontol* 2011; 38 (suppl 11):188-202.
- Bragger U, Aeschlimann S, Burgin W, et al. Biological and technical complications and failures with fixed partial dentures (FPD) on implants and teeth after four to five years of function. *Clin Oral Implants Res* 2001; 12:26-34.
- Davis DM, Packer ME, Watson RM. Maintenance requirements of implant-supported fixed prostheses opposed by implant-supported fixed prostheses, natural teeth, or complete dentures: a 5-year retrospective study. *Int J Prosthodont* 2003; 16:521-523.
- Dharmar S. Locating the mandibular canal in panoramic radiographs. *Int J Oral Maxillofac Implants* 1997; 12:113-117.
- Ellegaard B, Baelum V, Karring T. Implant therapy in periodontally compromised patients. *Clin Oral Implants Res* 1997; 8:180-188.
- Esposito M, Grusovin MG, Coulthard P, et al. Interventions for replacing missing teeth: treatment of perimplantitis. *Cochrane Database Syst Rev* 2010; (6):CD004970.
- Esposito M, Hirsch JM, Lekholm U, et al. Differential diagnosis and treatment strategies of biologic complications and failing oral implants. *Int J Oral Maxillofac Implants* 1999; 14:473-490.
- Fransson C, Wennstrom J, Berglundh T. Clinical characteristics at implants with a history of progressive bone loss. *Clin Oral Implants Res* 2008; 19:142-147.
- Heitz-Mayfield LJ, Salvi GE, Botticelli D, et al. Anti-infective treatment of periimplant mucositis: a randomised controlled clinical trial. *Clin Oral Implants Res* 2011; 22:237-241.
- Isidor F. Loss of osseointegration caused by occlusal overload of oral implants. *Clin Oral Implants Res* 1996; 7:143-152.
- Isidor F. Histological evaluation of periimplant bone at implants subjected to occlusal overload or plaque accumulation. *Clin Oral Implants Res* 1997; 8:1-9.
- Jung RE, Pjetursson BE, Glauser R, et al. A systematic review of the 5-year survival and complication rates of implant-supported single crowns. *Clin Oral Implants Res* 2008; 19:119-130.
- Lekholm U, Sennerby L, Roos J, et al. Soft tissue and marginal bone conditions at osseointegrated implants that have exposed threads: a 5 year retrospective study. *Int J Oral Maxillofac Implants* 1996; 11:599-604.
- Mann M, Parmar D, Walmsley AD, et al. Effect of plastic-covered ultrasonic scalers on titanium implant surfaces. *Clin Oral Implants Res* 2011. DOI: 10.1111/j.1600-0501.2011.02186.x.
- Mombelli A, Feloutzis A, Bragger U, et al. Treatment of peri-implantitis by local delivery of tetracycline. Clinical, microbiological and radiological results. *Clin Oral Implants Res* 2001; 12:287-294.
- Persson LG, Berglundh T, Lindhe J, et al. Re-osseointegration after treatment of peri-implantitis at different implant surfaces. An experimental study in the dog. *Clin Oral Implants Res* 2001; 12:595-603.
- Persson LG, Ericsson I, Berglundh T, et al. Guided bone regeneration in the treatment of peri-implantitis. *Clin Oral Implants Res* 1996; 7:366-372.
- Persson LG, Lekholm U, Leonhardt A, et al. Bacterial colonization on internal surfaces of Branemark system implant components. *Clin Oral Implants Res* 1996; 7:90-95.
- Pjetursson BE, Bragger U, Lang NP, et al. Comparison of survival and complication rates of tooth-supported fixed dental prostheses (FDPs) and implant-supported FDPs and single crowns (SCs). *Clin Oral Implants Res* 2007; (suppl 3):97-113.
- Quirynen M, Bollen CM, Eyssen H, et al. Microbial penetration along the implant components of the Branemark system. An in vitro study. *Clin Oral Implants Res* 1994; 5:239-244.
- Quirynen M, Peeters W, Naert I, et al. Peri-implant health around screw-shaped c.p. titanium machined implants in partially edentulous patients with or without ongoing periodontitis. *Clin Oral Implants Res* 2001; 12:589-594.
- Quirynen M, Vogels R, Alsaadi G, et al. Predisposing conditions for retrograde peri-implantitis, and treatment suggestions. *Clin Oral Implants Res* 2005; 16:599-608.
- Rangert B, Krogh PH, Langer B, et al. Bending overload and implant fracture: a retrospective clinical analysis. *Int J Oral Maxillofac Implants* 1995; 10:326-334.
- Renvert S, Lindahl C, Renvert H, et al. Clinical and microbiological analysis of subjects treated with Branemark or AstraTech implants: a 7-year follow-up study. *Clin Oral Implants Res* 2008; 19:342-347.
- Renvert S, Lindahl C, Roos-Jansaker AM, et al. Treatment of peri-implantitis using an Er:YAG laser or an air-abrasive device: a randomized clinical trial. *J Clin Periodontol* 2011; 38:65-73.
- Renvert S, Persson GR. Periodontitis as a potential risk factor for peri-implantitis. *J Clin Periodontol* 2009; 36(suppl 10):9-14.
- Renvert S, Polyzois I, Maguire R. Re-osseointegration on previously contaminated surfaces: a systematic review. *Clin Oral Implants Res* 2009; 20(suppl 4):216-227.
- Renvert S, Roos-Jansaker AM, Claffey N. Non-surgical treatment of peri-implant mucositis and peri-implantitis: a literature review. *J Clin Periodontol* 2008; 35:305-315.
- Romeo E, Ghisolfi M, Murgolo N, et al. Therapy of peri-implantitis with resective surgery. A 3-year clinical trial on rough screw-shaped oral implants. Part I: clinical outcome. *Clin Oral Implants Res* 2005; 16:9-18.
- Romeo E, Lops D, Chiapasco M, et al. Therapy of peri-implantitis with resective surgery. A 3-year clinical trial on rough screw-shaped oral implants. Part II: radiographic outcome. *Clin Oral Implants Res* 2007; 18:179-187.
- Roos-Jansaker AM, Lindahl C, Persson GR, et al. Long-term stability of surgical bone regenerative procedures of peri-implantitis lesions in a prospective case-control study over 3 years. *J Clin Periodontol* 2011; 38:590-597.
- Salvi GE, Persson GR, Heitz-Mayfield LJ, et al. Adjunctive local antibiotic therapy in the treatment of peri-implantitis II: clinical and radiographic outcomes. *Clin Oral Implants Res* 2007; 18:281-285.
- Schwarz F, Sahm N, Iglhaut G, et al. Impact of the method of surface debridement and decontamination on the clinical outcome following combined surgical therapy of peri-implantitis: a randomized controlled clinical study. *J Clin Periodontol* 2011; 38:276-284.
- Schwarz F, Sahm N, Schwarz K, et al. Impact of defect configuration on the clinical outcome following surgical regenerative therapy of peri-implantitis. *J Clin Periodontol* 2010; 37:449-455.
- Teughels W, Van AN, Sliepen I, et al. Effect of material characteristics and/or surface topography on biofilm development. *Clin Oral Implants Res* 2006; 17(suppl 2):68-81.
- van Steenberghe D, Klinge B, Linden U, et al. Periodontal indices around natural and titanium abutments: a longitudinal multicentre study. *J Periodontol* 1993; 64:538-541.

## Prosthodontic complications of implant treatment and maintenance of implant overdentures

This chapter will describe prosthodontic complications and the postinsertion maintenance of the completed implant dentures. Complications may occur before, during, and after the prosthodontic phase of implant treatment; maintenance and repairs of the dentures and components will be required after the overdentures are fitted. Various studies have shown different results for the maintenance requirements for implant overdentures. There is also conflicting evidence on whether implant overdentures require more or less maintenance than fixed restorations.

### COMPLICATIONS BEFORE THE PROSTHODONTIC PHASE OF TREATMENT Placement of implants in an Unplanned Position

Implants may be inadvertently placed in an unplanned buccopalatal or buccolingual position, in an unplanned mesiodistal position, at an unplanned angulation, or at an unplanned depth. Situations such as these are reduced when a stent is used but may still occur even when a stent is used if there are unexpected findings during surgery. Nonparallel placement is also more likely in post cancer surgery patients, where availability of suitable and appropriate bone is the deciding factor.

Minor changes from the intended implant position or angulation can usually be accommodated within an overdenture, although an alternative attachment mechanism may have to be used, for instance, a shorter ball attachment or Locator<sup>®</sup> may be needed (Fig. 17.1). All manufacturers provide a choice of sizes and these have been described in chapter 6.

Deviations from the intended implant position will create an abnormal contour in the finished denture. This may be uncomfortable for the patient, may cause speech difficulties, or even soft tissue proliferation (Figs. 17.2 and 17.3).

Where an implant has been placed too superficially, there may be insufficient space for the prosthodontic components to be contained within the normal contour of the proposed denture. Even when there is sufficient bulk of acrylic resin, and a bar/clip system is planned, the resulting bar may be several millimeters away from the mucosa (Fig. 17.4). While this in itself is only critical when short implants are used and the leverage is increased under loading, the amount of so-called dead space is increased and there may be tissue overgrowth beneath the bar.

Where several implants have been placed too close together, there may be insufficient space for clips between them. In such situations, cantilever extensions may be necessary but the clips are more likely to fracture or be pulled out of the resin.

### Failure of Integration of One or More Implants

One or more implants may fail to integrate prior to the commencement of implant overdenture construction, leaving remaining implants in an unfavorable distribution. In the maxilla, the normal recommendation is that a minimum of four implants should be placed. If one or two should fail, an implant denture can still be made but the risks of overload are higher, particularly where there are opposing teeth in the mandible. If the remaining implants are unilateral, the stability of the implant denture will suffer (Fig. 17.5).

In these situations, further implants should be placed to achieve the planned implant distribution. A transitional denture can be constructed but the risks of overloading the remaining implants must be considered.

### Failure of Bone Graft Preventing Implant Placement

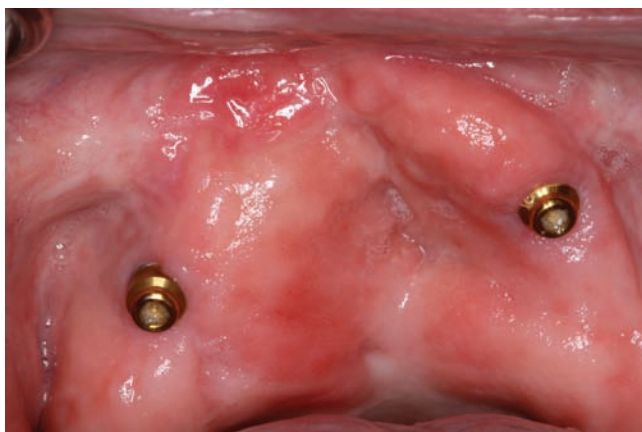
If this happens, it is possible to repeat the procedure but, in our experience, the patients have usually decided to remain with a conventional denture. A new denture is usually required because of the inevitable change of contour of the residual ridge after the surgery and, more problematically, because of the change of sulcus elasticity due to scarring.

### COMPLICATIONS DURING THE PROSTHODONTIC PHASE OF TREATMENT

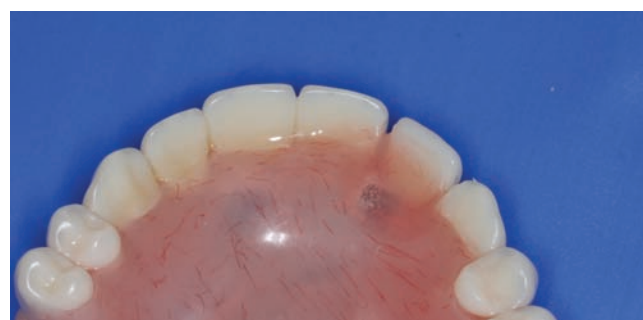Complications include fracture of the existing denture after removal of acrylic resin to allow for the temporary soft lining, and loosening and damage to healing abutments (Fig. 17.6). Existing cobalt-chromium-based dentures, even when widely cut away, are particularly hard on healing abutments, ball attachments, or standard abutments that remain in the mouth during the prosthodontic phase of treatment. It is always preferable to have an acrylic resin-based denture, especially as soft lining materials adhere more securely.

Opposing teeth may damage healing abutments, standard abutments, or ball attachments, particularly when a shearing or glancing contact is possible. This possibility must be taken into consideration during planning stages, even to the extent of changing the retention system so that such contacts are vertical onto a flat surface away from a screw head. Where ball attachments are unavoidable, a soft acrylic mouthguard can be made for nighttime wear.

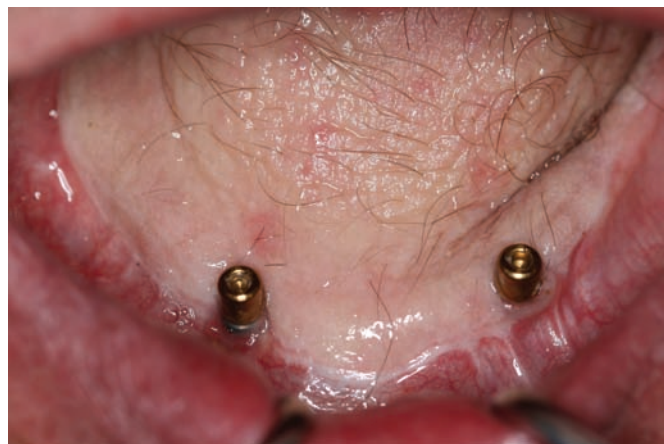Where a cast bar/clip system is being used, it is advisable to try the bar in the mouth before the denture is finished. If the bar does not fit, it should be checked on the working cast. If it does not fit the working cast, it should be cut and



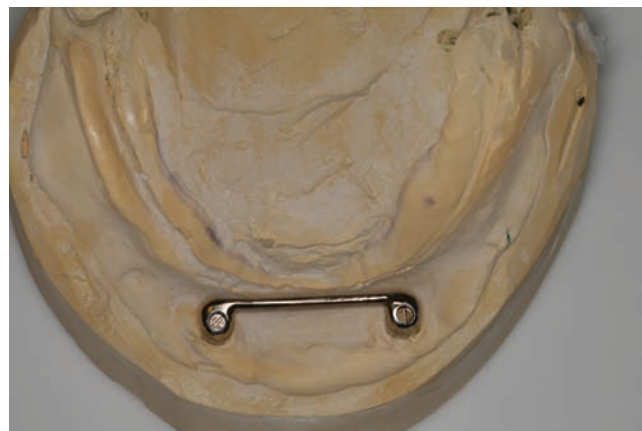**Figure 17.1** Implants placed too buccally. This will result in the prosthetic component not being in the thickest part of the denture, which lead to show through of the component or fracturing of the overlying thin acrylic.



**Figure 17.3** Completed denture with unfavorable contour. The palatal positioning of the implants will result in the denture having acrylic bulge to ensure that the components are within acrylic.



**Figure 17.2** Implant placed in grafted bone. The implant on the left was placed in sufficient bone but in a region without keratinized tissue resulting in mucosal inflammation.

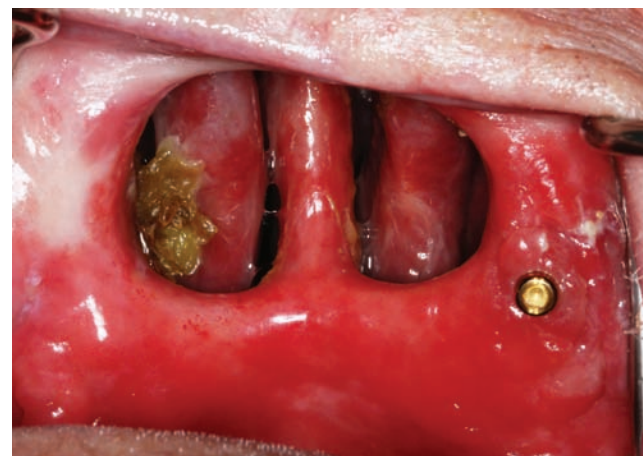

**Figure 17.4** Labial placement of the bar necessitating soldering the bar to the lingual surface of gold alloy cylinders to ensure that the clips are placed in the thickest portion of the denture.

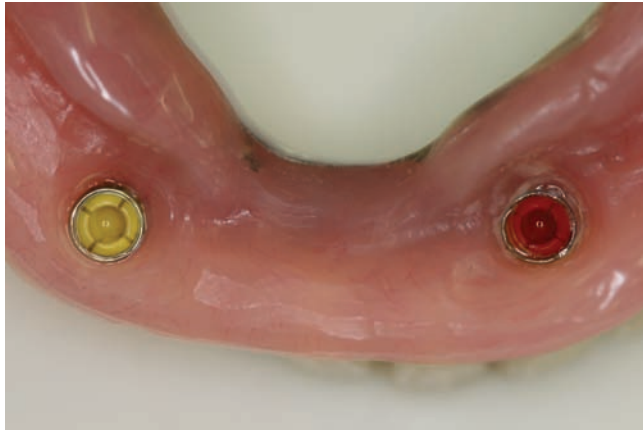resoldered, or remade, prior to trying it in the mouth again. If the bar fits the cast but not the mouth, the cast must be at fault and a new final impression will be required.

#### Dentures Unable to Be Inserted Over Ball Attachments

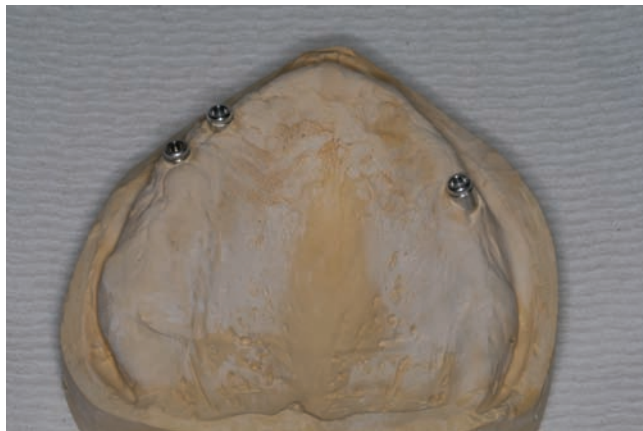If one of the laboratory analogues was not inserted precisely into the impression, the error in the working cast may prevent the completed denture from being inserted (Fig. 17.7). In such



**Figure 17.5** Failure of an implant on the right maxillary premolar region, leaving only one implant in the upper left premolar region with a Locator® abutment. The maxillary obturator is still reasonably stable.



**Figure 17.6** The yellow clip is in good condition, the red clip shows signs of damage to not only the plastic insert but also the metal housing.



**Figure 17.7** The Locator replica in the maxillary canine has moved, an error either in attaching the replica to the coping or the replica moved when pouring the model.

situations, retention caps can be removed and reattached using autopolymerizing resin in an intraoral procedure.

## POSTINSERTION COMPLICATIONS AND MAINTENANCE

### Failure of Integration of One or More Implants

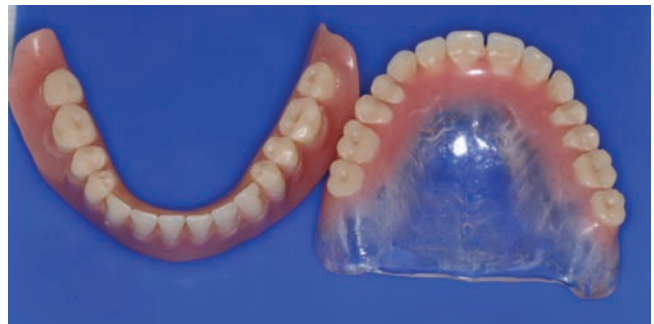In common with most published studies, our experience has been that this is very rare in the mandible. Some failures in the maxilla should be expected, particularly in smokers and where there are opposing natural teeth. Where a bar is the retention system, the bar will need to be unscrewed to remove the failed implant and then sectioned to reduce its length unless the failed implant is between two other quite close implants. The latter situation is quite unusual as most failures tend to be the most distal implants.

### Fracture of Ball Attachment or Implant

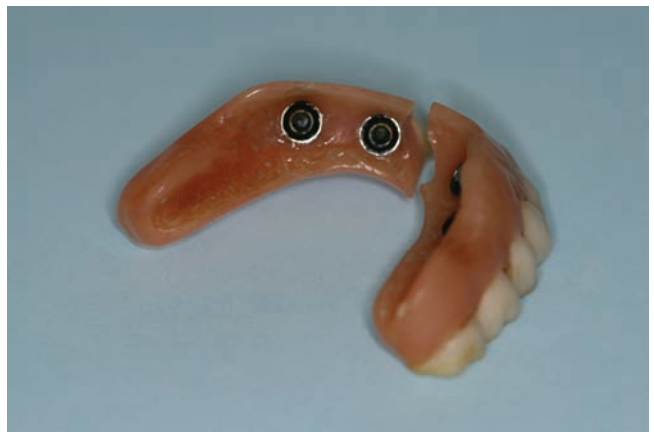Fractures of ball attachments may occur when they oppose natural teeth. The remaining portion of fractured ball attachment can be unscrewed with a dental explorer or the manufacturer may provide a "rescue kit." In extremis, the portion can be drilled out but it is difficult to avoid damaging the internal implant threads. The Nobel Biocare rescue kit comes with miniature taps to tidy up the internal thread and should probably be used whenever one of their damaged components is removed.

### Fracture or Wear of Denture and Components

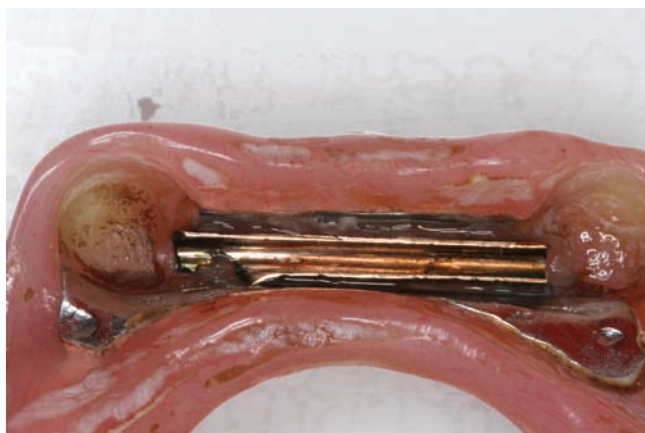
Once implant overdentures have been made, some patients appear to increase the force exerted upon the dentures during mastication or possibly parafunction. Although the implants may be able to withstand these forces, the prosthodontic components and the denture itself are more vulnerable. Complications include excessive wear of the occlusal surfaces of the teeth (Fig. 17.8), perforation and fracture of denture base material (Fig. 17.9), fracture of denture teeth, fracture of clips, dislodgement of clips from acrylic resin, wear and



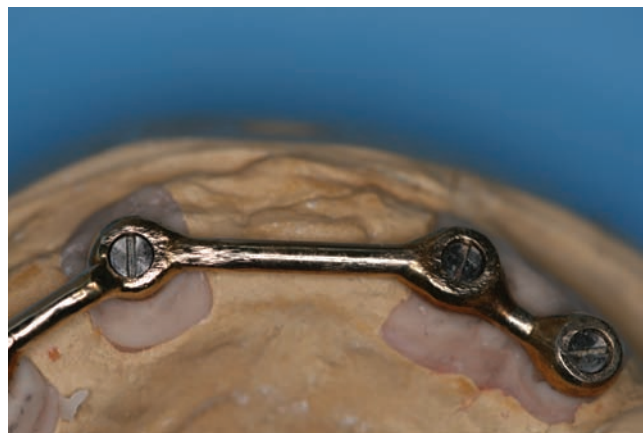**Figure 17.8** Excessive occlusal wear on implant overdentures after three years of use.



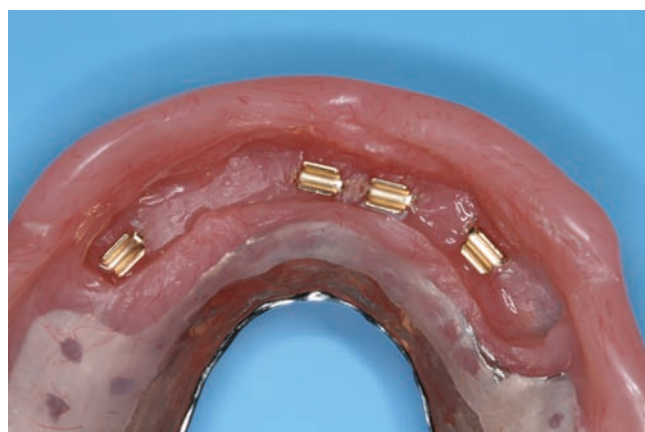
**Figure 17.9** A midline fracture of a maxillary overdenture after five years of use. There was a clean break allowing for a simple laboratory repair.



**Figure 17.10** A fractured gold Dolder® clip in a mandibular overdenture.



**Figure 17.12** A worn Astra Tech gold round bar.



**Figure 17.11** A mandibular overdenture in which one gold clip had dislodged from the acrylic base.

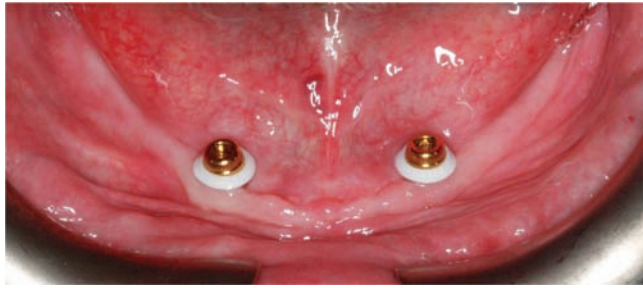fracture of ball attachment matrices, and wear of bars (Figs. 17.10–17.12). Ball or locator components can be replaced using cold-cure acrylic resin as an intraoral procedure with relative ease. There is little chance of “cold curing” the denture onto the abutments. But extreme care is needed when replacing clips with such an intraoral procedure; it is essential to avoid the acrylic flowing under the bar. This can be achieved by blocking out under the bar with wax. It is also advisable to use a small amount of acrylic initially to merely pick up the clip and add more acrylic around the clip to fill in any voids. In cases where multiple clips need to be replaced, it is best to replace one clip at a time. However, in these situations it may be prudent to remove the bar and have the clips attached in the laboratory.

The Ti-alloy matrix available from Nobel Biocare and Straumann consists of three parts: a retention part that is embedded in the acrylic resin of the denture, a stainless steel

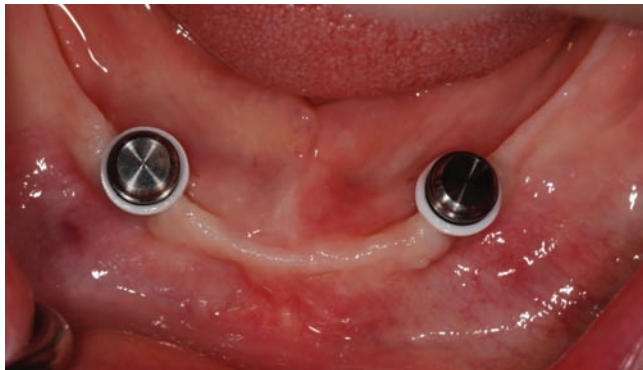

**Figure 17.13** (A) A Straumann ball abutment matrix screwdriver. The screwdriver removes the cover of the matrix giving access to the circlip. This allows the circlip to be changed without drilling the matrix out of the overdenture base. (B) A Straumann titanium matrix that has been unscrewed and the broken circlip has been removed.

circlip, and a removable cover for the circlip. If the circlip needs replacing, the cover can be unscrewed to allow replacement of the circlip without disturbing the retention part (Fig. 17.13).



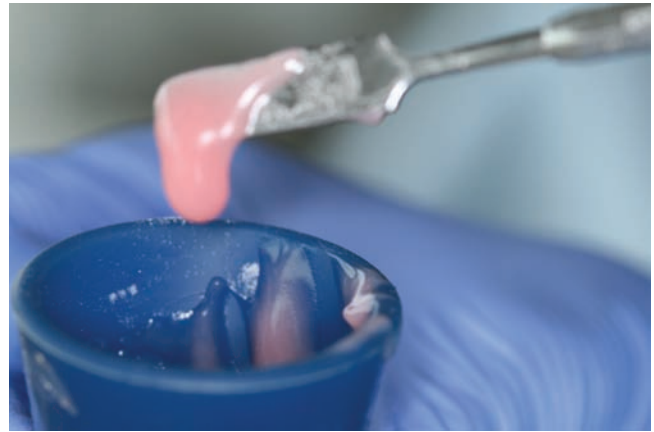**Figure 17.14** Chairside insertion of the Locator housing cap. The white O rings are placed over the Locator abutments to prevent acrylic flowing below the housing caps.



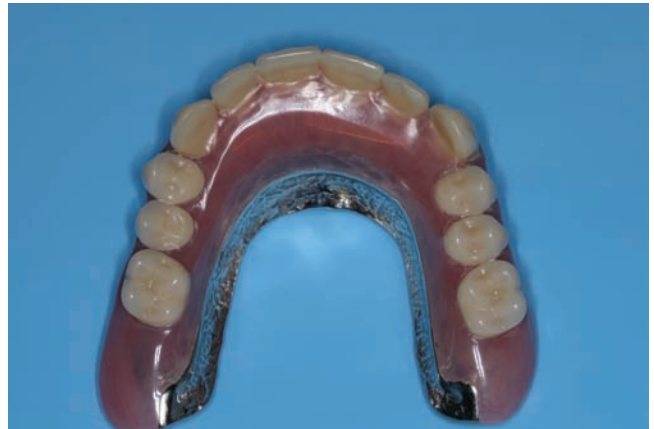**Figure 17.15** The Locator housing caps are snapped onto the abutments. The denture is adjusted to ensure that the caps do not prevent the denture from fully seating.

The Locator system has color-coded nylon inserts; the three standard inserts are blue, pink, and clear that are in order of increasing retention. The core locator tool can be used to remove and replace the inserts. There are two nonstandard inserts red and the more retentive green that are used when there is greater angulation of the implants. The inserts can also be removed with a sharp probe. If the locator housing needs to be replaced, this can easily be done chairside. A white washer is placed over the locator abutment and the new housing caps are placed on (Fig. 17.14). The old housing caps are drilled out of the dentures and the denture is tried in to ensure the denture has sufficient clearance of the new caps (Fig. 17.15). Autopolymerizing acrylic is mixed and placed inside the denture, the denture is inserted and the patient is asked to close mouth until the acrylic has set (Fig. 17.16). The denture is removed and any excess acrylic is trimmed back, the black laboratory insert is removed and a new insert is placed. It is common to start with the least retentive insert, which is the blue.

Cobalt-chromium alloy bases can be used to prevent excessive wear of acrylic resin, particularly when opposing crowned teeth (Fig. 17.17) and also to prevent fracture of the



**Figure 17.16** Autopolymerized acrylic is mixed to a relatively thick consistency and inserted into the overdenture. A closed mouth technique is used. Once the acrylic has set, the overdenture is removed, any excess acrylic trimmed. The black insert can be left for a few weeks or an active nylon insert can be placed immediately.



**Figure 17.17** A cobalt-chromium-based maxillary overdenture with the palate cut out.

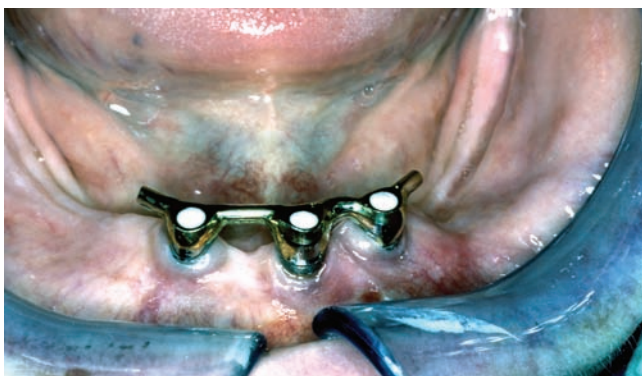base when this has been reduced in patients who have a strong gag reflex.

### Continued Bone Resorption

Where there is evidence of continued bone resorption in the edentulous areas away from the implants, implant dentures can be relined or a new overdenture may be indicated.

### Overgrowth of Mucosa Under Bar

Overgrowth of mucosa beneath a bar can be surgically removed if its presence causes discomfort or difficulty with cleaning (Fig. 17.18).



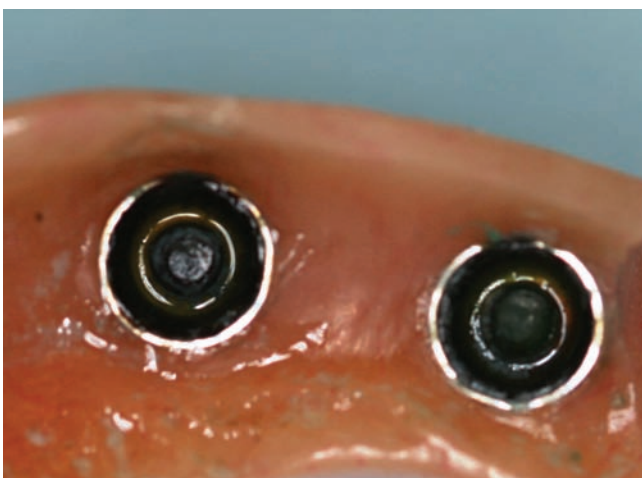
**Figure 17.18** Gingival overgrowth under a bar makes cleaning under the bar difficult and painful. The overgrowth can be surgically excised. The minor overgrowth at the implant abutment on the patient's lower right may reduce with better cleaning.

### Difficulty with Speech

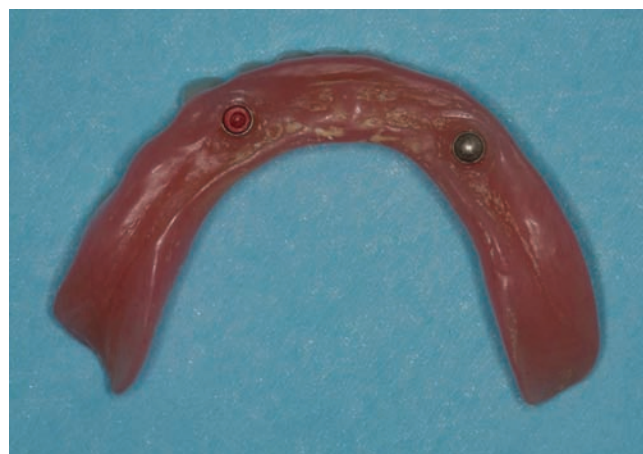This is not uncommon with maxillary dentures where the palatal contour is bulky to accommodate a cast bar and clip system, this is less likely if a milled bar has been used where 3D software has been used in the design of the bar based on the denture try-in stage. If the patient cannot get used to the new contour after several weeks, a different retention system such as ball attachments or Locators may have to be considered.

### MAINTENANCE SCHEDULE

After all normal postinsertion adjustments have been carried out and the patient is comfortable with the new implant dentures, the patient should be seen at least once per year for review. The patient should be asked to make contact immediately if there are any sudden changes such as loosening of a bar or attachment or loosening of the dentures. The latter may indicate fracture of a clip or matrix, or deterioration of an insert in an attachment retainer (Figs. 17.19 and 17.20).



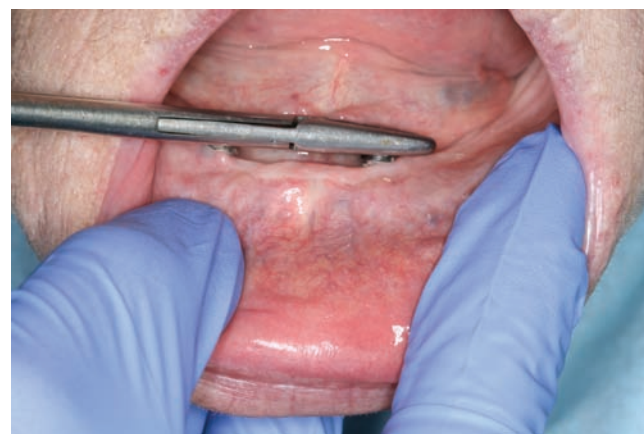**Figure 17.19** A blue nylon Locator<sup>®</sup> insert that shows signs of wear and tear after two years of use. The inserts are easily removed and new inserts replaced using the Locator core tool.



**Figure 17.20** A lost metal housing from a denture is more likely to occur when the housing has been added chairside.

At the annual visit, dentures should be tested for stability on the mucosa and any rocking diagnosed, for example, bone resorption or wear or fracture of a prosthodontic component. Attachments should be checked for tightness using the appropriate screwdriver. Bars should be removed and individual abutments checked for tightness and implants for any mobility. With the bar off, any calculus can be easily removed from the abutments and bar itself with a plastic instrument. The attachment retainers in the dentures should be inspected for any fractures of the tines or deterioration of nylon inserts. Clips in dentures should be checked for any fractures or looseness in the resin.

Attachment retainers or clips can be replaced as an intraoral procedure as mentioned earlier. Replacement of the intraoral implant components is unfortunately not a simple matter of unscrewing the worn part and replacing with a new part. The torque drive for ball abutments will not engage an abutment that has become worn. In this situation, artery forceps may need to be used to remove the worn attachment (Fig. 17.21).



**Figure 17.21** Artery forceps can be used to remove worn ball abutments when their retentive drivers do not engage them. Care must be exercised to prevent any soft tissue being caught in the forceps or fracturing any part of the abutment.

The implants themselves should be radiographed using the same view, otherwise any changes may not be detected. Where changes are visible, overloading may be responsible and it may be reexamining the occlusion. The denture teeth can be adjusted to reduce any potential overloading where necessary. Implants supporting overdentures are also susceptible to peri-implantitis and require appropriate management (see chap. 16).

## BIBLIOGRAPHY

- Batenburg RH, Meijer HJ, Geraets WG, et al. Radiographic assessment of changes in marginal bone around endosseous implants supporting mandibular overdentures. *Dentomaxillofac Radiol* 1998; 27:221–224.
- Chan MFW-Y, Johnston C, Howell RA. A retrospective study of the maintenance requirements associated with implant stabilized mandibular overdentures. *Eur J Prosthodont Rest Dent* 1996; 4:39–43.
- Davis DM, Packer ME. The maintenance requirements of mandibular overdentures stabilized by Astra Tech implants using three different attachment mechanisms balls, magnets, and bars; 3-year results. *Eur J Prosthodont Restor Dent* 2000; 8:131–134.
- Gotfredsen K, Holm B, Sewerin I, et al. Marginal tissue response adjacent to Astra Dental Implants supporting overdentures in the mandible. *Clin Oral Implants Res* 1993; 4:83–89.
- Hemmings KW, Schmitt A, Zarb GA. Complications and maintenance requirements for fixed prostheses and overdentures in the edentulous mandible: a five year report. *Int J Oral Maxillofac Implants* 1994; 9:191–196.
- Mericske-Stern R, Steinlin Schaffner T, Marti P, et al. Peri-implant mucosal aspects of ITI implants supporting overdentures. A five-year longitudinal study. *Clin Oral Implants Res* 1994; 5:9–18.
- Watson RM, Davis DM. Follow up and maintenance of implant supported prostheses: a comparison of 20 complete mandibular overdentures and 20 complete mandibular fixed cantilever prostheses. *Br Dent J* 1996; 181:321–327.
- Watson RM, Jemt T, Chai J, et al. Prosthodontic treatment, patient response, and the need for maintenance of complete implant-supported overdentures: an appraisal of 5 years of prospective study. *Int J Prosthodont* 1997; 10:345–354.
- Wright PS, Glantz PO, Randow K, et al. The effects of fixed and removable implant-stabilised prostheses on posterior mandibular residual ridge resorption. *Clin Oral Implants Res* 2002; 13:169–174.

# Index

Page numbers followed by f and t indicate figures and tables, respectively.

- Abutments, 121, 122t
  - ceramic, 132
  - computer-generated, 130–132
  - customized, 125
  - fully customized gold, 129–130
  - index/location of, 155
  - prepable, 132–136
  - protection caps, 156f
  - for screw-retained crowns, 137
  - selection of, 181
  - selection of height, 122f
  - semiprepared, 125–129
  - standard, 121–126, 127f
  - try-in kits, 160–161
  - used for fixed restorations, 155t
  - zirconia, 134f
- Abutment connection surgery
  - flap design for, 65–68, 67f–68f
- Abutment impression copings, 122f, 142f, 157f, 163f
- Abutment impressions, 137
- Abutments, types of
  - for cemented bridges
    - customized abutments, 156, 160
  - for screw-retained bridges
    - angled abutments, 155
- Abutment selection and impressions
  - abutment try-in kits, 160–161
  - evaluation using a diagnostic workup, 160
  - implant head impressions, 160
- Abutment selection and seating
  - for cemented restorations
    - impression verification for all techniques, 165
  - for screw-retained bridges, 161–162
    - impression materials, 162–163
    - impression trays, 162
    - pick-up impressions (open tray technique), 163
    - reseating impressions (closed tray technique), 163, 165
- Acrylic, 172
  - autopolymerized, 212f
- Acrylic linkage (in Duralay), 173f
- Adhesive bridgework, 28–29
- Allogenic grafts, 91, 92
  - for implant placement, 91, 92
- Alloplastic grafts, 91, 92
  - materials, for implant placement, 91, 92
- Alveolar defects, large
  - surgical management of, 102, 102f, 103f–104f
- Anesthesia
  - and implant surgery, 61–62
- Angular cheilitis, 48, 48f
- Angulation, of implant site, 80–81, 81f
  - fixed bridge and, 39–43, 41f–43f
- Articulating paper, 174f
- Astra Tech, 51–52, 52f–54f, 122f
  - ball attachment, 52, 52f
  - gold cap, 52, 53f
  - implants, 70f–71f, 78f, 79f, 126f, 151f, 154f, 157f
  - replacement of maxillary canine with, 23f, 24f
  - single 5-mm diameter, replacement of
    - mandibular molar with, 33f
  - ST implant, 136f, 146f
- Autogenous bone grafts, for implant placement, 91, 93–102, 94f, 95f, 96f–97f, 98f–99f, 100f
- Autogenous grafts, 91
- Autopolymerized acrylic, 212f
- Biocompatibility, 4
- Bio-Oss<sup>®</sup>, for implant placement, 92
- Bleeding disorders
  - in dental implants, 4
- Blue nylon Locator<sup>®</sup> insert, 213f
- Bone
  - cells, and implant surgery, 57
  - factors, 11
  - grafting, surgical guide for, 50f
  - loss, 204f
- Bone grafts materials, for implant placement, 91–92
  - allogenic grafts, 91, 92
  - alloplastic grafts, 91, 92
  - autogenous grafts, 91
  - deproteinized bovine bone mineral, 92
  - xenografts, 91, 92
- Bone levels, evaluation of marginal, 200–201
  - peri-implantitis, 202–203
- Bone loss
  - radiographic, 1
- Branemark concept, 59
- Bridges
  - cementation, 175
  - follow-up, 175
  - immediate restoration of multiple implants, 176
  - instructions to the patient, 175
  - joining teeth and implants, 175
  - occlusion, 174–175
  - placement, 173–174
  - provisional, 168
  - screw tightening, 175
  - try-in, 173
- Bridge prosthodontics, fixed
  - cemented bridges, 149, 151–152
    - advantages, 155
    - disadvantages, 155
  - distal cantilevers, 149
  - occlusal records, 165, 168
  - screw-retained, 149, 151–152
    - advantages of, 152
    - disadvantages of, 152
  - short-span and long-span bridges, 149
- Bridges, construction
  - laboratory procedures, 168, 170–171
  - materials, 171–173
- Buccolingual positioning, 69
- CAD/CAM Atlantis abutments, 133f, 135f
- CAD/CAM titanium milled bar, 52, 52f
  - advantages of, 55
  - Nobel Biocare and, 54
- CBCT. *See* Cone-beam computed tomography (CBCT)
- Cemented bridges, 149, 151–152
  - advantages, 155
  - customized abutments, 156, 160
  - disadvantages, 155
- Cemented restorations
  - impression verification for all techniques, 165
- Cemented/screw-retained crowns, 27, 27f–28f
- Chlorhexidine gluconate, 61
- Clinical examination
  - of edentulous space/ridge, 18–19
  - extraoral/intraoral, 15
  - for fixed bridge, 35, 36f–38f
  - for single tooth replacement, 21–23, 22f–24f
- Clix system, 52, 53f
- Cobalt-chromium-based maxillary overdenture, 212f
- Complications
  - prosthetic, 193
    - fixed, 196–197
    - implant fractures, 198
    - removable, 197
  - screw and abutment connections, 197
  - single tooth units, 194–196
  - surgical sequelae and
    - damage to neurovascular structures, 193
    - early implant failures, 192
    - fractures, 193
    - wound dehiscence, 191
- Composite, 173
- Computed tomography (CT) scans
  - advantages of, 39
  - for fixed bridge, 38–39
  - and implant overdentures, 50–51
  - for single tooth replacement, 23–26, 24f–26f, 27f
- Cone-beam computed tomography (CBCT), 39, 50
- Configuration, of implant site
  - fixed bridge and, 39–43, 41f–43f
- Controlling variables, in implant placements, 69–76
  - buccolingual positioning, 69
  - implant angulation, 69–70, 73f, 74f
  - mesiodistal positioning, 69
- Crest splitting, in implant placement, 107, 108, 112f, 113f–114f
- CT scans. *See* Computed tomography (CT) scans
- Decalcified freeze-dried bone allograft (DFDBA), 92
- Dehiscences, in implant placement, 107, 110f, 111f–112f
- Dental implants
  - age, 2–3
  - bleeding disorders, 4
  - patient factors, 1
  - poor bone quality, 3–4
  - poorly controlled systemic disease, 4
  - previous radiotherapy to the jaws, 4
  - severe mucosal lesions, 3
  - tobacco smoking and drug abuse, 3
  - untreated dental disease, 3
- Dental panoramic tomograph (DPT), 19, 19f, 26, 27f, 47f
  - for fixed bridge, 38
  - and implant overdentures, 50–51, 50f
  - Scanora, 50f
- Dentures. *See also* Overdentures, implant defined, 46
  - existing, examination of, 48–50, 48f–50f
  - maximum thickness of, 49f
  - removable, 44, 46

- Deproteinized bovine bone mineral, 92  
for implant placement, 92
- DFDBA. *See* Decalcified freeze-dried bone allograft (DFDBA)
- Diagnostic setup  
for fixed bridge, 35, 38f  
implant restorations, 19  
single tooth replacement, 26
- Diamond discs, for bone grafting  
contra-angled and straight handpieces for use of, 94, 94f
- Dilation, in implant placement, 107, 108, 112f, 113f–114f
- Distraction osteogenesis, 108, 110
- Dolder® bar clips, 189f
- Dolder bars, 54, 54f
- DPT. *See* Dental panoramic tomograph (DPT)
- Edentulous space/ridge  
clinical examination of, 18–19  
evaluation of, 17–19, 18f–19f  
fibrous replacement in, assessment of, 49f  
mapping of, 21  
measurement of, 21, 23f
- Edentulous space/ridge, evaluation of, 17–19, 18f–19f
- Essix splint, 44
- Extraction sites, management of, 106, 107
- Facebow transfer, 187f
- Fenestrations, in implant placement, 107, 110f, 111f–112f
- Fissure burs, for harvesting blocks of bone, 94
- Fixed bridge  
clinical examination for, 35, 36f–38f  
diagnostic setups, 35, 38f  
implantation, planning for, 35–44  
numbers/distribution, 39–43, 40t, 41f–43f  
implant placement of, 77–81  
angulation, 80–81, 81f  
positioning/installation, 77  
spacing requirements, 77–80, 78f–80f  
radiography for, 38–39, 39f–41f  
treatment schedules, 44  
vs. multiple single units, 43–44
- Flaps, 60f, 62  
design for implant surgery. *See* Flap design  
elevation of, 63
- Flap design  
for abutment connection surgery, 65–68, 67f–68f  
in aesthetic zone, 63  
edentulous maxilla/mandible, 63–65, 64f–65f  
for implant surgery, 63–68  
for single tooth implant, 63
- Flat top implant systems, 77
- Fractured Branemark abutment screw, 197f
- Frialit 2 implant, 138f
- Frialit system, 77, 79  
installation of, 80f
- GBR. *See* Guided bone regeneration (GBR)
- Gingival height, 182f
- Gingival retraction cord, 142f
- Gold, 171–172
- Gold cap Astra, 52, 53f
- Gold-ceramic bridge, 151f, 152f
- Guided bone regeneration (GBR), 63, 92–93, 93f
- Hygiene maintenance requirements, routine.  
*See also* Maintenance  
fixed bridges and removable  
prostheses, 205  
scaling of implant prostheses, 205  
single tooth restorations, 203, 205
- Hypodontia, 17f
- I-CATVision, 41
- Implant  
head impressions, 138–139
- Implant design  
implant-abutment design, 7–9  
implant diameter, 4–5  
implant length, 4  
implant shape, 5  
surface characteristics, 5–7
- Implant head  
impressions, 140–141  
level of, 81  
vertical position of, 72, 75, 75f, 76, 76f
- Implant overdentures, 46–56  
assessment of patient and, 48  
completion of the implant overdentures, 188–189  
confirmation of cast relationship on the articulator, 187–188  
custom tray construction and final impressions, 181–183  
diagnosis of, 51, 51f–52f  
existing dentures, examination of, 48–50, 48f–50f  
indications for  
as definitive treatment, 46, 47f–48f  
as provisional prostheses, 46  
insertion of the implant overdentures, 189–190  
maintenance schedule, 190  
overview of, 46  
radiographic assessment, 50–51, 50f  
recording primary impressions, 181  
recording the maxillomandibular relationship, 183, 185–186  
and retention device, 55–56  
selection of abutments, 181  
selection of denture teeth, 186–187  
single-stage/two-stage, 56  
treatment planning, 51, 51f–52f  
verification of final cast, 183
- Implant placement, grafting procedures for, 91–119  
autogenous bone grafting, 91, 93–102, 94f, 95f, 96f–97f, 98f–99f, 100f  
bone graft materials. *See* Bone grafts  
materials  
crest splitting and dilation, 107, 108, 112f, 113f–114f  
dehiscences and fenestrations, 107, 110f, 111f–112f  
distraction osteogenesis, 108, 110  
extraction sites, management of, 106, 107  
GBR membranes, 92–93, 93f  
intraoral harvesting. *See* Intraoral harvesting  
harvesting  
large alveolar defects, surgical management of, 102, 102f, 103f–104f  
nerve transpositioning/obliteration, 110, 111, 114f, 115f–116f  
overview, 91  
sinus lift, procedures, 102, 104–106, 105f–106f, 107f  
soft tissue grafting techniques. *See* Soft tissue grafting techniques  
transalveolar sinus floor elevation, 106, 108f, 109f–110f
- Implant restorations  
single tooth. *See* Single tooth replacement  
treatment planning for, 15–20  
clinical examination, 15  
overview of, 15  
screening radiograph, 19  
study casts/diagnostic setups, 19  
vertical position of, 72, 75, 75f, 76, 76f
- Impregum, 157f, 161f
- Impression coping, 126f
- Impression verification stent, 185f
- Intraoral harvesting, for implant placement, 93–102, 94f, 95f  
bone trap used for harvesting bone chips, 98f–99f  
diamond discs in, 94, 94f  
fissure burs for, 94  
iliac crest, extraoral site for, 99, 100f  
Micros instruments in, 99  
osseous coagulum in, 95, 98f–99f, 99  
piezosurgery in, 94  
Safescraper® TWIST in, 99, 99f  
sites, 94–95, 95f, 96f–97f, 98f  
stability and protection of, 99  
titanium screws and, 100f–101f  
trephine specimens for, 94–95, 95f, 96f–97f
- Keratinized tissue, 18–19, 63
- Loading conditions, 11–12  
loading protocols, 12
- Locator® abutment, 52, 53f, 54f, 55, 182f, 209f
- Locator housing cap, 212f
- Locator impression coping, 184f. *See also* Abutment impression coping
- Maintenance  
prosthetic, 193  
fixed, 196–197  
implant fractures, 198  
removable, 197  
screw and abutment connections, 197  
single tooth units, 194–196
- Mandibular bridge, 206f
- Mandibular molar  
replacement with single 5-mm diameter Astra Tech, 33f
- Mandibular overdentures, 55
- Mandibular ridge, 47f  
with Sjogren's syndrome, 48f
- Maxillary central incisor tooth  
intraoral radiograph of, 24f  
labial view of missing, 25f  
lower right, replacement of, 23f  
small upper, replacement of, 22f  
upper right, replacement with Nobel Biocare implant, 24f
- Maxillary first molar, radiograph of, 33f, 34f
- Maxillary open tray technique, 184f
- Maxillary overdentures, 55–56
- Mesiodistal positioning, 69
- Metal-ceramic bridge, 159f
- Micros instruments, in intraoral harvesting, 99
- Midcrestal incision  
flap design and, 63
- Milled bar, 52, 52f
- Milled titanium Hader® bar, 188f
- Molars, replacement of, 30–34  
single-implant solutions for, 30, 32f–34f  
two-implant solution for, 30, 31f–32f
- Nerve transpositioning/obliteration, in implant placement, 110, 111, 114f, 115f–116f
- Nobel Biocare®, 54, 54f–55f  
abutment impression copings, 163f  
abutment try-in kit, 162f  
bar/clip system, 56  
implants, 78f, 79f, 125f, 135f, 142f, 153f  
2.25-mm ball attachments, 55f  
replacement of maxillary canine with, 24f
- Nobel Biocare EsthetiCone  
bridge abutments, 156f
- Occlusion, examination of, 21, 24f
- Onlay graft, in implant placement, 110, 115f
- Osseosconduction, in bone grafting, 91

- Osseointegration, in bone grafting, 91  
 Osseointegration, 1, 4  
 Osseous coagulum, in intraoral harvesting, 95, 98f–99f, 99  
 Overdentures, implant, 46–56.  
   *See also* Dentures  
   assessment of patient and, 48  
   diagnosis of, 51, 51f–52f  
   existing dentures, examination of, 48–50, 48f–50f  
   indications for  
     as definitive treatment, 46, 47f–48f  
     as provisional prostheses, 46  
   overview of, 46  
   radiographic assessment, 50–51, 50f  
   and retention device, 55–56  
   single-stage/two-stage, 56  
   treatment planning, 51, 51f–52f
- Peri-implantitis, 202–203  
   management of, 203  
 Piezosurgery, for harvesting blocks of bone, 94  
 Poor occlusal contact, 187f  
 Porcelain, 172  
 Porcelain CerAdapt abutments, 135f  
 Postinsertion complications and maintenance schedule, 213–214  
 Procera crowns, 135f  
 Prosthetic complications, 193  
   fixed, 196–197  
   implant fractures, 198  
   removable, 197  
   screw and abutment connections, 197  
   single tooth units, 194–196  
 Prosthodontic complications  
   postinsertion complications and maintenance  
     continued bone resorption, 212  
     difficulty with speech, 213  
     failure of integration of one or more implants, 210  
     fracture of ball attachment or implant, 210  
     fracture or wear of denture and components, 210–212  
     overgrowth of mucosa under bar, 212  
   before the prosthodontic phase of treatment  
     failure of bone graft preventing implant placement, 208  
     failure of integration of one or more implants, 208  
     placement of implants in an unplanned position, 208  
   during the prosthodontic phase of treatment, 208–210  
 Provisional restorations, 27, 28–29, 44  
   adhesive bridgework, 28–29  
   removable partial dentures, 27, 28  
 Push-on impression copings, 122f. *See also* Abutment impression copings
- Radiographic bone loss, 1  
 Radiography, 19  
   CT scans. *See* Computed Tomography (CT) scans  
   dental panoramic tomograph. *See* Dental panoramic tomograph (DPT)  
   for fixed bridge, 38–39, 39f–41f  
   for implant overdentures, 50–51, 50f  
   for single tooth replacement, 23–26, 24f–26f, 27f  
 Reline material, soft, 156f  
 Removable dentures, 44, 46  
 Removable partial dentures, 27, 28  
 Ridge, edentulous. *See* Edentulous space/ridge
- Safescraper® TWIST, in intraoral harvesting, 99, 99f  
 Scanora, 50f  
 Scanora DPT, 50f  
 Scanora (Soredex, Finland), 26  
 Screw-retained bridges, 149, 151–152, 161–162  
   advantages of, 152  
   angled abutments, 155  
   disadvantages of, 152  
   impression materials, 162–163  
   impression trays, 162  
   pick-up impressions (open tray technique), 163  
   reseating impressions (closed tray technique), 163, 165  
 Screw-retained crowns, 27, 27f–28f  
 Sealed occlusal rims, 186f  
 Shim stock, 174f  
 Short-span and long-span bridges, 149  
 SimPlant software, 39, 39f  
 Single tooth replacement, 21–29  
   in anterior maxilla, 69–76  
     controlling variables in, 69–76  
     cemented/screw-retained crowns, 27, 27f–28f  
   clinical examination, 21–23, 22f–24f  
   diagnostic setup, 26  
   flap design for, 63  
   overview, 21  
   provisional restoration, 27, 28–29  
   radiography for, 23–26, 24f–26f, 27f  
   treatment schedule for, 29  
 Sinus lift, procedures, 102, 104–106, 105f–106f, 107f  
 Sjogren's syndrome, 46  
   mandibular ridge with, 48f  
 Soft tissue evaluation and problems, 198–200  
   deficiencies, 200  
   overgrowth, 200  
   persistent inflammation, 200  
 Soft tissue grafting techniques, 111, 112, 118–119  
   aesthetic soft tissue problems, 118–119, 119f  
   functional soft tissue problems, 112, 117f, 118, 118f
- Stents, surgical, 51, 51f  
   labial view of, 70f  
   placement of, 60–61, 60f–61f  
 Straumann ball abutments, 183f, 211f  
 Straumann implants, 137f, 150f, 176f  
 Straumann system, 54–55, 59, 60f, 77  
   spring, 55f  
 Study casts, implant restorations, 19  
 Submerged and nonsubmerged protocols, 9–10  
 Surgery, implant, 57–62  
   and bone injuries, 57  
   factors to control in, 57  
   flap design for. *See* Flaps  
   initial stability of, 57, 59, 60  
   postoperative care, 62  
   preoperative care, 61–62  
   preparation of, 57, 58f–60f, 59–60  
   and single tooth replacement. *See* Single tooth replacement  
   stent placement, 60–61, 60f–61f  
 Surgical sequelae and complications  
   damage to neurovascular structures, 193  
   early implant failures, 192  
   fractures, 193  
   wound dehiscence, 191  
 SynOcta® abutment, 55  
 SynOcta bridge abutments, 150f
- Tissue level implant systems, 77, 81  
 Titanium, 172  
 Tobacco smoking and drug abuse  
   and dental implants, 3  
 Transalveolar sinus floor elevation, 106, 108f, 109f–110f  
 Treatment  
   for fixed bridge, 44  
   for implant restorations, 15–20  
     clinical examination, 15  
     overview, 15  
     screening radiograph, 19  
     study casts/diagnostic setups, 19  
   planning for implant overdentures, 51, 51f–52f  
   for single tooth replacement, 29  
 Trephine specimens, for harvesting blocks of bone, 94–95, 95f, 96f  
 Try-in kits, 160–161
- UniAbutments, 165f
- Wider-diameter implants, of molars, 30, 32f–34f  
 Working casts, 187f
- Xenografts, for implant placement, 91, 92
- Zirconia abutments, 134f



# Implants in Clinical Dentistry

## Second Edition

### About the book

Dental implants that integrate with bone are a very popular option for tooth replacement; they are, however, very demanding for the practitioner to plan and implement properly, and although there has been technical consolidation between different systems there are still important considerations remaining between them. This new edition of the best-selling guide to current implant systems considers the practical features that a clinician needs to know for successful treatment planning, surgical placement, prosthodontics and long-term maintenance.

### CONTENTS

Overview of implant dentistry • Treatment planning for implant restorations: general considerations • Single tooth planning in the anterior region • Single tooth planning for molar replacements • Fixed bridge planning • Diagnosis and treatment planning for implant overdentures • Basic factors in implant surgery • Flap design for implant surgery • Surgical placement of the single tooth implant in the anterior maxilla • Implant placement for fixed bridgework • Immediate and early replacement implants • Grafting procedures for implant placement • Single tooth implant prosthodontics • Fixed bridge prosthodontics • Implant overdentures • Complications and maintenance • Prosthodontic complications of implant treatment and maintenance of implant overdentures

### About the editors

**Richard M. Palmer**, PhD, BDS, FDS RCS(Eng), FDS RCS(Ed)  
Professor of Implant Dentistry and Periodontology  
King's College London Dental Institute

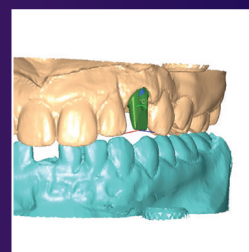
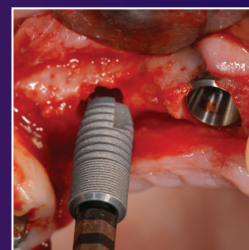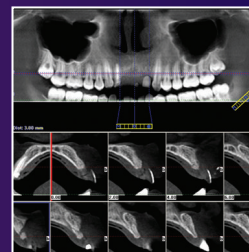**Leslie C. Howe**, BDS, FDS RCS (Eng)  
Head of Conservative Dentistry  
King's College London Dental Institute

**Paul J. Palmer**, BDS, MSc, MRD RCS (Eng)  
Consultant in Periodontology  
Guy's and St Thomas' NHS Foundation Trust

*With contributions from:*

**Kalpesh Bavisha**, BDS, MSc, FDS RCPS(Glasg)  
Consultant in Restorative Dentistry,  
Guy's and St Thomas' NHS Foundation Trust

**Mahmood Suleiman**, PhD, BDS, MSc, MFGDP  
Hon Specialist Clinical Teacher Implant Dentistry  
Guy's and St Thomas' NHS Foundation Trust  
Associate Specialist Maxillofacial Surgery  
Ashford and St. Peter's NHS Foundation Trust



### From reviews of the first edition:

“This is a well written and well illustrated book and will appeal to any dentist involved in, or looking to become involved in implant treatment. It would be an excellent first book on implants for the conscientious and motivated dentist.”  
*Dental Practice*

“This is a very welcome addition to the literature and amply reflects the broad experience of the authors. It is an excellent resume of the state of the art to date. This book was a pleasure to read. The use of bullet points to outline key details and structure the text gives the book clear and crisp style which is apparent from the first few pages.”  
*British Dental Journal*

“This title is characterised by its organisational rigour and its wide range of themes.”  
*Implant*

**informa**  
healthcare

Telephone House, 69-77 Paul Street, London EC2A 4LQ, UK  
52 Vanderbilt Avenue, New York, NY 10017, USA

[www.informahealthcare.com](http://www.informahealthcare.com)

[www.informahealthcarebooks.com](http://www.informahealthcarebooks.com)

ISBN 978-184184906-5



9 781841 849065